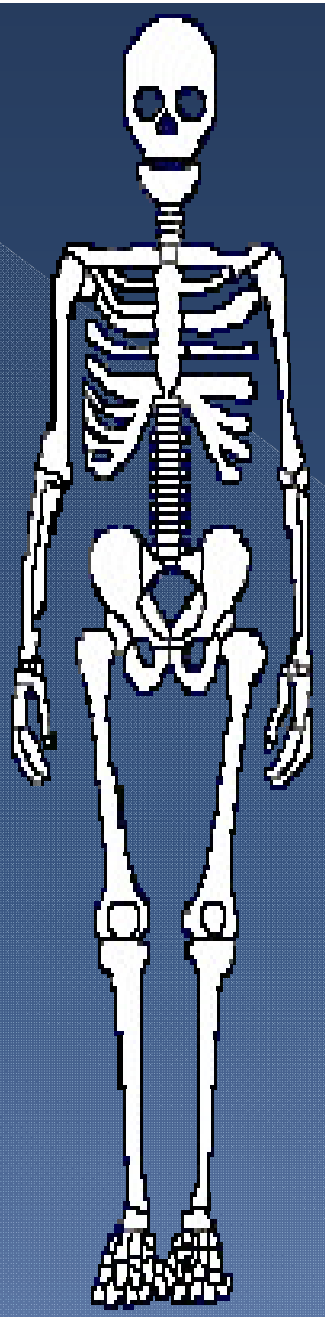

Bones

By: Katie, Connie, Ben, Mike, Shirley

What are the six main functions of bone?

A. Support of soft tissues of the body.

B. Protection of internal organs such as the brain (cranial bones), spinal cord (vertebral column), heart and lungs (rib cage), and reproductive organs (pelvic bones).

C. Facilitation of movement by serving as points of attachment for muscle organs.

D. Storage of minerals such as calcium and phosphorus.

E. Storage of blood cell producing tissues (red marrow). for hemopoiesis.

F. Storage of energy rich tissues (yellow marrow).

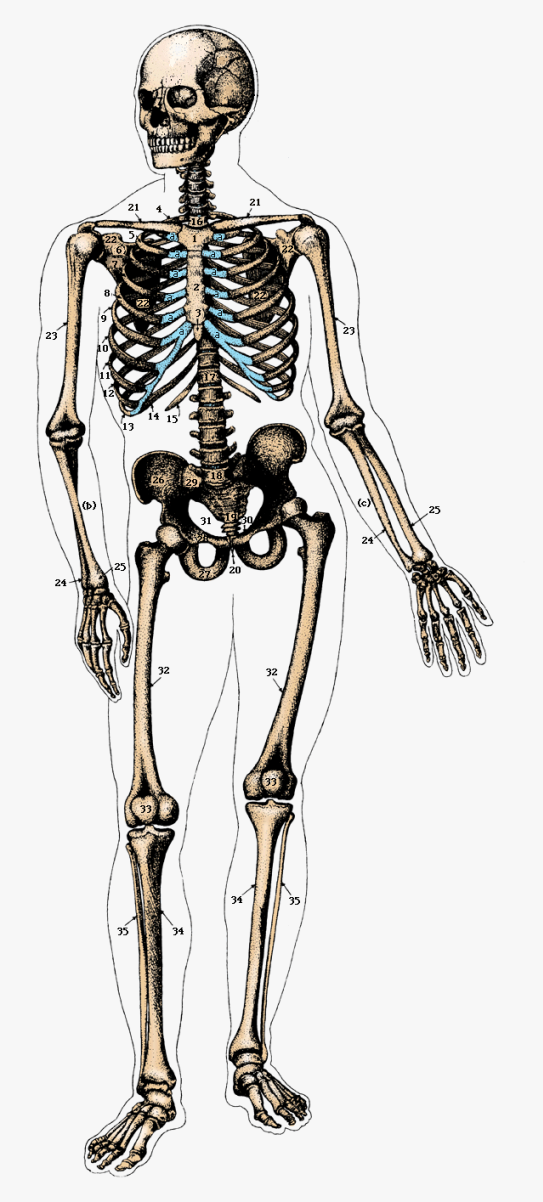

What type of basic tissue is bone?

- A.) Epithelial
- B.) Connective
- C.) Muscle
- D.) Nervous

Answer: B

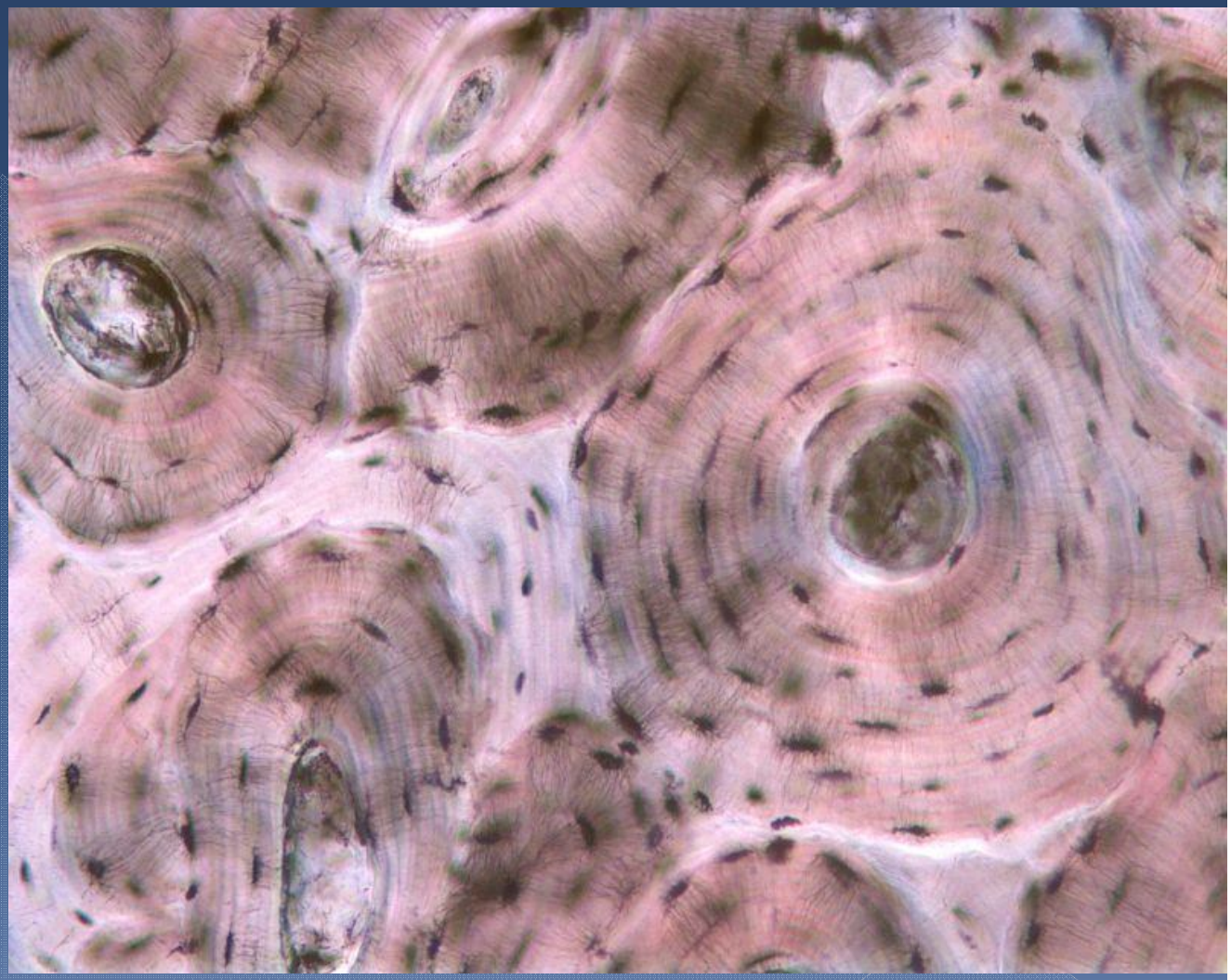

What are Osteons?

A.) Canals of interconnecting systems in the microscopic structure of adult compact bone.

B.) Systems of interconnecting canals in the macroscopic structure of adult compact bone.

C.) Systems of interconnecting canals in the microscopic structure of adult compact bone.

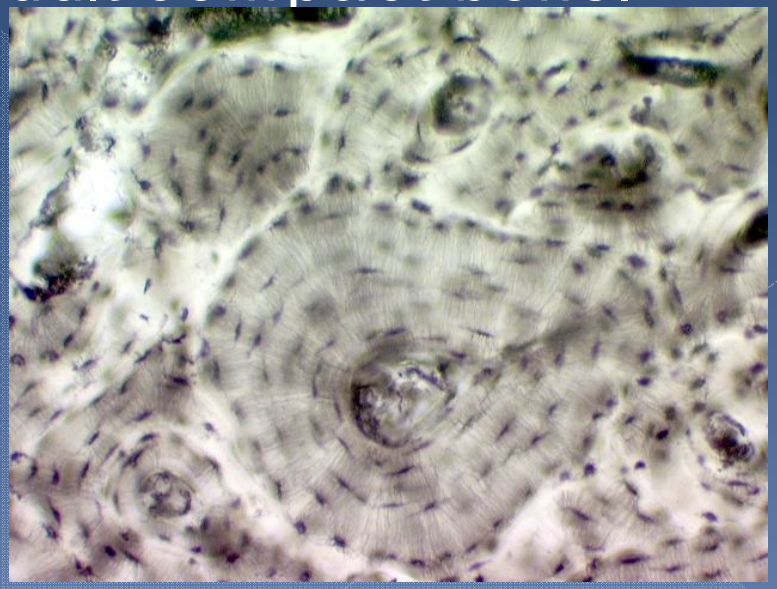

Wha es of tissue are fo in bones?

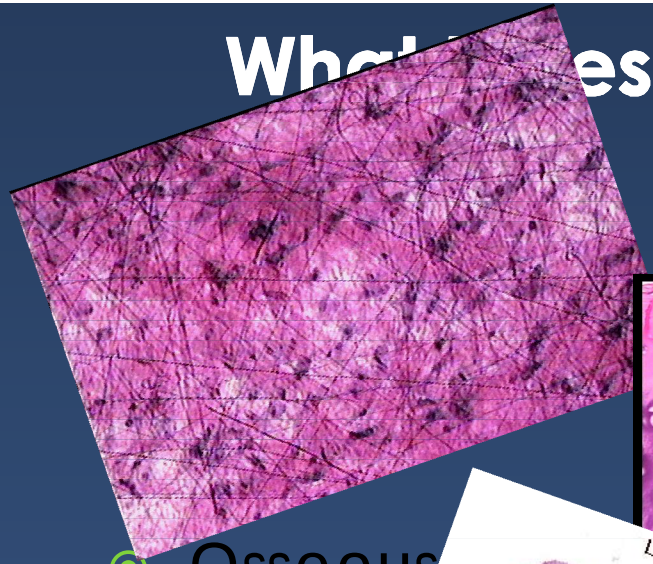

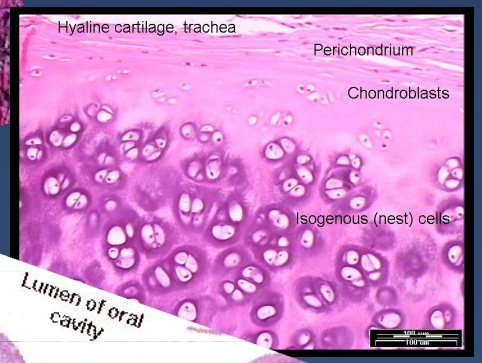

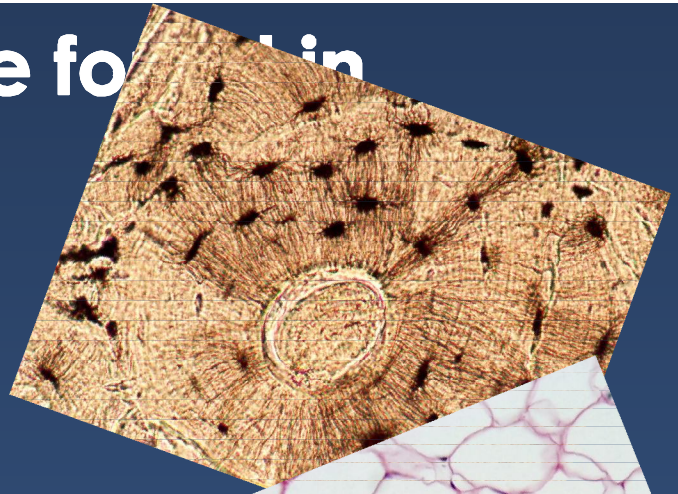

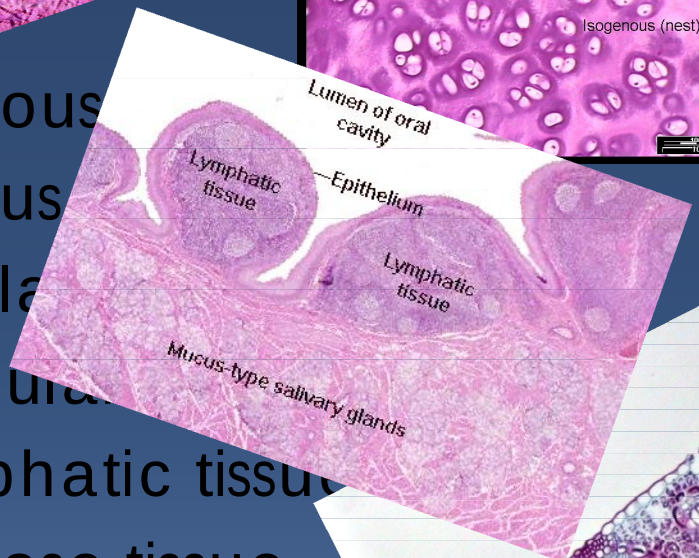



- Osseous
- Fibrous
- Cartila
- Vascula
- Lymphatic tissu
- Adipose tissue
- Nervous tissue

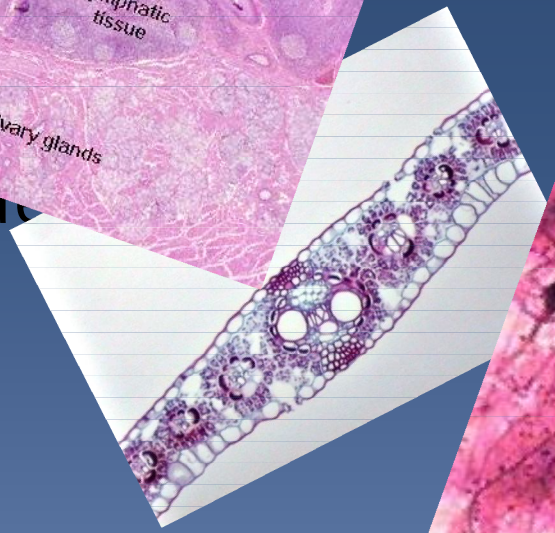

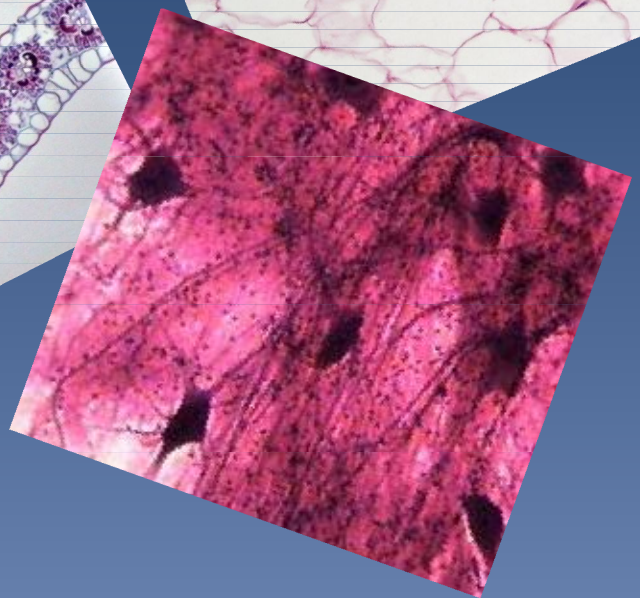

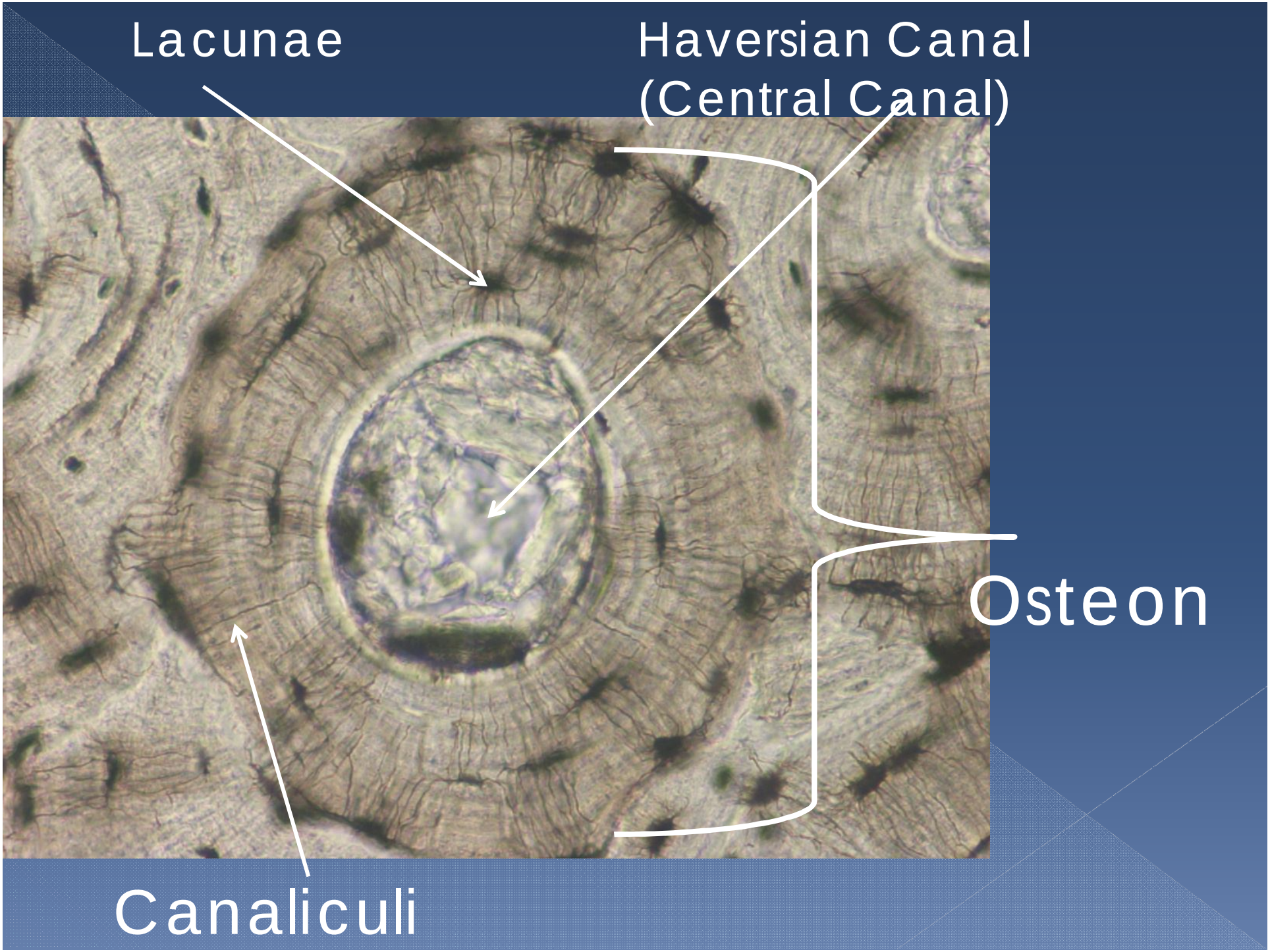
Lacunae
Haversian Canal
(Central Canal)
Osteon
Canaliculi

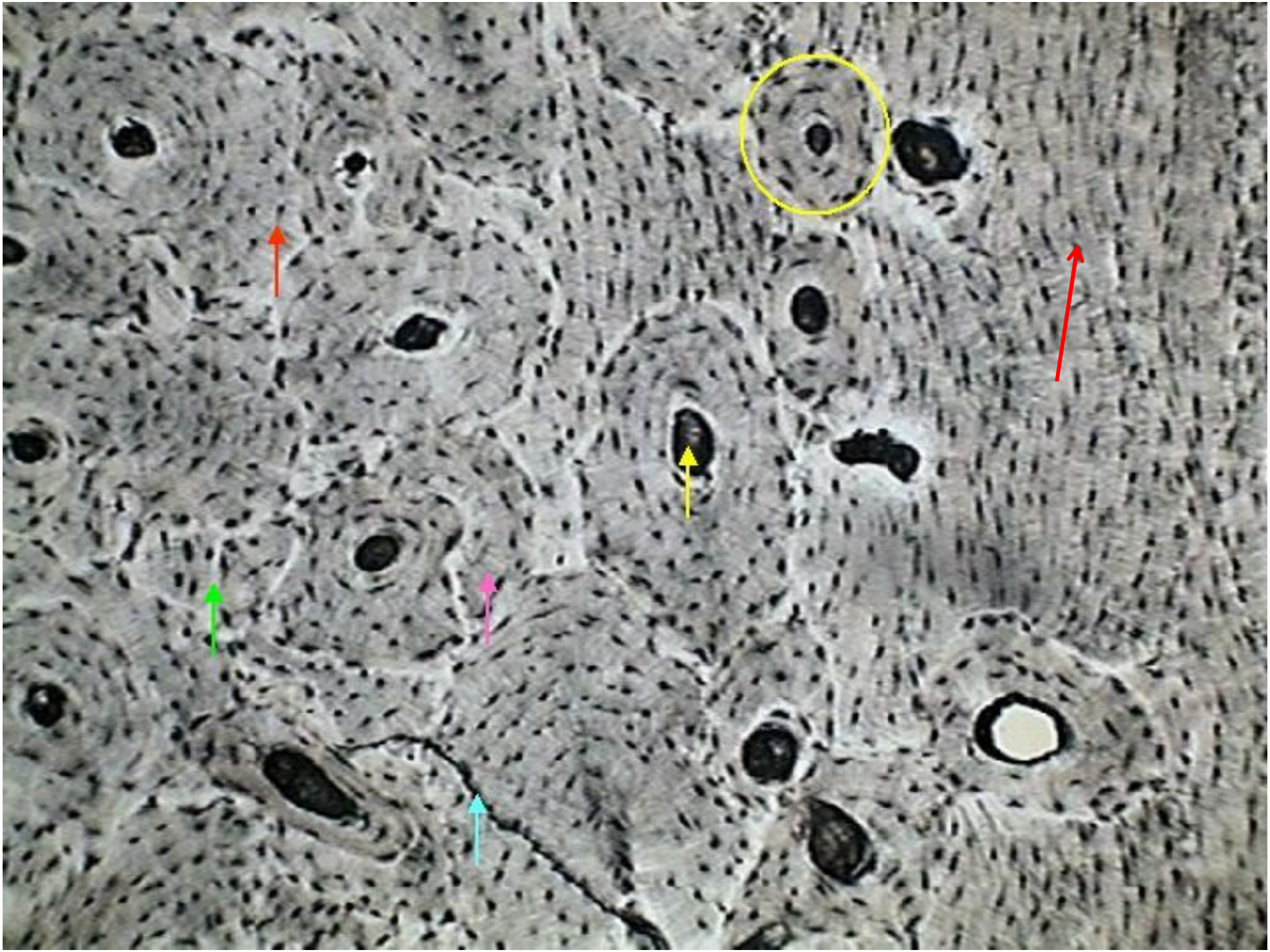

Label the arrows

What type of cell is this and where is it located?

Name the bone types:

- 1.) Flat
- 2.) Long
- 3.) Flat
- 4.) Irregular
- 5.) Long
- 6.) Sesamoid
- 7.) Short

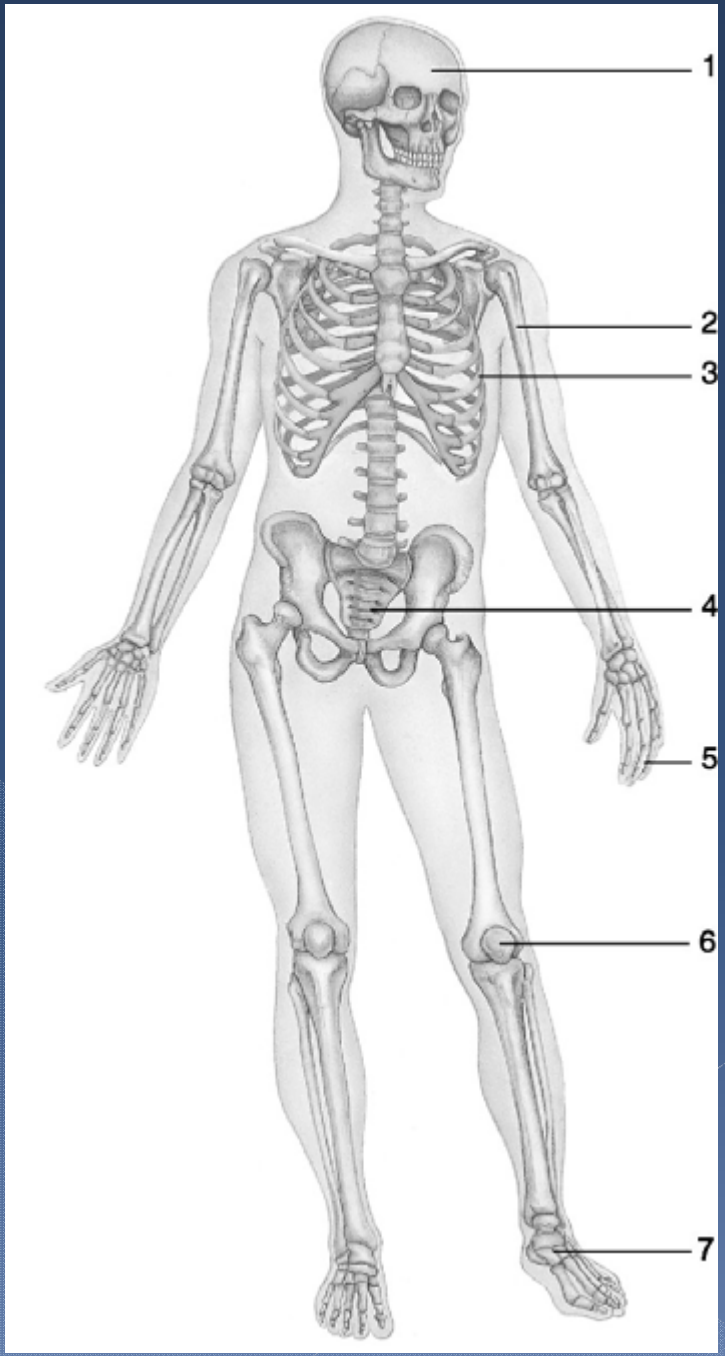

Name the bones of the appendicular Skeletal

- Bones of the upper and lower limbs (arms and legs)
- Bones of the pectoral girdle. (shoulder)
- Bones of the pelvic Girdle (Hip)

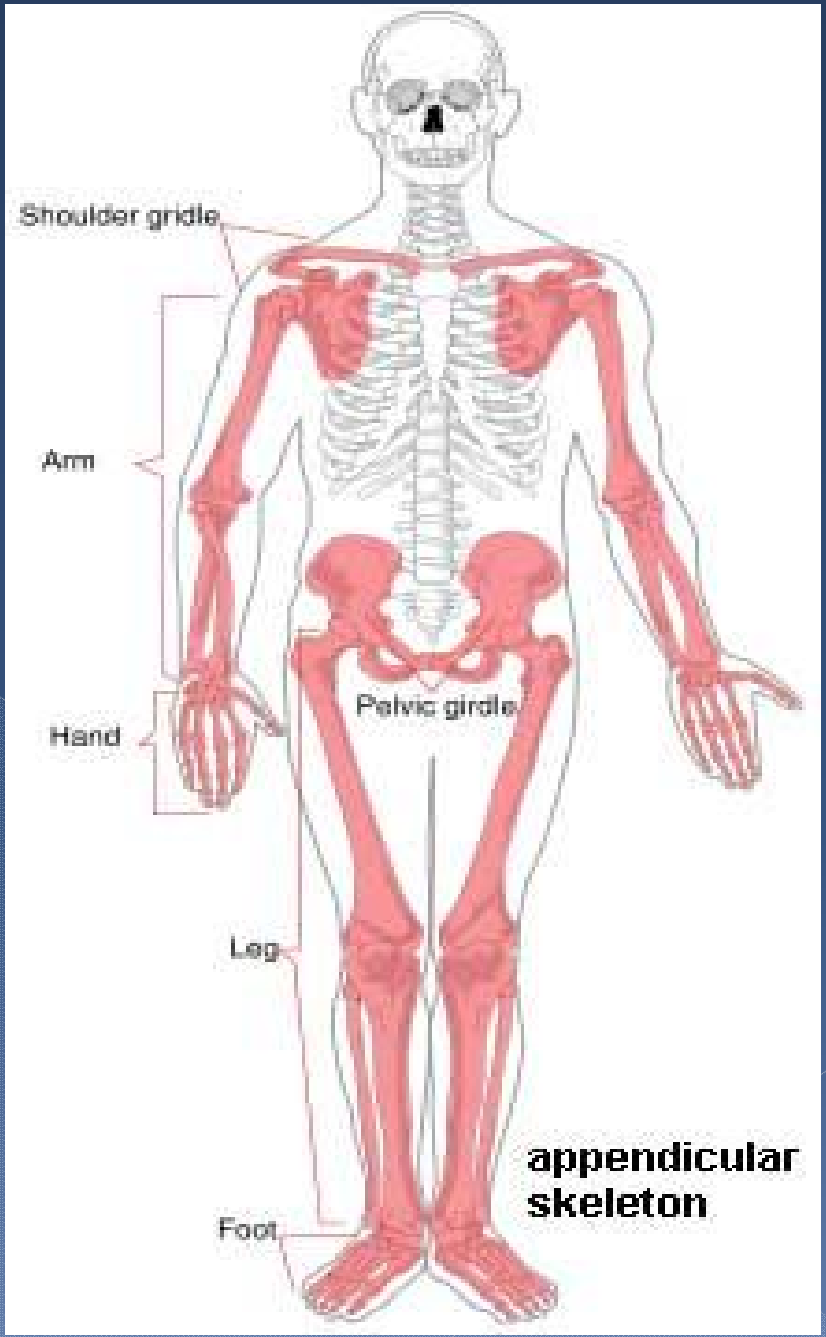

In general, the axial skeletal Consist of what bones?

- All the bones of the skull
- Rib cage
- Vertebral column

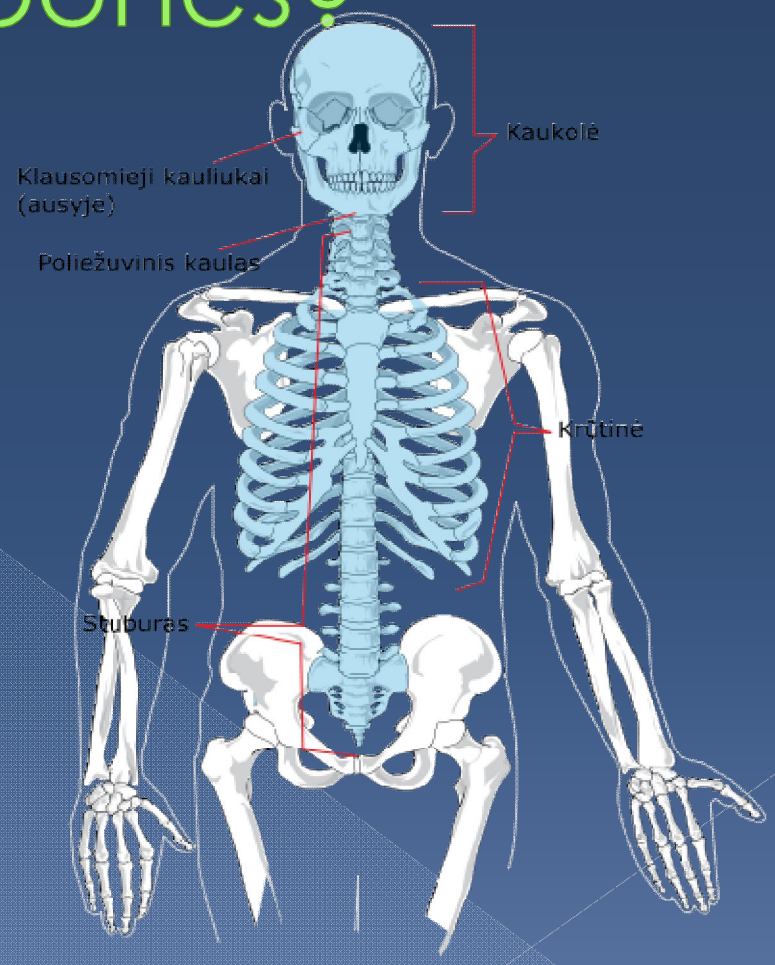

Match these descriptions:

- Clavicle
- Scapula
- Femur
- Ulna
- Tibia
- Phalanges
- Os coxae
- Metatarsals

- Attached to the patella by a ligament.
- Has no bony or ligamentous bonds to the thoracic cage, but it is extremely important for muscle attachment.
- Articulates with the manubrium of the sternum,.
- Longest, strongest, and heaviest bone in the body.
- Forms the medial support of the forearm.
- Formed from a fusion of three bones.
- Consist of 14 pairs of finger bones.
- Supports the sole of the foot, with the distal ends forming the ball of the foot.

Sutures:

- Connects occipital and temporal bones.
- Connects occipital and parietal bones.
- Connects temporal and parietal bones.
- Connects parietal and frontal bones.
- Connects right and left parietal bones.

- Coronal suture
- Sagittal suture
- Squamous suture
- Lambdoid suture
- Occipitomastoid suture

Name the 8 Cranial Bones:

- Frontal bone
- Parietal bones (2)
- Occipital bone
- Temporal bones (2)
- Sphenoid bone
- Ethmoid bone

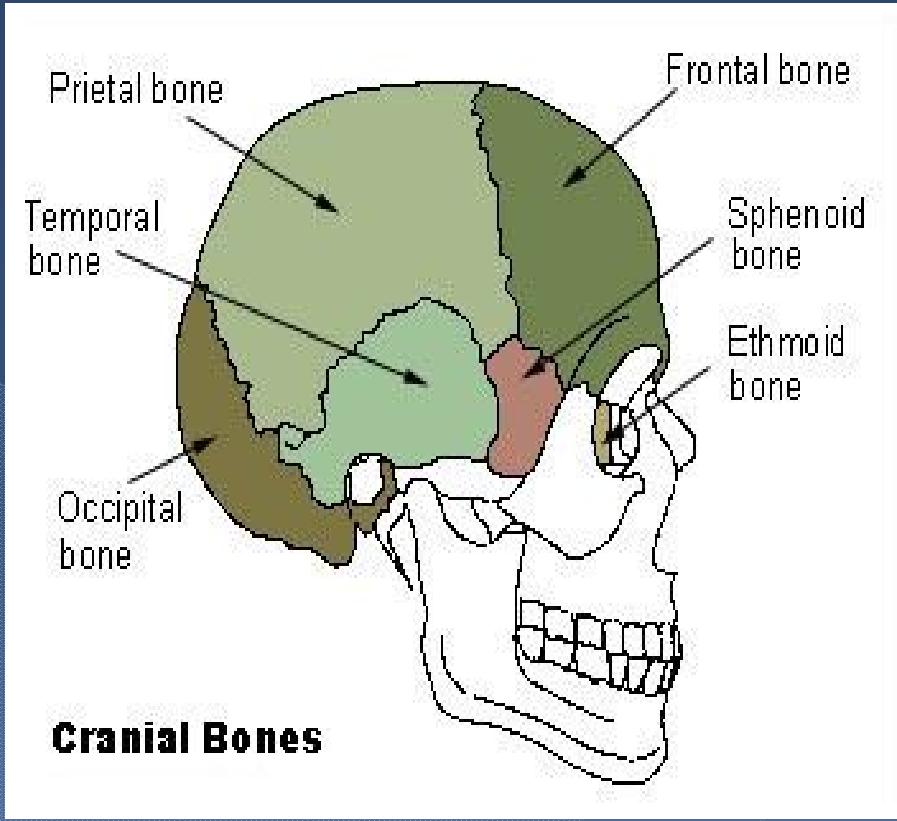

How many bones are in the middle ear and what are they?

- 6 bones
- Malleus
- Incus
- Stapes

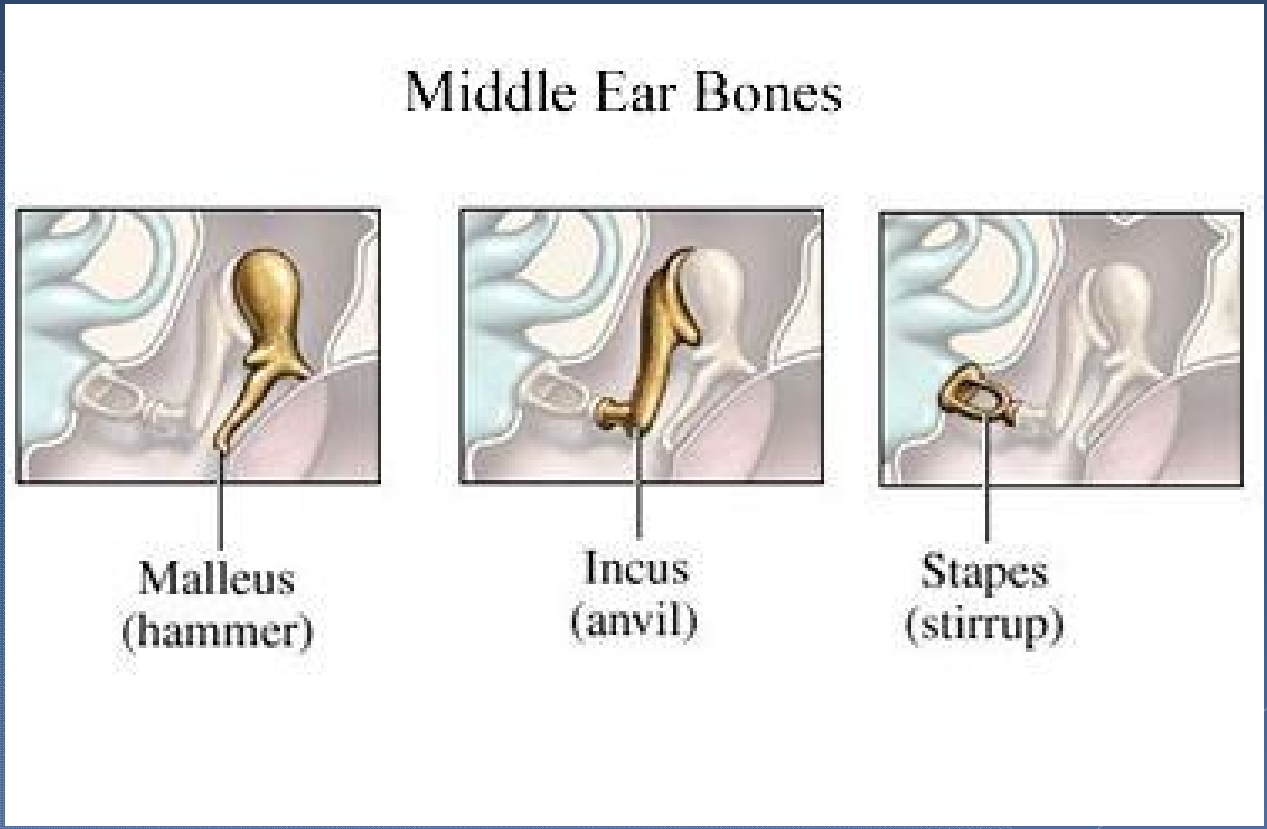

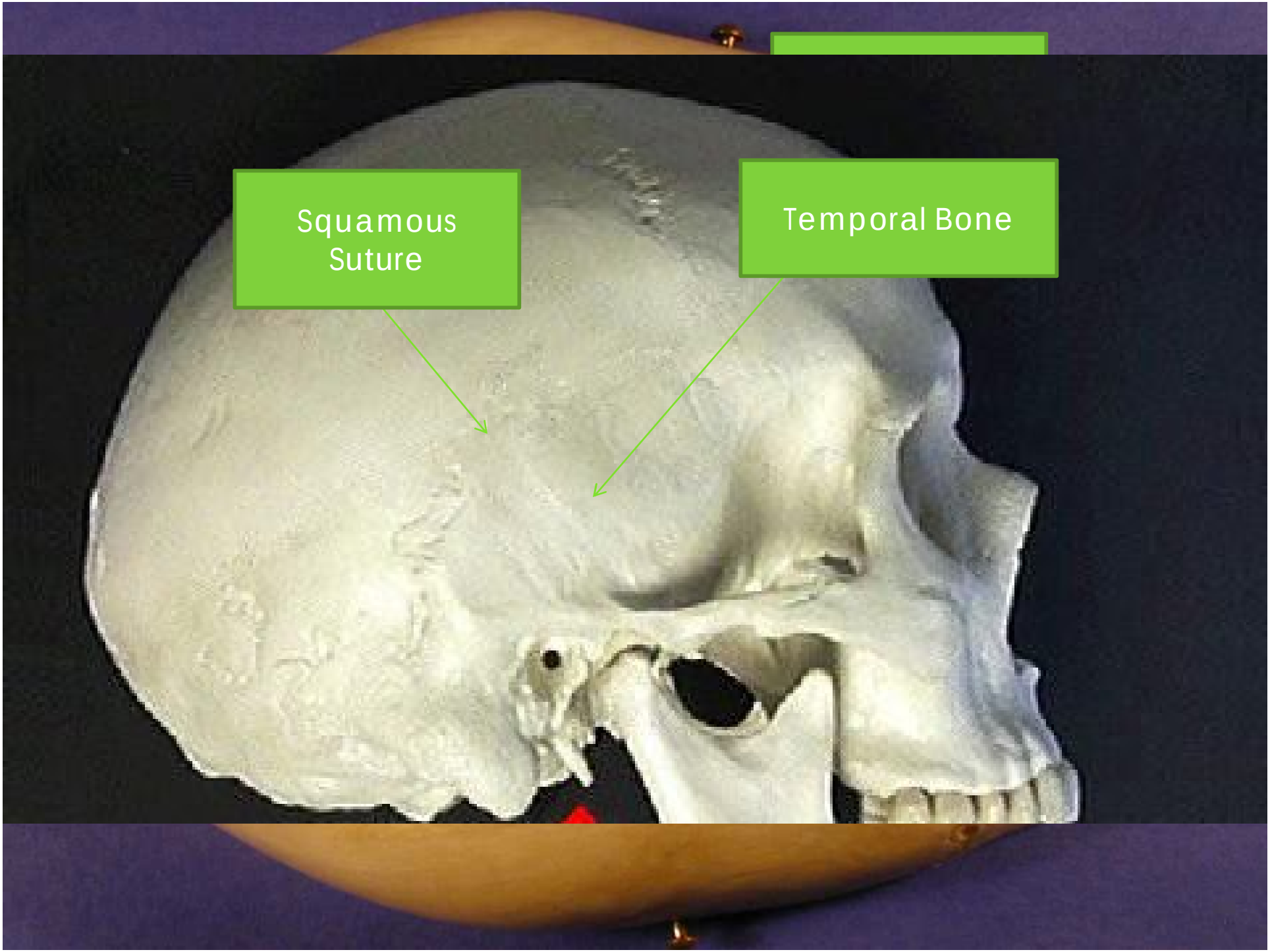
Squamous Suture
Temporal Bone

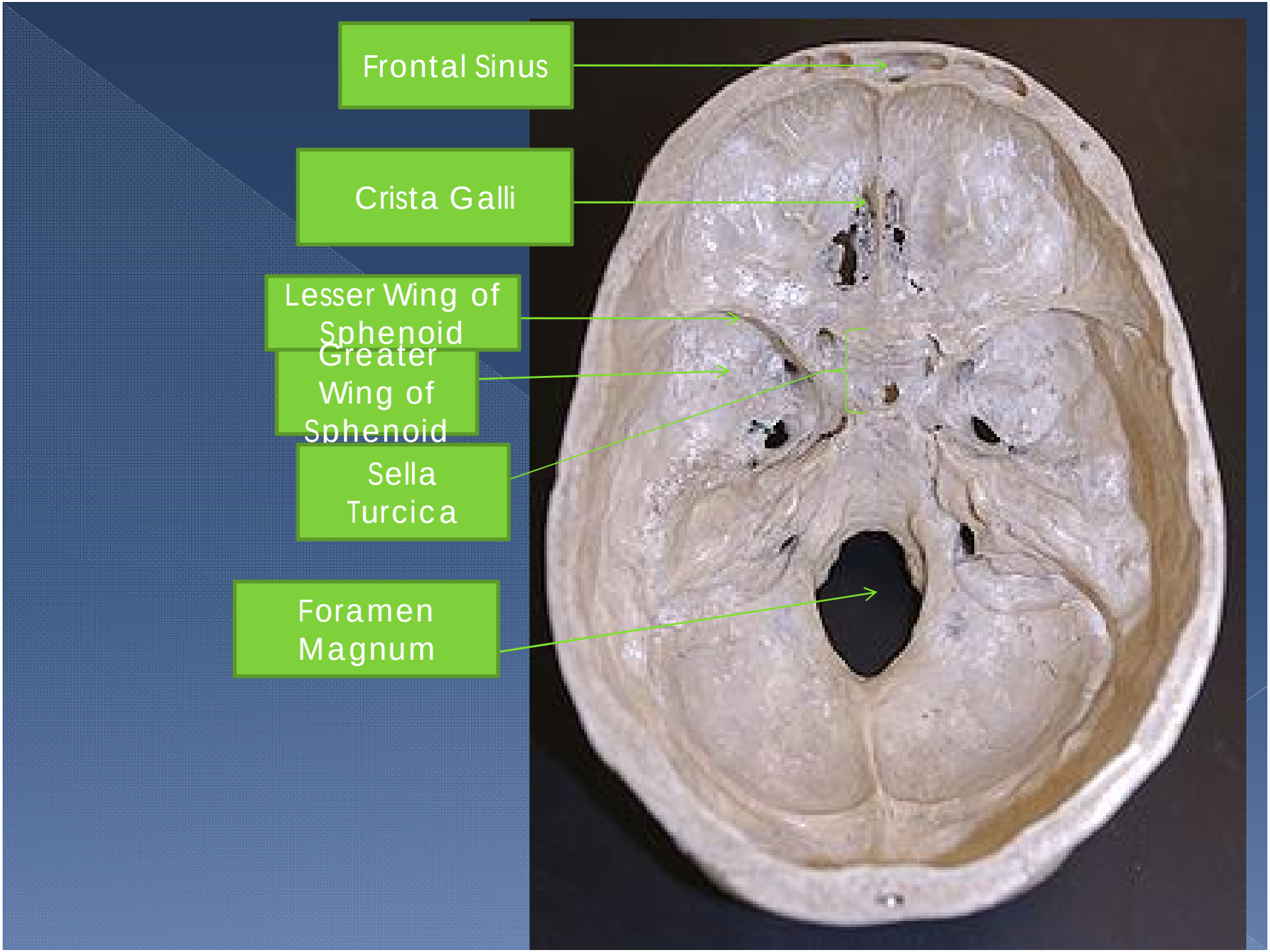
Frontal Sinus
Crista Galli
Lesser Wing of Sphenoid
Greater Wing of Sphenoid
Sella Turcica
Foramen Magnum

Occipital Bone

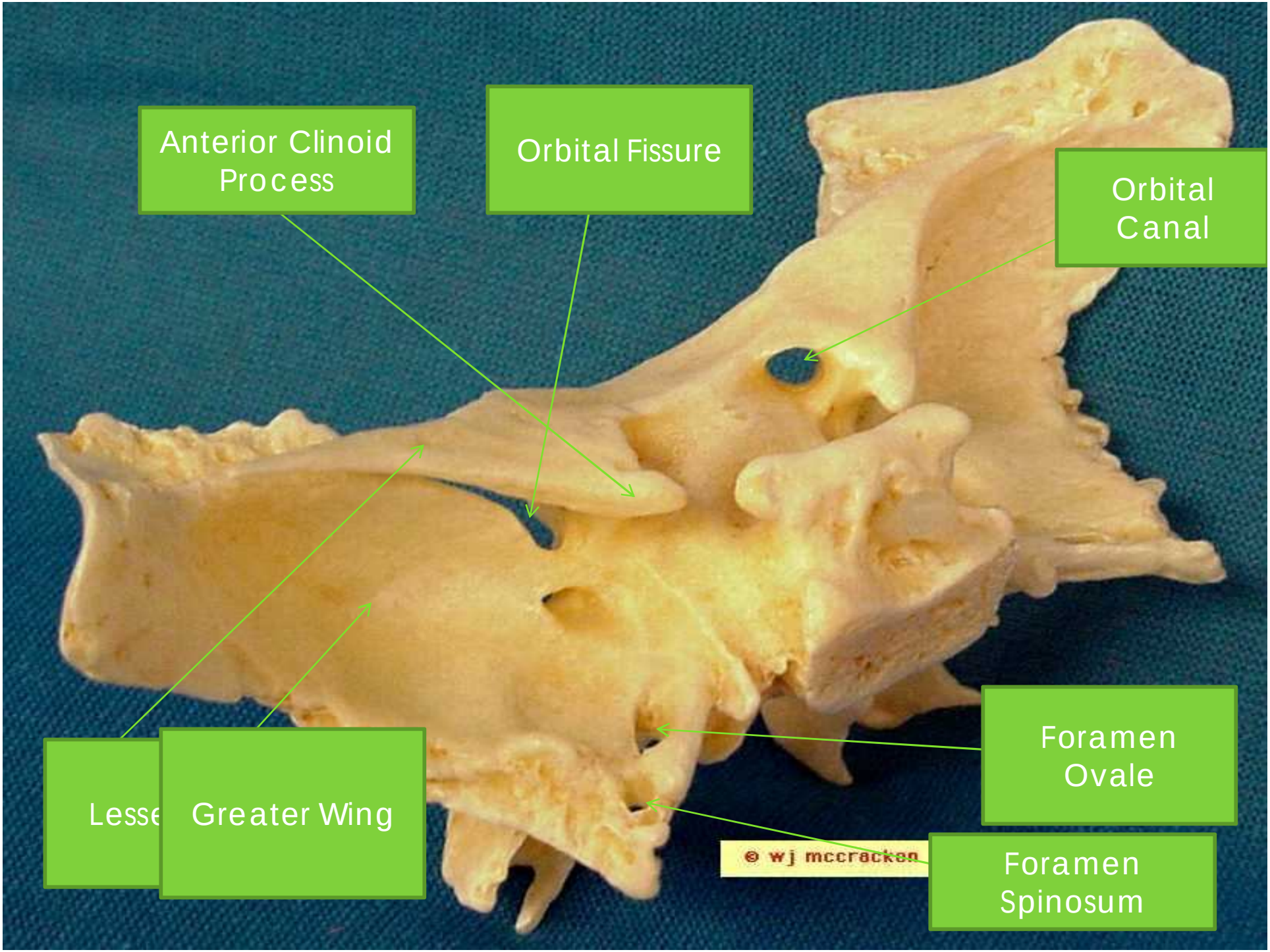
Anterior Clinoid Process
Orbital Fissure
Orbital Canal
Lesse
Greater Wing
Foramen Ovale
Foramen Spinosum
© wj mccracken

Name the 14 facial bones.

- Zygomatic bone (2)
- Superior and Inferior Maxilla
- Nasal Bone (2)
- Mandible
- Palatine Bone (2)
- Lacrimal Bone (2)
- Vomer bone
- Inferior Nasal Conchae

Label:



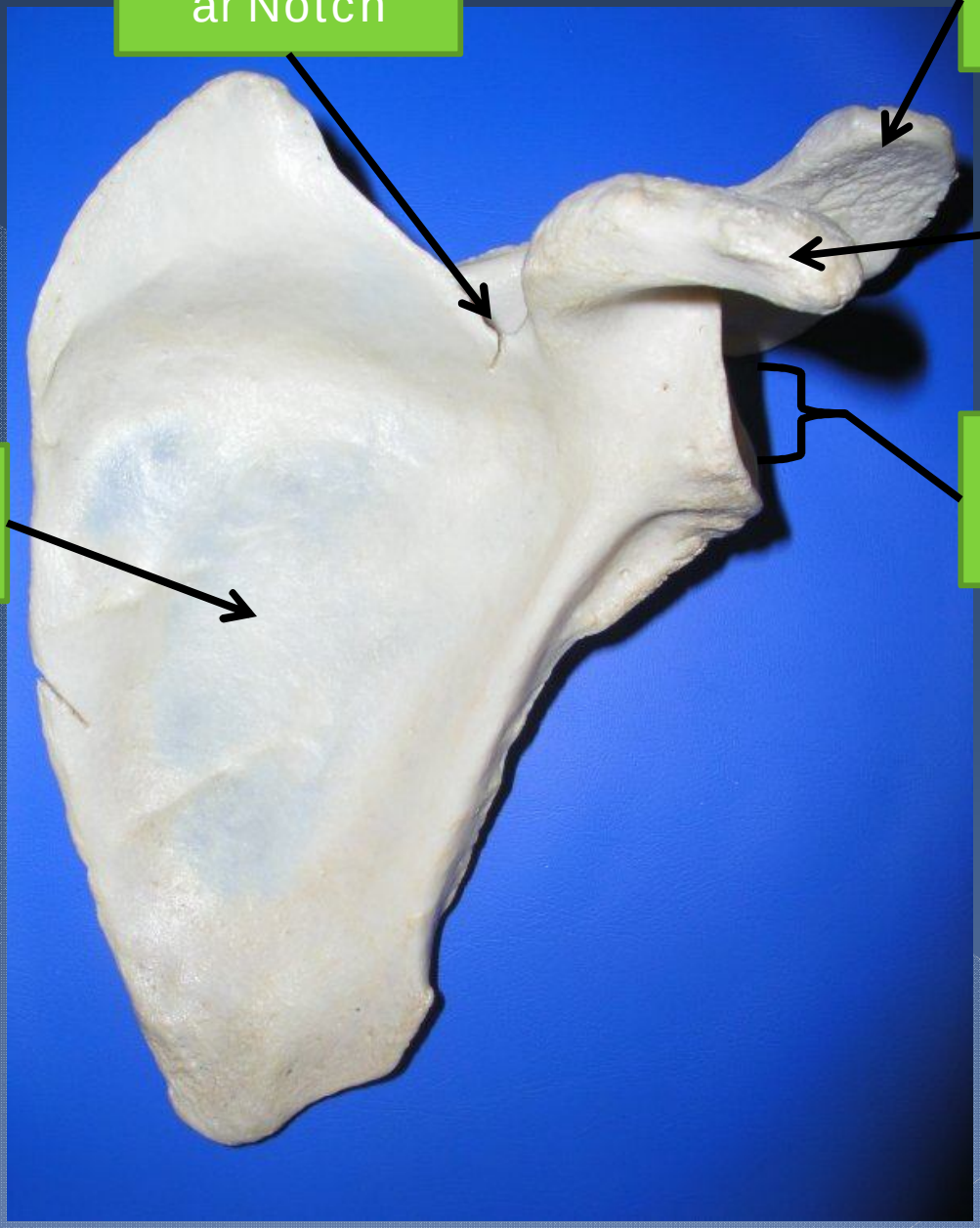
Suprascapular Notch
Acromion
Coracoid Process
Glenoid Cavity
Subscapular Fossa

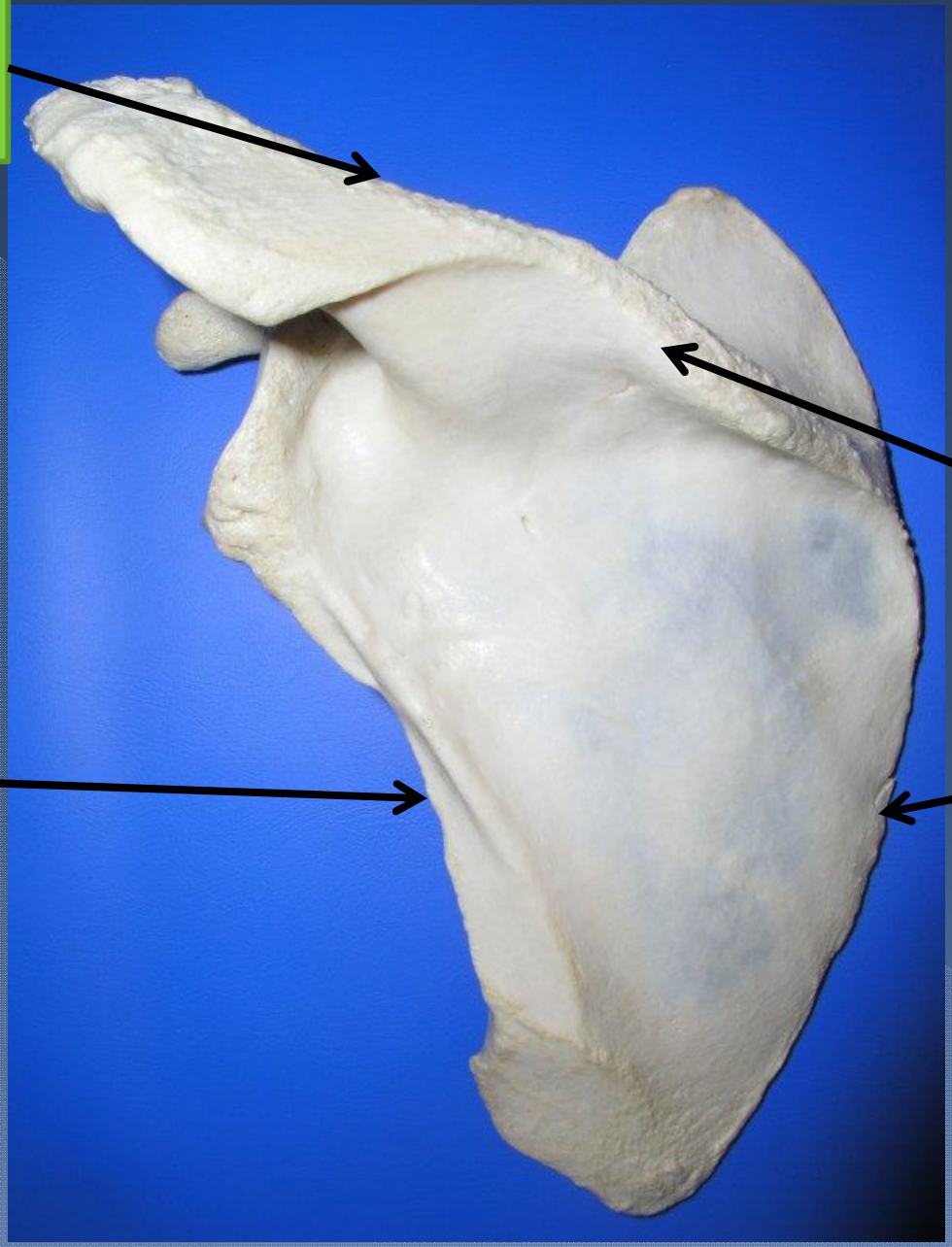
Superior Border
Spine of Scalpula
Lateral Border
Medial Border

Identify and label this bone:

Humerus

Right/left? Orientation?

Right, posterior

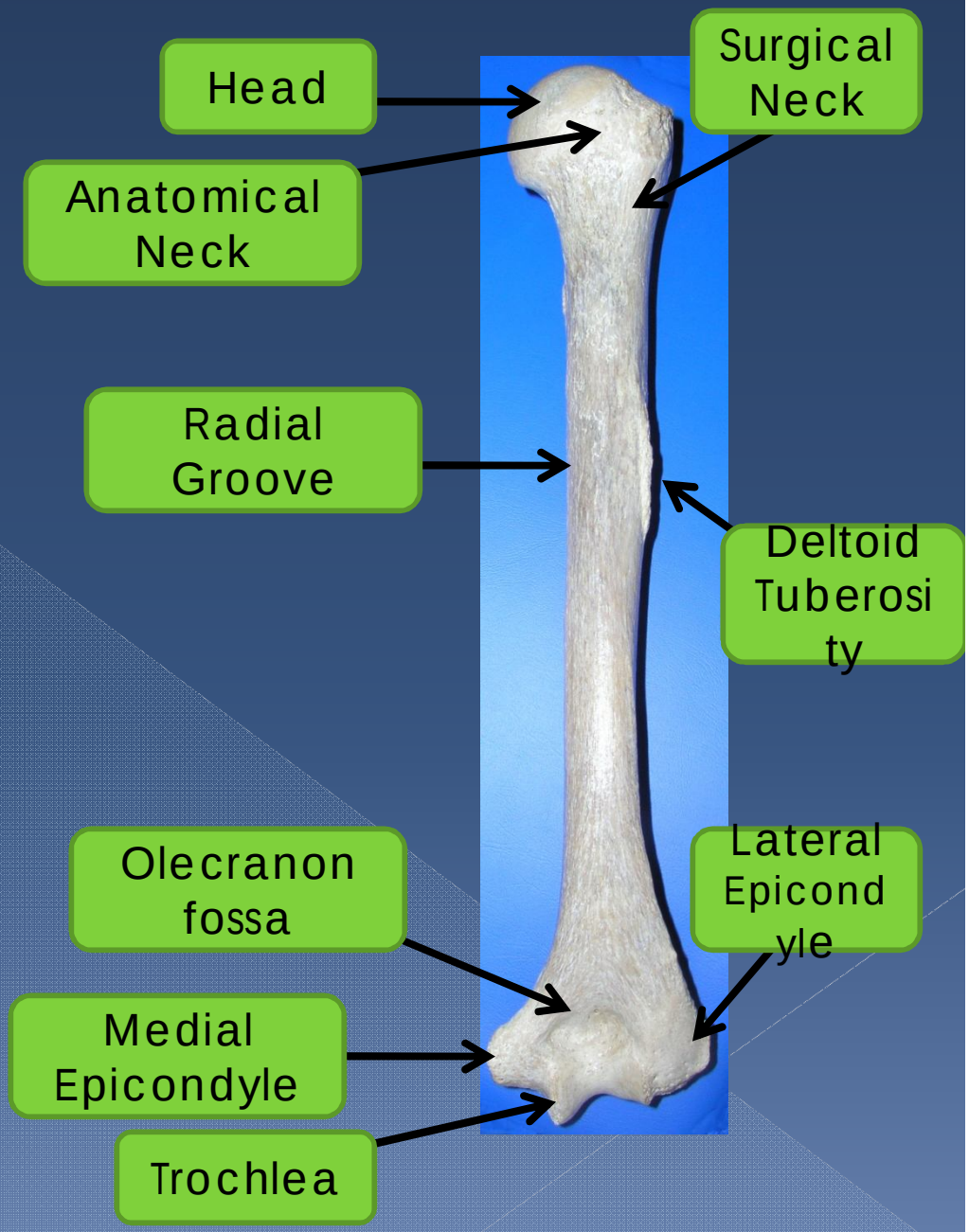

Identify and label these bones:

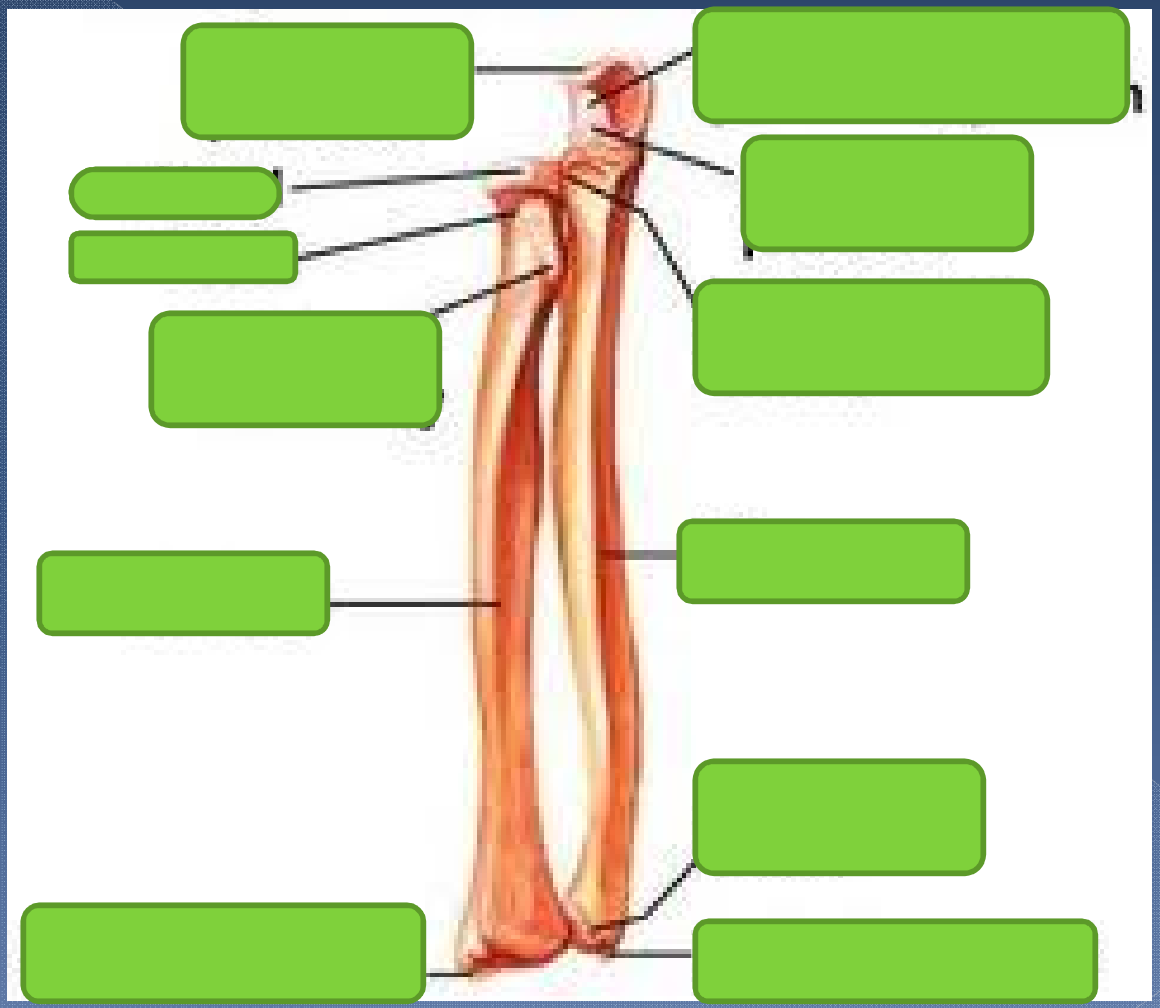

What projection is commonly called the elbow?

Olecranon process

- On which bone is it located?

Ulna

- With which bone does it articulate?

Humerus

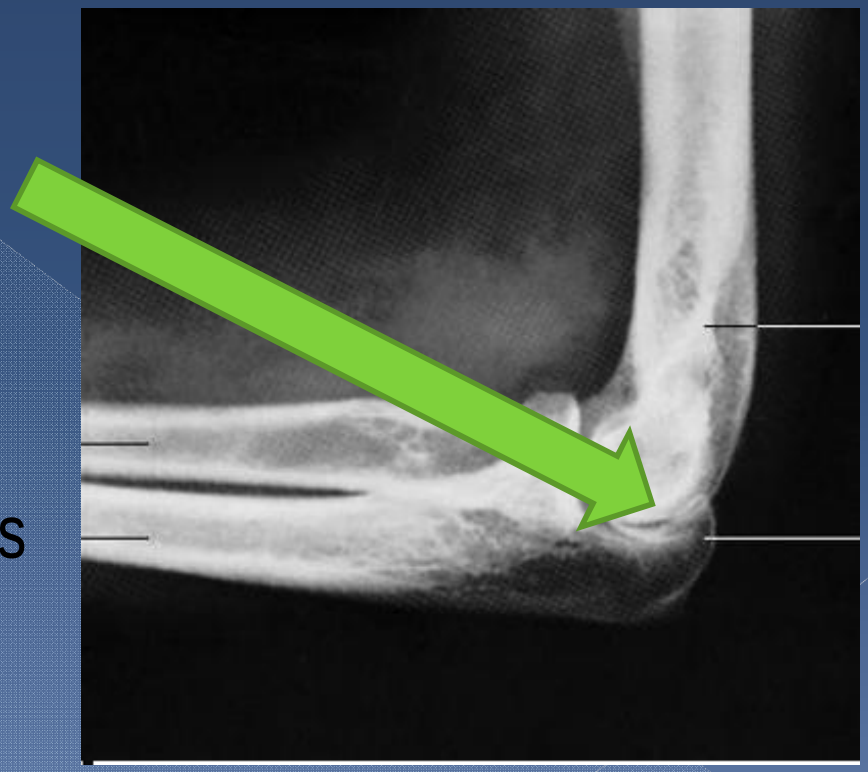

Clavicle



Acromial: Acromion of the scapula
Sternal: Manubrium of the sternum

Connective tissue sacs lined with synovial membranes that act as cushions in places where friction develops are called what?

A. Bursae
B. Intercalated disc
C. Meniscus
D. Synovial cavity.

Answer : A. Bursae

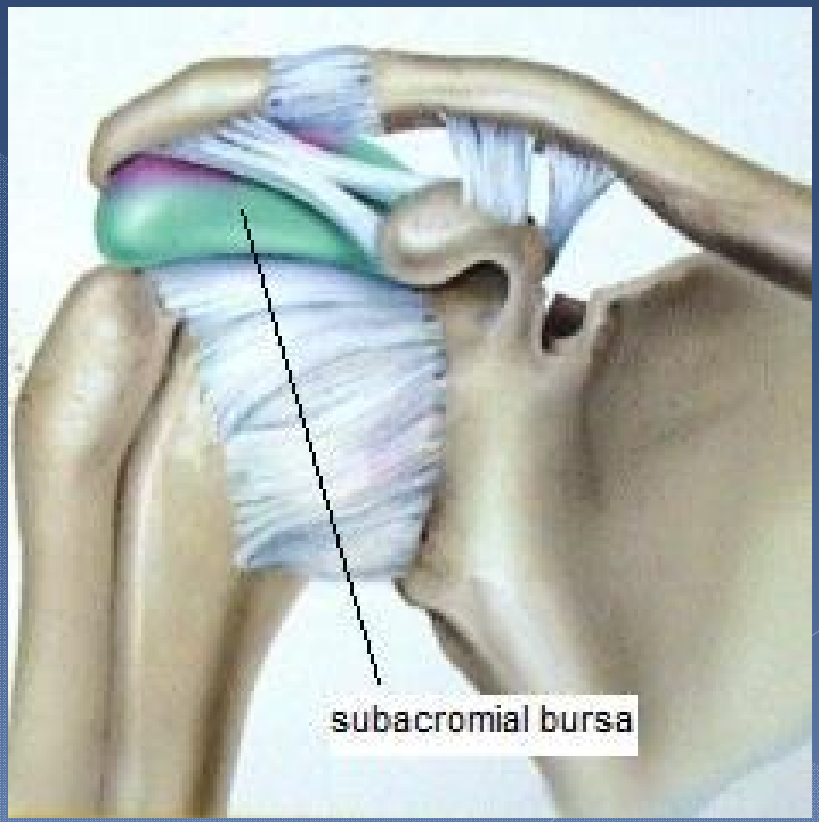

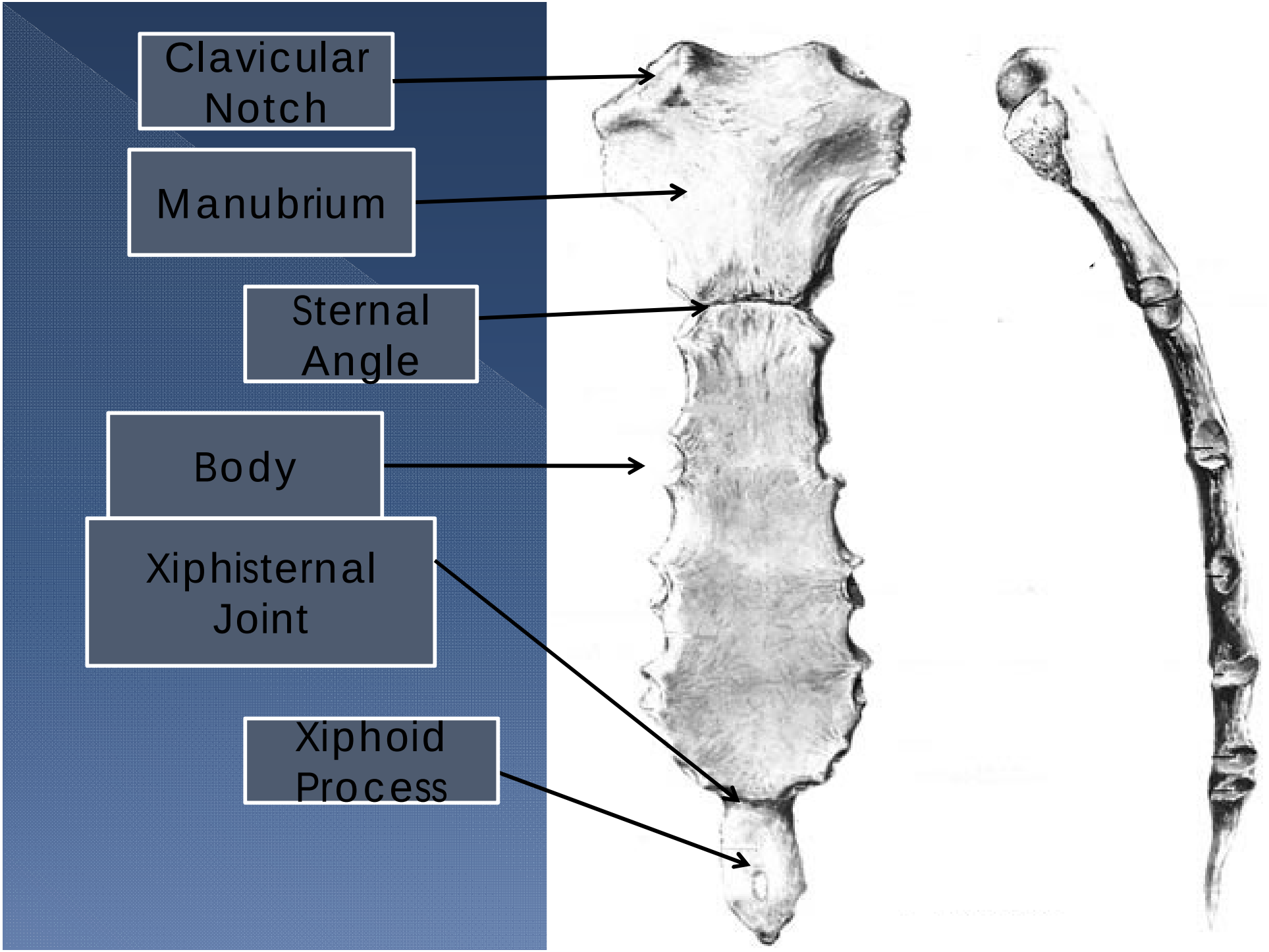
Clavicular Notch
Manubrium
Sternal Angle
Body
Xiphisternal Joint
Xiphoid Process

Define each and give the number of ribs in each section.

- **True Ribs-**

First 7 pairs, they are connected to the spine, and connected directly to the sternum by strips of cartilage called the costal cartilage.

- **False Ribs-**

The next 3 pairs, slightly shorter than true ribs, connected to the spine, and attached to the lowest true rib.

- **Floating Ribs-**

The last 2 pairs, smaller than both the true and false ribs, connects to the spine, but isn't connected to anything in the front.

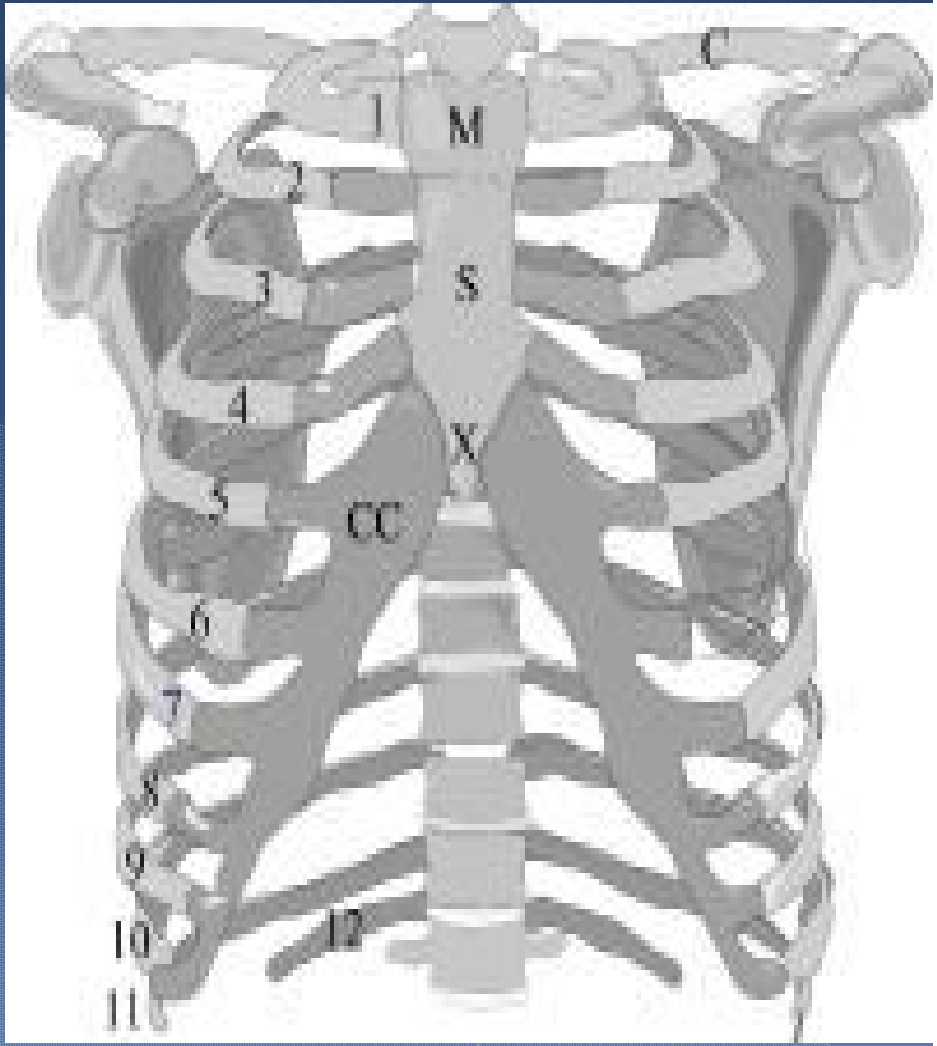

Name the regions on the vertebral column, and the # of vertebrae in each region:

- Cervical region: C1 – C7
- Thoracic region:T1 – T12
- Lumbar region: L1 – L 5
- Sacral region: S1- S5
- Coccyx: “tail bone”

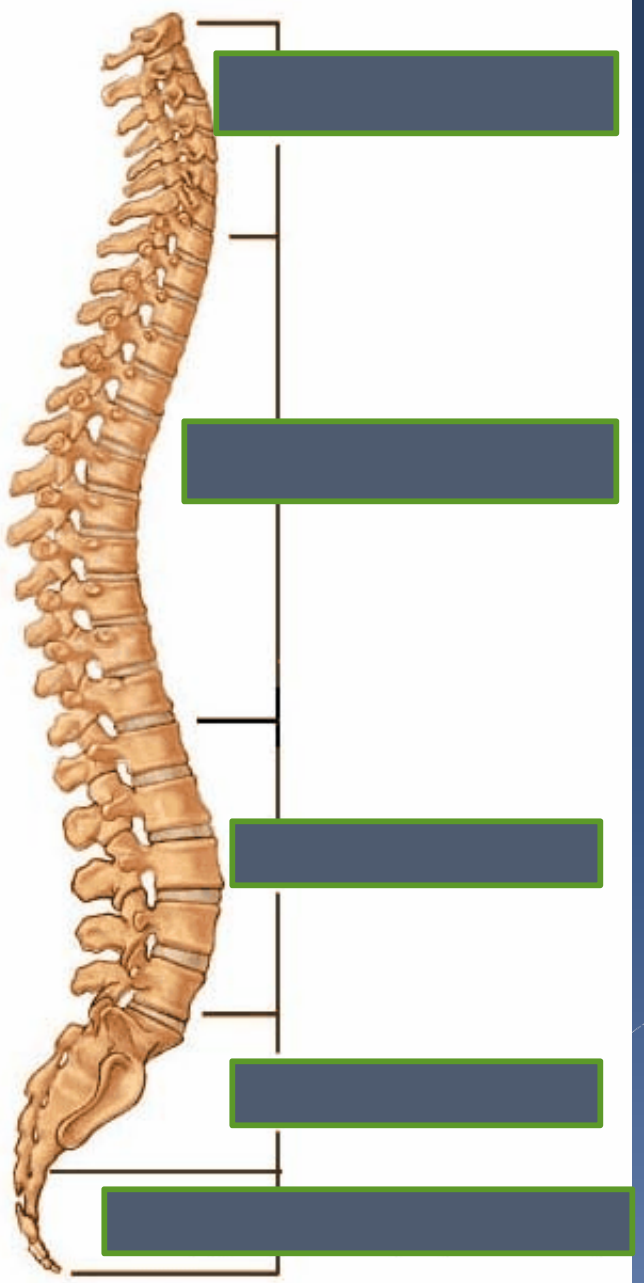

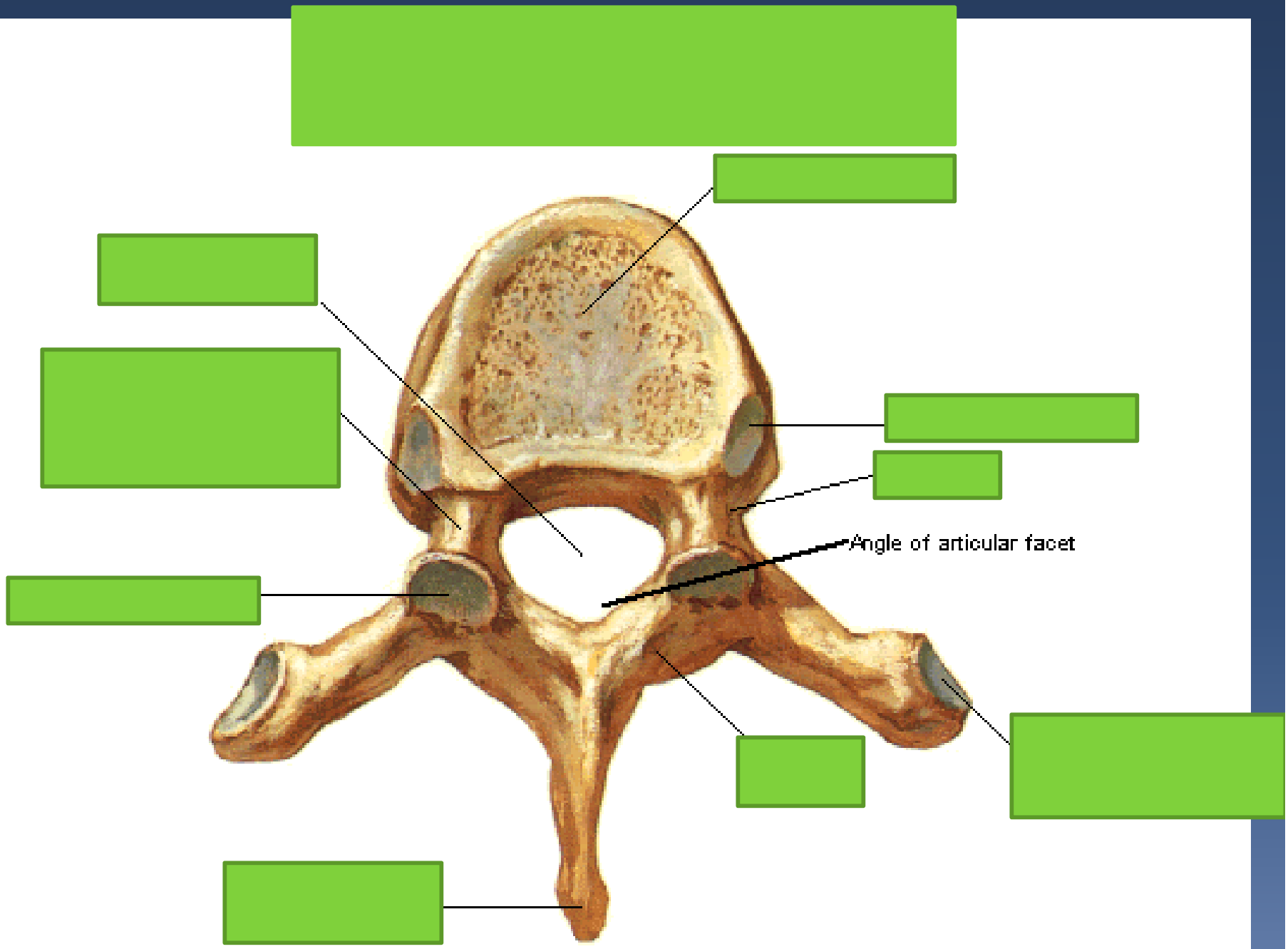
Angle of articular facet

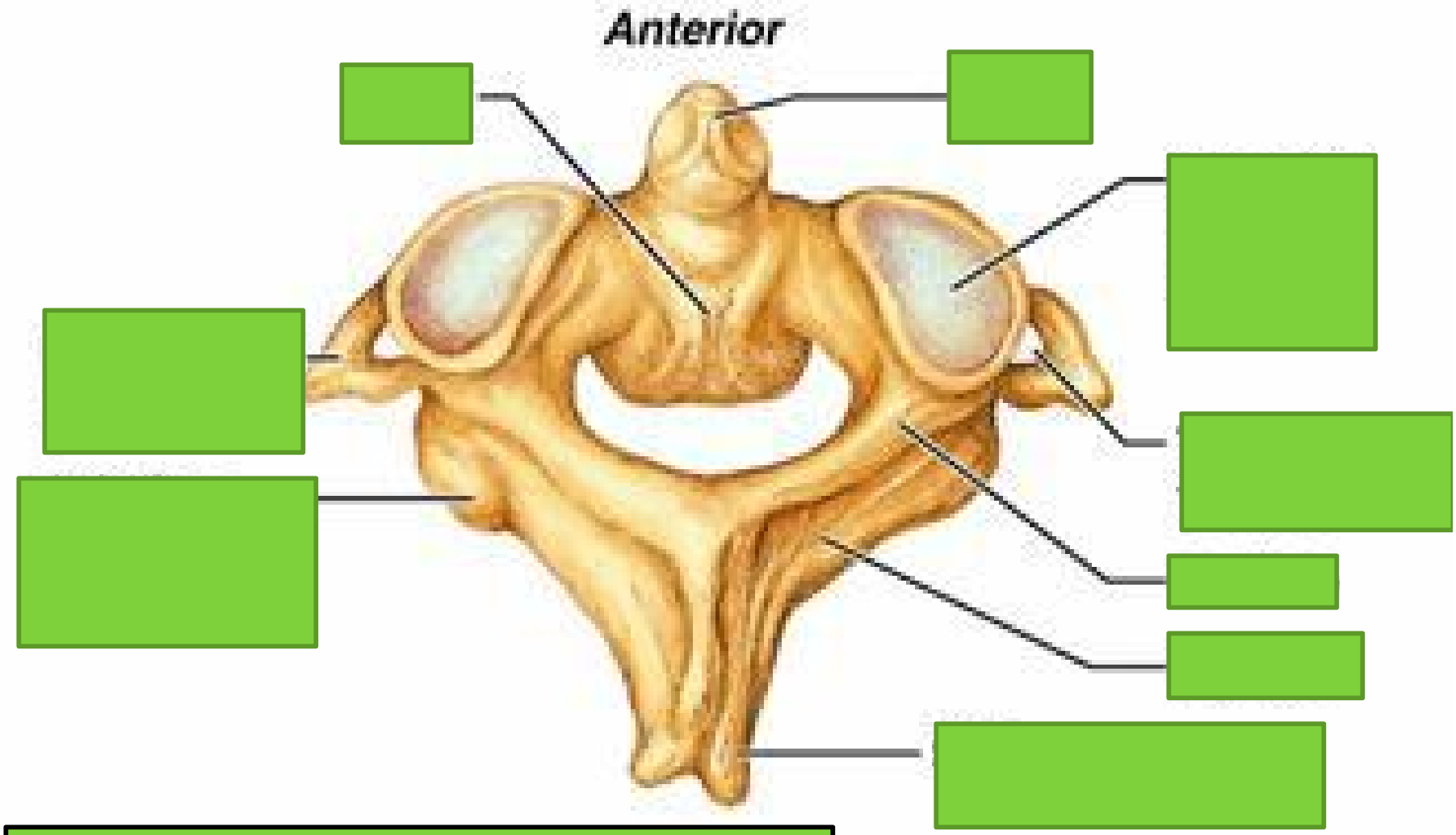
Anterior

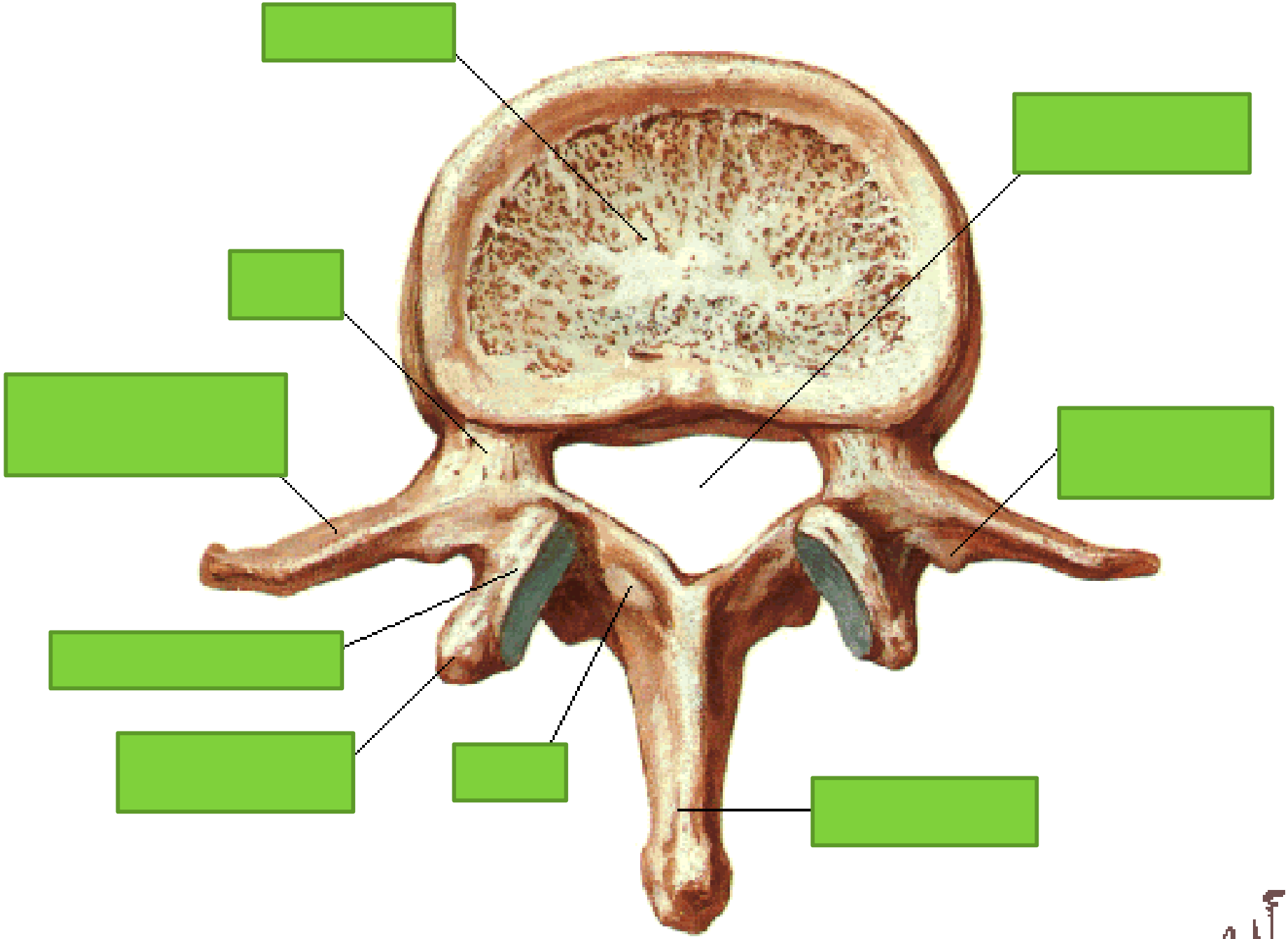

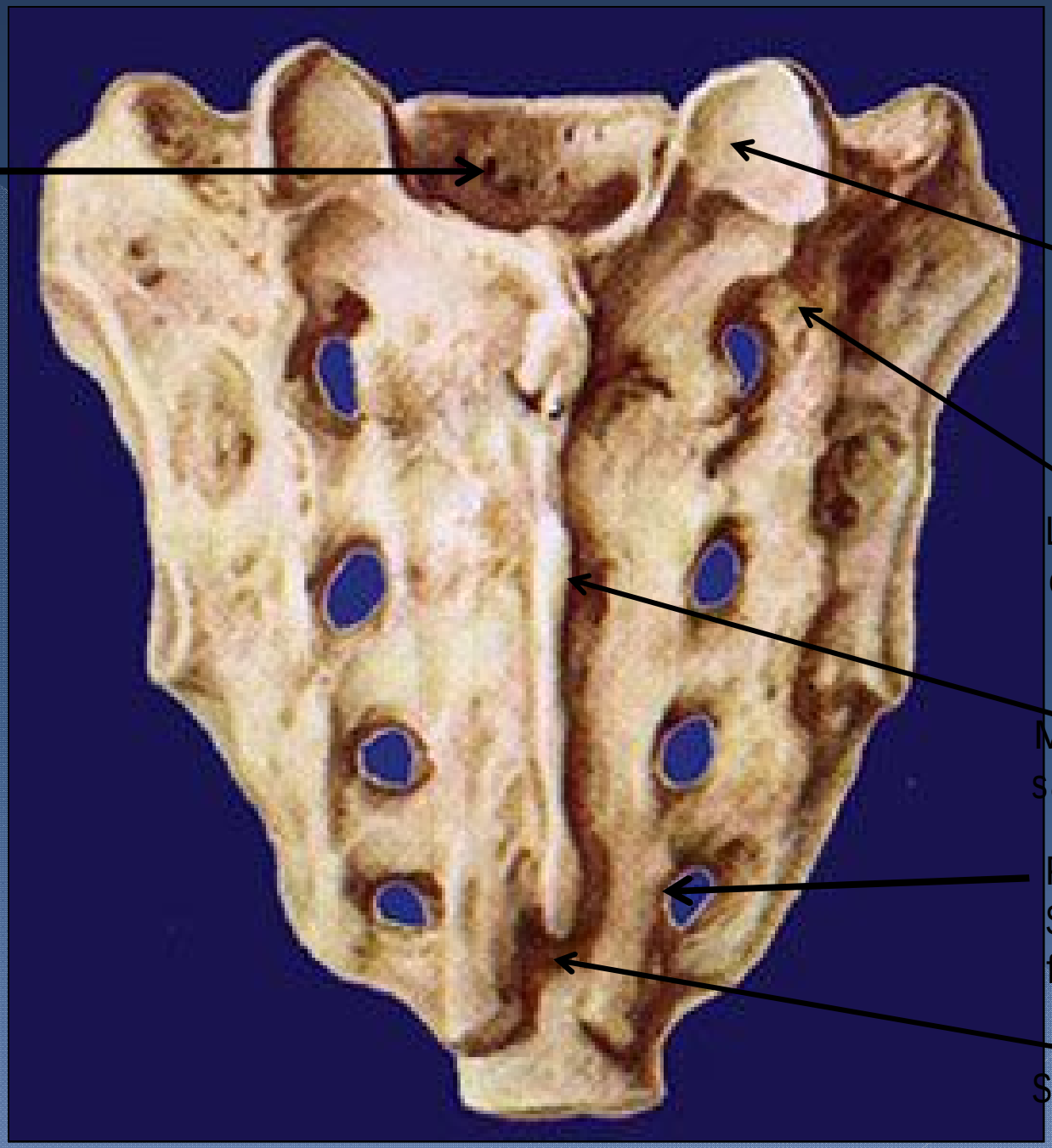
Sacral canal
Facet of superior articular process
Lateral sacral crest
Medial sacral crest
Posterior Sacral foramina
Sacral Hiatus

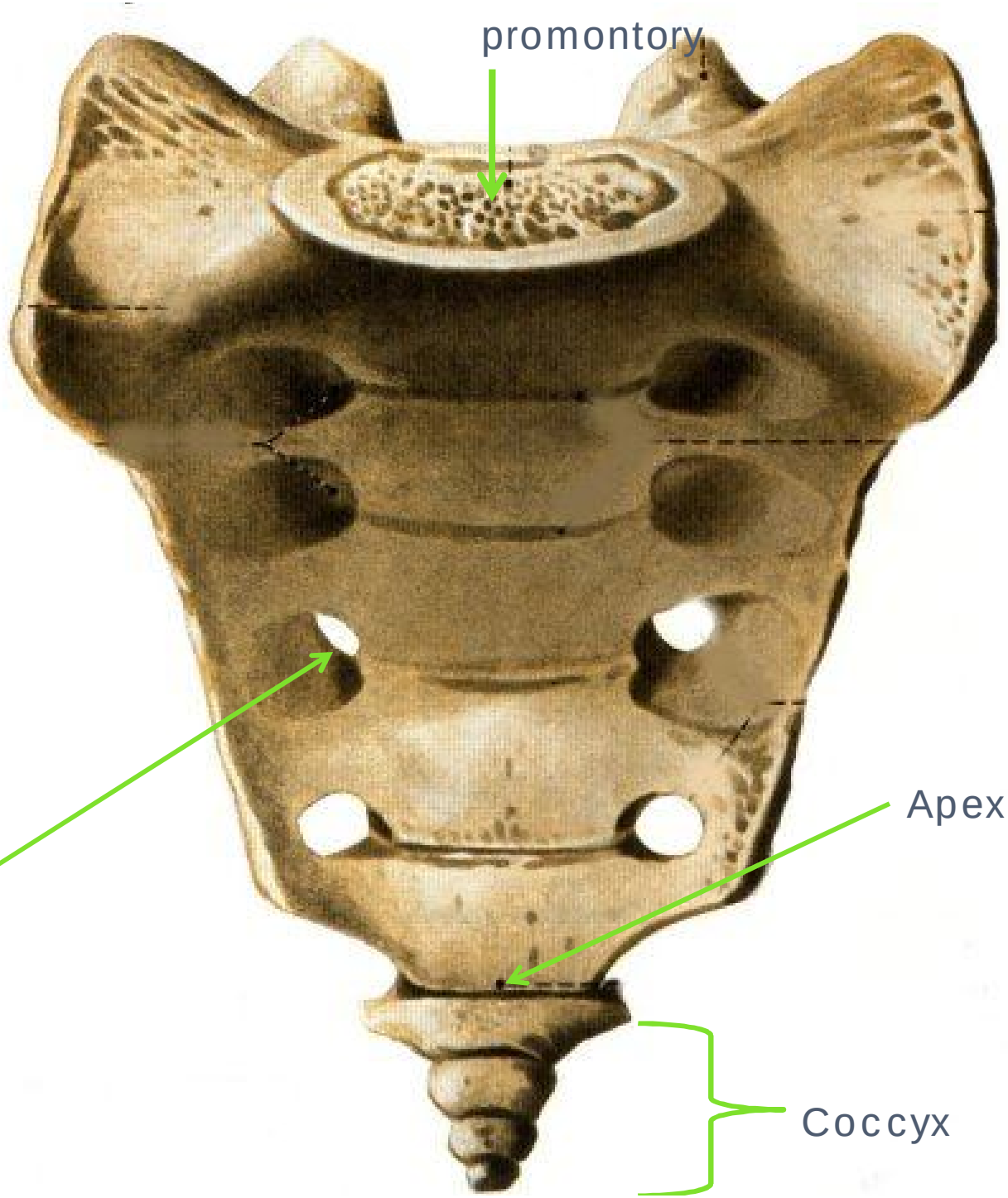
promontory
Anterior sacr
foramina
Apex
Coccyx

Femur

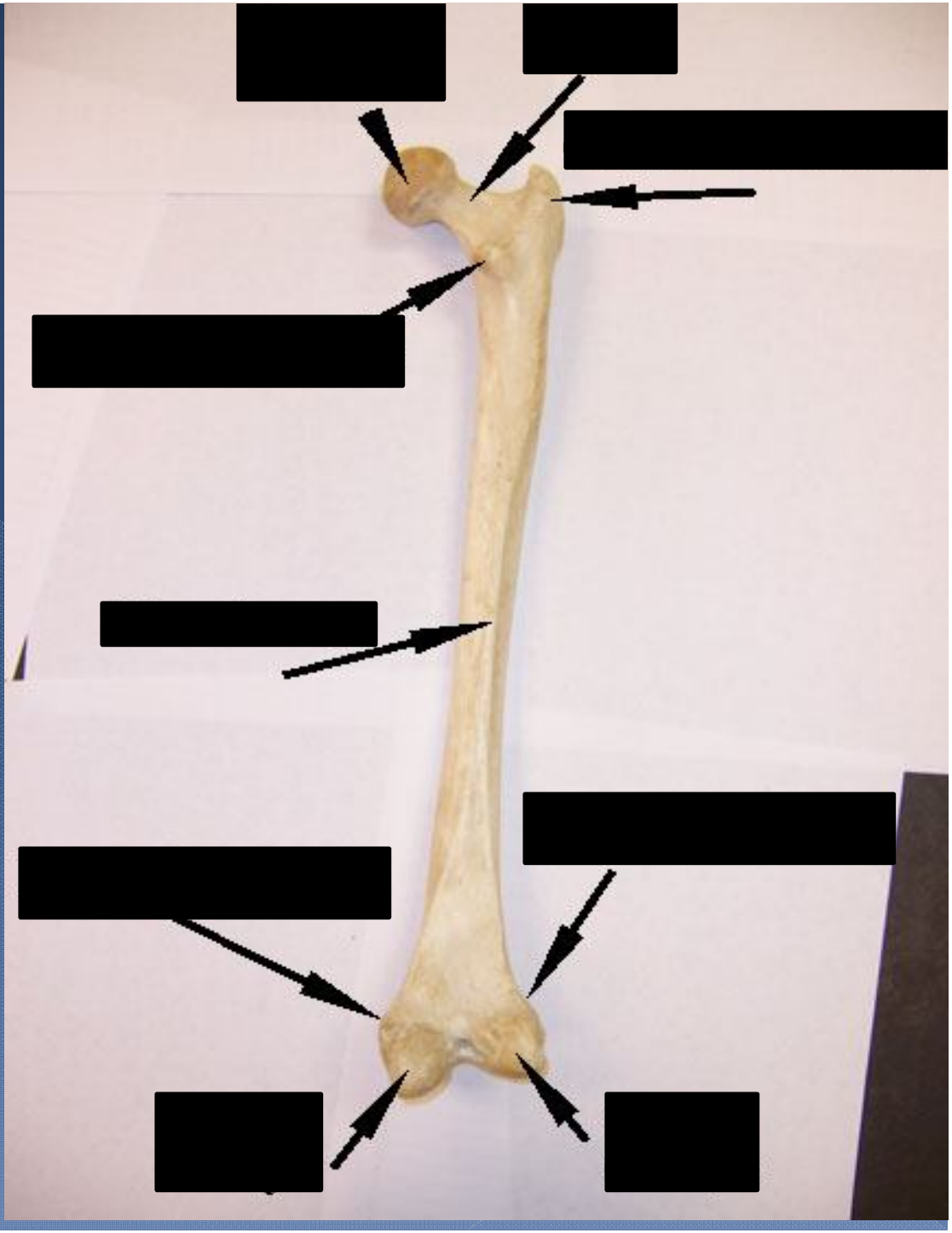

Tibia

1.) Internal condyle
2.) Medial malleous
3.) Body
4.) Tibial tuberosity
5.) External condyle
6.) Tibial spine

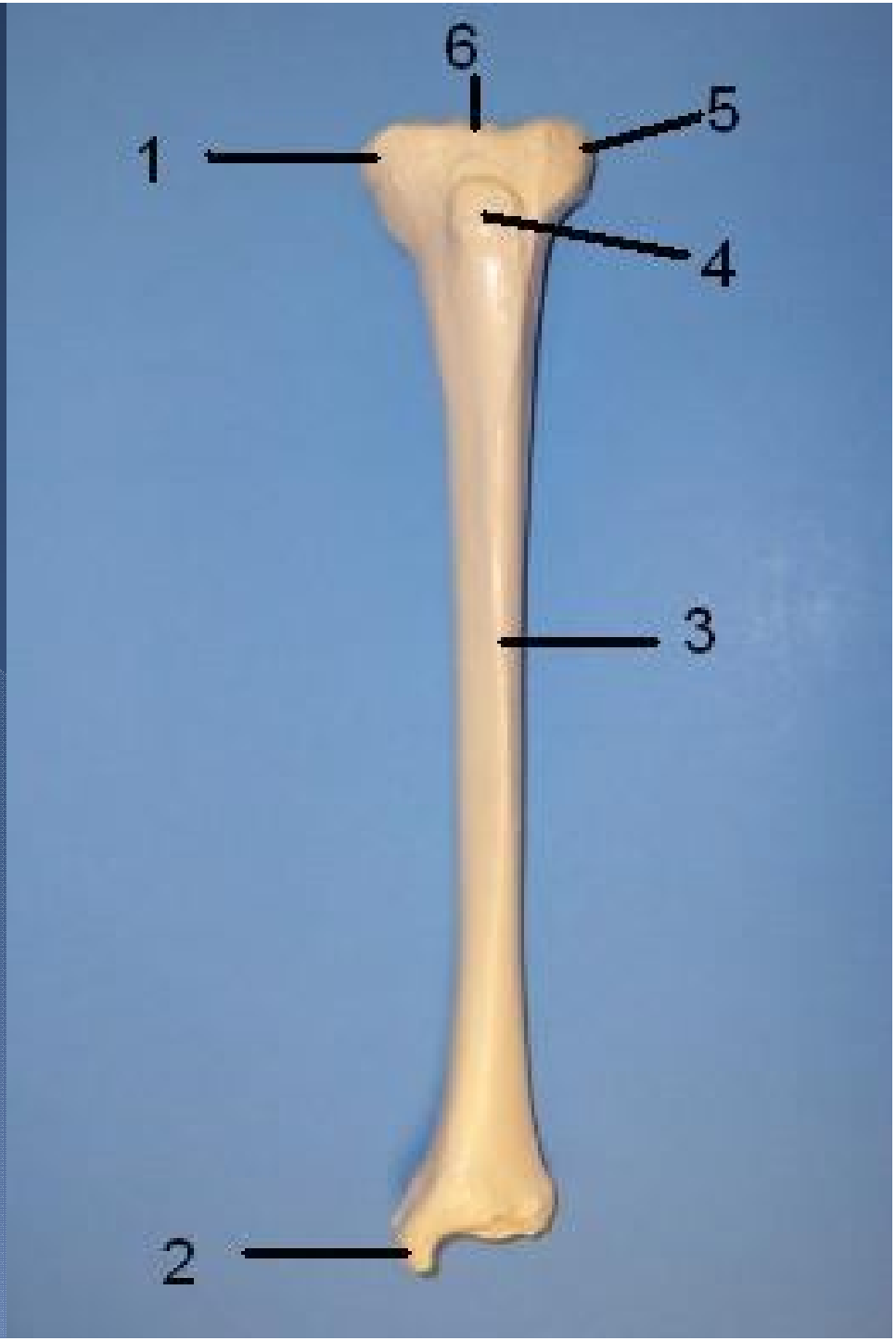

What is this?

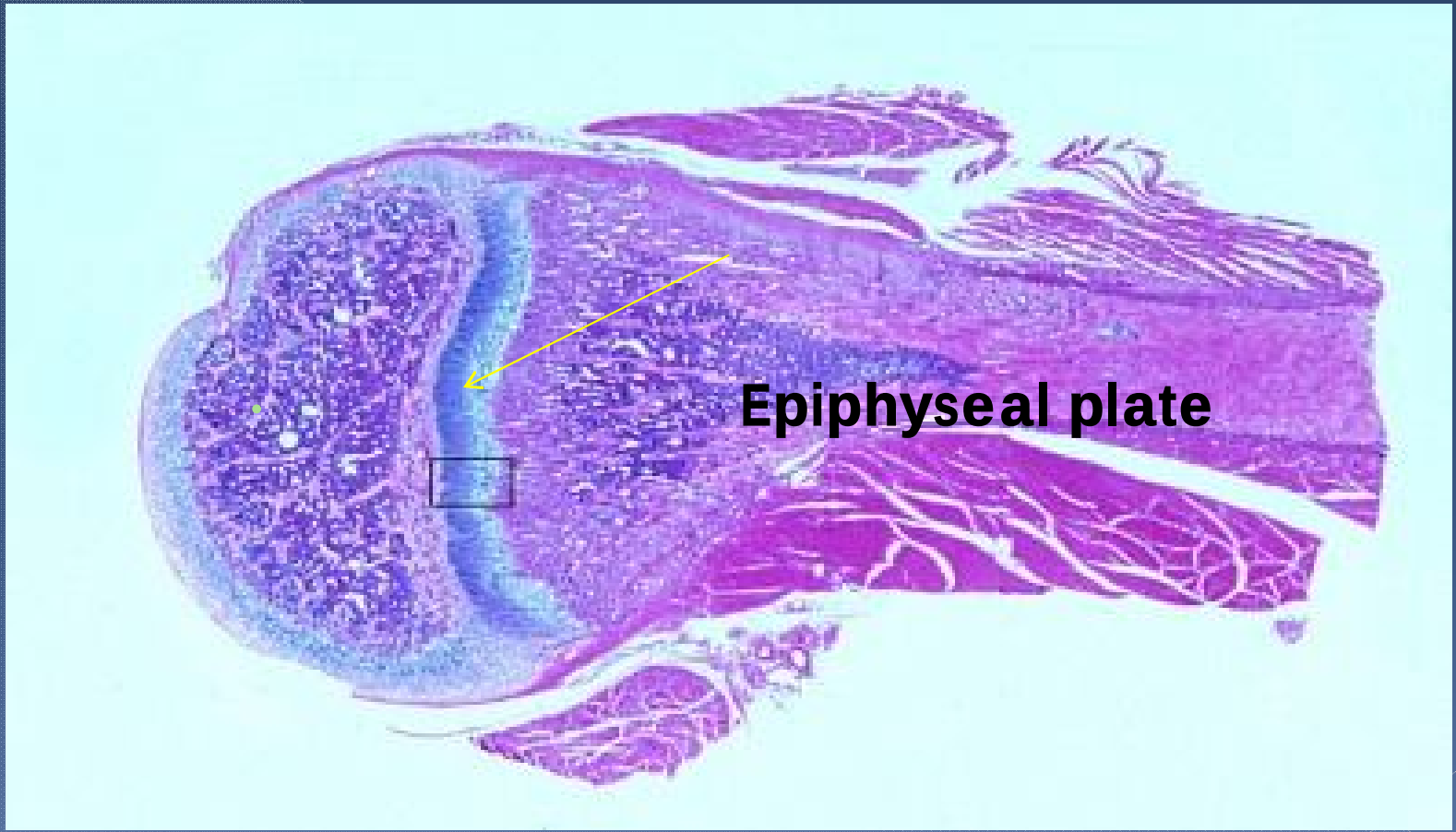

The definition of… ?

- A thorn like projection.
  -**Spine**
- A cavity within a bone.
  -**Sinus**
- A projection situated above a condyle.
  -**Epicondyle**
- A tiny pit or depression.
  -**Fovea**
- A relatively deep pit or depression.
  -**Fossa**
- A tube like passageway within a bone.
  -**Meatus**
- A rounded process that usually articulates with another bone.
  -**Condyle**
- A small knob like process.
  -**Tubercle**
- A prominent projection on a bone.
  - **Process**

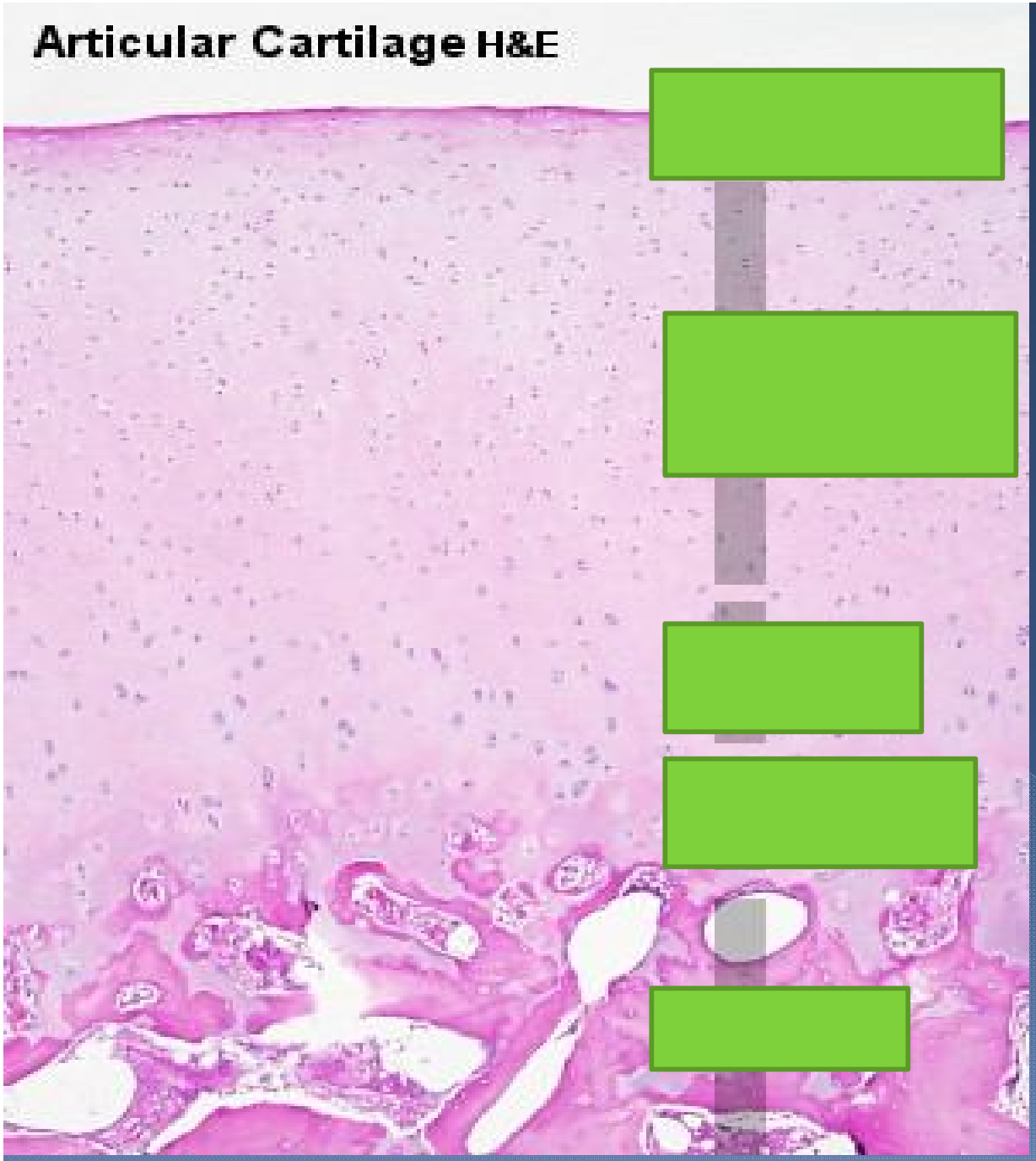

Label the Layers:

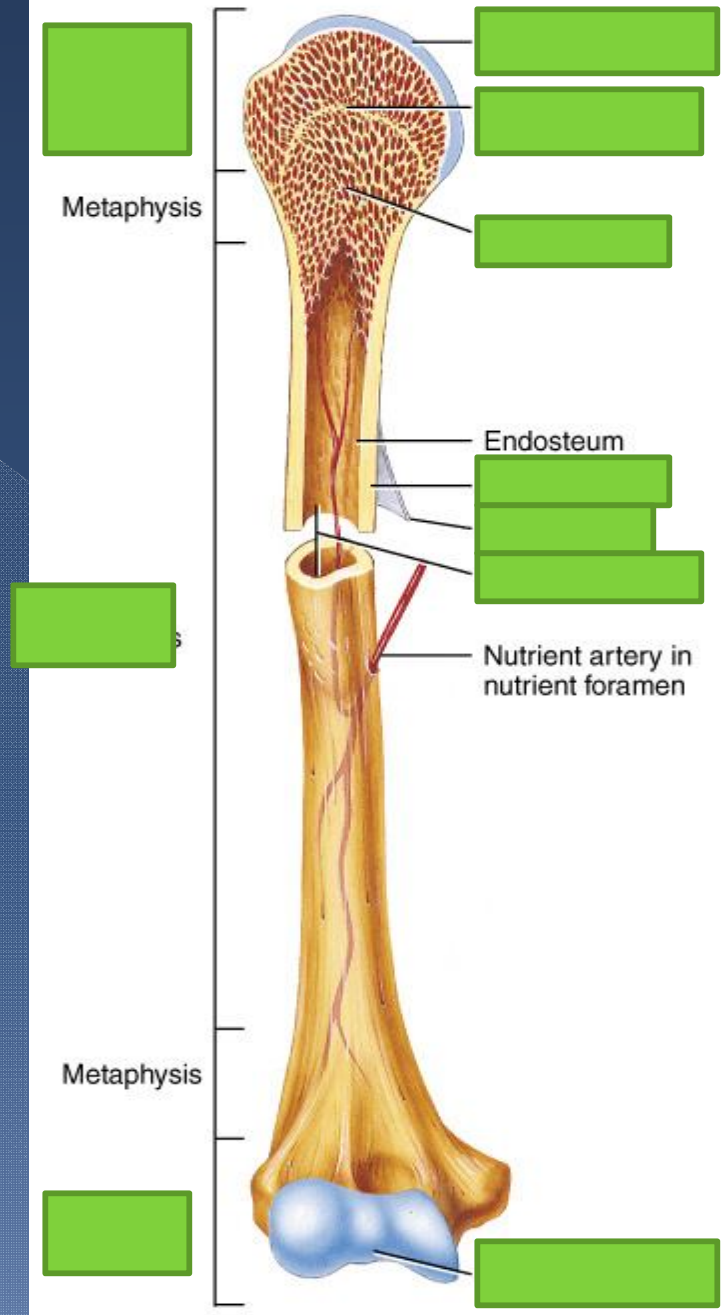

(a) Partially sectioned humerus (arm bone)

Which is pelvis is female?

A

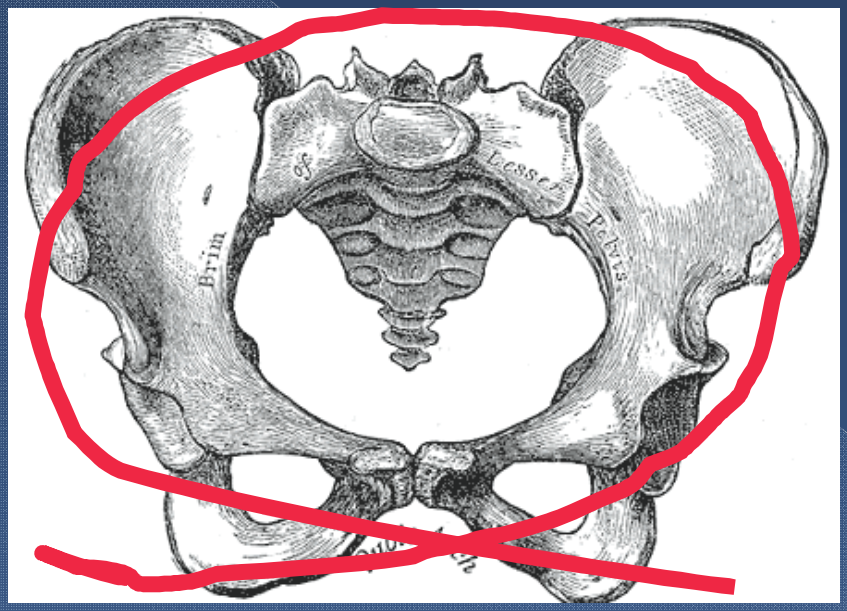

- Tilted forward (child bearing, defines birth canal)
- True pelvis cavity is broad/shallow with greater capacity
- Acetabula smaller, farther apart
- Pubic angle more rounded , 80° to 90°

B

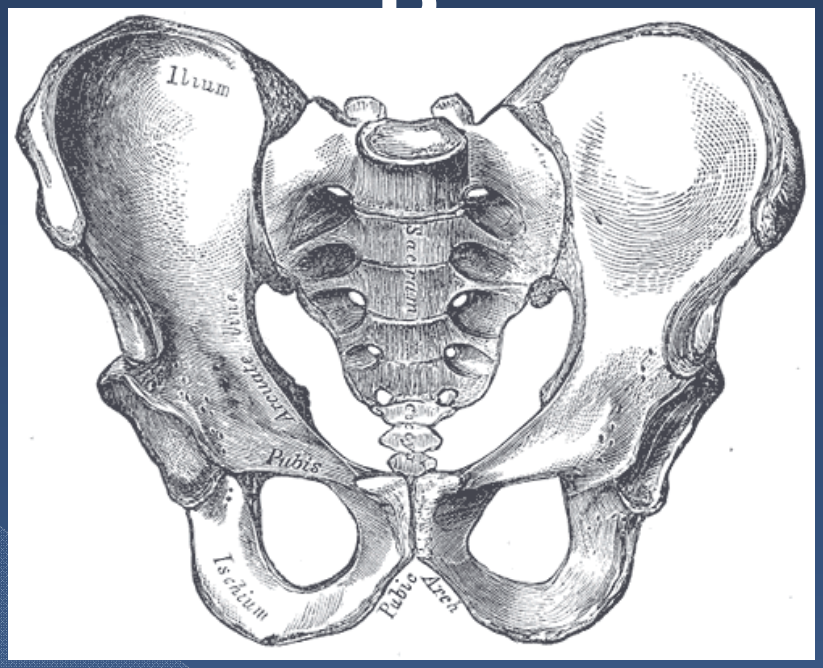

- Tilted less forward (support heavier build, stronger muscles)
- True pelvis cavity is narrow/deep
- Acetabula larger, closer together
- Public angle more acute, 50° to 60°

What three bones come together to make up the acetabulum?

- Ilium
- Ischium
- Pubis

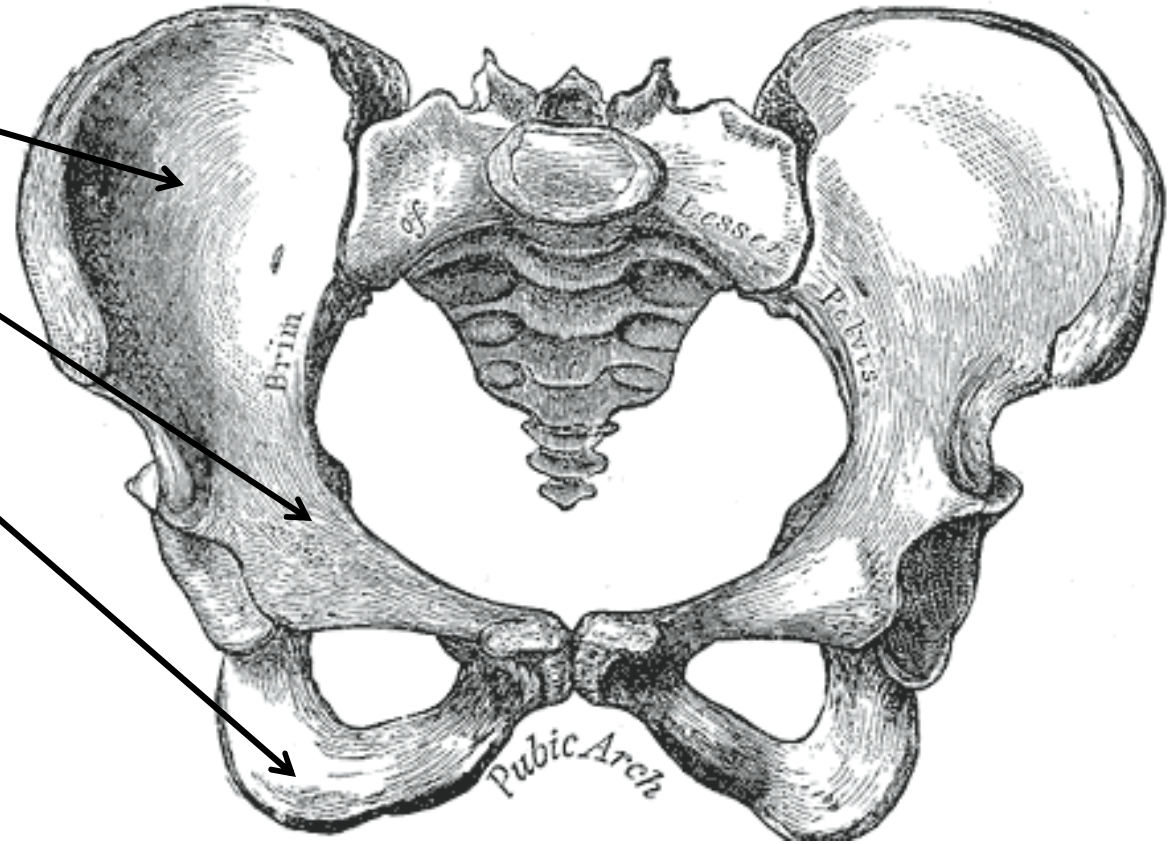

Matching:

Osteoblast

Osteocyte

Osteoclast

Osteogenic

Mature bone cell

Bone stem cell

Removes excess bone

Builds bone matrix

What forms the epiphyseal growth plate?

a. Elastic cartilage
b. Fibrocartilage
c. Hyaline cartilage
d. Compact bone
e. Spongy bone

At what age does it become an epiphyseal line?

25

Answer: c

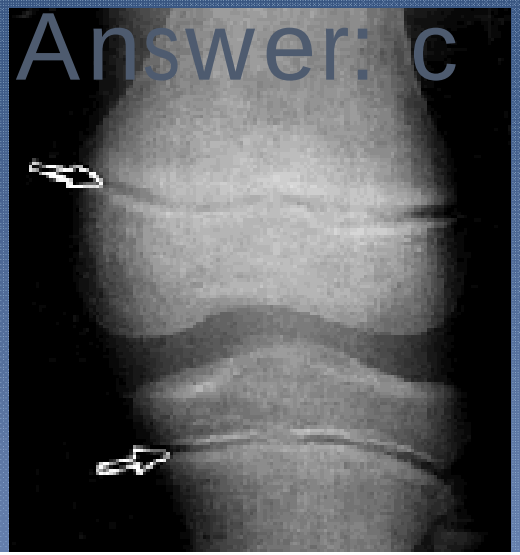

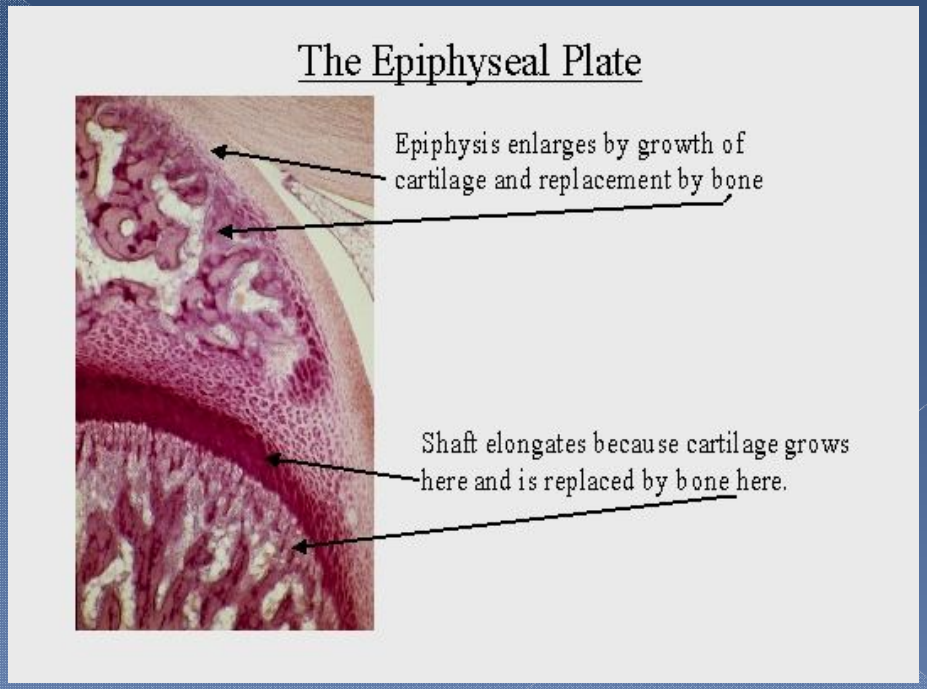

Matching

- Open (compound)
- Closed (simple)
- Comminuted
- Greenstick
- Spiral
- Impacted

- One bone fragment is driven into the medullary space or spongy bone of another.
- Bone ends penetrate the skin
- Bone breaks incompletely. One side bent, one side broken common in kids.
- Ragged break caused by excessive twisting forces. Sports injury/Injury of abuse.
- Bone fragments into 3 or more pieces. Common in the elderly (brittle bones).
- Bone ends don't penetrate the skin

WHAT TYPE OF FRACTURE IS THIS?

Greenstick

Most common in…

Children

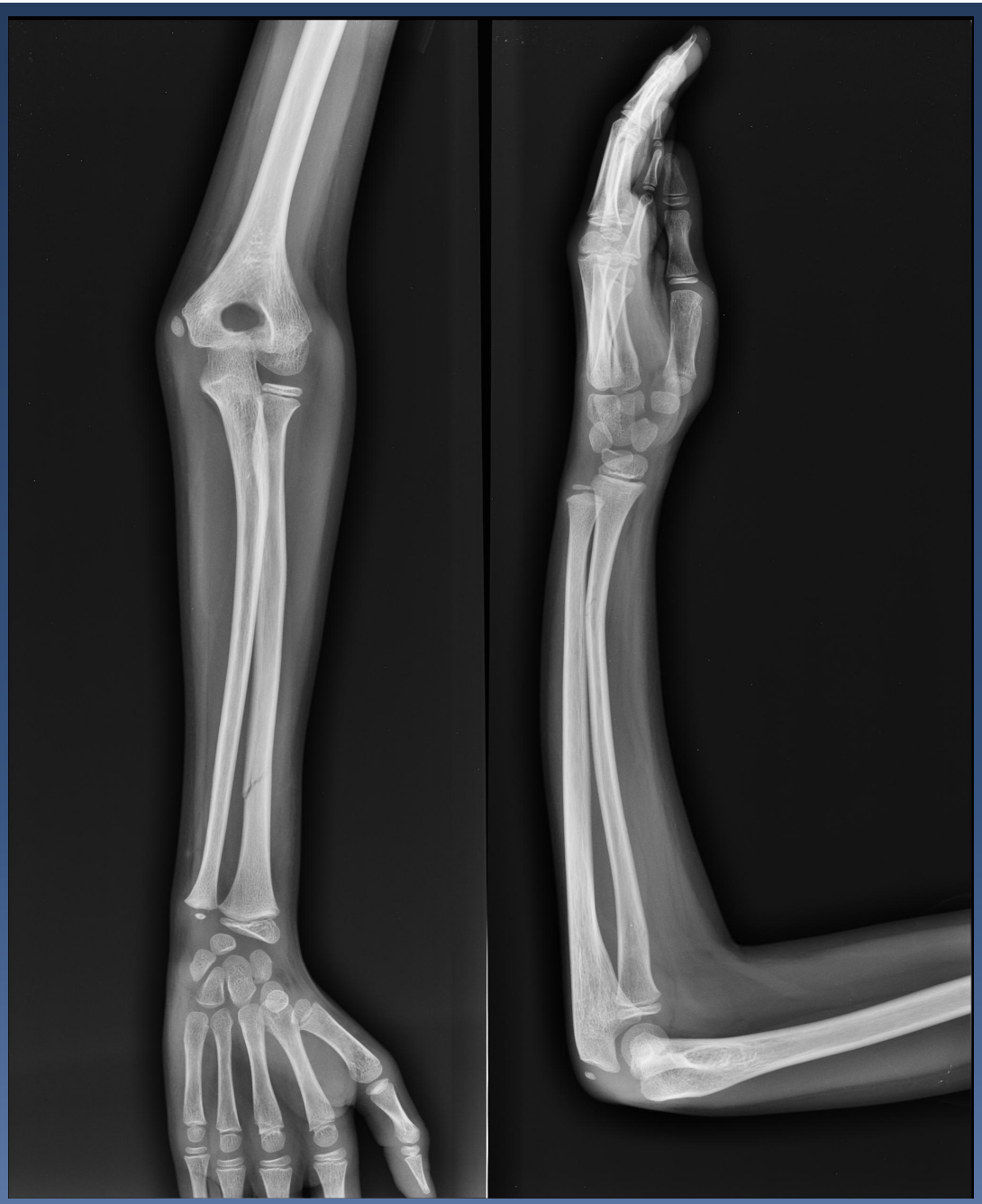

Name the fracture

Spiral Fracture

What type of fracture is this?

Comminuted Fracture

What type of fracture is this?

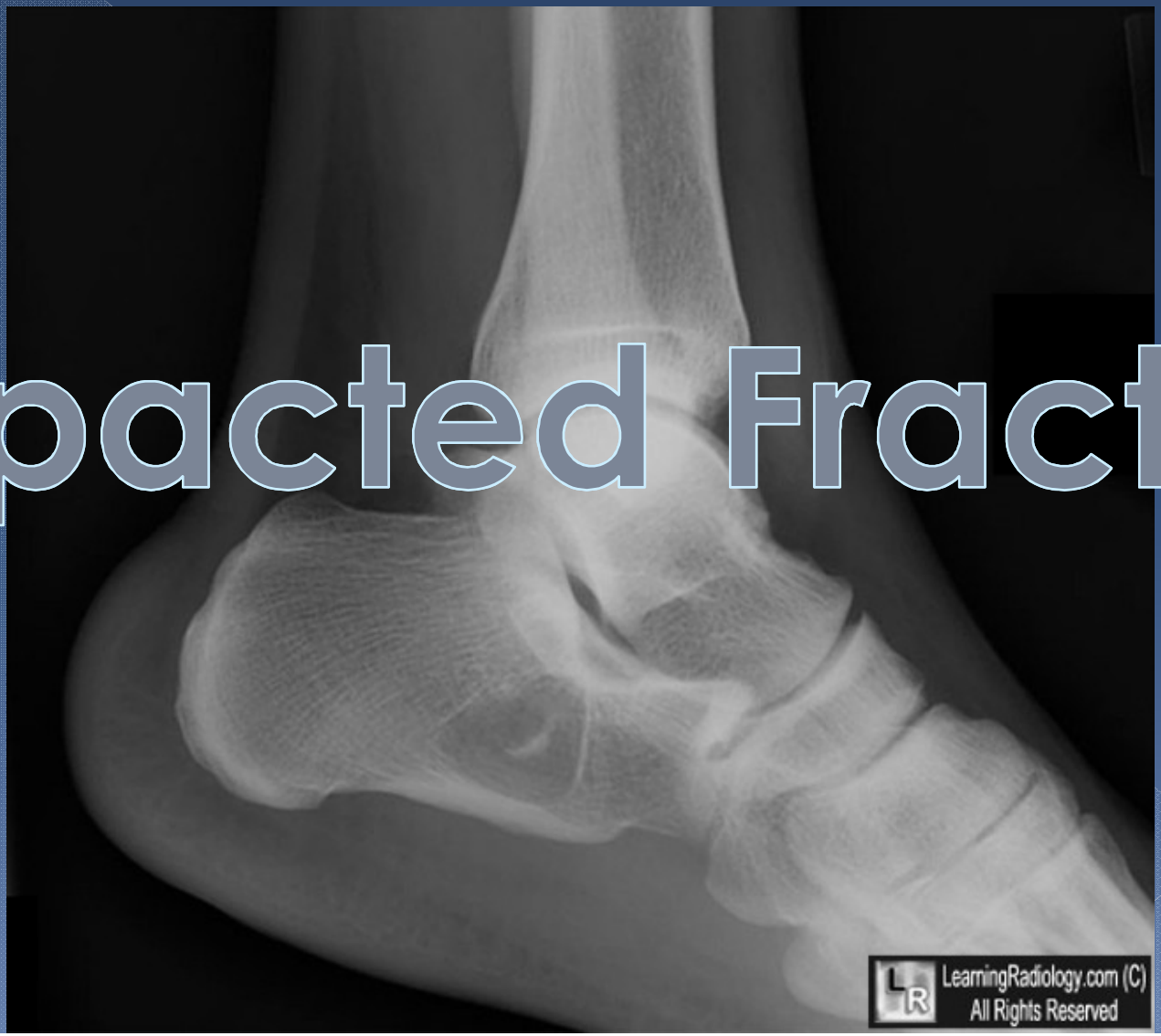

Impacted Fracture

Matching!!

- Osteomalacia
- Paget's disease
- Osteoporosis

- Bones are porous and thin but bone composition is normal
- Bone formed is poorly mineralized and soft. Deforms on weight bearing bone. Only in adults
- Abnormal bone formation and reabsorption

What disease is this?

OSTEOPOROSIS

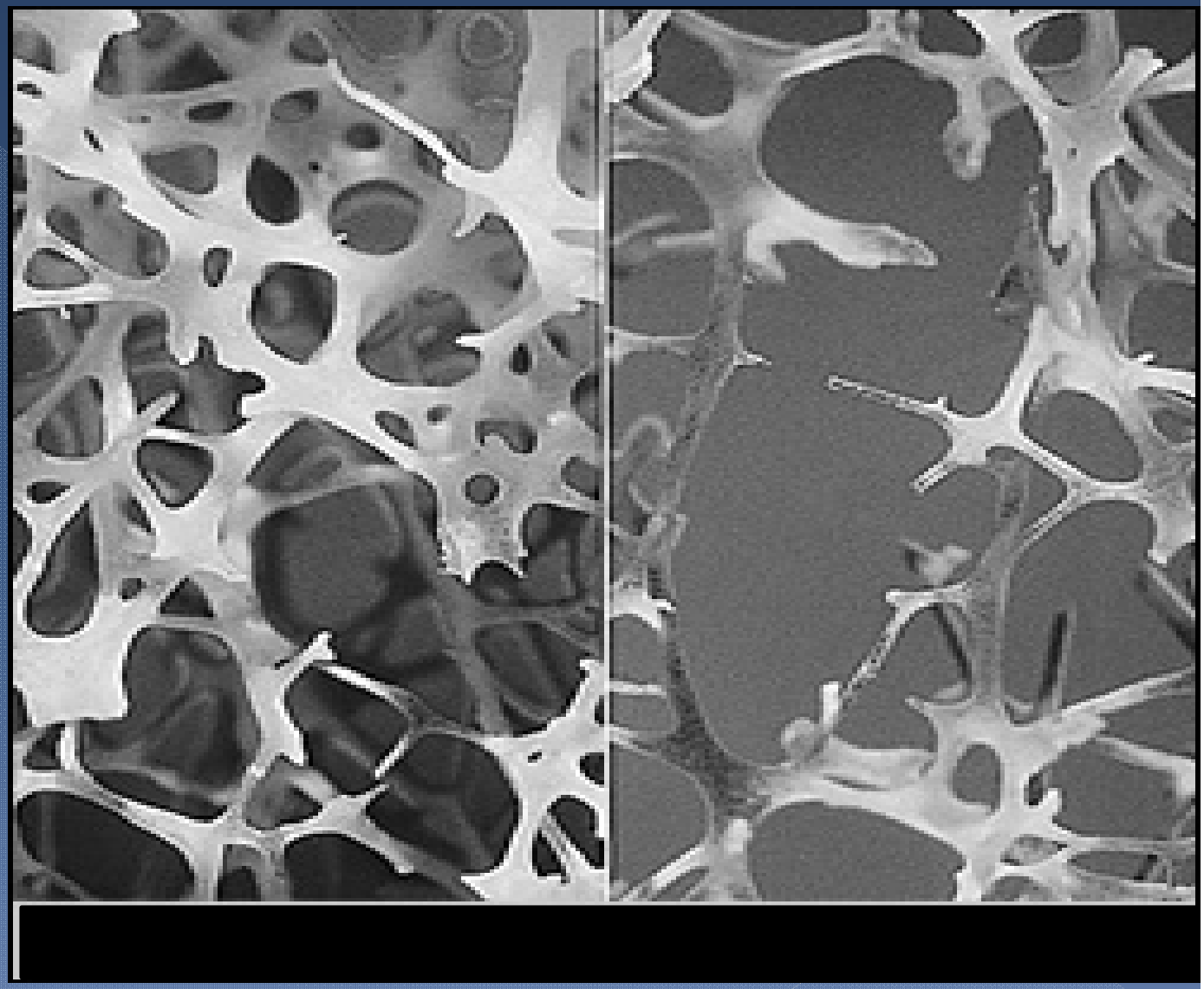

What is this disease?

- Rickets-

the children's form of osteomalacia.

What is happening here?

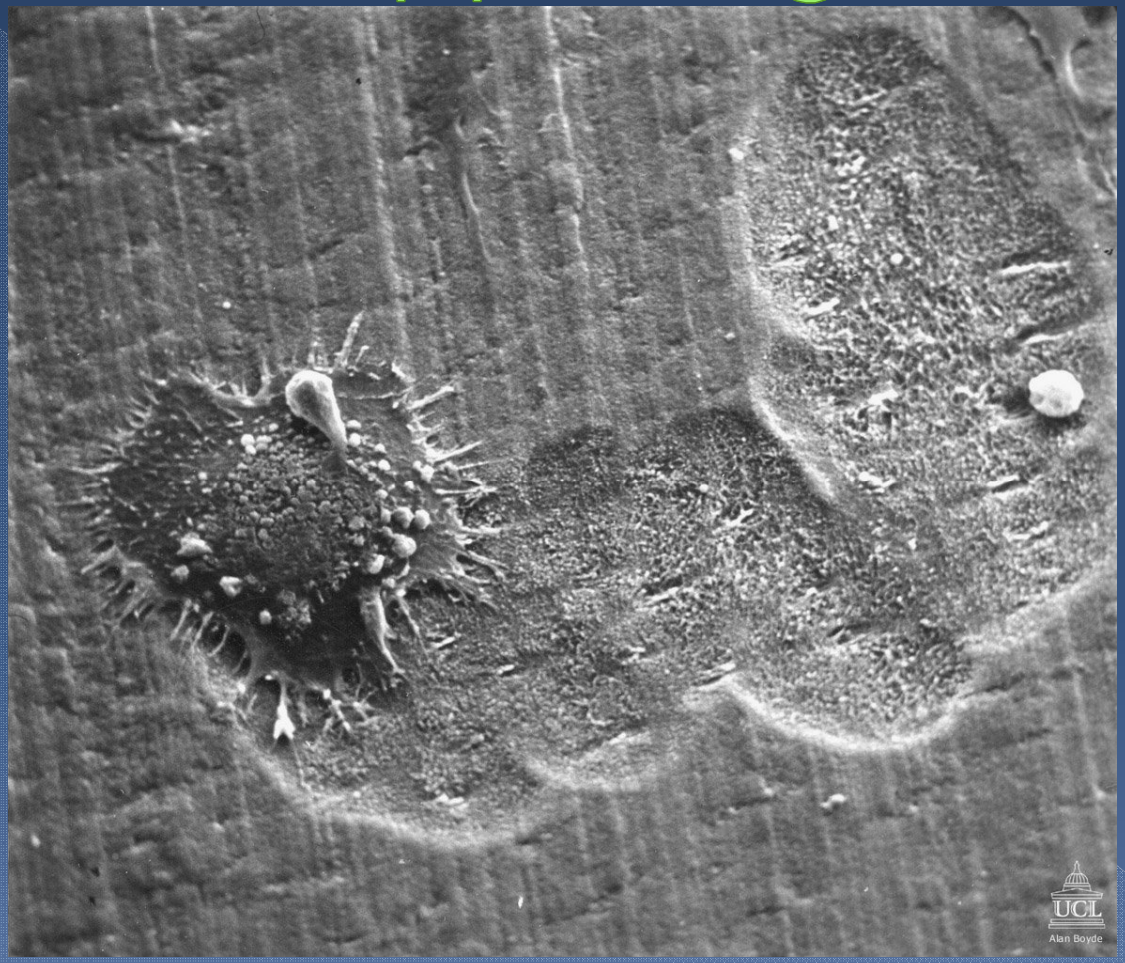

Osteoclast – Doin' its thang…

What type of cartilage do you see and where is it located?

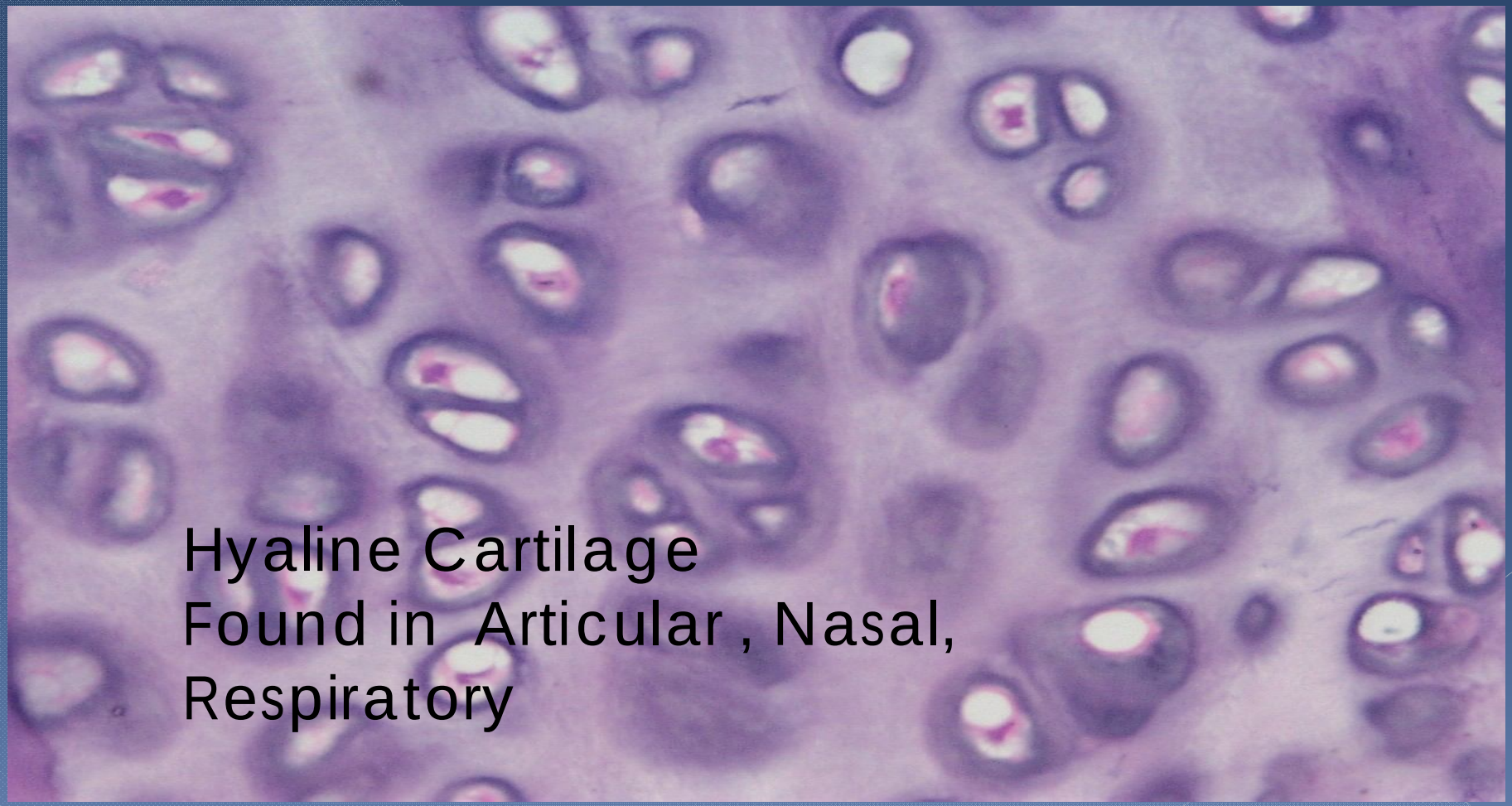

What type of tissue is this and where is it located?

Elastic Cartilage. Found in the epiglottis and the external ears.

What type of tissue is this and where is it located?

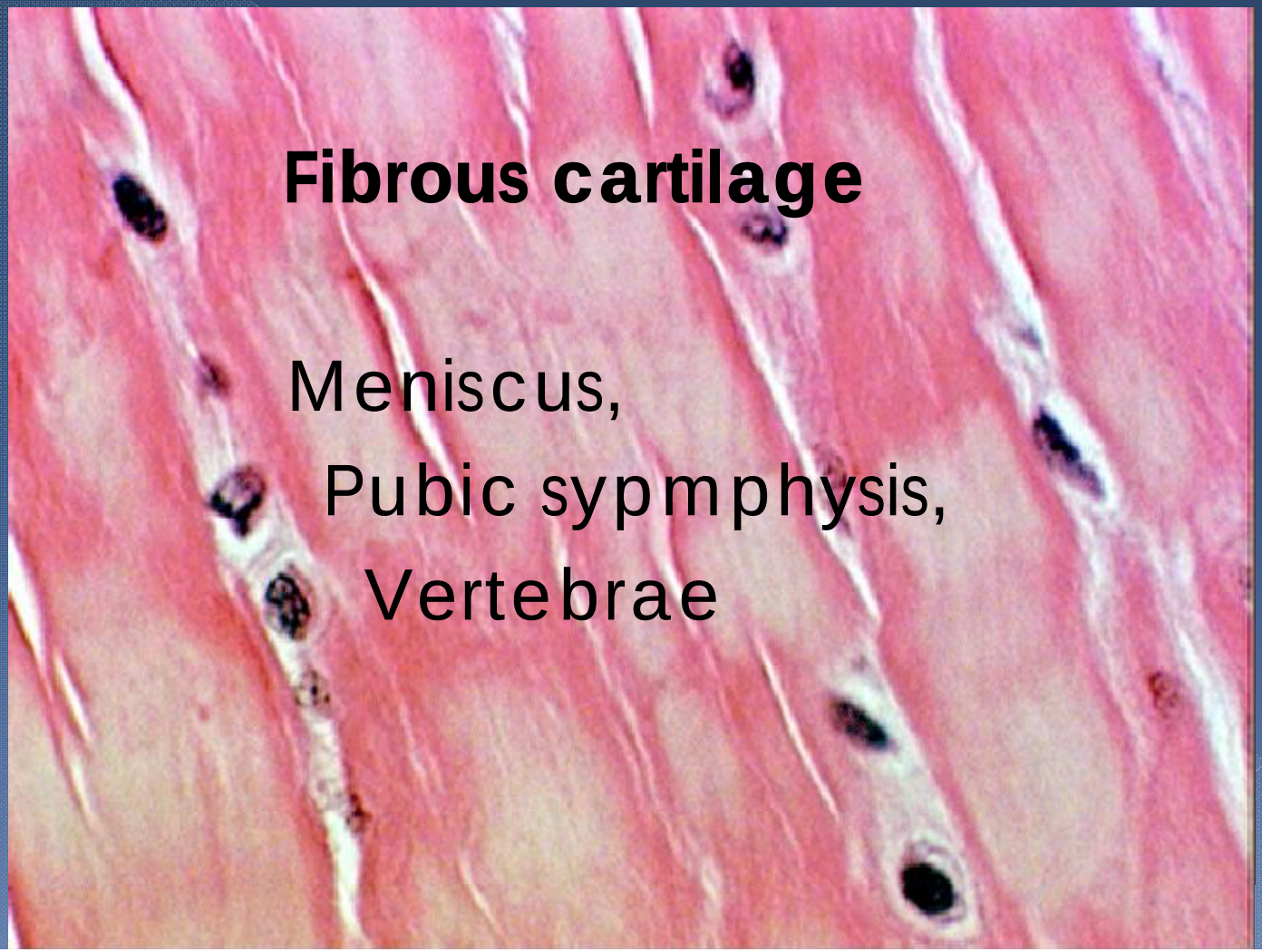

Identify this Cartilage:

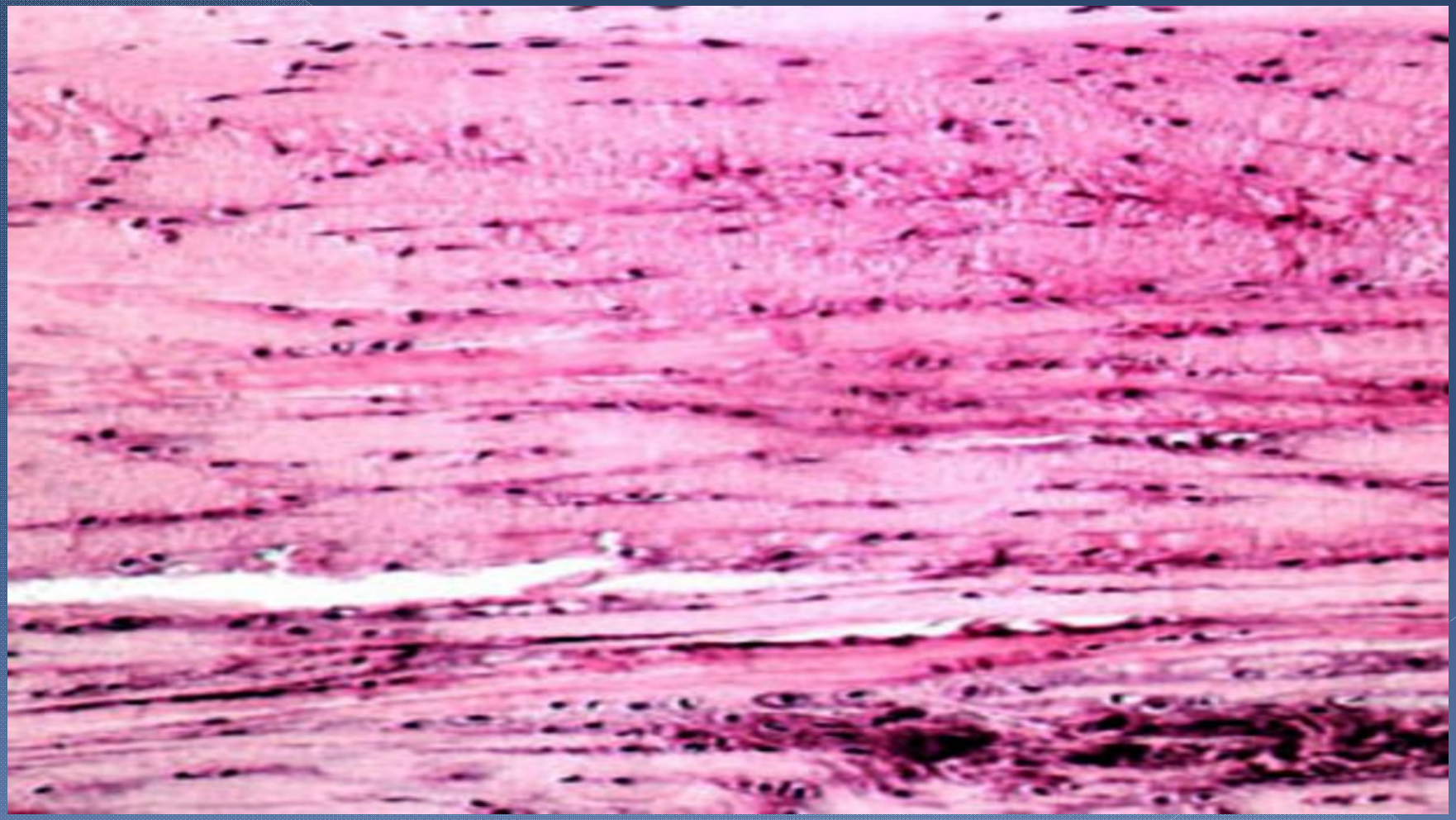

Identify this cartilage:

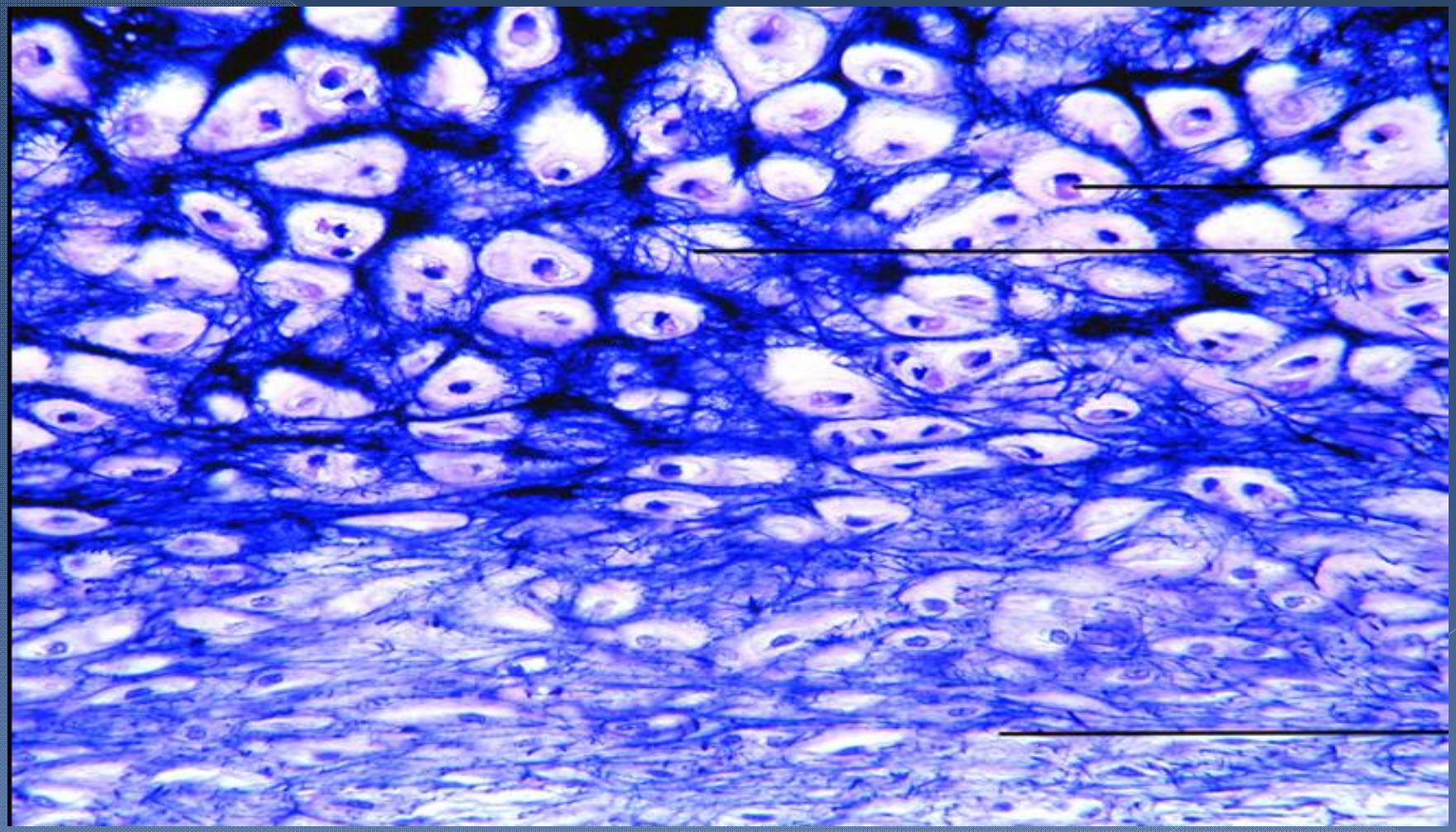

Where is hyaline cartilage located?

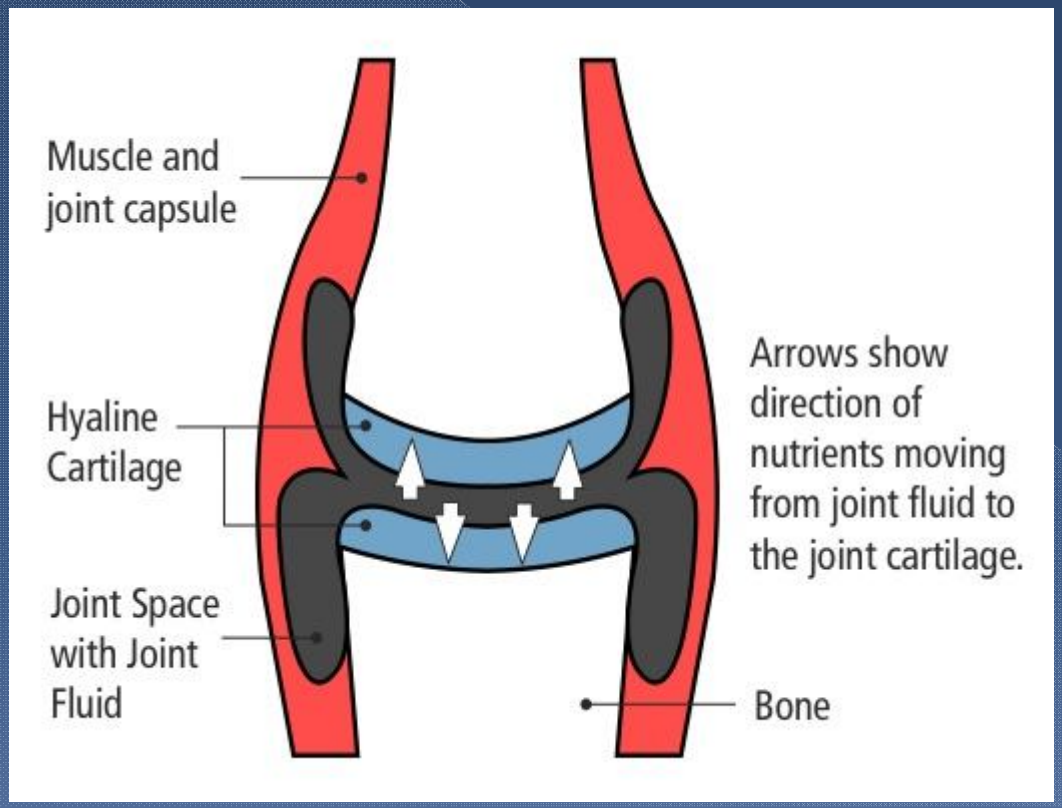

- Any one point of articulation

--Knee

--Shoulder

--Elbow

--Ribs

--Trachea

What is the location of elastic cartilage

- Ears
- Epiglottis
- Outer portion of the nostrils

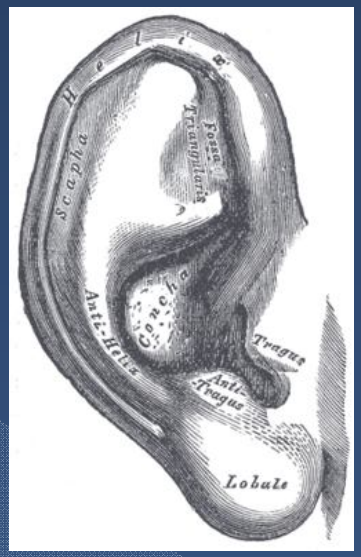

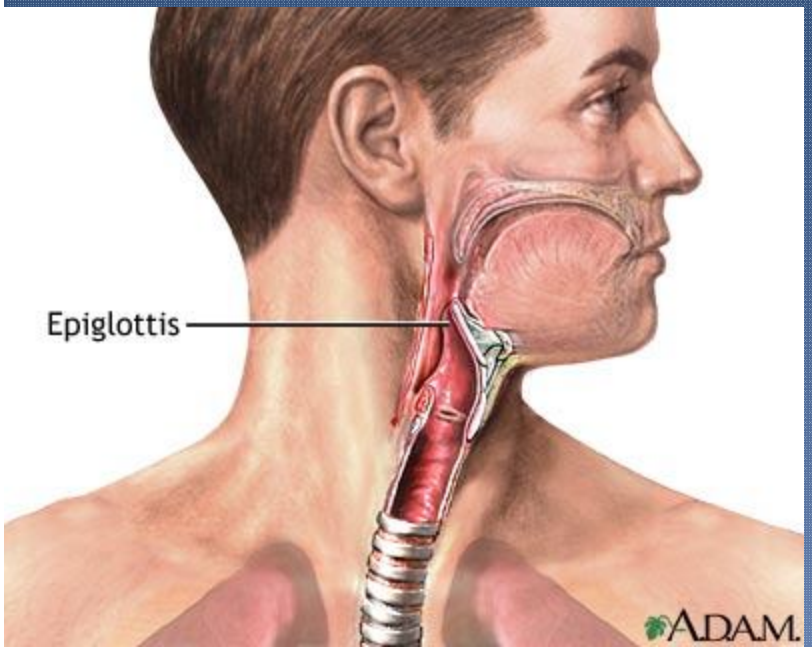

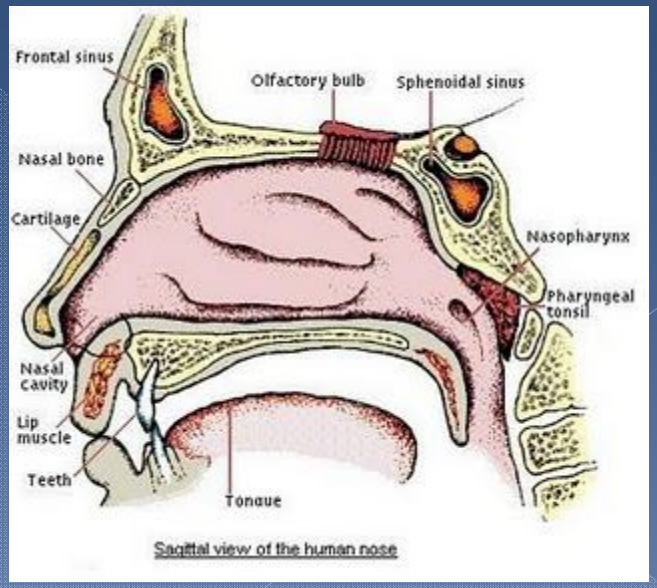

Identify this Cartilage:

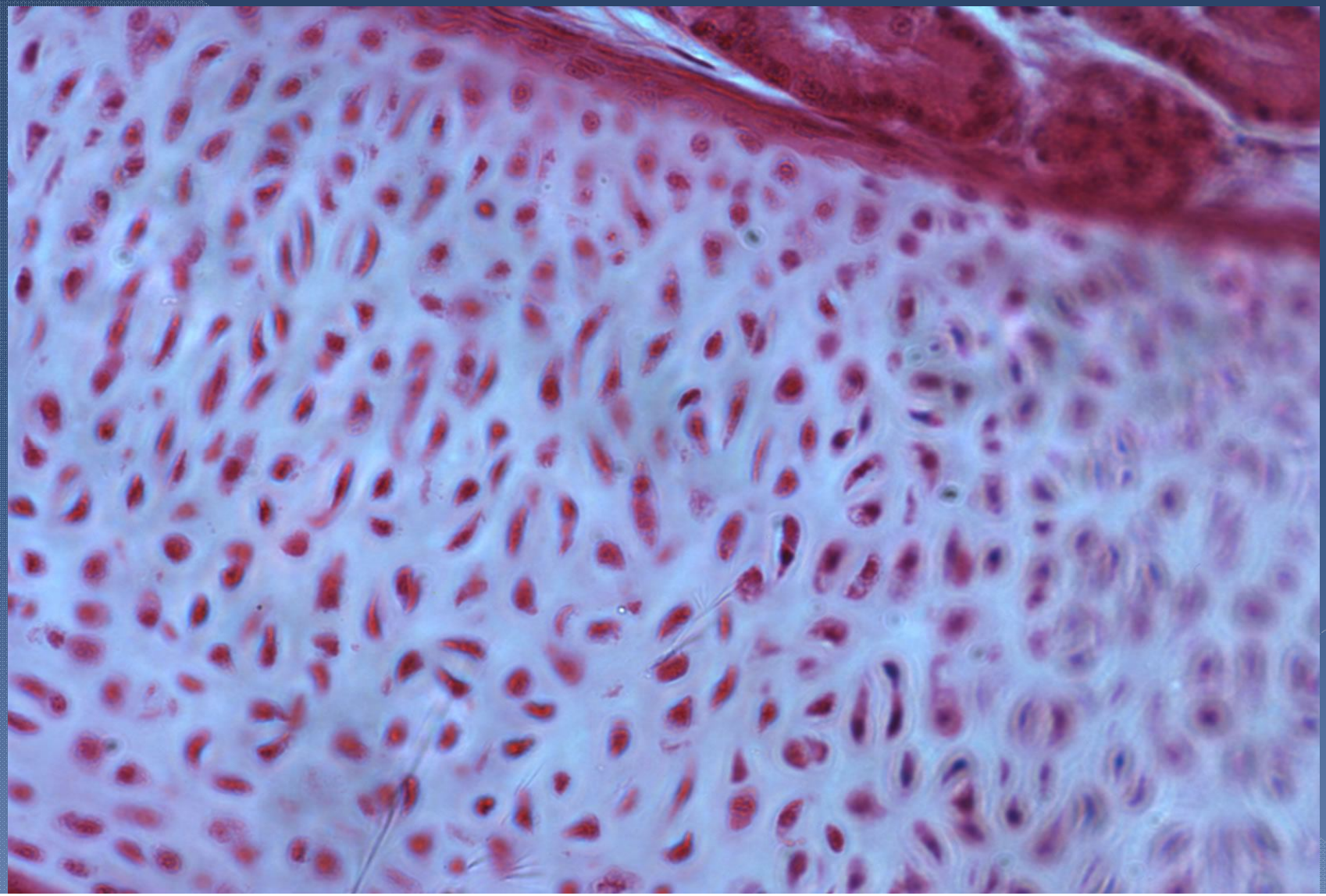

Joints

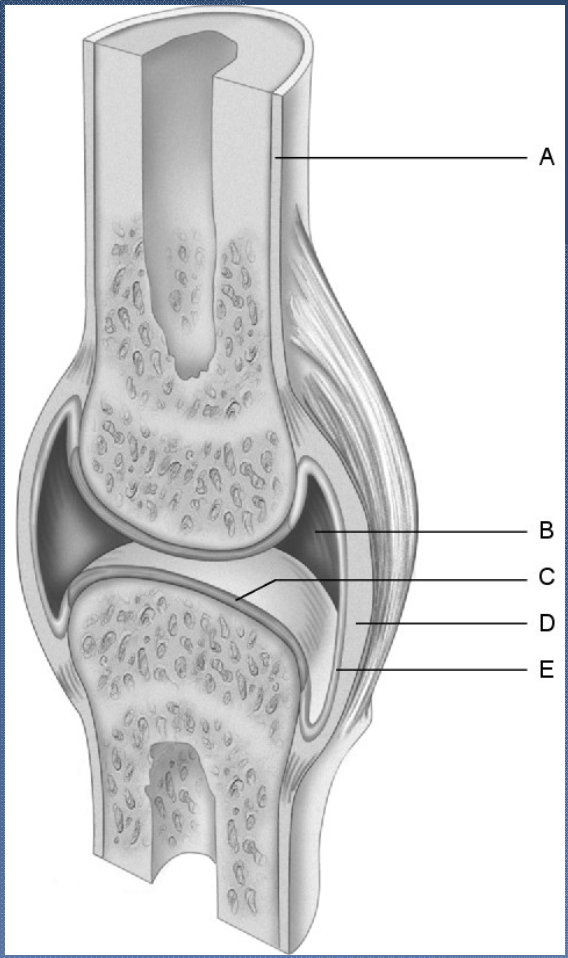

- A - Periosteum
- B - Joint (synovial) cavity
- C - Articular cartilage
- D - Fibrous capsule
- E - Synovial membrane

- Glenohumeral
- Acetabularfemeral
- Tibiofemeral
- Intervertebral
- Humerounlnar
- Radiocarpal
- Gomphoses

- Hip joint
- Shoulder
- Elbow
- Wrist
- Teeth
- Spine
- Knee

- Ball and socket joint
- Hinge joint
- Condyoid joint
- Symphisis joint
- Amphiathosis joint
- Peg and socket joint

- Synarthroses
- Amphiartroses
- Diarthroses

- Slightly movable joints
- Freely movable joints
- Immovable joints

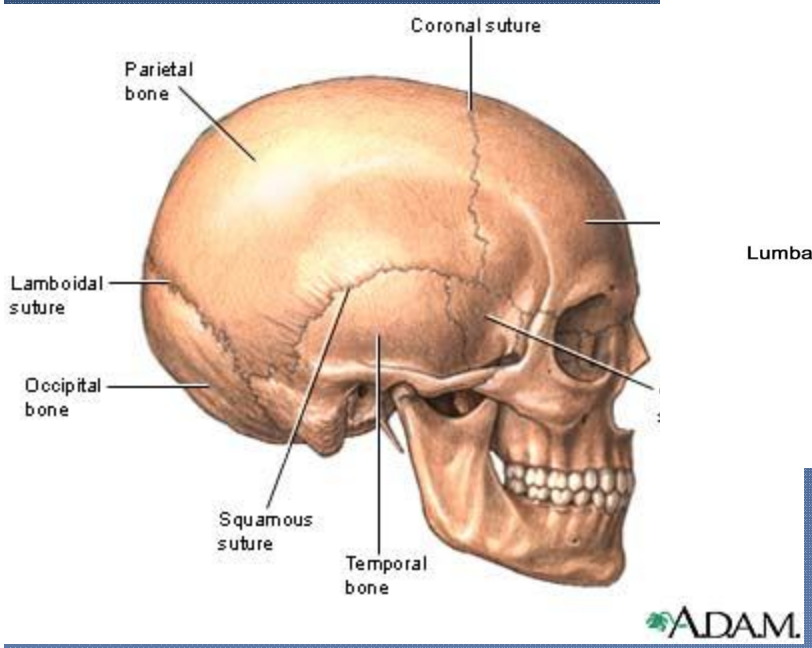

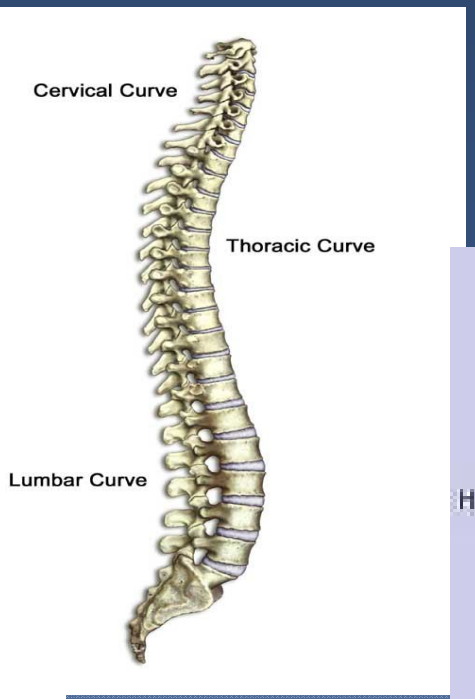

1. TCL
2. Medial Condyle
3. PCL
4. ACL
5. Lateral Condyle
6. FCL
7. Lateral condyle of Tibia
8. Lateral Meniscus
9. Medial Menisucs
10. Medial condyle of the Tibia
11. Tibia
12. Fibula
13. Transverse Ligament

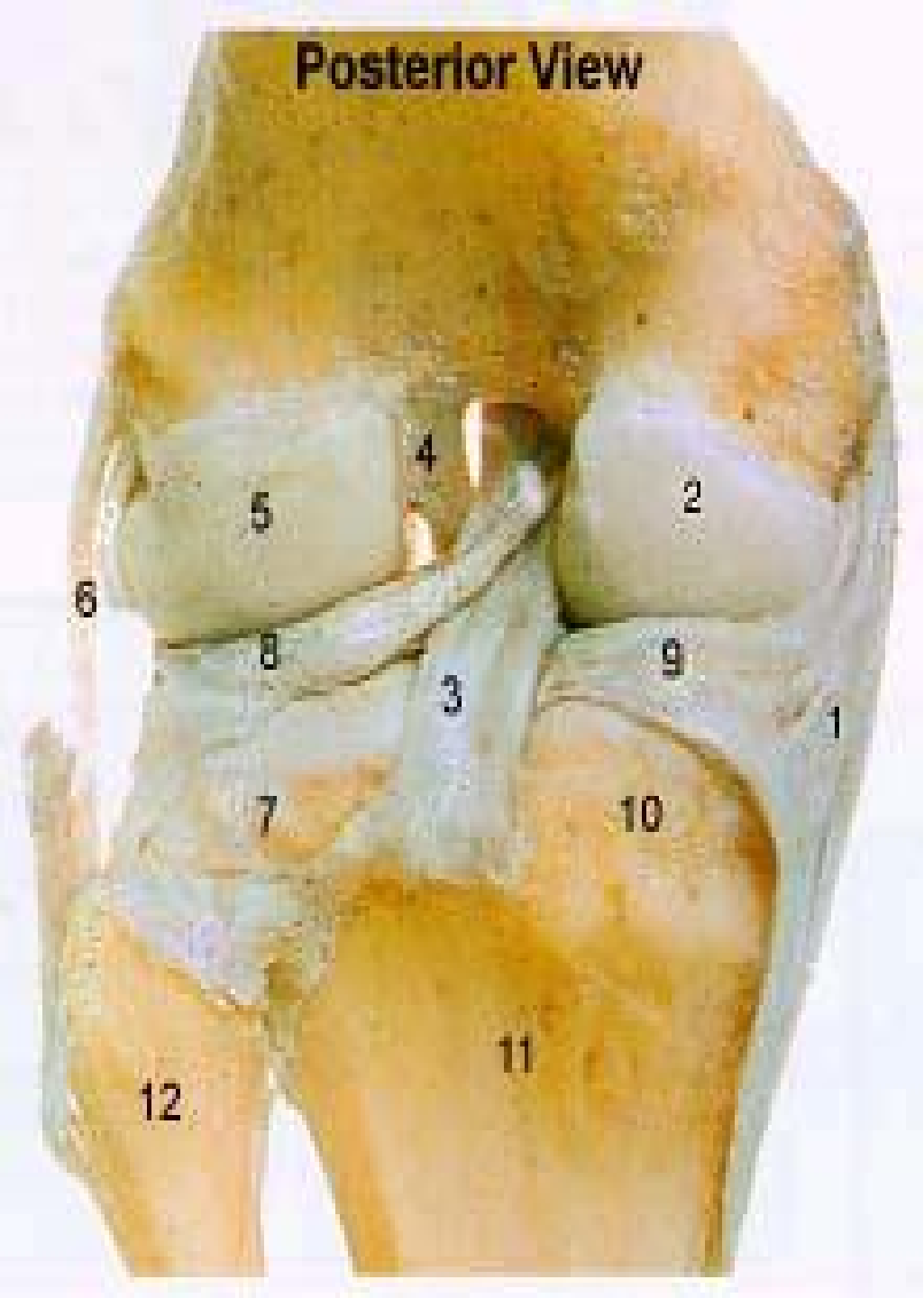

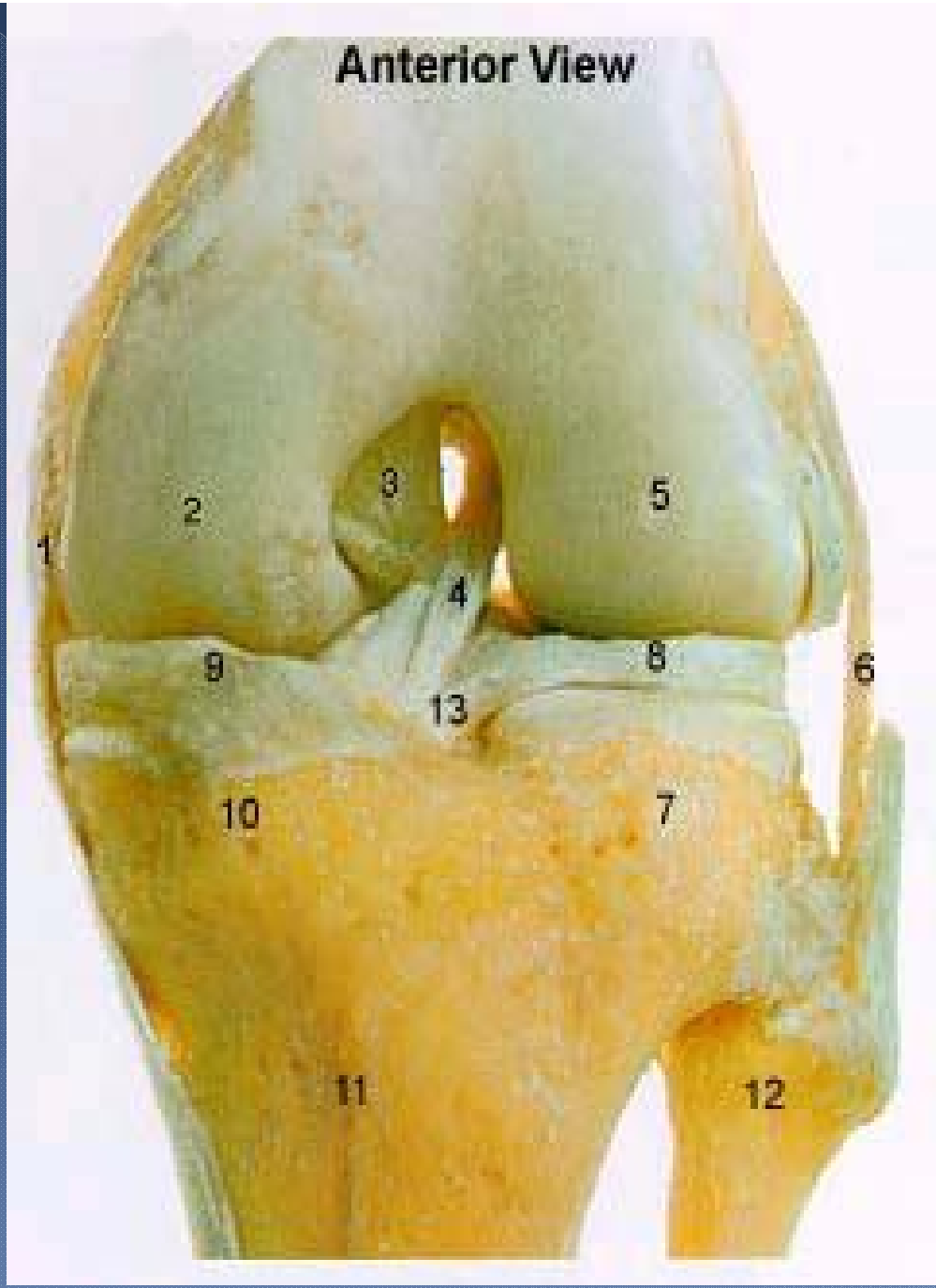

1. TCL
2. Medial Condyle
3. PCL
4. ACL
5. Lateral Condyle
6. FCL
7. Lateral condyle of Tibia
8. Lateral Meniscus
9. Medial Meniscus
10. Medial condyle of the Tibia
11. Tibia
12. Fibula
13. Transverse Ligament

Location of fibrous cartilage:

- Pubic symphysis
- Vertebrae
- Meniscus

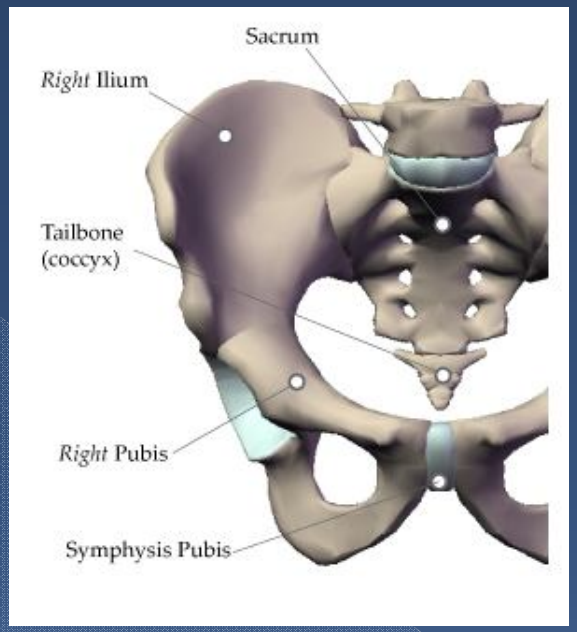

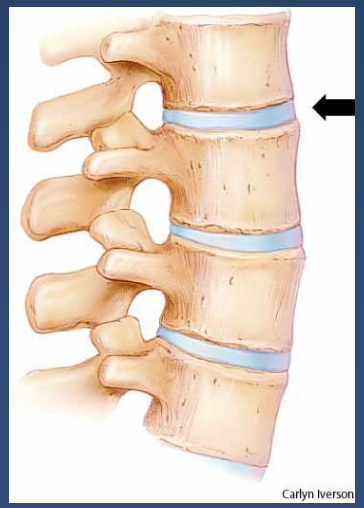

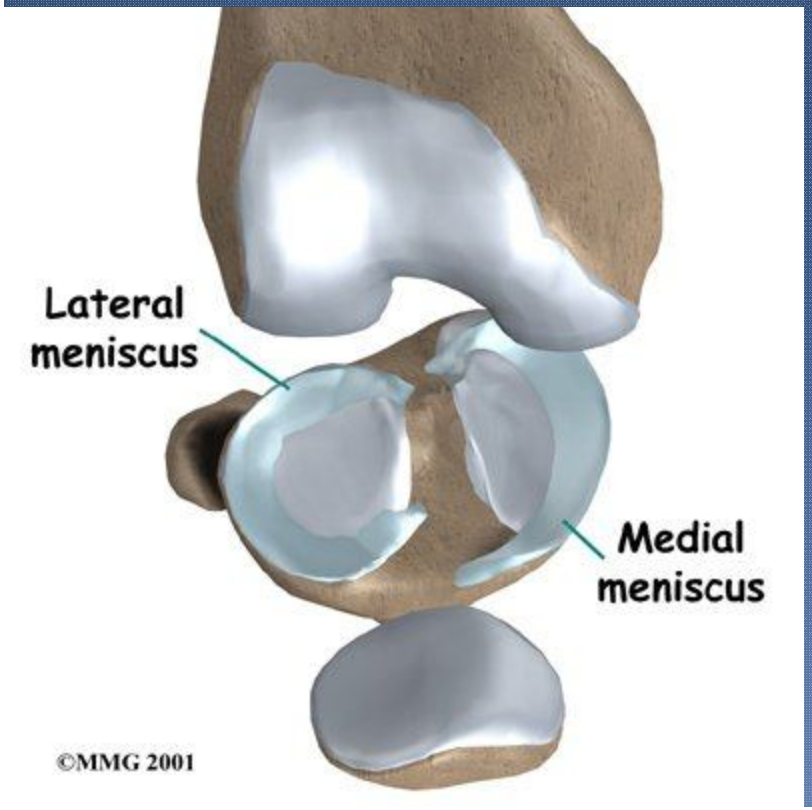

True or False?

- The pectoral girdles are responsible for attaching the superior appendages to the axial skeleton.

- The glenoid depression faces medially and is the socket where the scapula articulates with the humerus.

- The pectoral girdle consists of two bones: the scapula and the clavicle.

- The coracoid process serves as a point of attachment for the triceps muscle.