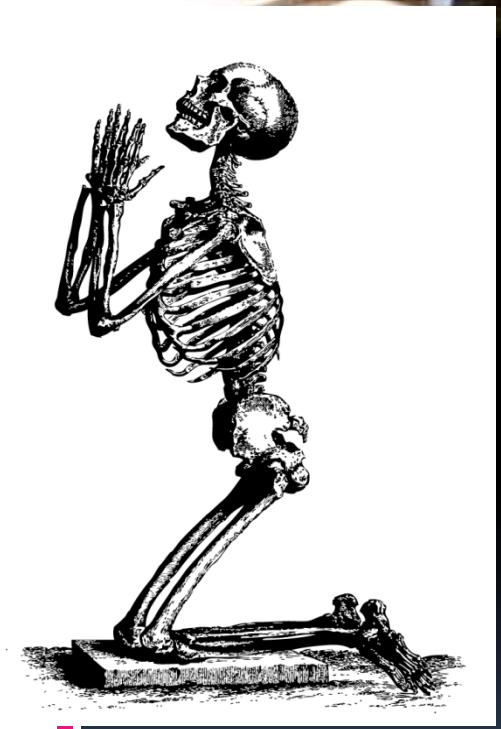

BONES AND JOINTS INTRODUCTION

Danil Hammoudi.MD

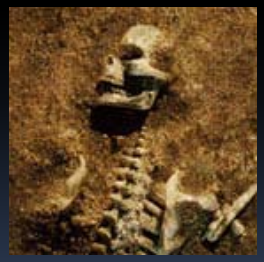

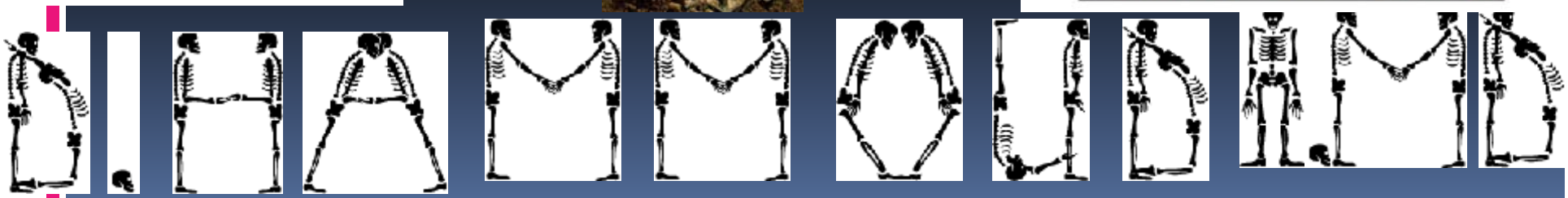

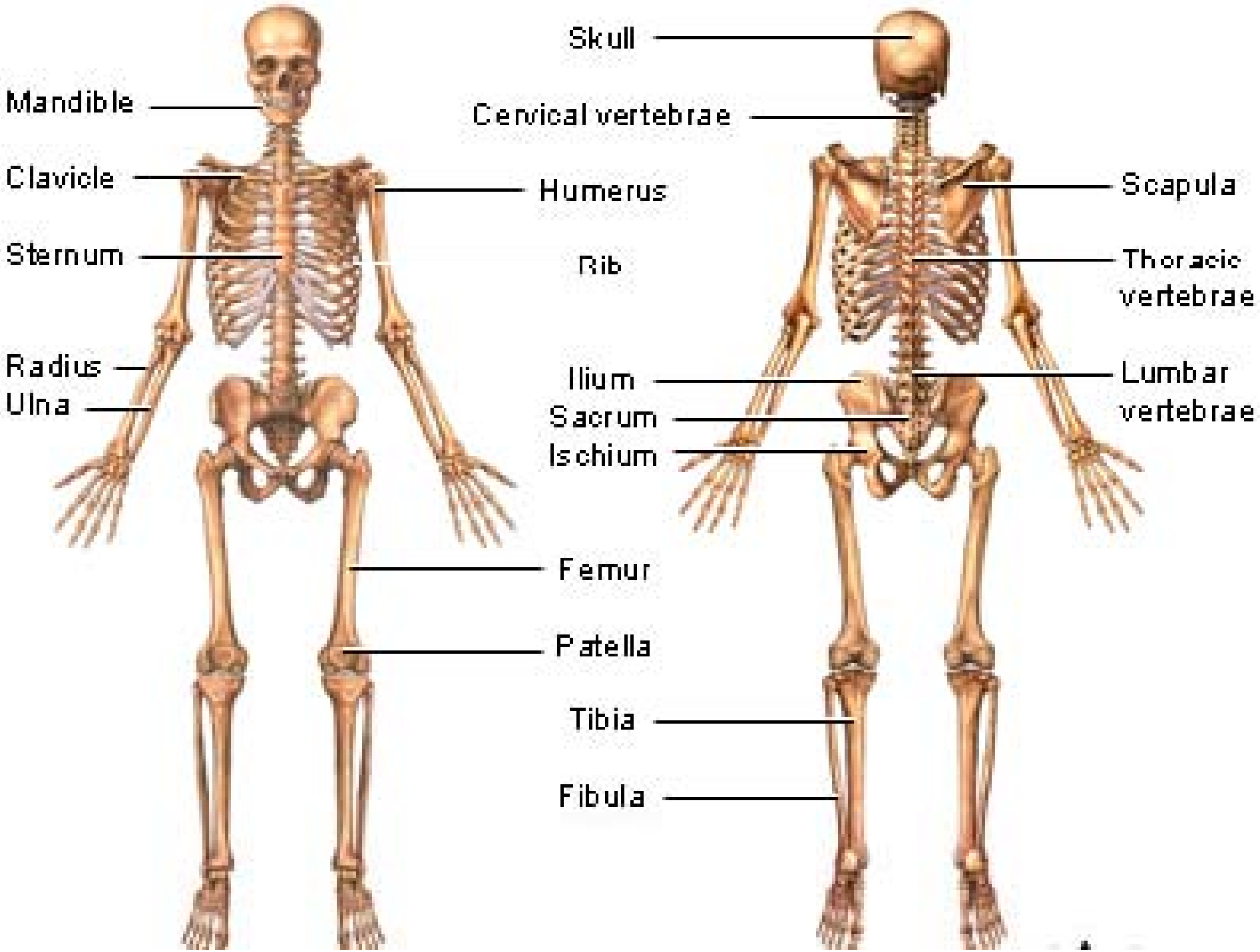
Mandible
Clavicle
Sternum
Radius
Ulna
Humerus
Rib
Femur
Patella
Skull
Cervical vertebrae
Scapula
Thoracic vertebrae
Ilium
Sacrum
Ischium
Lumbar vertebrae
Tibia
Fibula

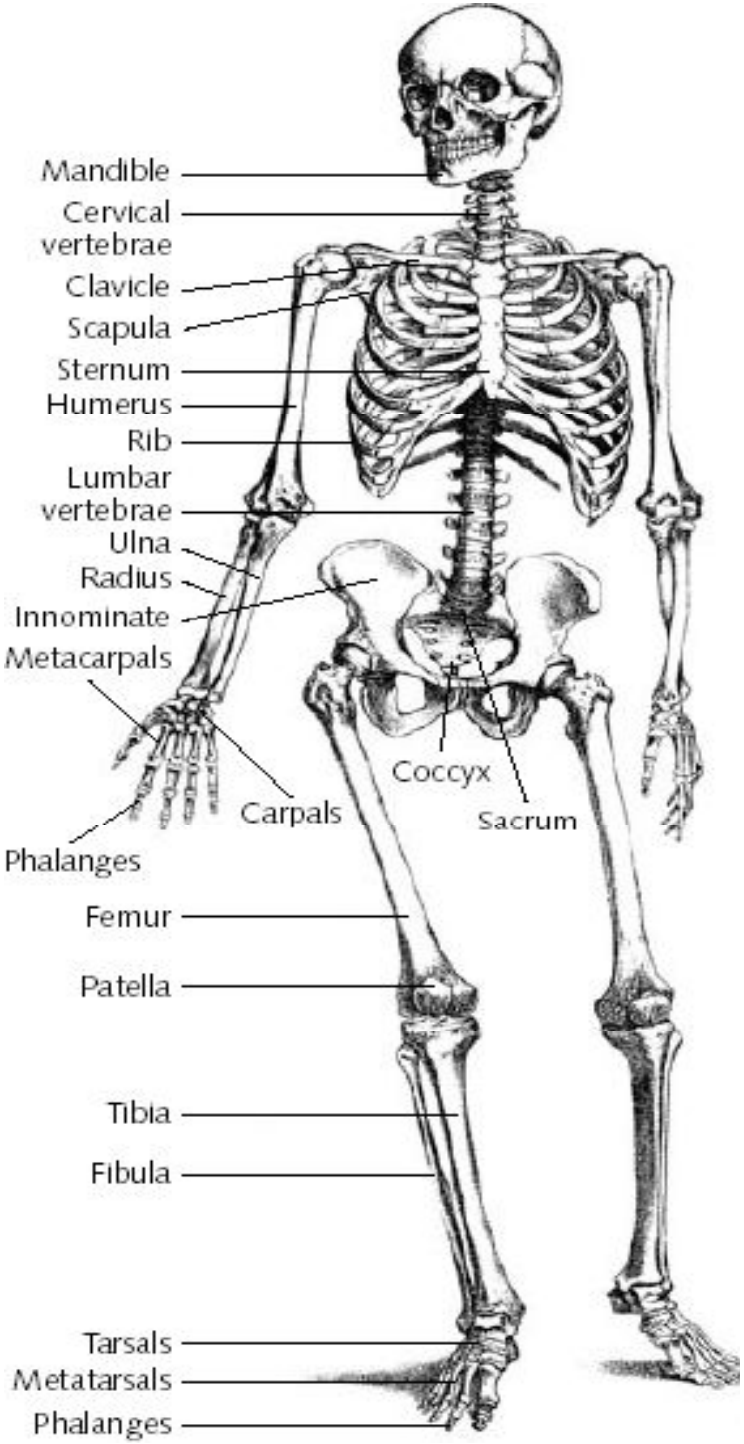
Mandible
Cervical vertebrae
Clavicle
Scapula
Sternum
Humerus
Rib
Lumbar vertebrae
Ulna
Radius
Innominate
Metacarpals
Carpals
Phalanges
Coccyx
Sacrum
Femur
Patella
Tibia
Fibula
Tarsals
Metatarsals
Phalanges

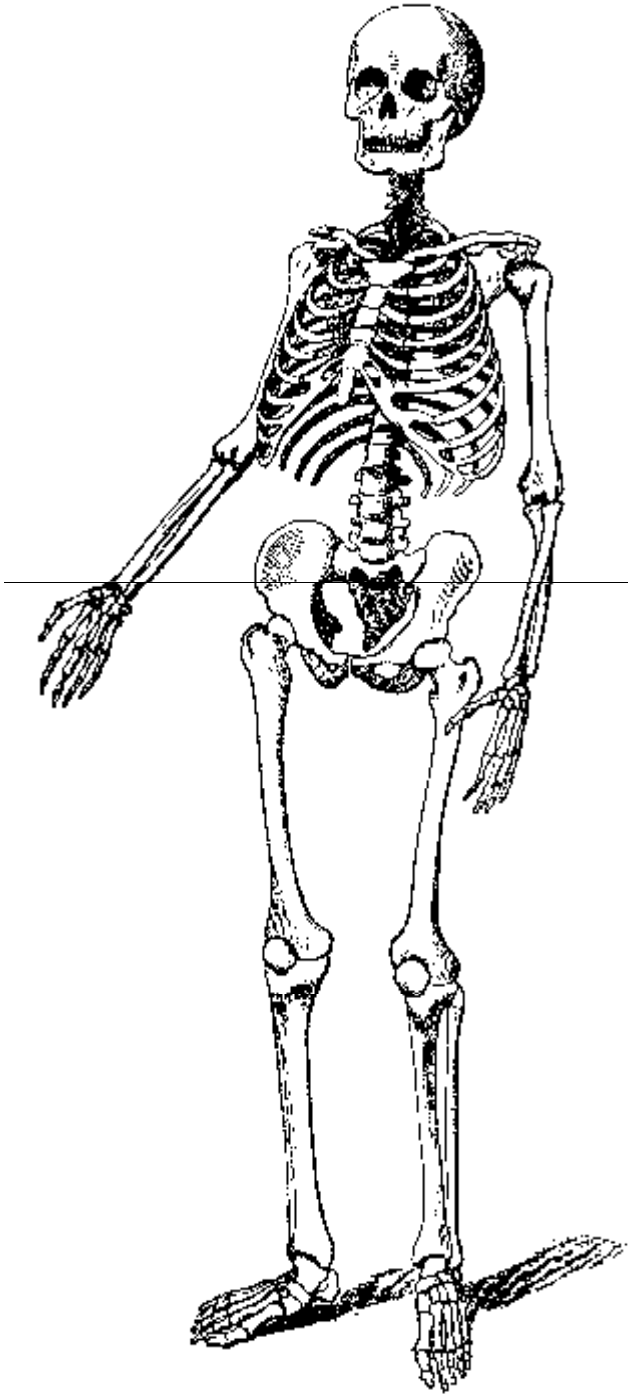

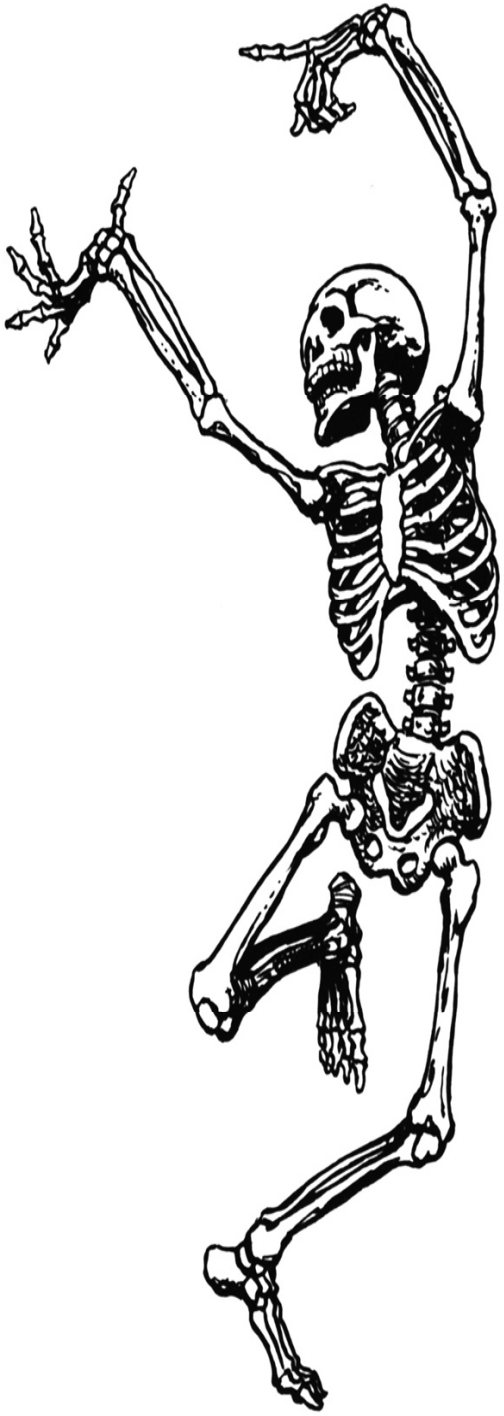

GENERALITY

- The human skeleton consists of **206 bones**. more than half of them are located just in our hands and feet!

- We are actually born with more bones (about 300), but many fuse together as a child grows up.

- These bones support your body and allow you to move.

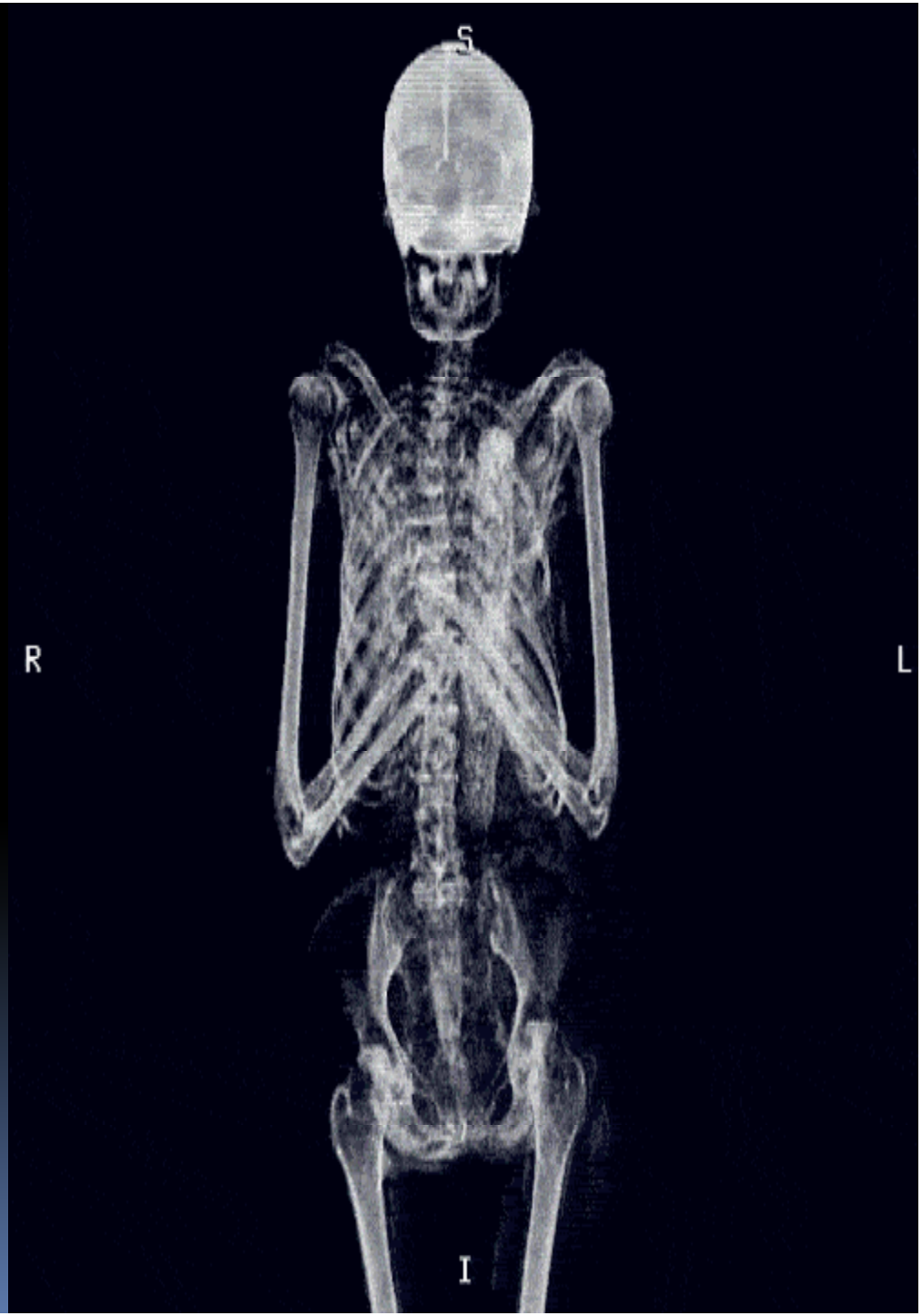

The facts

- Human thigh bones are stronger than concrete, the Femur bone as it's called, easily capable of lifting or supporting 30 times its own volume and weight
- The longest bone, strongest bone in our bodies is the **femur** (thigh bone).
- The smallest bone is the **stirrup bone inside the ear.**
- Each hand has 26 bones in it.
- Your nose and ears are not made of bone; they are **made of cartilage**.
- **Your bones consist of 50% water and 50% solid matter.**
- **By the age of 20, the average young person has acquired roughly 98% of his/her skeletal mass.**
- Adult human bones account for 14% of the body's total weight.
- Our ribs move about 5 million times a year, every time we breathe!
- For every 100 milligrams of caffeine (the amount in a small to medium-sized cup of coffee), you lose 6 milligrams of calcium.

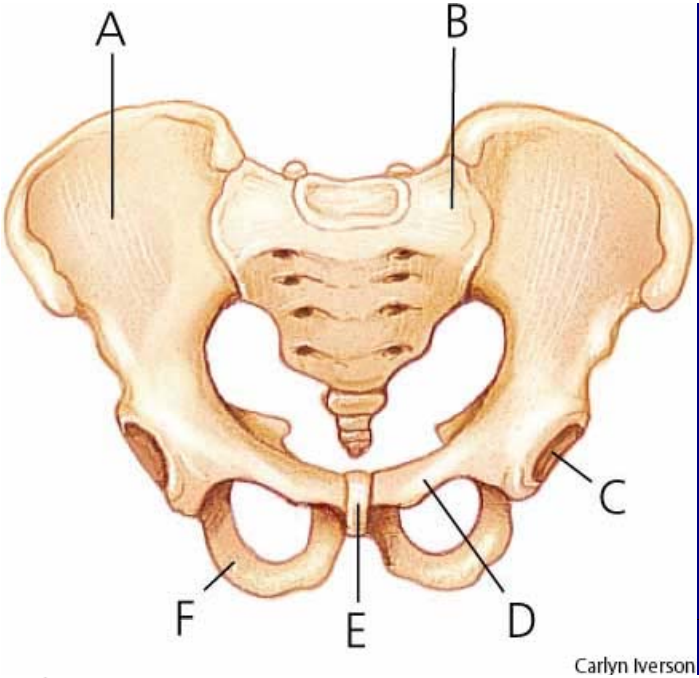

- The largest bone is the pelvis [6 bones]
- A. ilium
  B. sacrum
  C. acetabulum
  D. pubis
  E. pubic symphysis
  F. ischium

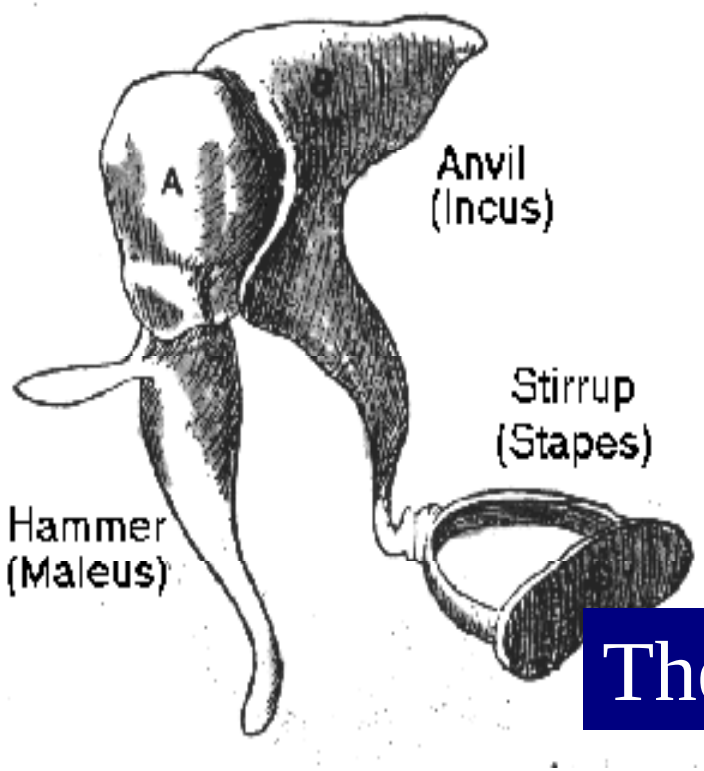

- The longest bone = femur

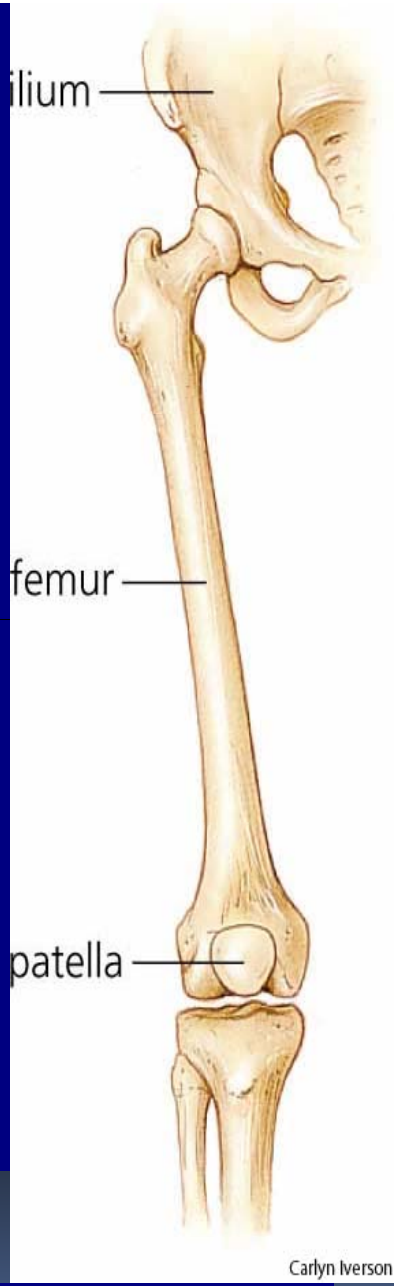

The smallest bone is = stirrup [ears]

How many bones

- Skull and upper jaw : 21 bones
- Ears : 3 tiny bones x 2
- Lower jaw
- Front neck bone = hyoid
- Backbone or spine = 26 vertebra
- Ribs = 12 x2
- Breastbone
- Each upper limb = 32 bones: 2 shoulder, 3 in arms, 8 in wrist, 19 in hands and fingers
- Each lower limb has 31 bones: 1 in hip one side,4 in legs, 7 in ankle, 19 foot and toes.

sskeletal Vocabulary

1. **Tuberosity** – large, rounded projection
2. **Trochanter** – large, irregularly shaped process
3. **Tubercle** – small, rounded projection
4. **Epicondyle** – raised area on or above a condyle
5. **Condyle** – rounded articular projection
6. **Fossa** – shallow, superficial depression
7. **Fissure** – narrow slit-like opening
8. **Foramen** – round opening



Tibial Tuberosity

Tuberosity refers to round elevation (bump) from the bone

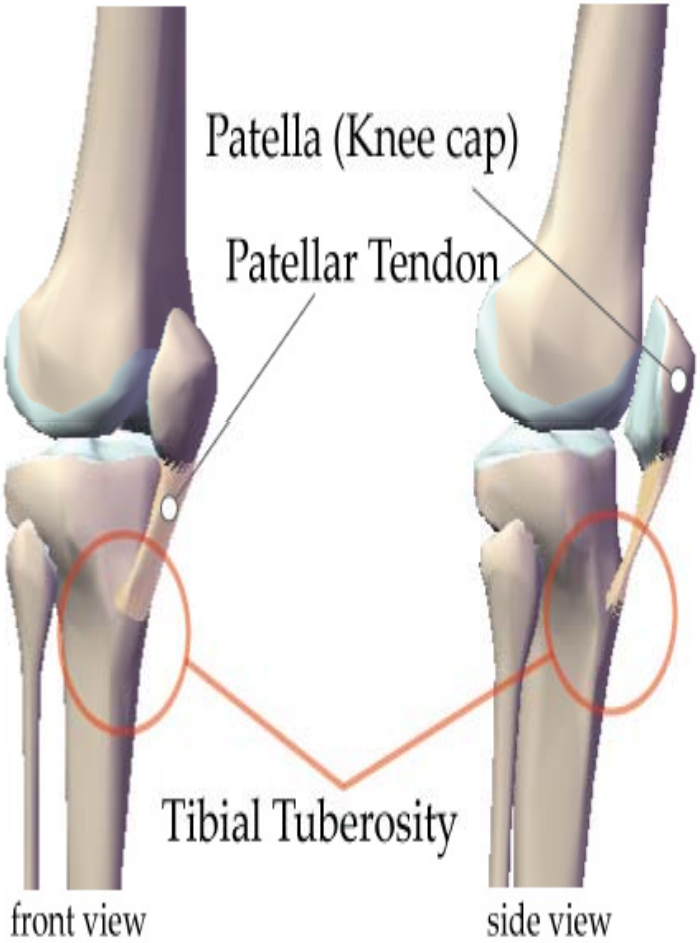

source: visiblebody & core concepts

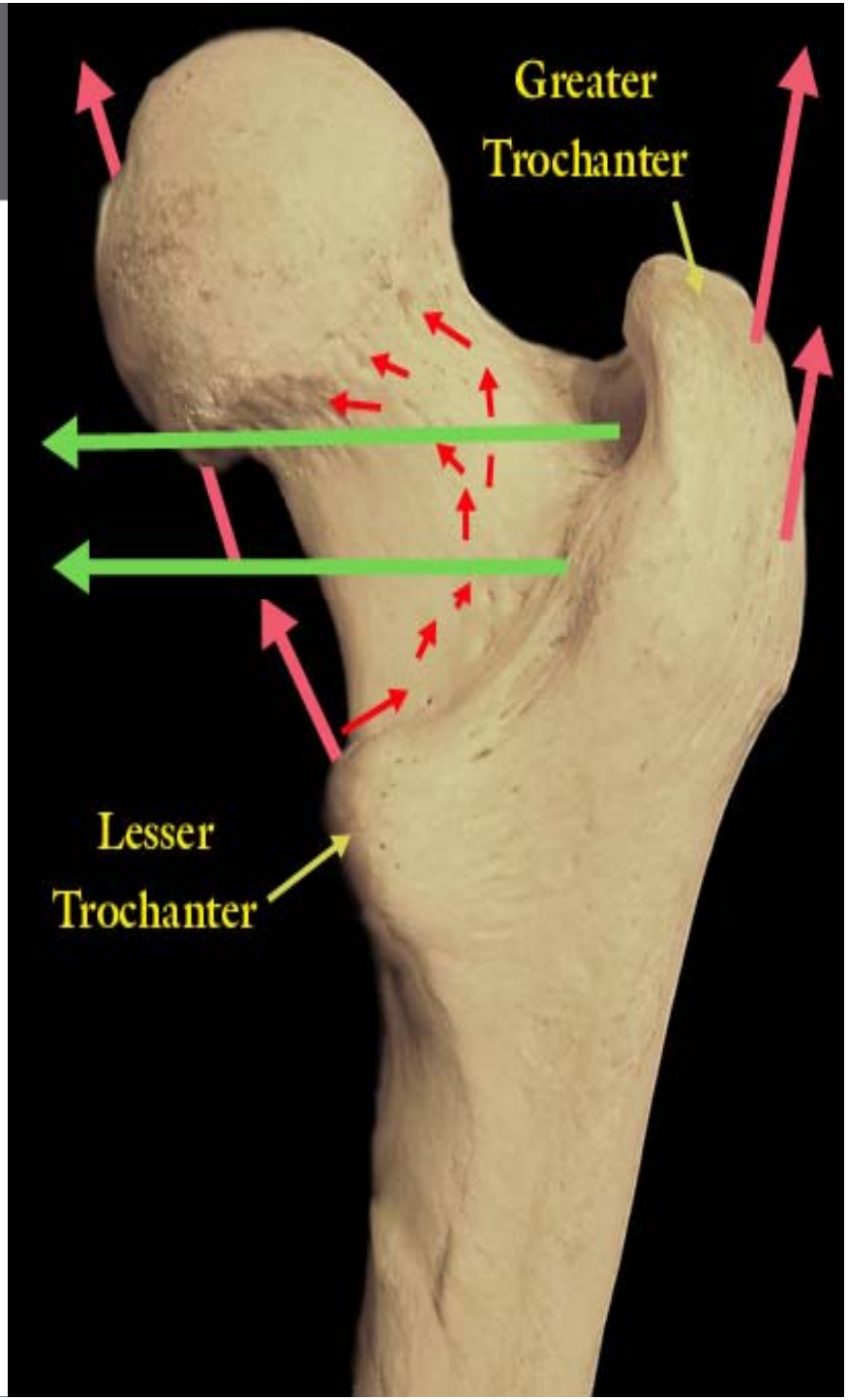

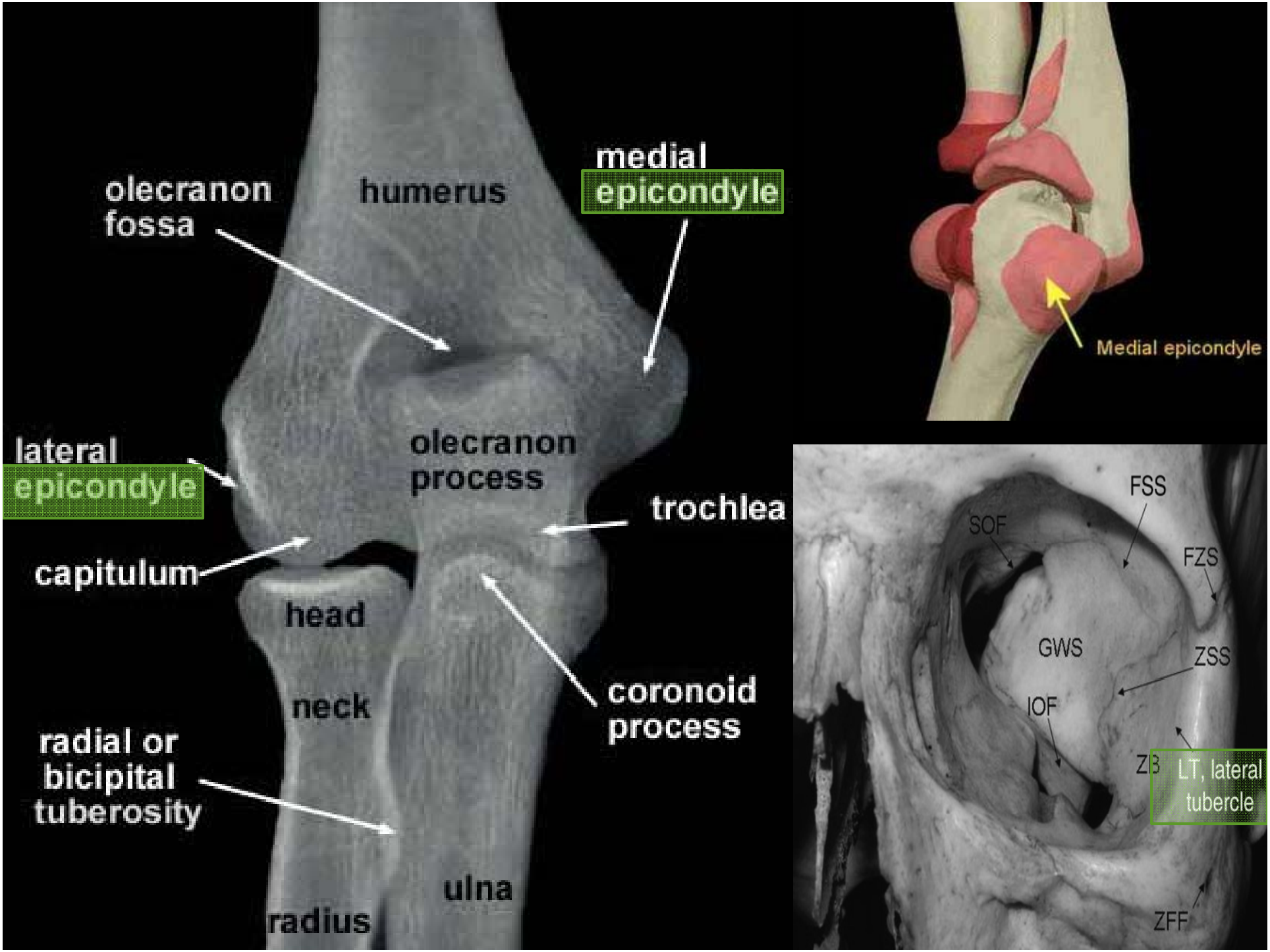
olecranon fossa
humerus
medial epicondyle
lateral epicondyle
olecranon process
trochlea
capitulum
head
neck
coronoid process
radial or bicipital tuberosity
ulna
radius
Medial epicondyle
FSS
SOF
FZS
GWS
ZSS
IOF
ZB
LT, lateral tubercle
ZFF

Bone Markings: Projections – Sites of Muscle and Ligament Attachment

- ***Tuberosity*** – rounded projection [at the end of a bone for the attachment of a muscle or tendon]
- ***Crest*** – narrow, prominent ridge of bone
- ***Trochanter*** – large, blunt, irregular surface
- ***Line*** – narrow ridge of bone

Bone Markings: Projections – Sites of Muscle and Ligament Attachment

- Tubercle – small rounded projection
- Epicondyle – raised area above a condyle
- Spine – sharp, slender projection
- Process – any bony prominence

Bone Markings: Projections – Projections That Help to Form Joints

- **Head** – bony expansion carried on a narrow neck
- **Facet** – smooth, nearly flat articular surface
- **Condyle** – rounded articular projection
- **Ramus** – armlike bar of bone

Bone Markings: Depressions and Openings

- Meatus – canal-like passageway
- Sinus – cavity within a bone
- Fossa – shallow, basin-like depression
- Groove – furrow
- **Fissure** – narrow, slit-like opening
- **Foramen** – round or oval opening through a bone

Bone Markings

TABLE 6.1 Bone Markings

NAME OF BONE MARKING	DESCRIPTION
PROJECTIONS THAT ARE SITES OF MUSCLE AND LIGAMENT ATTACHMENT	
Tuberosity (too″bĕ-ros′ĭ-te)	Large rounded projection; may be roughened
Crest	Narrow ridge of bone; usually prominent
Trochanter (tro-kan′ter)	Very large, blunt, irregularly shaped process (the only examples are on the femur)
Line	Narrow ridge of bone; less prominent than a crest
Tubercle (too′ber-kl)	Small rounded projection or process
Epicondyle (ep″ĭ-kon′dĭl)	Raised area on or above a condyle
Spine	Sharp, slender, often pointed projection
Process	Any bony prominence
PROJECTIONS THAT HELP TO FORM JOINTS	
Head	Bony expansion carried on a narrow neck
Facet	Smooth, nearly flat articular surface
Condyle (kon′dīl)	Rounded articular projection
Ramus (ra′mus)	Armlike bar of bone
DEPRESSIONS AND OPENINGS ALLOWING BLOOD VESSELS AND NERVES TO PASS	
Meatus (me-a′tus)	Canal-like passageway
Sinus	Cavity within a bone, filled with air and lined with mucous membrane
Fossa (fos′ah)	Shallow, basinlike depression in a bone, often serving as an articular surface
Groove	Furrow
Fissure	Narrow, slitlike opening
Foramen (fo-ra′men)	Round or oval opening through a bone

Table 6.1

Gross Anatomy of Bones: Bone Textures

- **Compact bone** – dense outer layer
- **Spongy bone** – honeycomb of trabeculae filled with yellow bone marrow

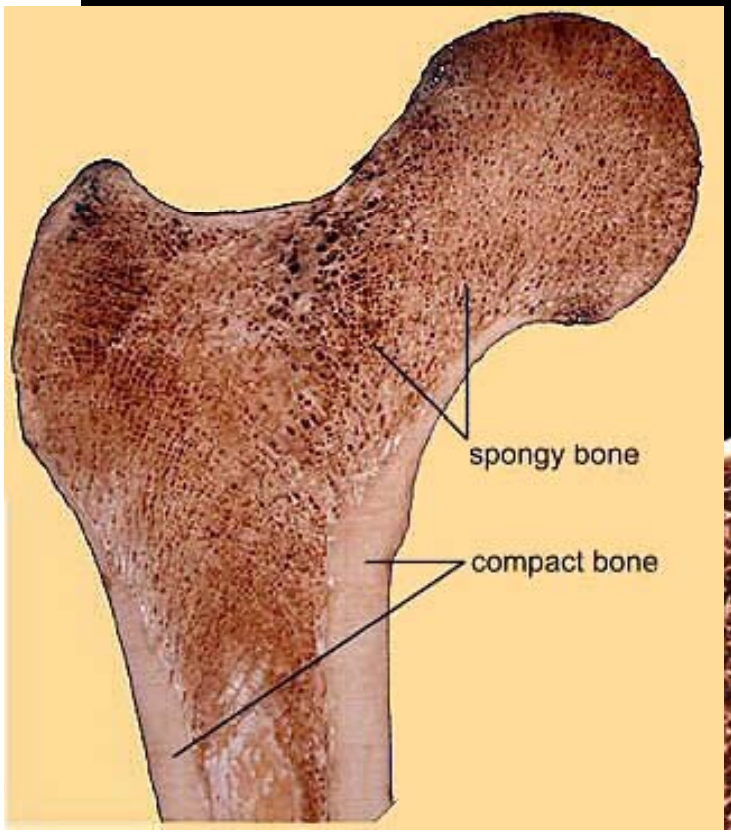

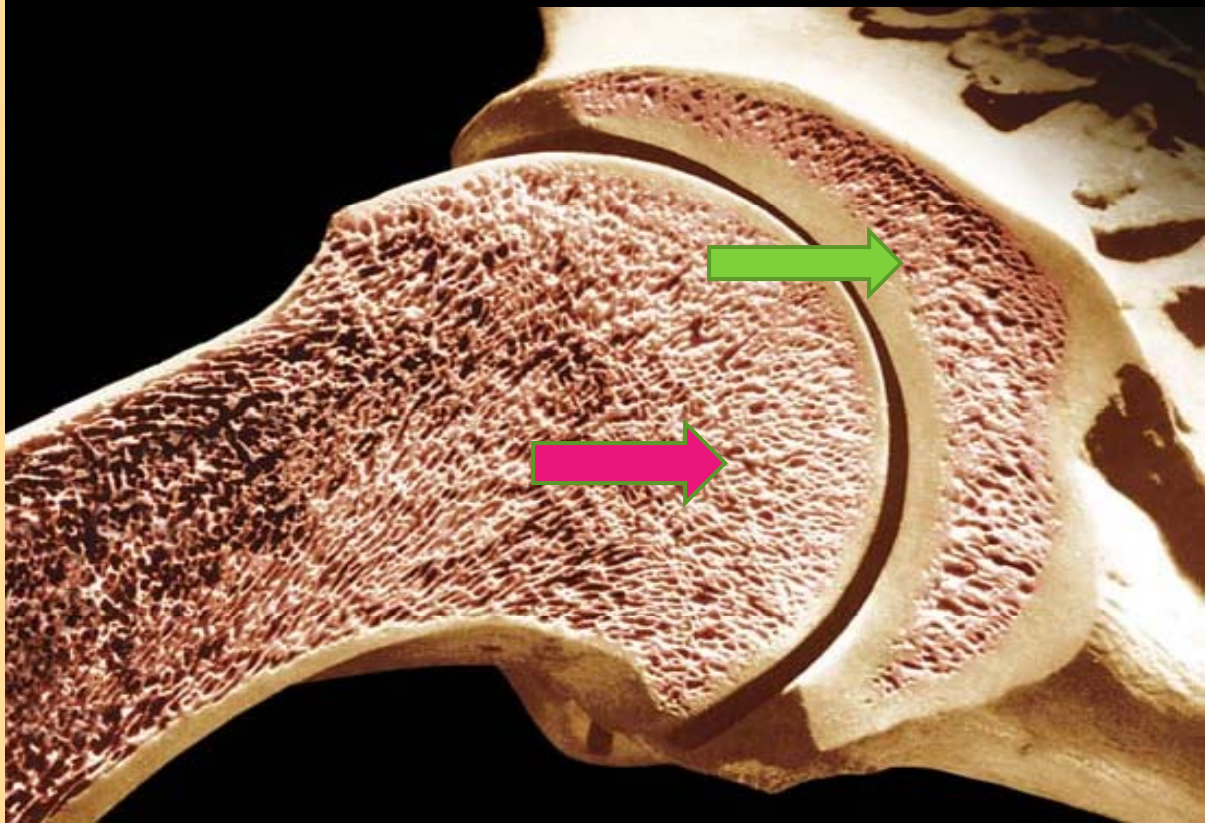

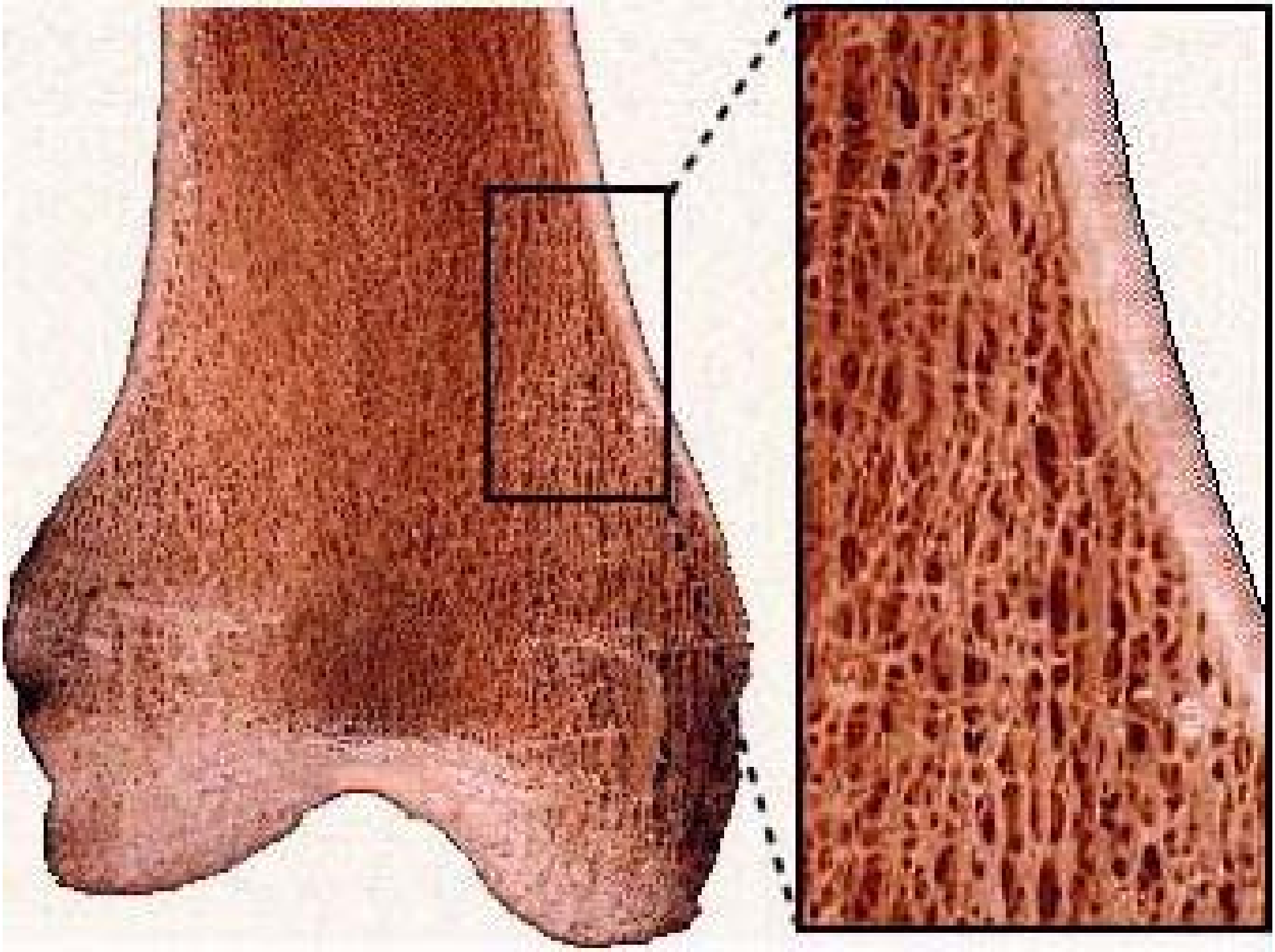

Functions of bone

- Bones function in:
  - Support of soft tissues
  - Movement
  - Protection
  - Mineral homeostasis - calcium and phosphate
  - Blood cell production - red marrow

Mechanical

Protection — bones can serve to protect internal organs, such as the skull protecting the brain or the ribs protecting the heart and lungs.

Structure — bones provide a frame to keep the body supported.

Movement — bones, skeletal
muscles, tendons, ligaments and joints function together to generate and transfer forces so that individual body parts or the whole body can be manipulated in three-dimensional space. The interaction between bone and muscle is studied in biomechanics.

Sound transduction — bones are important in the mechanical aspect of overshadowed hearing.

Skeletal System

Composed of the body's bones and associated ligaments, tendons, and cartilages.

1. **Support [see previous slide]**
   - The bones of the legs, pelvic girdle, and vertebral column support the weight of the erect body.
   - The mandible (jawbone) supports the teeth.
   - Other bones support various organs and tissues.
2. Protection
   - The bones of the skull protect the brain.
   - Ribs and sternum (breastbone) protect the lungs and heart.
   - Vertebrae protect the spinal cord.

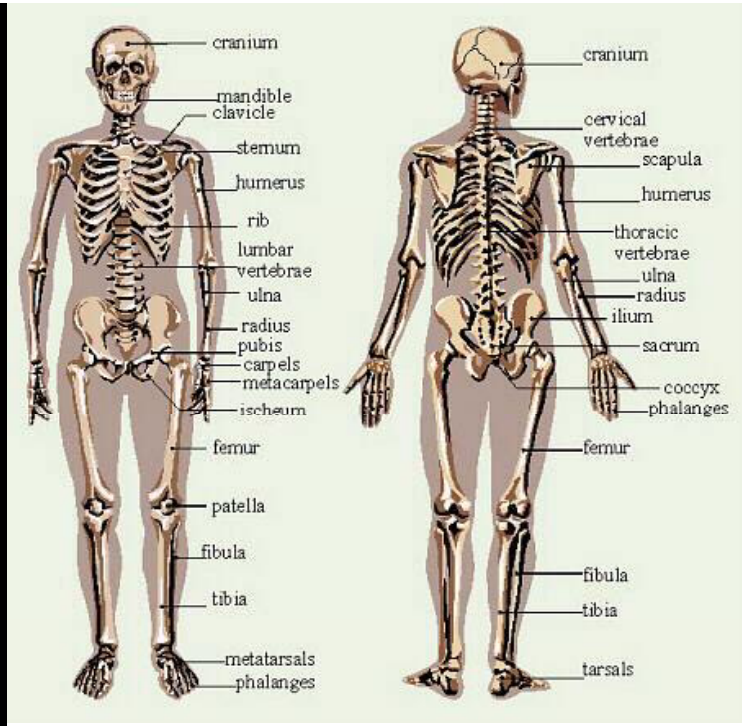

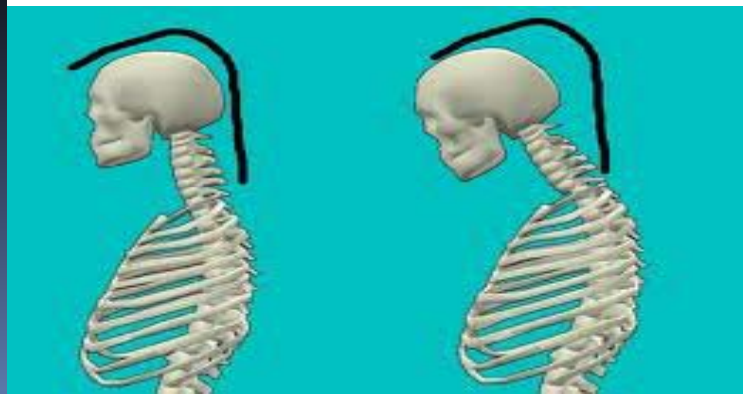

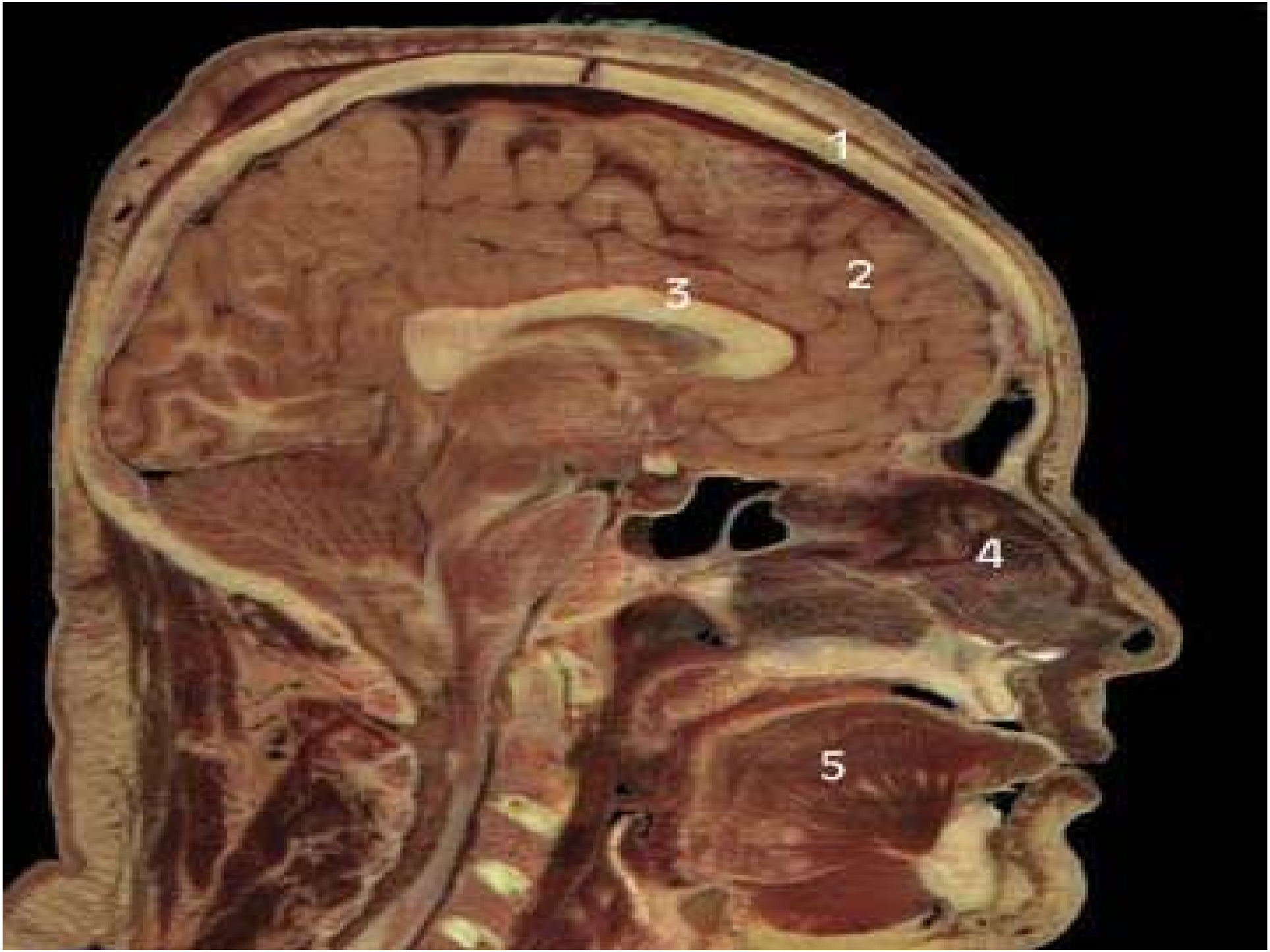
1
2
3
4
5

Skeletal System

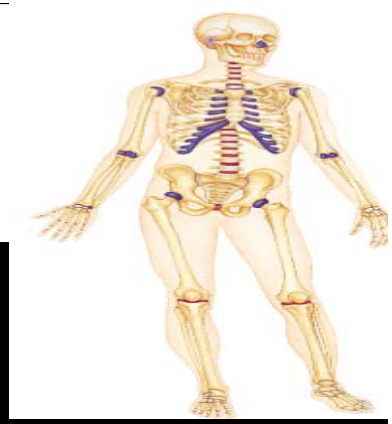

3. Movement
   - Skeletal muscles use the bones as levers to move the body.
4. Reservoir for minerals and adipose tissue
   - 99% of the body's calcium is stored in bone.
   - 85% of the body's phosphorous is stored in bone.
   - Adipose tissue is found in the marrow of certain bones.
5. **Synthetic =**Hematopoiesis [no really but has the component]
   - A.k.a. blood cell formation.
   - All blood cells are made in the marrow of certain bones.

Metabolic

- Mineral storage — bones act as reserves of minerals important for the body, most notably calcium and phosphorus.
- Growth factor storage — mineralized bone matrix stores important growth factors such as insulin-like growth factors, transforming growth factor, bone morphogenetic proteins and others.
- Fat storage — the yellow bone marrow acts as a storage reserve of fatty acids.
- Acid-base balance — bone buffers the blood against excessive pH changes by absorbing or releasing alkaline salts.
- Detoxification — bone tissues can also store heavy metals and other foreign elements, removing them from the blood and reducing their effects on other tissues. These can later be gradually released for excretion
- Endocrine organ — bone controls phosphate metabolism by releasing fibroblast growth factor – 23 (FGF-23), which acts on kidneys to reduce phosphate reabsorption. Bone cells also release a hormone called osteocalcin, which contributes to the regulation of blood sugar (glucose) and fat deposition. Osteocalcin increases both the insulin secretion and sensitivity, in addition to boosting the number of insulin-producing cells and reducing stores of fat

Bone Classification

- 2 large groups:
  - **Axial skeleton**
    - Forms long axis of the body.
    - Includes the bones of the skull, vertebral column, and rib cage.
    - These bones are involved in protection, support, and carrying other body parts.
  - **Appendicular skeleton**
    - Bones of upper & lower limbs and the girdles (shoulder bones and hip bones) that attach them to the axial skeleton.
    - Involved in locomotion and manipulation of the environment.

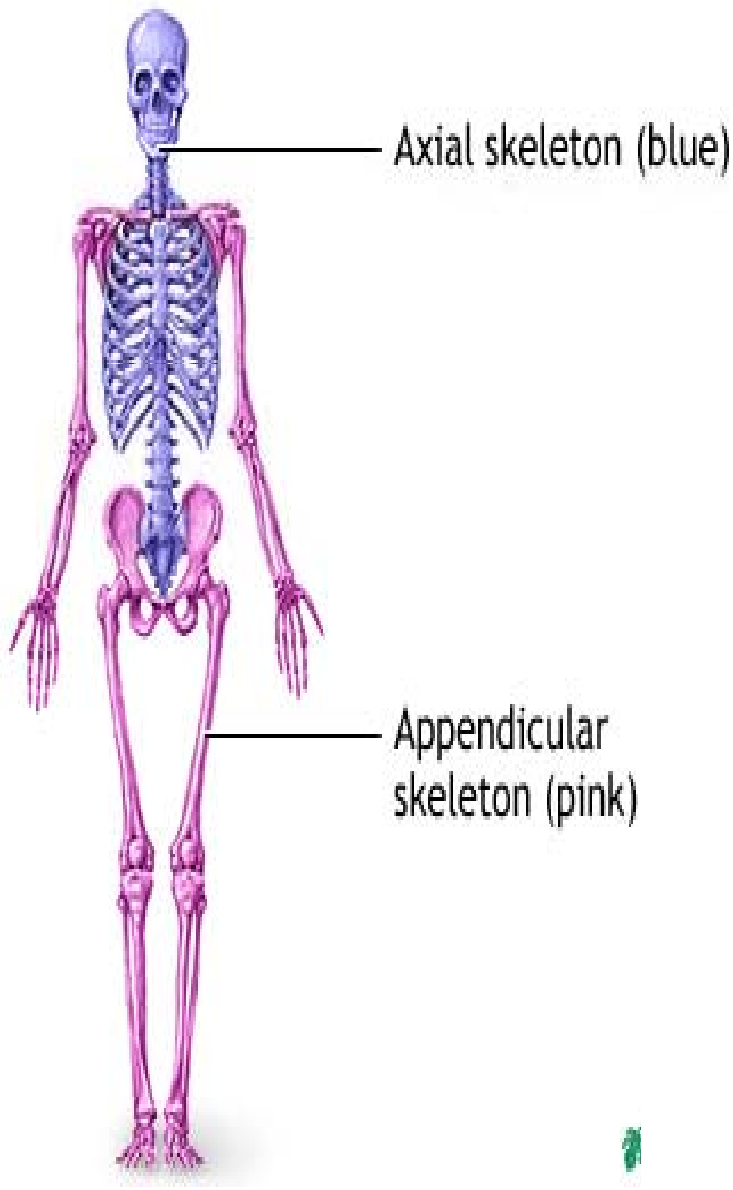

The skeleton has two parts:

- The axial skeleton
- the appendicular skeleton.

The axial skeleton includes 80 bones

- *the skull,*
- *The hyoid bone,*
- *The vertebral column (spine, sacrum, and coccyx),*
- *The sternum, and the ribs.*

- *Its components are aligned along the long axis of the body.*

The appendicular skeleton includes

- *Bones of the upper extremities (arms, forearms, and hands),*
- *The pectoral (shoulder) girdle,*
- *The pelvic (hip) girdle,*
- *The bones of the lower extremities (thigh, knee, leg, and foot).*
- *Its components are outside the body main axis*.

The appendicular skeleton of 126 bones and the axial skeleton of 80 bones together form the complete skeleton of 206 bones in the human body.

Unlike the axial skeleton, the appendicular skeleton is unfused. This allows for a much greater range of motion.

It is important to realize that through anatomical variation it is common for the skeleton to have many extra bones (sutural bones in the skull, cervical ribs, lumbar ribs and even extra lumbar vertebra)

Major Bones of the Axial Skeleton:

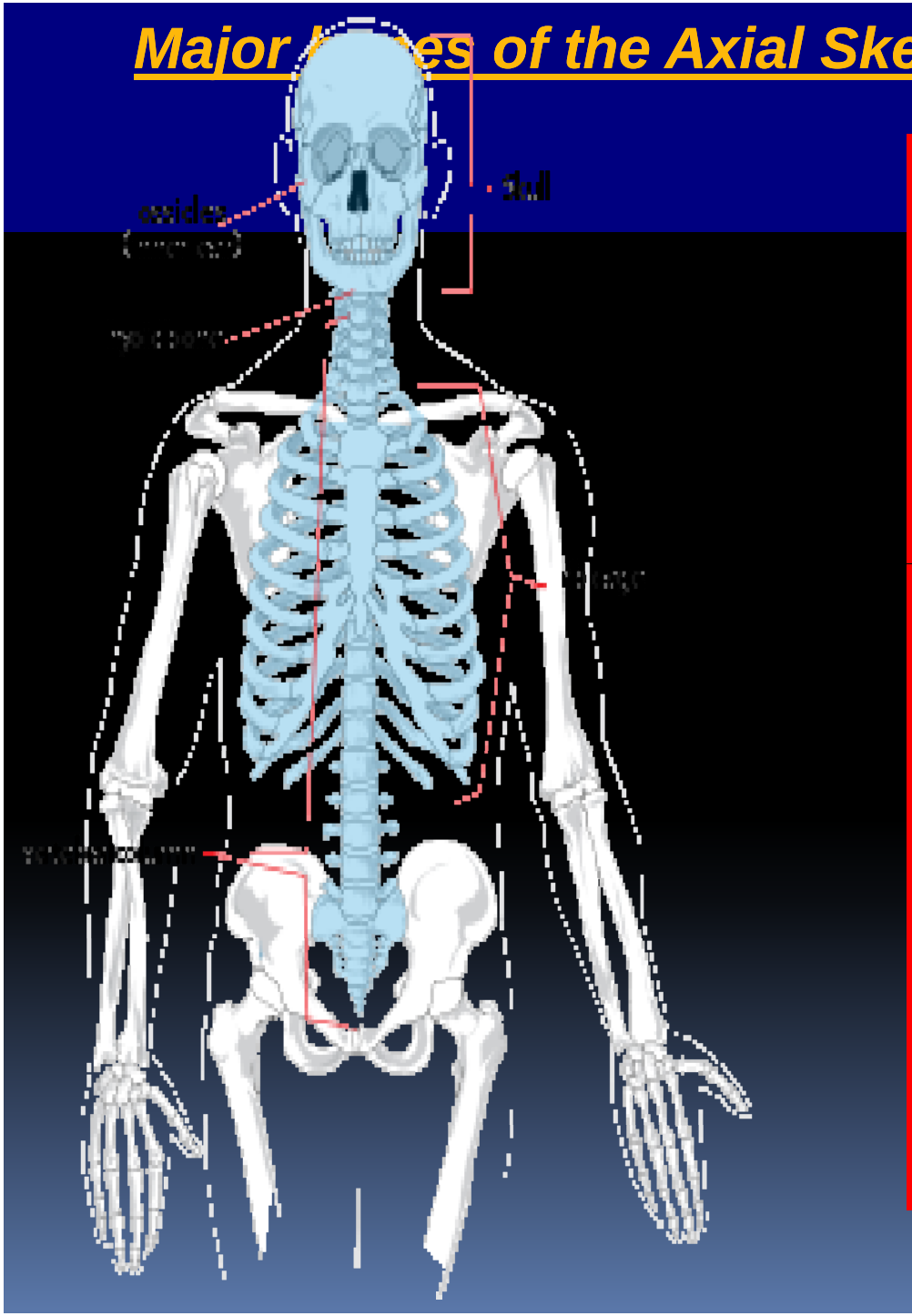

The **axial skeleton** consists of the 80 bones along the central axis of the human body. It is composed of six parts;

- The human skull,
- The ossicles of the middle ear,
- The hyoid bone of the throat,
- The rib cage,
- sternum
- the vertebral column

1) Pectoral Girdles (4 bones) - Left and right Clavicle (2) and Scapula (2).

2) Arm and Forearm (6 bones) - Left and right Humerus (2) (Arm), Ulna (2) and Radius (2) (Fore Arm).

3) Hands (54 bones) - Left and right Carpal (16) (wrist), Metacarpal (10), Proximal phalanges (10), Middle phalanges (8), distal phalanges (10).

4) Pelvis (2 bones) - Left and right os coxae (2) (ilium).

5) Thigh and leg (8 bones) - Femur (2) (thigh), Tibia (2), Patella (2) (knee), and Fibula (2) (leg).

6) Feet and ankles (52 bones) - Tarsals (14) (ankle), Metatarsals (10), Proximal phalanges (10), middle phalanges (8), distal phalanges (10).

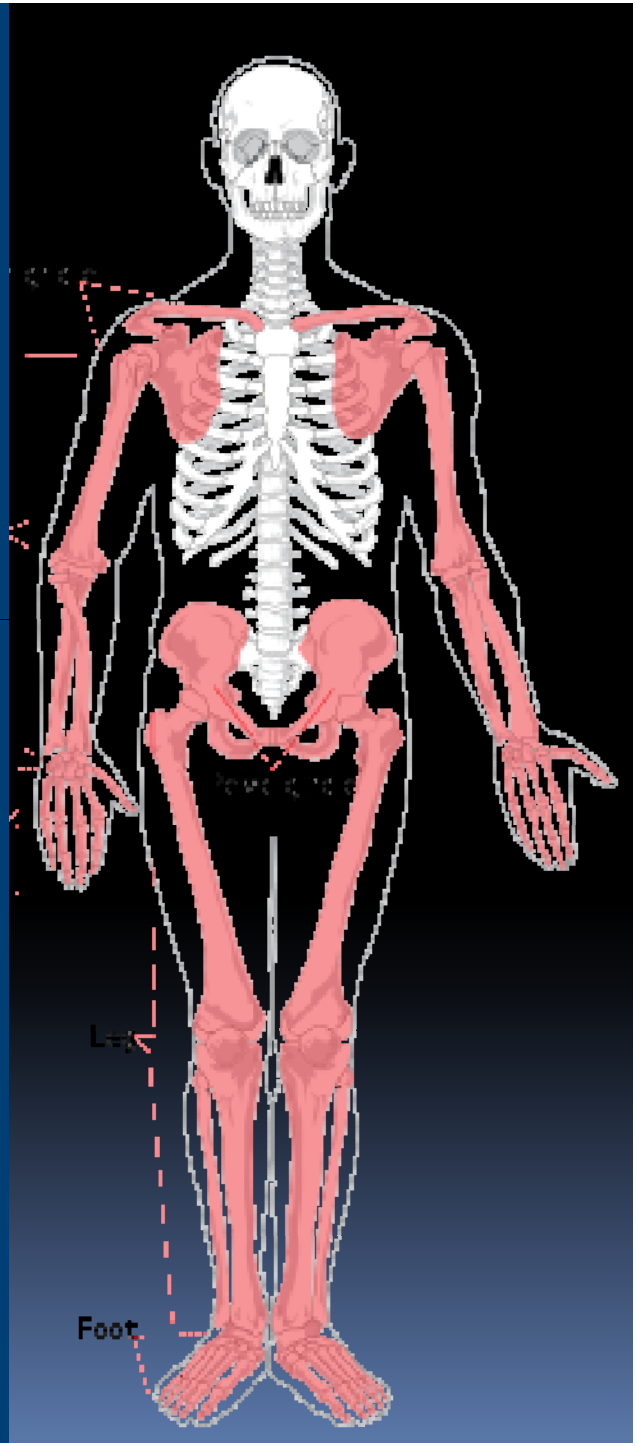

Types of Bone

- **Cancellous**
  - Found in marrow cavity
  - No Haversian systems
  - Surface lined by endosteum
- **Compact**
  - Forms the dense shell of bones
  - Has Haversian systems
  - Outer surface lined by periosteum
  - Inner surface lined by endosteum

- **Woven bone (Immature bone, Primary bone)**
- **Lamellar bone (Mature bone, Secondary bone)**

Bone

Woven bone

1. Immature bone formed rapidly as in the fetus or repair of an injury.
2. Collagen is irregularly arranged.

Lamellar bone

1. Mature bone that is physically stronger.
2. Collagen is regularly arranged

Skeletal structure

- Skeletal system contains 4 types of tissue:
  - **cartilage**
  - **osseous tissue**
  - **bone marrow**
  - **periosteum/endosteum**

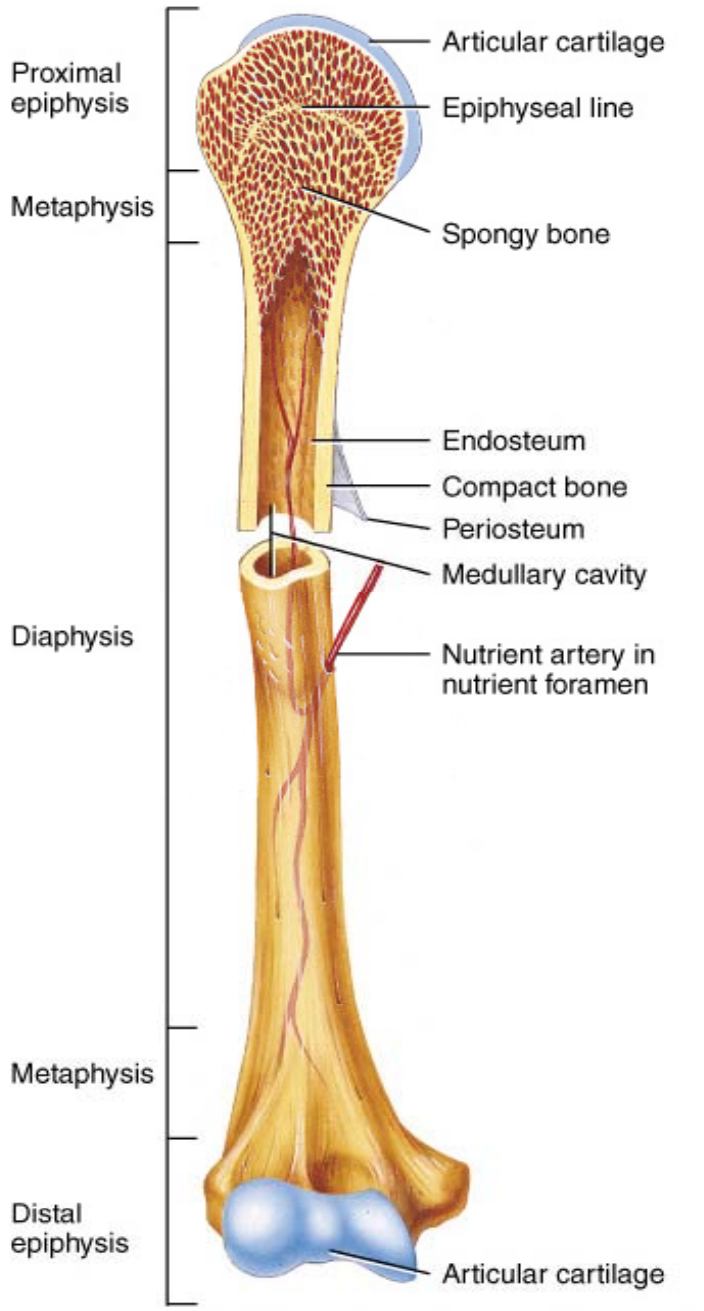

(a) Partially sectioned humerus (arm bone)

© John Wiley & Sons, Inc.

Bone structure

- Dense outer layer of compact bone.
- Internal spongy (cancellous) bone
- Long bones have internal marrow cavity

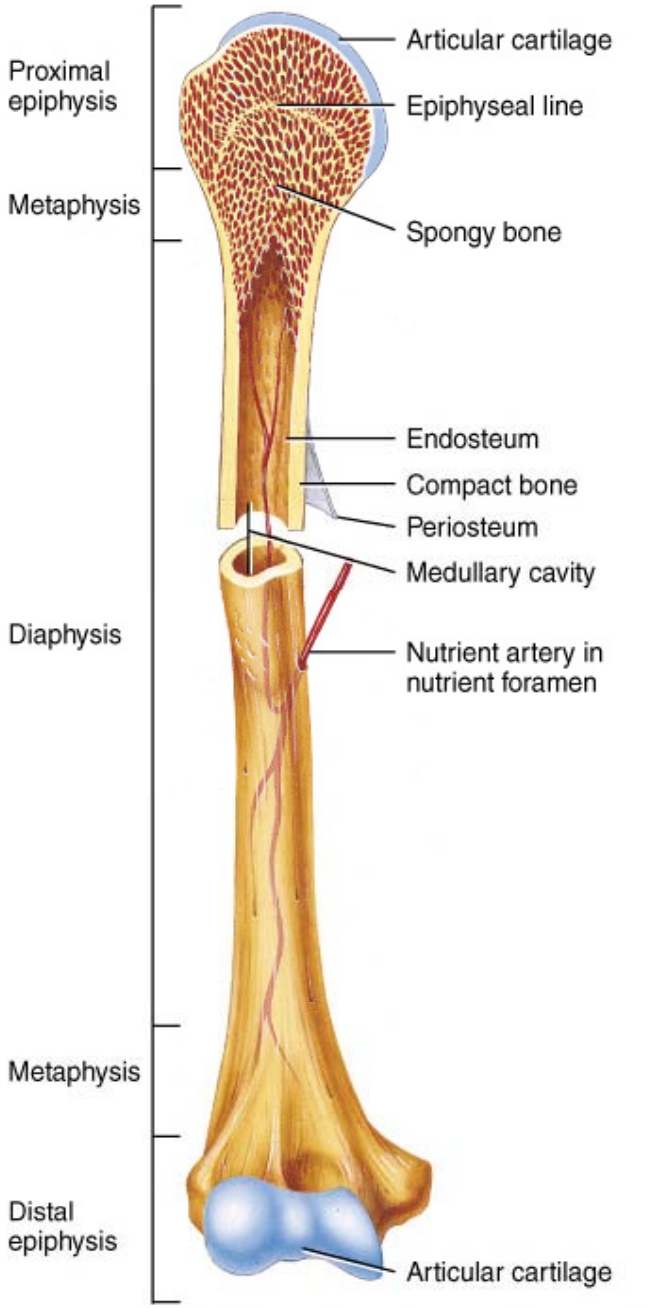

(a) Partially sectioned humerus (arm bone)

© John Wiley & Sons, Inc.

Bone Classification

- Types of bones:
- 1.short bones
- 2. long

3. Flat Bones
4. Irregular Bones
5. sesamoid

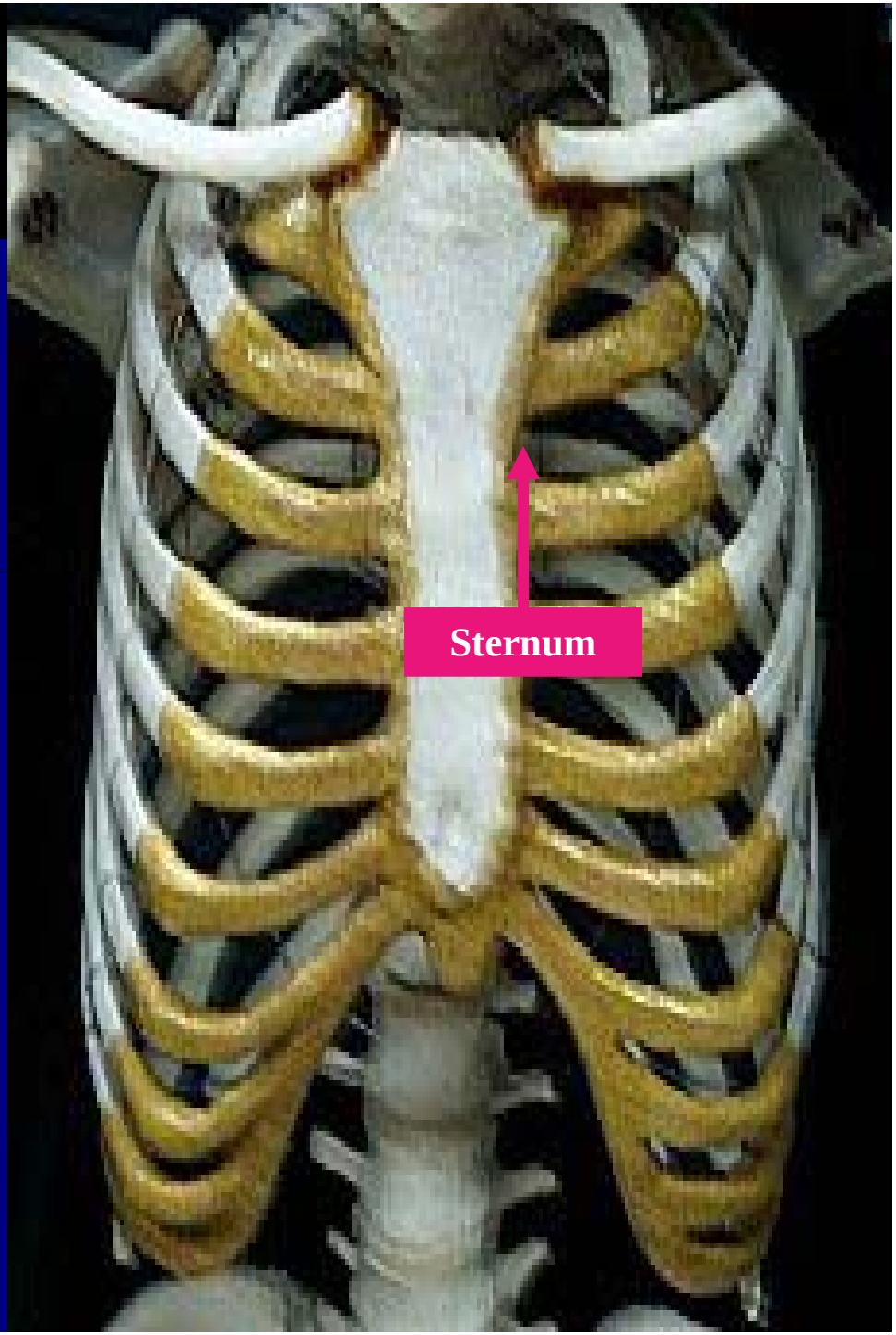

Classification of Bones: By Shape



- Long bones – longer than they are wide (e.g., humerus)

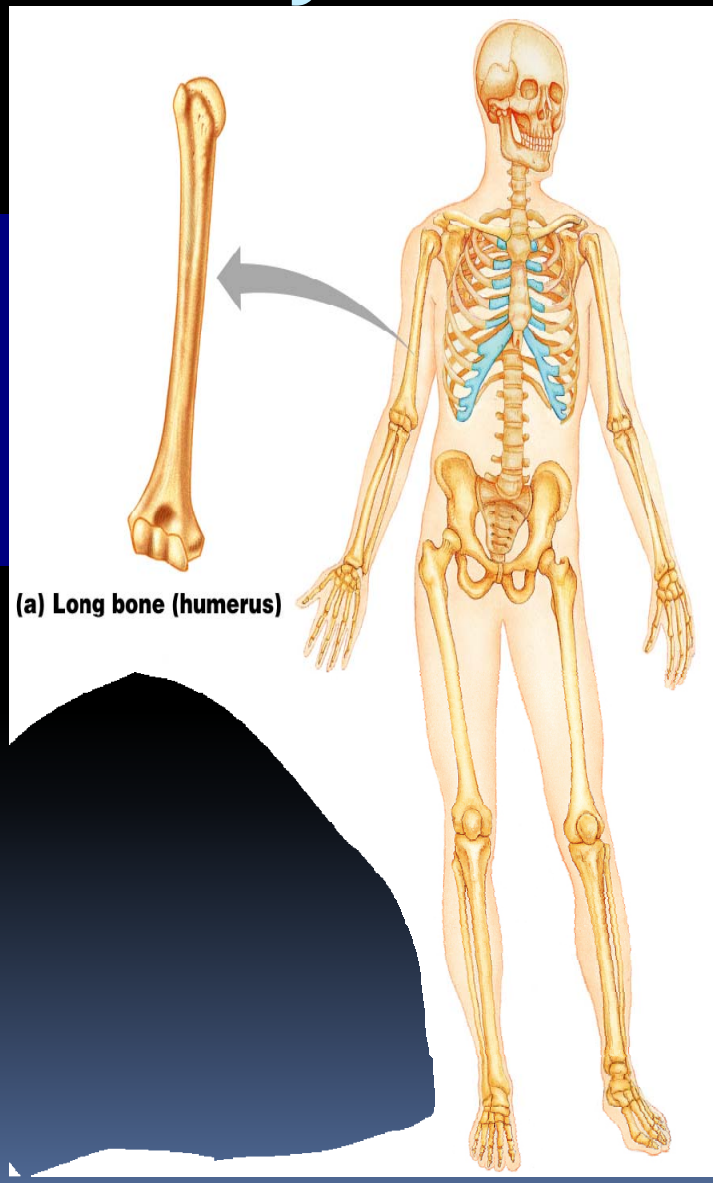

Figure 6.2a

Classification of Bones: By Shape

- Short bones
  - Cube-shaped bones of the wrist and ankle
  - Bones that form within tendons (e.g., patella)

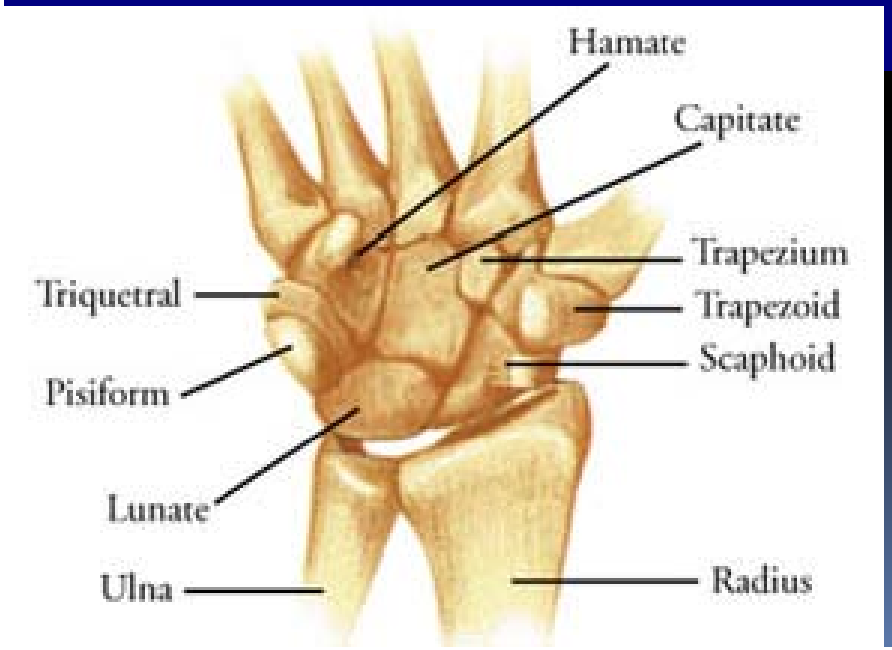

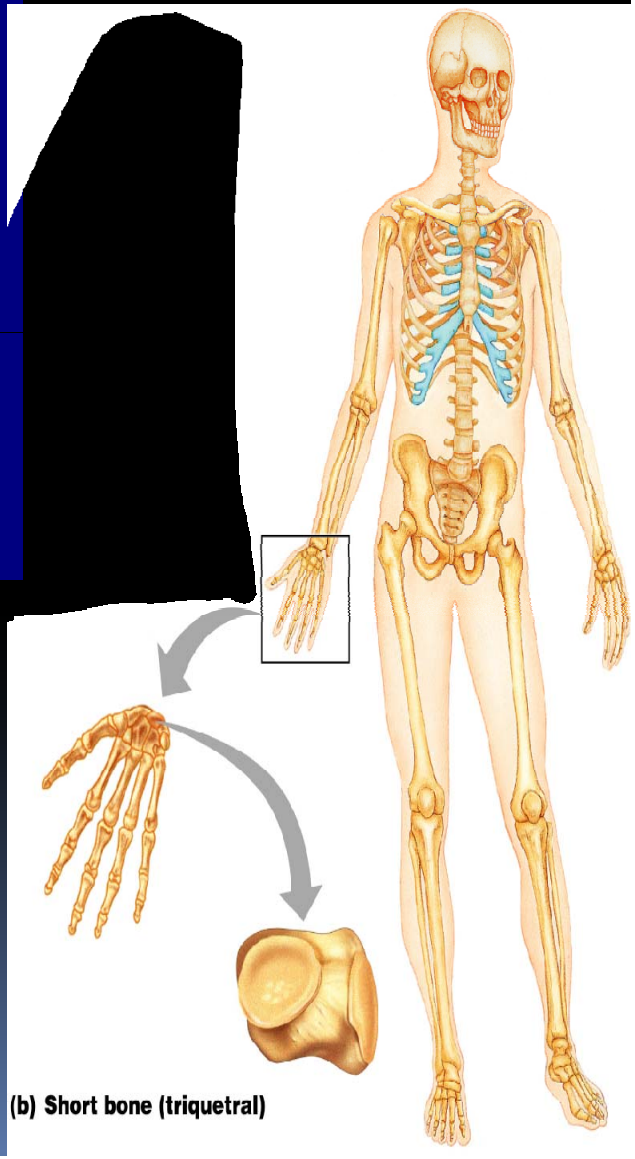

Classification of Bones: By Shape

- Flat bones – thin, flattened, and a bit curved (e.g., sternum, and most skull bones)

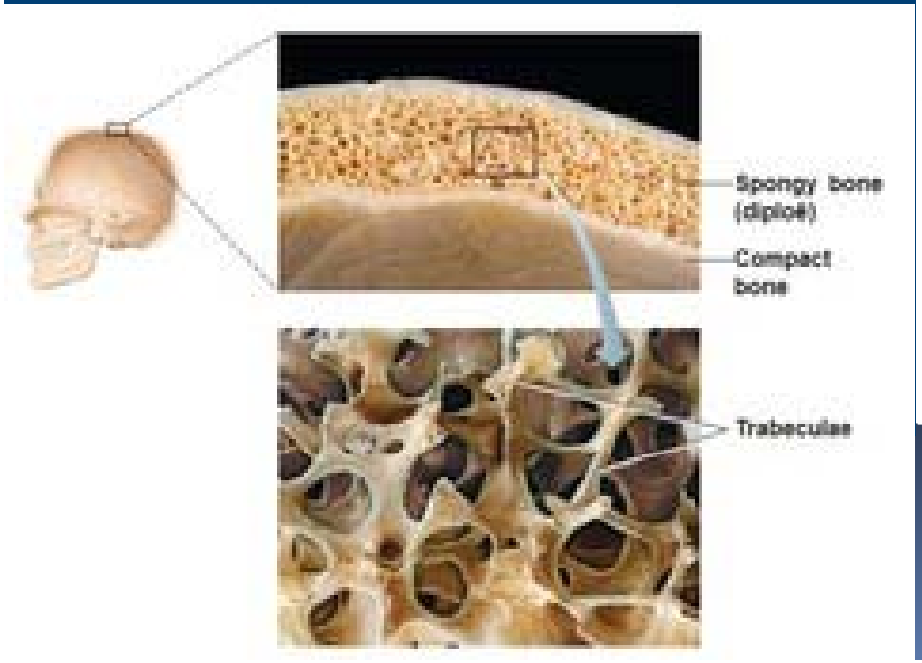

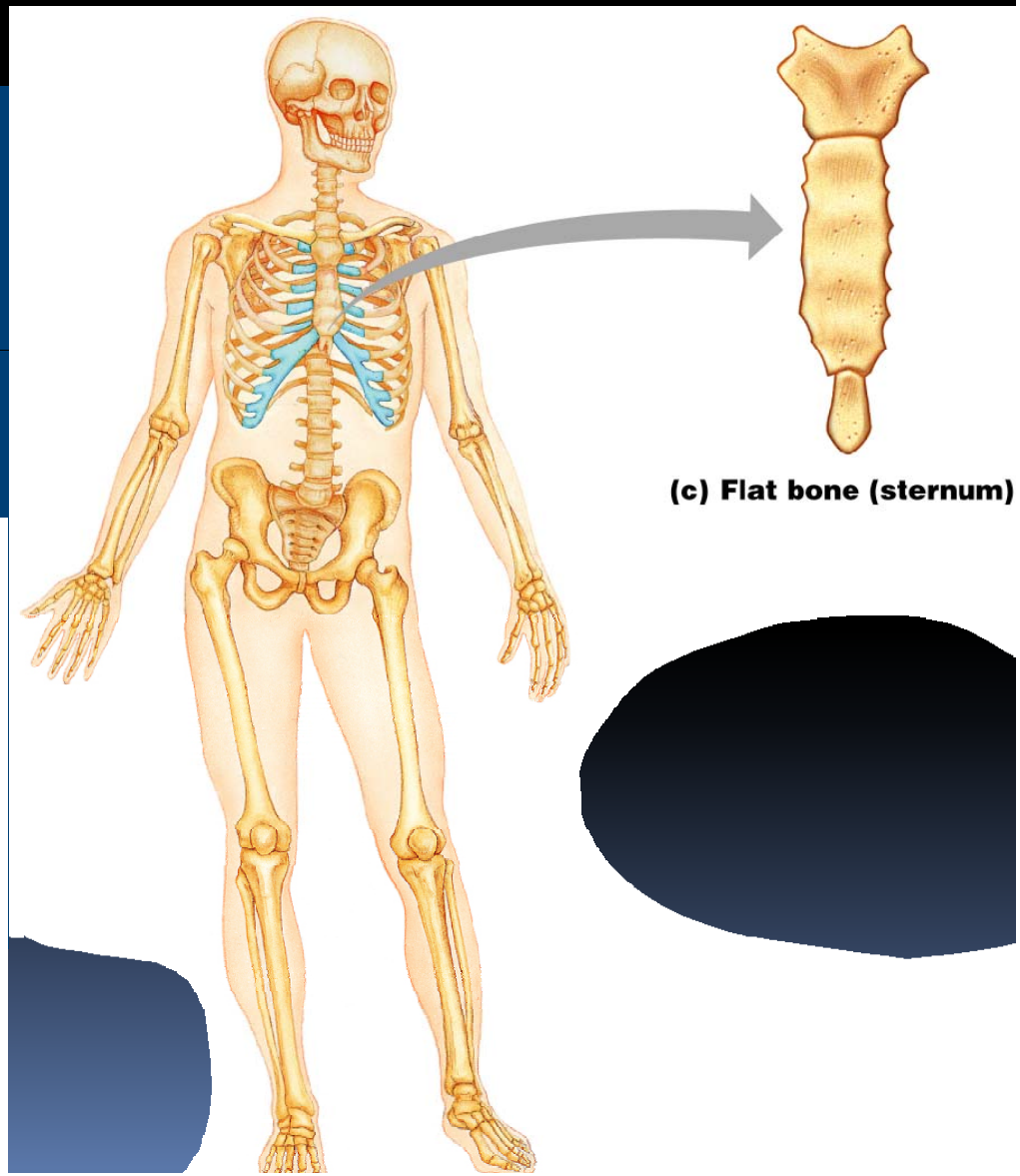

Flat bone

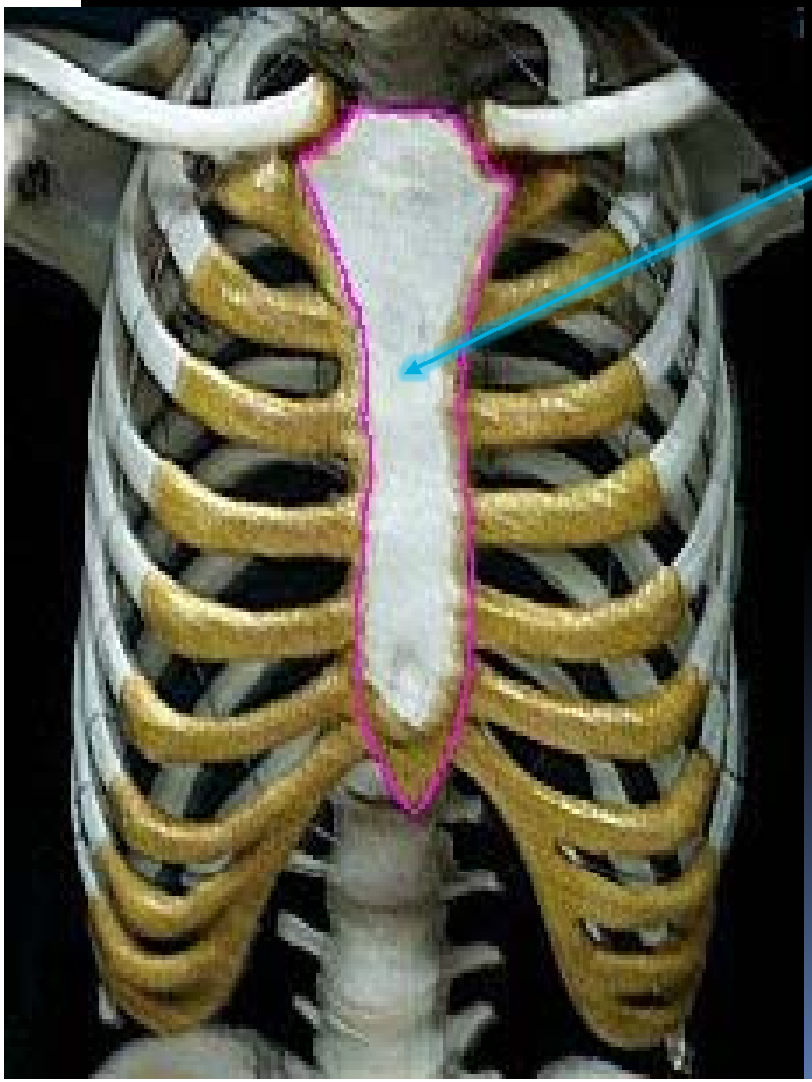

The sternum

The Vomer Bone



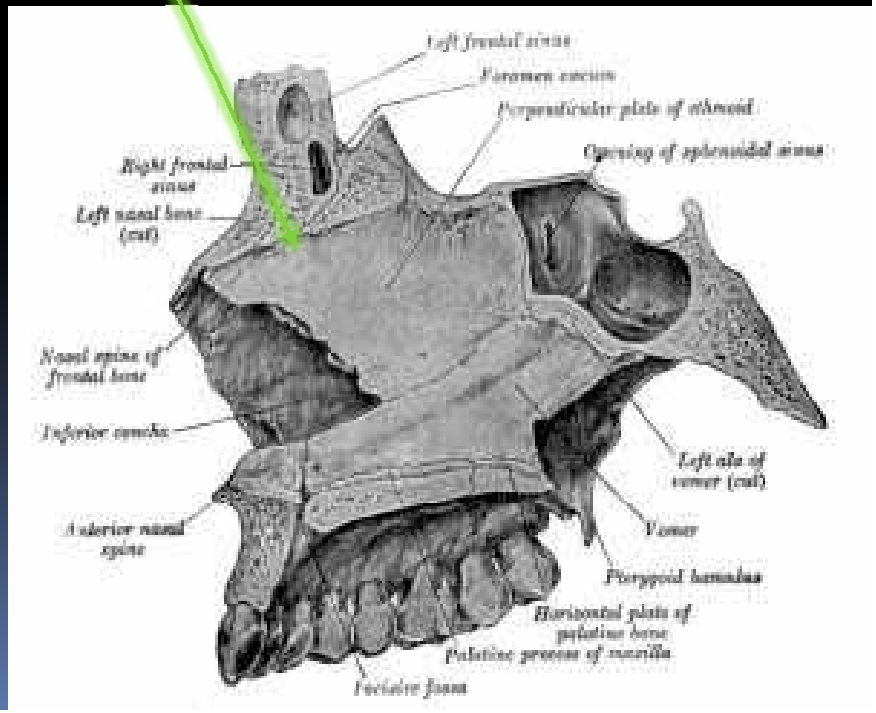

Classification of Bones: By Shape

- Irregular bones – bones with complicated shapes (e.g., vertebrae and hip bones)

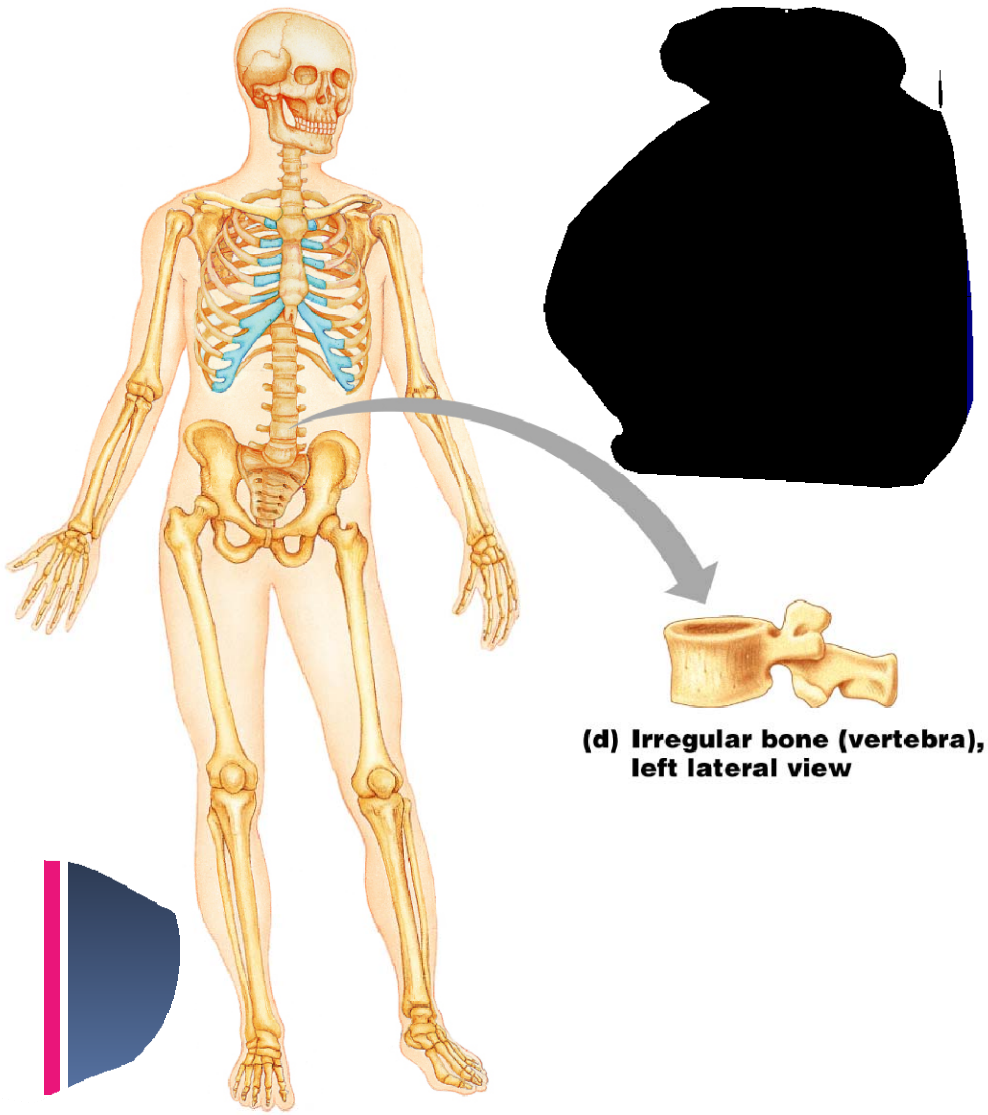

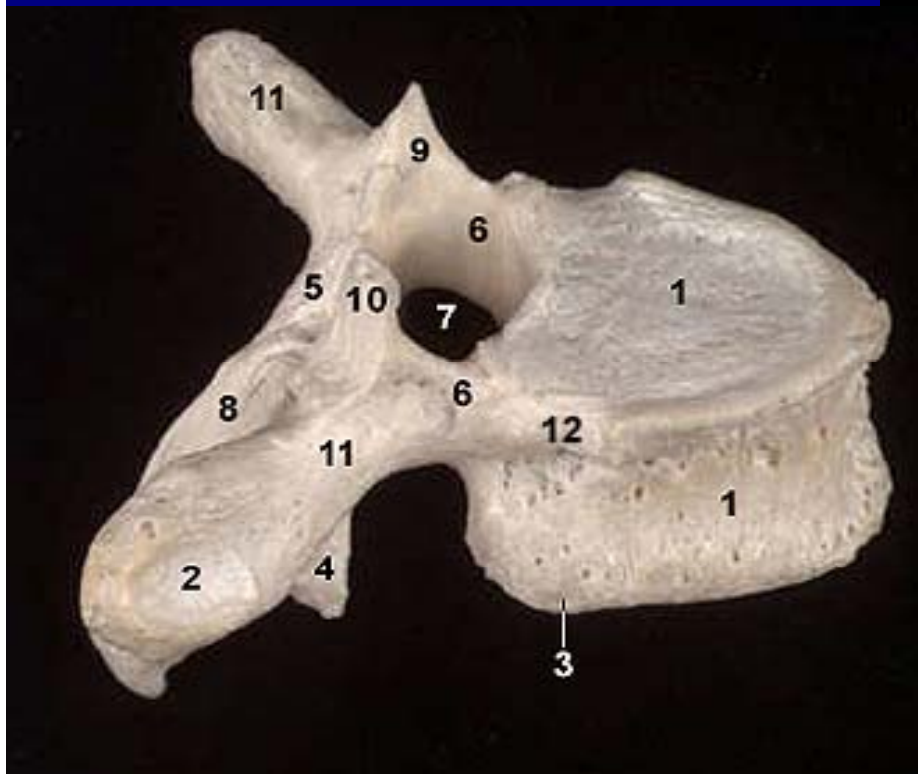

- Sesamoid bones" is a bone embedded within a tendon

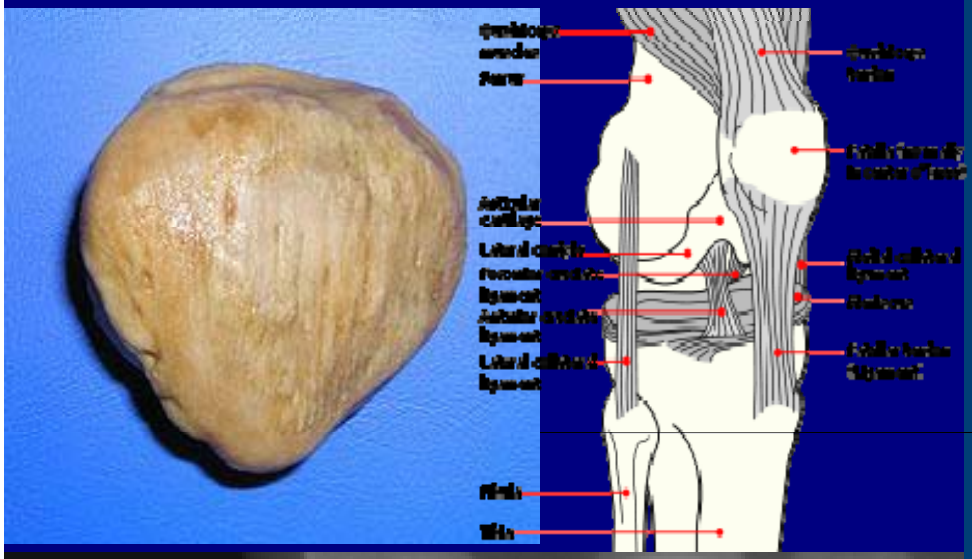

Sesamoid bones at the distal end of the first metatarsal bone of the foot.

Sesamoid bones can be found on joints throughout the body, including:

•**In the knee — the patella** (within the quadriceps tendon).

•**In the hand — two sesamoid bones** are commonly found in the distal portions of the first metacarpal bone (within the tendons of adductor pollicis and flexor pollicis brevis). There is also commonly a sesamoid bone in distal portions of the second metacarpal bone.

•**The pisiform of the wrist** is a sesamoid bone (within the tendon of flexor carpi ulnaris).

•**In the foot - the first metatarsal** bone usually has two sesamoid bones at its connection to the big toe (both within the tendon of flexor hallucis brevis). In some people, only a single sesamoid is found on the first MTP.

Copyright © The McGraw-Hill Companies, Inc. Permission required for reproduction or display.

Long bone
(femur or thighbone)

Irregular bone
(sphenoid bone
from skull)

Short bone
(carpal or wrist bone)

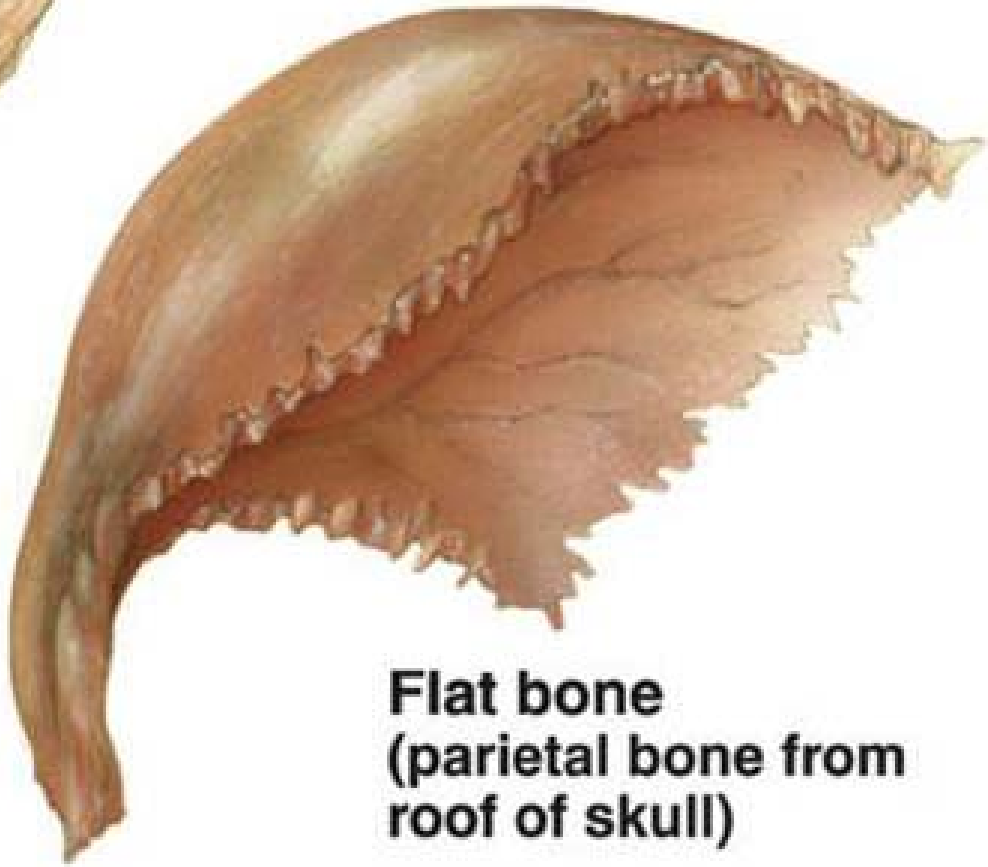

Flat bone
(parietal bone from
roof of skull)

Bone structure

- Typical long bone structure:
  - **articular cartilage**
  - **epiphyses (ends)**
    - **Spongy bone**
  - **diaphysis (shaft)**
    - **Compact bone**
  - **periosteum**
  - **medullary (marrow) cavity**
  - **endosteum**

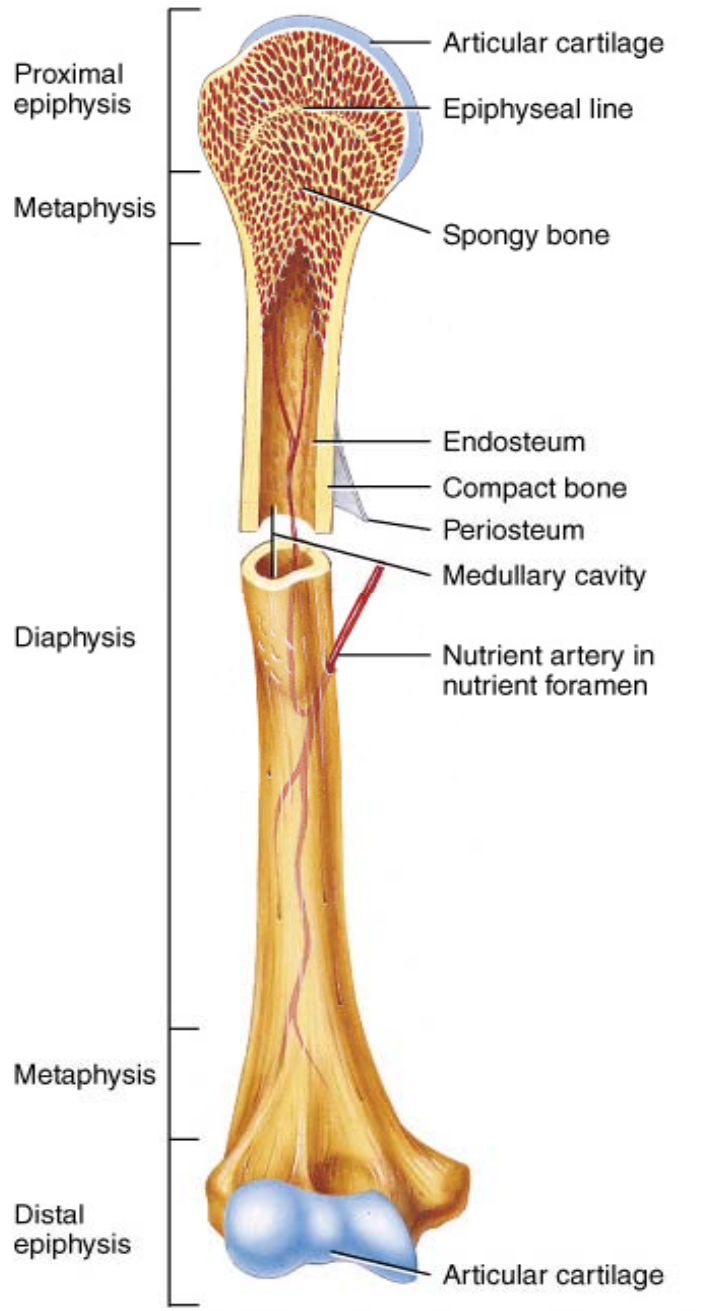

(a) Partially sectioned humerus (arm bone)

© John Wiley & Sons, Inc.

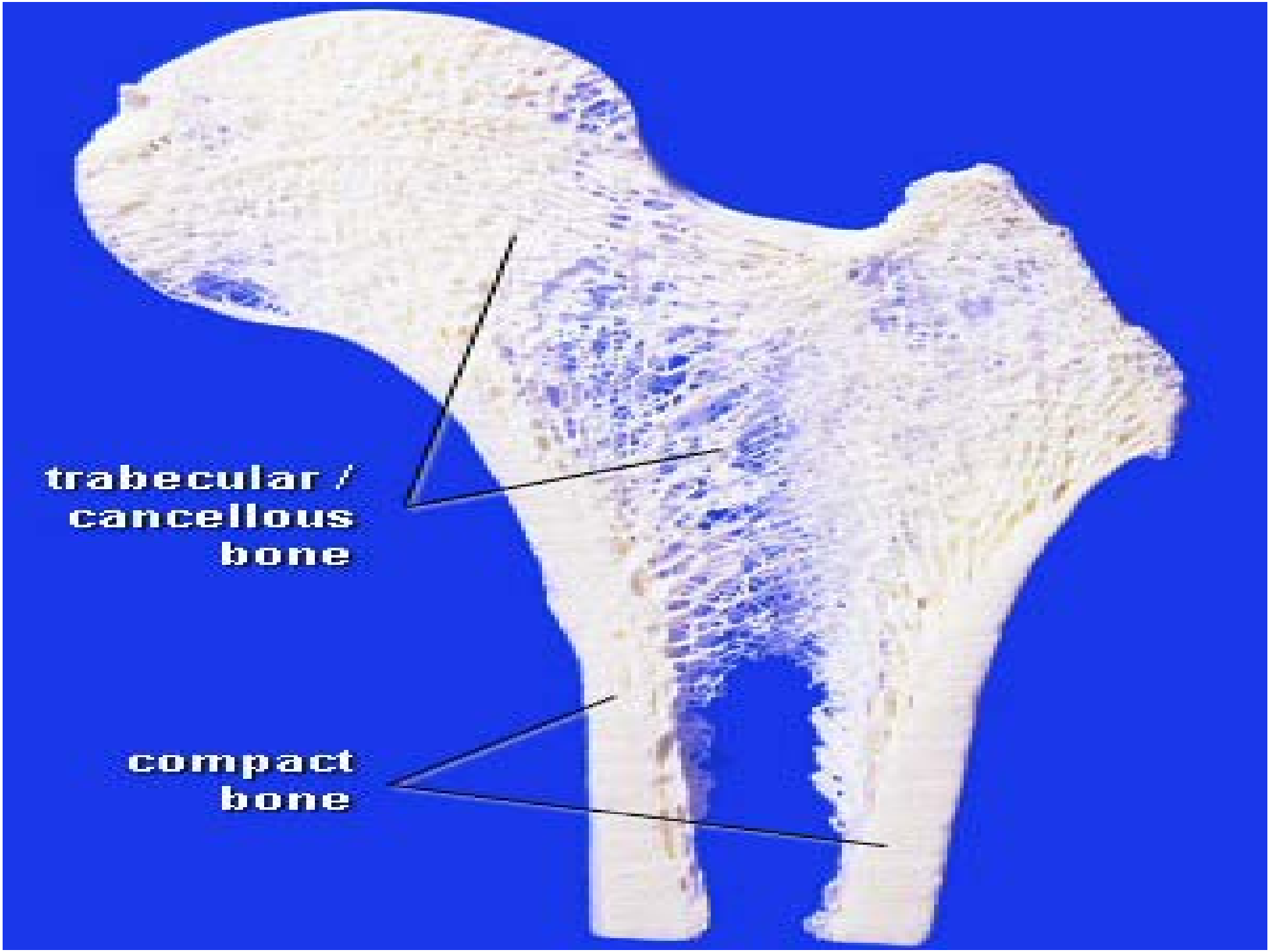
trabecular /
cancellous
bone
compact
bone

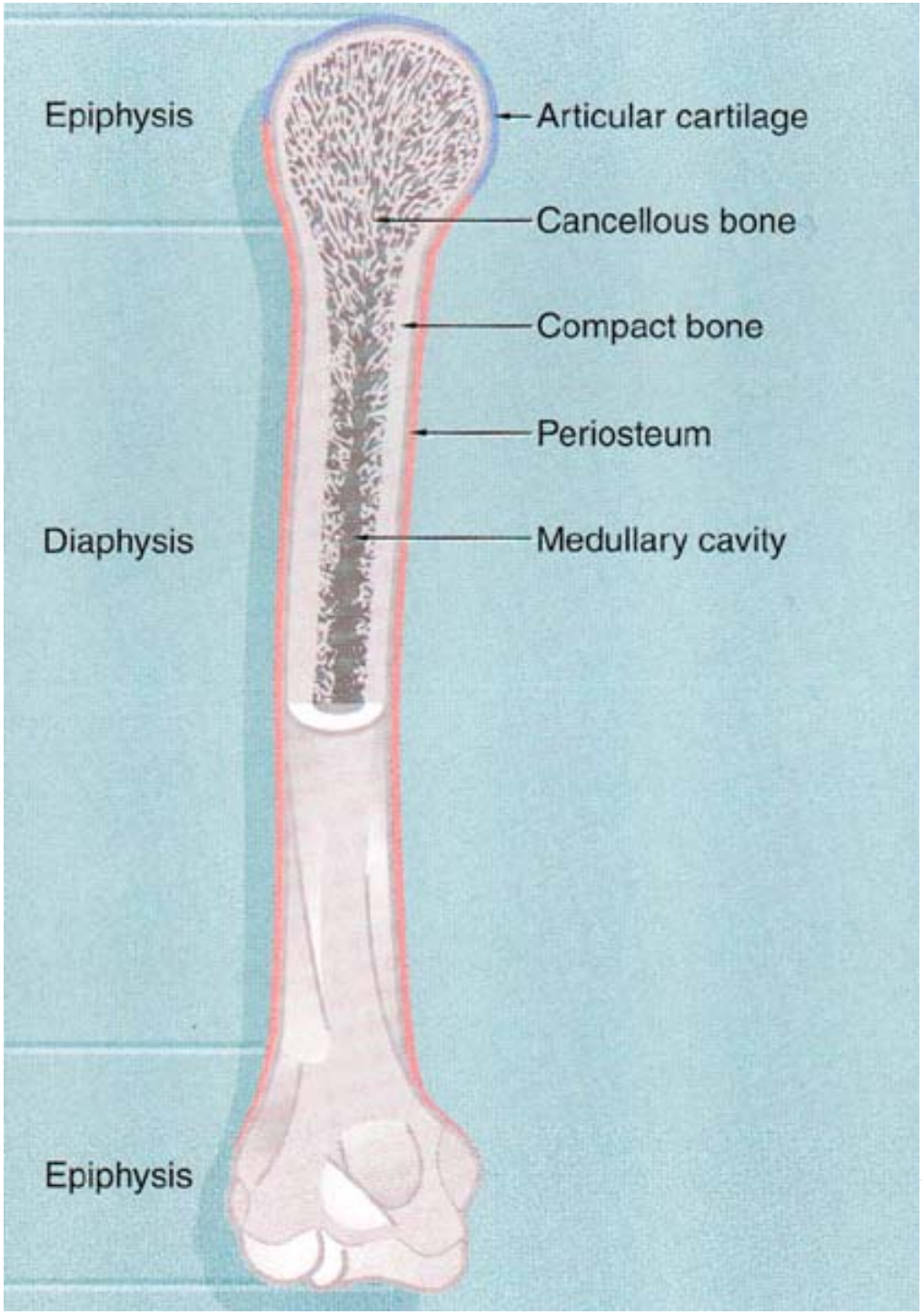
Epiphysis
Articular cartilage
Cancellous bone
Compact bone
Periosteum
Diaphysis
Medullary cavity
Epiphysis

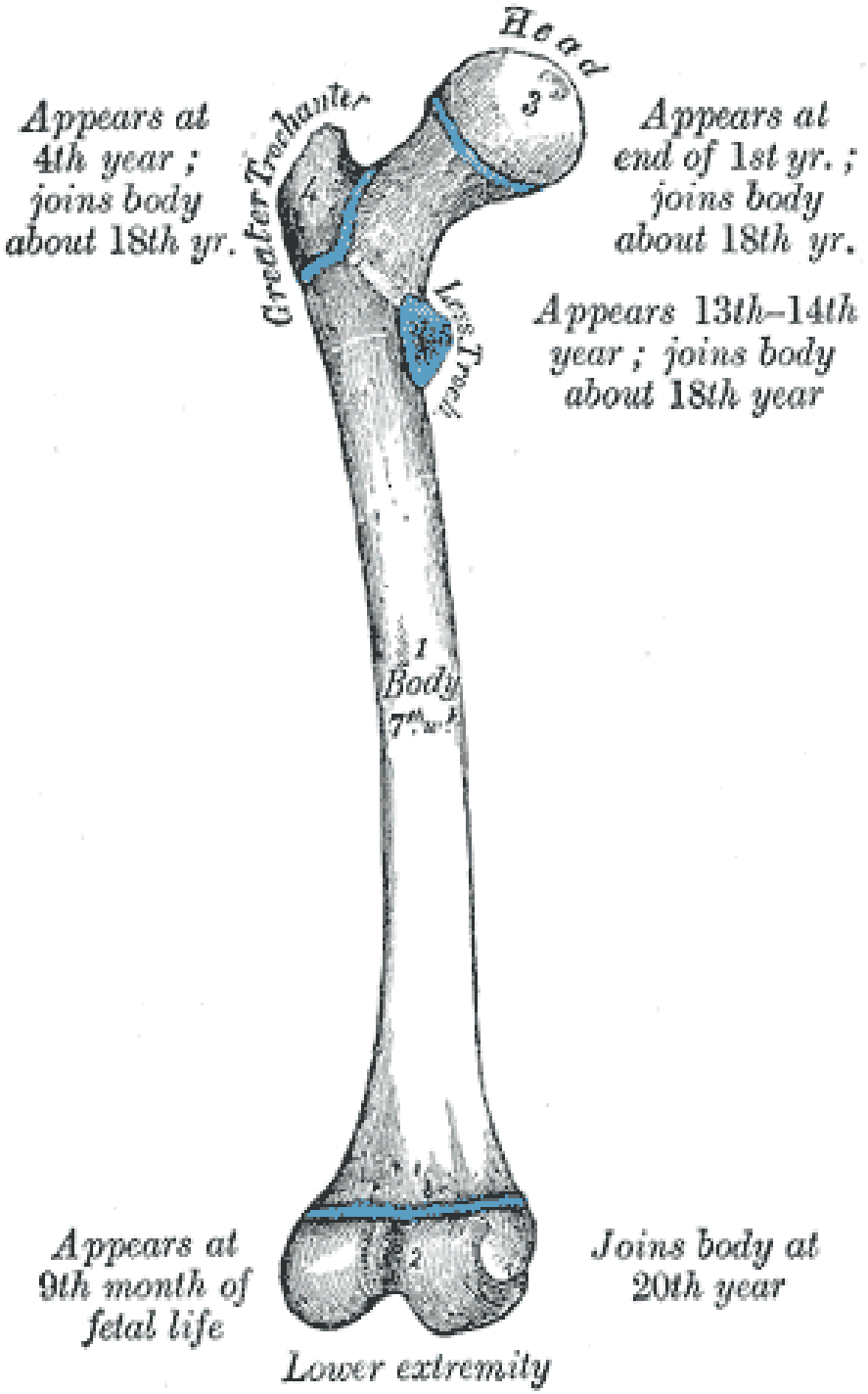
Head
Appears at 4th year; joins body about 18th yr.
Greater Trochanter
Appears at end of 1st yr.; joins body about 18th yr.
Appears 13th–14th year; joins body about 18th year
Lesser Troch.
Body
Appears at 9th month of fetal life
Joins body at 20th year
Lower extremity

Structure of Long Bone

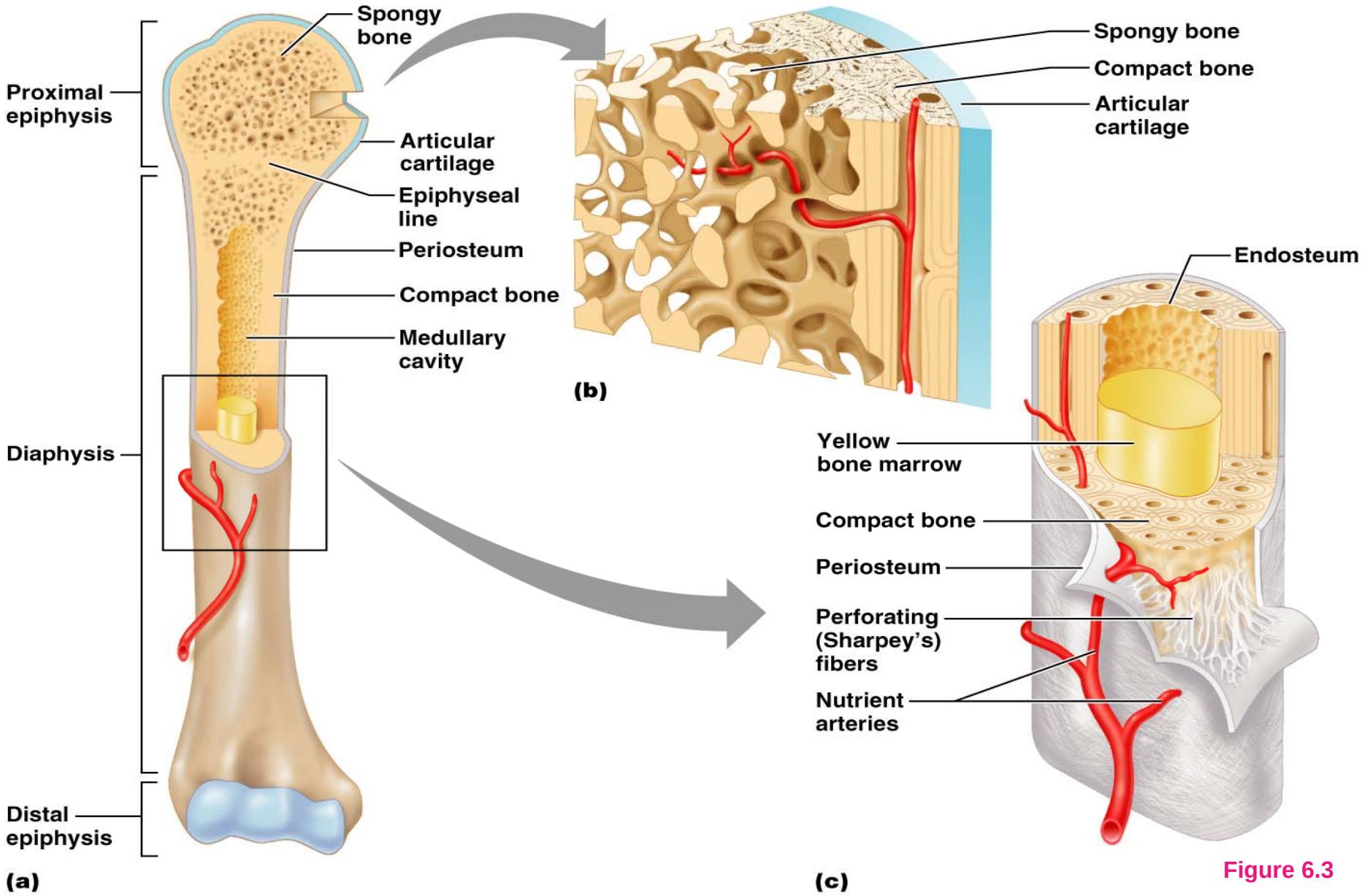

Figure 6.3

Long Bone Structure

- The external surface of the entire bone except for the joint surfaces of the epiphyses is covered by a double-layered membrane known as the periosteum.
  - Outer fibrous layer is dense irregular connective tissue.
  - Inner cellular layer contains osteoprogenitor cells and osteoblasts.
  - Periosteum is richly supplied with nerve fibers, lymphatic vessels and blood vessels.
    - These enter the bone of the shaft via a nutrient foramen.
  - Periosteum is connected to the bone matrix via strong strands of collagen.

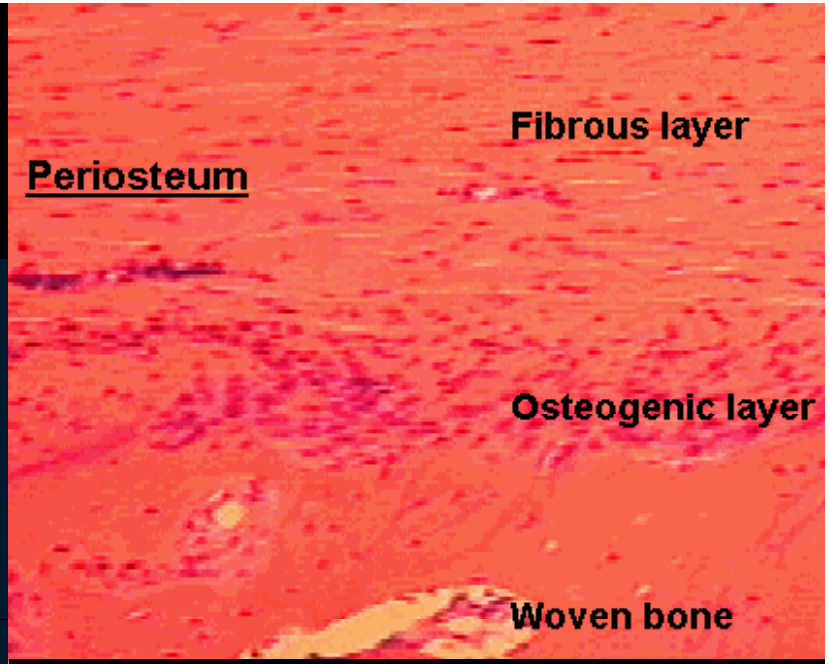

Long Bone Structure

- Internal bone surfaces are covered with a delicate connective tissue membrane known as the endosteum.
  - Covers the trabeculae of spongy bone in the marrow cavities and lines the canals that pass through compact bone.
  - Contains both osteoblasts and osteoclasts.

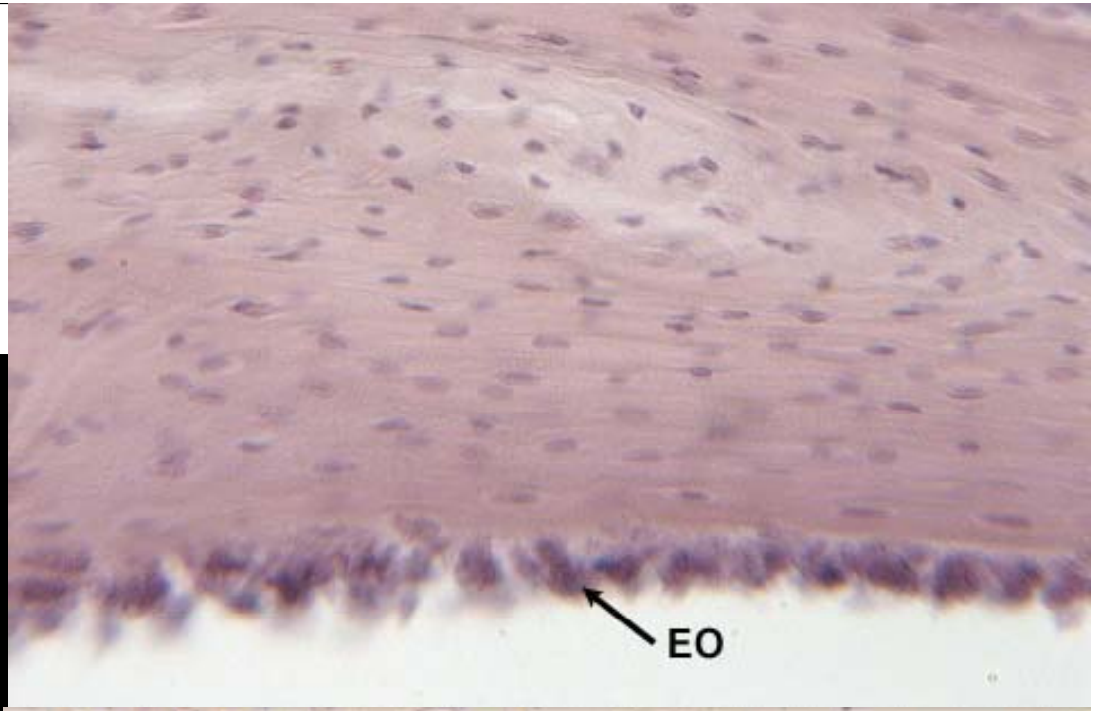

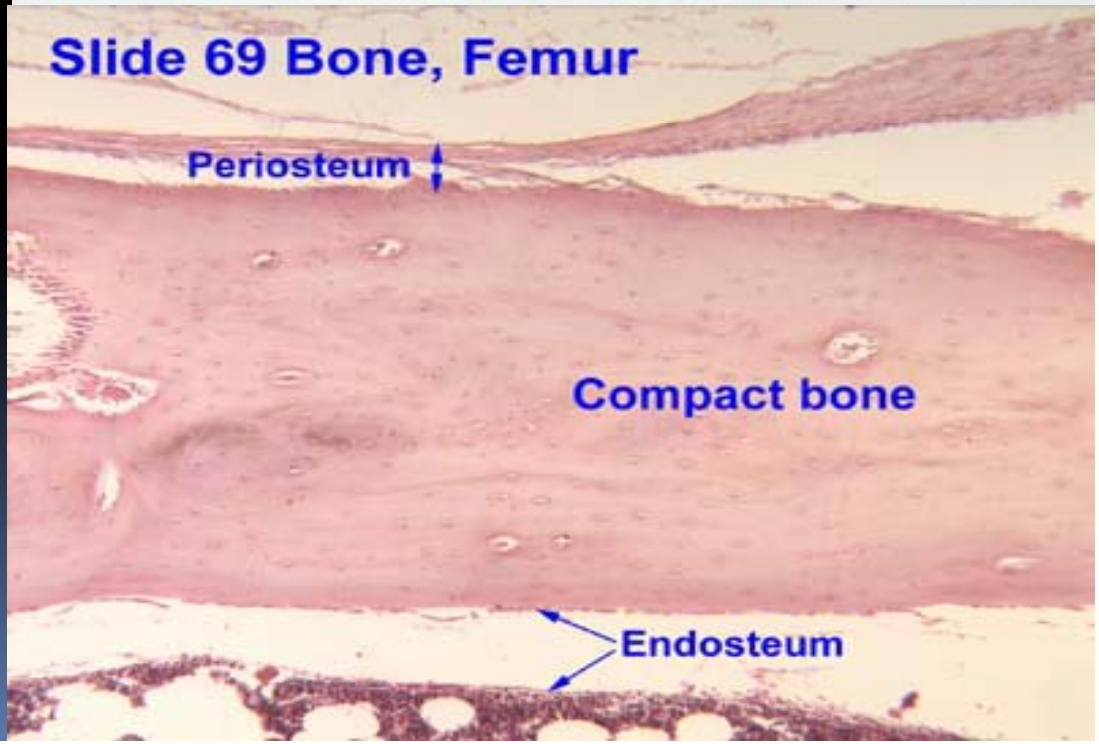

Bone structure

- Typical structure of short, flat and irregular bones
  - outer thin plates of periosteum covered compact bone
  - inner endosteum covered spongy bone

Structure of Short, Irregular, and Flat Bones

- Thin plates of periosteum-covered compact bone on the outside with endosteum-covered spongy bone (diploë) on the inside
- Have **no** diaphysis or epiphyses
- Contain bone marrow between the trabeculae

Structure of Short, Irregular, and Flat Bones

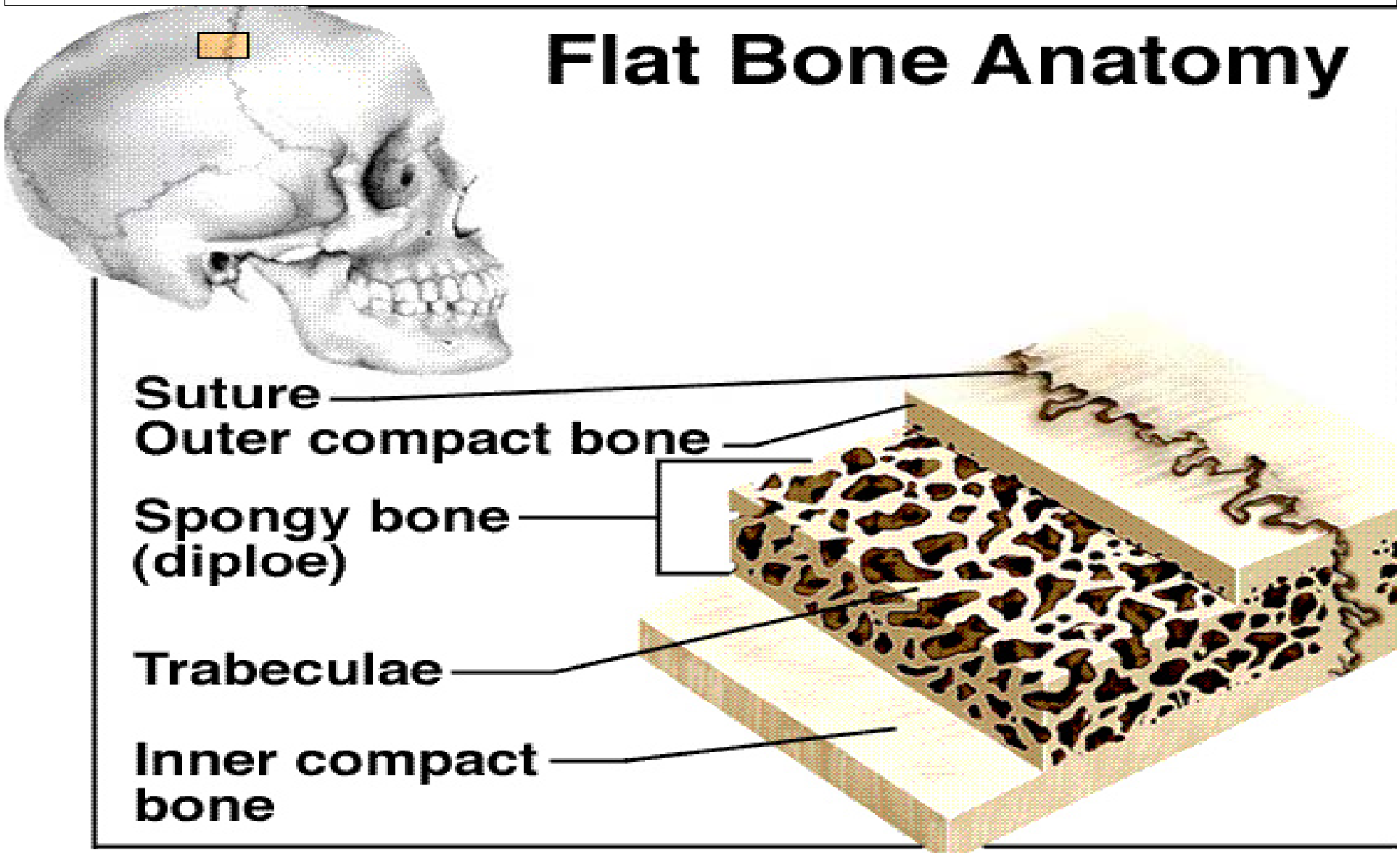

Structure of a Flat Bone

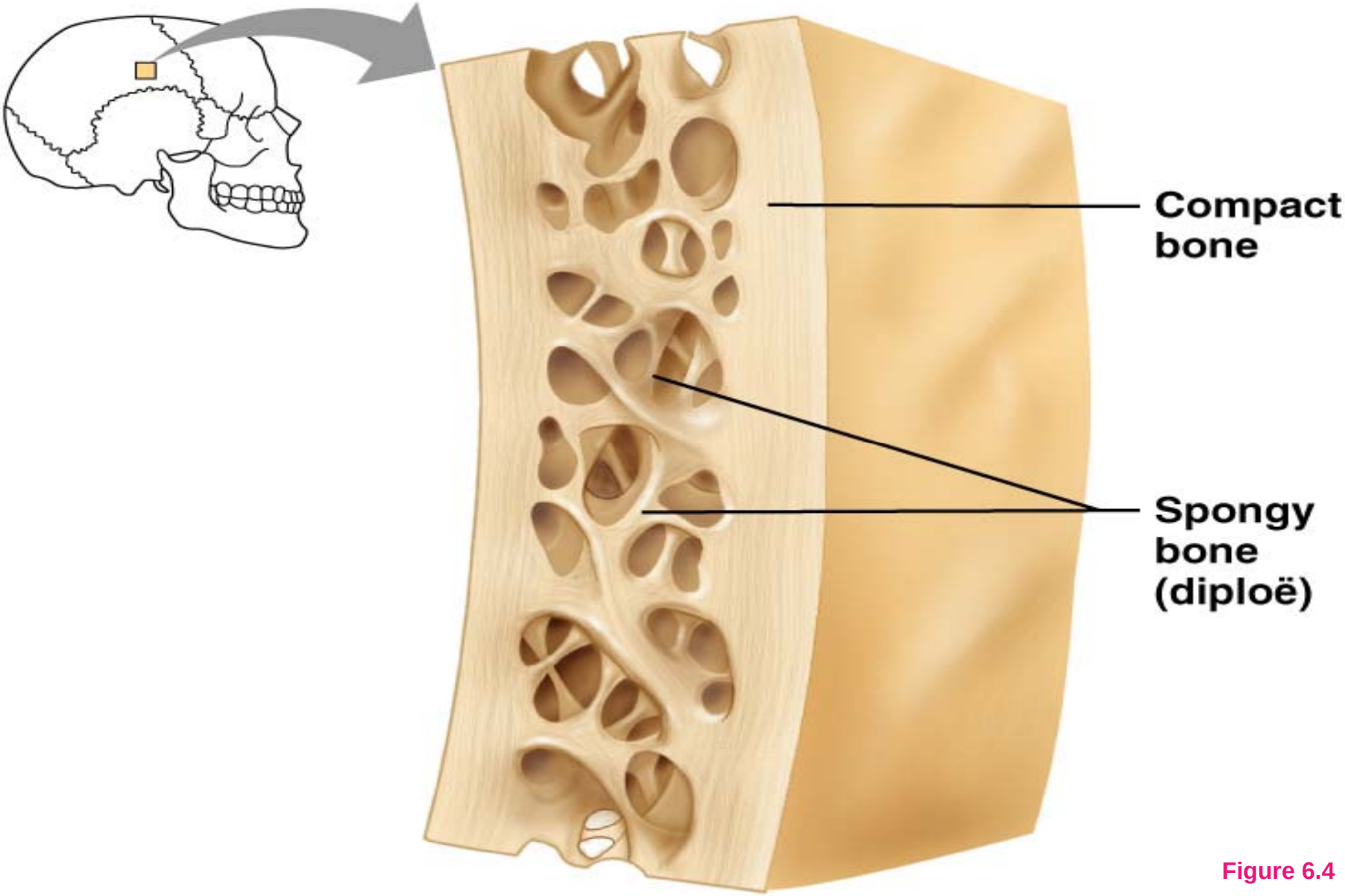

Figure 6.4

Bone marrow

•Within the long bones are two types of bone marrow**: red marrow and yellow marrow.**

•The yellow marrow has fatty connective tissue and fills the marrow cavity.

• During starvation, the body uses the fat in yellow marrow for energy.

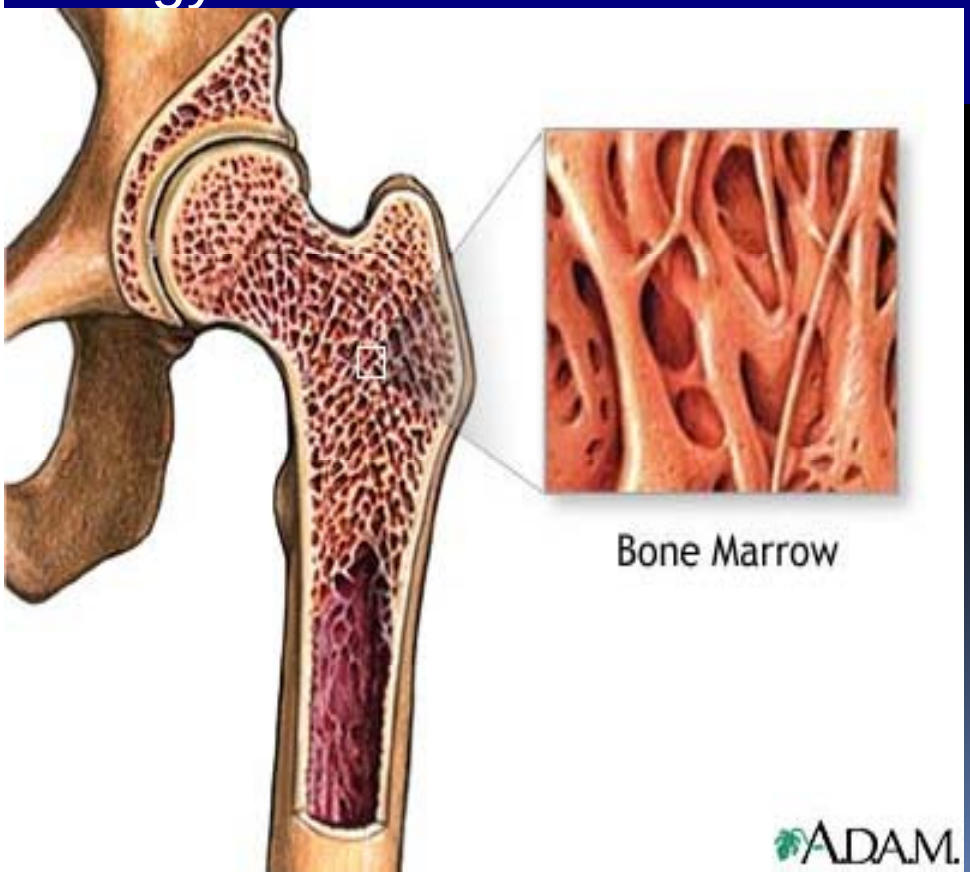

The red marrow of some bones is an important site for blood cell production. Here all erythrocytes (red blood cells), platelets, and most leukocytes (white blood cells) form in adults. From the red marrow, erythrocytes, platelets, and leukocytes migrate to the blood to do their special tasks. Red blood cells carry oxygen and nutrients to the body tissues. Platelets help in blood clotting. White blood cells help fight disease and infection.

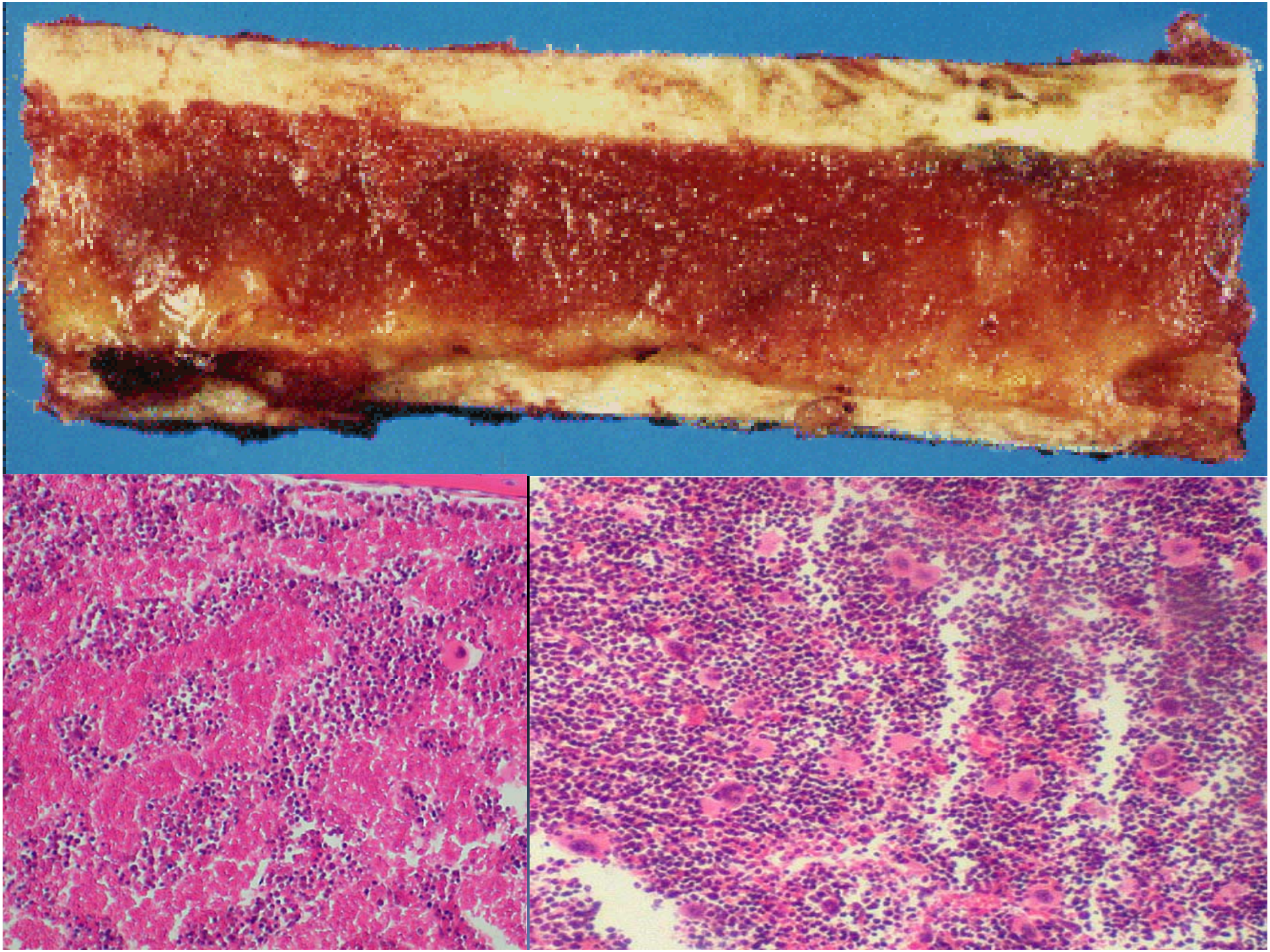

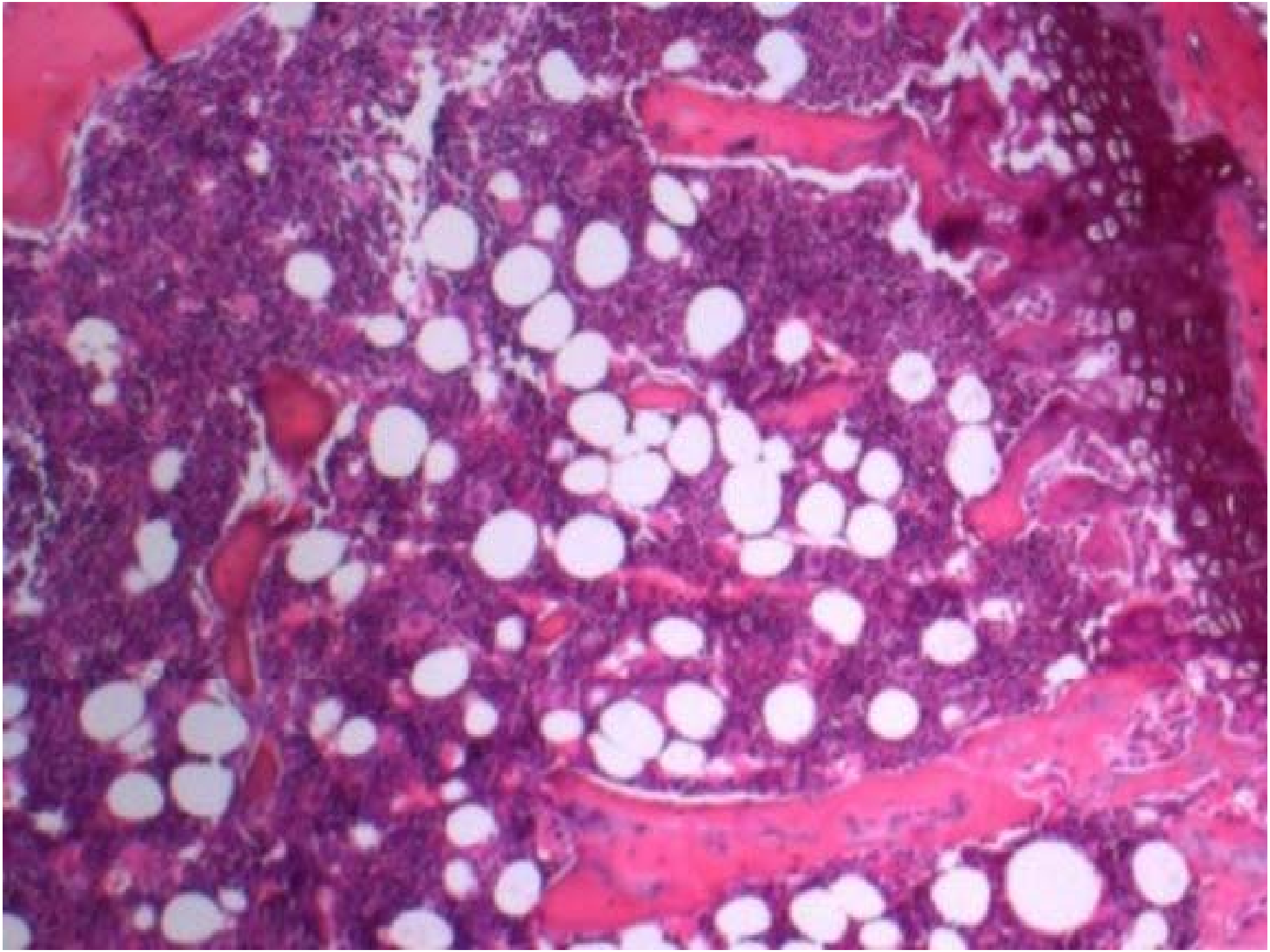

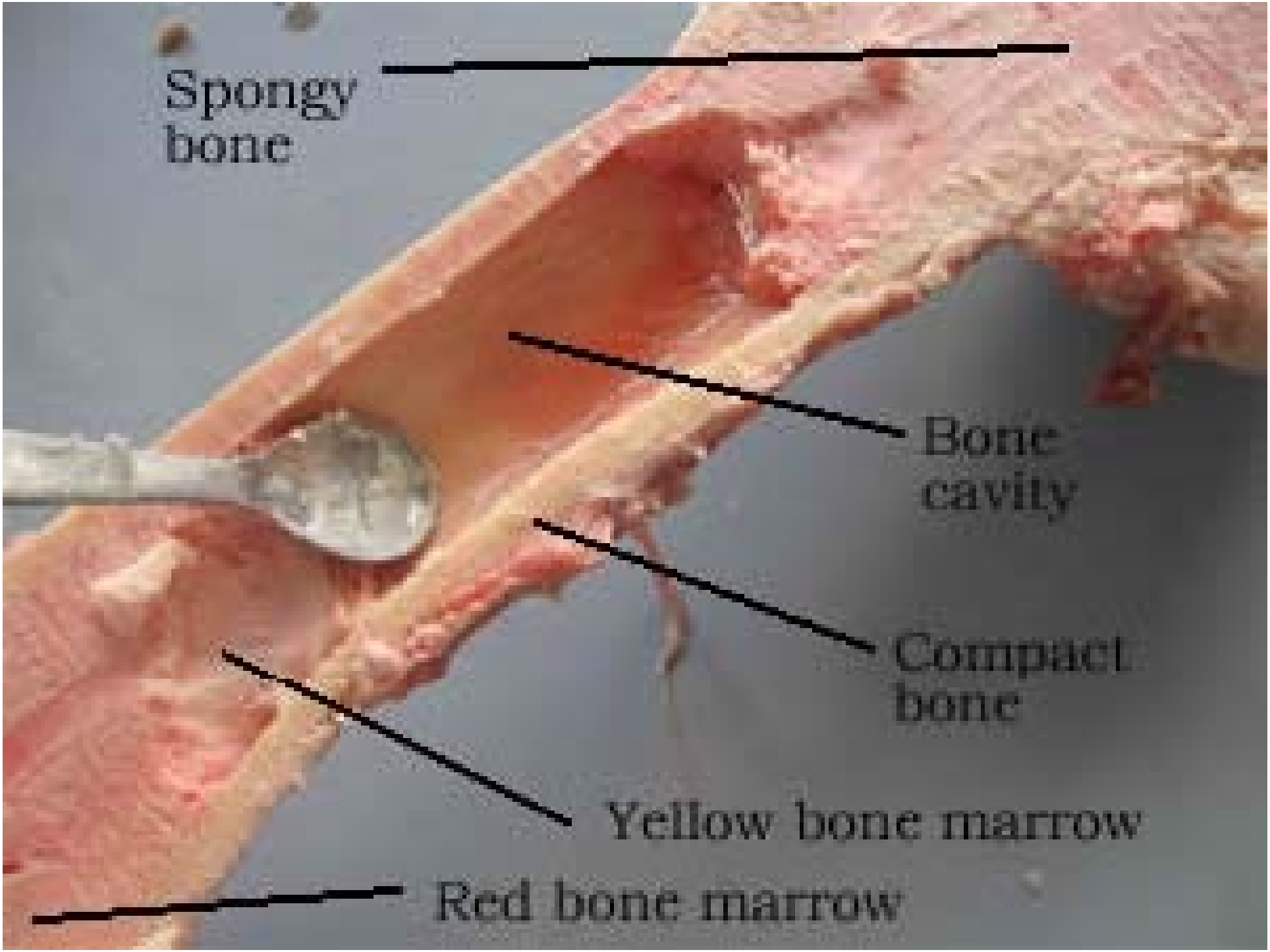
Spongy bone
Bone cavity
Compact bone
Yellow bone marrow
Red bone marrow

Bone Marrow

- **Red bone marrow = blood cell forming tissue = hematopoietic tissue**
  - Red bone marrow looks like blood but with a thicker consistency.
  - It consists of a delicate mesh of reticular tissue saturated with immature red blood cells and scattered adipocytes.

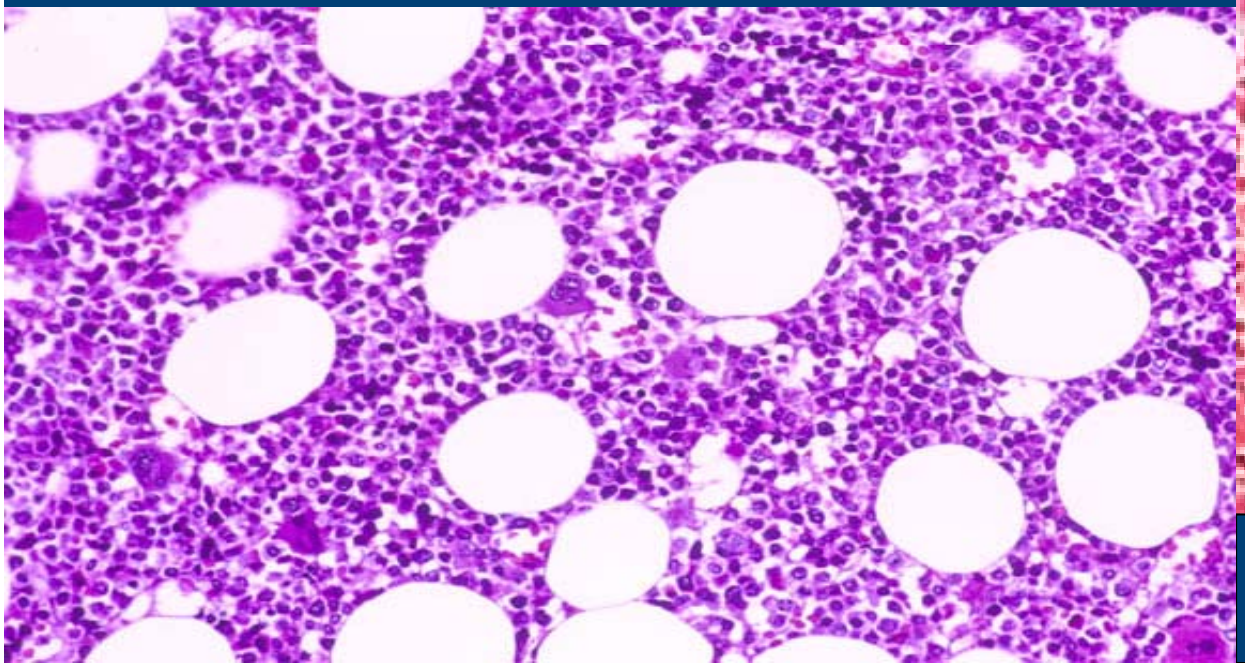

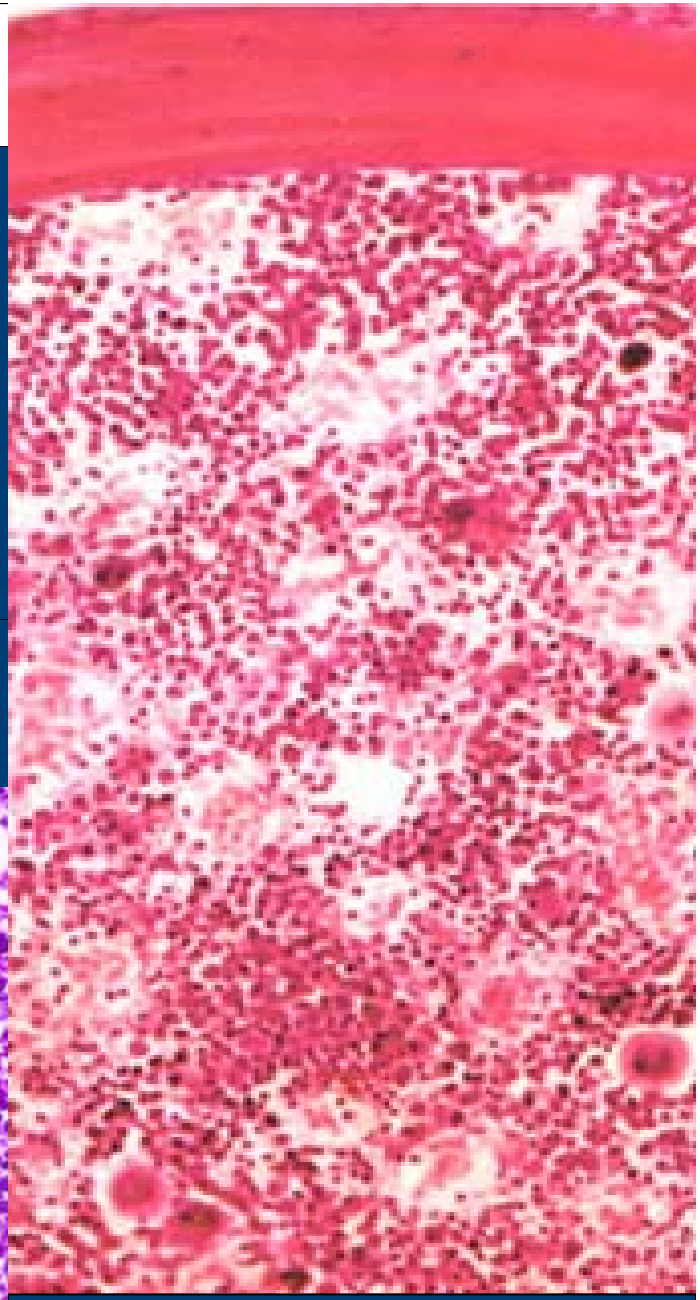

Notice the red marrow and the compact bone

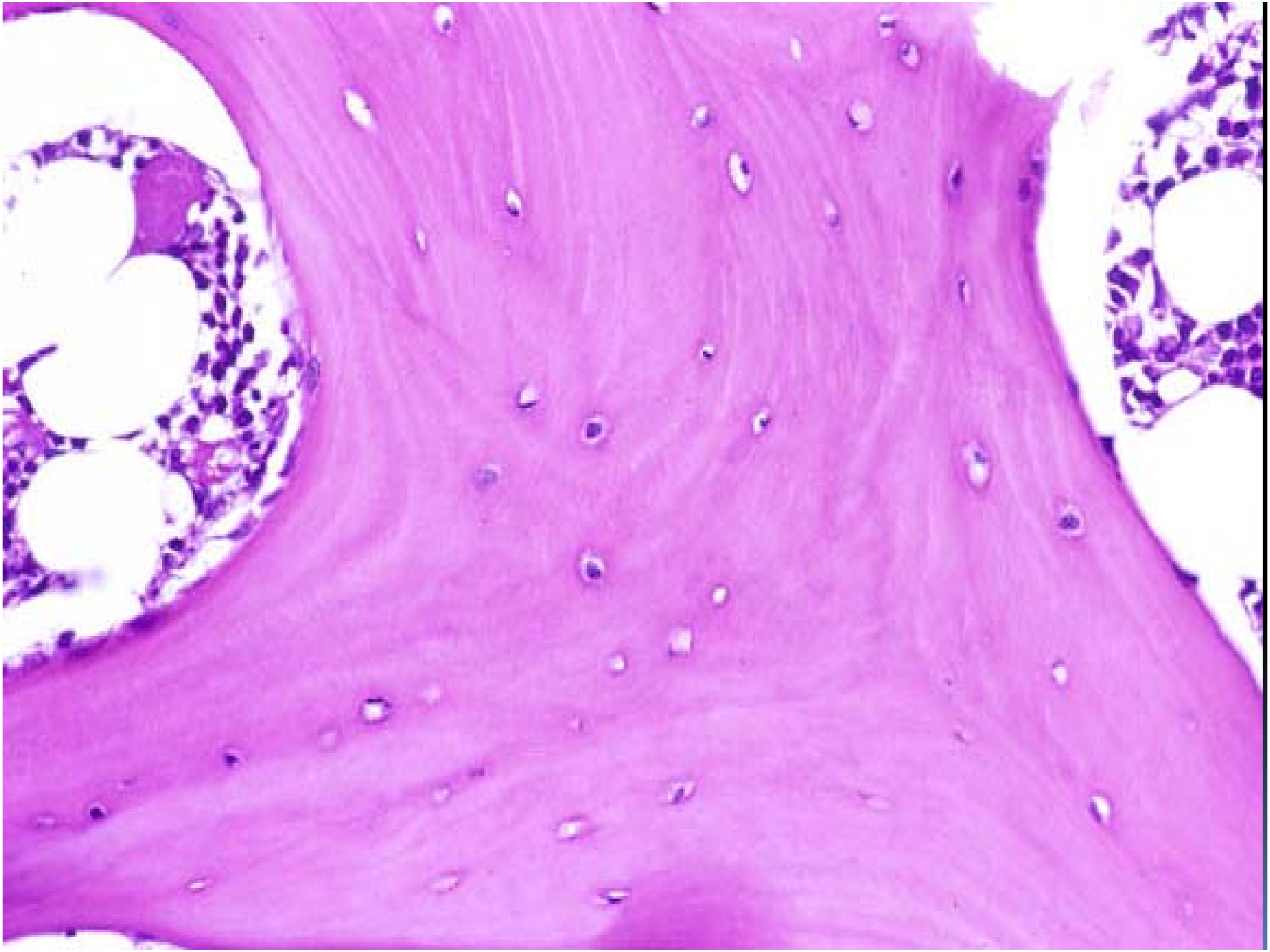

Distribution of Marrow

- **In a child, the medullary cavity of nearly every bone is filled with red bone marrow.**
- In young to middle-aged adults, the shafts of the long bones are filled with fatty yellow bone marrow.
  - Yellow marrow no longer produces blood, although in the event of severe or chronic anemia, it can transform back into red marrow
- In adults, red marrow is limited to
  - the axial skeleton,
  - pectoral girdle,
  - pelvic girdle,
  - proximal heads of the humerus and the femur.

Note the compact bone on the bottom and marrow on the bottom.

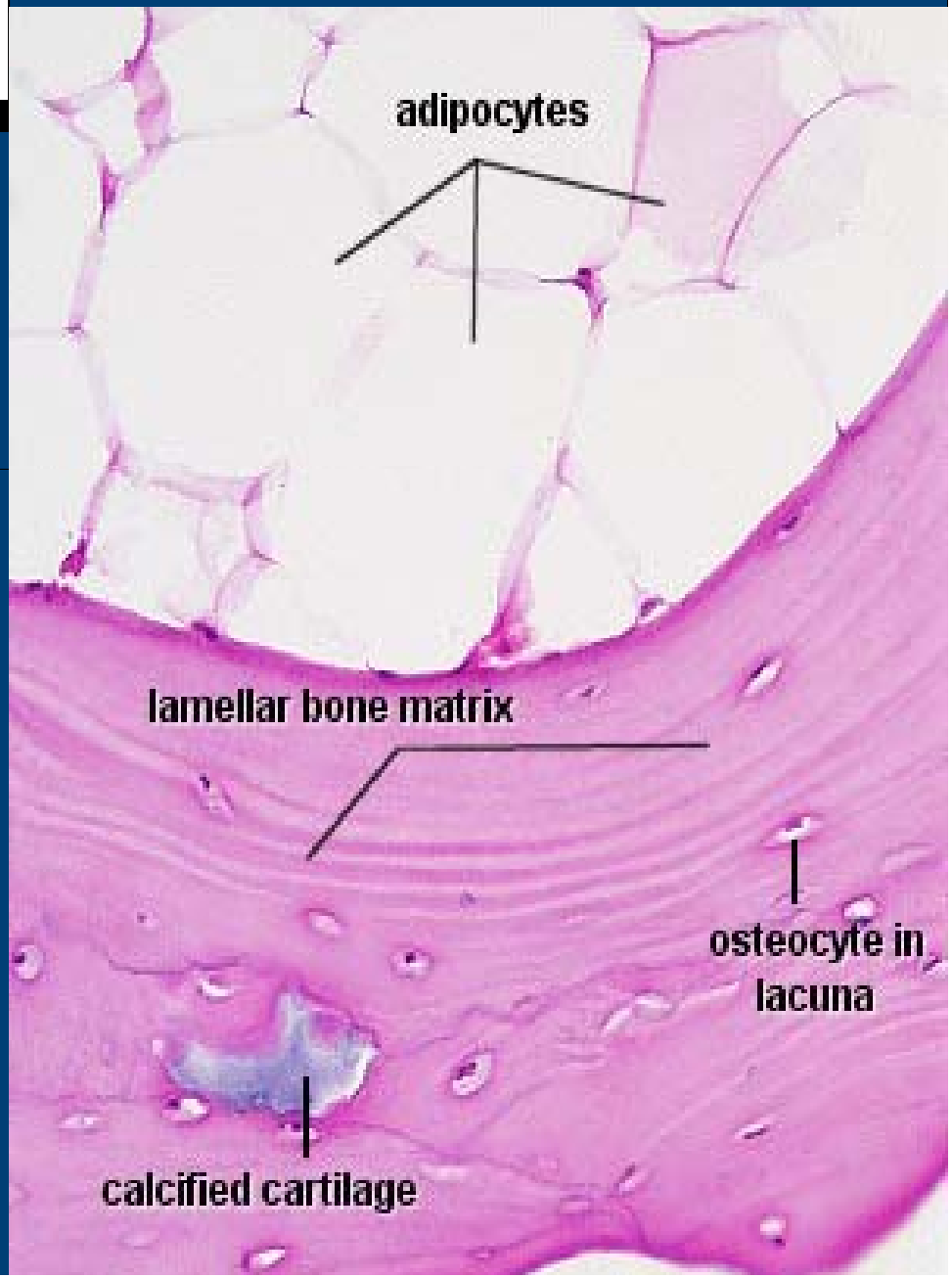

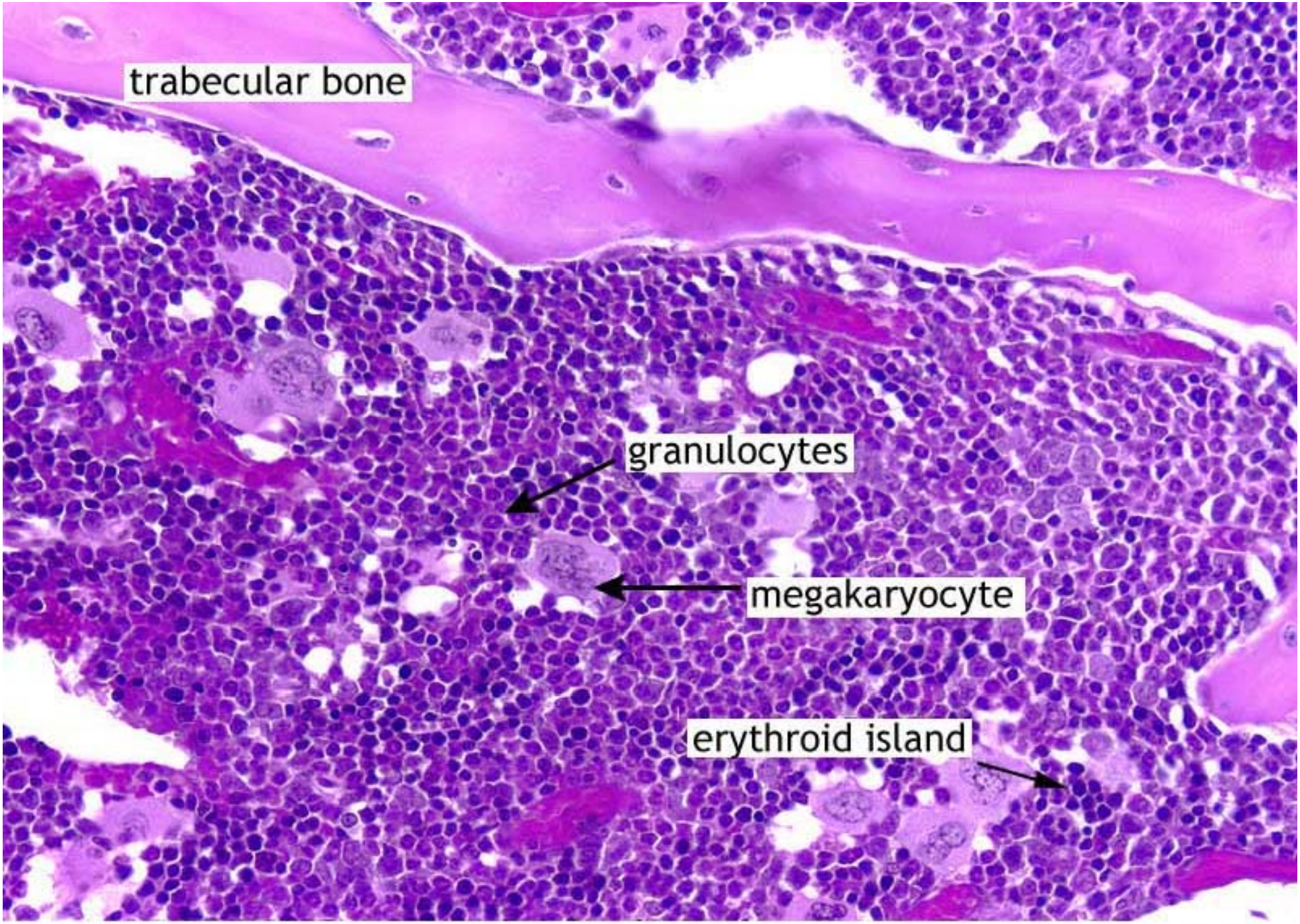

© Deltagen Inc.

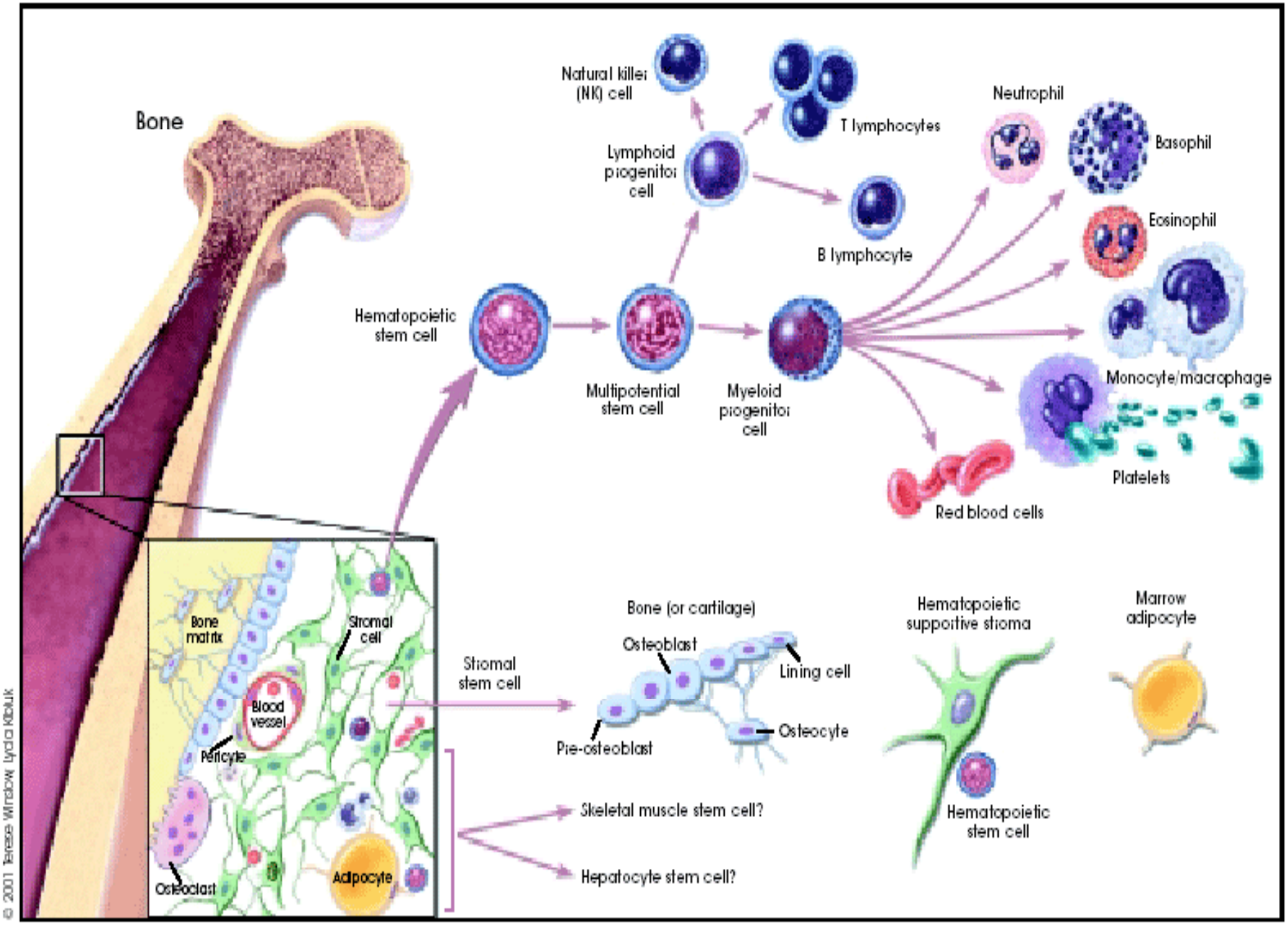

Figure 4.3. Hematopoietic and Stromal Stem Cell Differentiation.

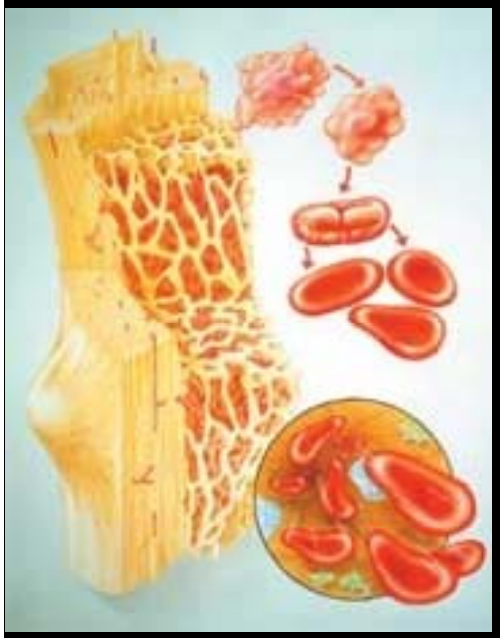

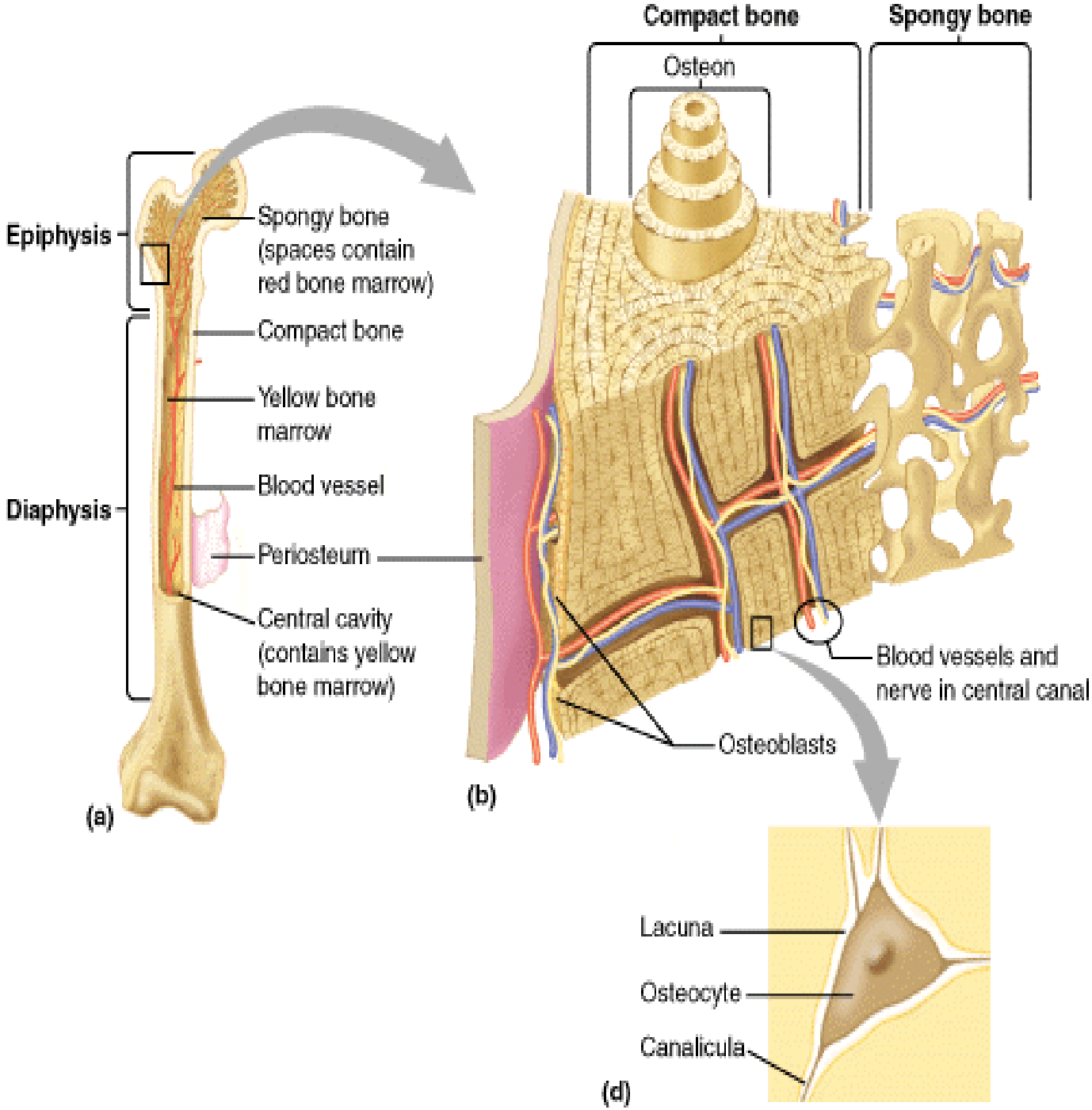
Compact bone
Spongy bone
Osteon
Epiphysis
Spongy bone (spaces contain red bone marrow)
Compact bone
Yellow bone marrow
Blood vessel
Diaphysis
Periosteum
Central cavity (contains yellow bone marrow)
(a)
Blood vessels and nerve in central canal
Osteoblasts
(b)
Lacuna
Osteocyte
Canalicula
(d)

Location of Hematopoietic Tissue (Red Marrow)

- In infants
  - Found in the medullary cavity and all areas of spongy bone
- In adults
  - Found in the diploë of flat bones, and the head of the femur and humerus

Bone Marrow
is the Site of Hematopoiesis

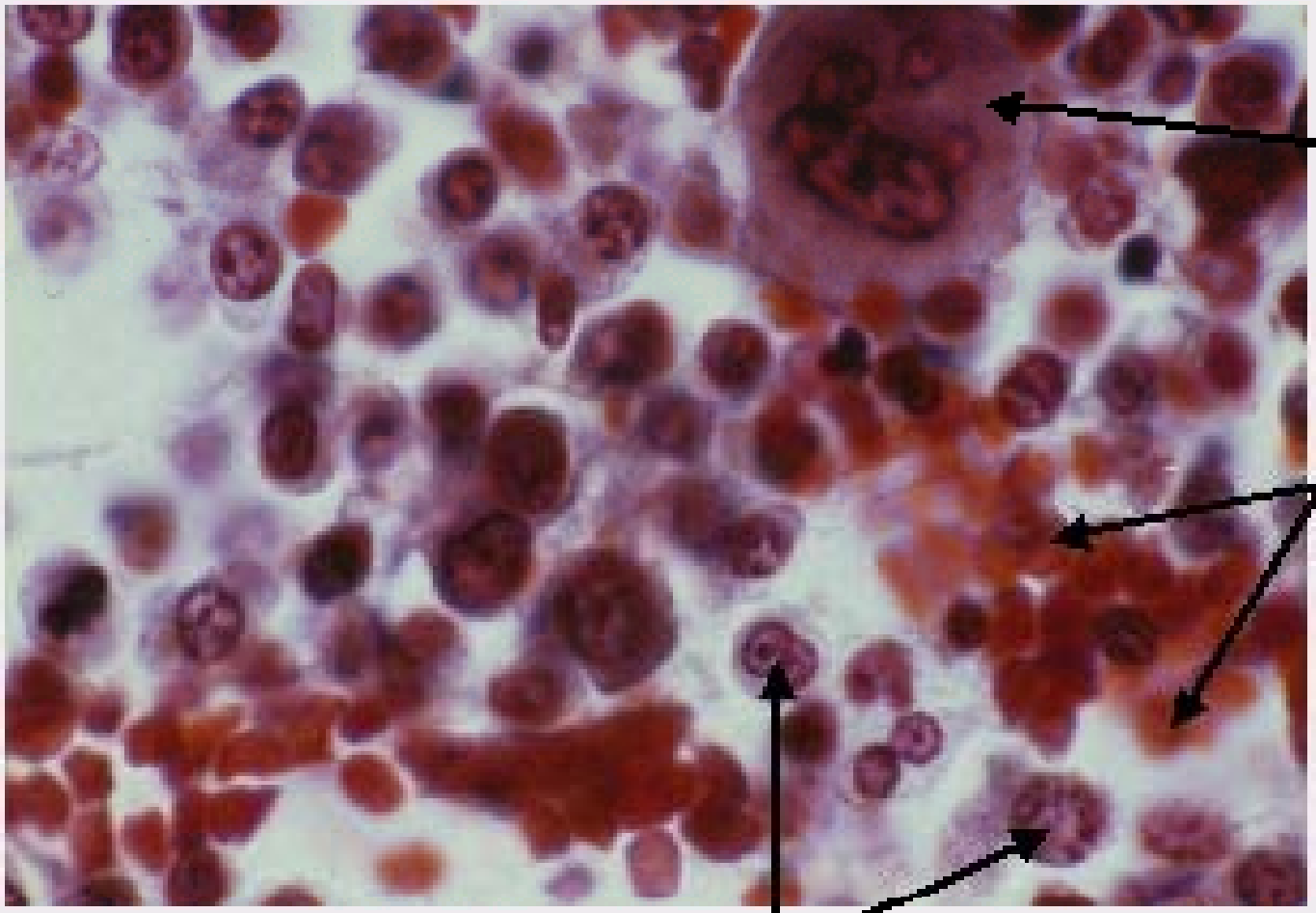

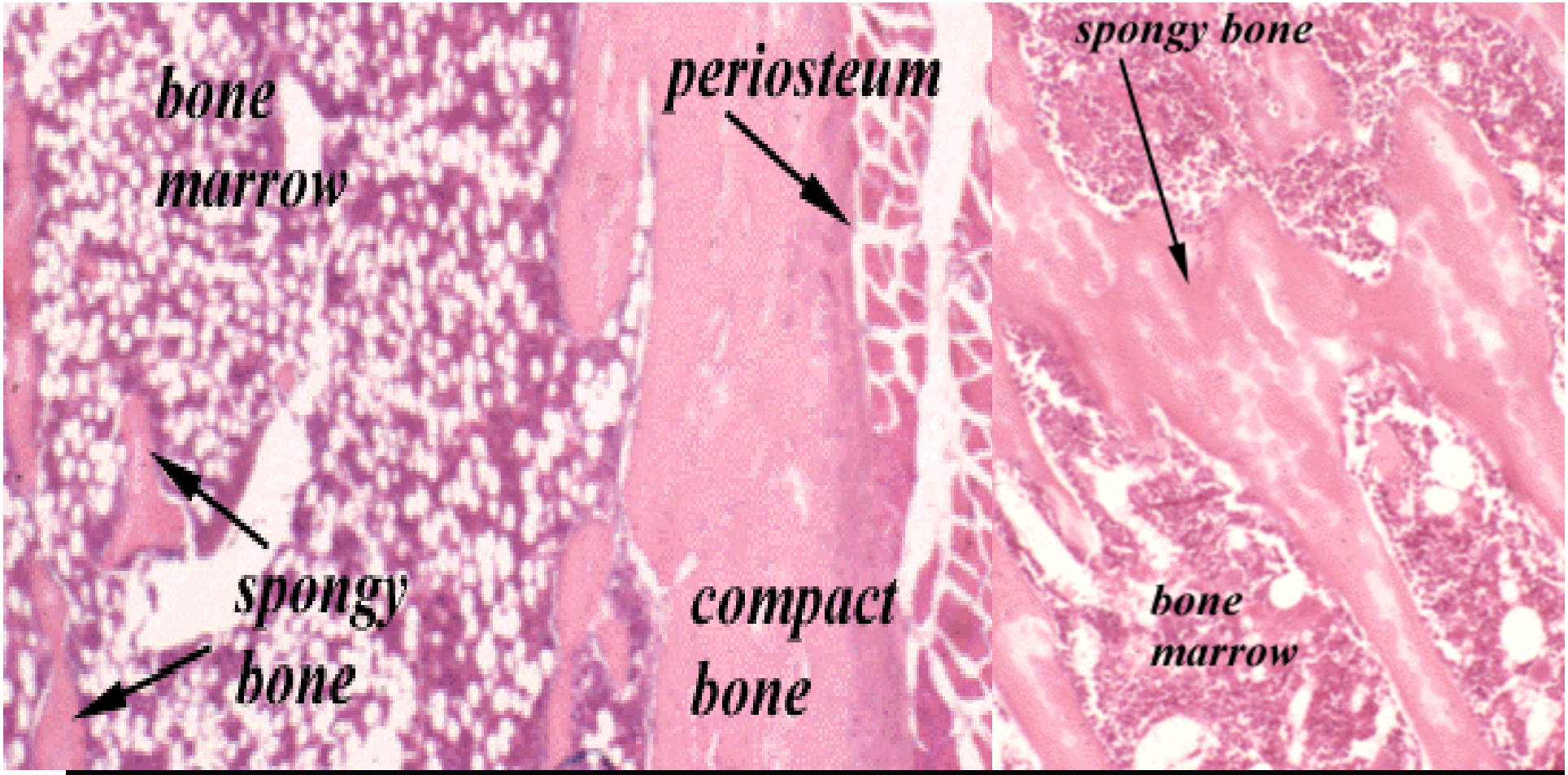

Compact bone
forming the tube shaft of long bones

spongy bone forming *trabeculae* in the bone marrow.

Microscopic Structure of Spongy Bone

- Appears poorly organized compared to compact bone.
- Lacks osteons.
- Trabeculae align along positions of stress and exhib extensive cross-bracing.
- Trabeculae are a few cell layers thick and contain irregularly arranged lamellae and osteocytes interconnected by canaliculi.
- *No haversian or Volkmann's canals are necessary. Why?*

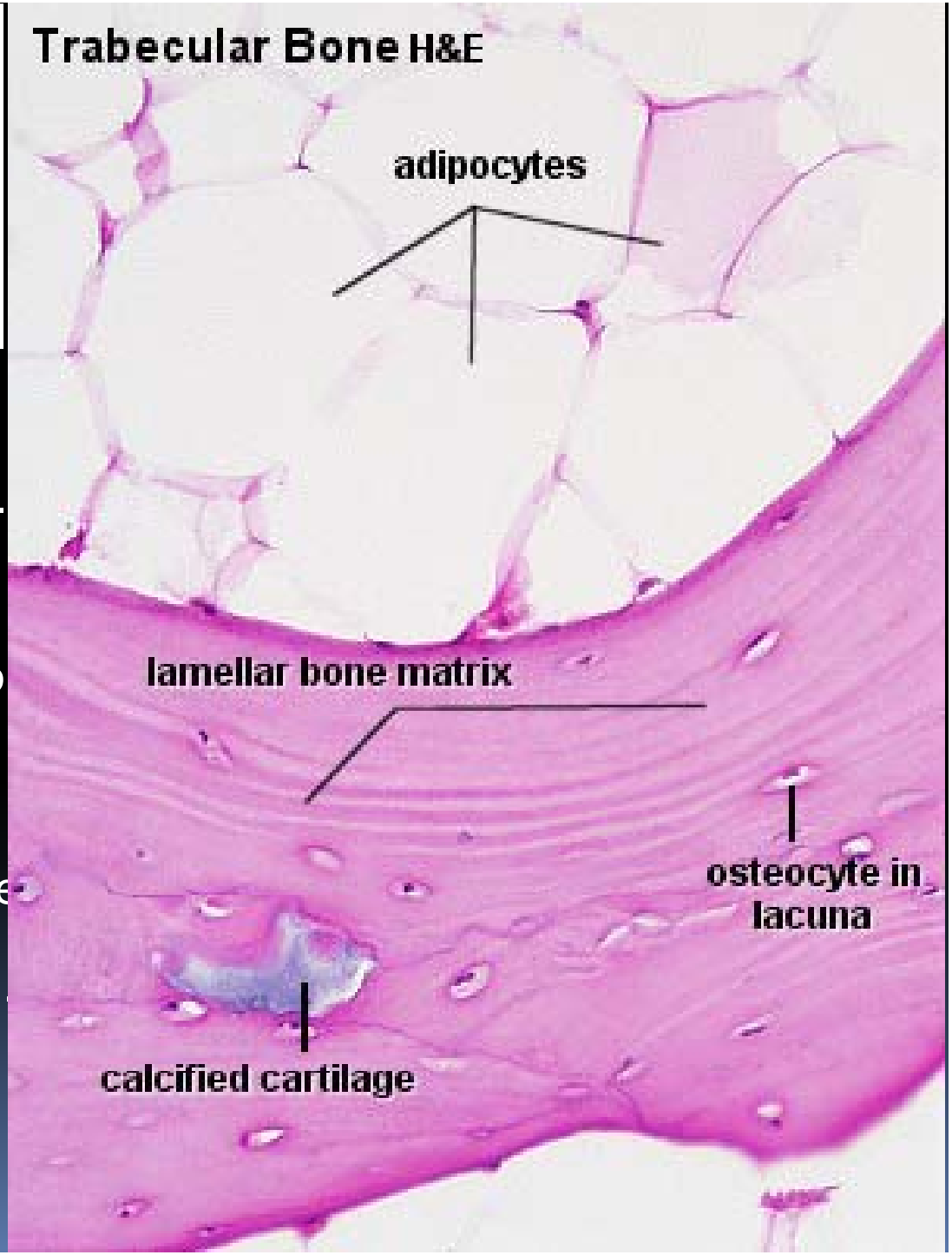

Microscopic Structure of Bone: Compact Bone

- **Haversian system, or osteon – the structural unit of compact bone**
  - **Lamella** – weight-bearing, column-like matrix tubes composed mainly of **collagen**
  - **Haversian, or central canal** – central channel containing blood vessels and nerves
  - **Volkmann's canals** – channels lying at right angles to the central canal, connecting blood and nerve supply of the periosteum to that of the Haversian canal

bone matrix

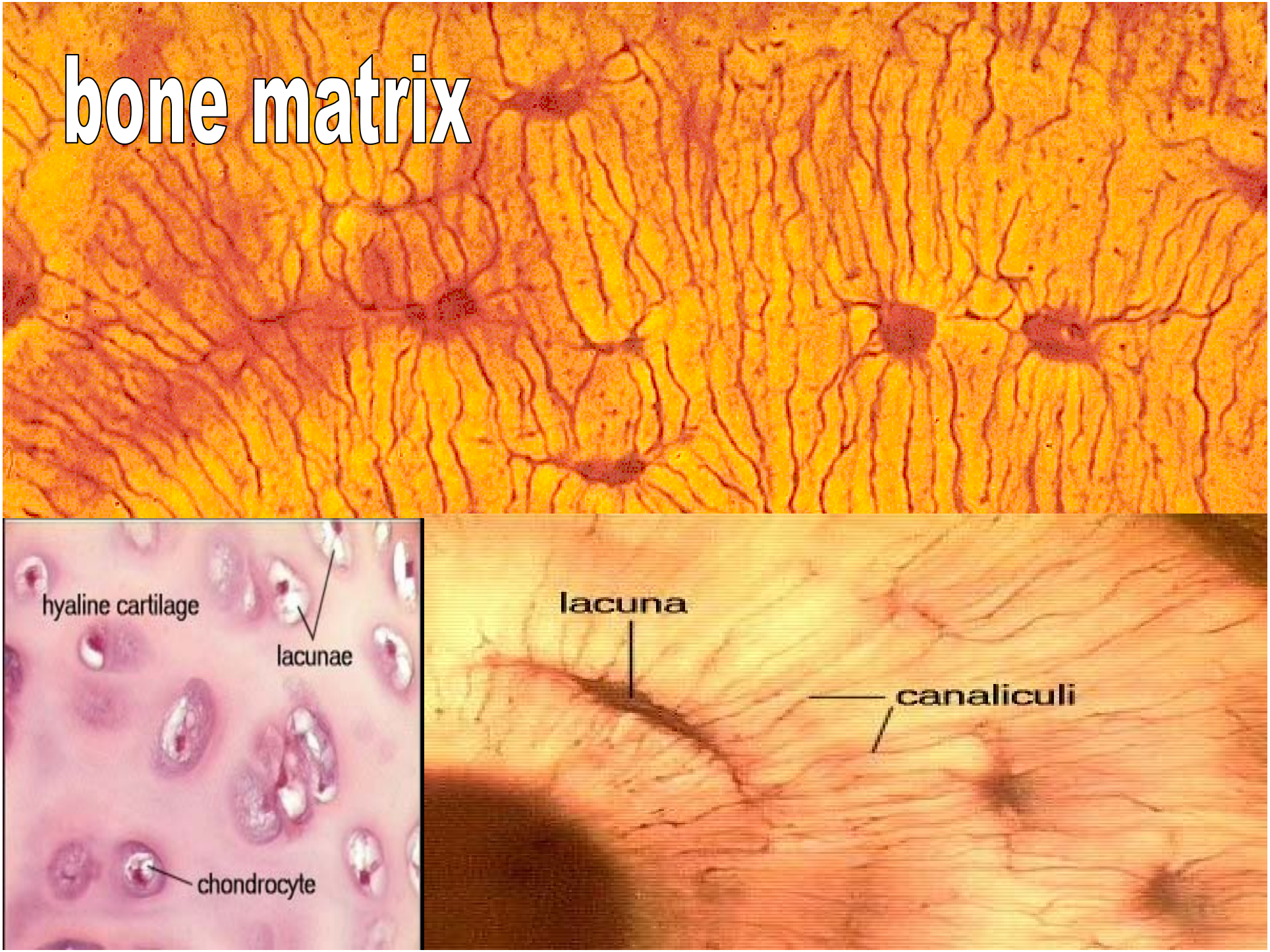
hyaline cartilage
lacunae
chondrocyte
lacuna
canaliculi

The **osteon** is a unit of structure consisting of **concentric lamellae** surrounding an **haversian canal**.

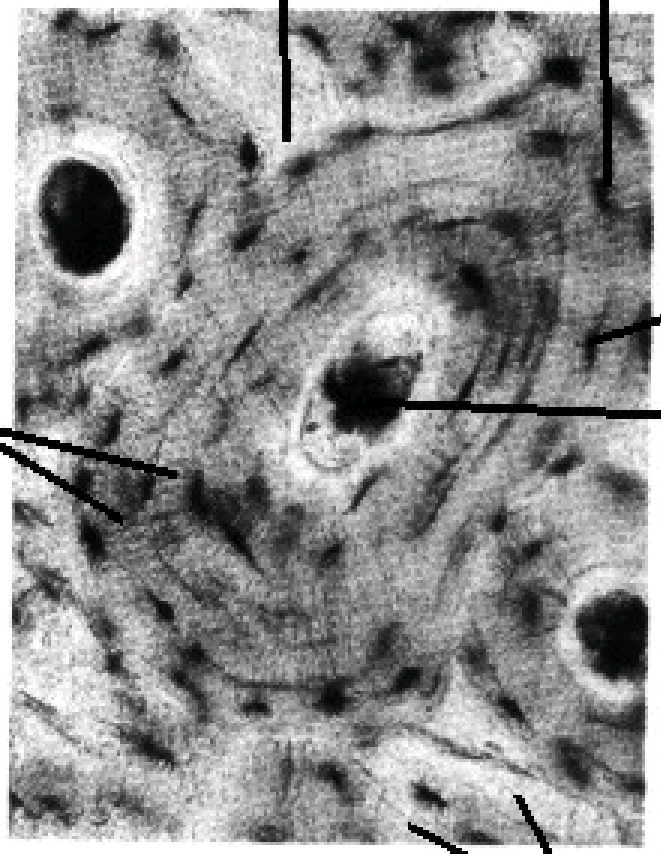

Lacunae are spaces enclosing the bone cells, or osteocytes.

Haversian canals run longitudinally through bone allowing passage of small blood vessels.

The tiny "hairs" are small canaliculi which allow extensions of the **osteocytes** to reach out and obtain nutrients and even form contacts with one another.

Interstitial lamellae are non-circular remnants left behind from former osteons when new osteons replace them.

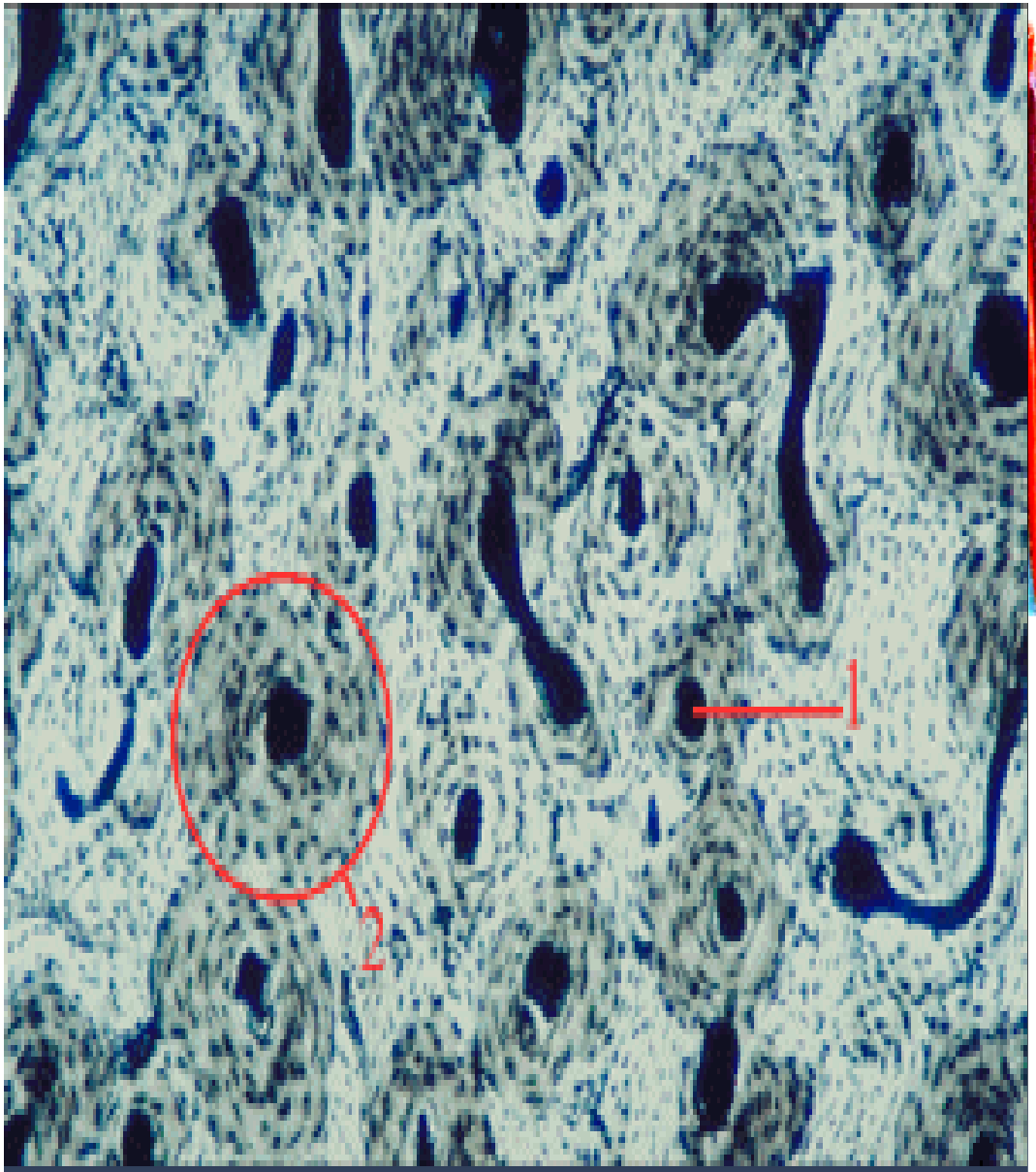

1.Haversian Canal
2.Haversian System

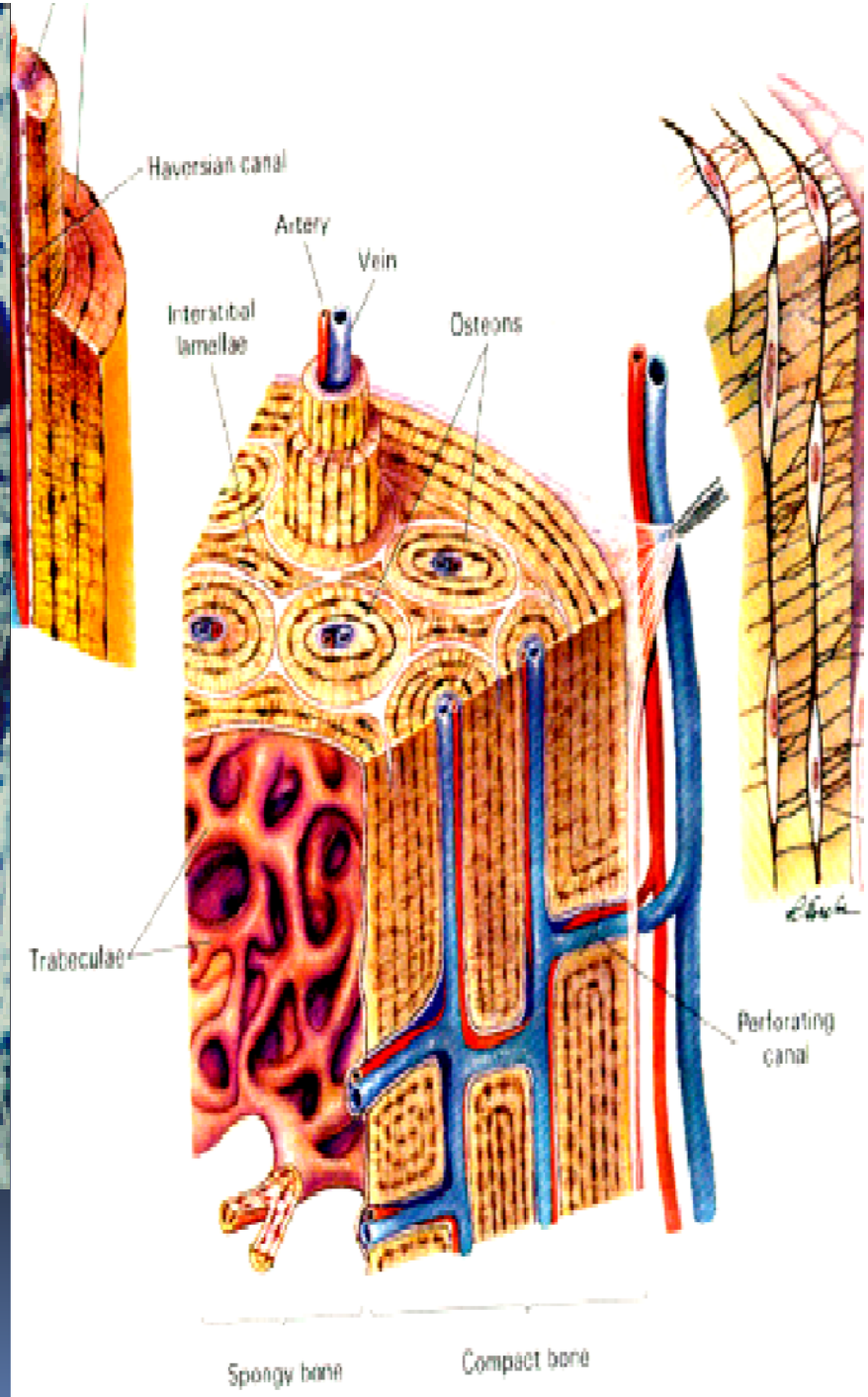



Haversian Canal

A higher magnification shows the concentric circles. After osteoclasts remove old bone, osteoblasts deposit bone in this circular arrangement beginning with the outer ring and working inward.

As the osteoblasts become trapped in their own calcified deposits, they are known as osteocytes.


Compact bone
Polarizing microscopy
100 µm
100 µm

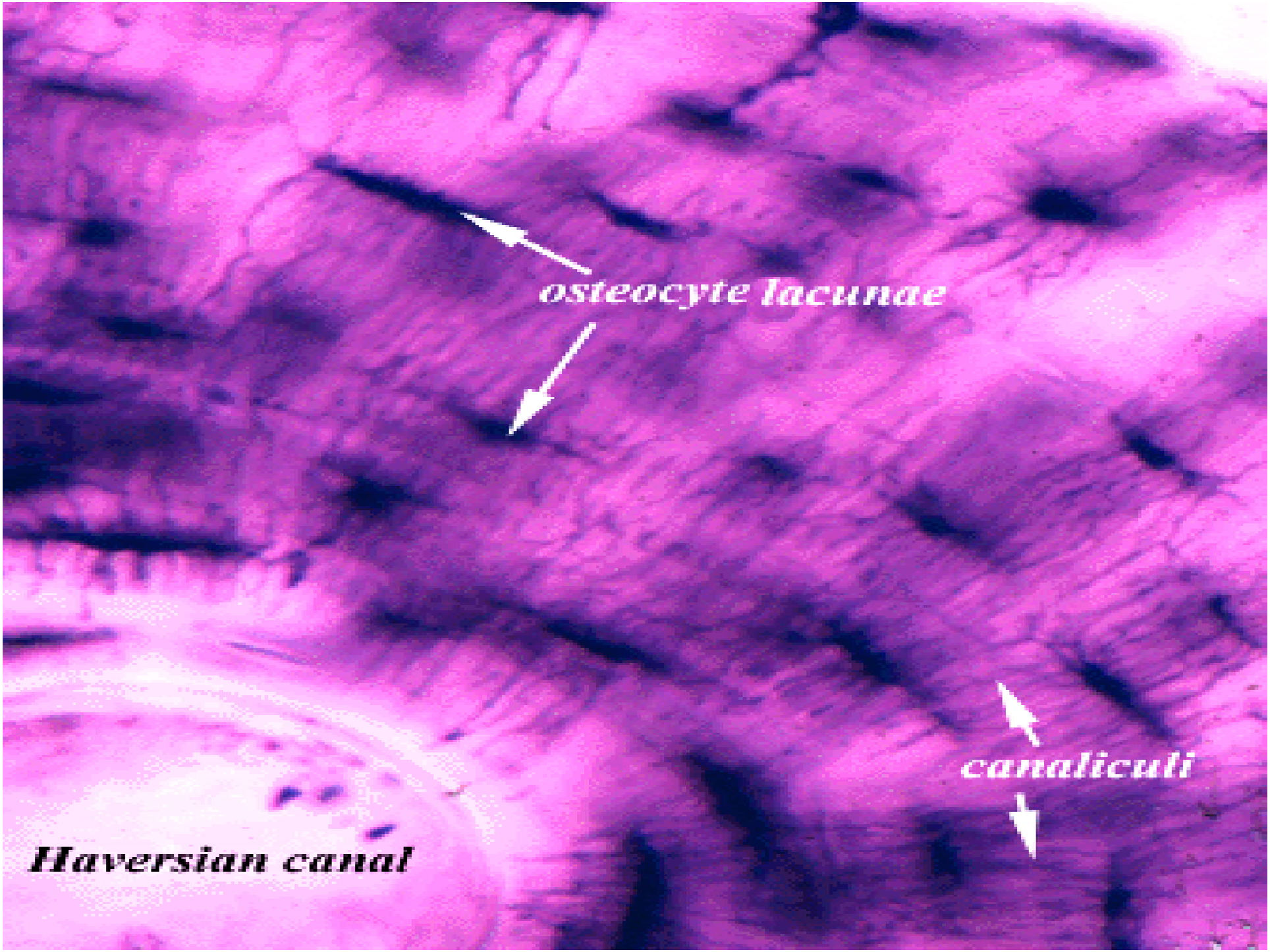
osteocyte lacunae
canaliculi
Haversian canal

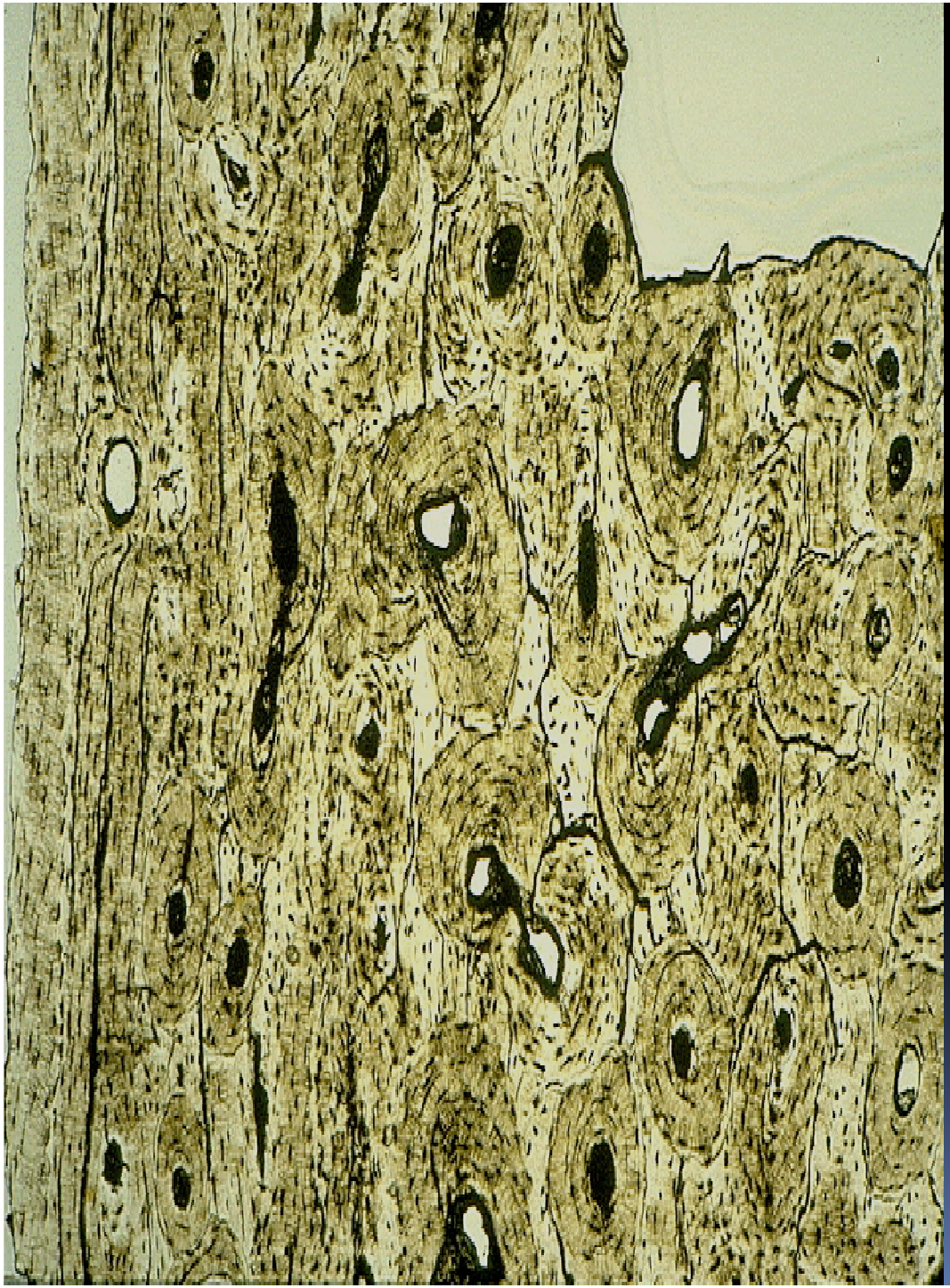

Within compact bone is a system of canals that contain blood vessels, nerves, and lymph vessels.

These canals form functional units called osteons (Haversian systems).

The osteon is a tube-like structure containing a central (Haversian) canal through which nerves and blood vessels pass.

Surrounding the central canal is bone matrix, a substance produced by osteocytes.

Within the osteon, osteocytes form lamellae, concentric layers of hard bone matrix.

As osteoblasts create lamellae, these osteoblasts become trapped within the compact bone and are called osteocytes.


A Haversian System

Haversian canals

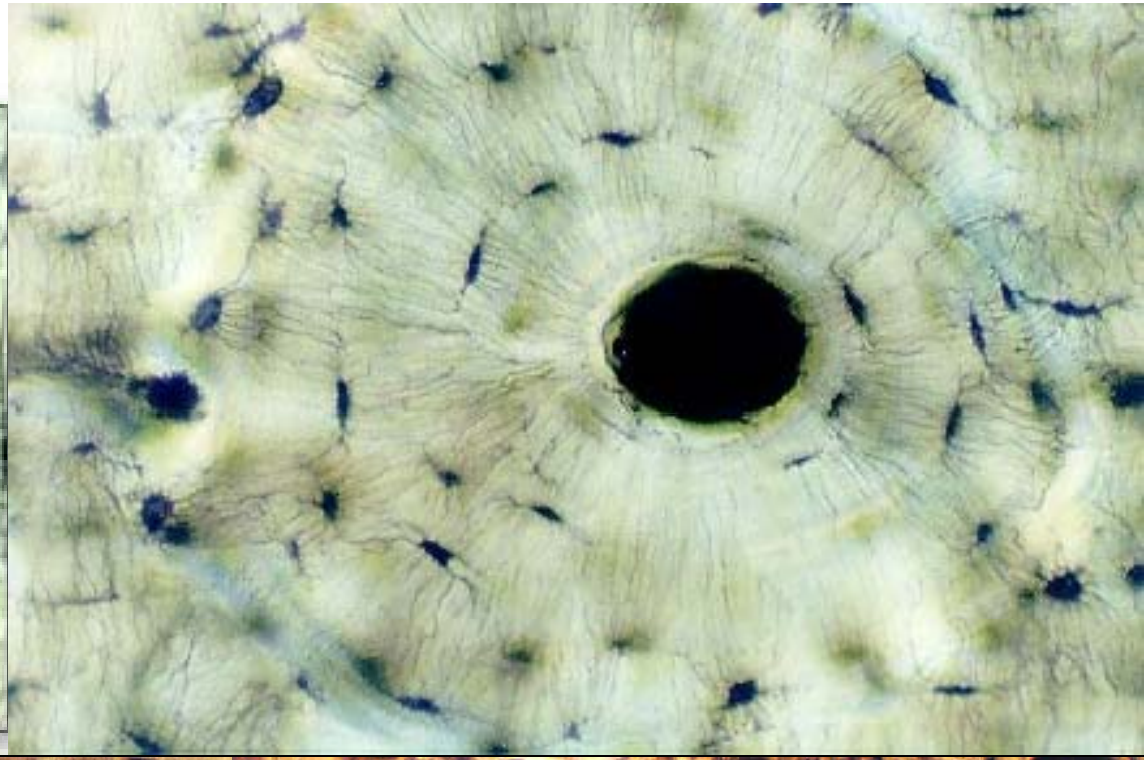

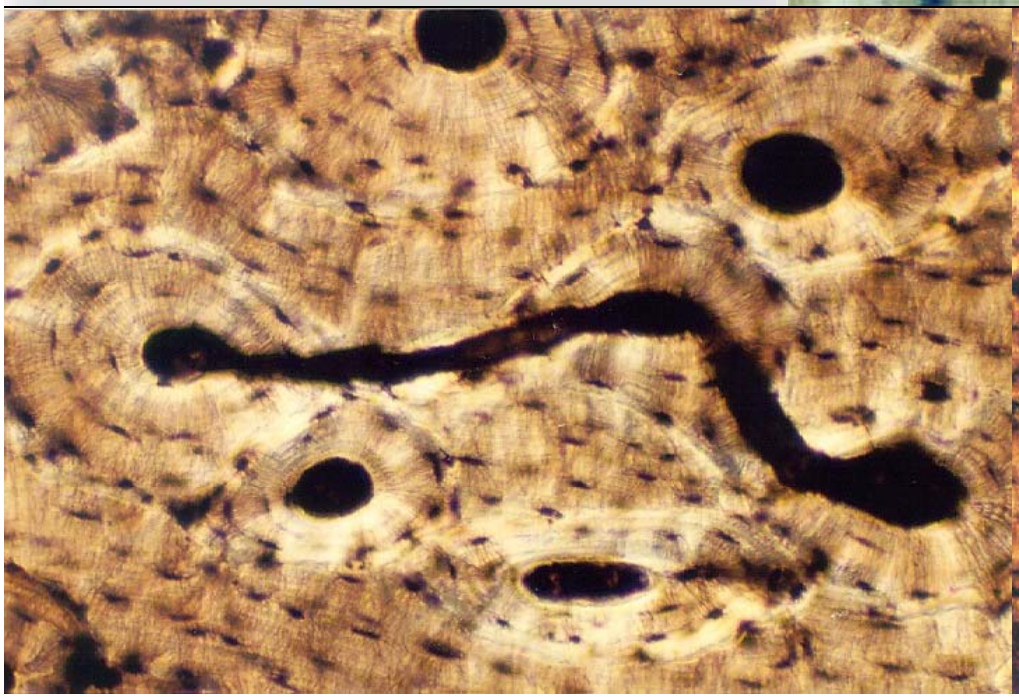

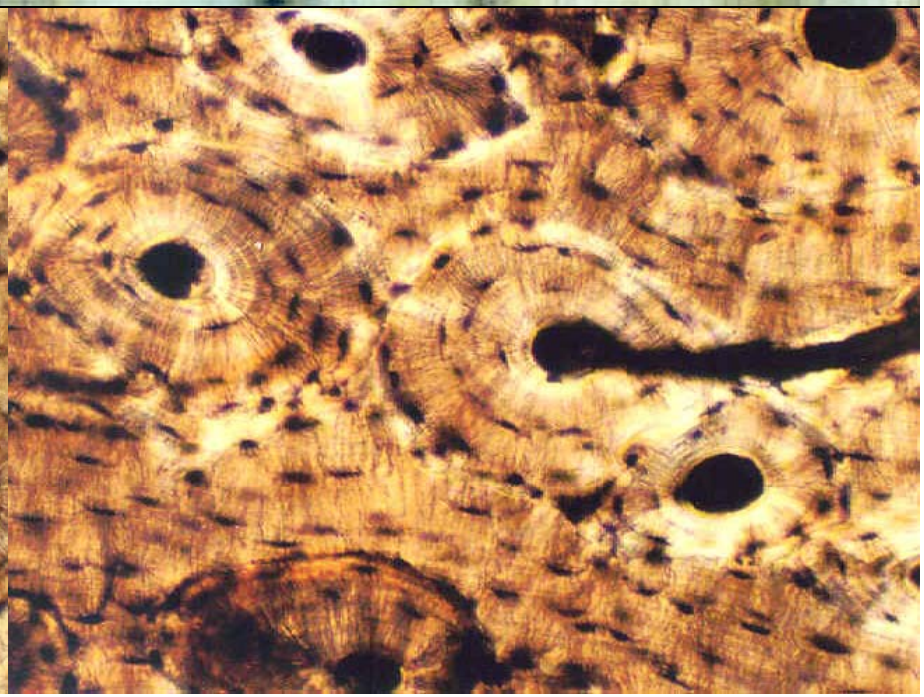

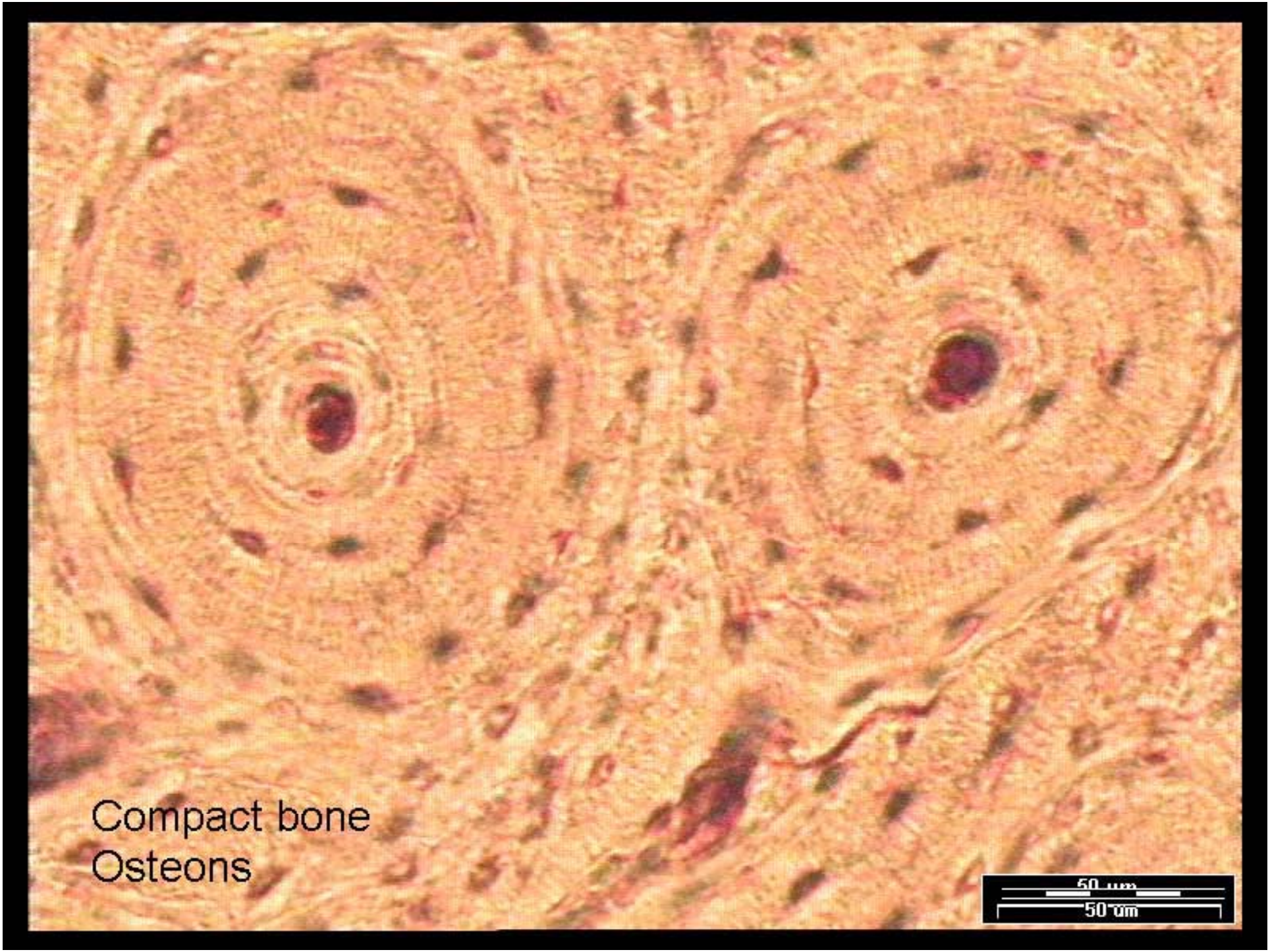
Compact bone
Osteons
50 µm

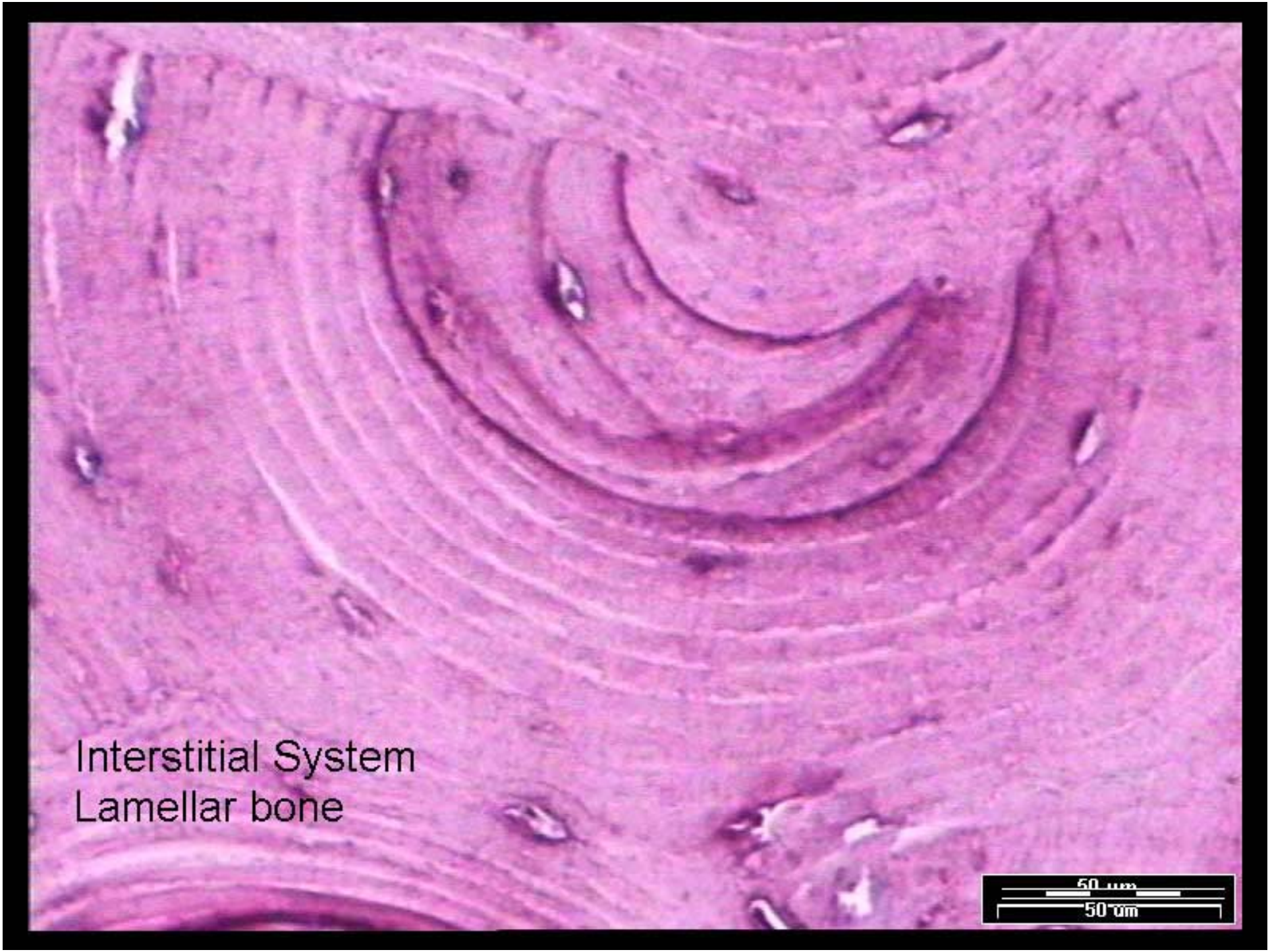
Interstitial System
Lamellar bone
50 µm

Interstitial System
Lamellar bone
100 µm
100 µm

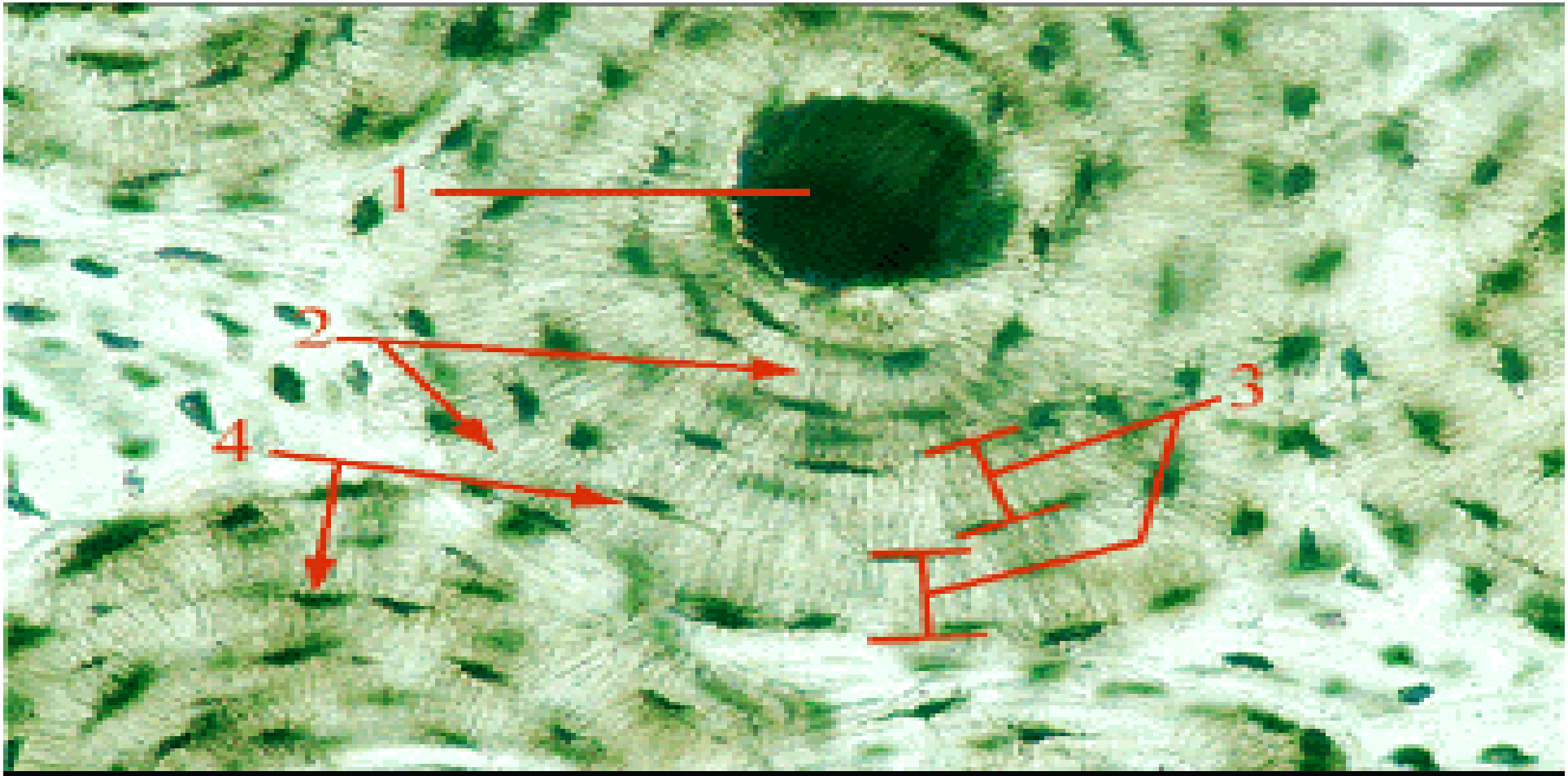

1.Haversian Canal
2.Canaliculi gap junction are found at the end of the extension
3.Lamellae
4.Lacunae

Microscopic Structure of Bone: Compact Bone

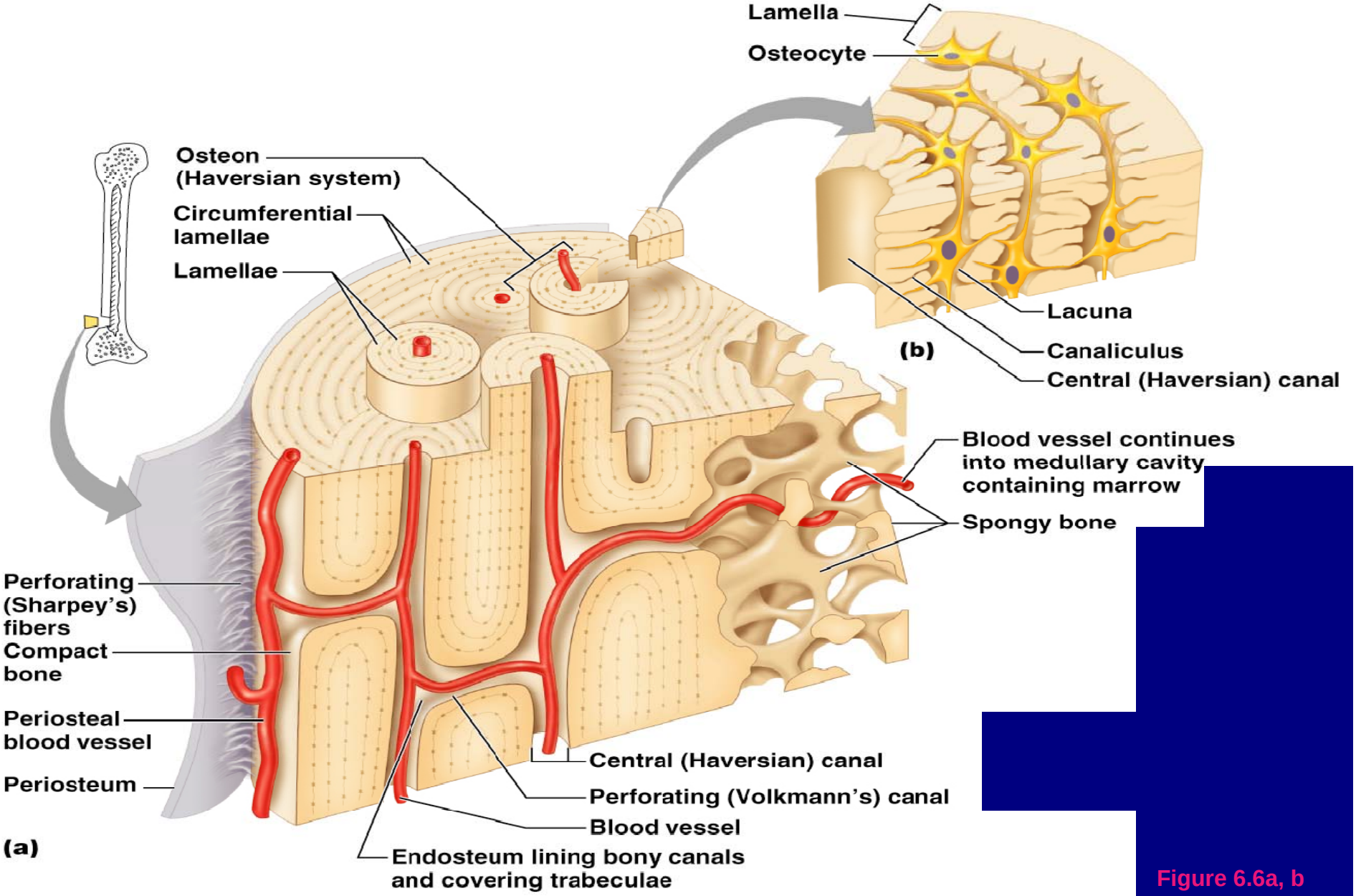

Figure 6.6a, b

Microscopic Structure of Bone: Compact Bone

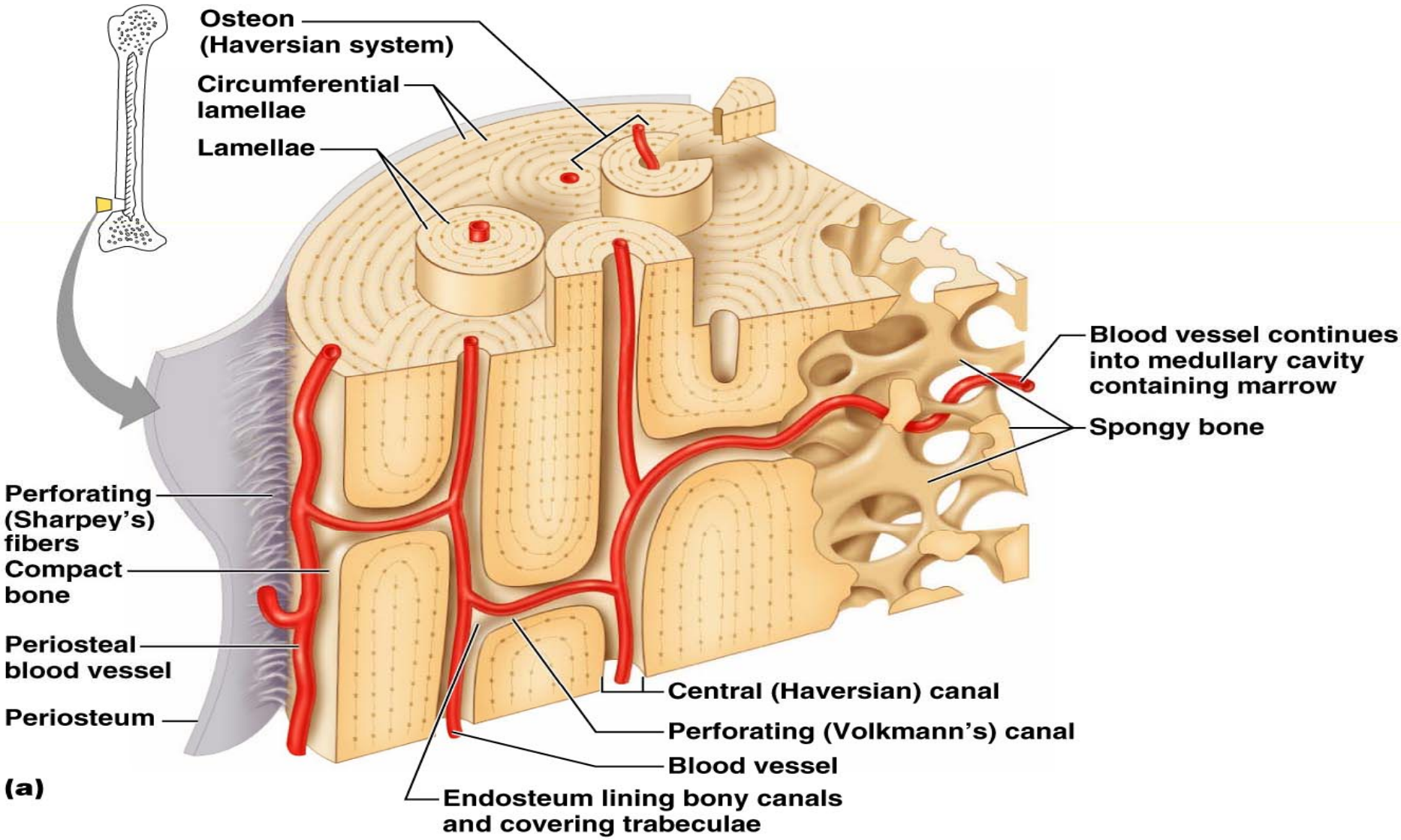

Microscopic Structure of Bone: Compact Bone

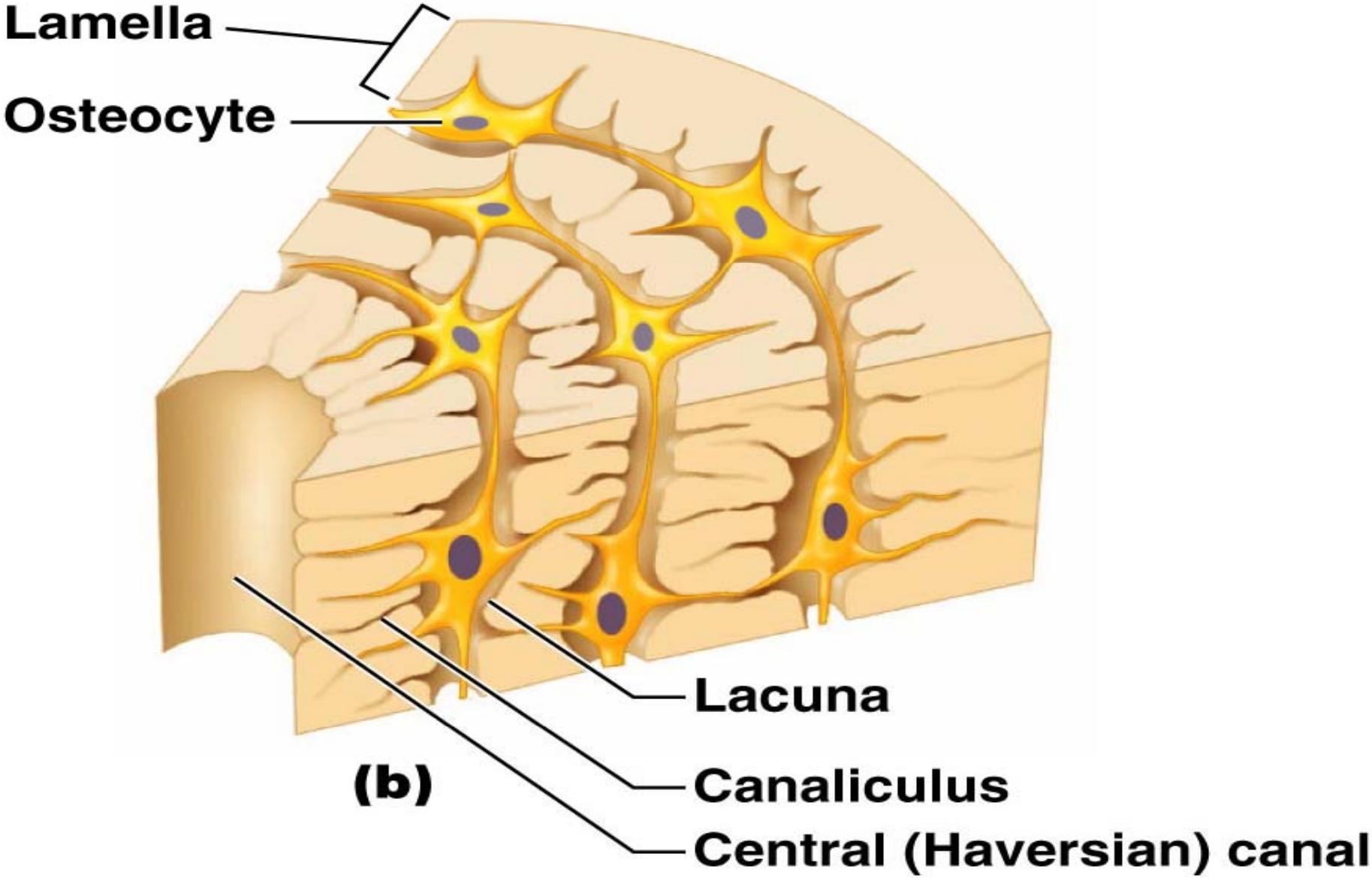

Microscopic Structure of Bone: Compact Bone

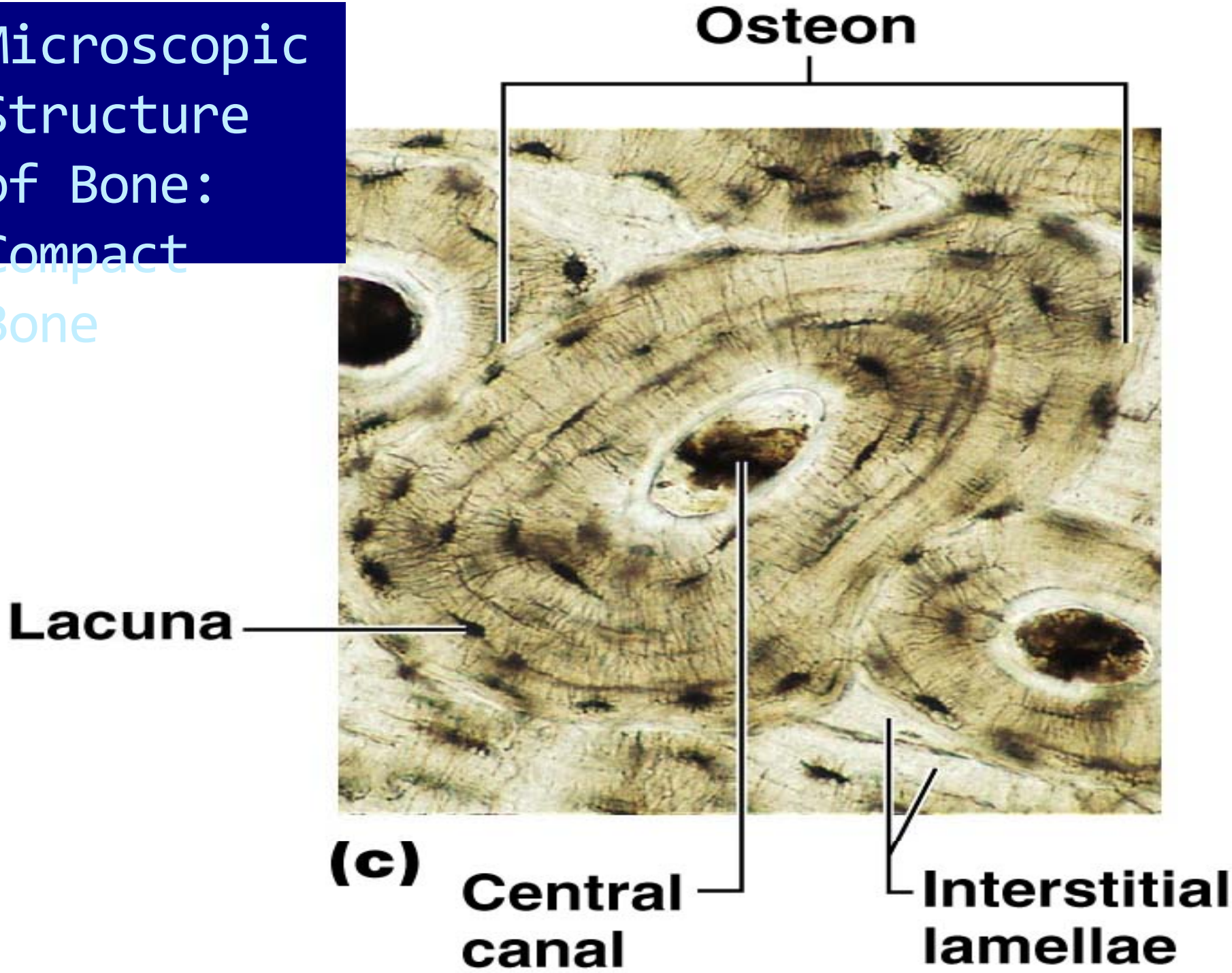

Why are canaliculi necessary in bone tissue

- The canaliculi. Canaliculi arising from one lacuna may anastomose with those of other lacunae and, eventually, with larger, vessel-containing canals within the bone.
- **Canaliculi provide the means for the osteocytes to communicate with each other and to exchange substances by diffusion.**

• The radiating processes of the osteocytes project into these canals. These cytoplasmic processes are joined together by **gap junctions.**
•Osteocytes do not entirely fill up the canaliculi. The remaining space is known as the periosteocytic space, which is filled with periosteocytic fluid.

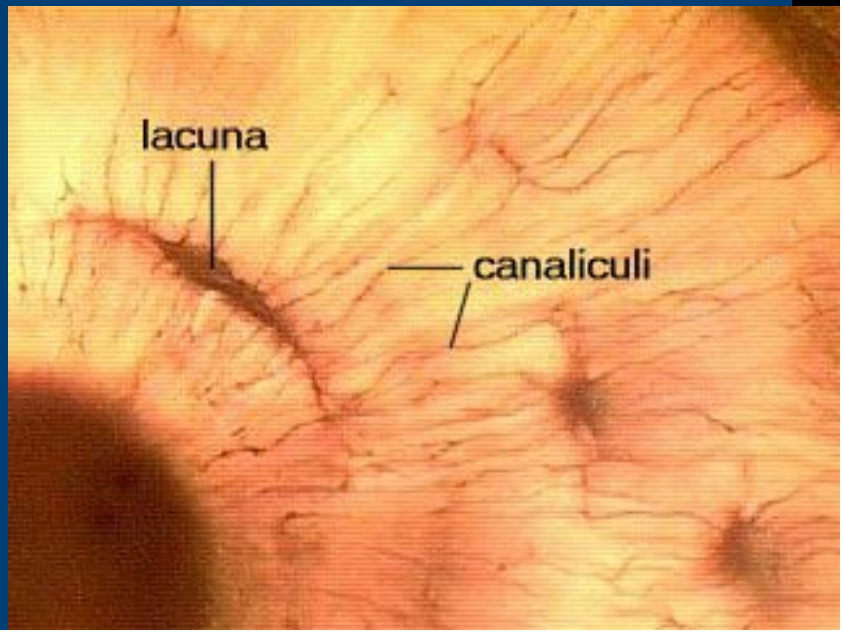

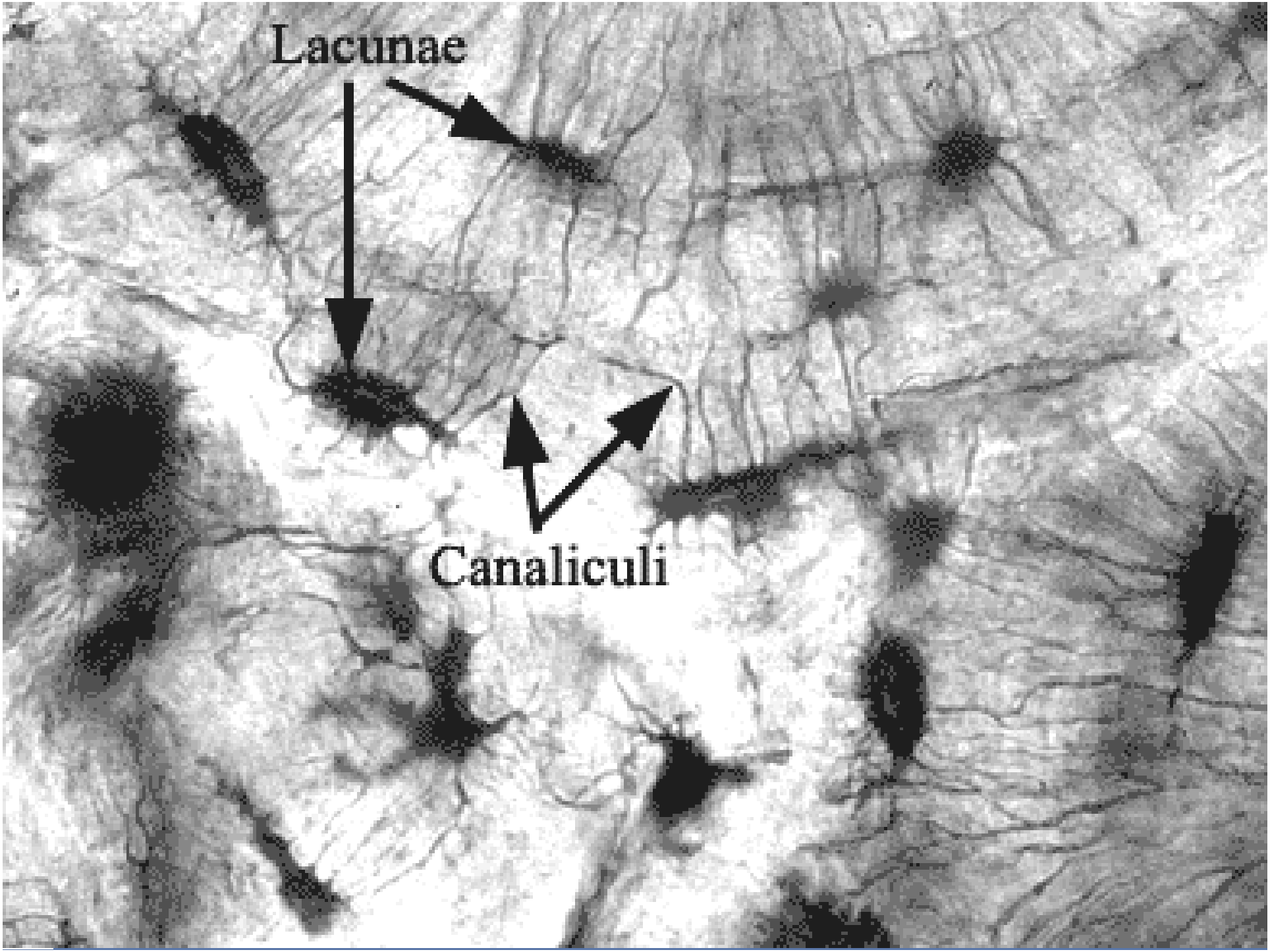
Lacunae
Canaliculi

Spongy bone

- No osteons
- Trabeculae surround red marrow-filled spaces.
- Trabeculae contain irregularly arranged lamellae and osteocytes connected by canaliculi
  - Nutrients reach osteocytes by diffusion through canaliculi from marrow spaces

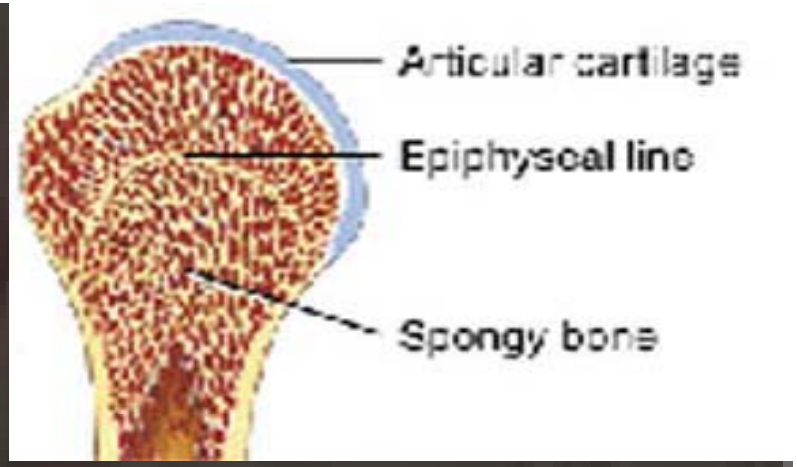

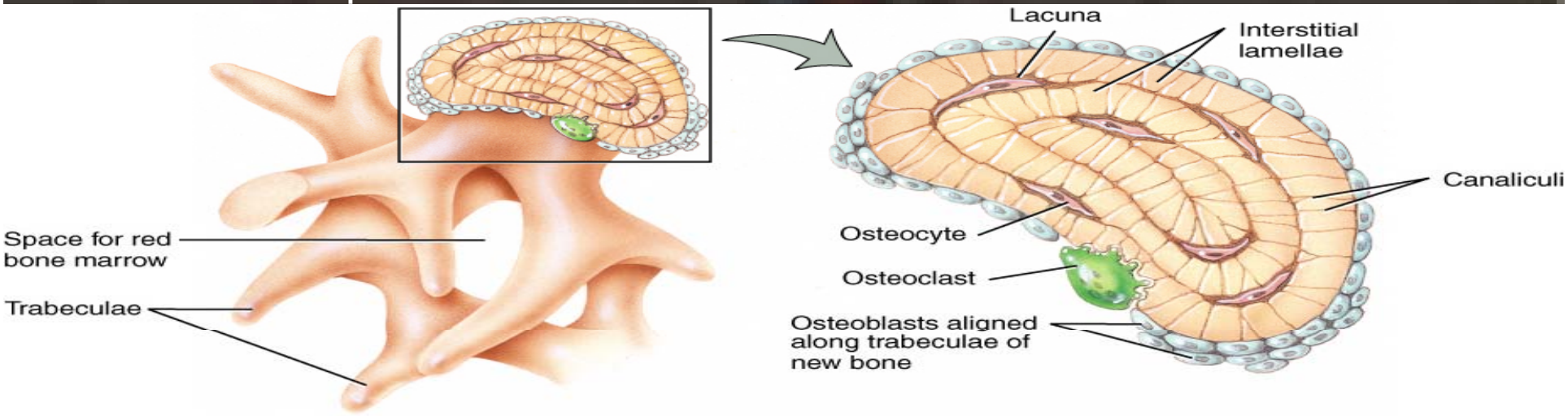

(a) Enlarged aspect of spongy bone trabeculae

(b) Details of a section of a trabecula

06.04

Developing Long Bone

In this trichrome stained section, calcified cartilage forms the cores of spicules with bone deposited on the outside.

This slide is taken from the ossification zone of a developing long bone.

- Spider-shaped osteocytes occupy small cavities known as lacunae at the junctions of the lamellae. Hairlike canals called canaliculi connect the lacunae to each other and to the central canal.
- Canaliculi allow the osteocytes to exchange nutrients, wastes, and chemical signals to each other via intercellular connections known as gap junctions.

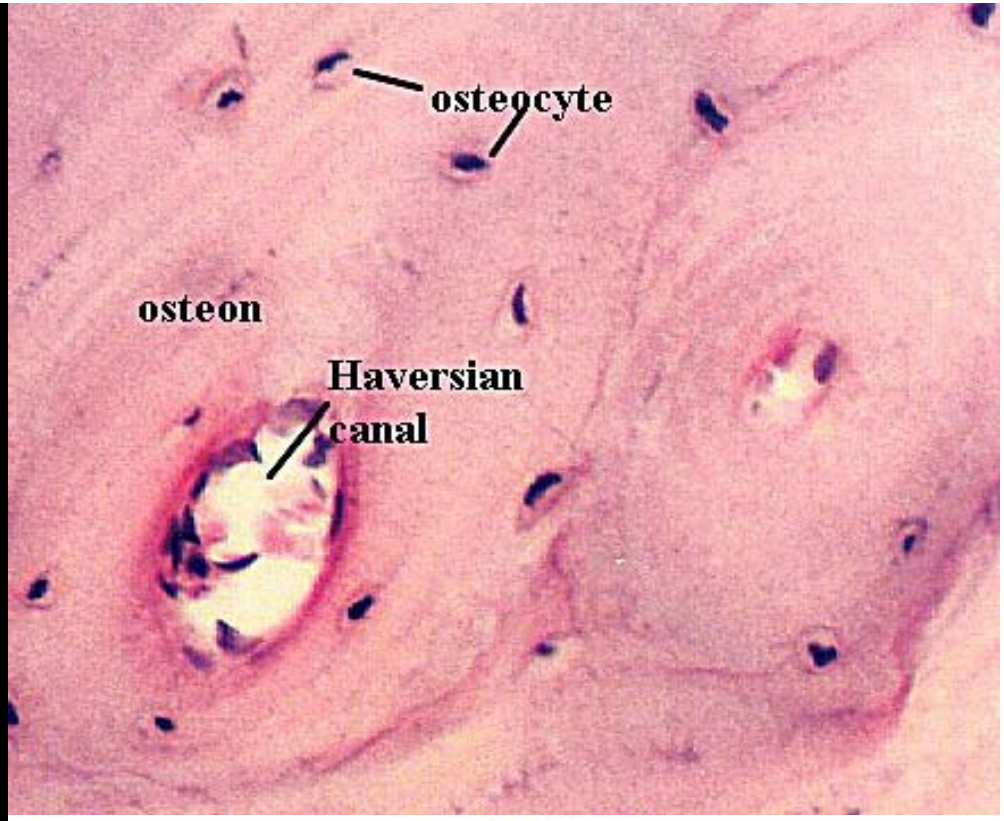

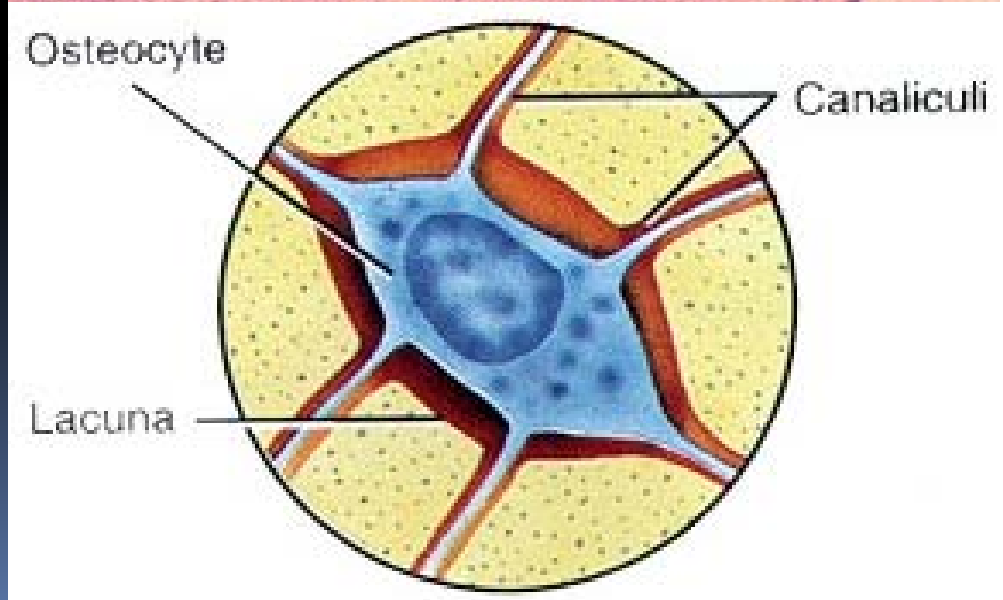

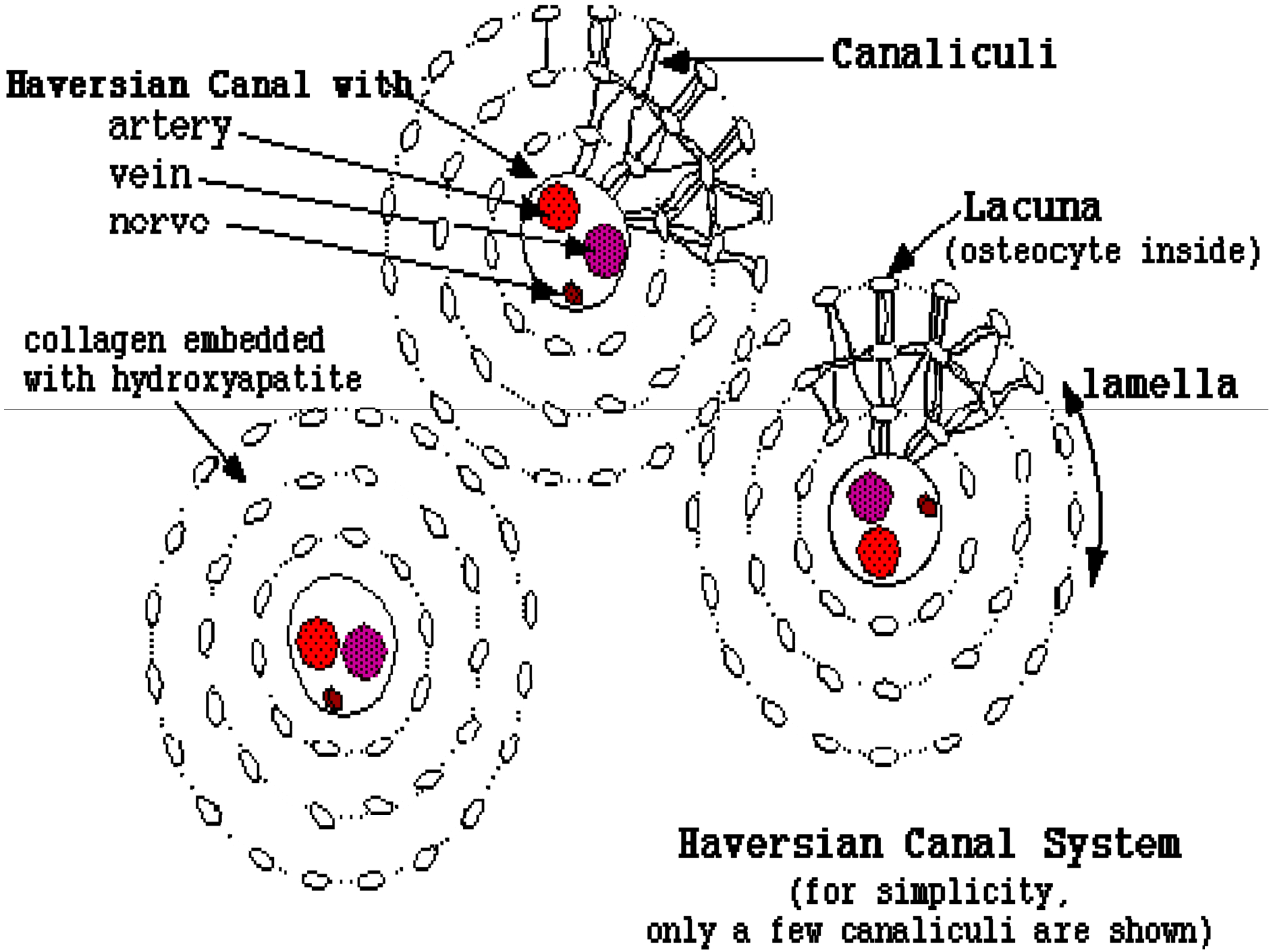
Canaliculi
Haversian Canal with
artery
vein
nerve
Lacuna
(osteocyte inside)
collagen embedded
with hydroxyapatite
lamella
Haversian Canal System
(for simplicity,
only a few canaliculi are shown)

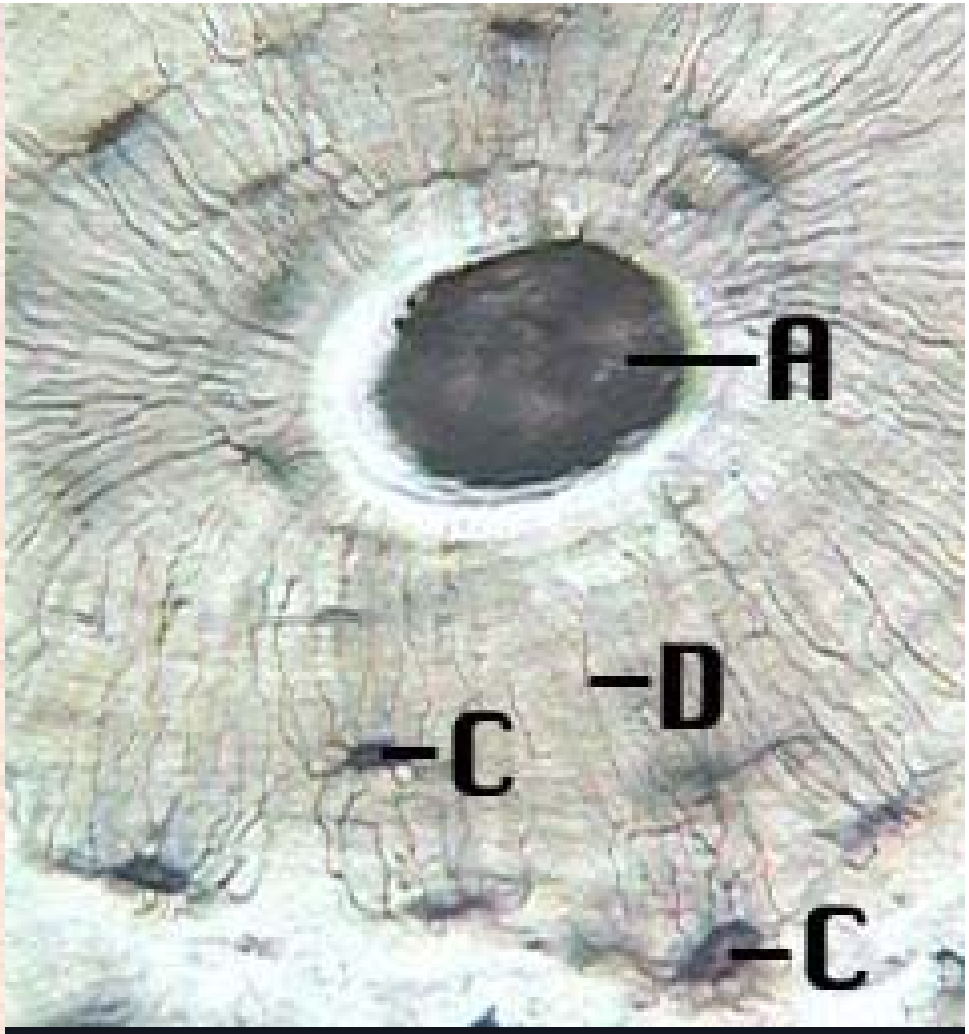

Here, we have a close up and a far away view of compact bone. You should be able to identify haversian canals, concentric lamellae, interstitial lamellae, lacunae, and canaliculi.

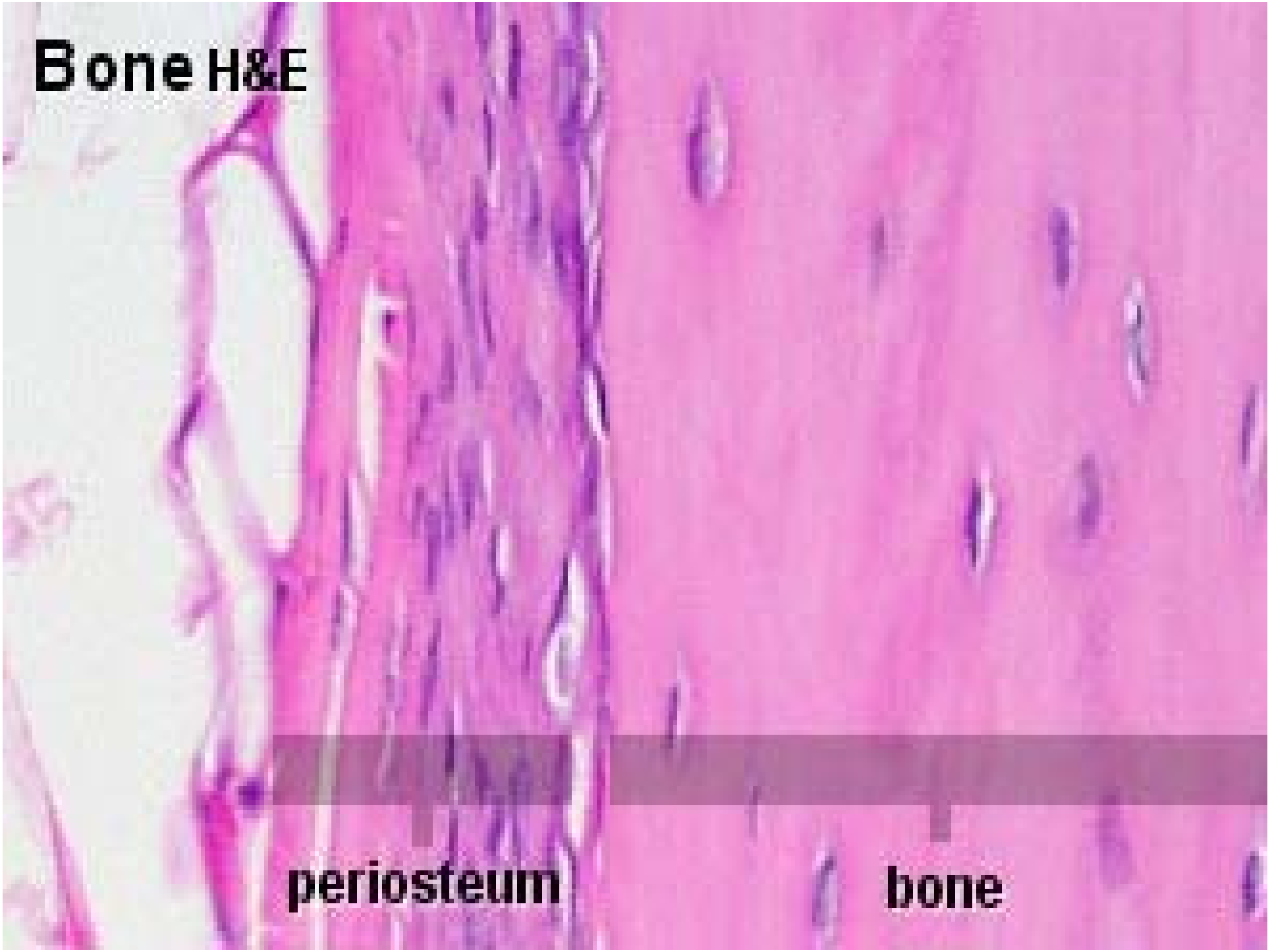
Bone H&E
periosteum
bone

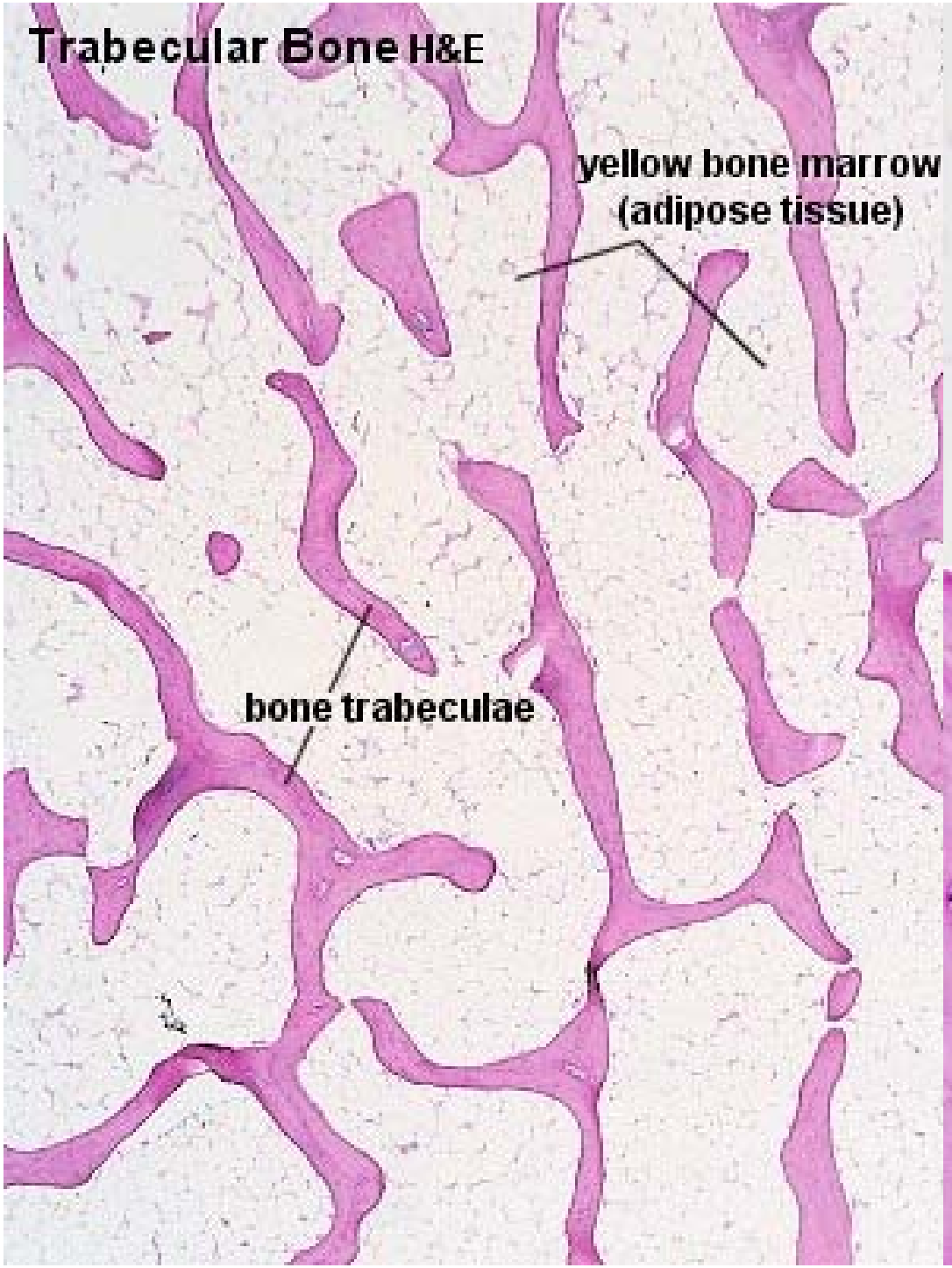
Trabecular Bone H&E
yellow bone marrow
(adipose tissue)
bone trabeculae

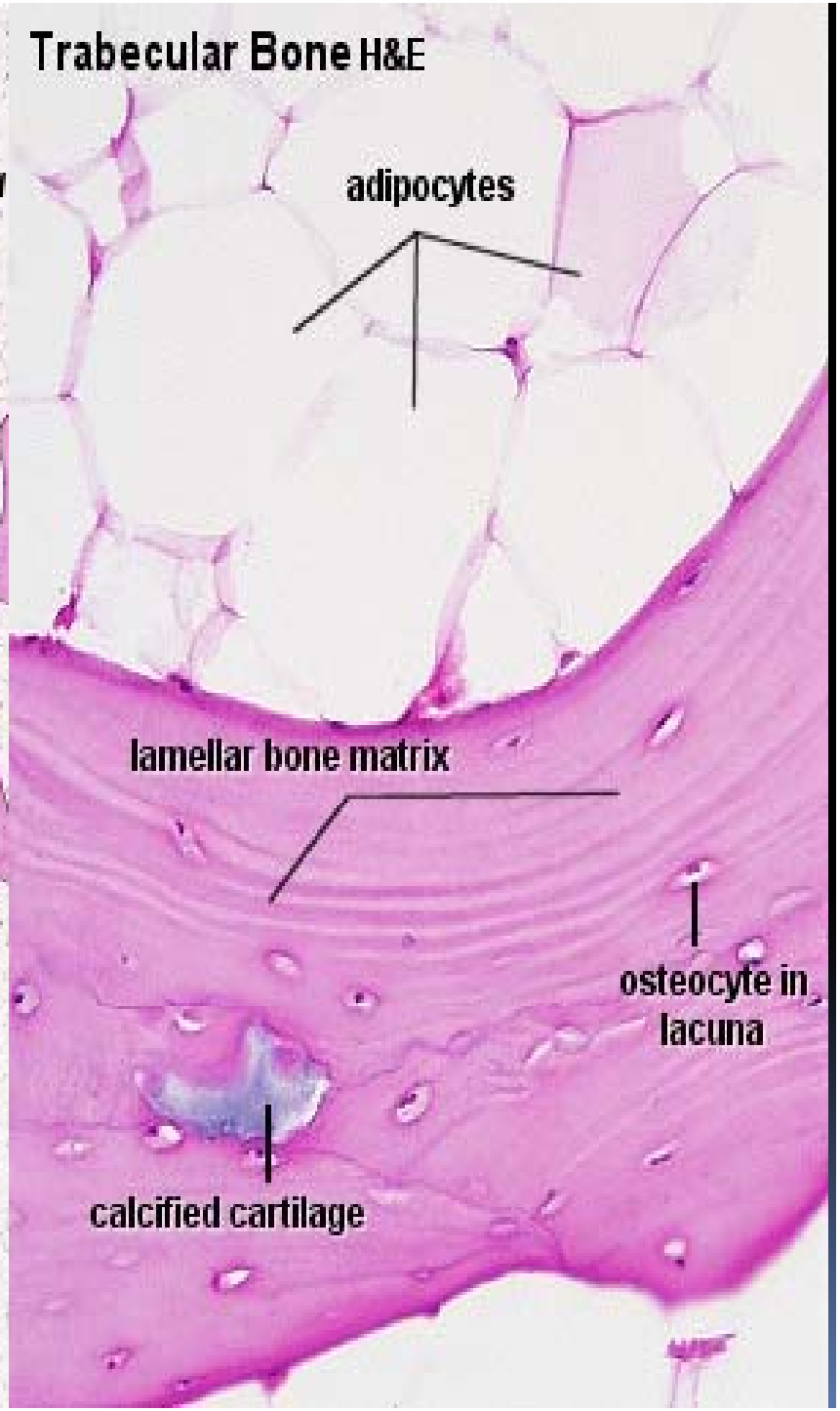
Trabecular Bone H&E
adipocytes
lamellar bone matrix
osteocyte in
lacuna
calcified cartilage

Osteons

Each osteon consists of a single central canal, known as a haversian canal, surrounded by concentric layers of calcified bone matrix.

- Haversian canals allow the passage of blood vessels, lymphatic vessels, and nerve fibers.
- Each of the concentric matrix "tubes" that surrounds a haversian canal is known as a lamella.
- All the collagen fibers in a particular lamella run in a single direction, while collagen fibers in adjacent lamellae will run in the opposite direction. This allows bone to better withstand twisting forces.

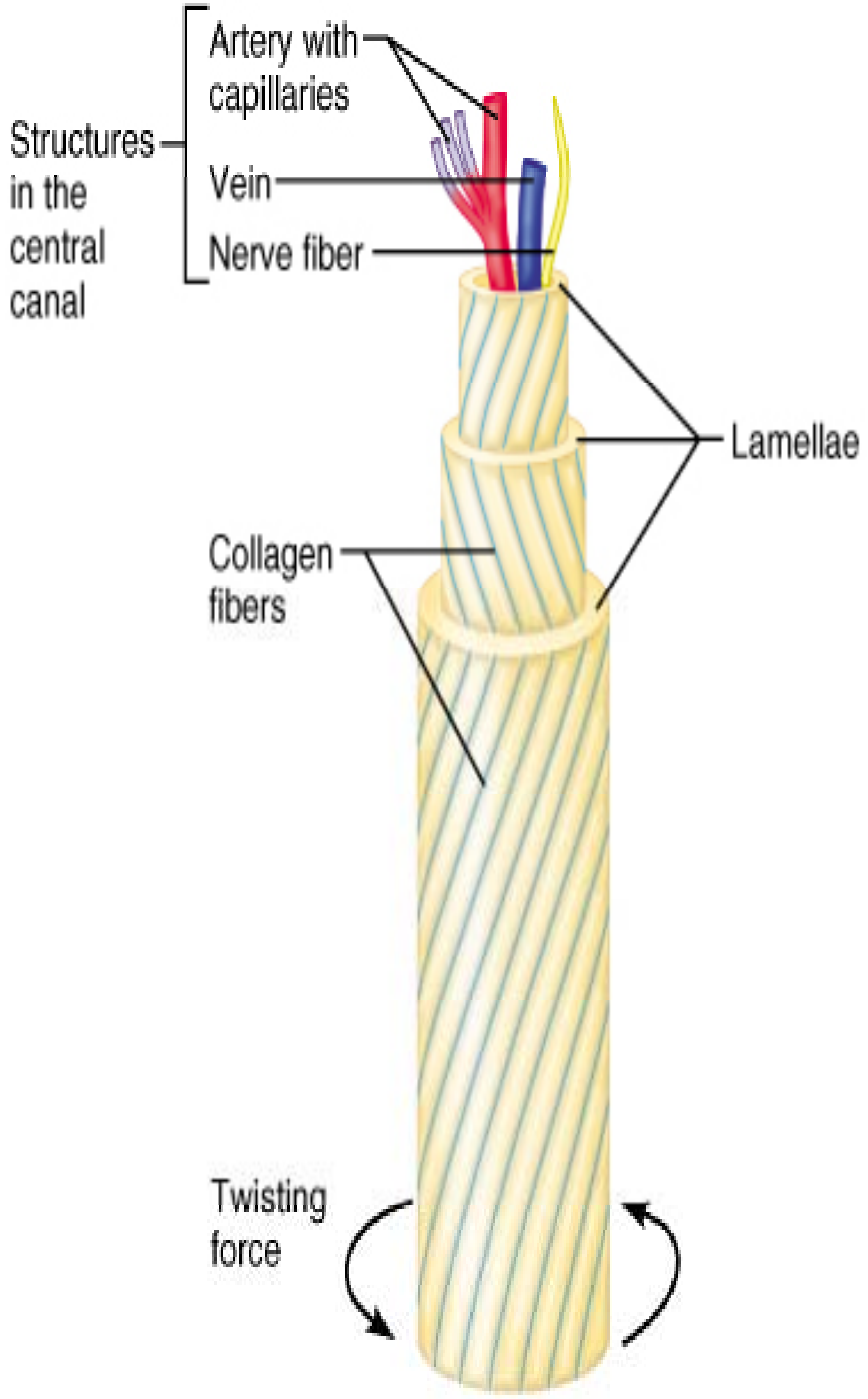

Running perpendicular to the haversian canals are Volkmann's canals. They connect the blood and nerve supply in the periosteum to those in the haversian canals and the medullary cavity.

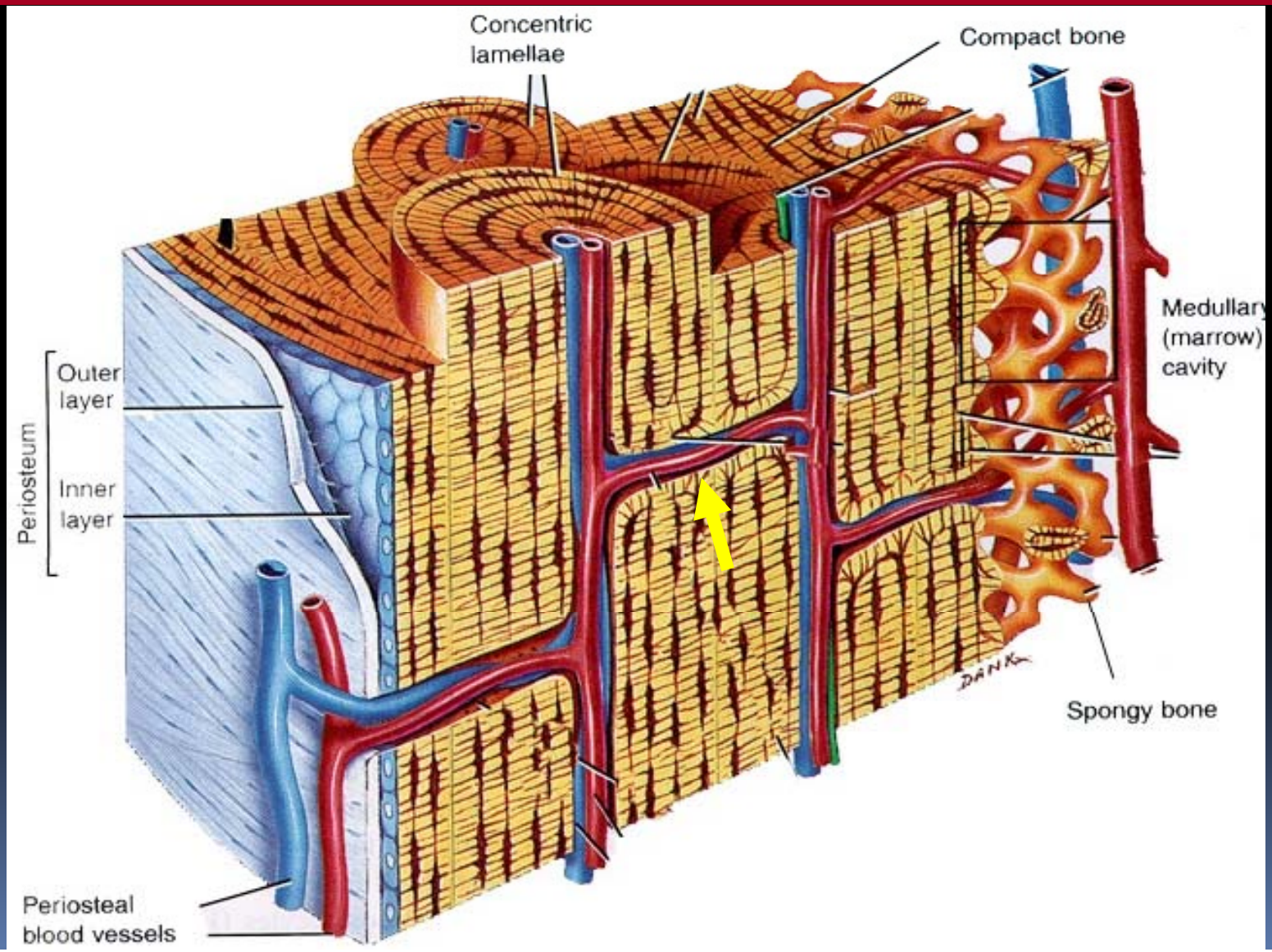

Osteons

- Lying in between intact osteons are incomplete lamellae called interstitial lamellae.
- These fill the gaps between osteons or are remnants of bone remodeling.

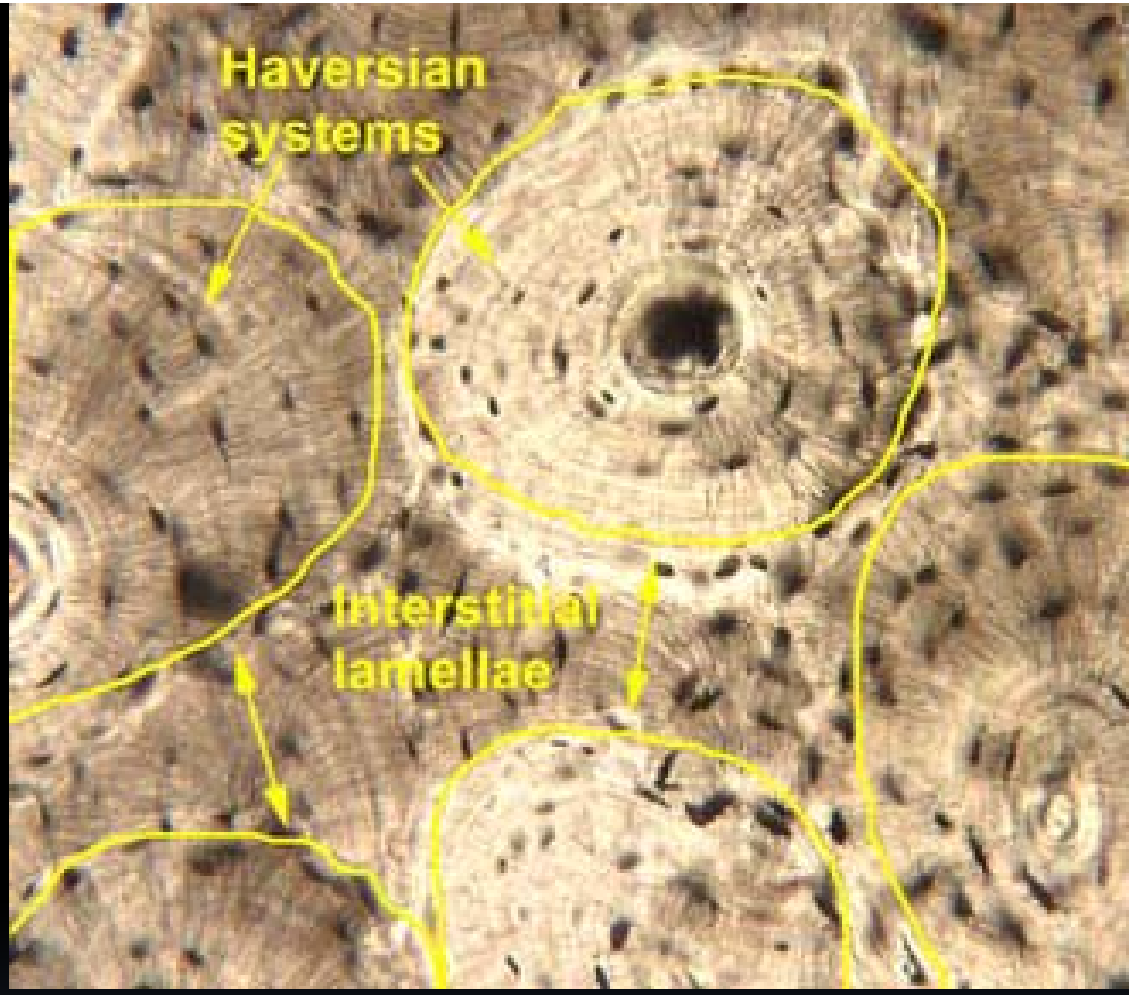

- There are also circumferential lamellae that extend around the circumference of the shaft. There are inner circumferential lamellae surrounding the endosteum and outer circumferential lamellae just inside the periosteum.

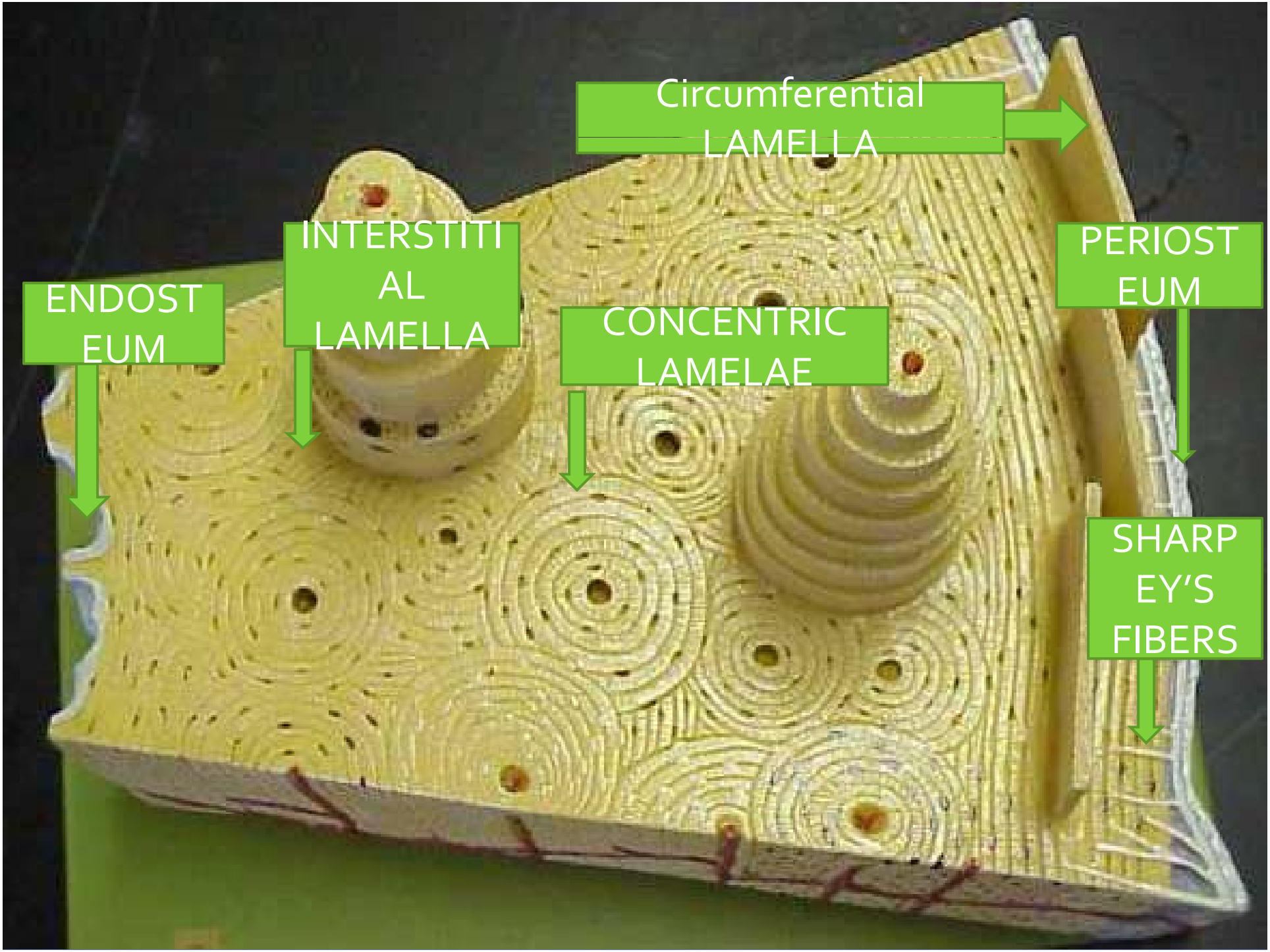
Circumferential LAMELLA
INTERSTITIAL LAMELLA
ENDOSTEUM
CONCENTRIC LAMELAE
PERIOSTEUM
SHARPEY'S FIBERS

Ground Bone - There is no organic matter in this slice (grinding) of compact bone. The Lacunae, the Canaliculi, and the Haversian Canal look black because of the bending of the light rays passing through the ground bone. The lamellae form concentric rings around the central Haversian Canal. Remember that the collagen in living bone spirals one way in one lamella and the other in the adjacent lamella adding strength to compact bone





Interstitial Lamellae are left over pieces of old Haversian systems.

The circumferential lamellae are of two types, inner and outer circumferential lamellae, neither of which can be seen in this section.

The inner circumferential lamellae, deposited by the endosteum, encircle the narrow cavity, while the outer circumferential lamellae are laid down around the outside of the bone by the periosteum.

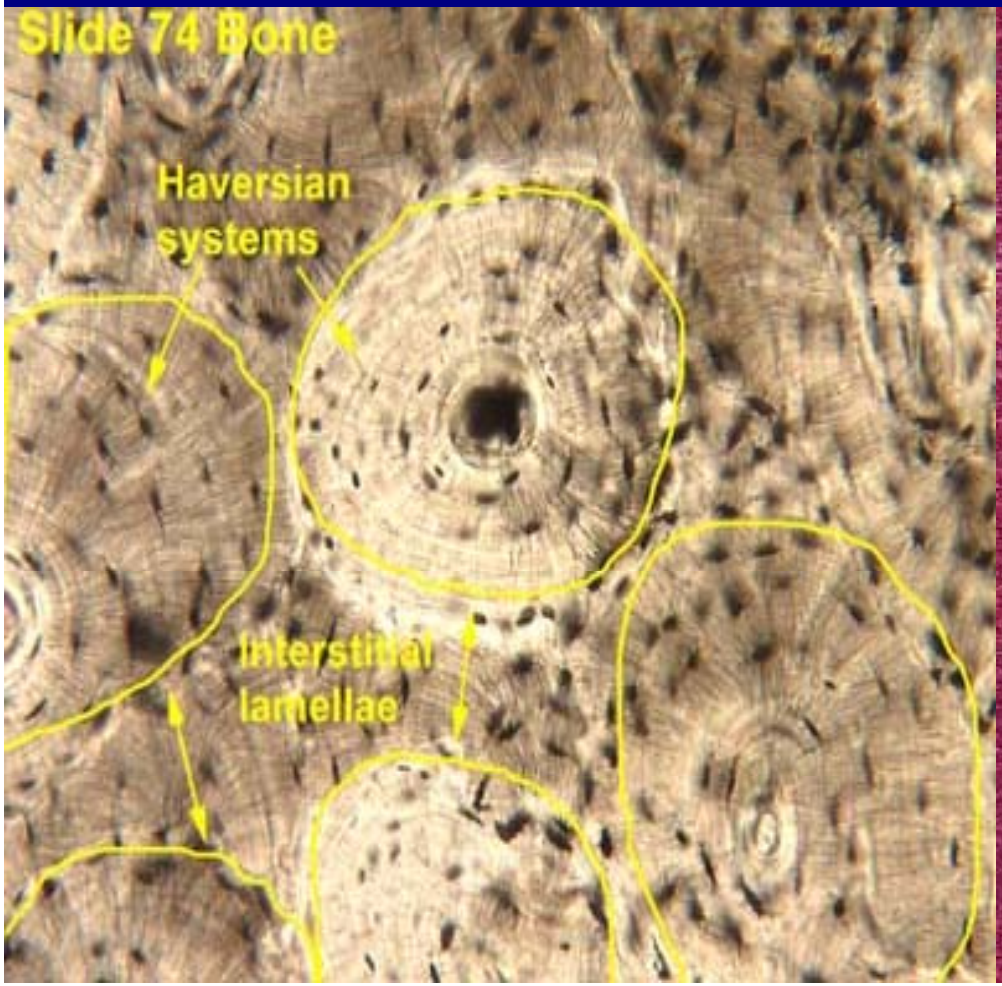

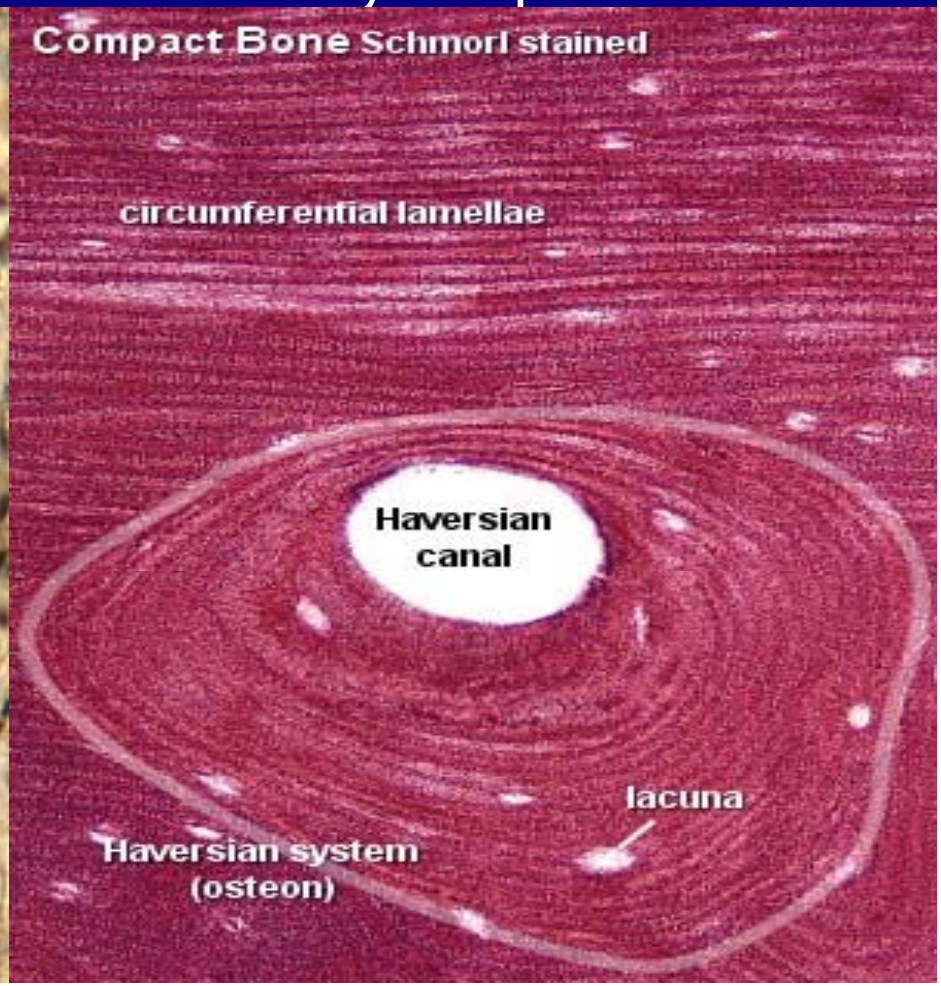

Chemical Composition of Bone: Organic

- Osteoid – unmineralized bone matrix composed of proteoglycans, glycoproteins, and collagen

•Osteoid makes up about 50% of bone volume and 40% of bone weight.

• It is composed of fibers and ground substance.

•The predominant fiber-type is Type I collagen and comprises 90% of the osteoid.

•The ground substance is mostly made up of chondroitin sulfate and osteocalcin

Chemical Composition of Bone: Inorganic

- Hydroxyapatites, or mineral salts
  - Sixty-five percent of bone by mass
  - Mainly calcium phosphates
  - Responsible for bone hardness and its resistance to compression

Bone Structure

- Bones are organs. Thus, they're composed of multiple tissue types. Bones are composed of:
  - Bone tissue (a.k.a. osseous tissue).
  - Fibrous connective tissue.
  - Cartilage.
  - Vascular tissue.
  - Lymphatic tissue.
  - Adipose tissue.
  - Nervous tissue.

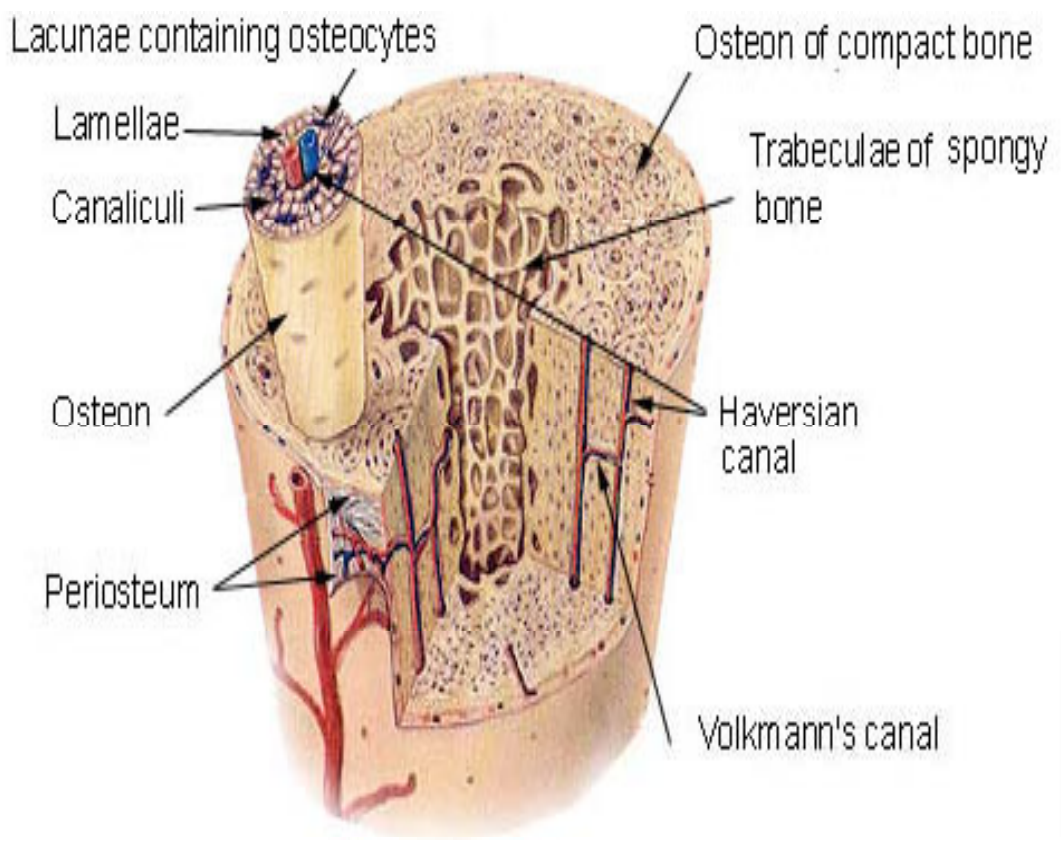

Bone membranes

- **Periosteum** - double layered membrane covering outer surface of bone
  - outer fibrous layer
  - inner osteogenic layer contains osteoblasts and osteoclasts
- **Endosteum** - lines trabeculae of spongy bone and internal structures
  - some connective tissue
  - osteoblasts and osteoclasts

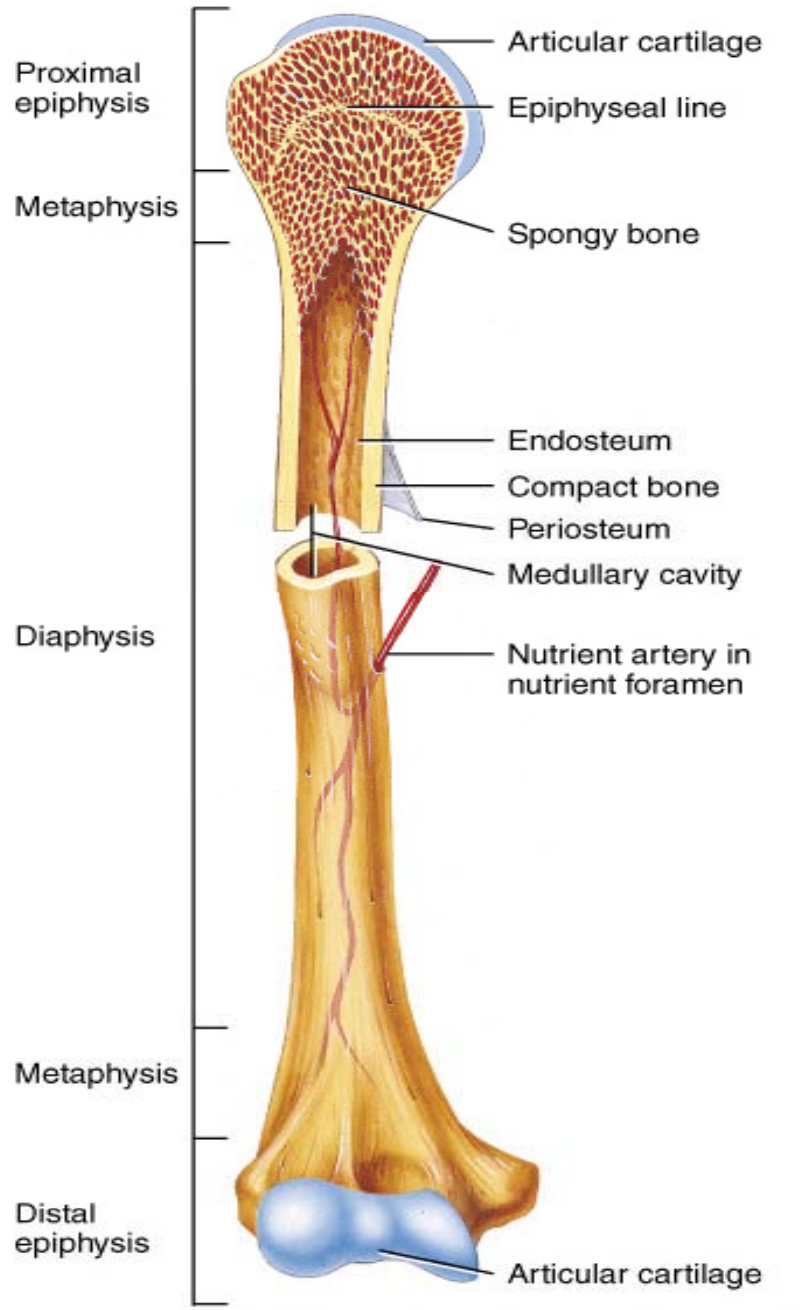

(a) Partially sectioned humerus (arm bone)

© John Wiley & Sons, Inc.

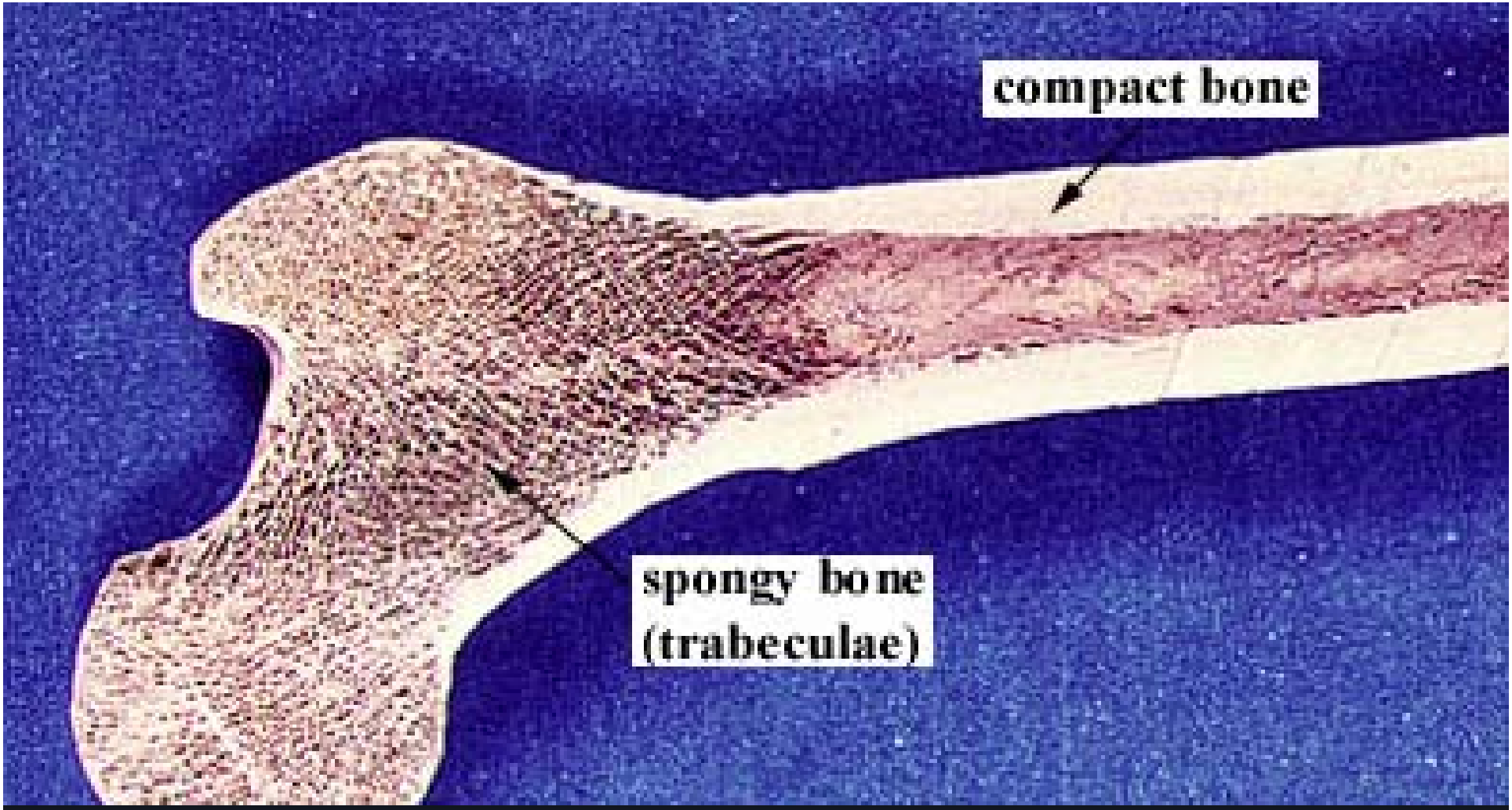

Note the gross differences between the spongy bone and the compact bone in the above photo.

Do you see the trabeculae?

<u>Sharpey's Fibers</u> =
direct extensions of dense irregular CT from periosteum into compact bone.
Functions to anchor tendon (with fibers penetrating periosteum to bone) to bone.
Formation by appositional bone growth around original attachment site.

A, Periodontal ligament fibers; **B**, Sharpey's fibers; **C**, Dentino-cementum junction; **D**, Cementoblasts; **E**, Acellular cementum

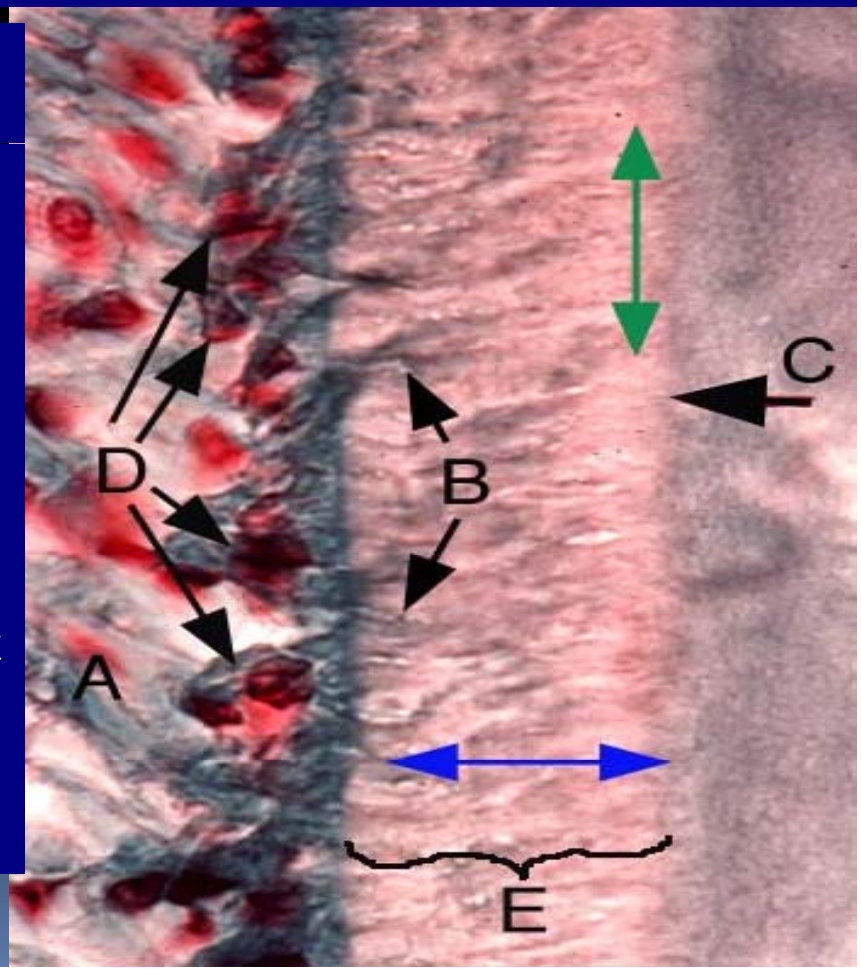

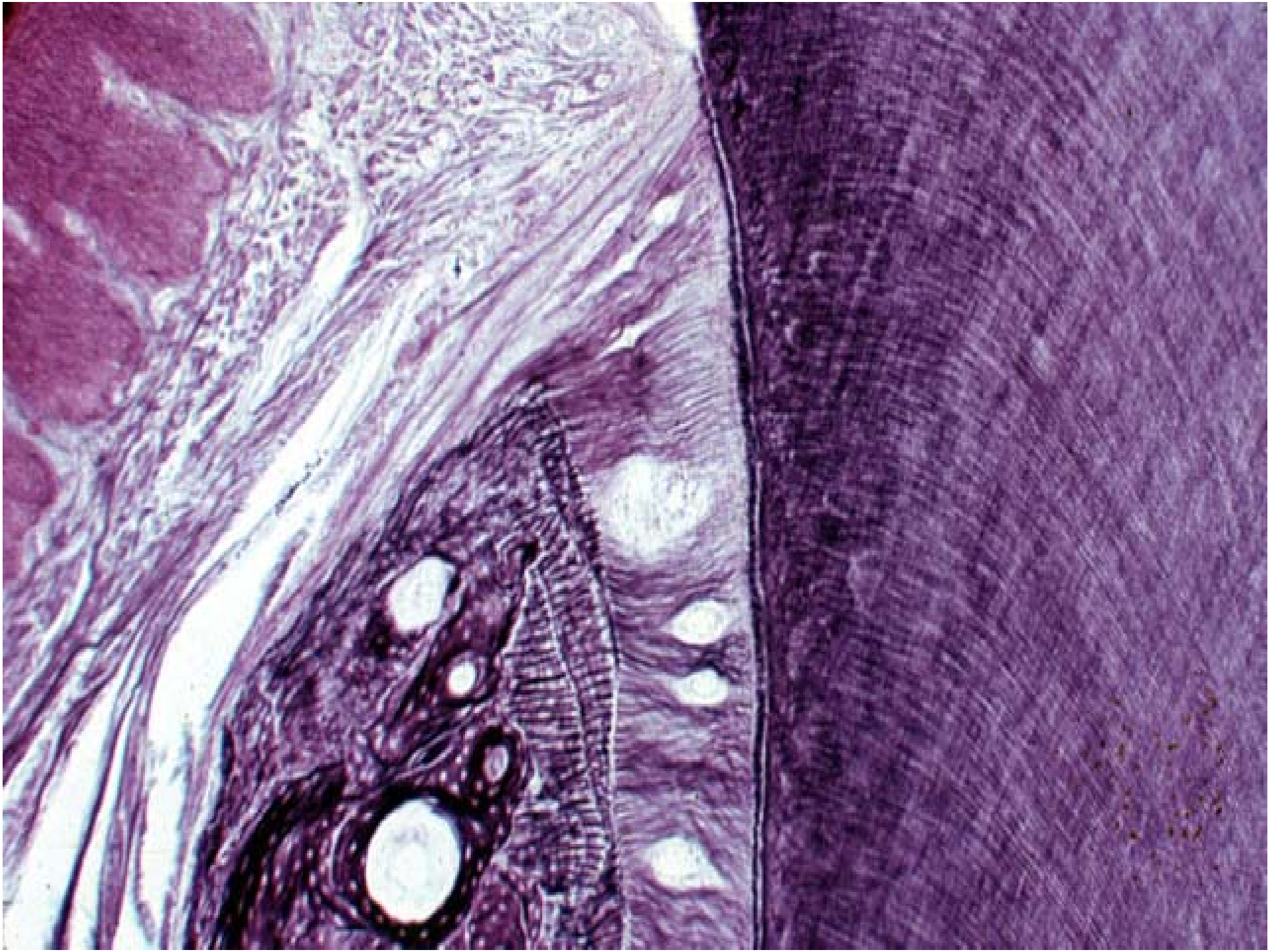

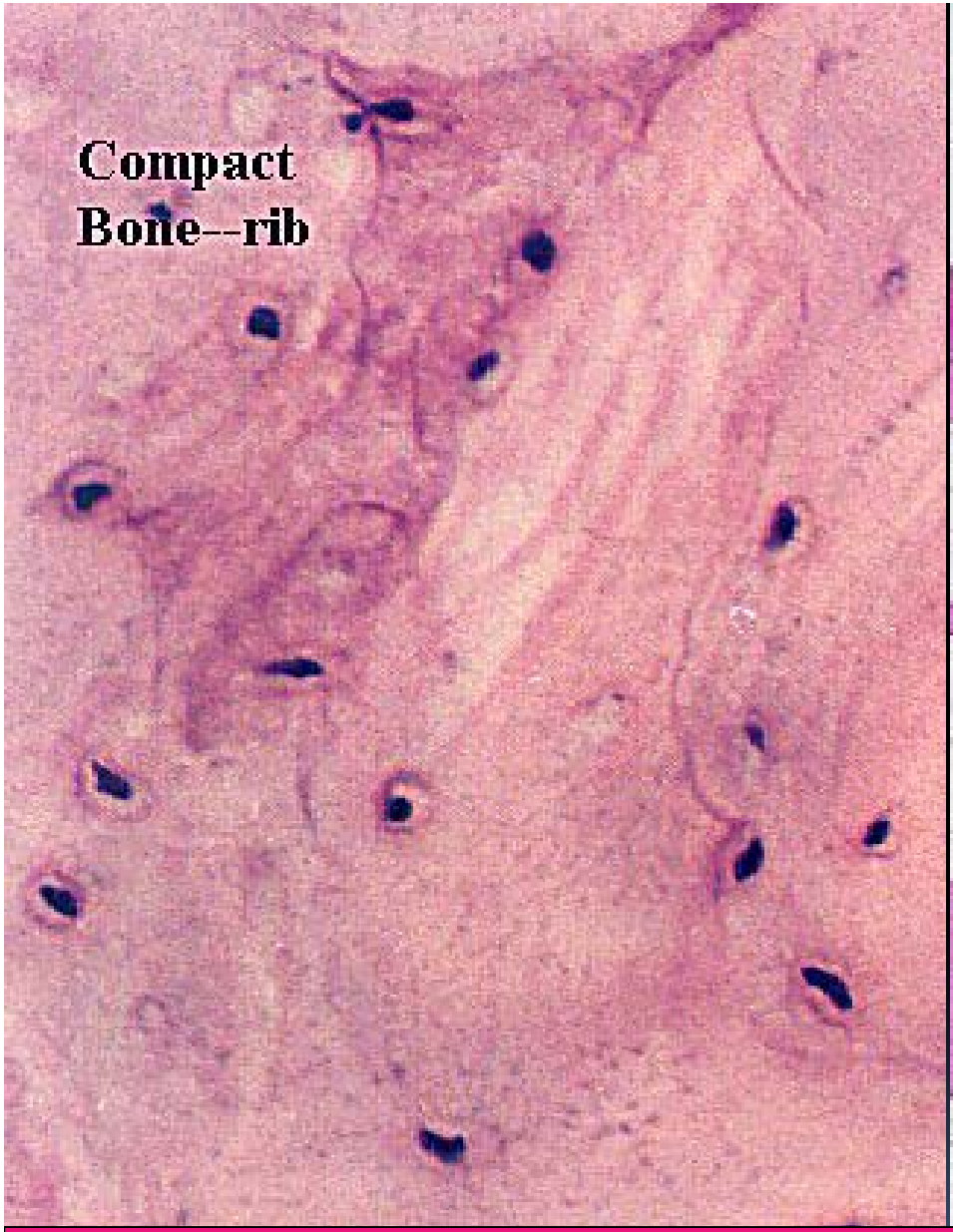

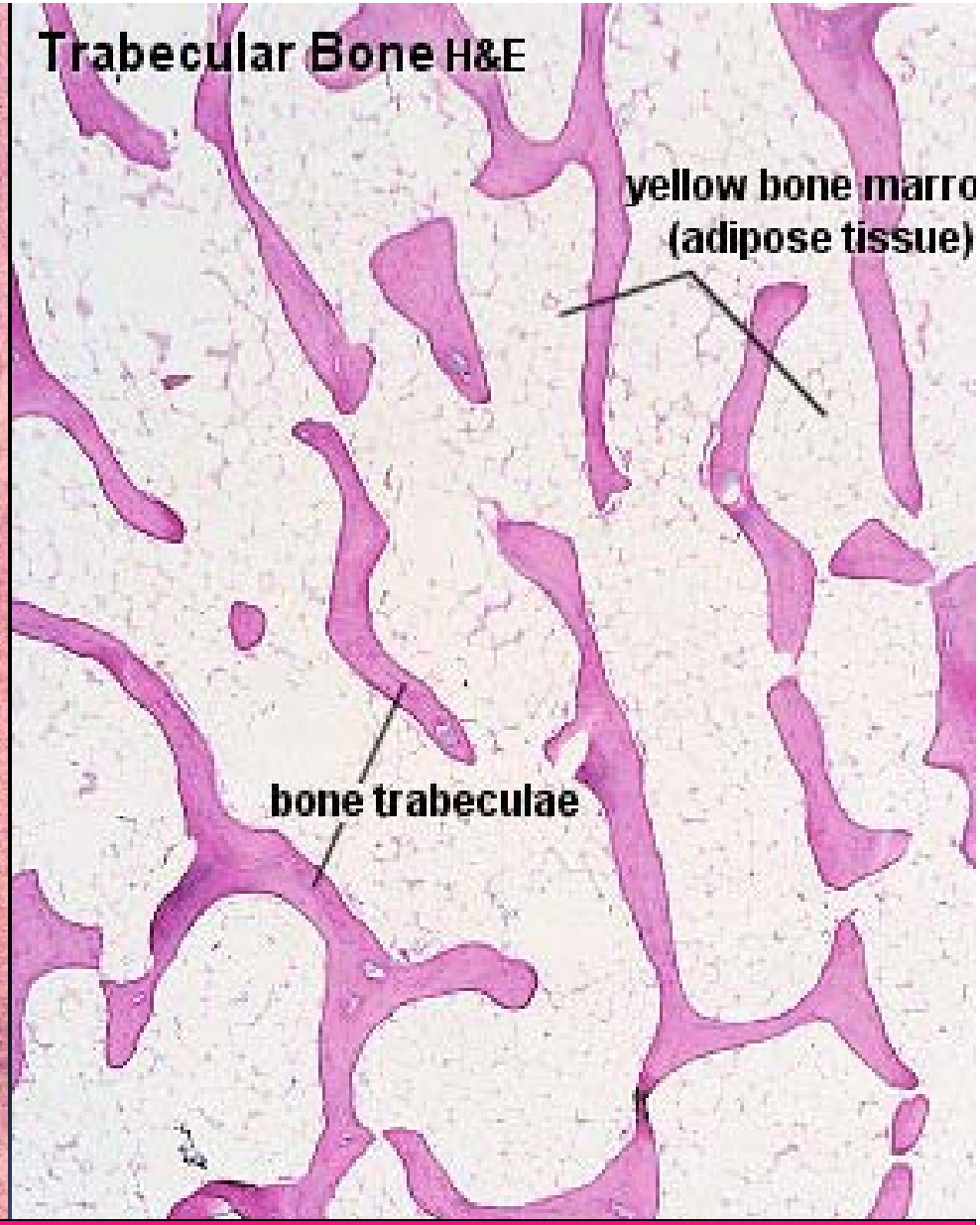

Compare compact and spongy bone as viewed with the light microscope

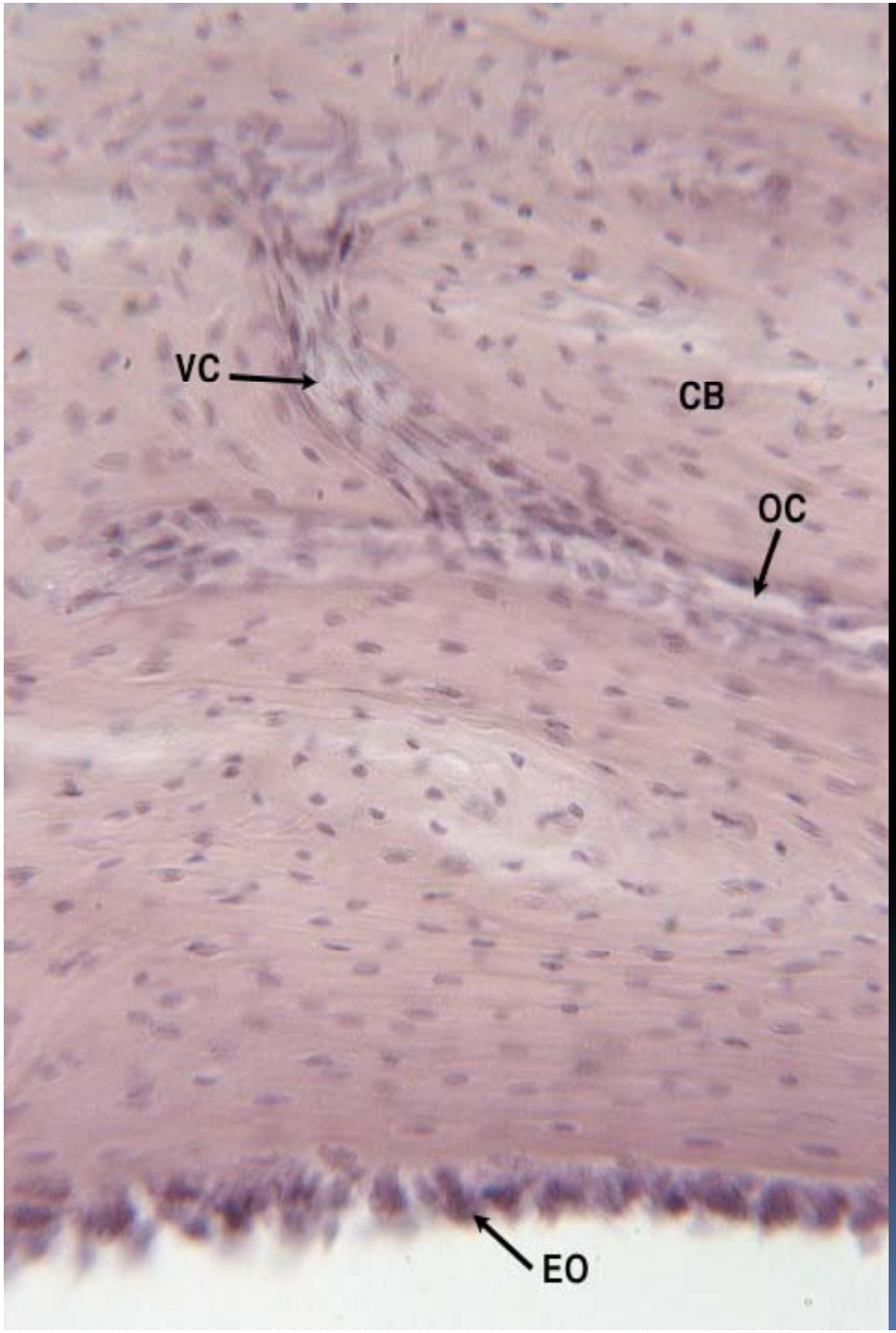

Endosteum

The thin layer of cells lining the medullary cavity of a bone.

ompact bone (CB) with longitudinal osteon canal (OC) and lateral Volkmann's canal (VC).

The inner surface of this bony surface is covered by a layer of endosteum (EO) - osteoprogenitor cells.

Histology of bone

- Matrix contains
  - mineral salts which confer hardness:
    - primarily hydroxyapatite (calcium and phosphate)
    - some calcium carbonate.
  - framework of collagen fibres
    - confers tensile strength

Bone Structure

- Bone Matrix:
  - Consists of organic and inorganic components.
  - 1/3 organic and 2/3 inorganic by weight.
    - Organic component consists of several materials that are secreted by the osteoblasts:
      - Collagen fibers and other organic materials
        - These (particularly the collagen) provide the bone with resilience and the ability to resist stretching and twisting.

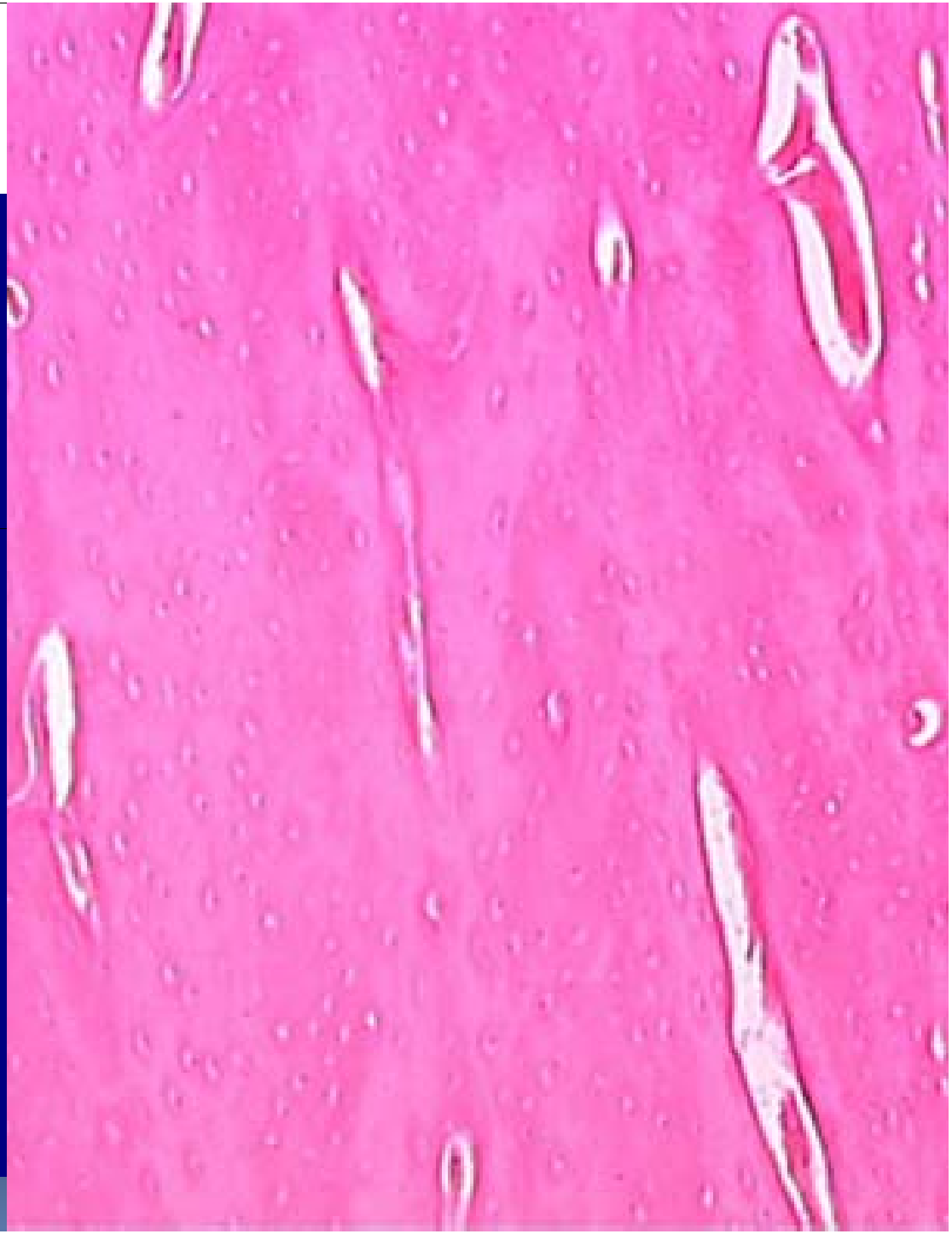



Three-dimensional array of collagen molecules. The rod-shaped molecules lie in a staggered arrangement which acts as a template for bone mineralization. Bone mineral is laid down in the gaps.

- Inorganic component of bone matrix
  - Consists mainly of 2 salts: **calcium phosphate and calcium hydroxide**. These 2 salts interact to form a compound called hydroxyapatite.
  - Bone also contains smaller amounts of magnesium, fluoride, and sodium.
  - These minerals give bone its characteristic hardness and the ability to resist compression.

Note collagen fibers in longitudinal & cross section and how they occupy space btwn the black bone cells.

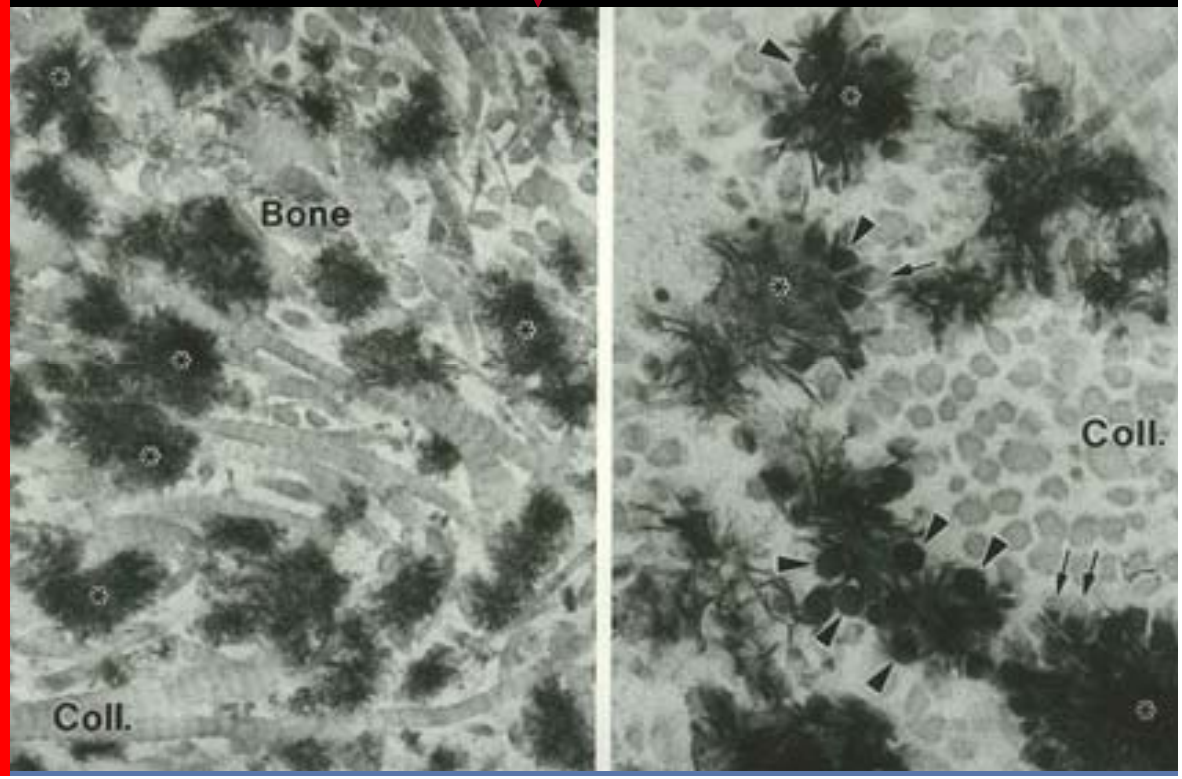

This bone:

a. Has been demineralized

b. Has had its organic component removed

Bone

- The cellular components of bone consist of
  - osteogenic precursor cells,
  - ***osteoblasts,***
  - ***osteoclasts,***
  - ***osteocytes***,
  - hematopoietic elements of bone marrow

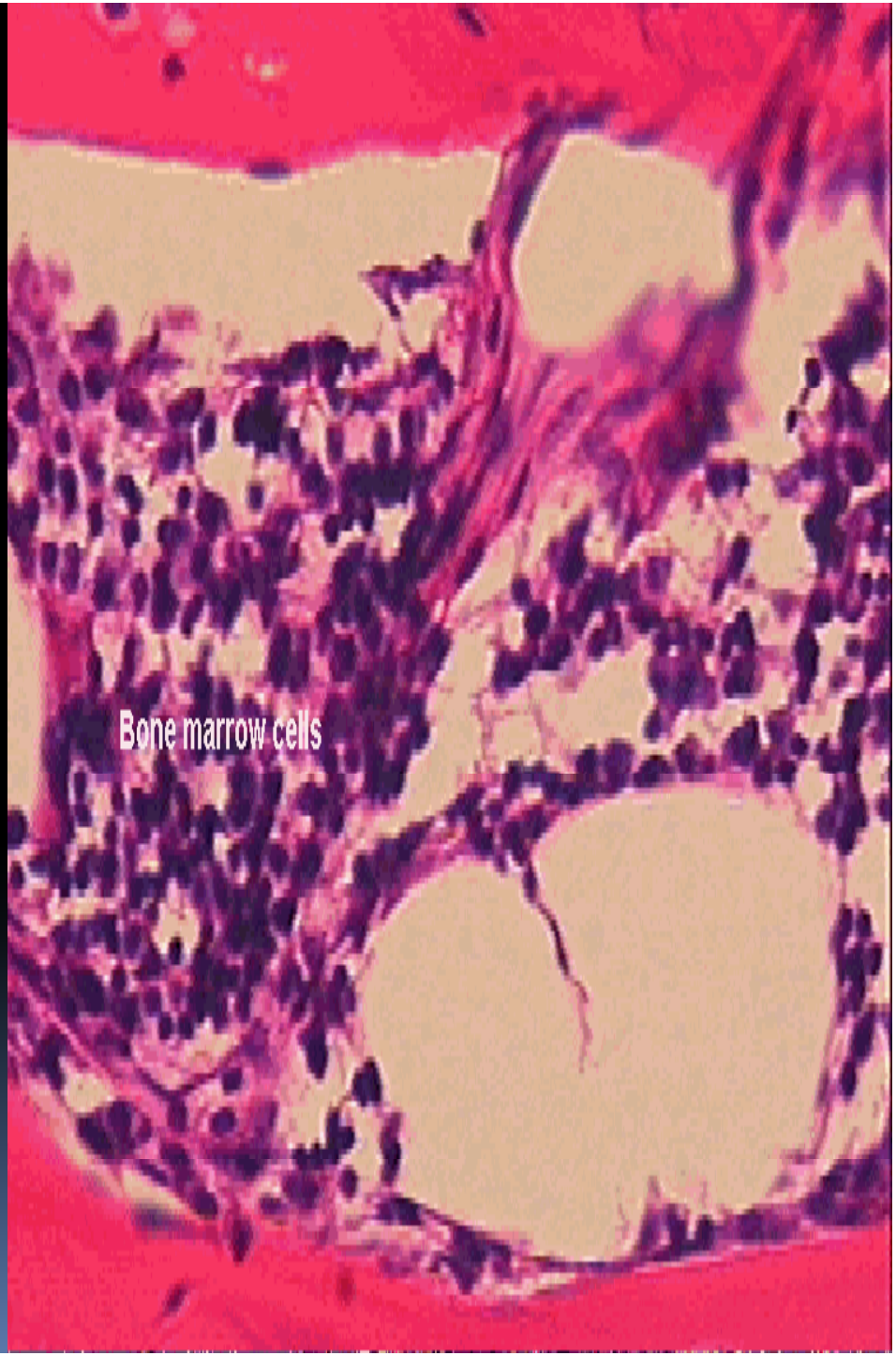

Histology of osseous tissue

- Widely separated cells surrounded by large amounts of matrix
- Four principal types of cells:
  - **osteogenic cells - develop into osteoblasts**
  - **osteoblasts - lay down bone matrix**
    - **High capacity for mitosis**
  - **osteocytes - maintain bone matrix**
  - **osteoclasts - break down bone matrix**

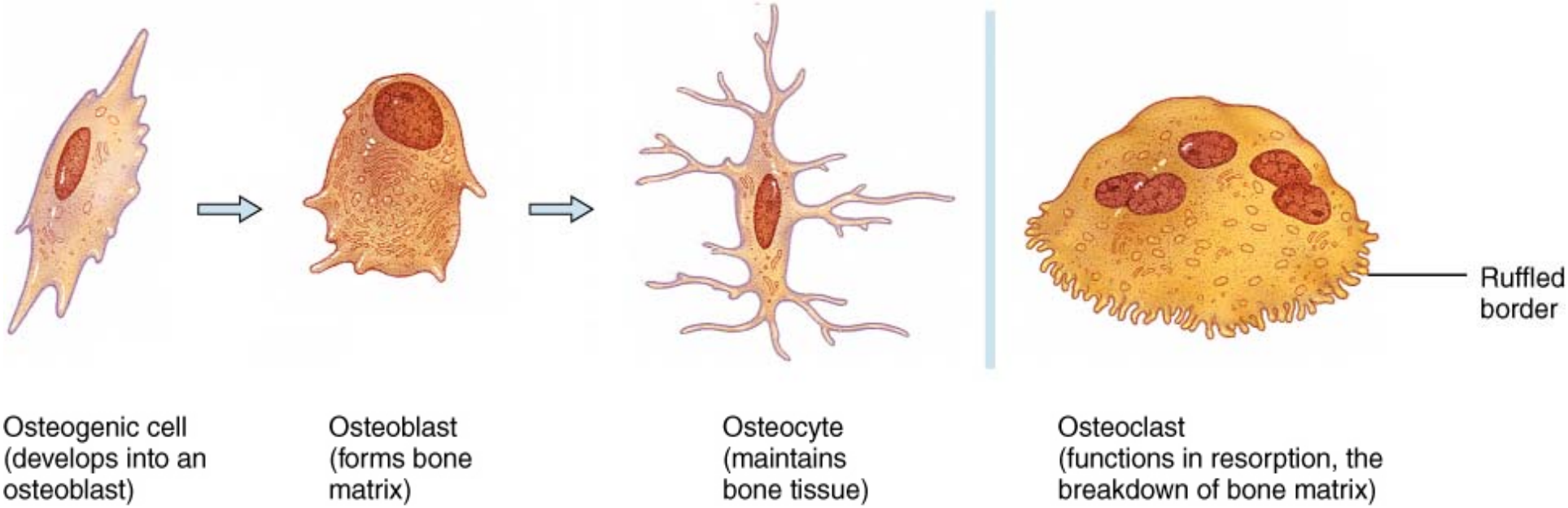

Bone Structure

- Bone tissue is a type of connective tissue, so it must consist of cells plus a significant amount of extracellular matrix.
- Bone cells:
  1. Osteoblasts
     - Bone-building cells.
     - Synthesize and secrete collagen fibers and other organic components of bone matrix.
     - Initiate the process of calcification.
     - Found in both the periosteum and the endosteum

The blue arrows indicate the osteoblasts. The yellow arrows indicate the bone matrix they've just secreted.

Bone Structure

2. Osteocytes
   - Mature bone cells.
   - Osteoblasts that have become trapped by the secretion of matrix.
   - No longer secrete matrix.
   - Responsible for maintaining the bone tissue.

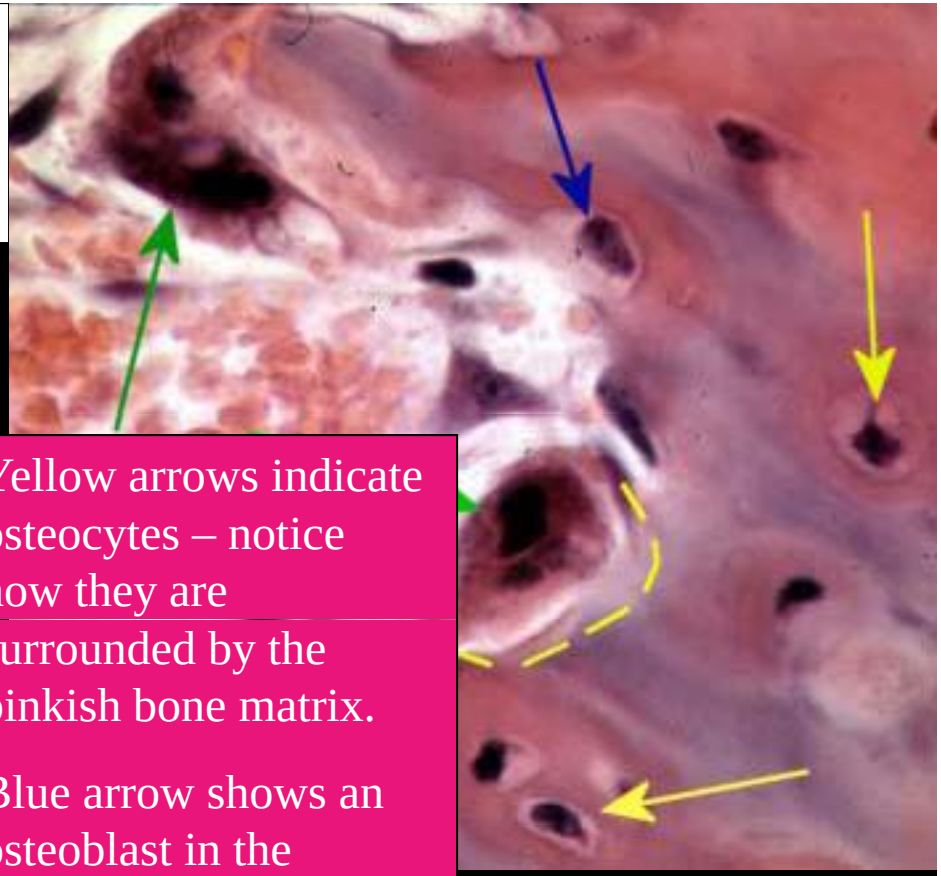

Yellow arrows indicate osteocytes – notice how they are surrounded by the pinkish bone matrix.

Blue arrow shows an osteoblast in the process of becoming an osteocyte.

On the right, notice how the osteocyte is “trapped” within the pink matrix

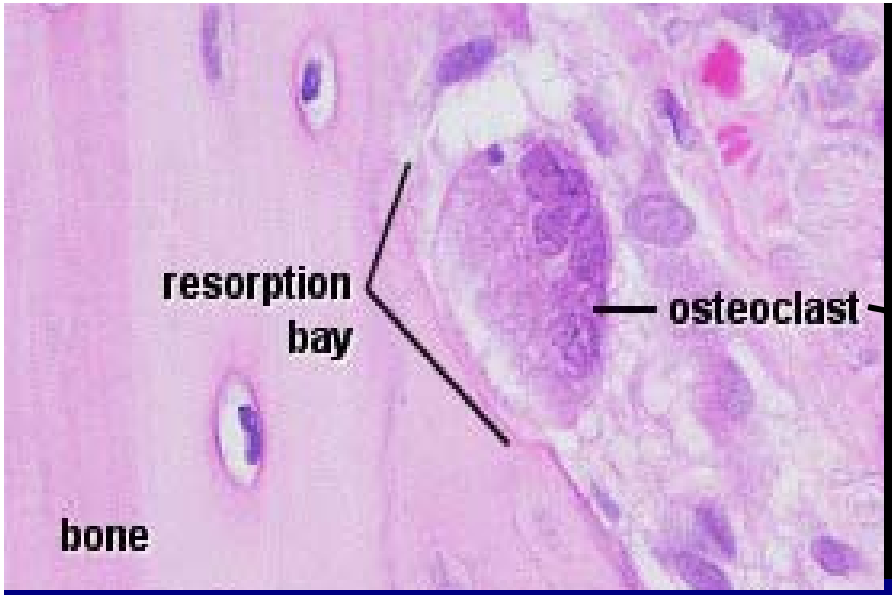



3. Osteoclasts

- Huge cells derived from the fusion of as many as 50 monocytes (a type of white blood cell).
- Cells that digest bone matrix – this process is called bone resorption and is part of normal bone growth, development, maintenance, and repair.
- Concentrated in the endosteum.
- On the side of the cell that faces the bone surface, the PM is deeply folded into a ruffled border. Here, the osteoclast secretes digestive enzymes (*how might this occur?*) to digest the bone matrix. It also pumps out hydrogen ions (*how might this occur?*) to create an acid environment that eats away at the matrix. *What advantage might a ruffled border confer?*
- Why do we want a cell that eats away at bone? (Hint: bone is a very dynamic tissue.)

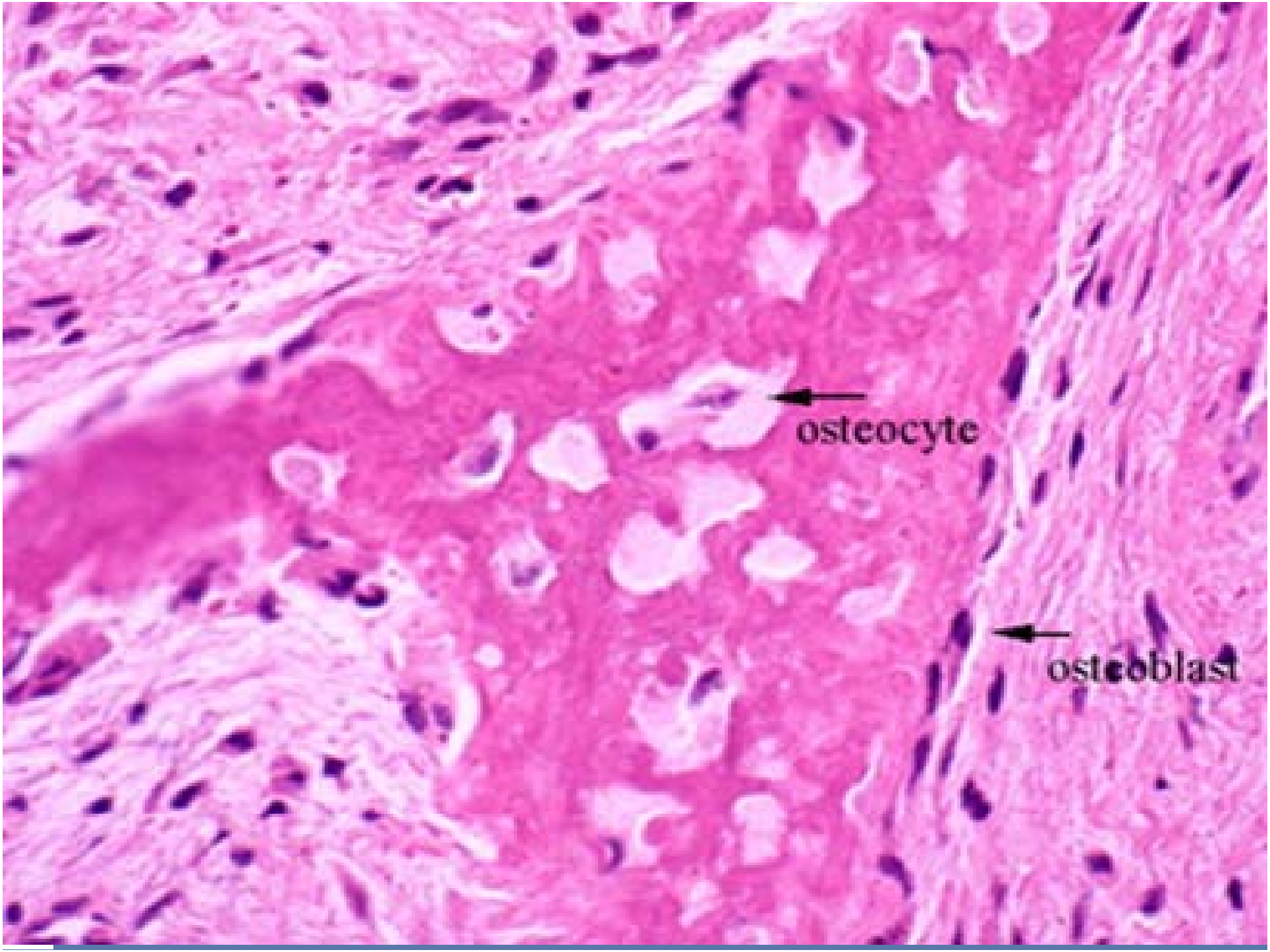
osteocyte
osteoblast

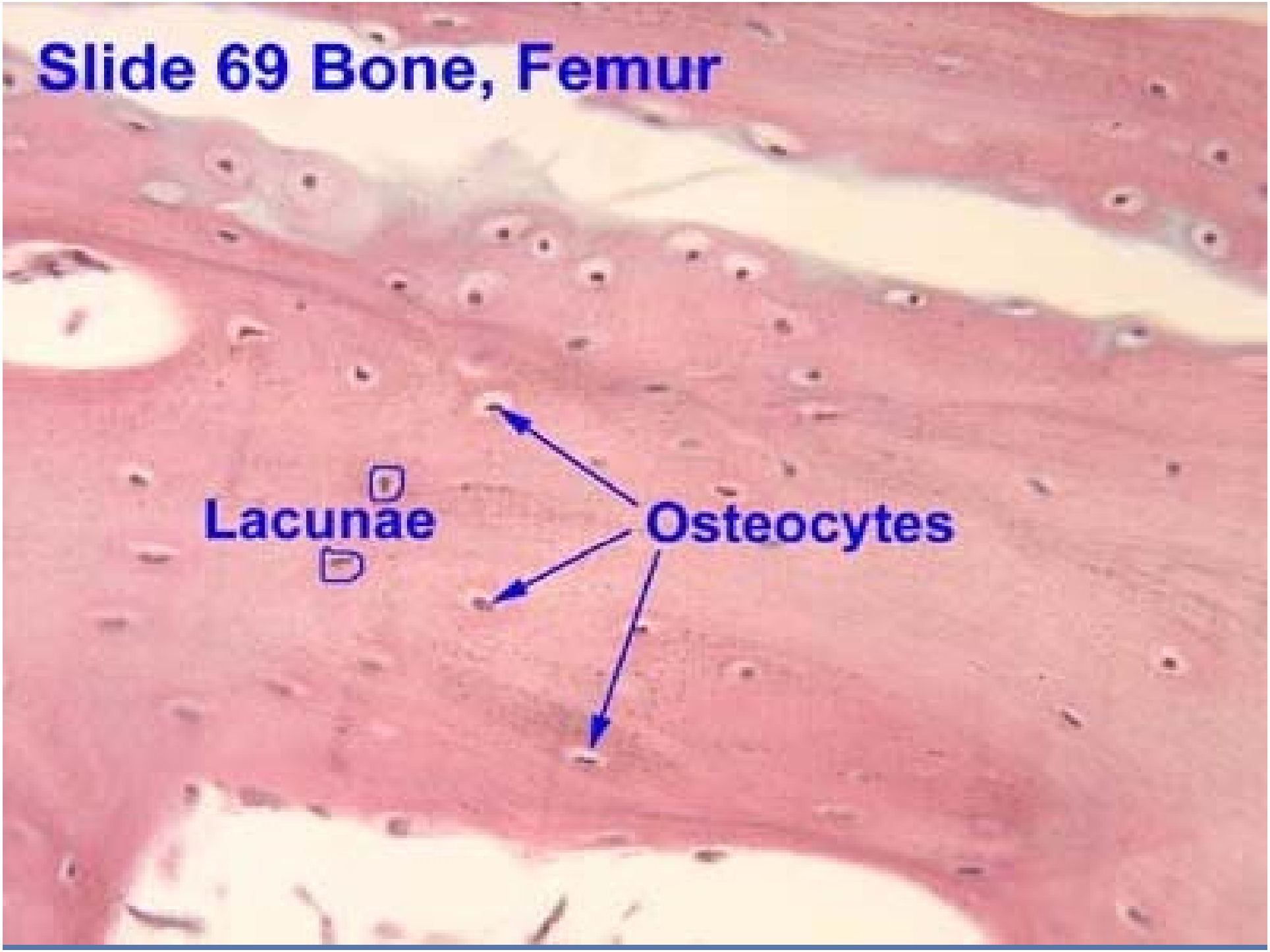
Slide 69 Bone, Femur
Lacunae
Osteocytes

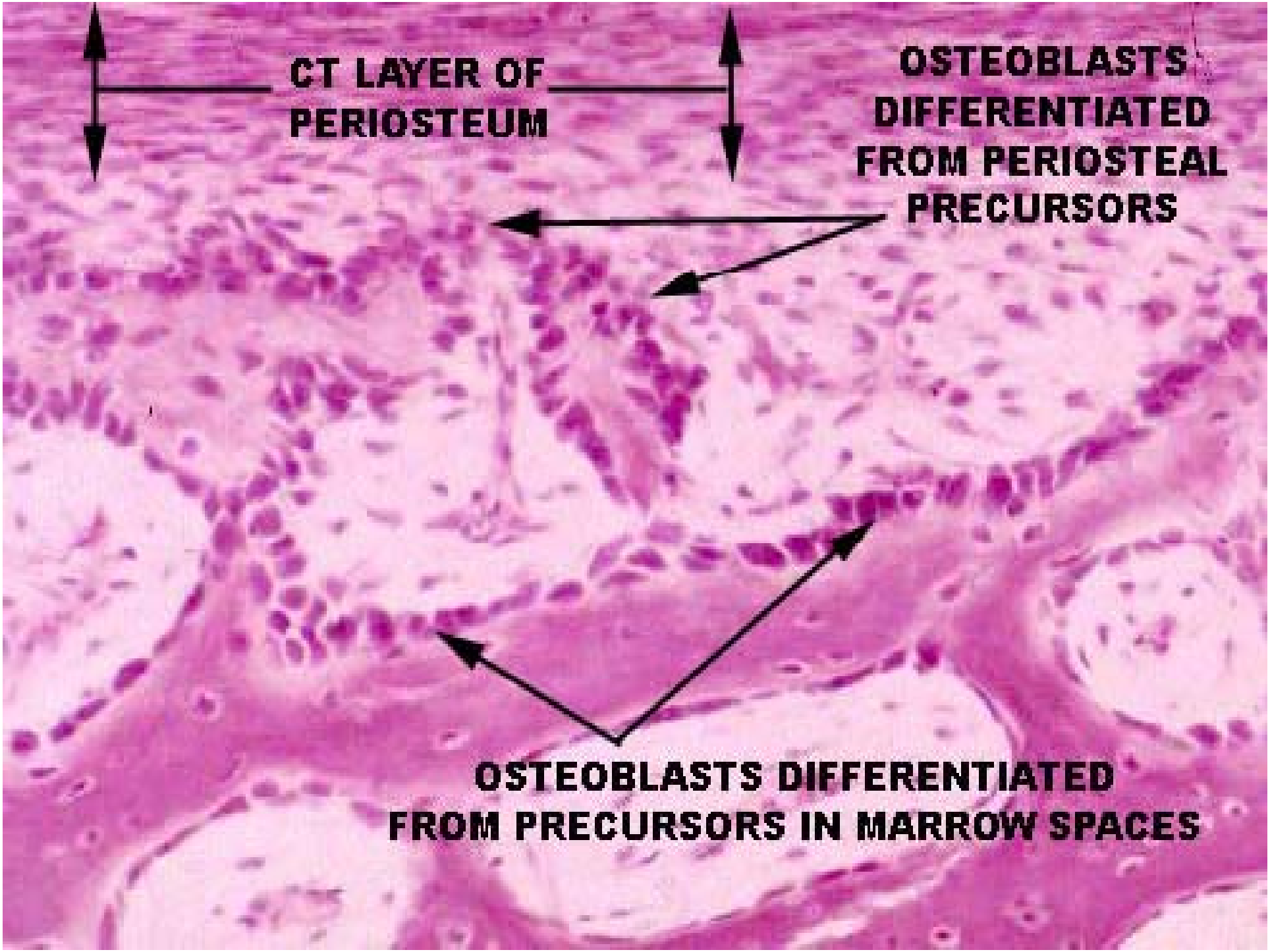
CT LAYER OF
PERIOSTEUM
OSTEOBLASTS
DIFFERENTIATED
FROM PERIOSTEAL
PRECURSORS
OSTEOBLASTS DIFFERENTIATED
FROM PRECURSORS IN MARROW SPACES

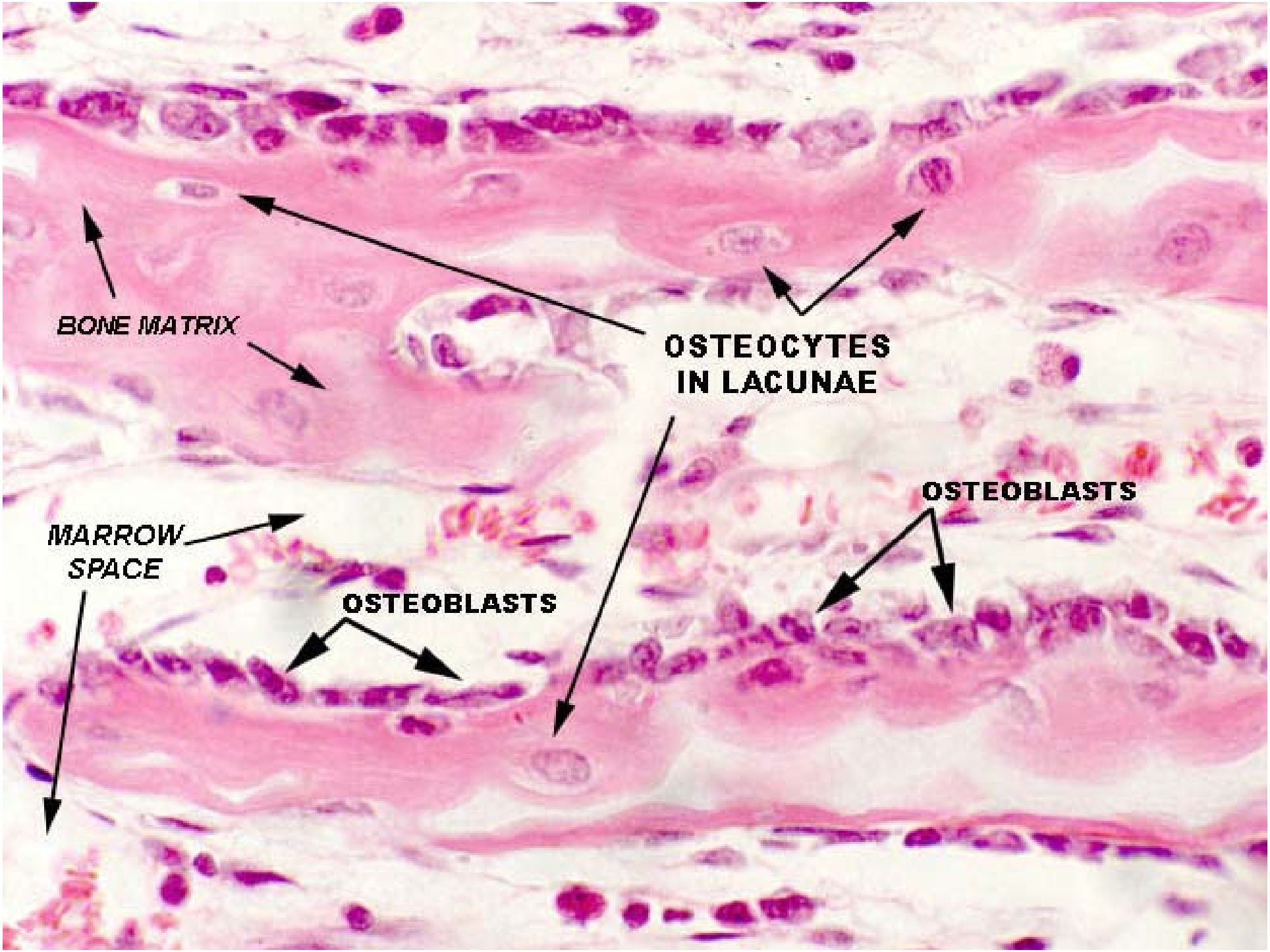
BONE MATRIX
OSTEOCYTES
IN LACUNAE
OSTEOBLASTS
MARROW
SPACE
OSTEOBLASTS

Osteoclast

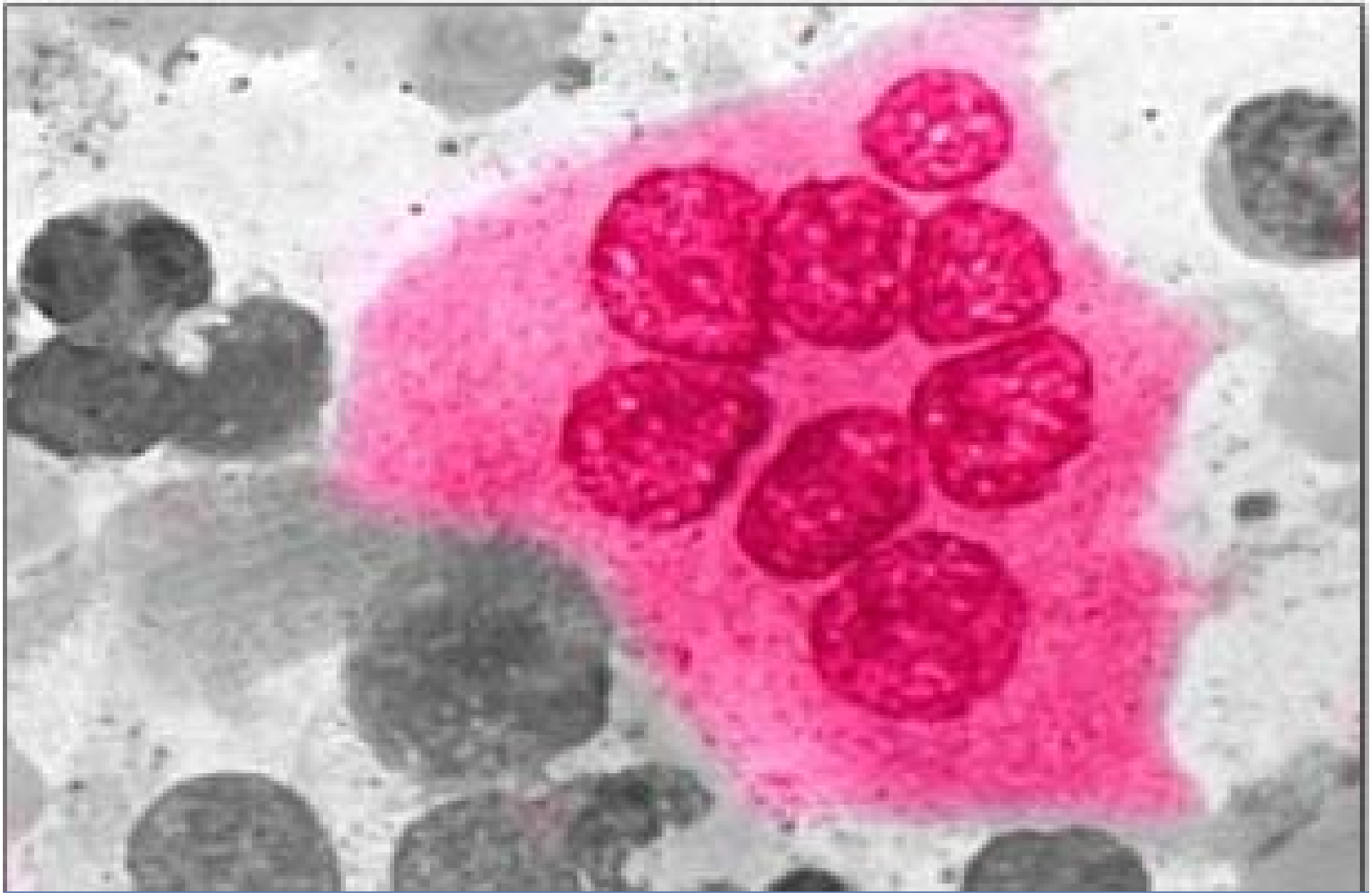

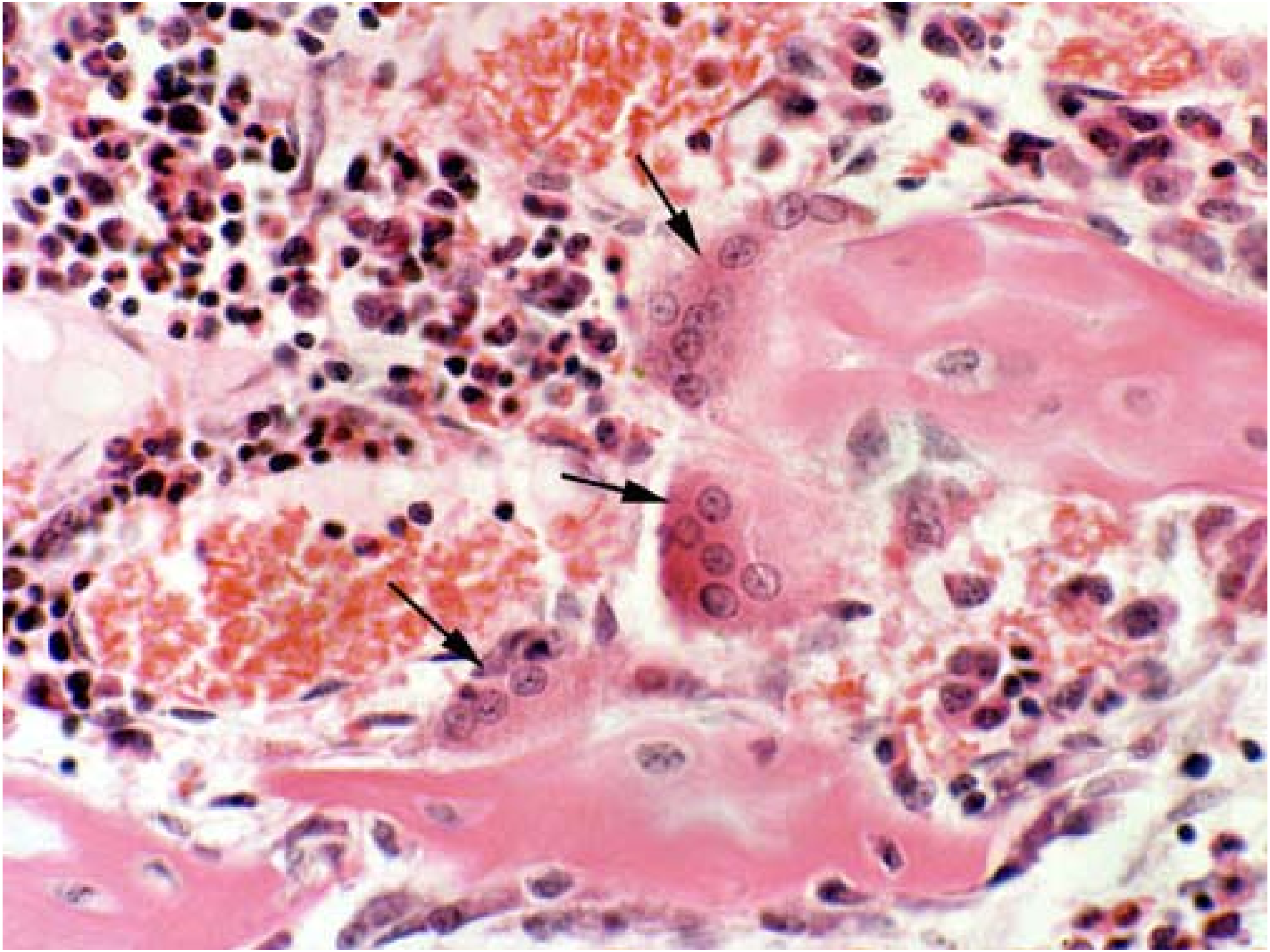

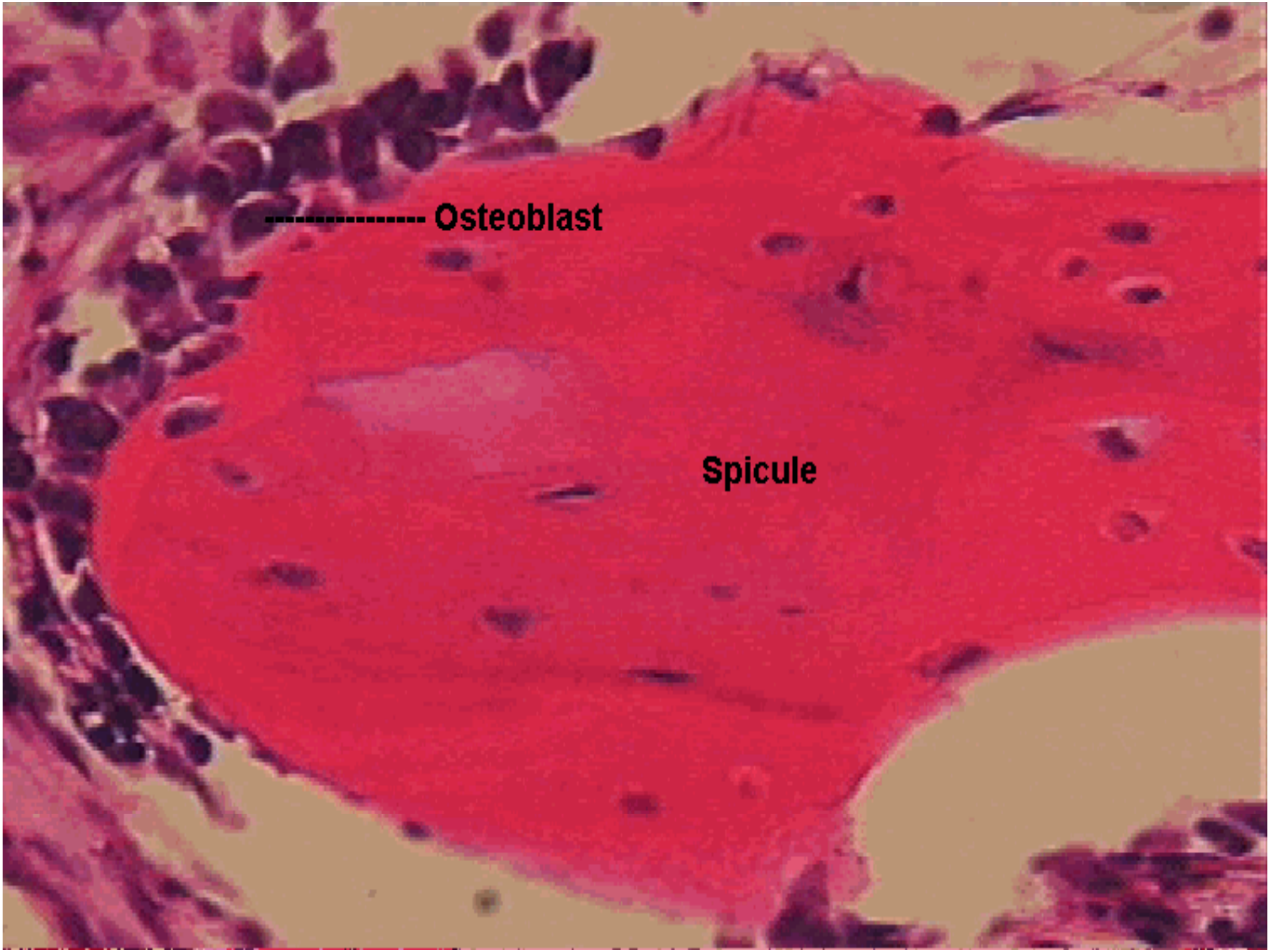
Osteoblast
Spicule

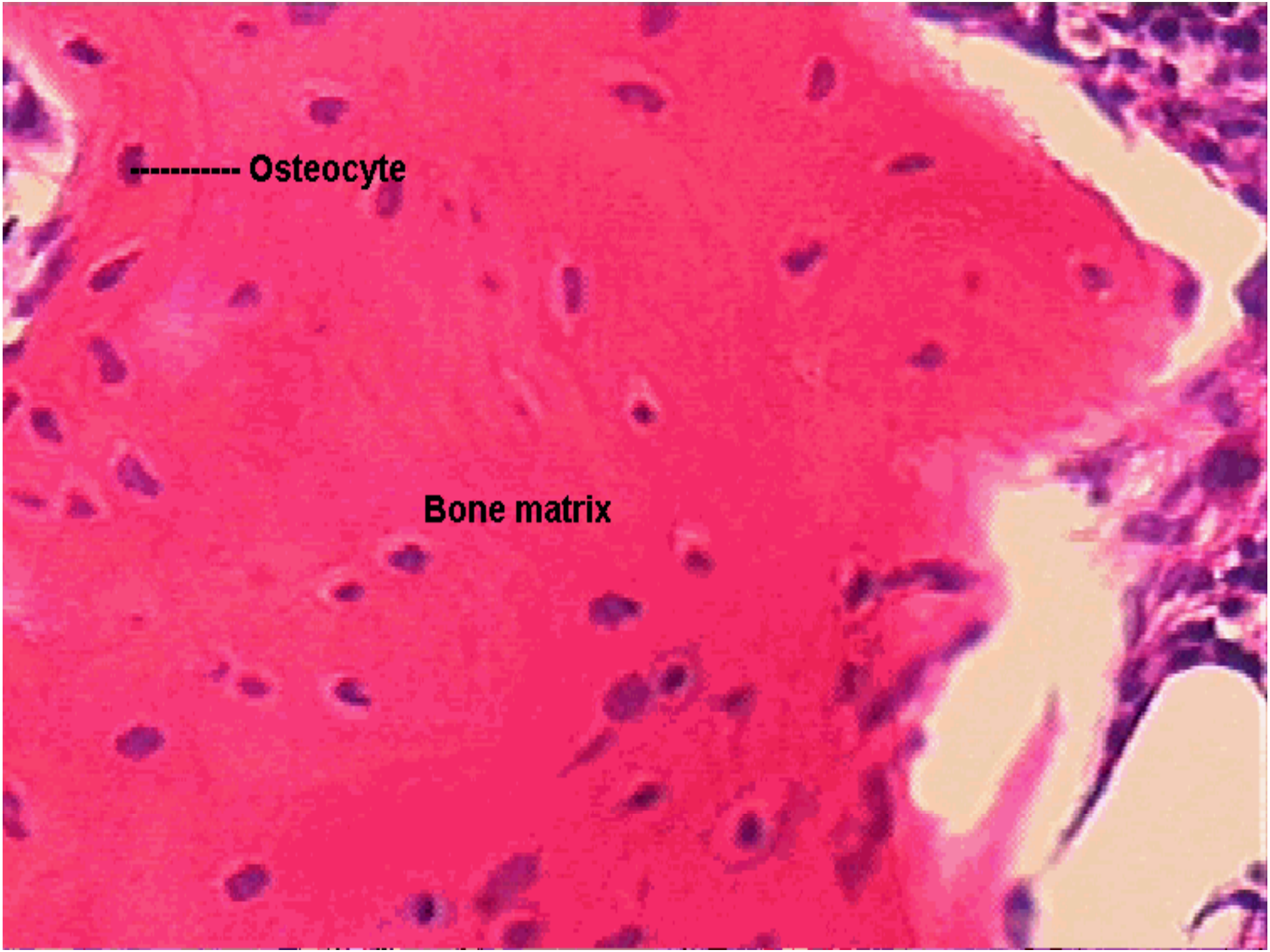
---------- Osteocyte
Bone matrix

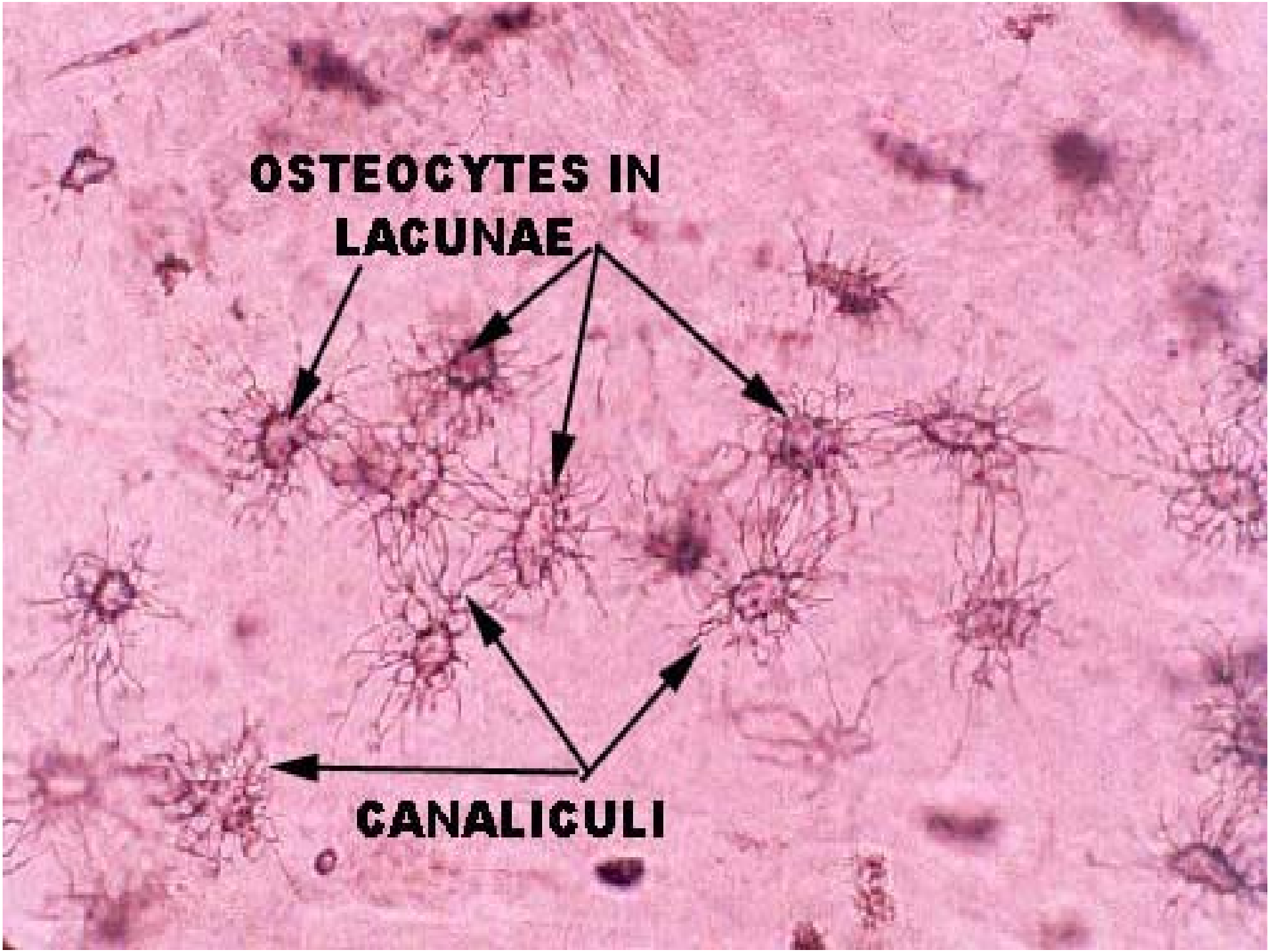
OSTEOCYTES IN
LACUNAE
CANALICULI

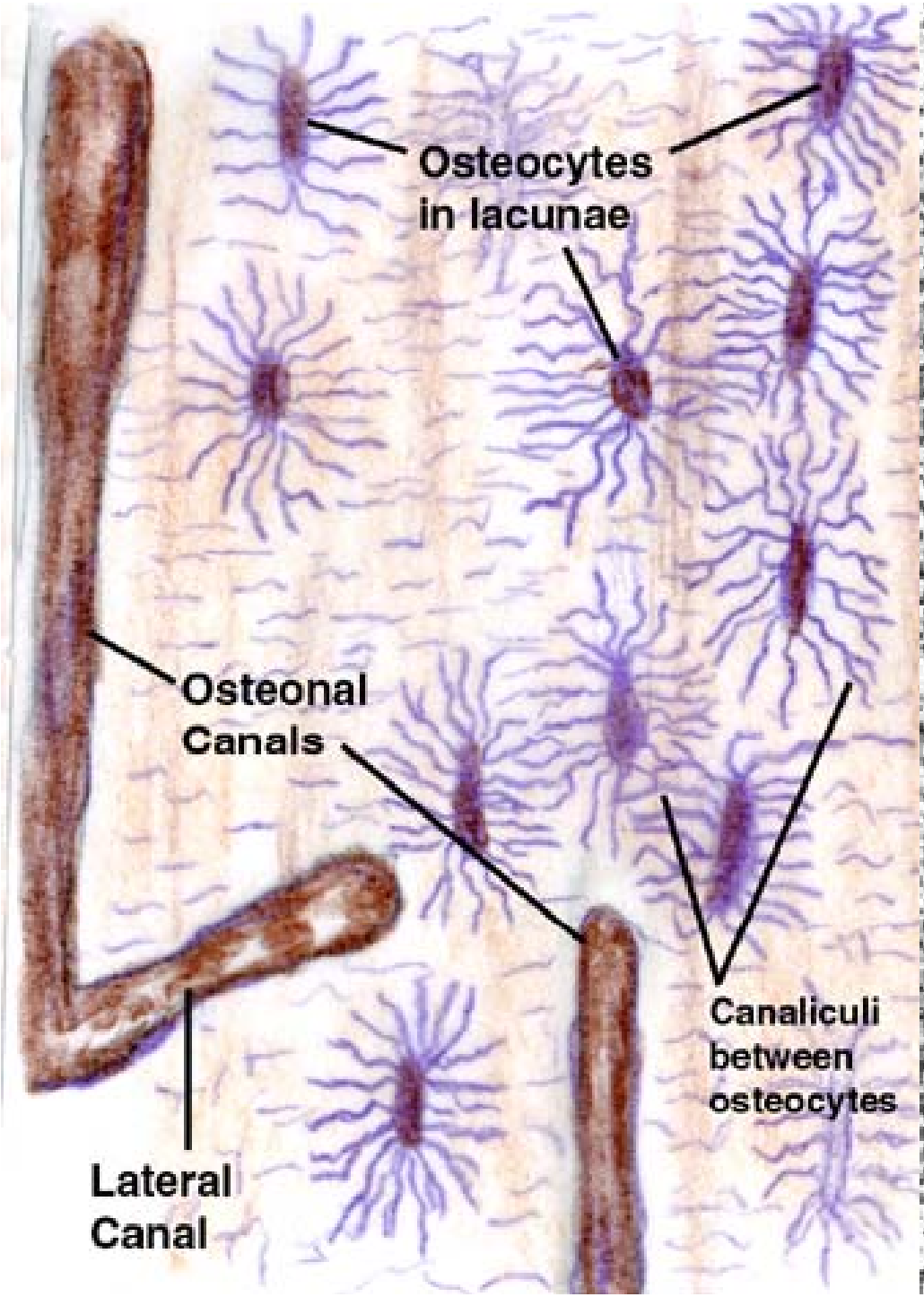
Osteocytes
in lacunae
Osteonal
Canals
Canaliculi
between
osteocytes
Lateral
Canal

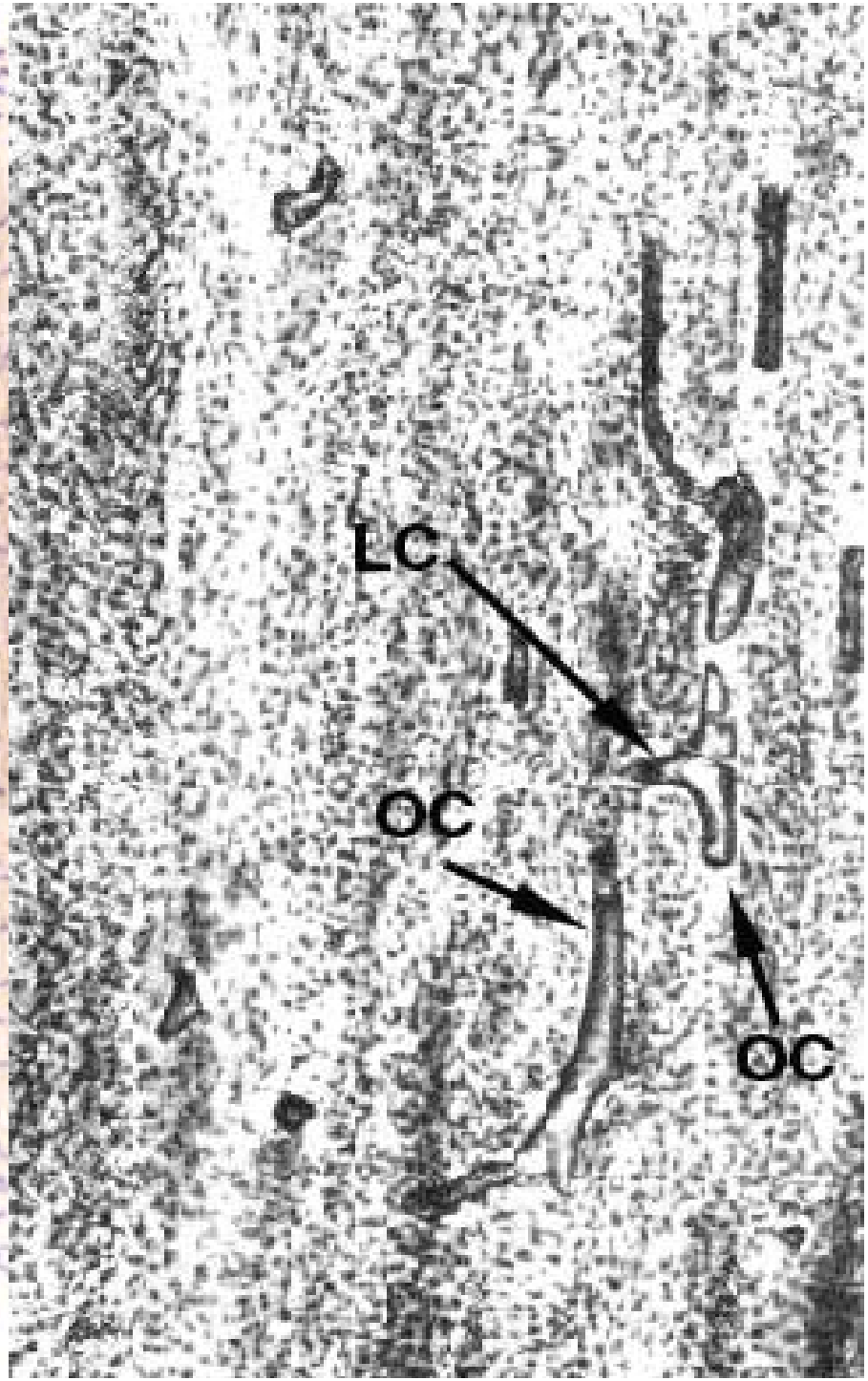
LC
OC
OC

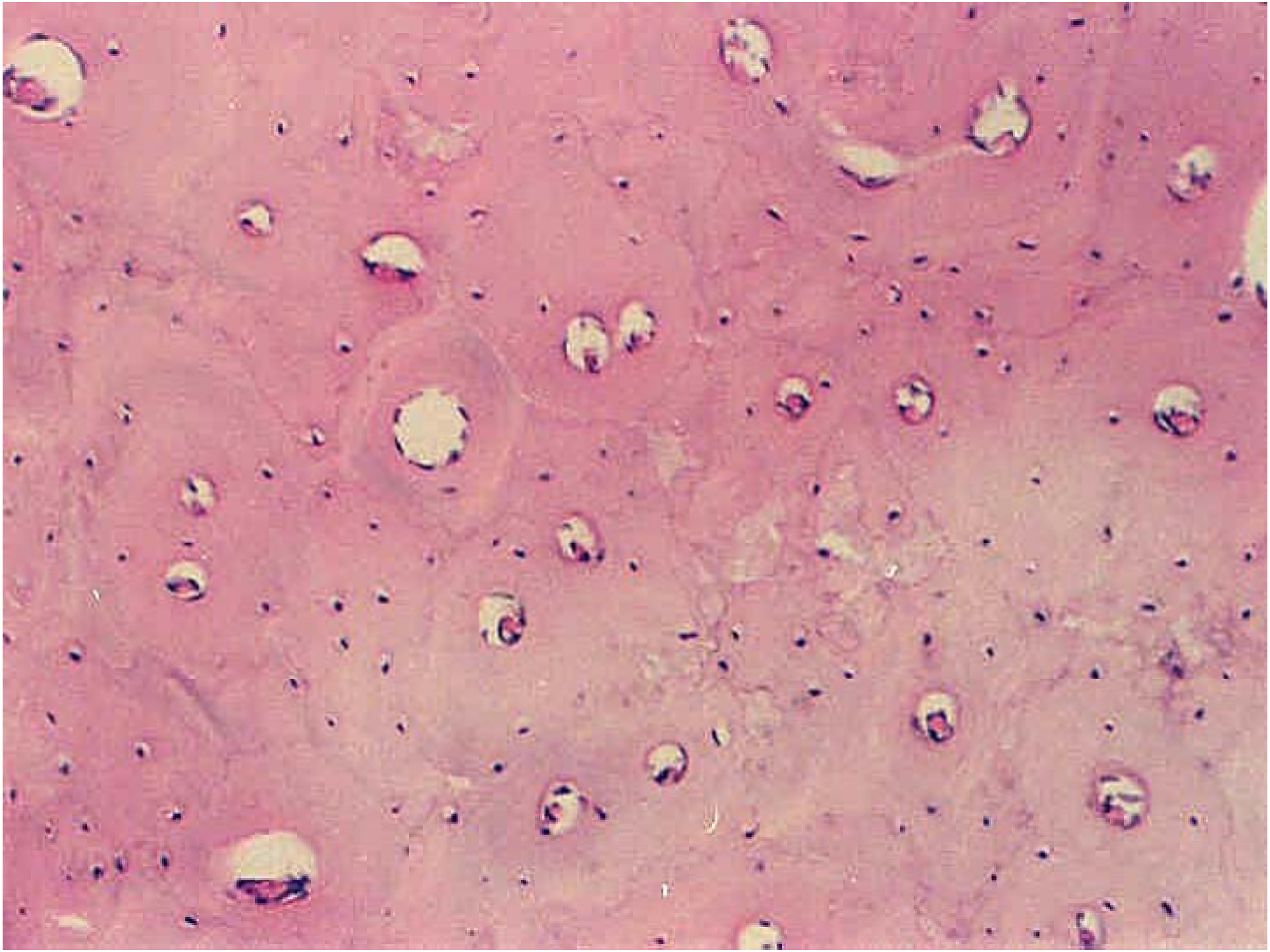

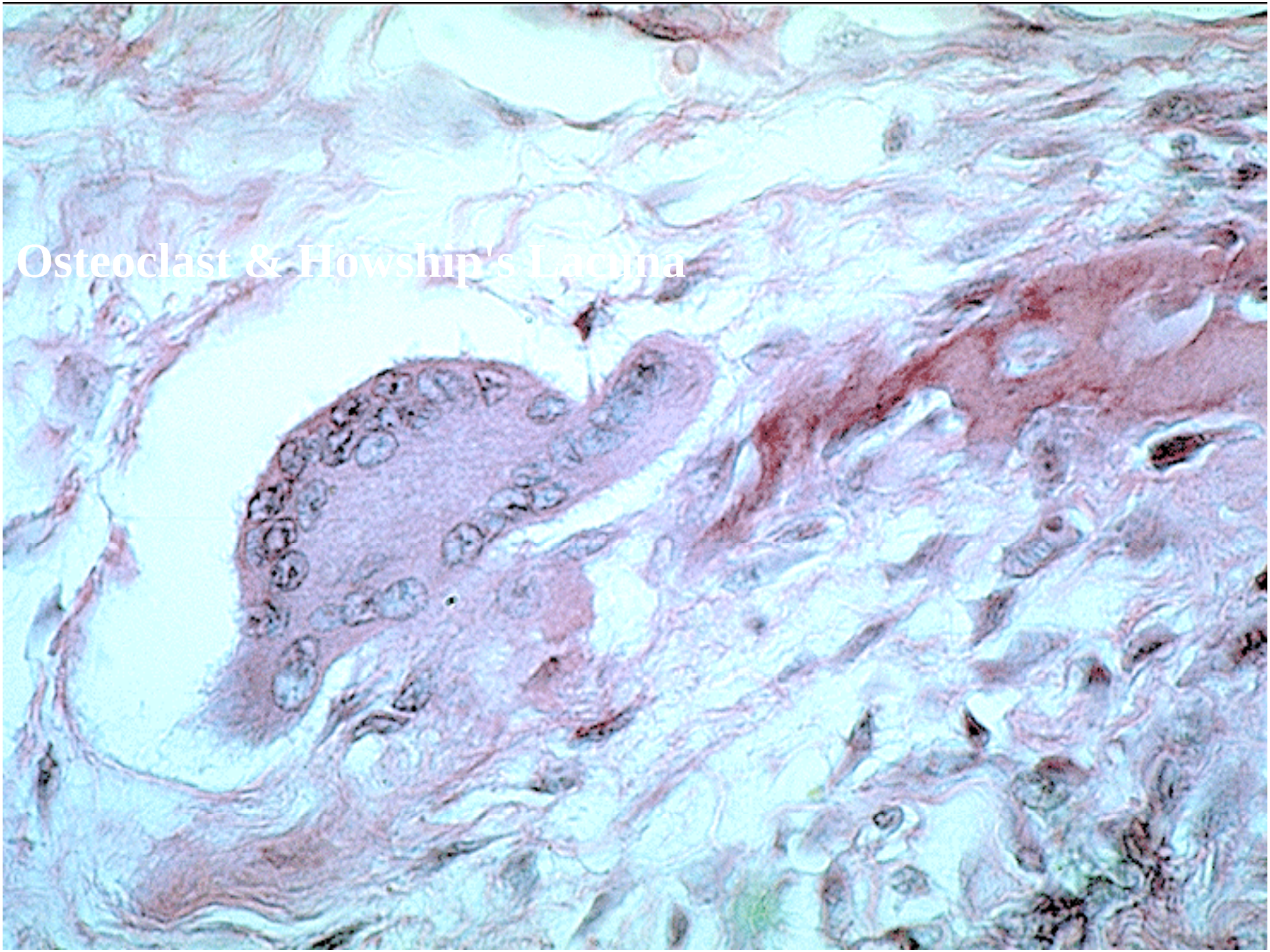
Osteoclast & Howship's Lacuna

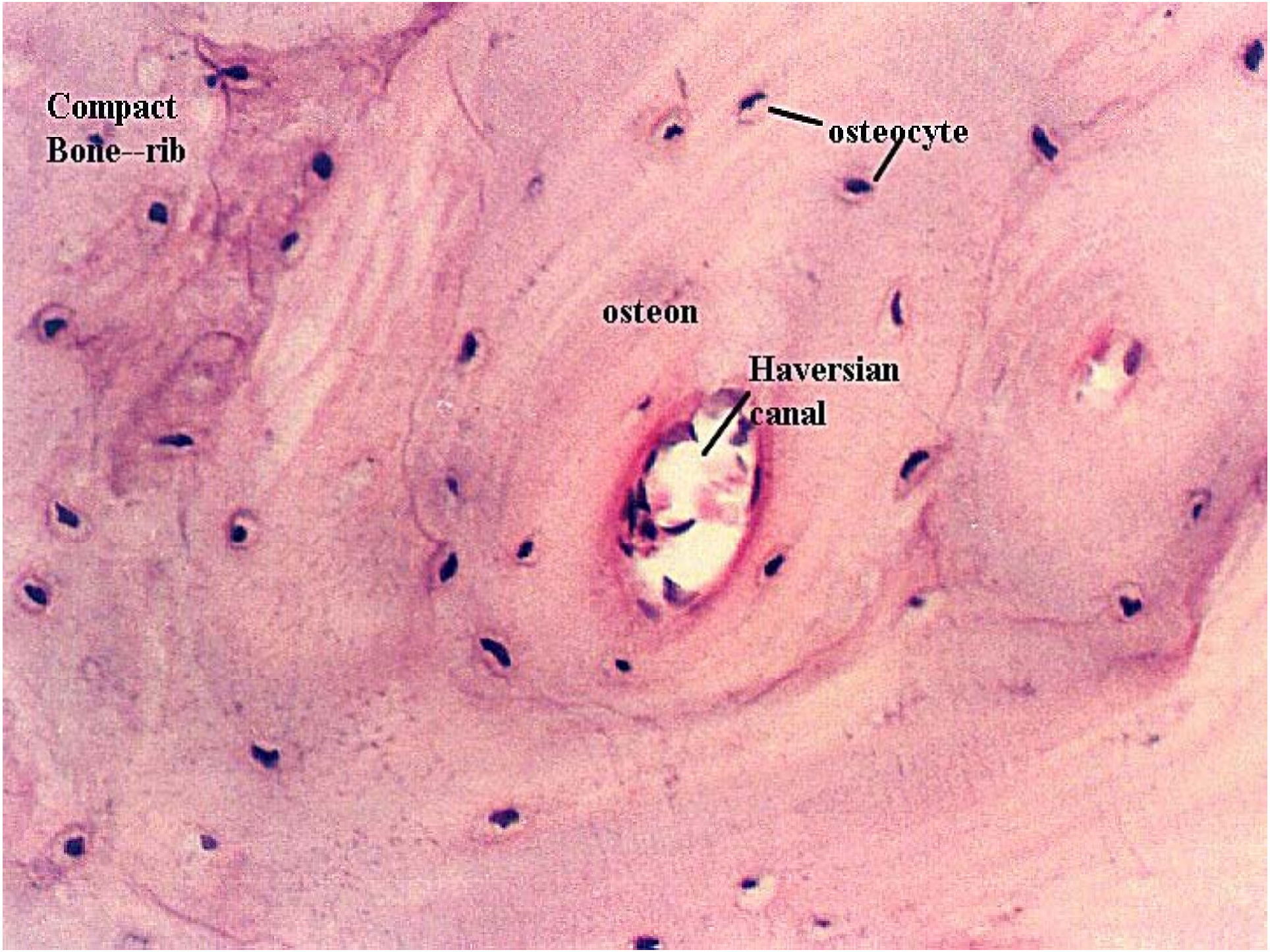
Compact
Bone--rib
osteocyte
osteon
Haversian
canal

Interstitial lamellae of cortical bone found in the shafts of long bones are served by systems of canaliculi shaped like a broom.

The handle of the broom is crowded by canaliculi which open into a transverse communication between the longitudinal vascular canals of osteons.

The existence of these systems of canaliculi has not been previously recorded.

Their presence argues against the widely held view that interstitial lamellae are merely the remains of osteons which have been partially resorbed during remodelling of bone.

A fresh look at the development of interstitial lamellae needs be taken.

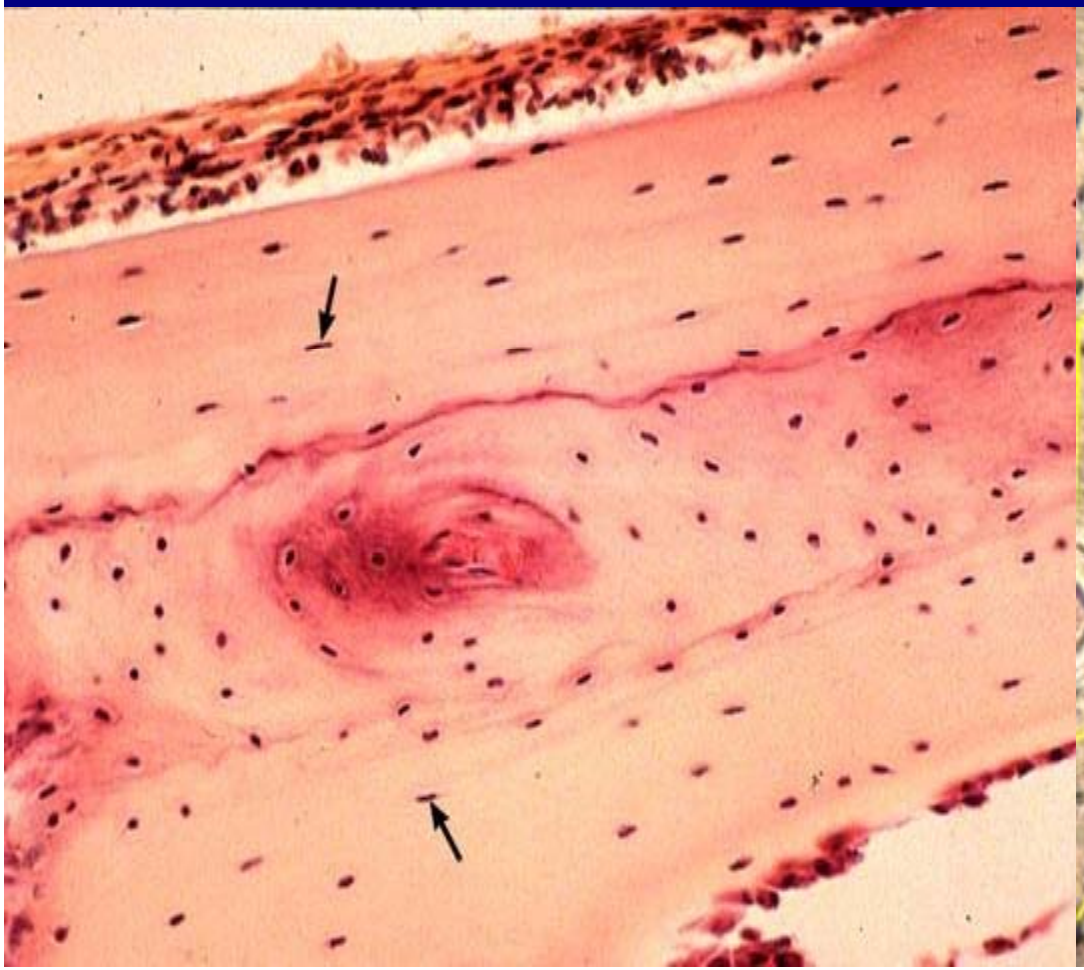

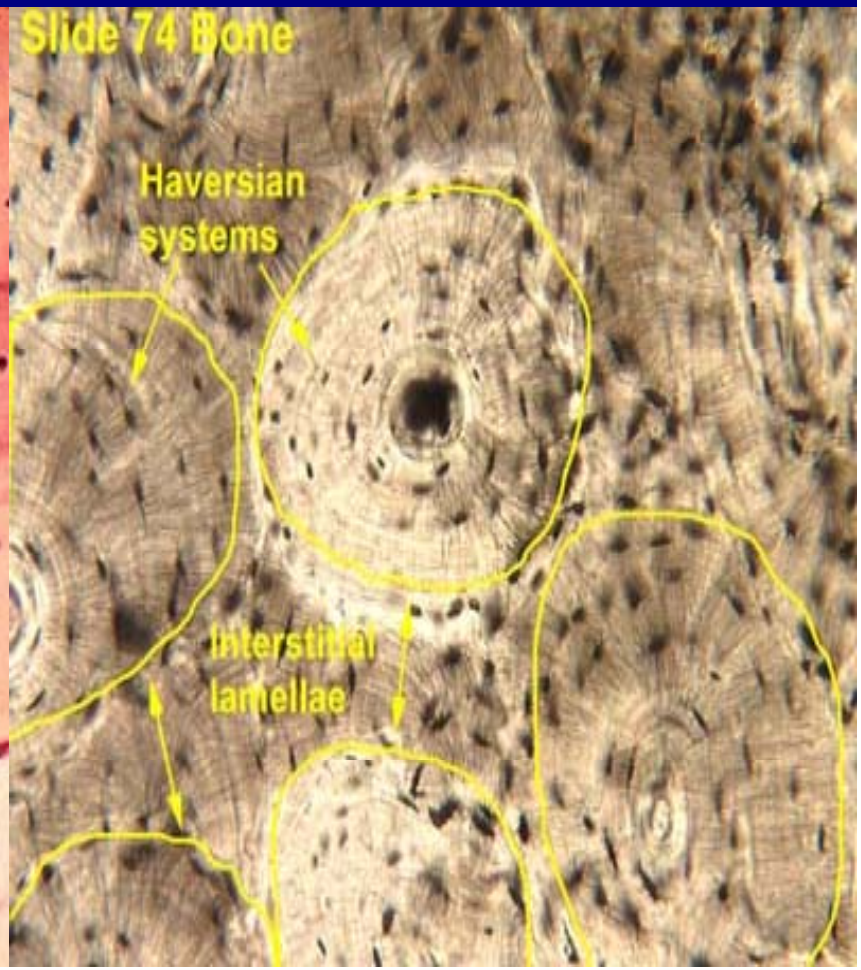

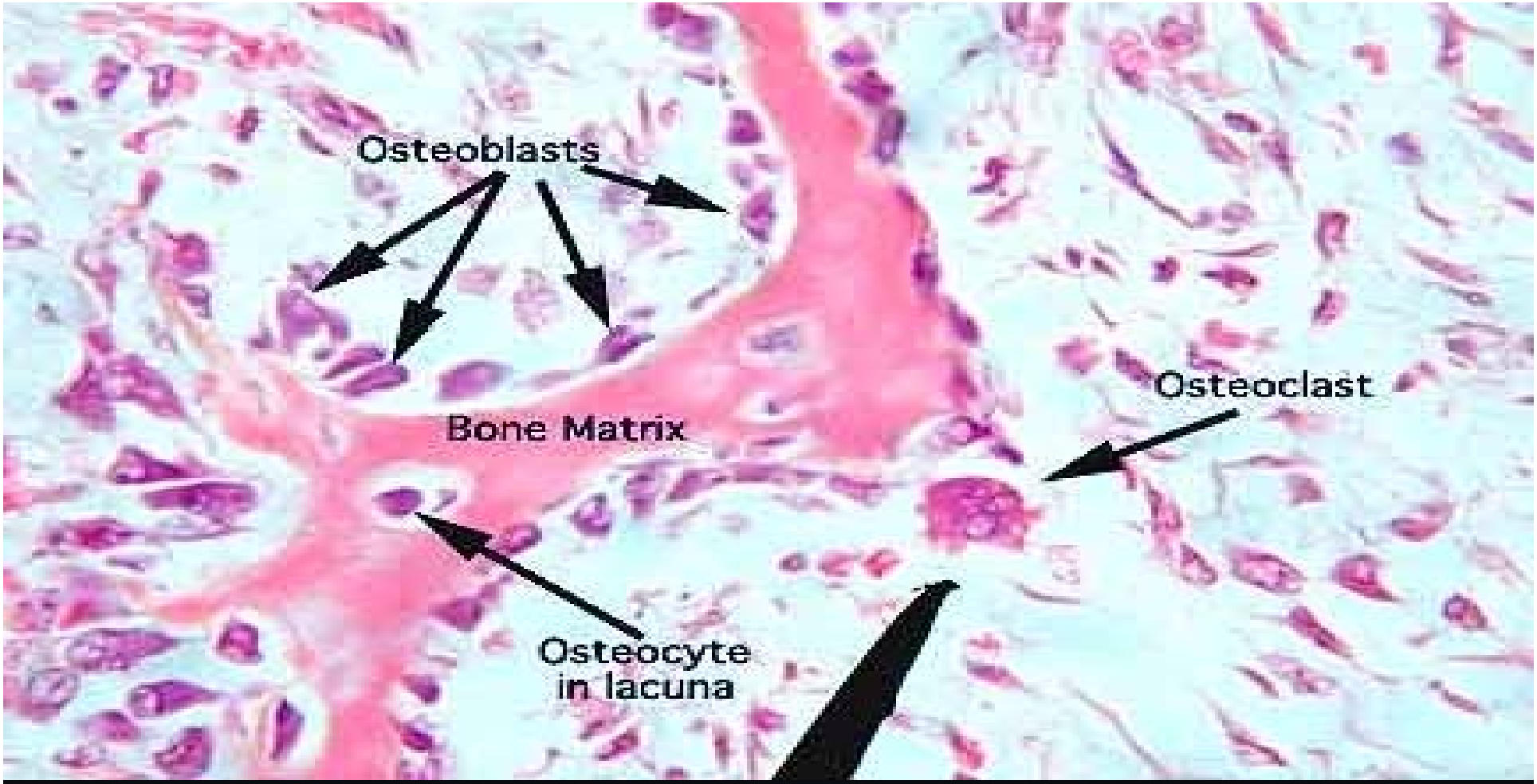

Cancellous or Membrane Bone –

Osteoblasts are arranged along the surface of a bone spicule. Some have become trapped in matrix and are now Osteocytes.

One multinucleate acidophillic Osteoclast can be seen.

- Here, we see a cartoon showing all 3 cell types. Osteoblasts and osteoclasts are indicated.
- Note the size of the osteoclast (compare it to the osteoblast), and note the ruffled border.
- Why is there a depression underneath the osteoclast?
- What is the name of the third cell type shown here?
- What do you think the tan material represents?

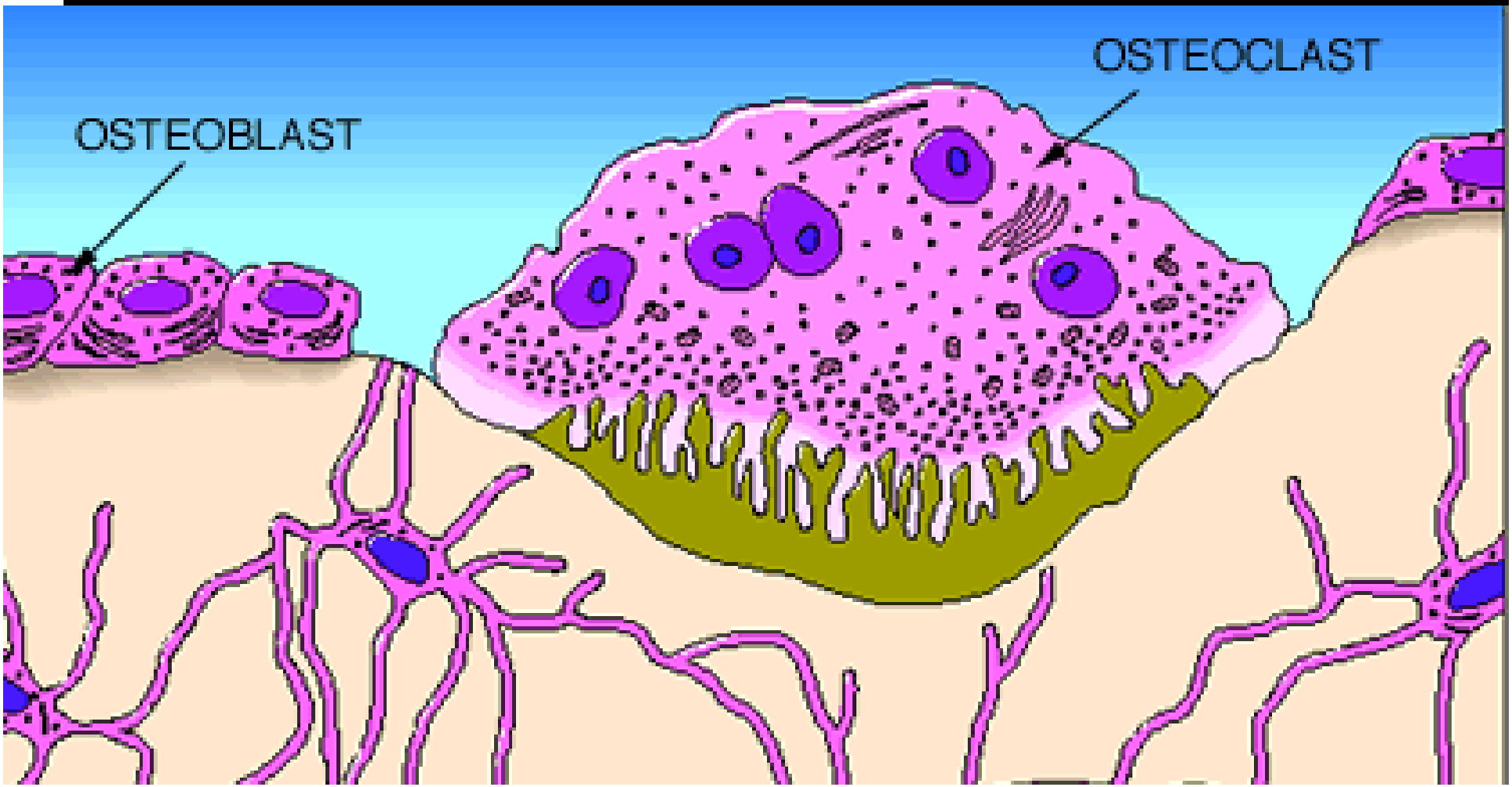

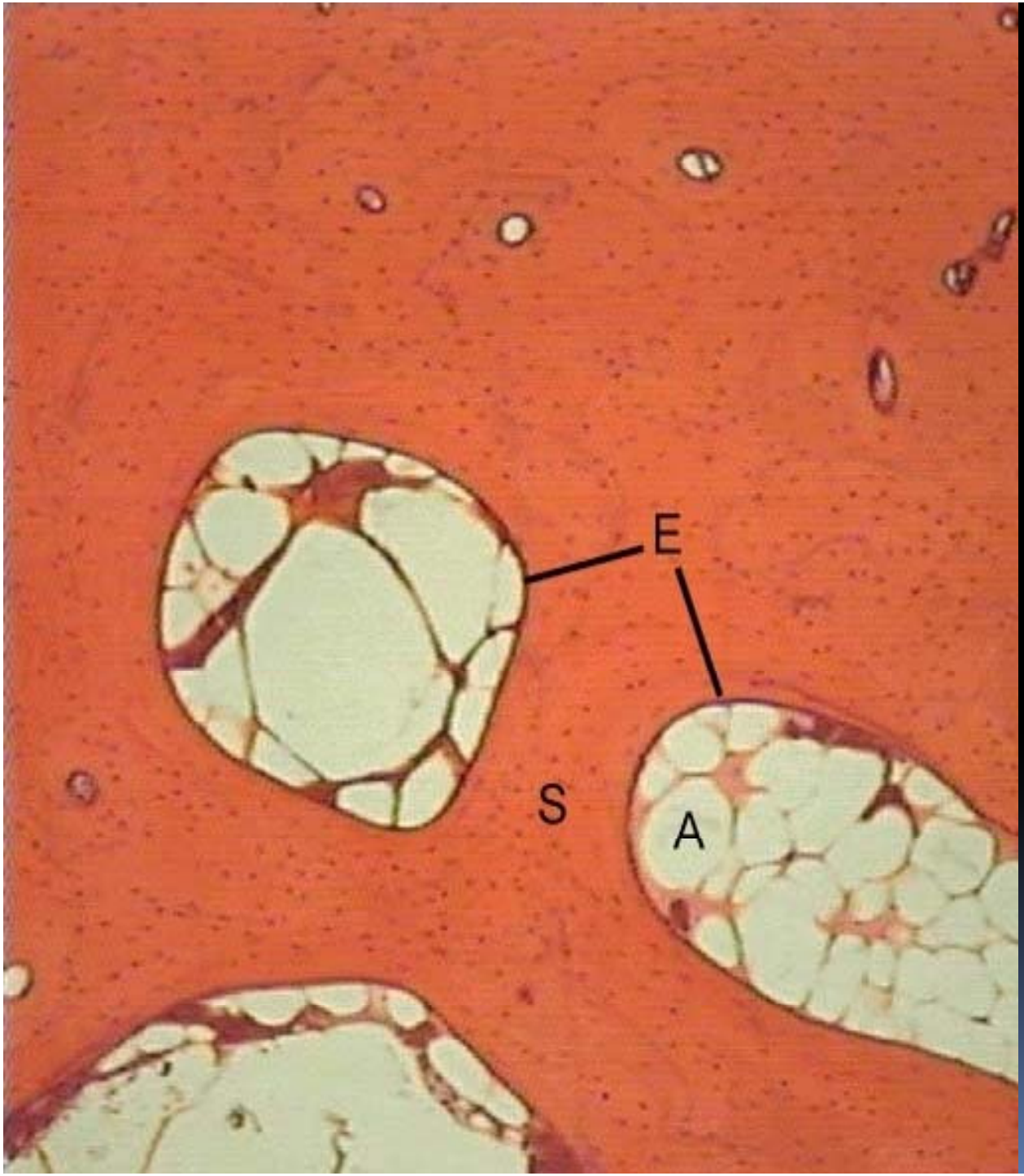

E - endosteum;
A - fat cell;
S - spongy bone

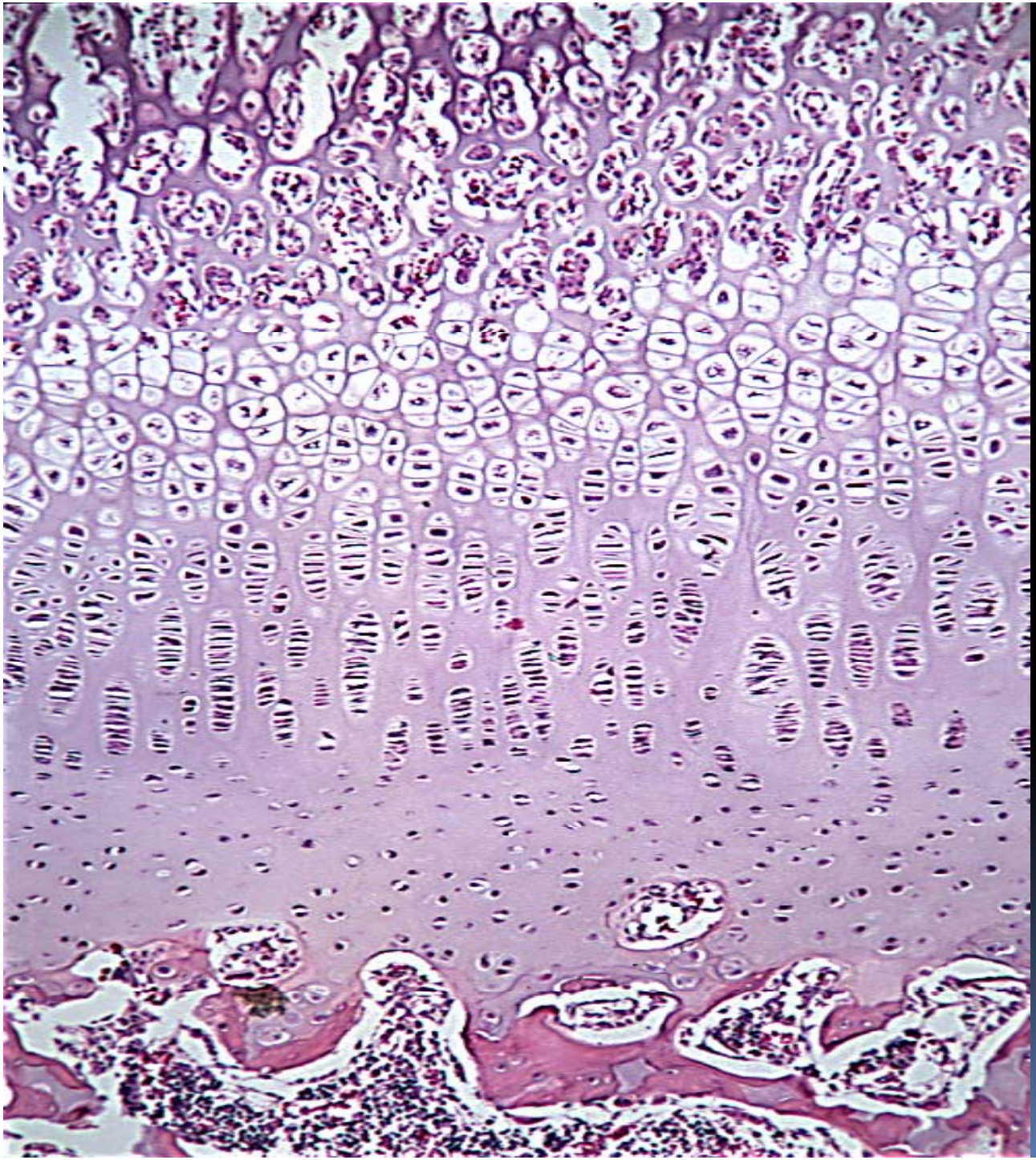

Epiphysial Growth Plate
The epiphysial growth plate, where cartilage is removed and bone is formed, is marked by four stages (left to right):

- **resting zone,**
- **proliferative zone,**
- **hypertrophy zone,**
- **ossification zone.**

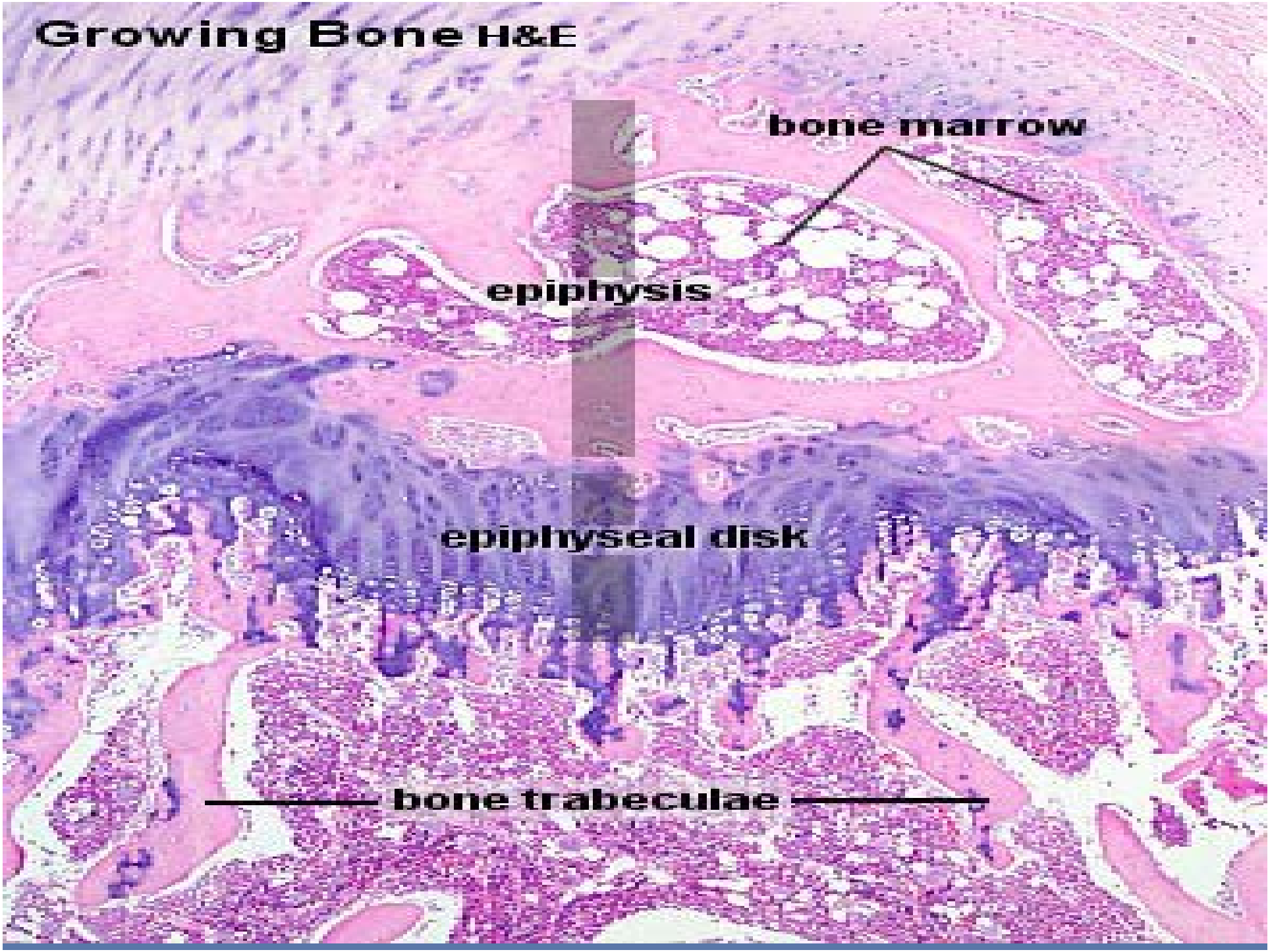
Growing Bone H&E
bone marrow
epiphysis
epiphyseal disk
bone trabeculae

The Epiphyseal Plate

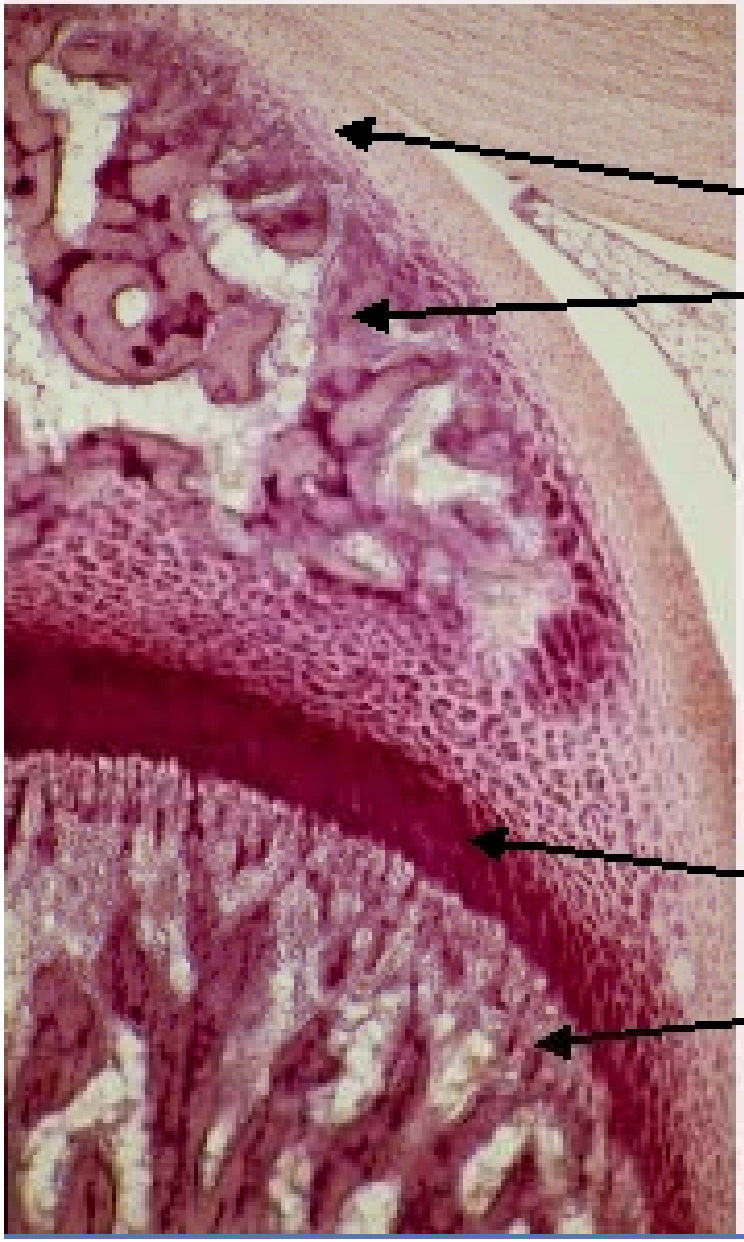

Epiphysis enlarges by growth of cartilage and replacement by bone

Shaft elongates because cartilage grows here and is replaced by bone here.