
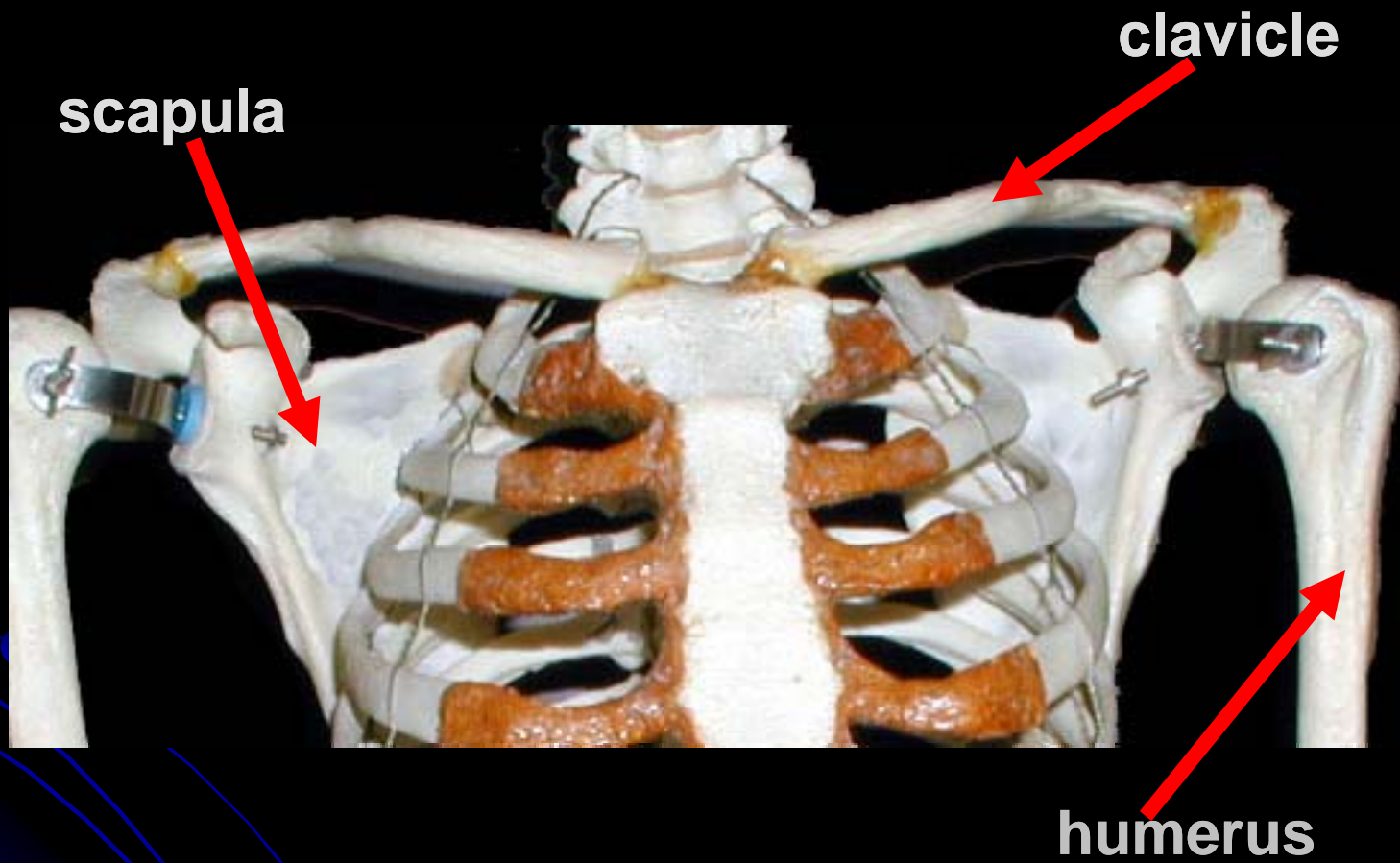


Appendicular Skeleton

Pectoral Girdle and Upper Limb




Pectoral Girdle





Clavicle

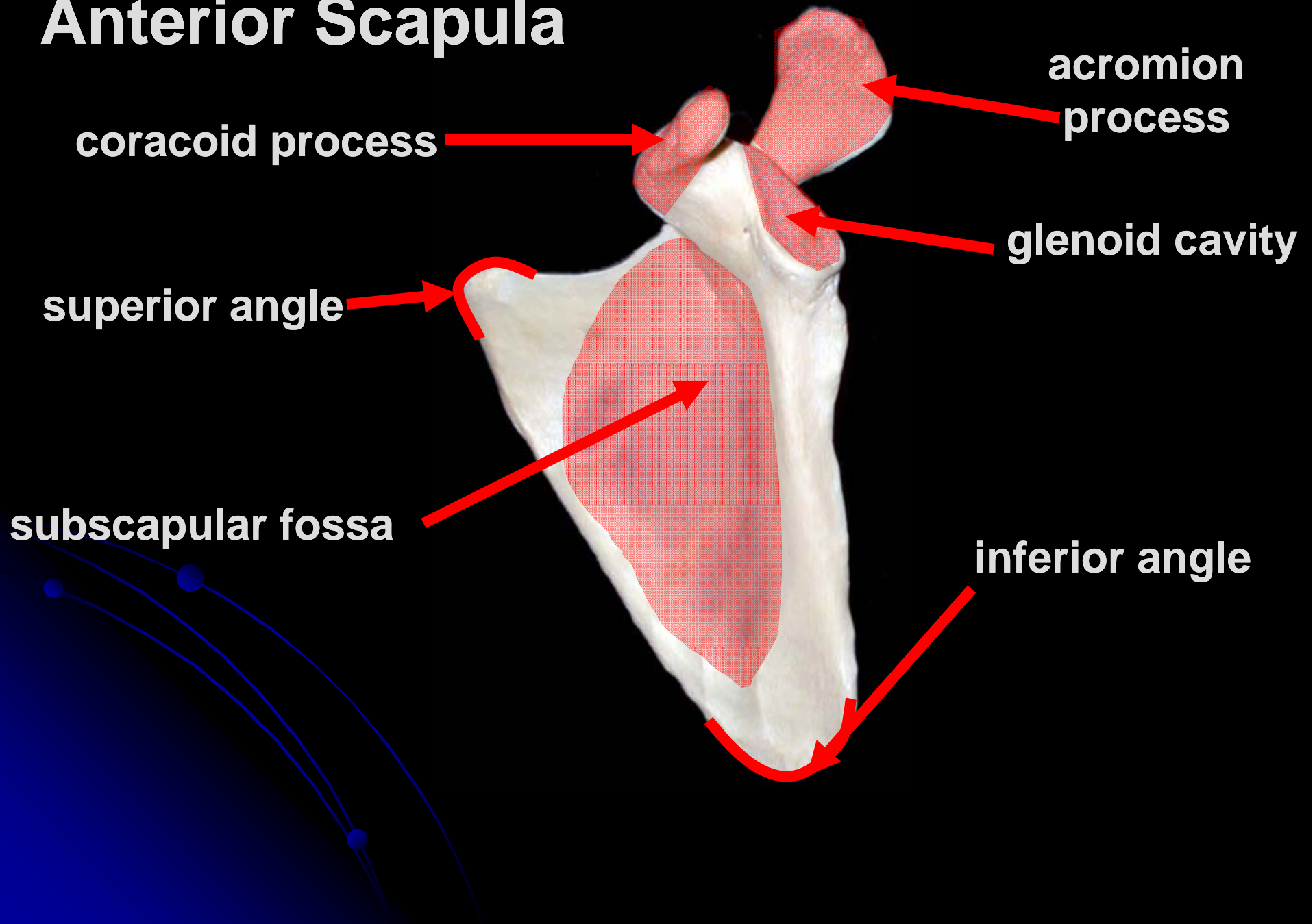
acromial end



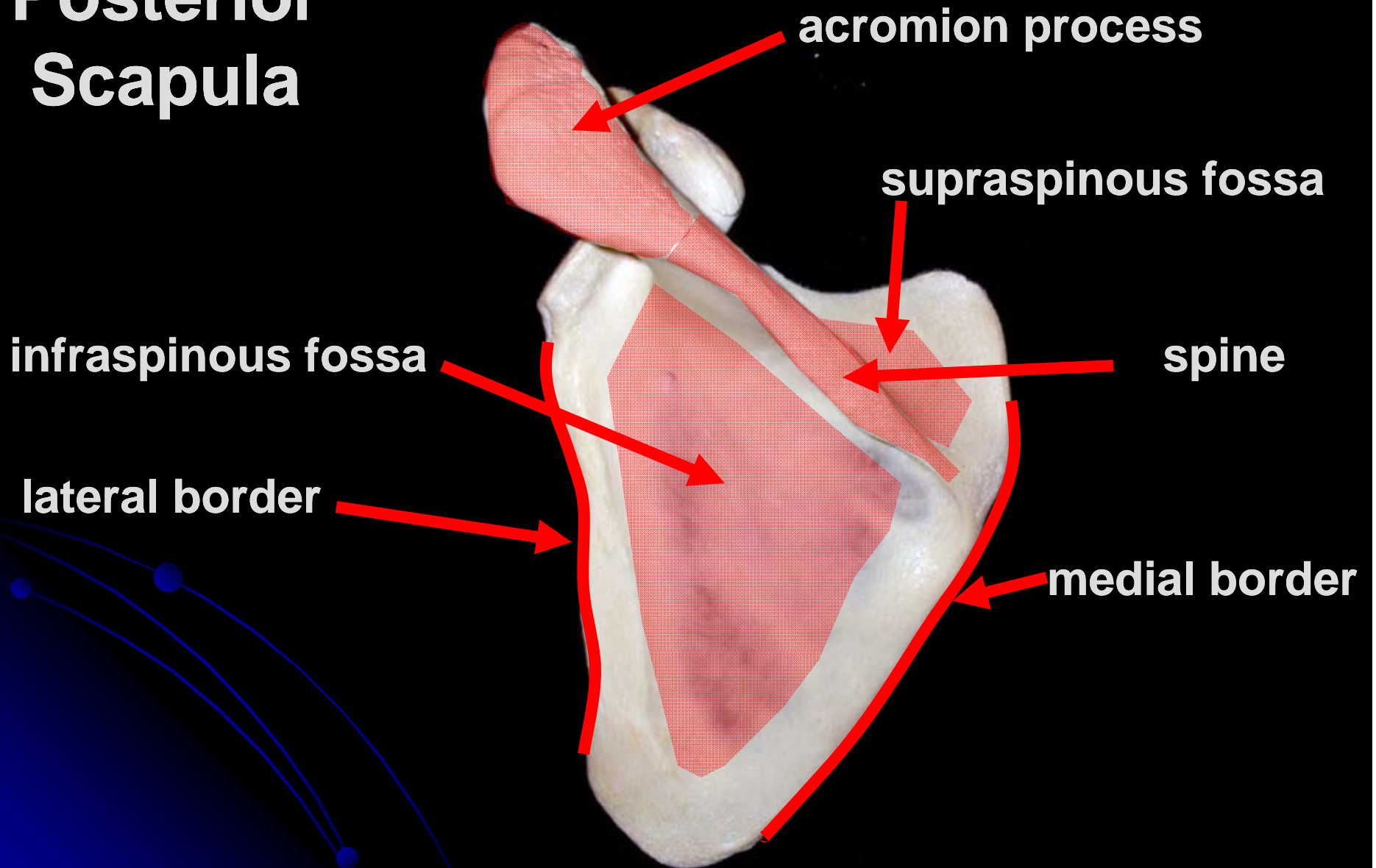
sternal end



Anterior Scapula



Posterior Scapula



Humerus

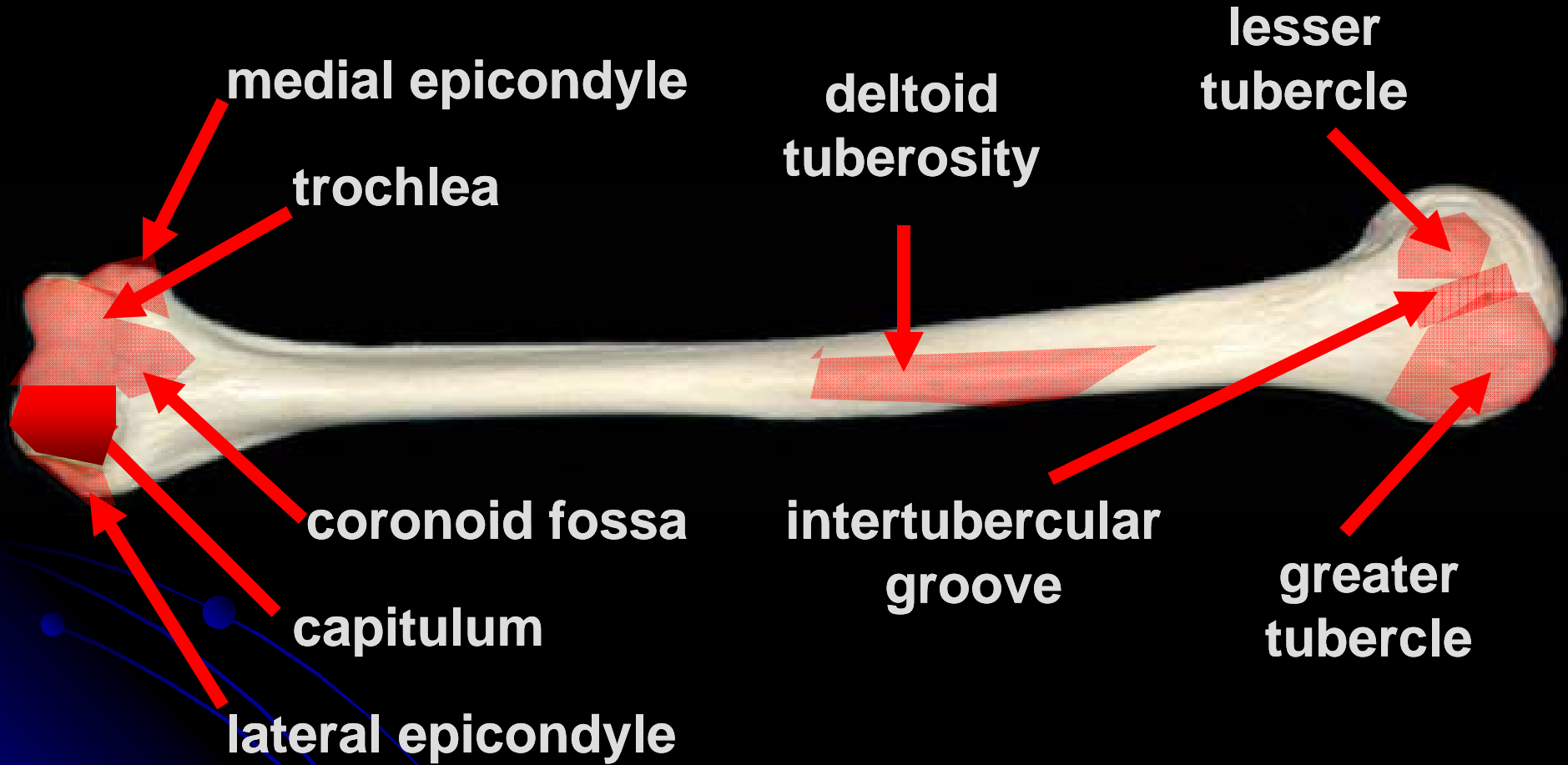
head

neck

olecranon fossa



Anterior Humerus



Ulna

trochlear notch

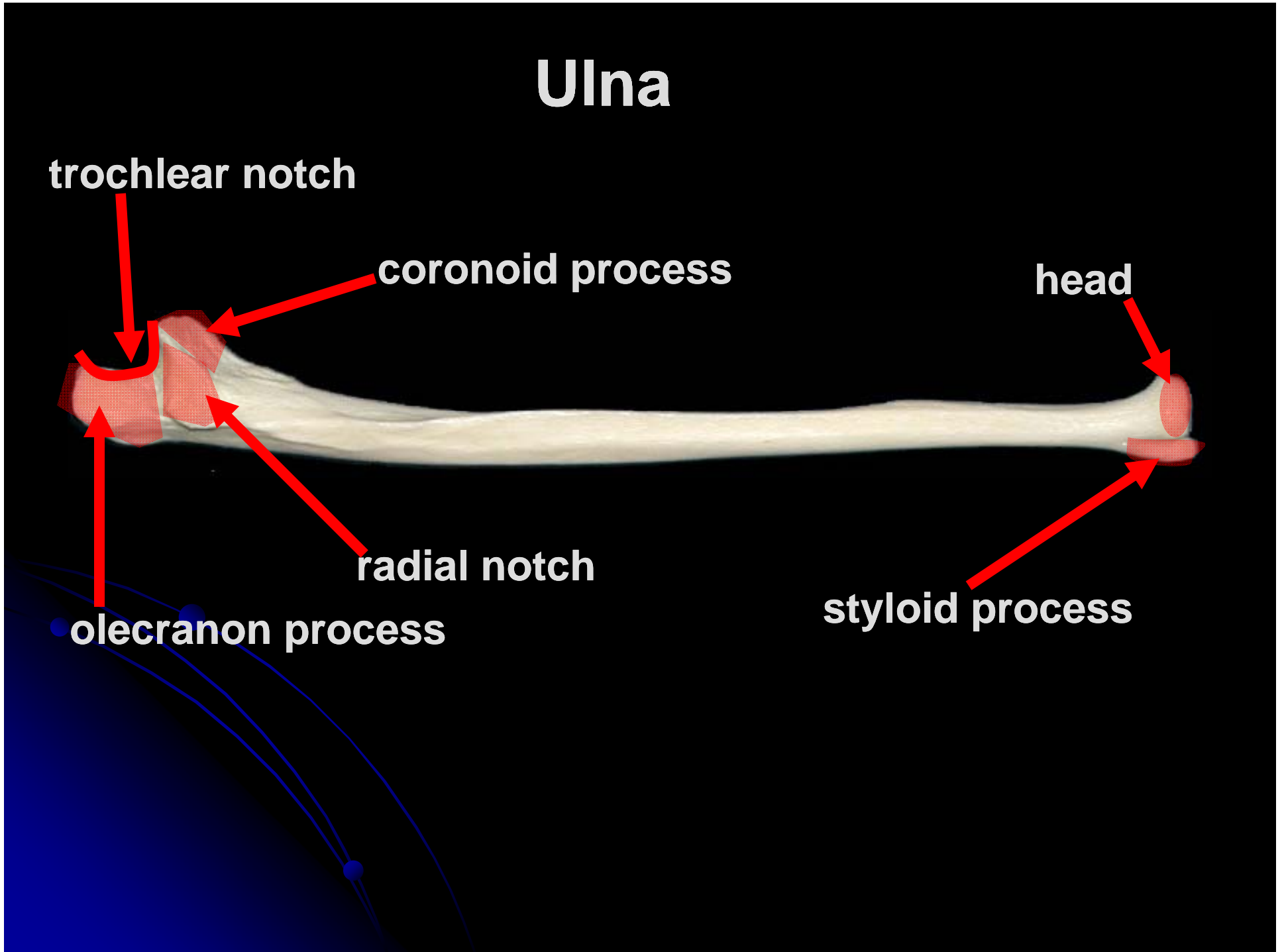
coronoid process

head


radial notch

olecranon process

styloid process

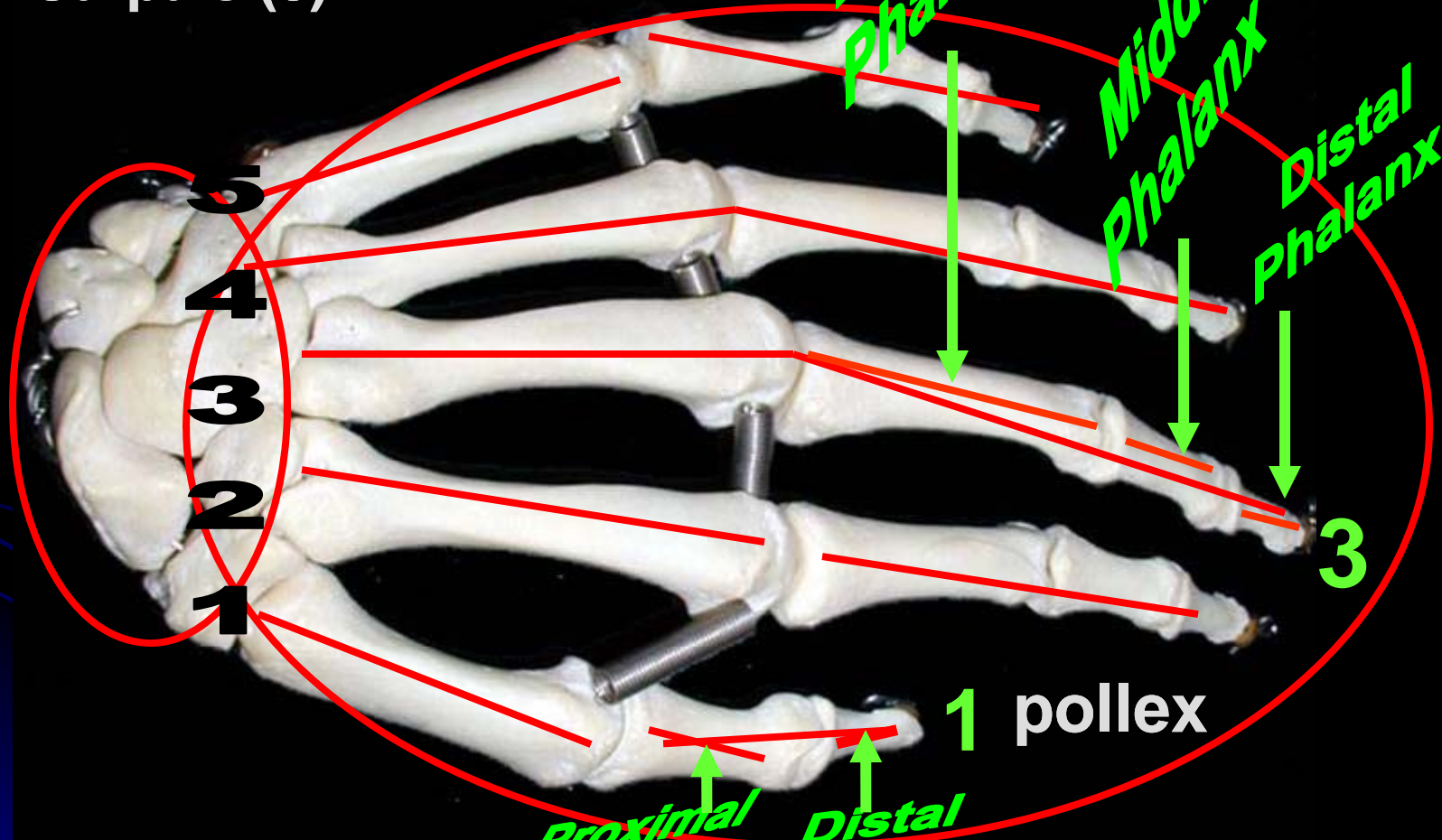


Radius



Manus (Hand)

Carpals (8)



Proximal Phalanx

Middle Phalanx

Distal Phalanx

5
4
3
2
1

3

1 pollex

Proximal Phalanx


Distal Phalanx

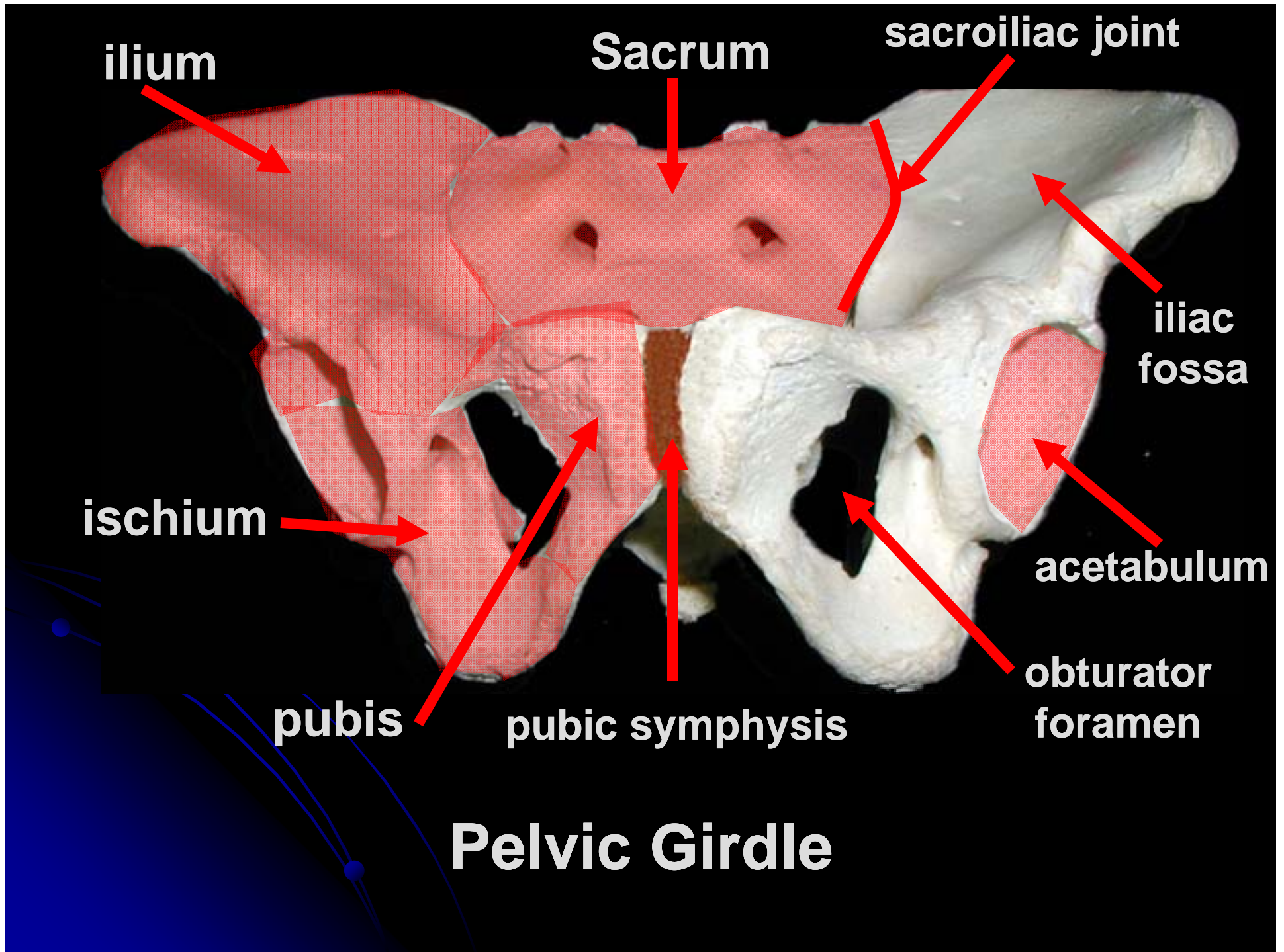
Metacarpals (5)

Digits (5)

Appendicular Skeleton

Pelvic Girdle and Lower Limb





HIP BONE

iliac crest

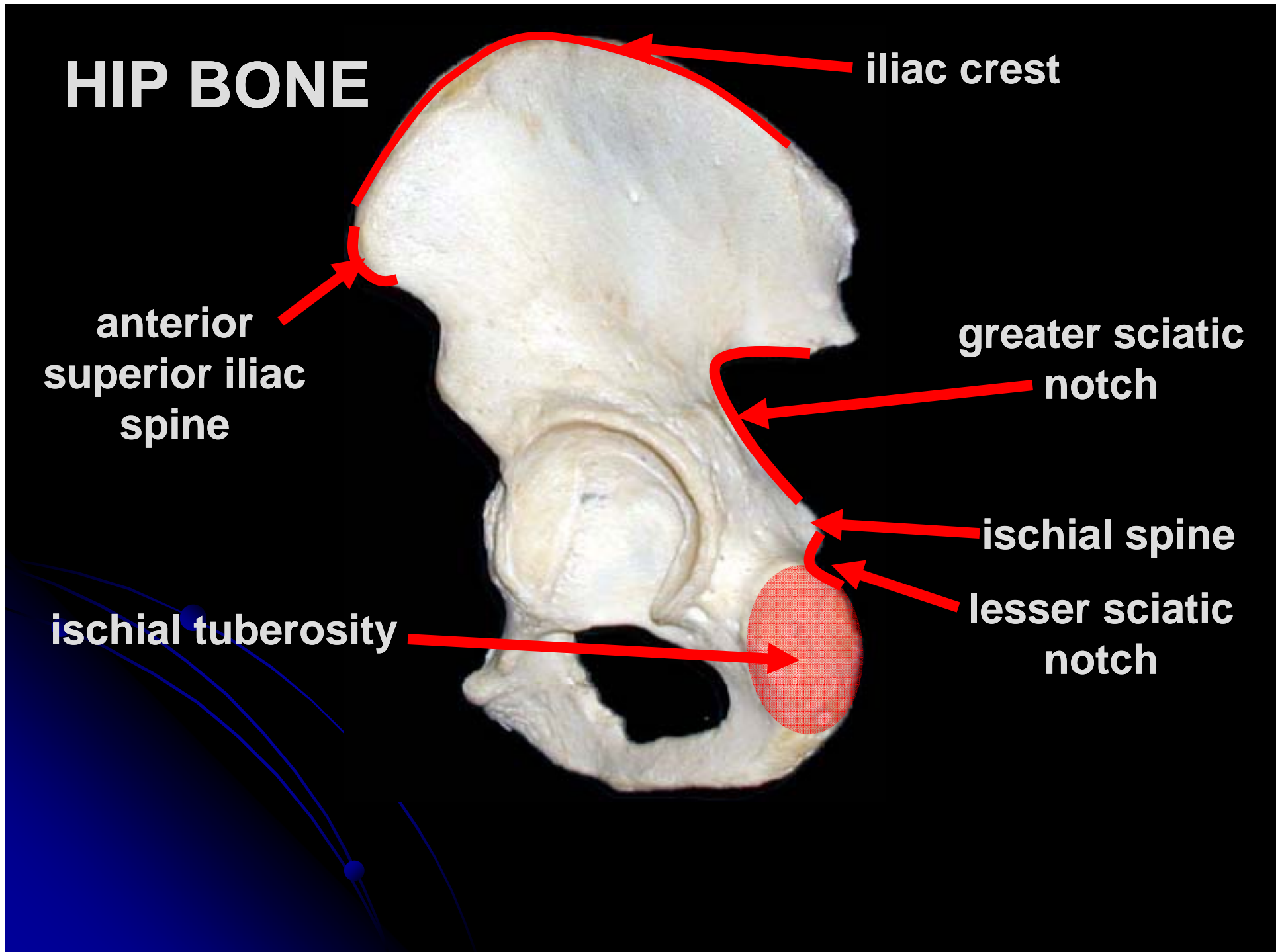
anterior
superior iliac
spine

greater sciatic
notch

ischial spine

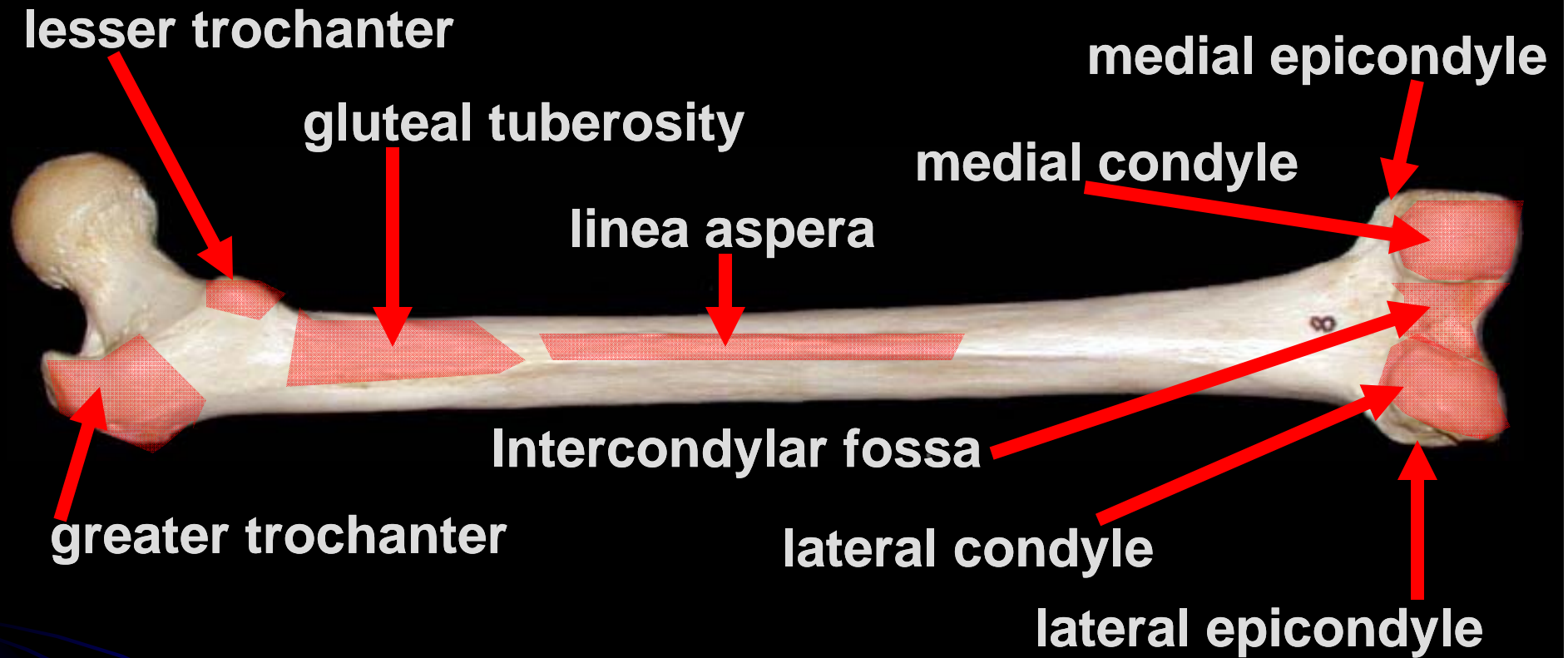
lesser sciatic
notch

ischial tuberosity



Anterior Femur





Posterior Femur

Tibia

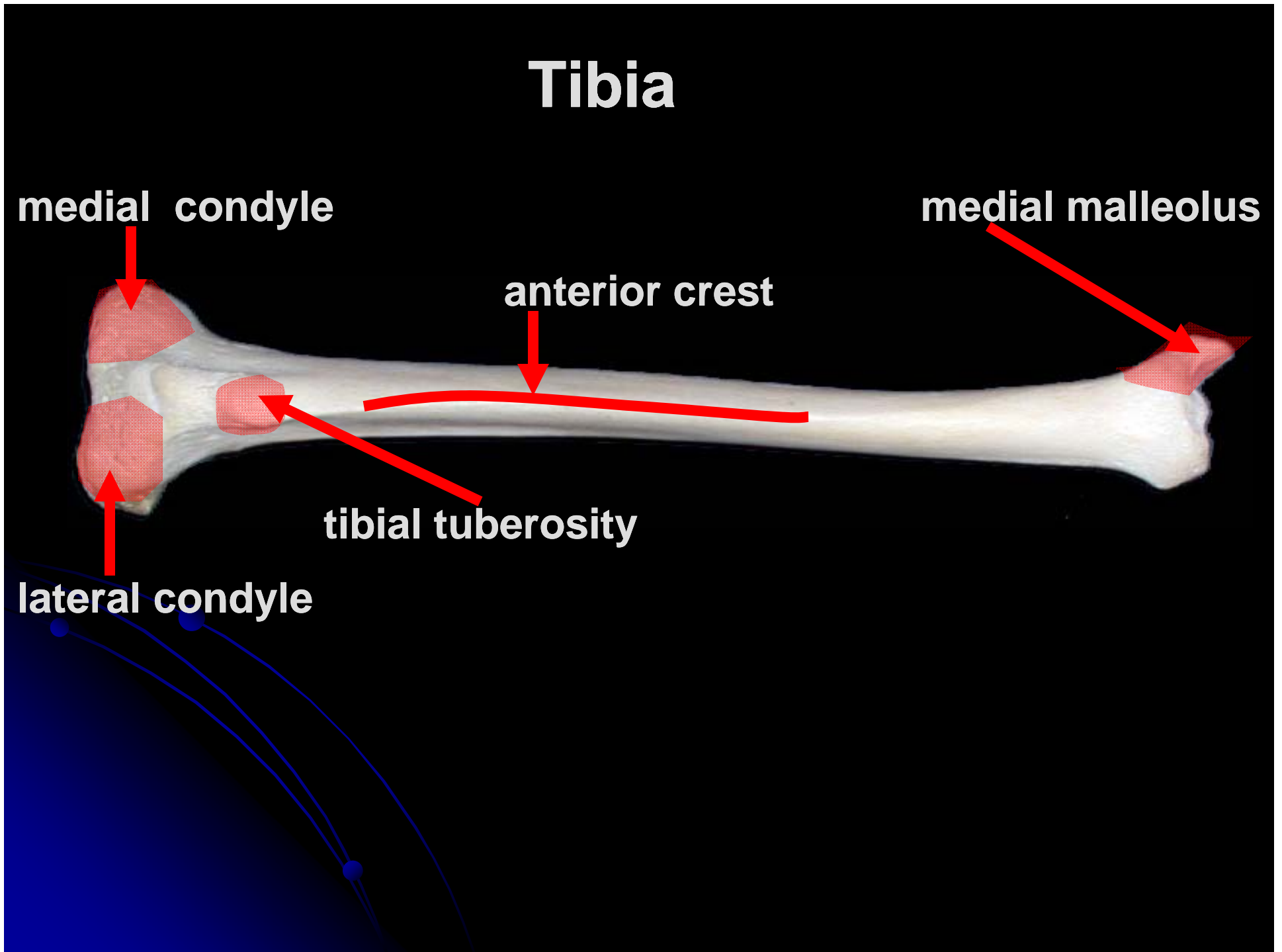
medial condyle

medial malleolus


anterior crest

tibial tuberosity


lateral condyle



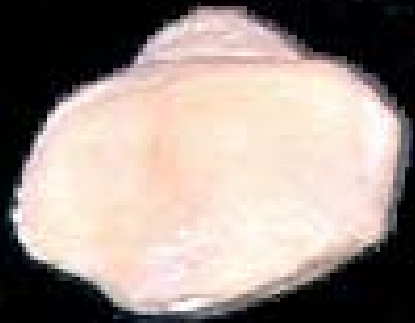Fibula




head



lateral malleolus



Patella

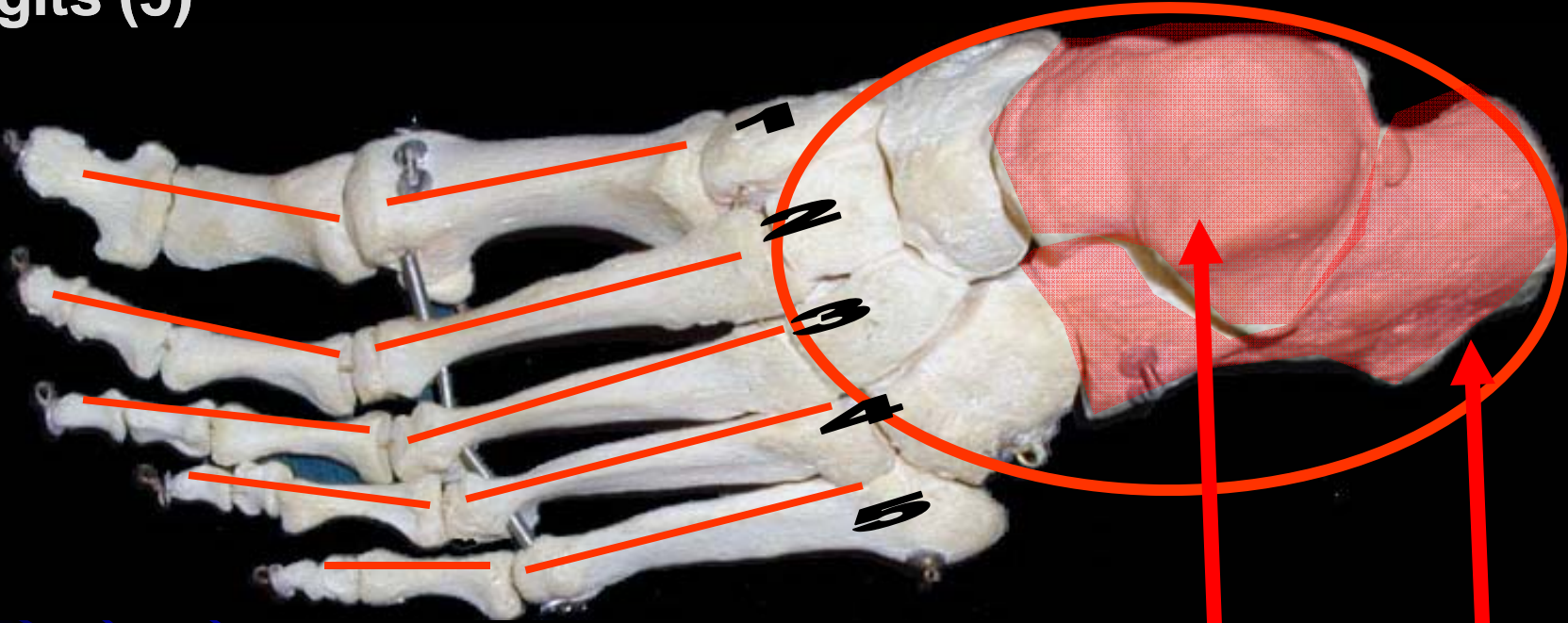


Foot

Digits (5)

Metatarsals (5)

Tarsals (7)



Talus

Calcaneus

Hallux (Great Toe)

Name the Individual Phalanx

