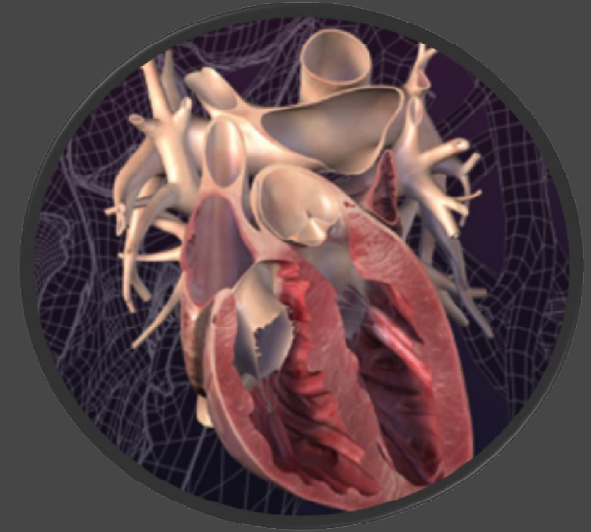
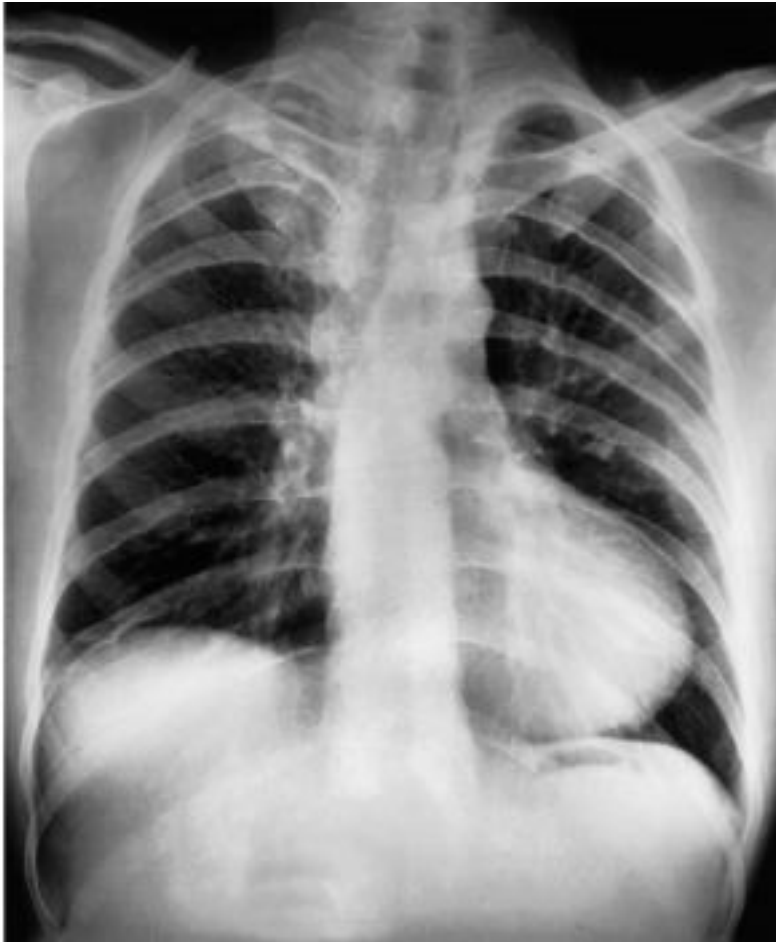
CARDIOVASCULAR SYSTEM

PART 1

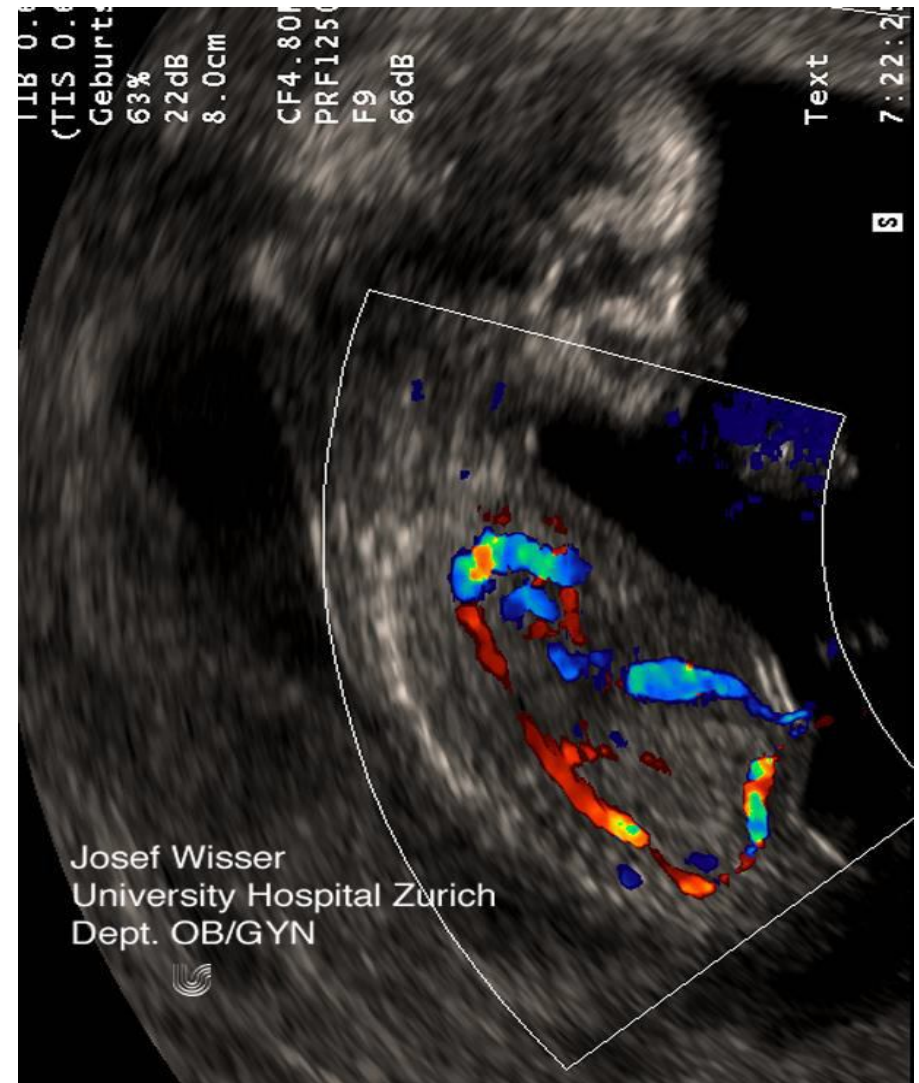
DANIL HAMMOUDI.MD

□ CARDIOVASCULAR EMBRYOLOGY

Cardiovascular Development

- **3rd gestational week ...**
heart formed [five weeks
after the last normal
menstrual period (LMP)]
- **8th gestational week...**
heart functional

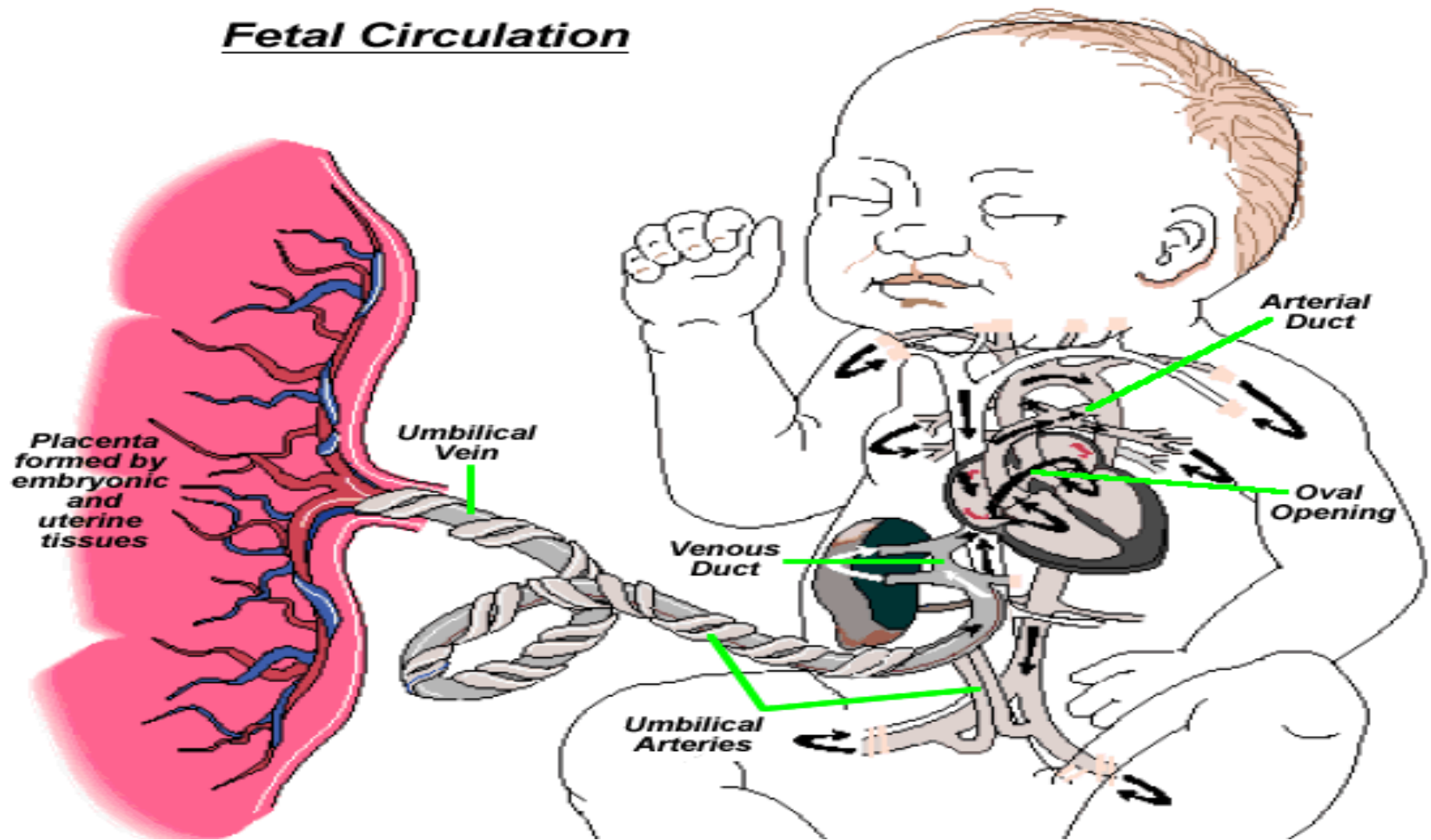
The heart is the first functional organ in a vertebrate embryo



- Start at the mother rate 70 -80 until the 7th week
- 165-185 BPM during the early 7th week, (early 9th week after the LMP).
- This acceleration is approximately 3.3 BPM per day, or about 10 BPM every three days, an increase of 100 BPM in the first month
- After peaking at about 9.2 weeks after the LMP, it decelerates to about 150 BPM (+/-25 BPM) during the 15th week after the LMP. After the 15th week the deceleration slows reaching an average rate of about 145 (+/-25 BPM) BPM at term. The regression formula which describes this acceleration before the embryo reaches 25 mm in crown-rump length or 9.2 LMP weeks is:

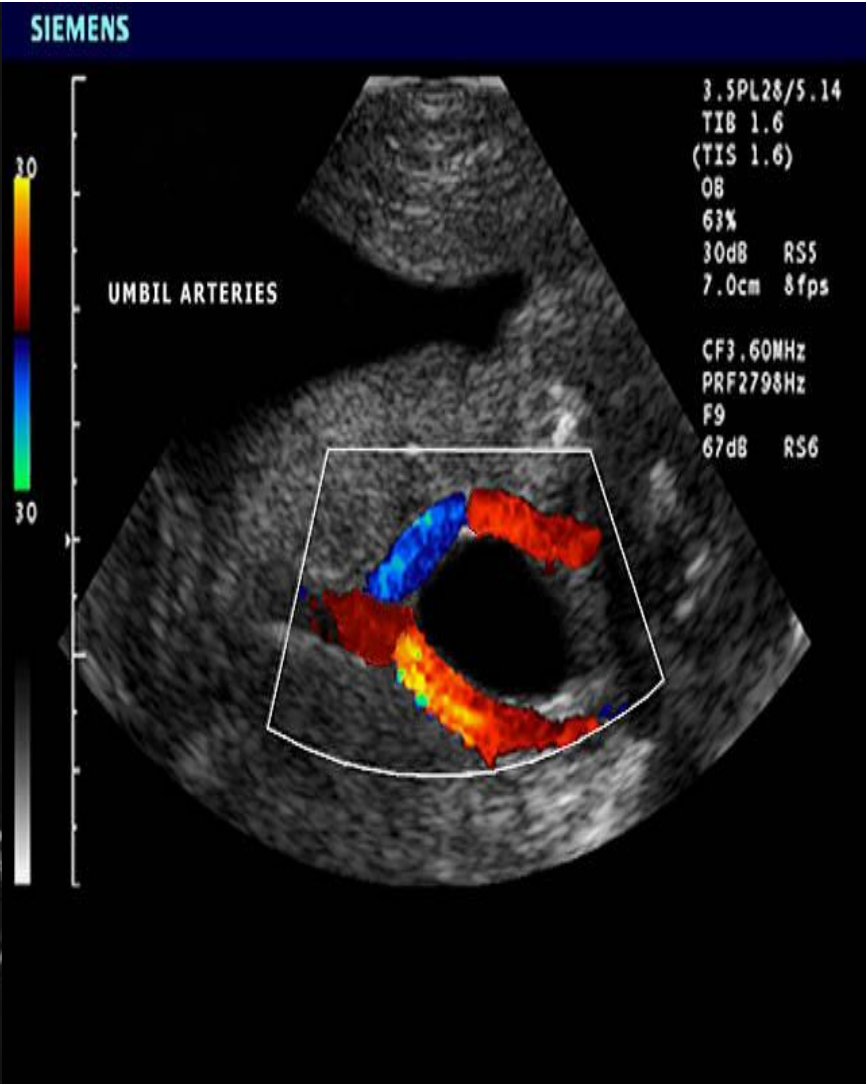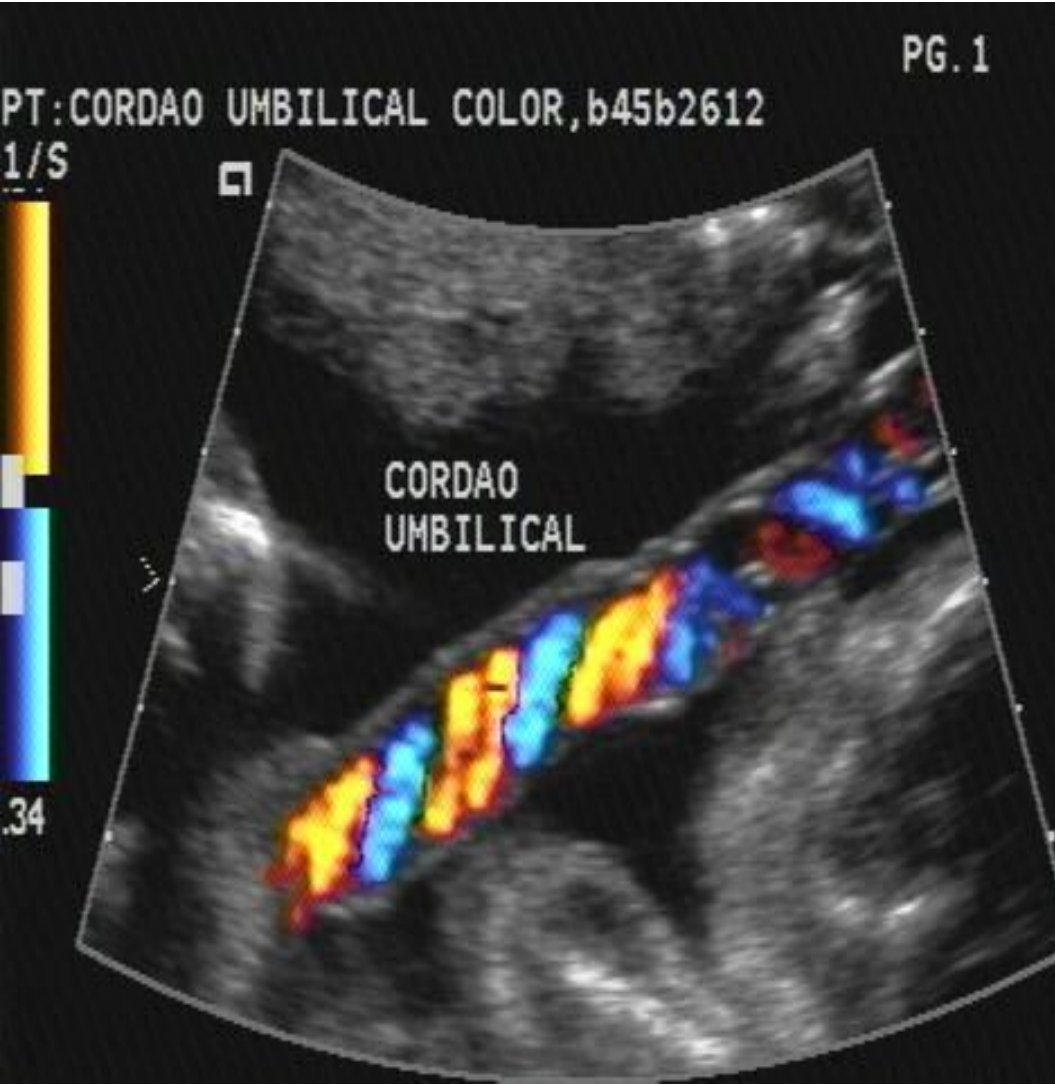
$$\text{Age in days} = \text{EHR}(0.3) + 6$$

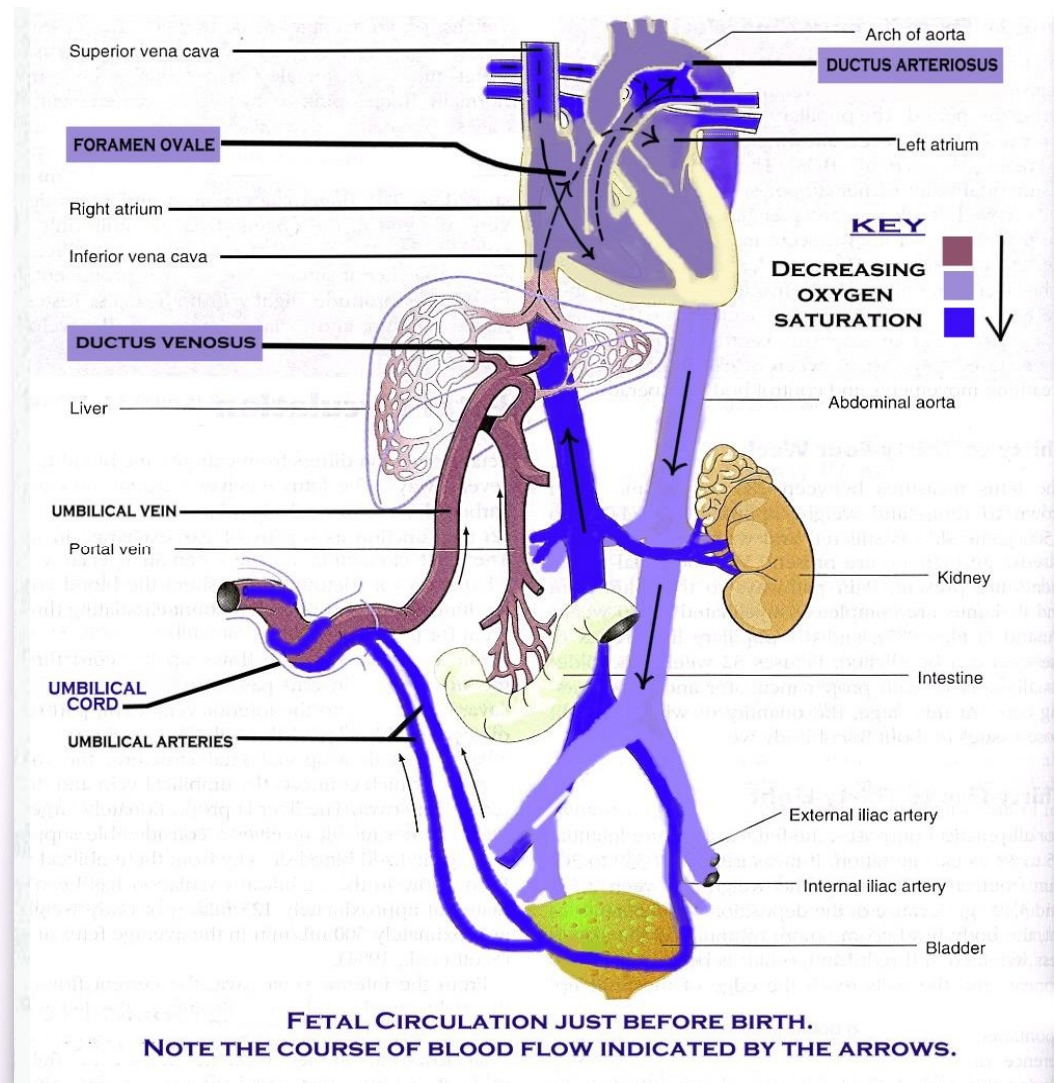
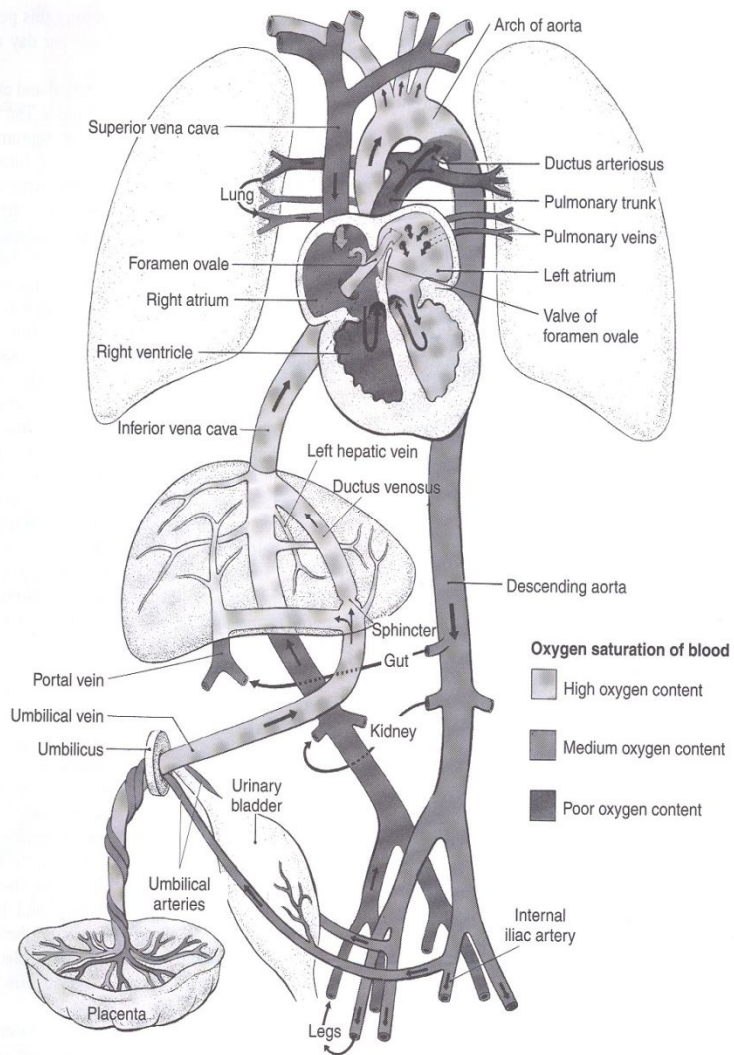
Fetal Circulation

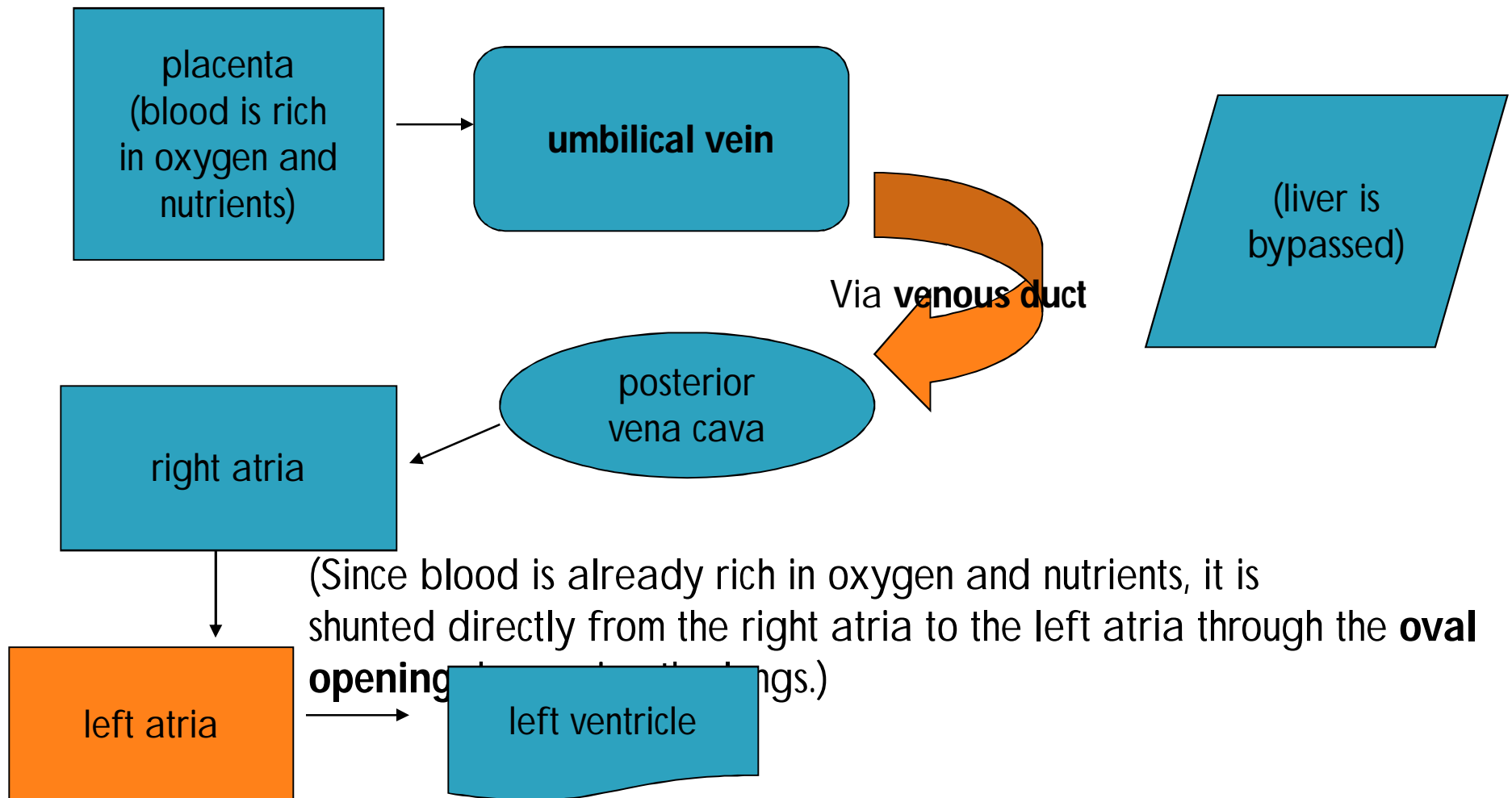


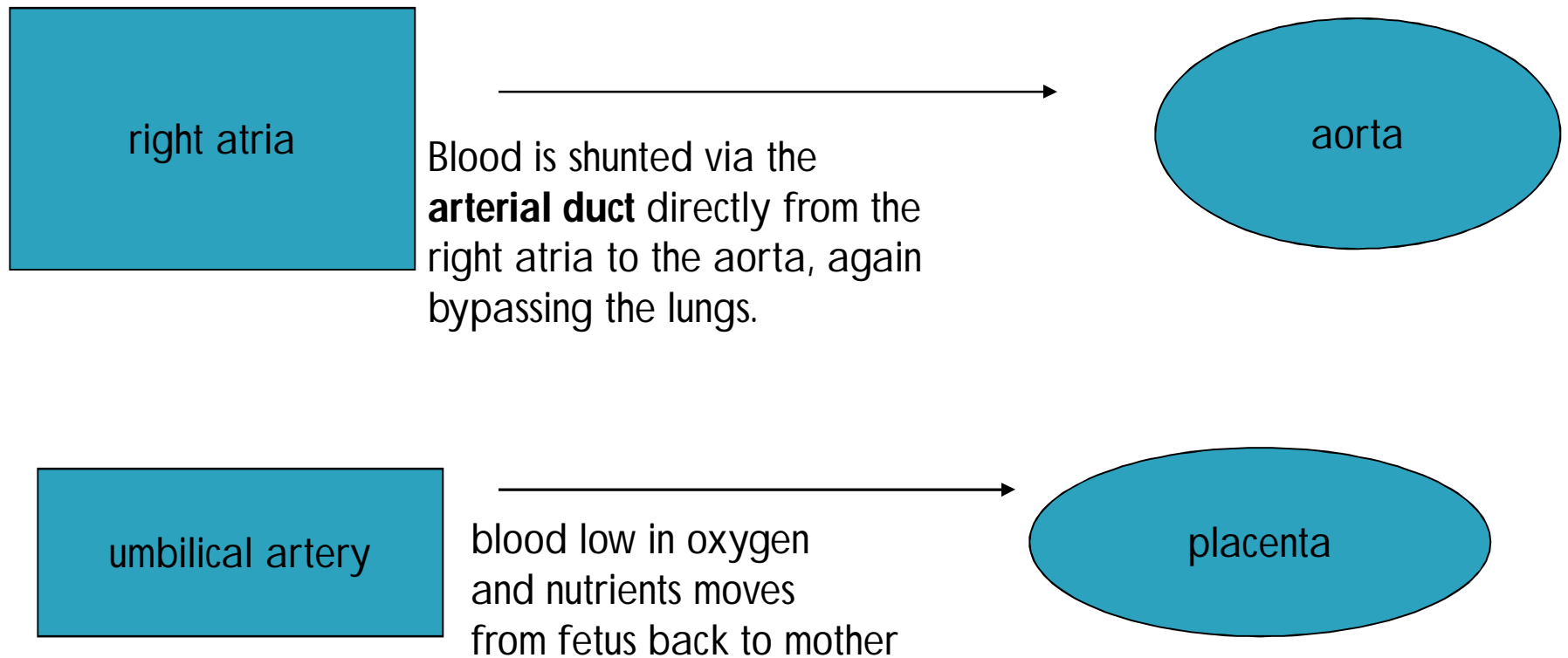
In the developing fetus, the **ductus arteriosus (DA)**, also called the **ductus Botalli**, is a shunt connecting the pulmonary artery to the aortic arch. It allows most of the blood from the right ventricle to bypass the fetus' fluid-filled lungs, protecting the lungs from being overworked and allowing the right ventricle to strengthen. There are two other fetal shunts, the ductus venosus and the foramen ovale.

In the fetus, the **ductus venosus** shunts a significant majority (80%) of the blood flow of the umbilical vein directly to the inferior vena cava. Thus, it allows oxygenated blood from the placenta to bypass the liver. In conjunction with the other fetal shunts, the foramen ovale and ductus arteriosus, it plays a critical role in preferentially shunting oxygenated blood to the fetal brain







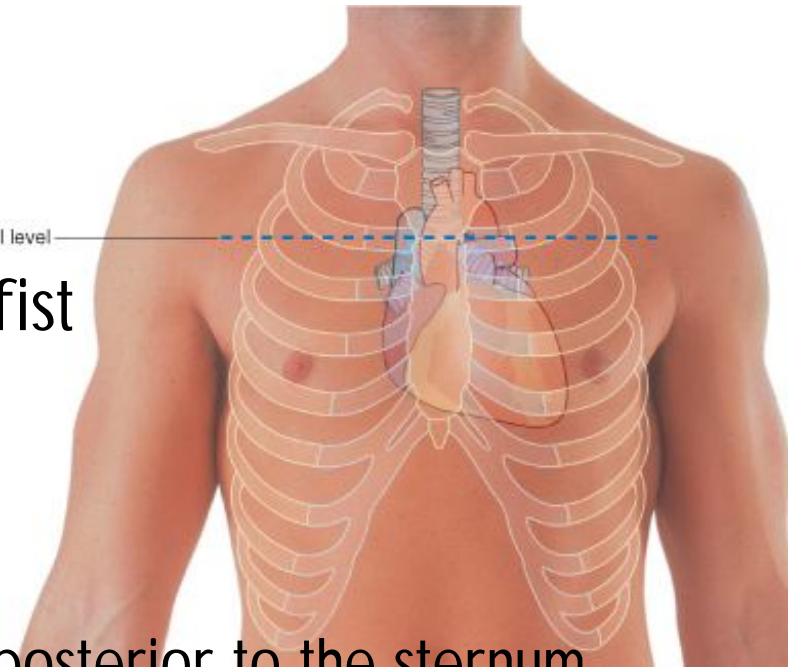


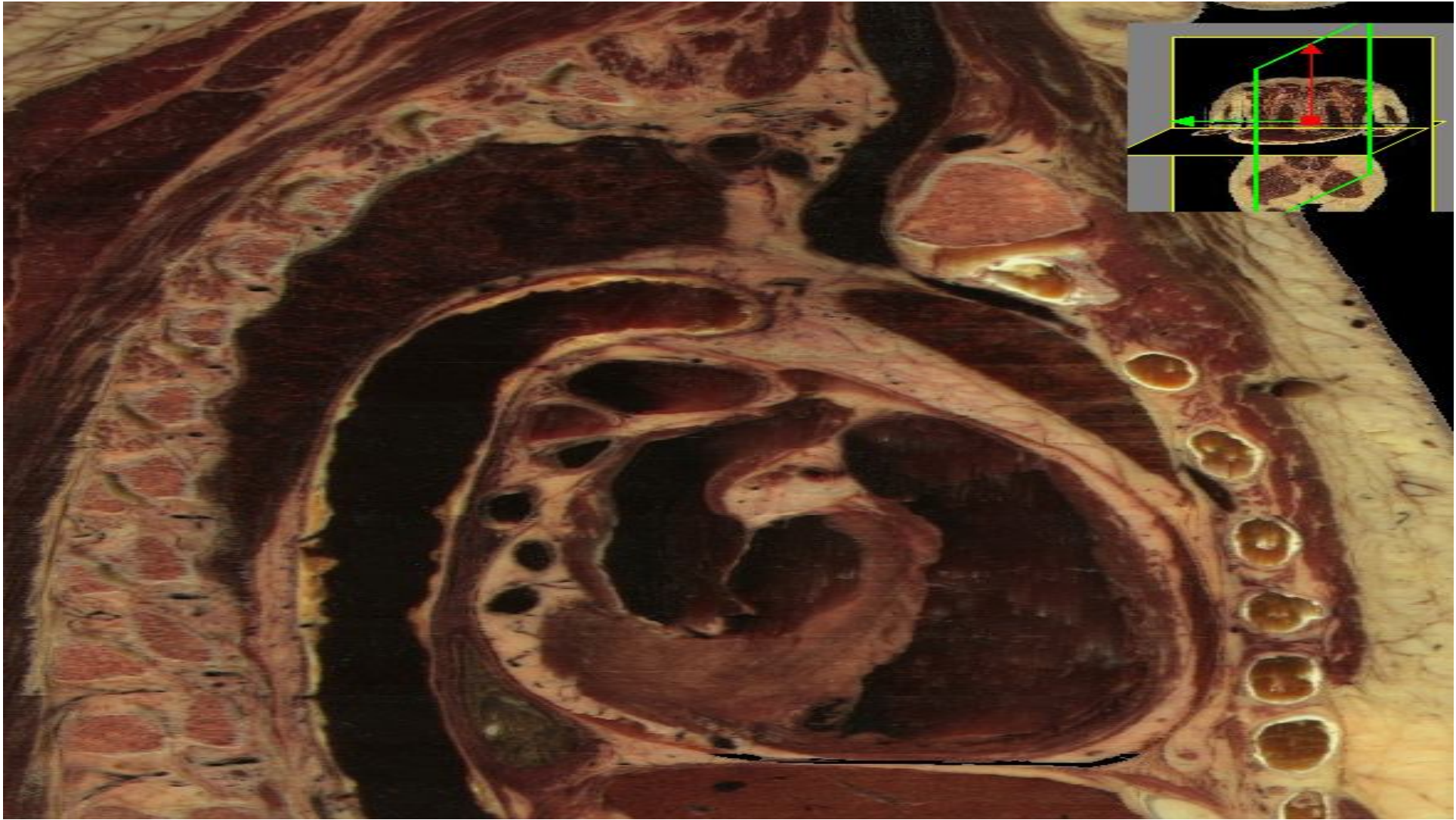
Adult remnants of fetal circulation

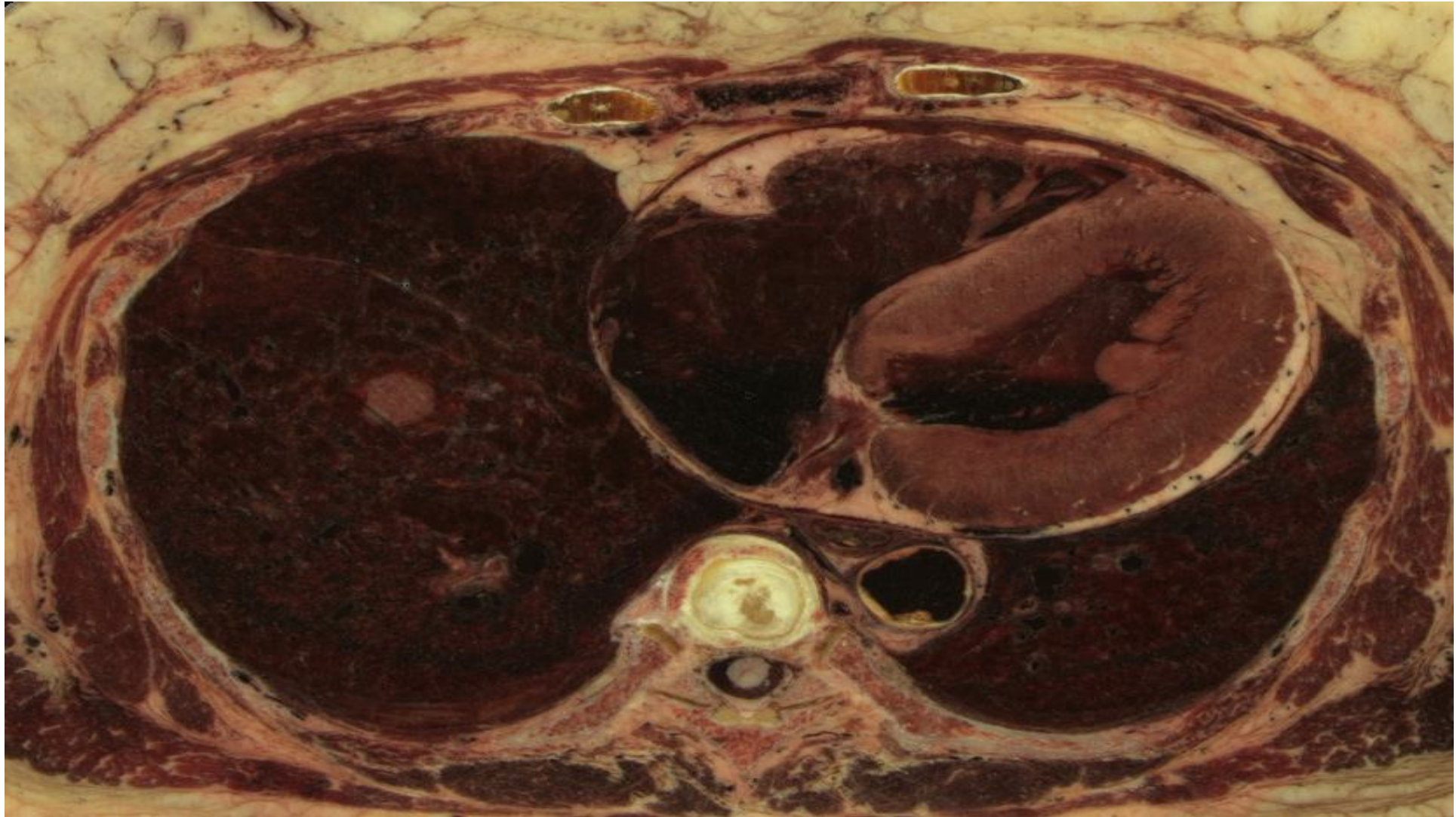
| Adult | Fetus |
|--|--------------------------------|
| Fossa ovale | Foramen ovale |
| Ligamentum arteriosum | Ductus arteriosus |
| Medial umbilical ligaments | Umbilical aa.(within fetus) |
| Round ligament (ligamentum teres) of liver | Umbilical v.(within fetus) |
| Ligamentum venosum | Ductus venosus |
| Medial umbilical ligament | Umbilical cord (leaving fetus) |

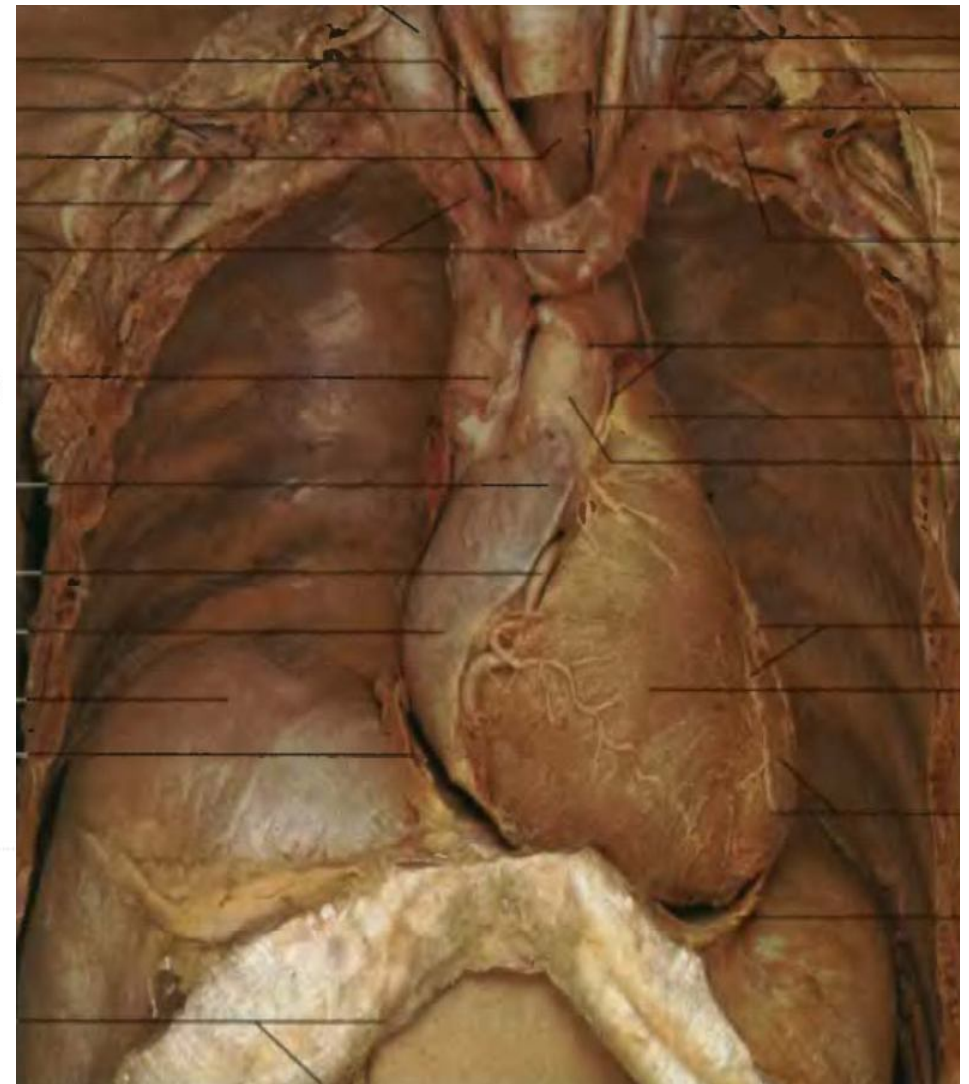
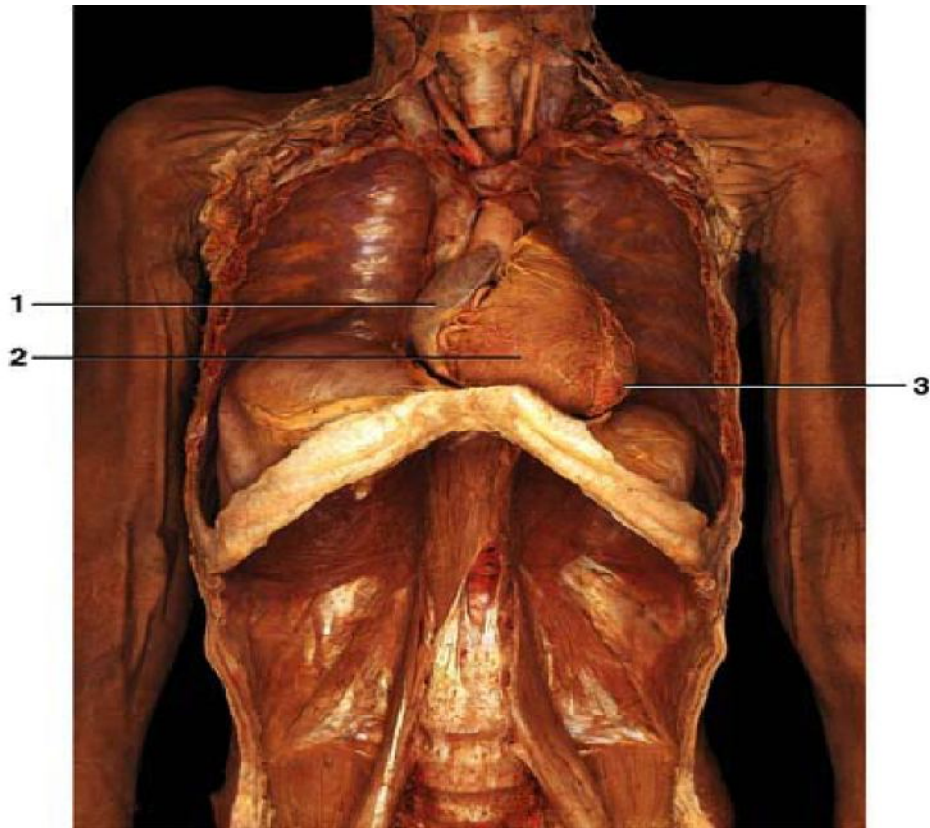
Heart Anatomy

- Approximately the size of your fist
- Location
 - ▣ Superior surface of diaphragm
 - ▣ Left of the midline
 - ▣ Anterior to the vertebral column, posterior to the sternum
- The **heart** is positioned obliquely between the
- lungs in the mediastinum









1.5

1. right atrium; forms right border of heart
2. right ventricle; forms most of sternocostal surface of heart
3. left ventricle; forms most of left border of heart

Orientation of the Heart

The heart and roots of the great vessels within the pericardial sac are related anteriorly

- to the sternum,
- costal cartilages,
- and the medial ends of the **3rd and 5th ribs on the left side**.

The heart and pericardial sac are situated obliquely, about two thirds to the left and one third to the right of the median plane.

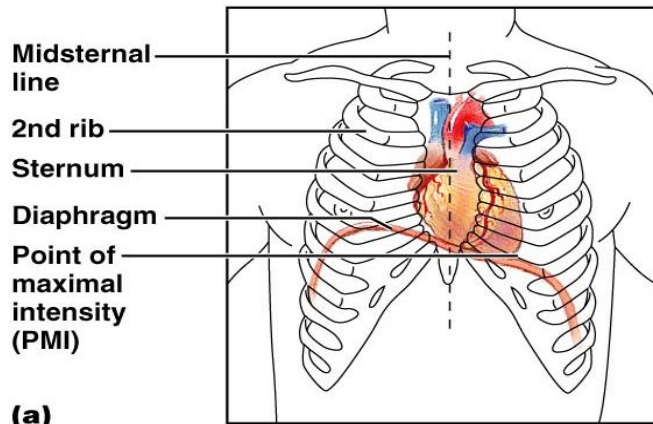
The heart is shaped like a tippedover, three-sided pyramid with an **apex, base, and four surfaces**.

The apex of the heart

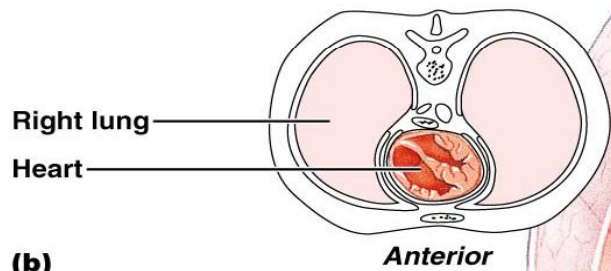
- Is directed anteriorly and to the left and is formed by the inferolateral part of the left ventricle.
- Is located posterior to the left 5th intercostal space in adults, usually 9 cm from the median plane.
- Is where the sounds of mitral valve closure are maximal (apex beat); the apex underlies the site where the

The base of the heart

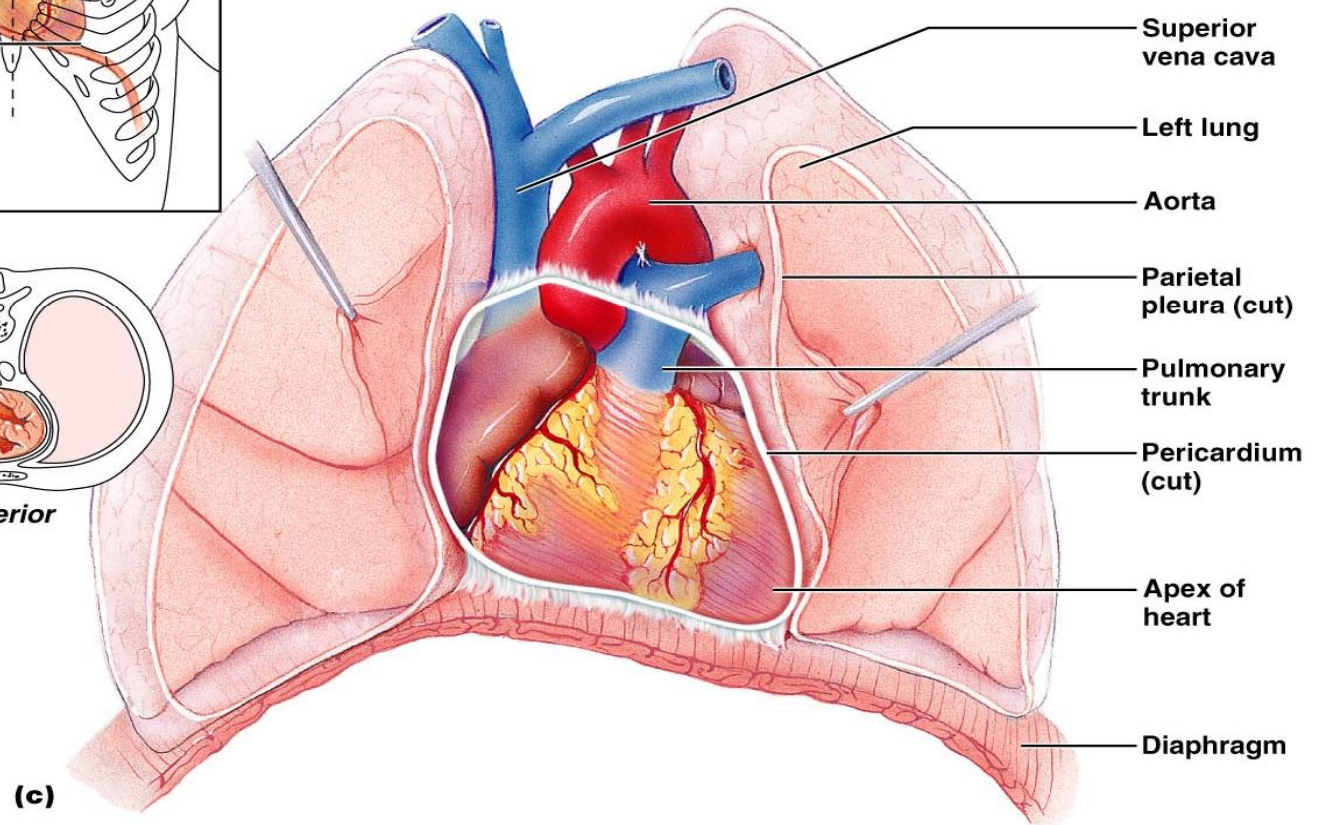
- Is the heart's posterior aspect.
- Is formed mainly by the left atrium, with a lesser contribution by the right atrium.
- Faces posteriorly toward the bodies of vertebrae T6/T9, and is separated from them by
 - *the pericardium,*
 - *oblique pericardial sinus,*
 - *esophagus, and aorta.*
- Extends superiorly to the bifurcation of the pulmonary trunk and inferiorly to the coronary groove.
- Receives the pulmonary veins on the right and left sides of its left atrial portion and the superior and inferior venae cavae at the superior and inferior ends of its right atrial portion.



(a)

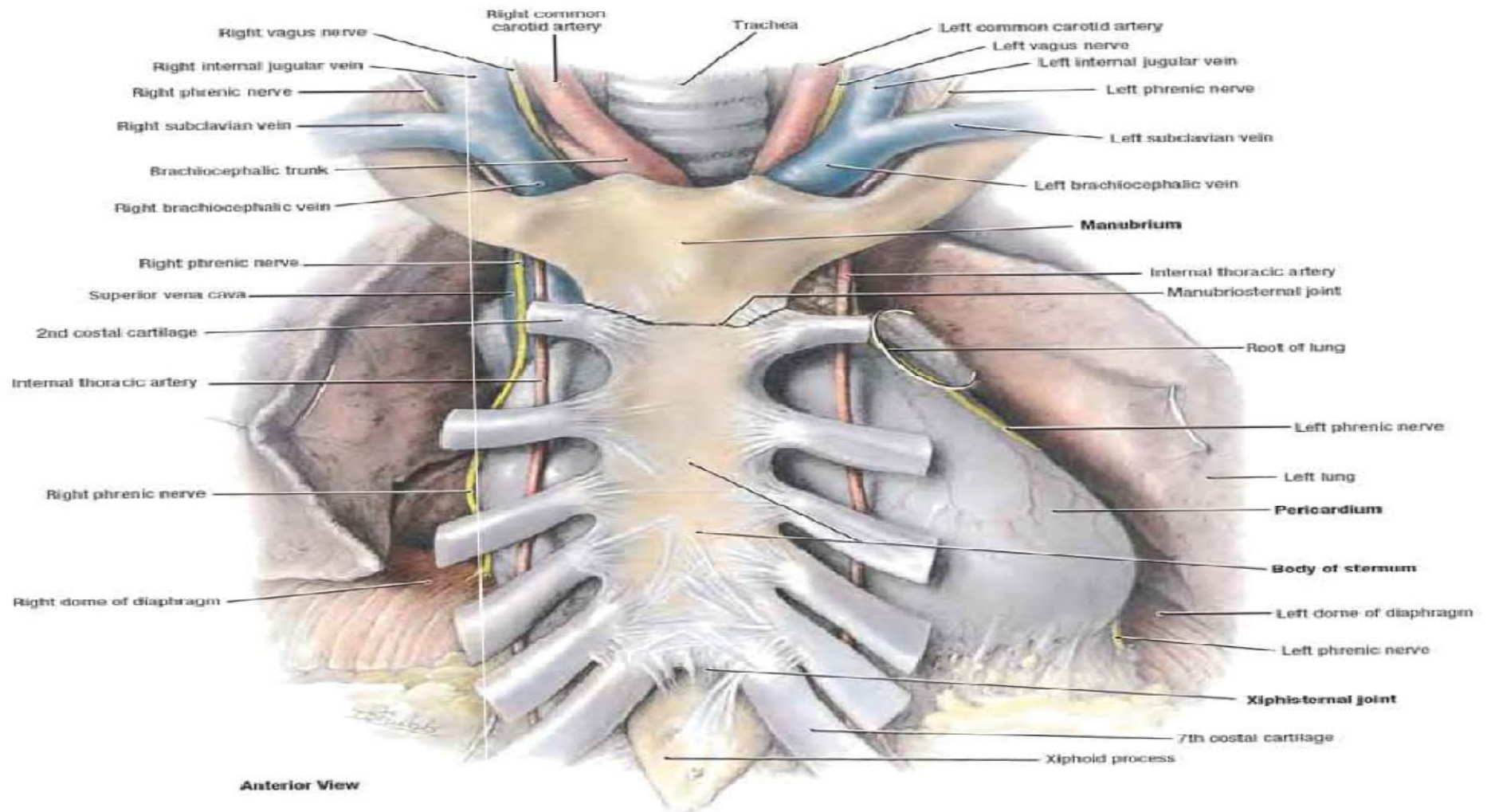


(b)



(c)

Figure 10.1

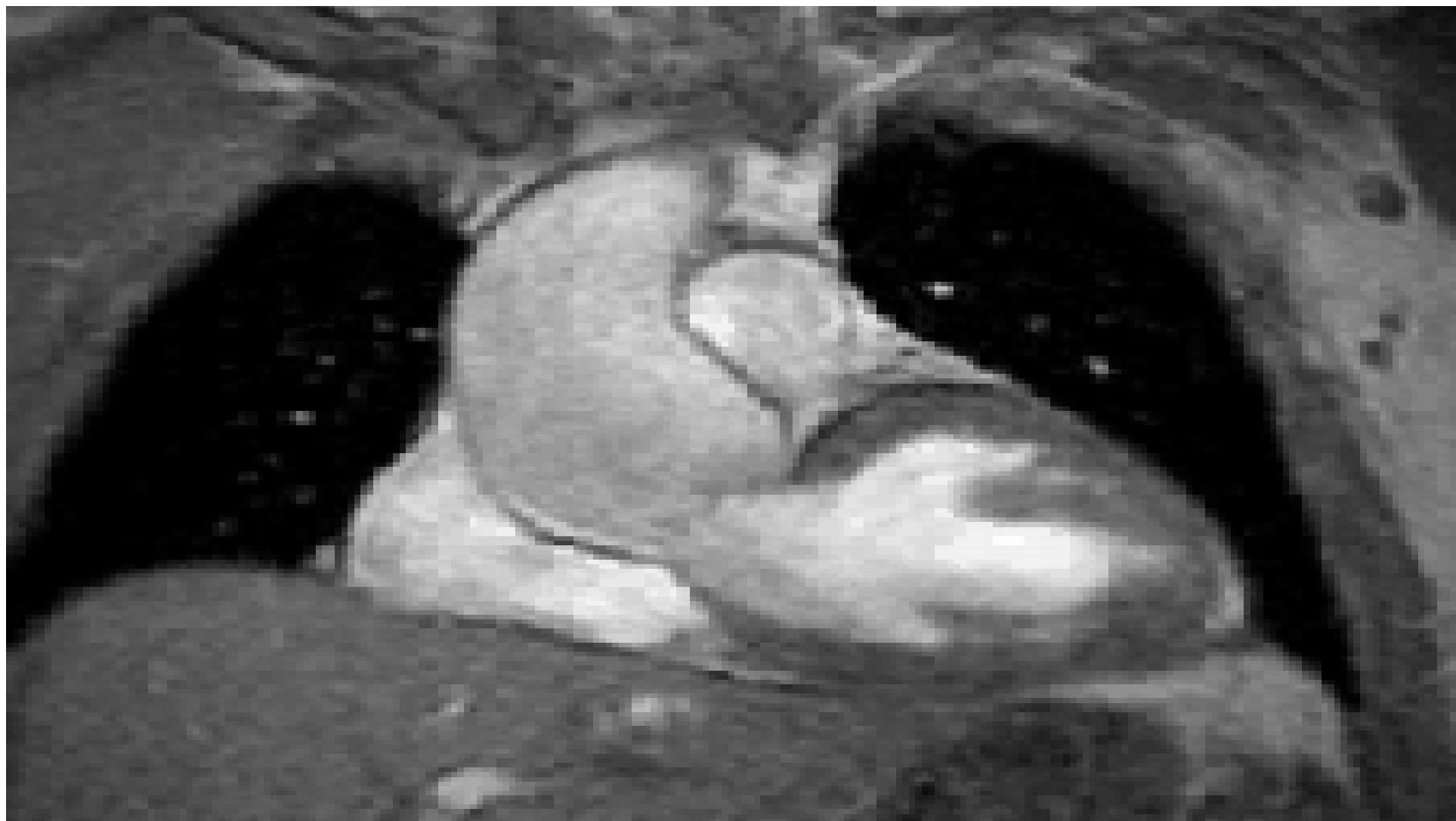

- **Anterior (sternocostal) surface**, formed mainly by the right ventricle.
- **Diaphragmatic (inferior) surface**, formed mainly by the left ventricle and partly by the right ventricle; it is related to the central tendon of the diaphragm.
- **Left pulmonary surface**, formed mainly by the left ventricle; it forms the cardiac impression of the left lung.
- **Right pulmonary surface**, formed mainly by the right atrium.

The heart appears trapezoidal in both anterior and posterior views.

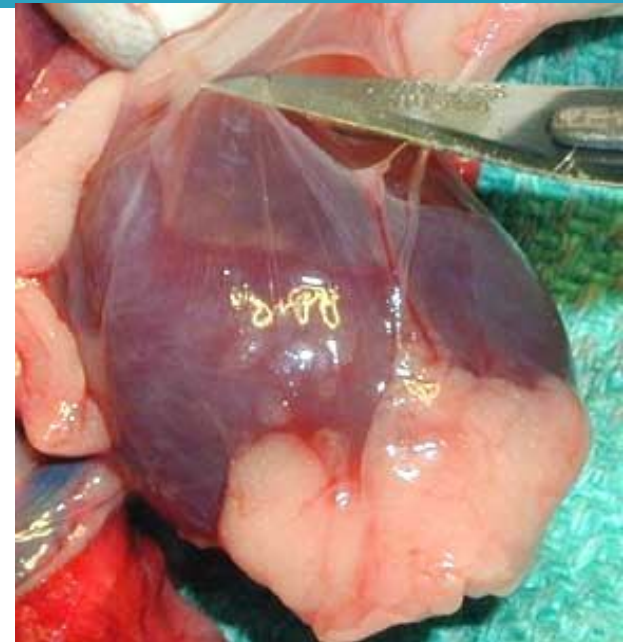
The four borders of the heart are the

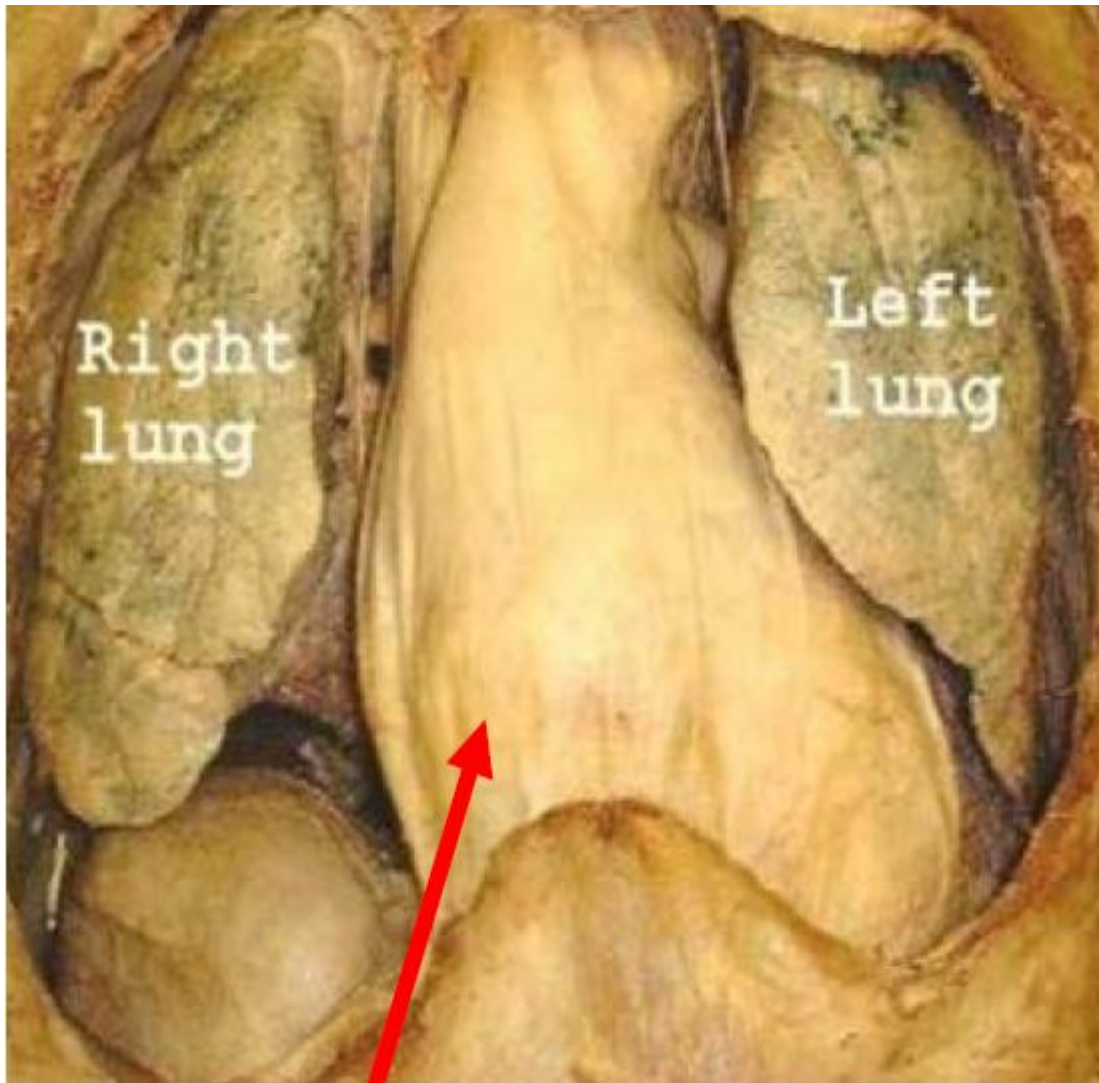
- **Right border** (slightly convex), formed by the right atrium and extending between the SVC and the IVC.
- **Inferior border** (nearly horizontal), formed mainly by the right ventricle and only slightly by the left ventricle.
- **Left border** (oblique), formed mainly by the left ventricle and slightly by the left auricle.
- **Superior border**, formed by the right and left atria and auricles in an anterior view; the ascending aorta and pulmonary trunk emerge from the superior border, and the SVC enters its right side. Posterior to the aorta and pulmonary trunk and anterior to the SVC, the superior border forms the inferior boundary of the transverse pericardial sinus.



Coverings of the Heart: Anatomy

- Pericardium – a double-walled sac around the heart composed of:
 - ▣ A superficial fibrous pericardium
 - ▣ A deep two-layer serous pericardium
 - The parietal layer lines the internal surface of the fibrous pericardium
 - The visceral layer or epicardium lines the surface of the heart
 - They are separated by the fluid-filled pericardial cavity



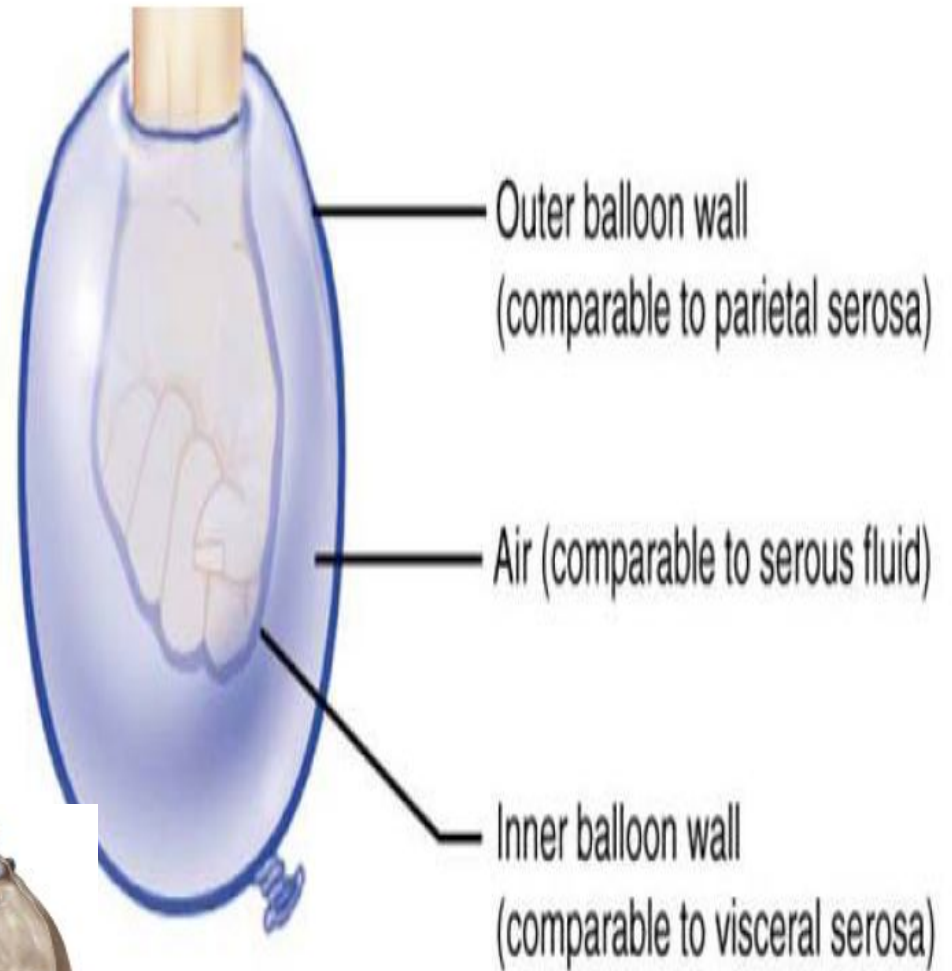
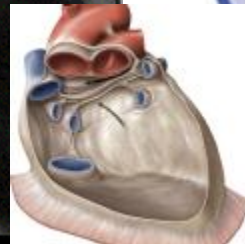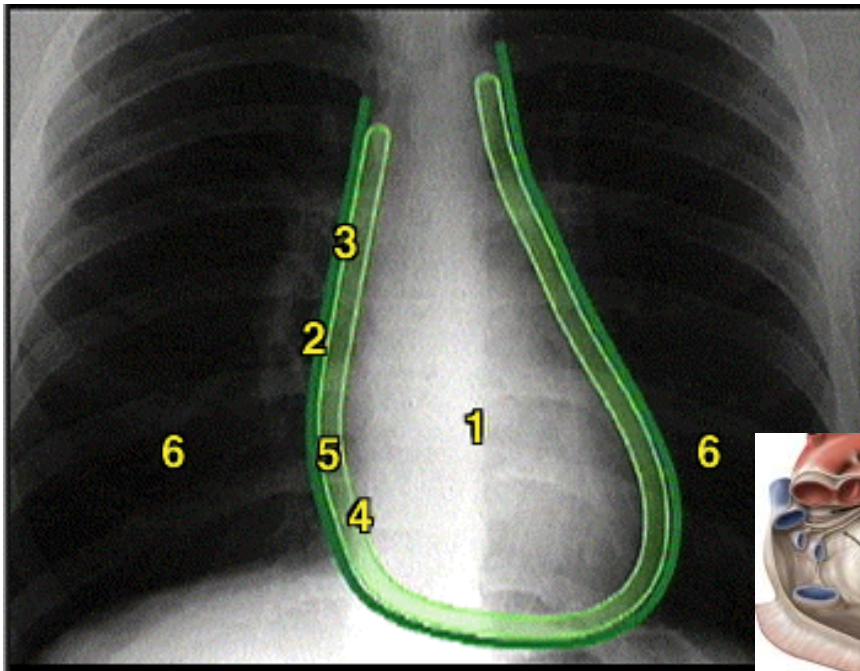


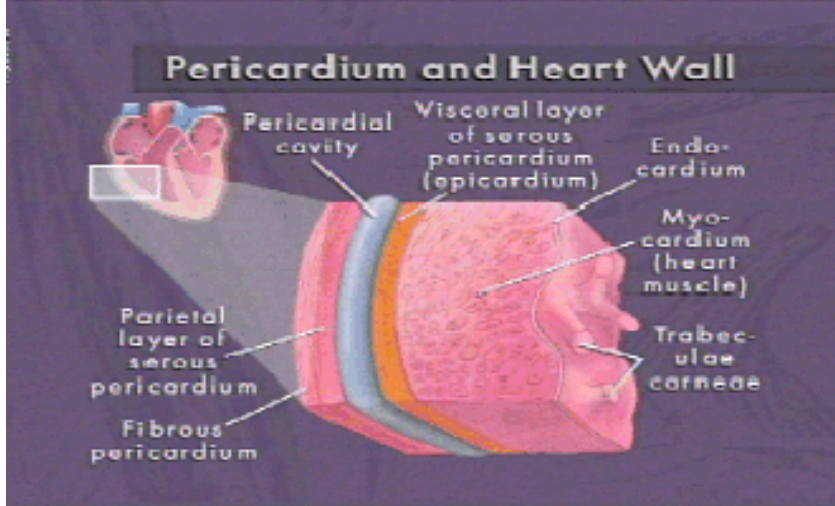
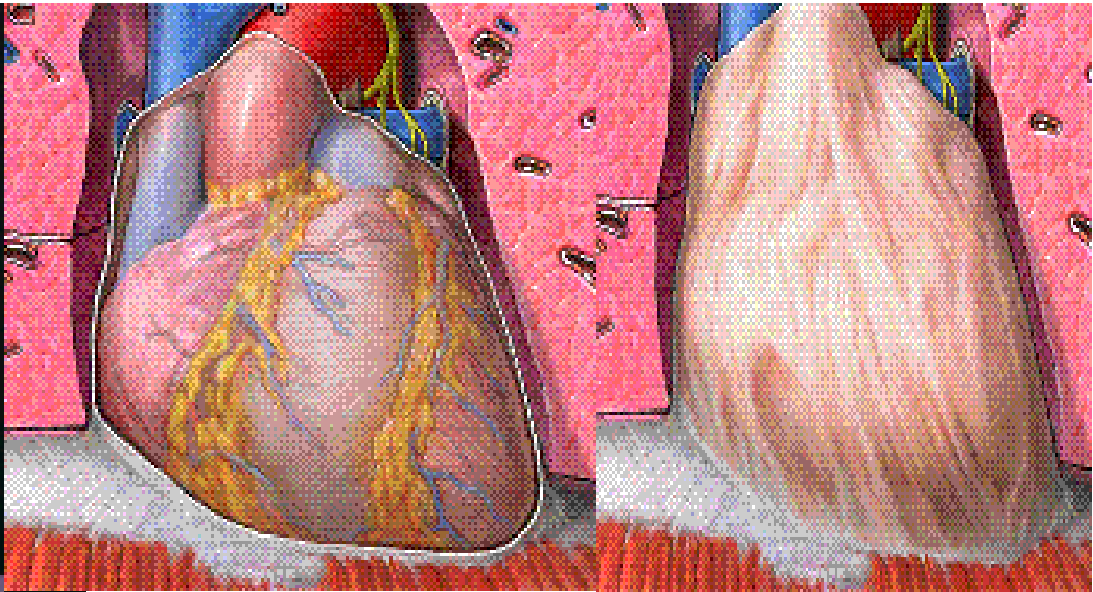
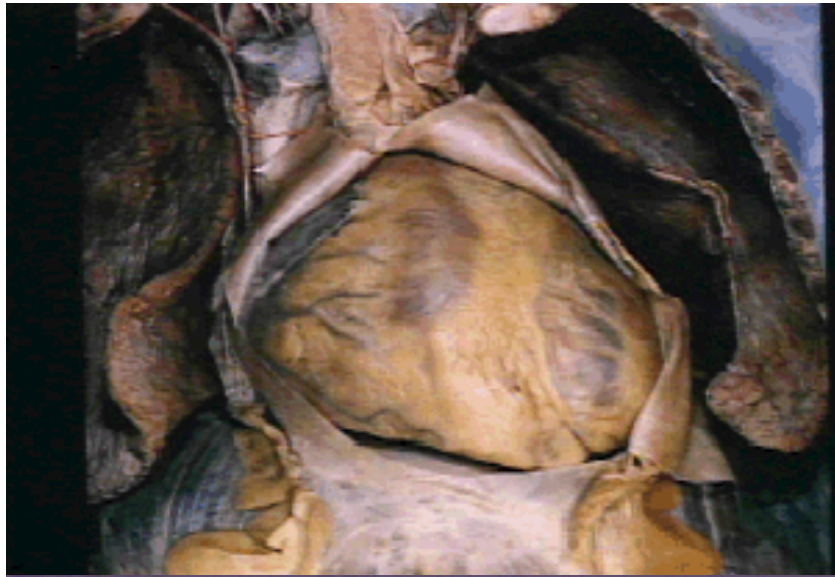Fibrous Pericardium

- Collagenous sac enclosing the heart.
- Stabilizes heart's position and prevents over distention.

Serous Pericardium

- Deep to the fibrous pericardium.
- 2 layered structure.
- Relationship with the heart is similar to that of a fist punching a balloon.





Epicardium

Corresponds to the visceral pericardium.

Functions as an outer protective layer.

Serous membrane that consists of connective tissue covered by epithelium.

Includes blood capillaries, lymph capillaries, and nerve fibers.

Myocardium

Relatively thick.

Consists largely of cardiac muscle tissue **responsible for forcing blood out of the heart chambers.**

Muscle fibers are arranged in planes, separated by connective tissues that are richly supplied with blood capillaries, and nerve fibers.

Endocardium

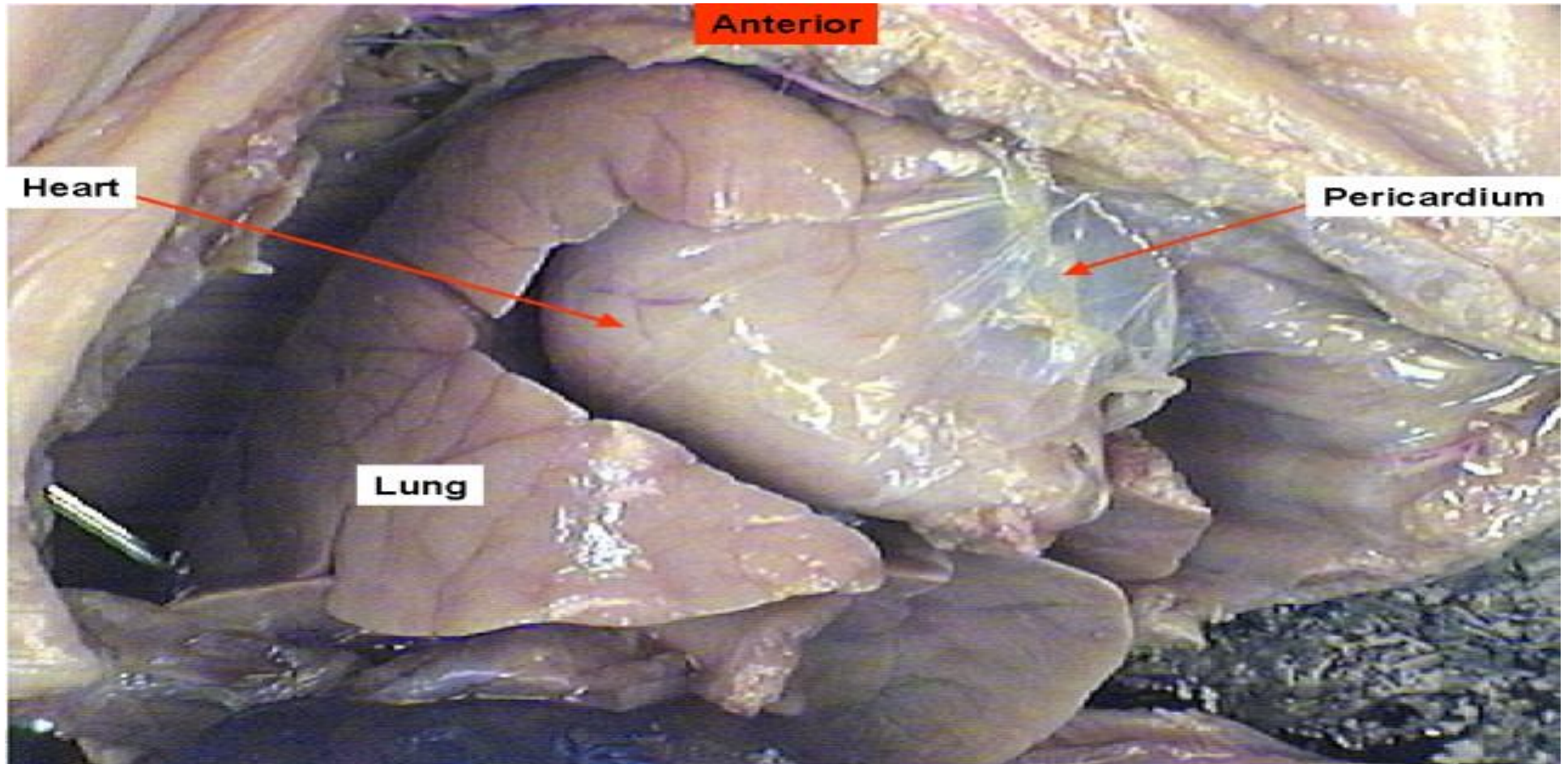
Consists of epithelial and connective tissue that contains many elastic and collagenous fibers.

Connective tissue also contains blood vessels and some **specialized cardiac muscle fibers called Purkinje fibers.**

Lines all of the heart chambers and covers heart valves.

Is continuous with the inner lining of blood vessels--**endothelium.**

Pericardium



Coverings of the Heart: Physiology

- **The pericardium function :**
 - ▣ *Protects and anchors the heart*
 - ▣ *Prevents overfilling of the heart with blood*
 - ▣ *Allows for the heart to work in a relatively friction-free environment*

Pericardial Layers of the Heart

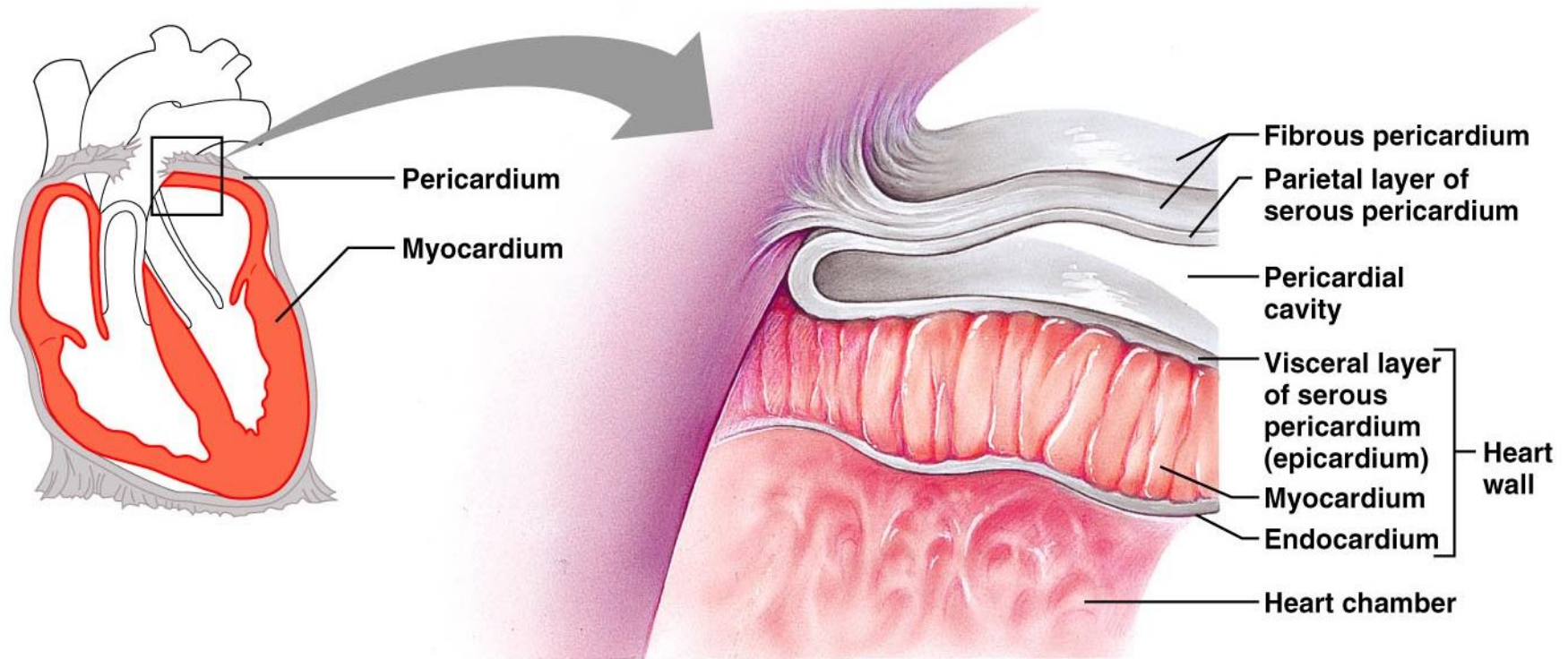
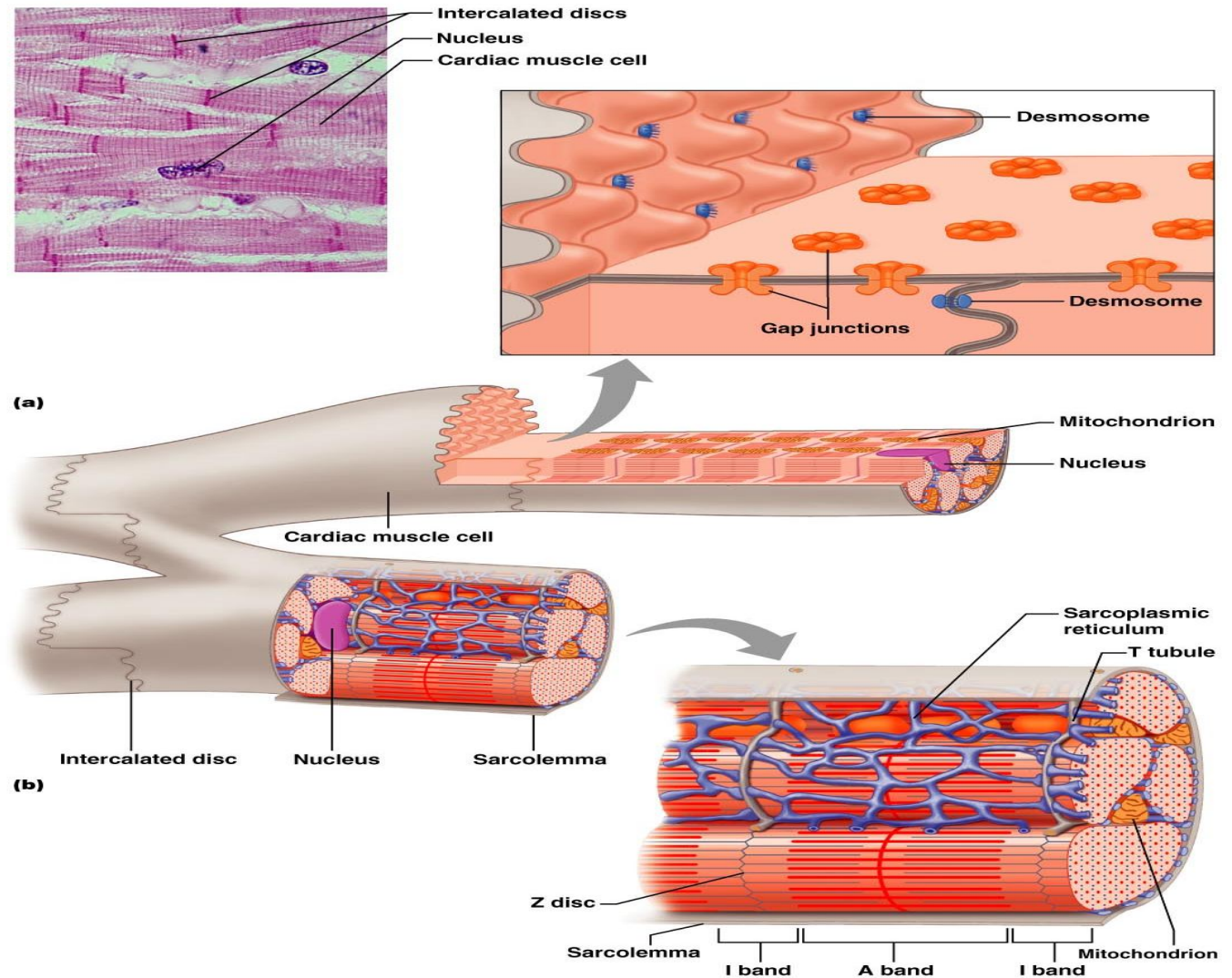


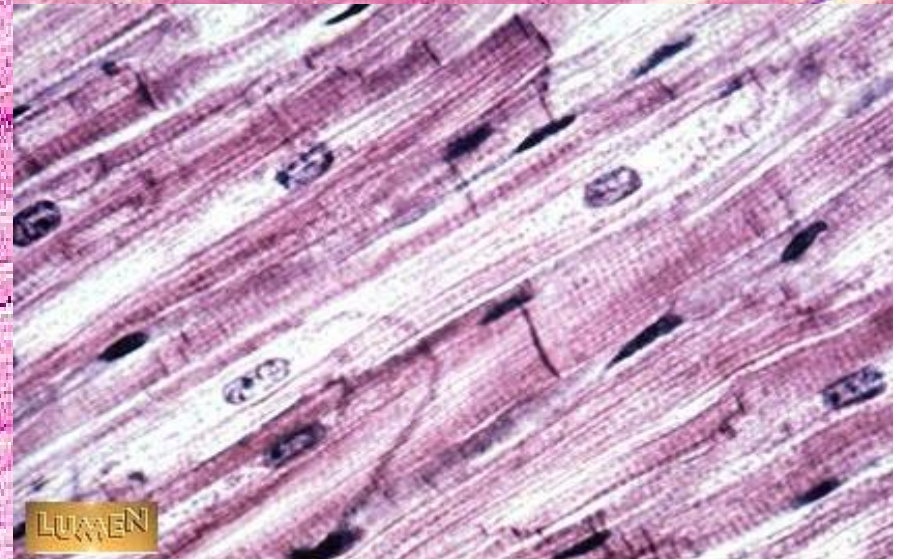
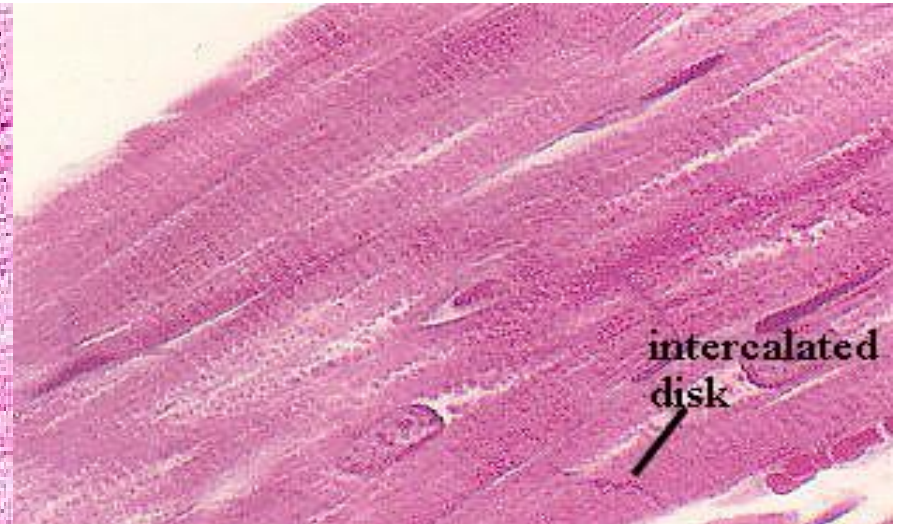
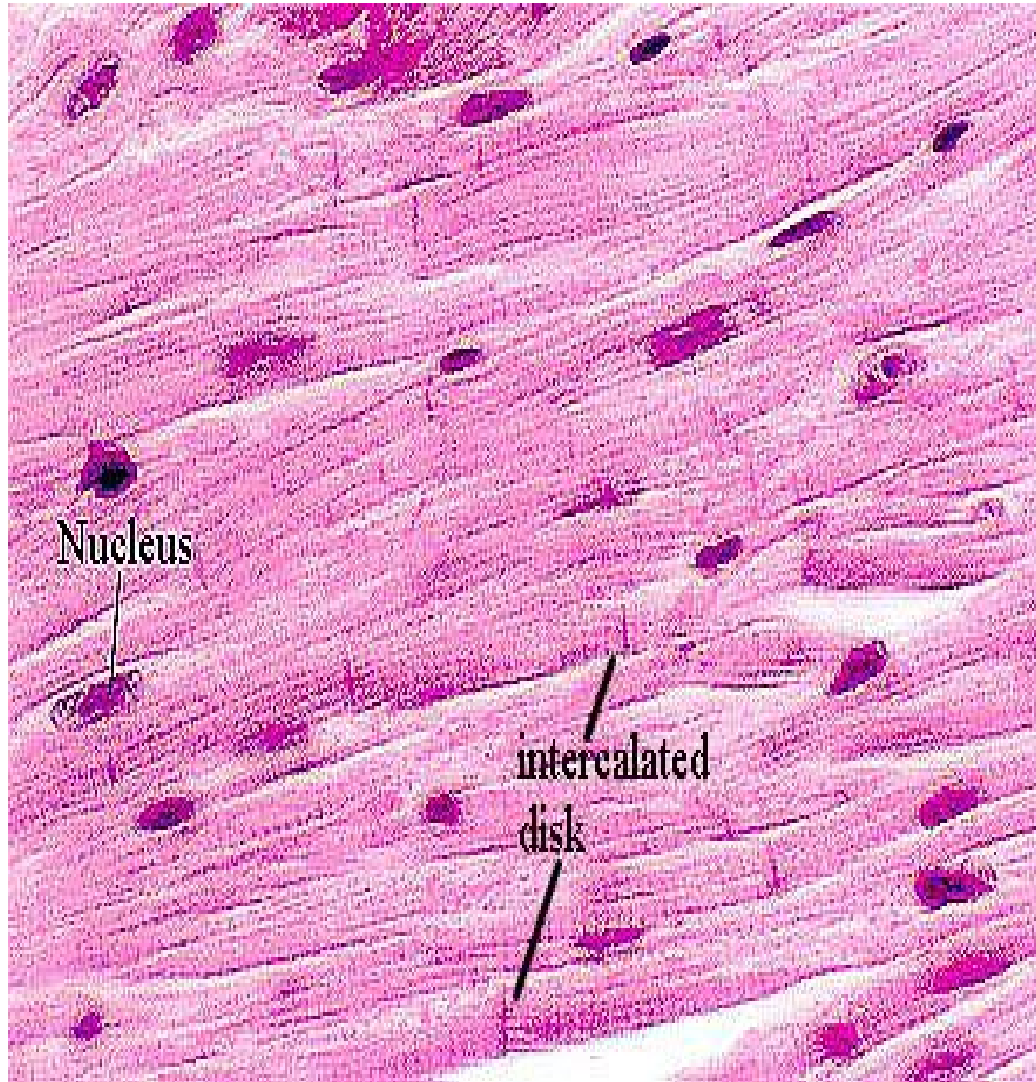
Figure 18.2

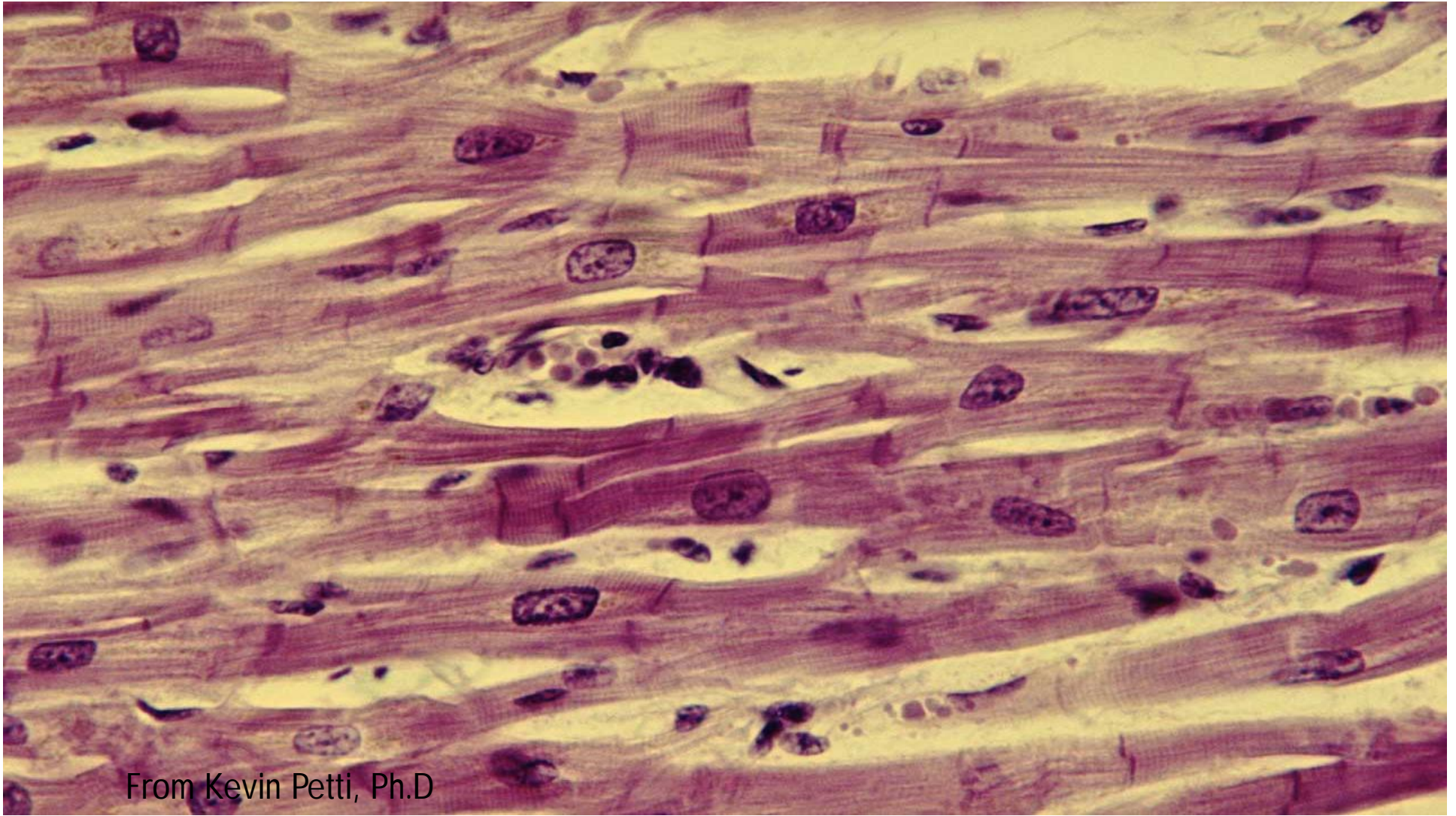
Microscopic Anatomy of Heart Muscle

- ❑ Cardiac muscle is striated, short, fat, branched, and interconnected
- ❑ The connective tissue endomysium acts as both tendon and insertion
- ❑ Intercalated discs anchor cardiac cells together and allow free passage of ions
- ❑ Heart muscle behaves as a functional syncytium

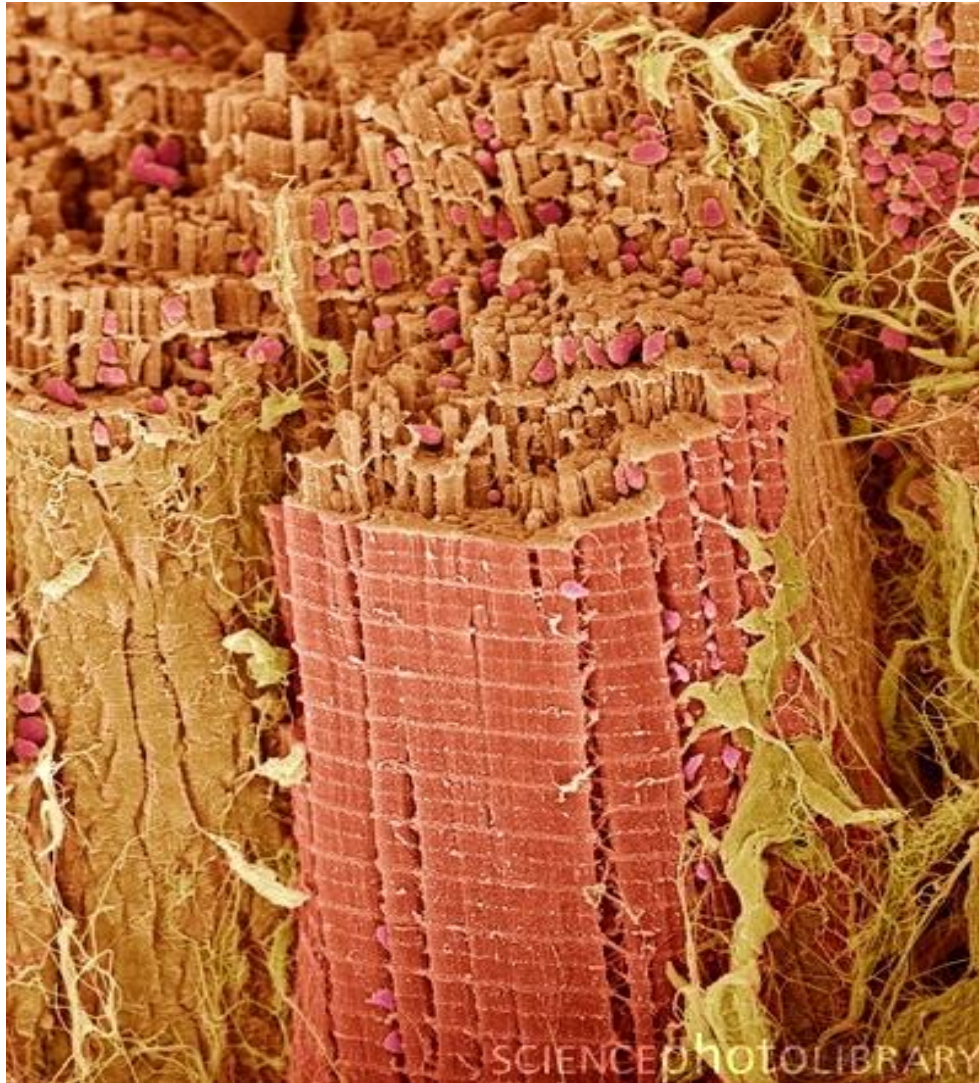
Microscopic Anatomy of Cardiac Muscle







From Kevin Petti, Ph.D

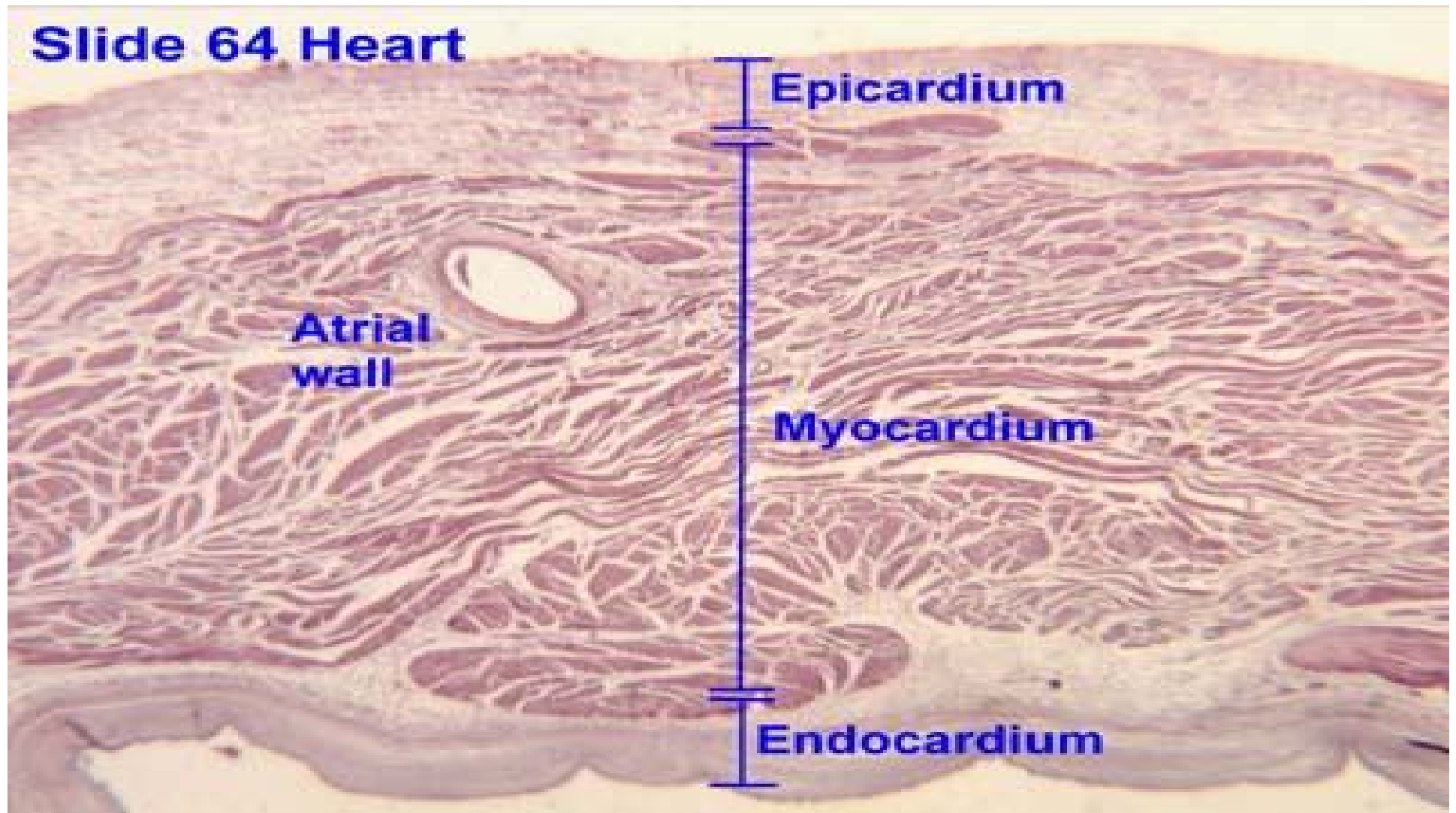


SCIENCEPHOTO LIBRARY

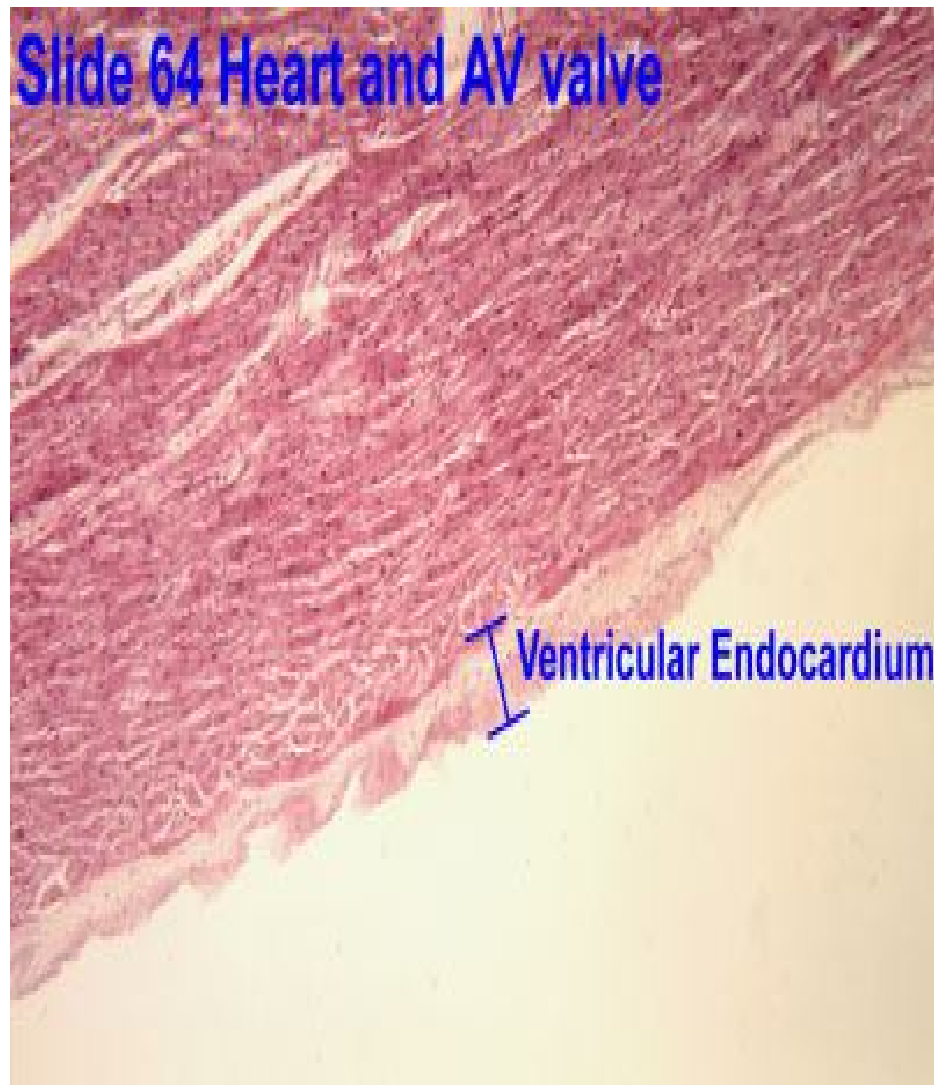
Heart Wall

- **Epicardium** – visceral layer of the serous pericardium
- **Myocardium** – cardiac muscle layer forming the bulk of the heart
- Fibrous skeleton of the heart – crisscrossing, interlacing layer of connective tissue
- **Endocardium** – endothelial layer of the inner myocardial surface

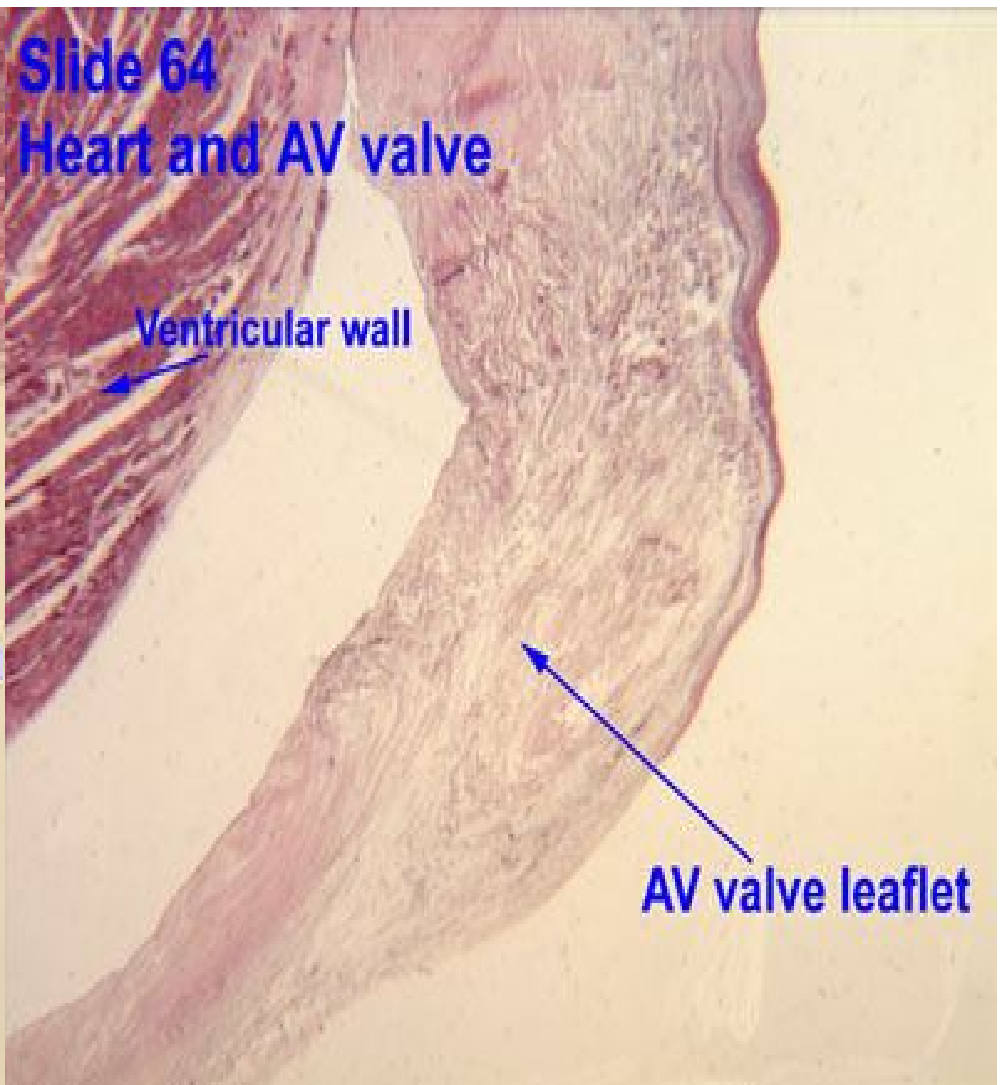
Slide 64 Heart



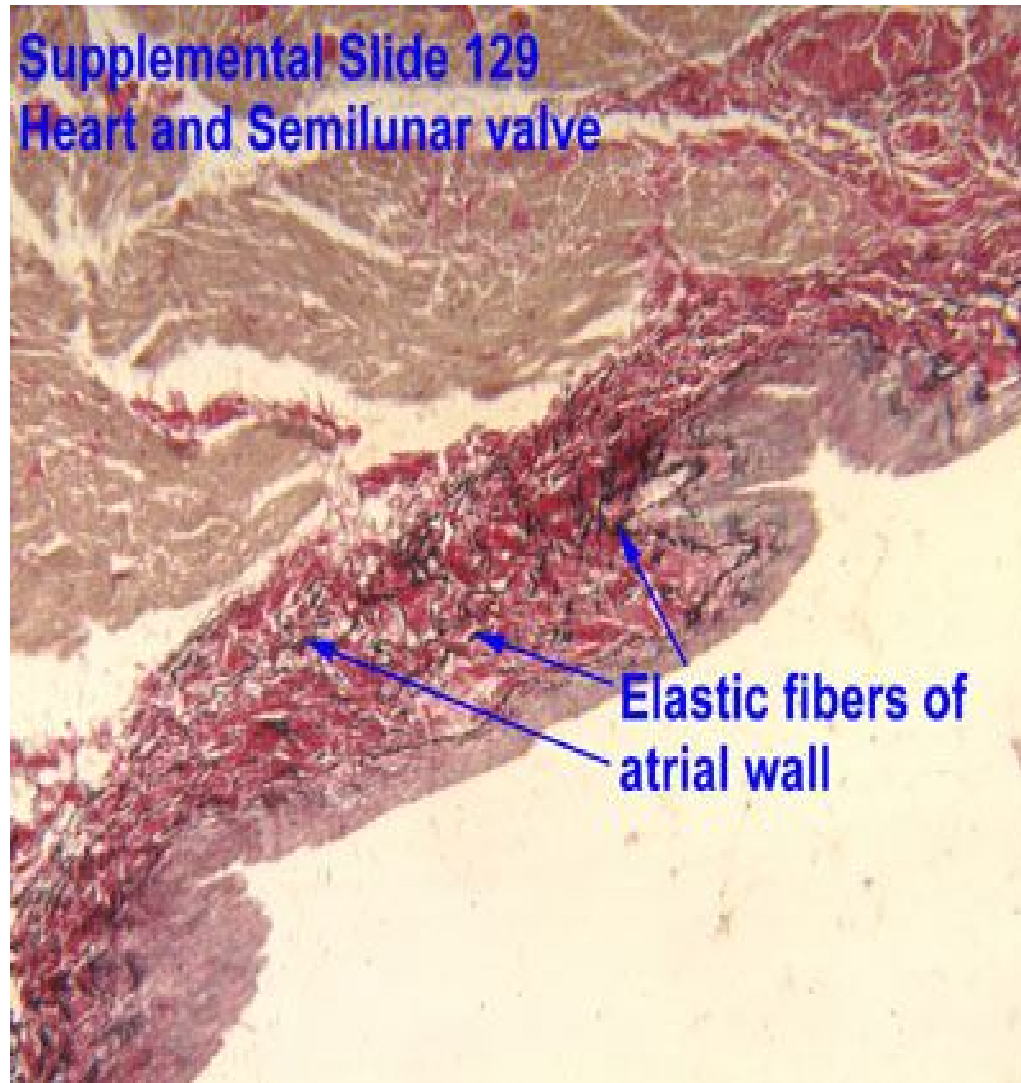
Slide 64 Heart and AV valve



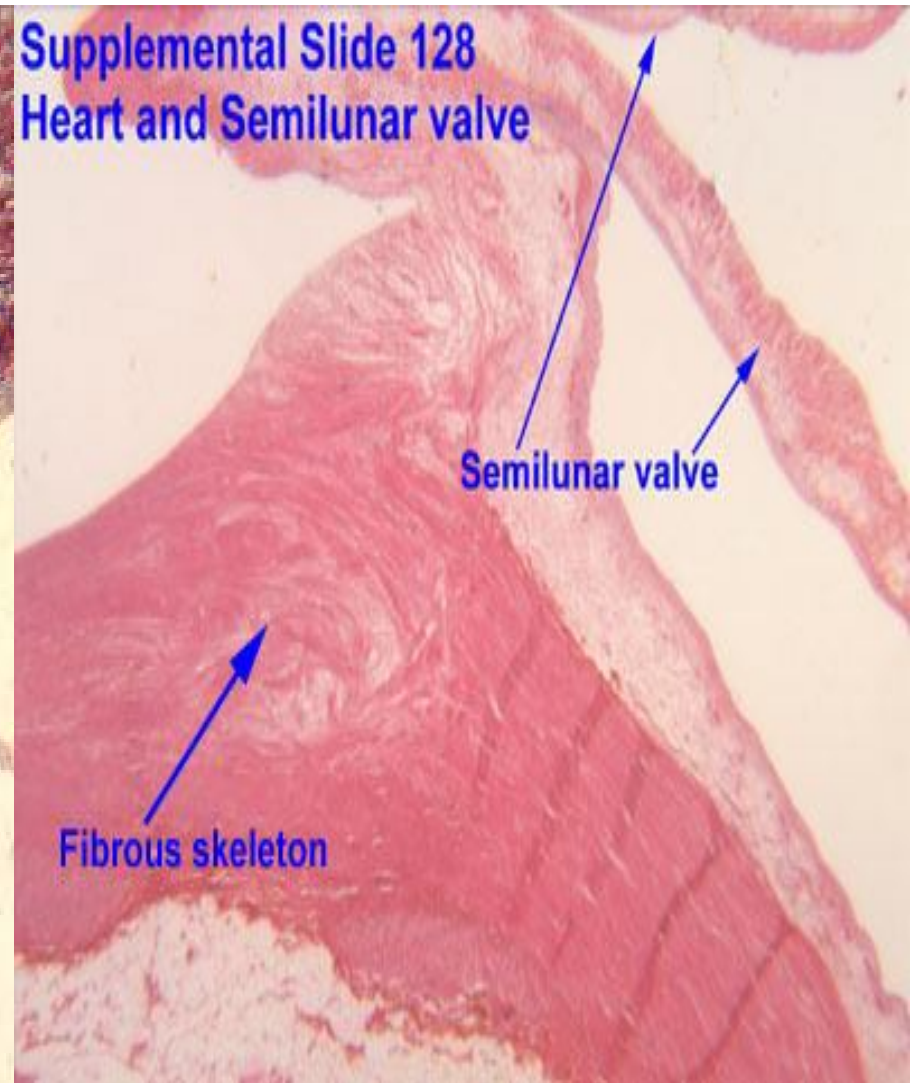
**Slide 64
Heart and AV valve**

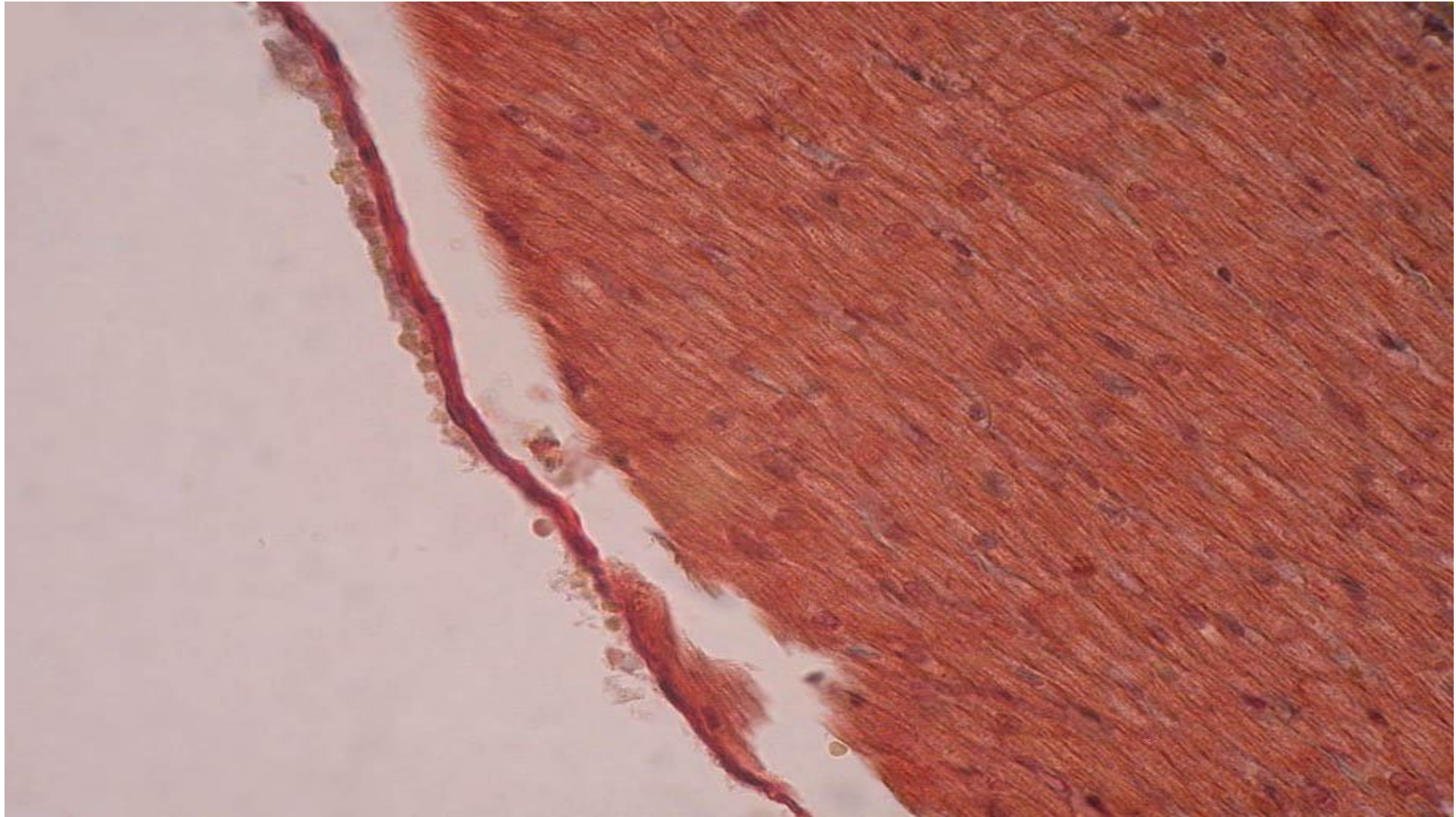


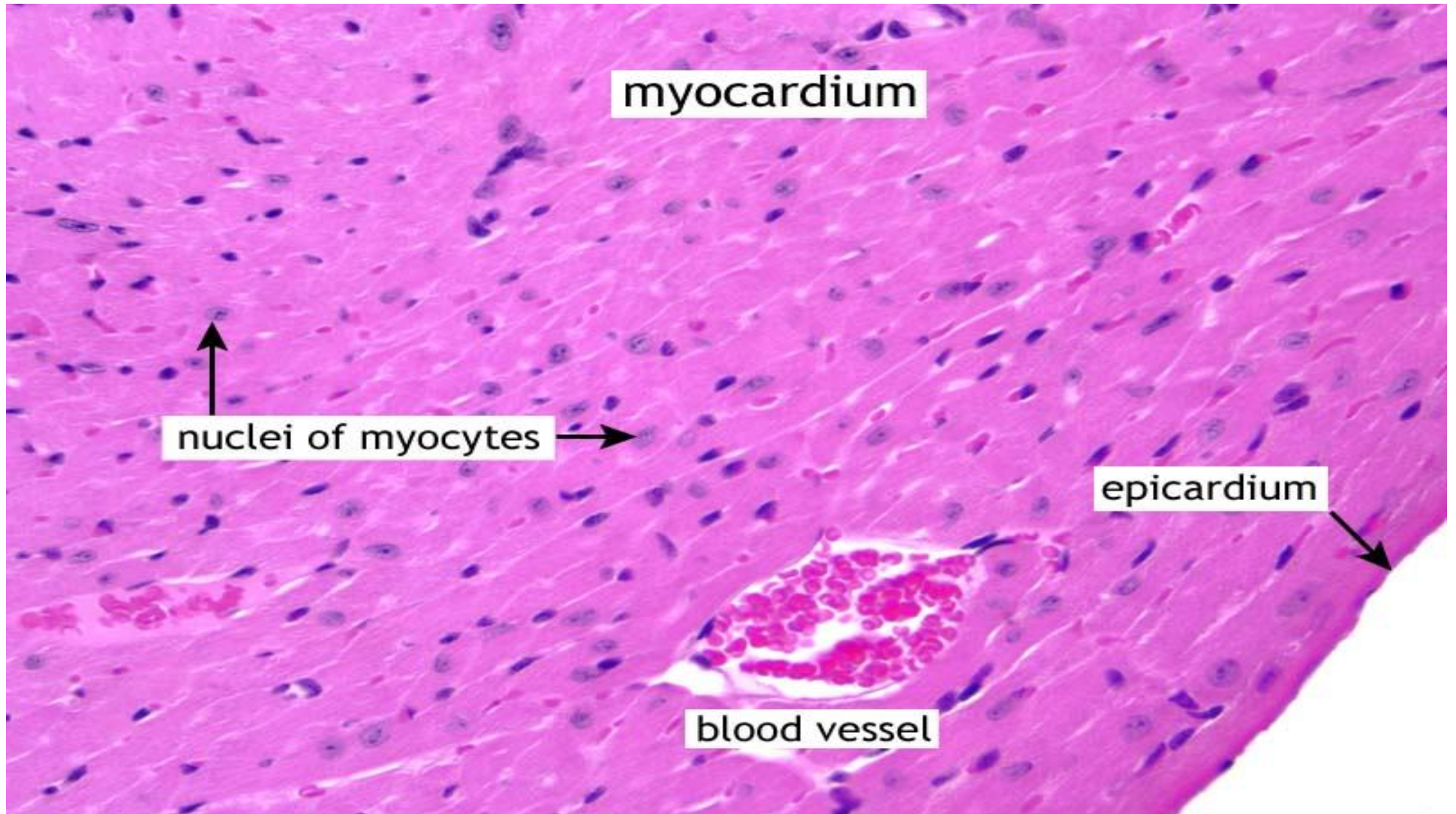
Supplemental Slide 129
Heart and Semilunar valve

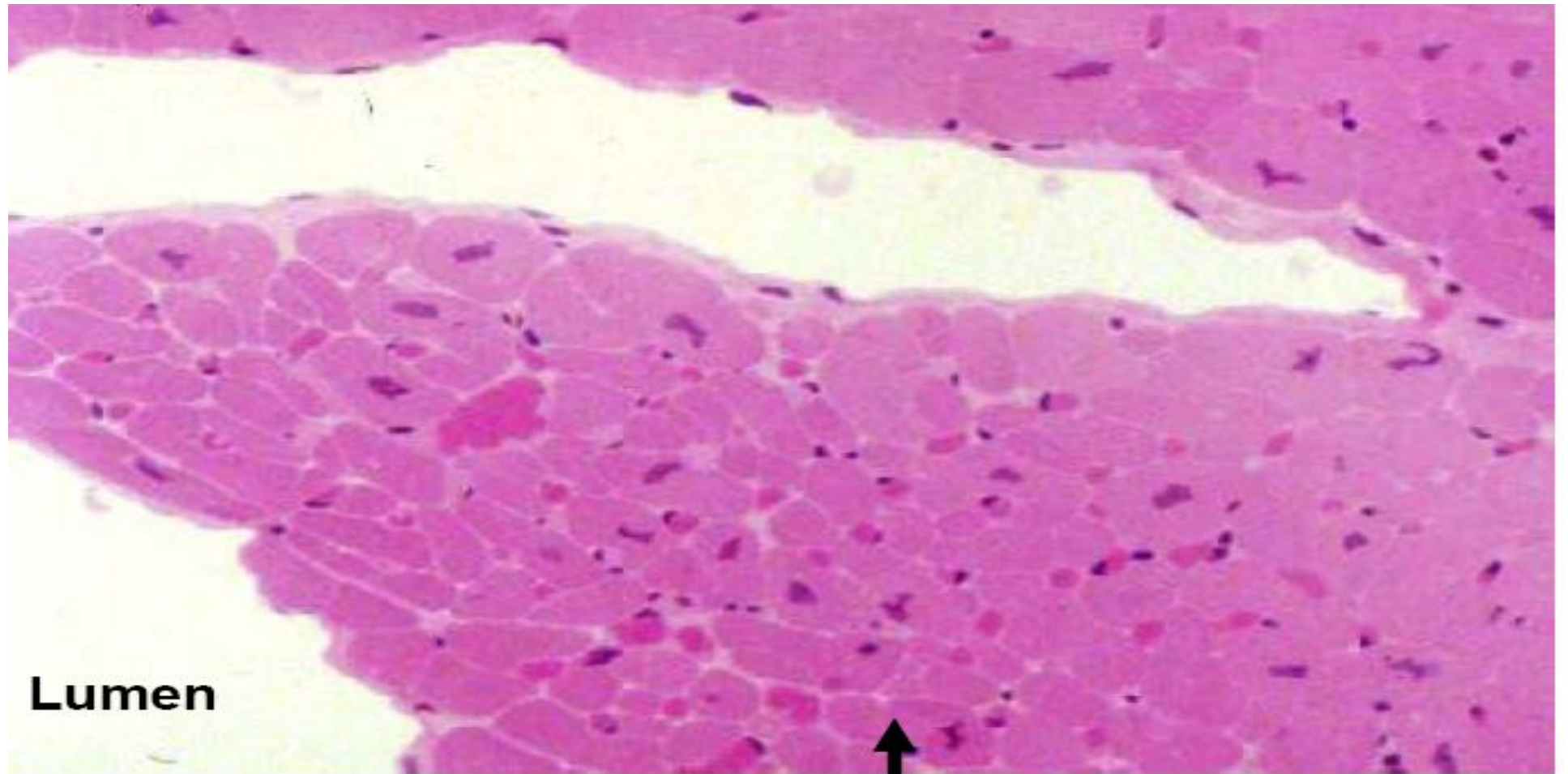


Supplemental Slide 128
Heart and Semilunar valve





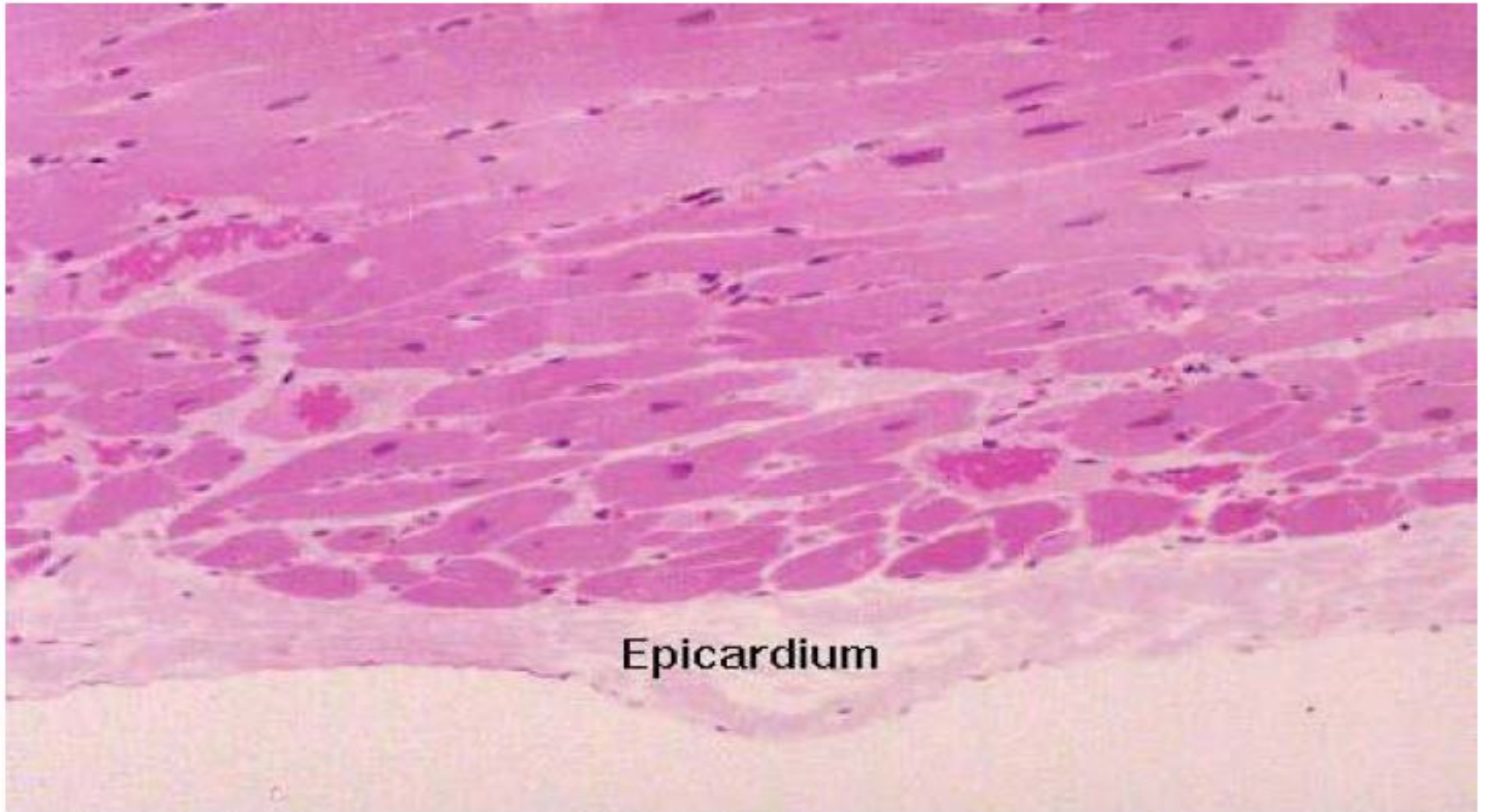




Lumen

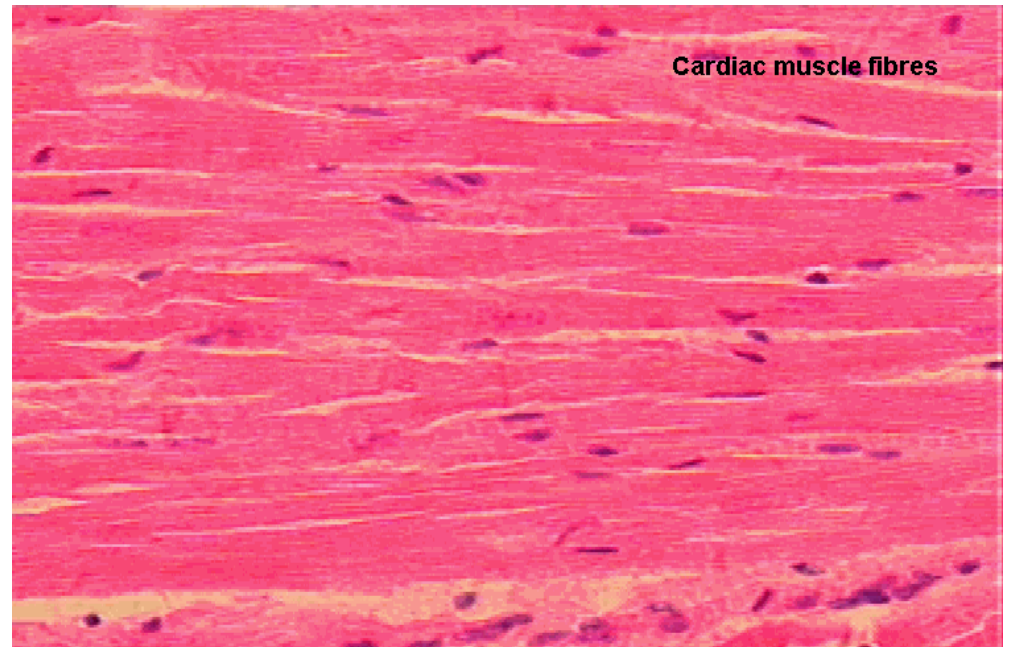
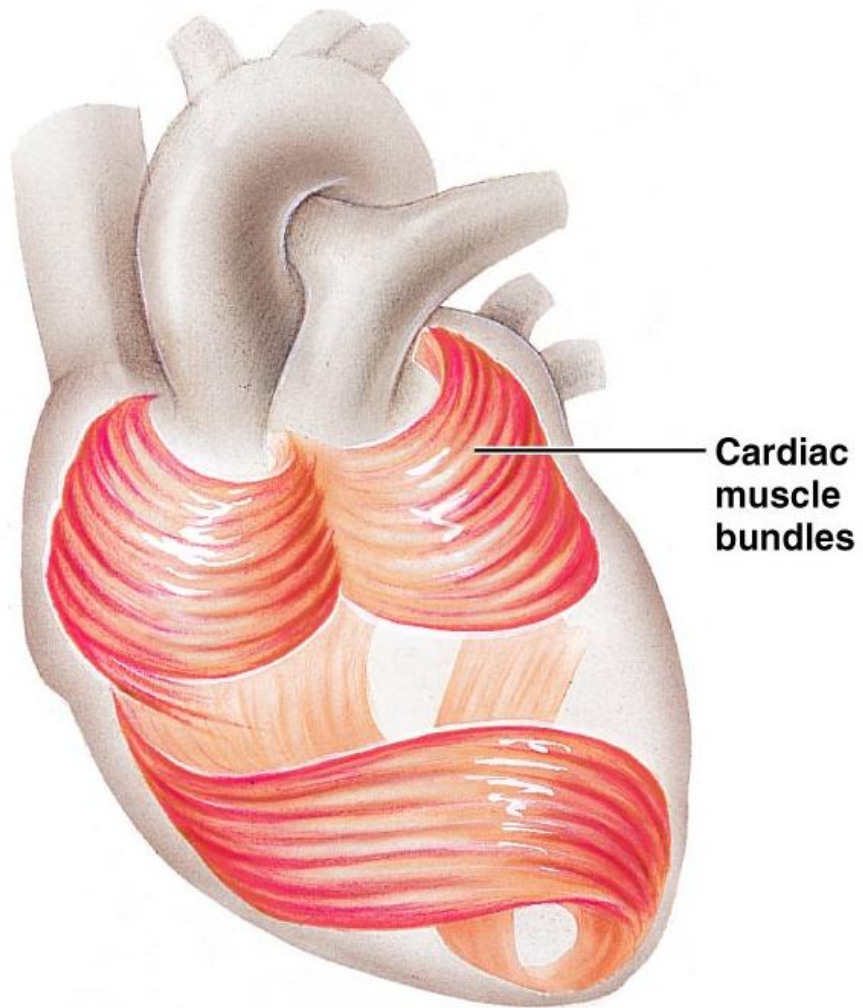


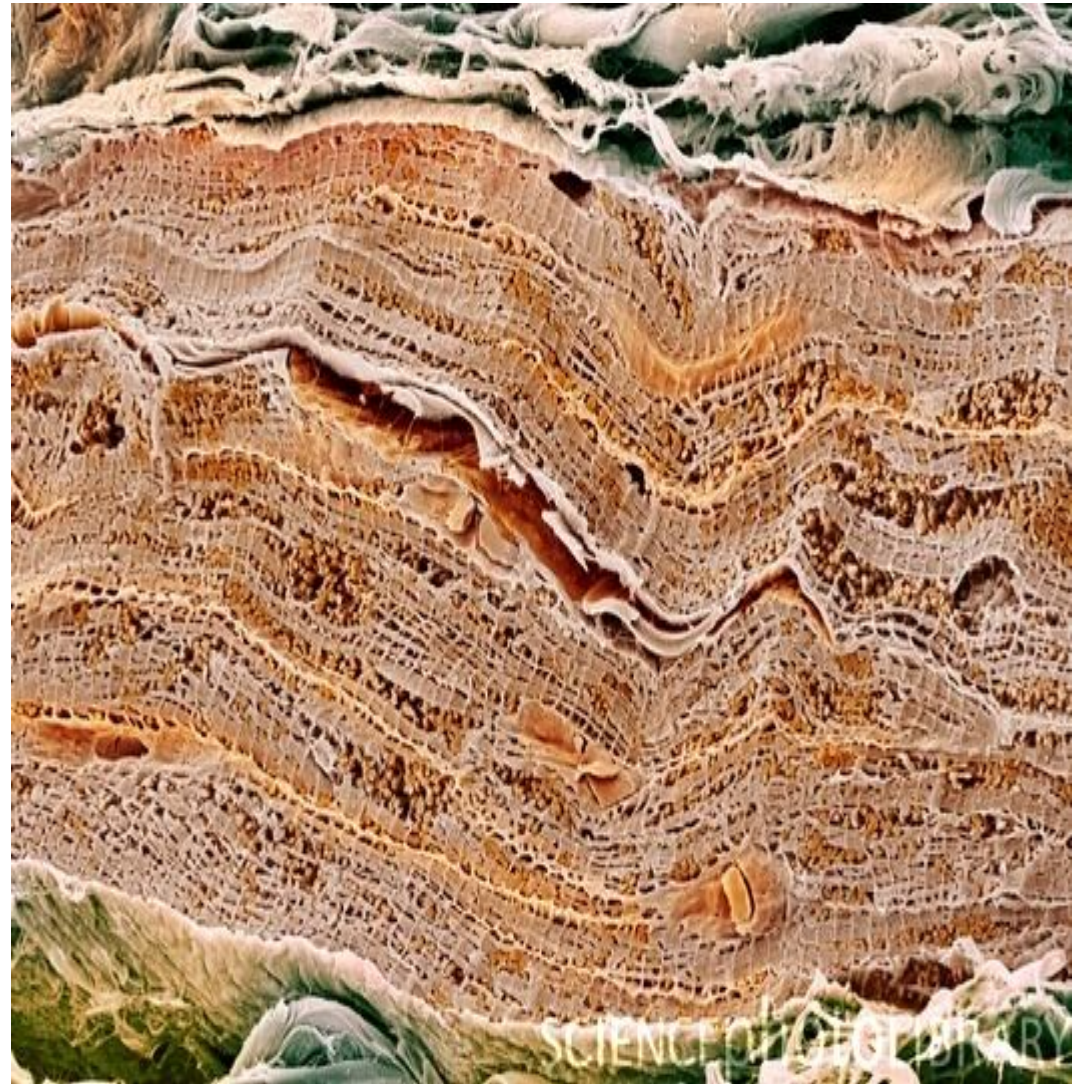
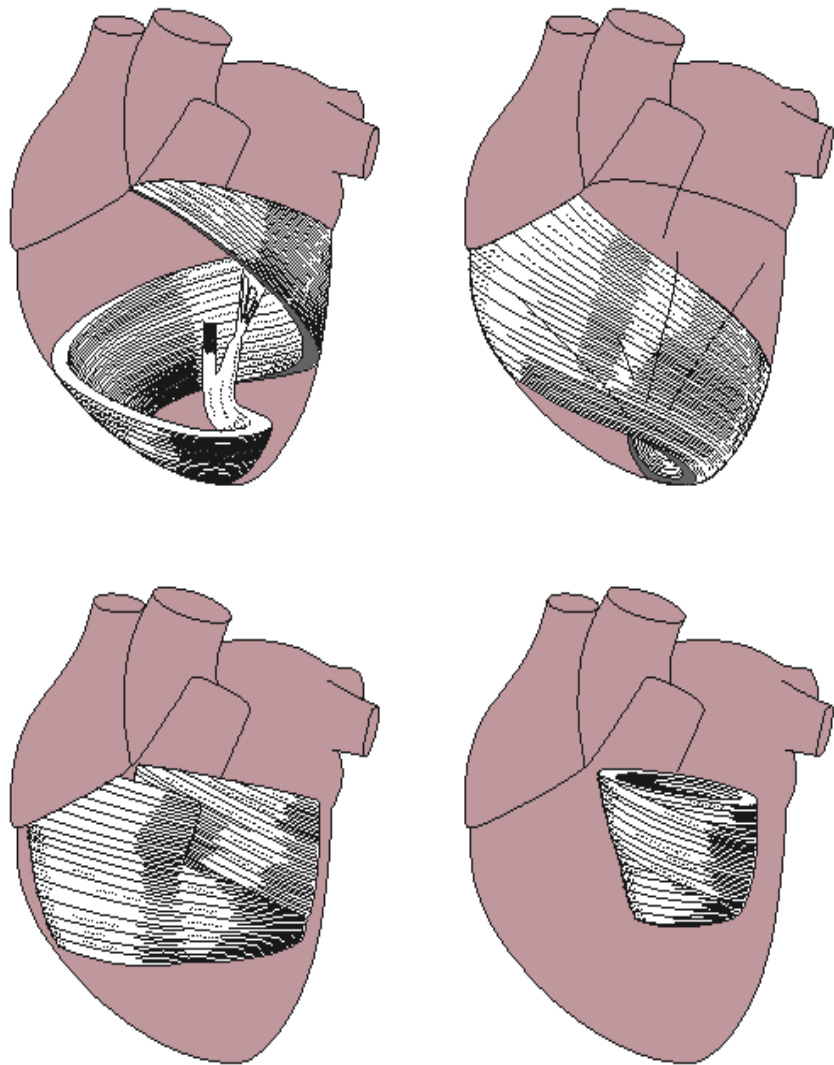
Myocardium

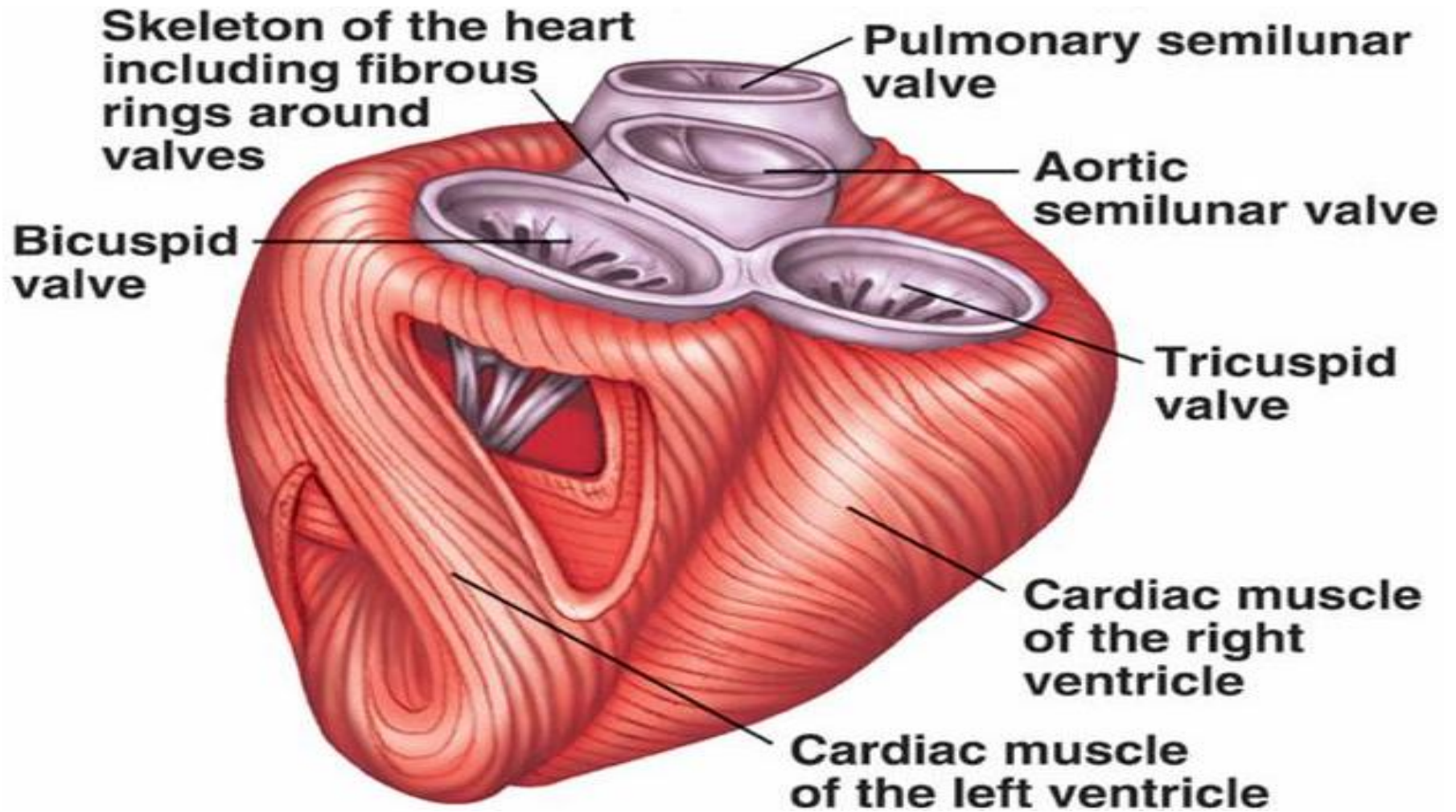


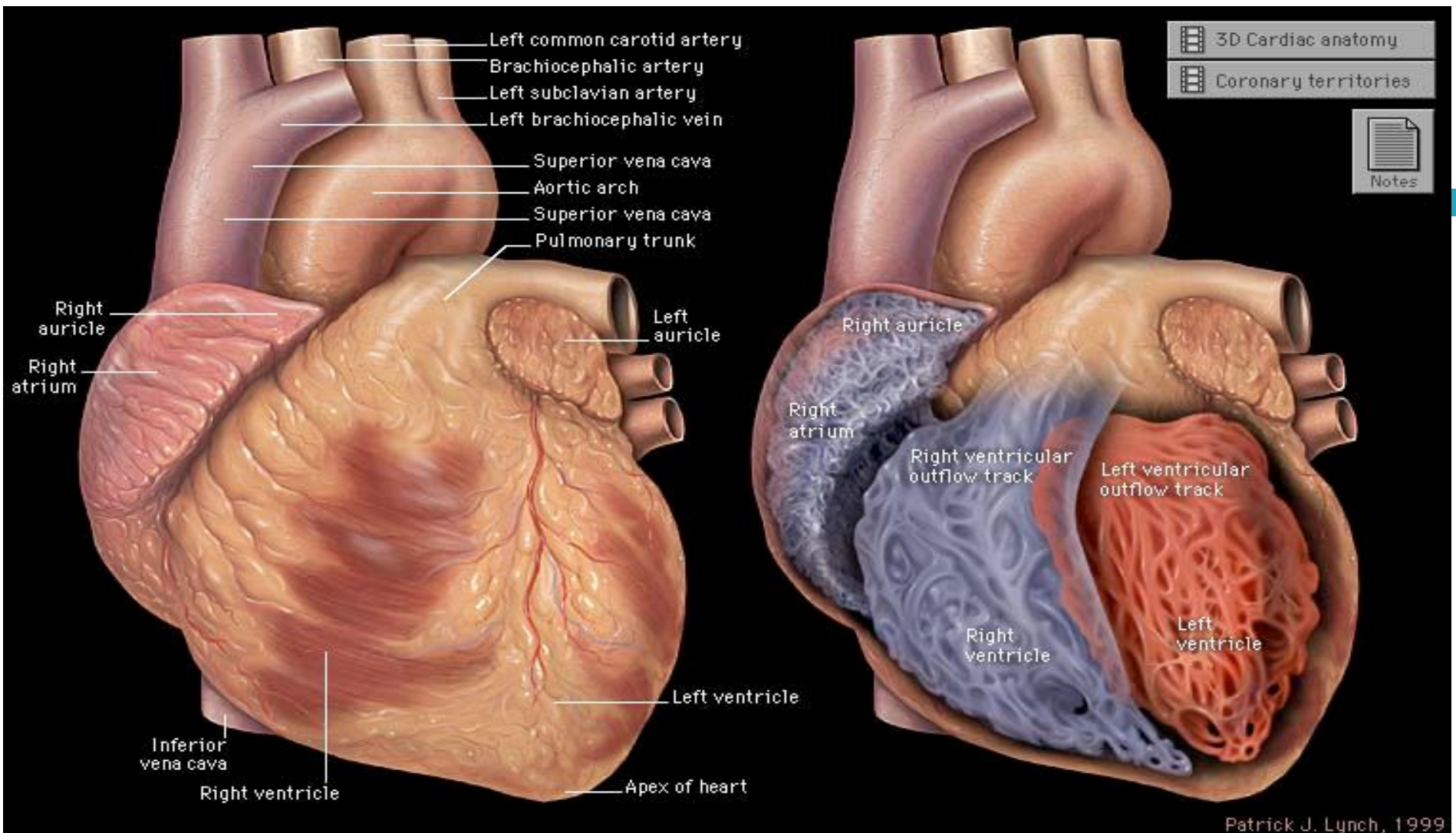
Epicardium

Cardiac Muscle Bundles









Histology

Striated muscle but fibres divide and recombine.

Though each cell is distinct with its own nucleus, the cells are joined end to end by specialised cell junctions called **intercalated disks**.

These junctions offer a very weak resistance to electrical flow and thus the heart muscle acts as a **syncetium**.

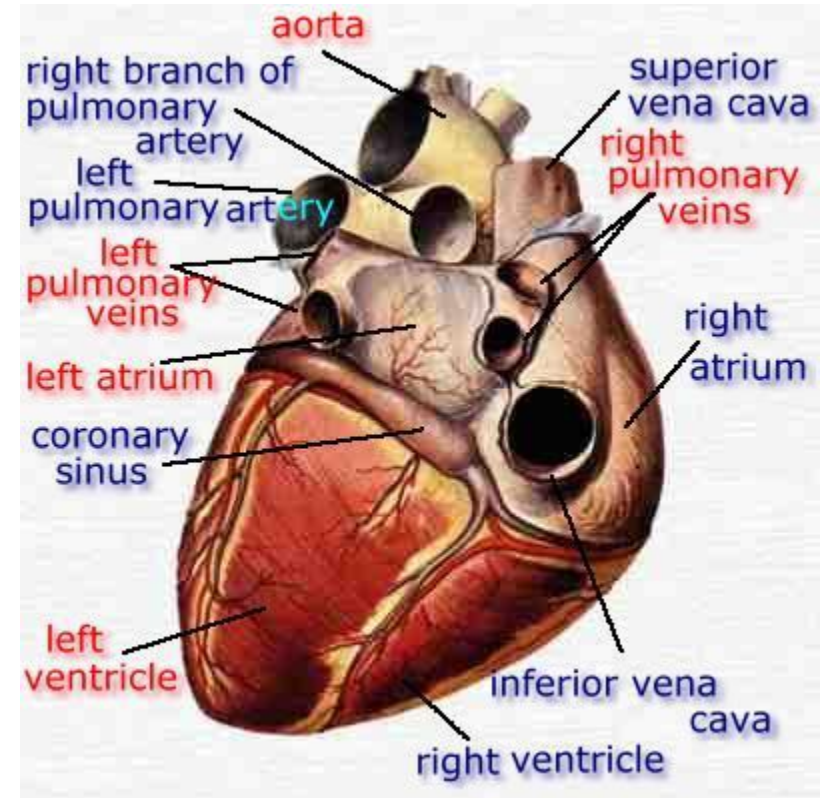
In contrast with skeletal muscle, the heart muscle tissue can contract without a nervous stimulation.

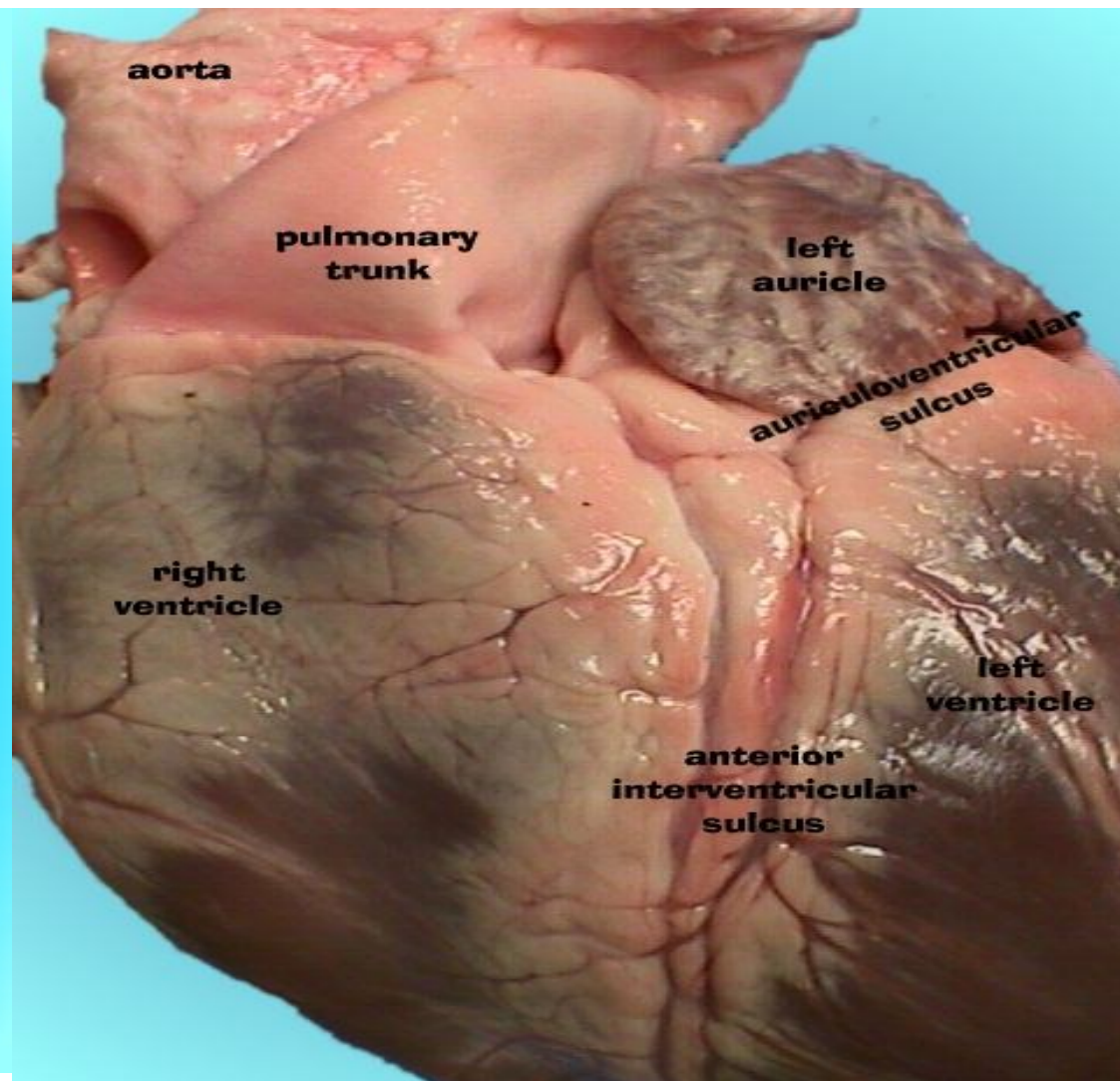
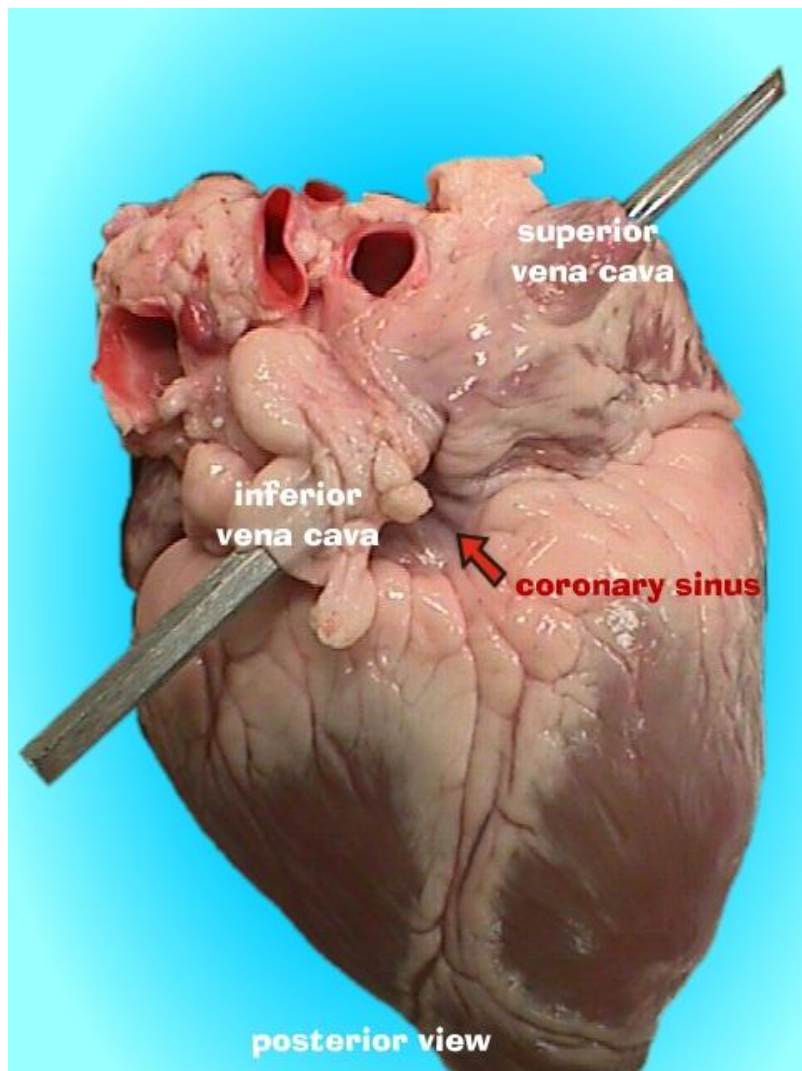
Other differences between cardiac and skeletal muscle tissue

- **Sarcoplasmic Reticulum** is less extensive in cardiac muscle.
- **Calcium** sensitivity of intact cardiac muscle is greater than skeletal muscle. Because of this increased sensitivity, cardiac muscle contraction is longer than skeletal muscle.
- Cardiac muscle **cannot** undergo **tetanicisation**. This occurs as the absolute refractory period in the cardiac muscle cell is longer than for skeletal muscle. In fact absolute refractory period is almost as long as the contraction period - 200 msec.
- Cardiac muscle **resists wear and tear** better than skeletal muscle. This is important as cardiac muscle contracts some 100,000 times/day (in 70 years this totals to 2.5 billion times).
- Cardiac muscle is **very susceptible to oxygen lack** - can withstand not more than 30secs without oxygen before they stop working.
- The cardiac muscle as a whole, and not only the single muscle fibre, obeys the all or none rule i.e. if one muscle cell in the syncetium contracts, the rest contract at the same time.

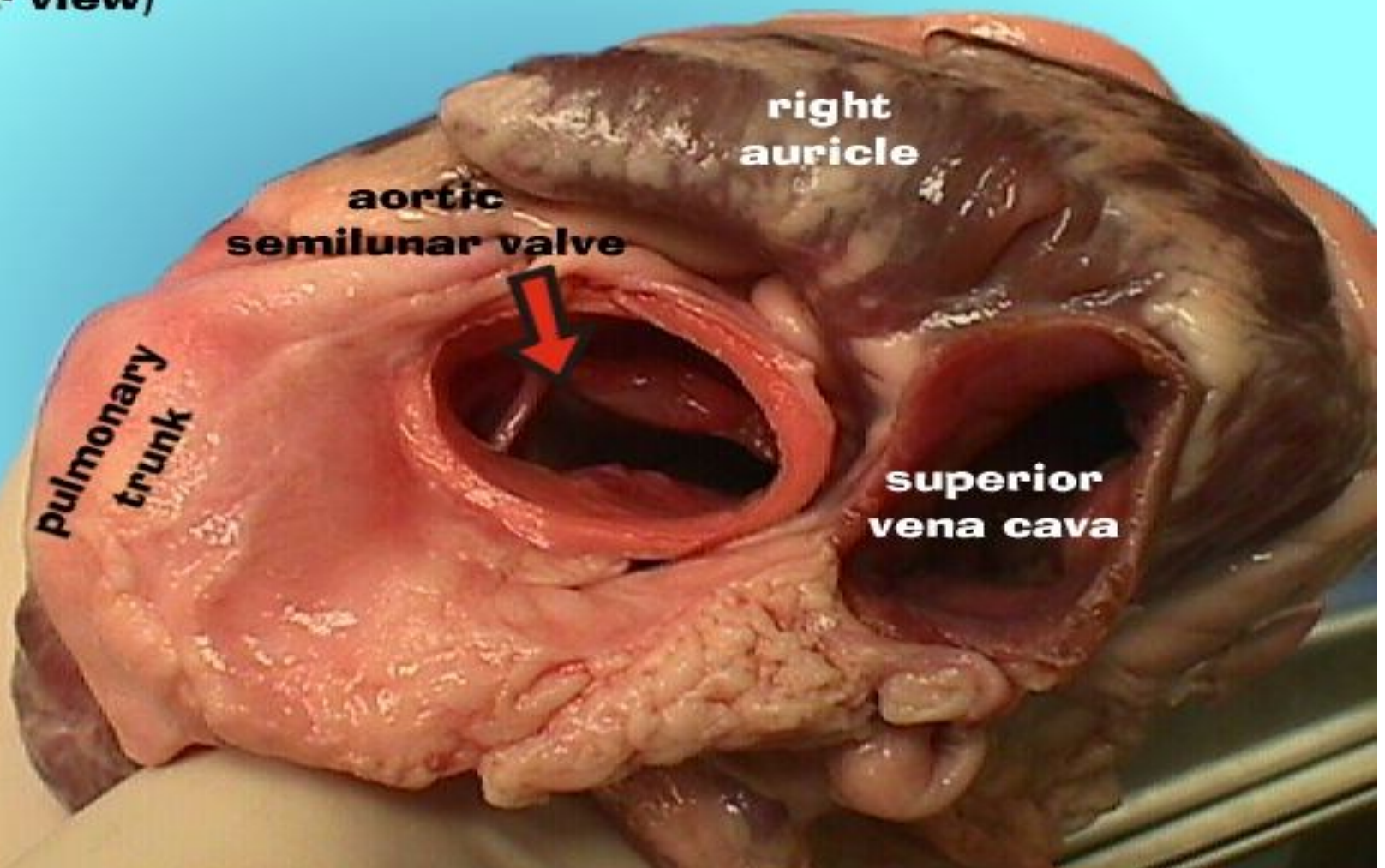
External Heart: Major Vessels of the Heart (Anterior View)

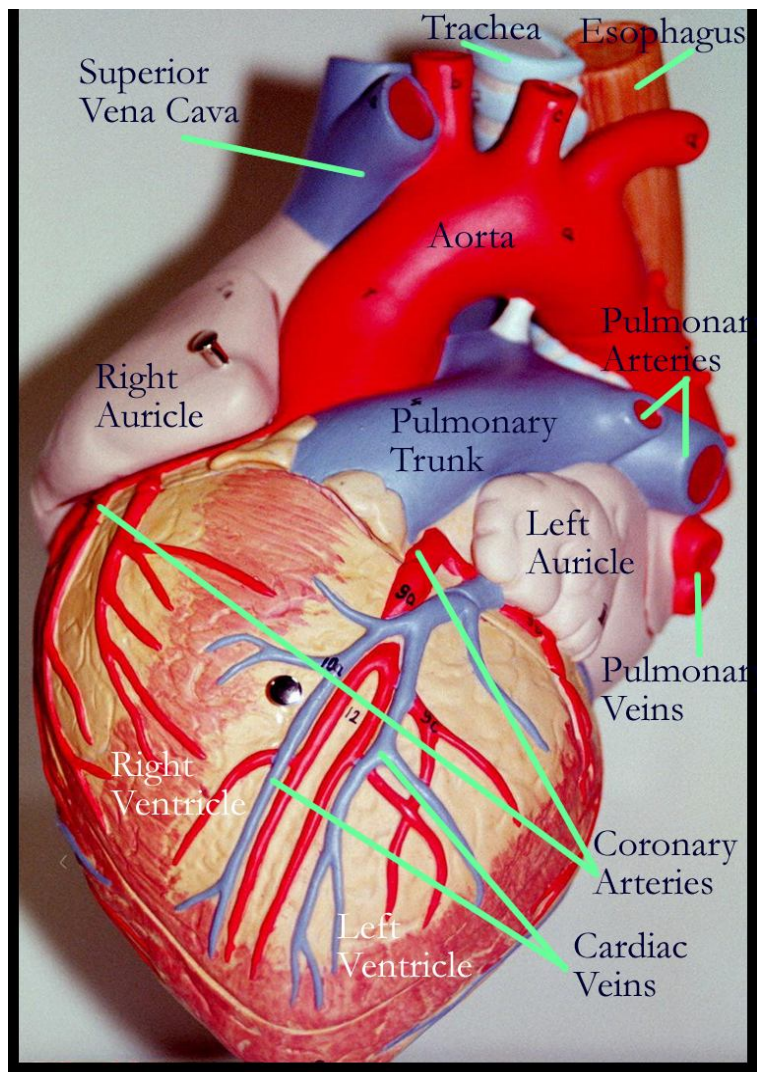
- **Vessels returning blood** to the heart include:
 - ▣ Superior and inferior venae cavae
 - ▣ Right and left pulmonary veins
- **Vessels conveying blood away from the heart:**
 - ▣ Pulmonary trunk, which splits into right and left pulmonary arteries
 - ▣ Ascending aorta (three branches) – brachiocephalic, left common carotid, and subclavian arteries



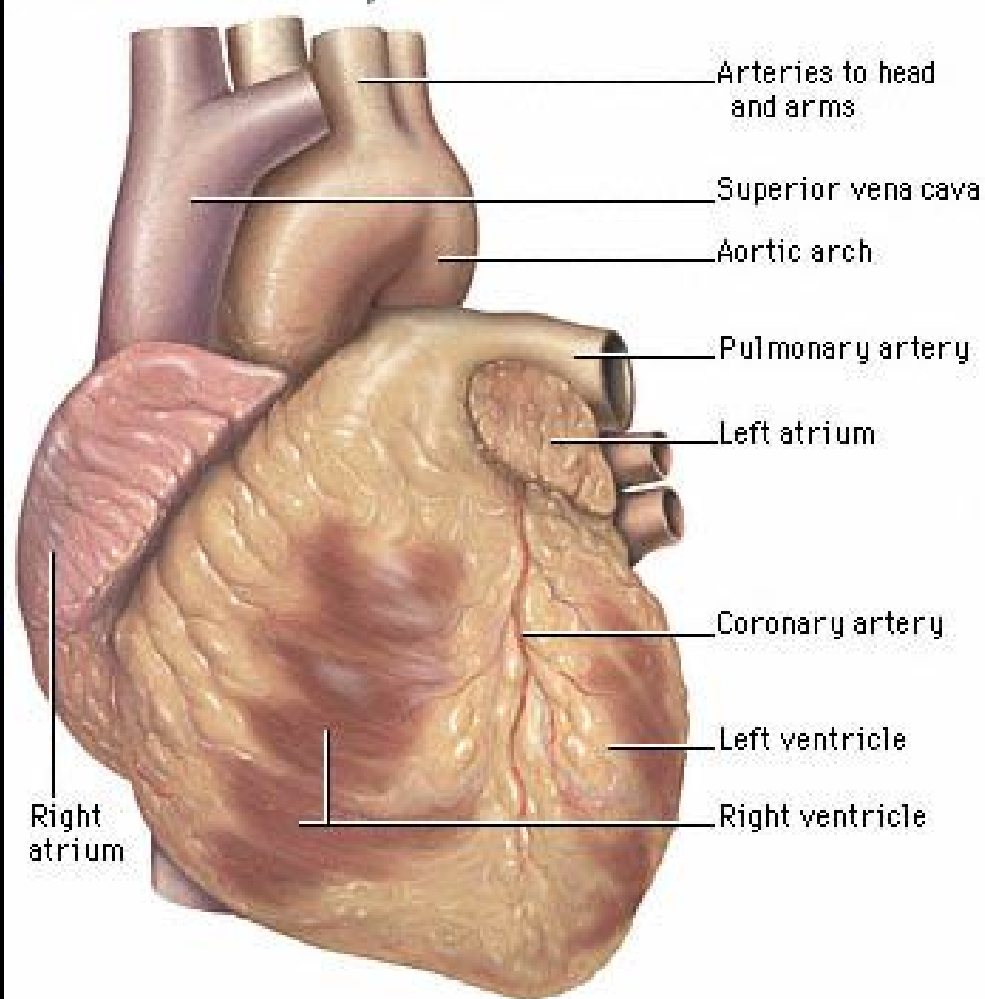


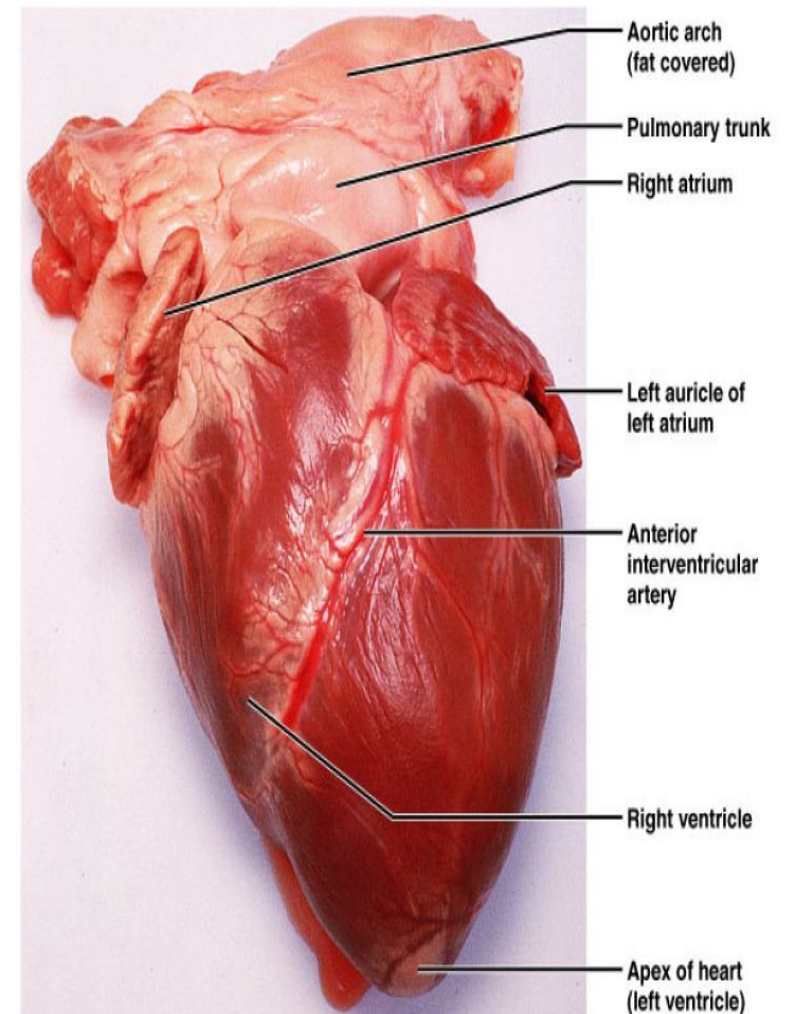
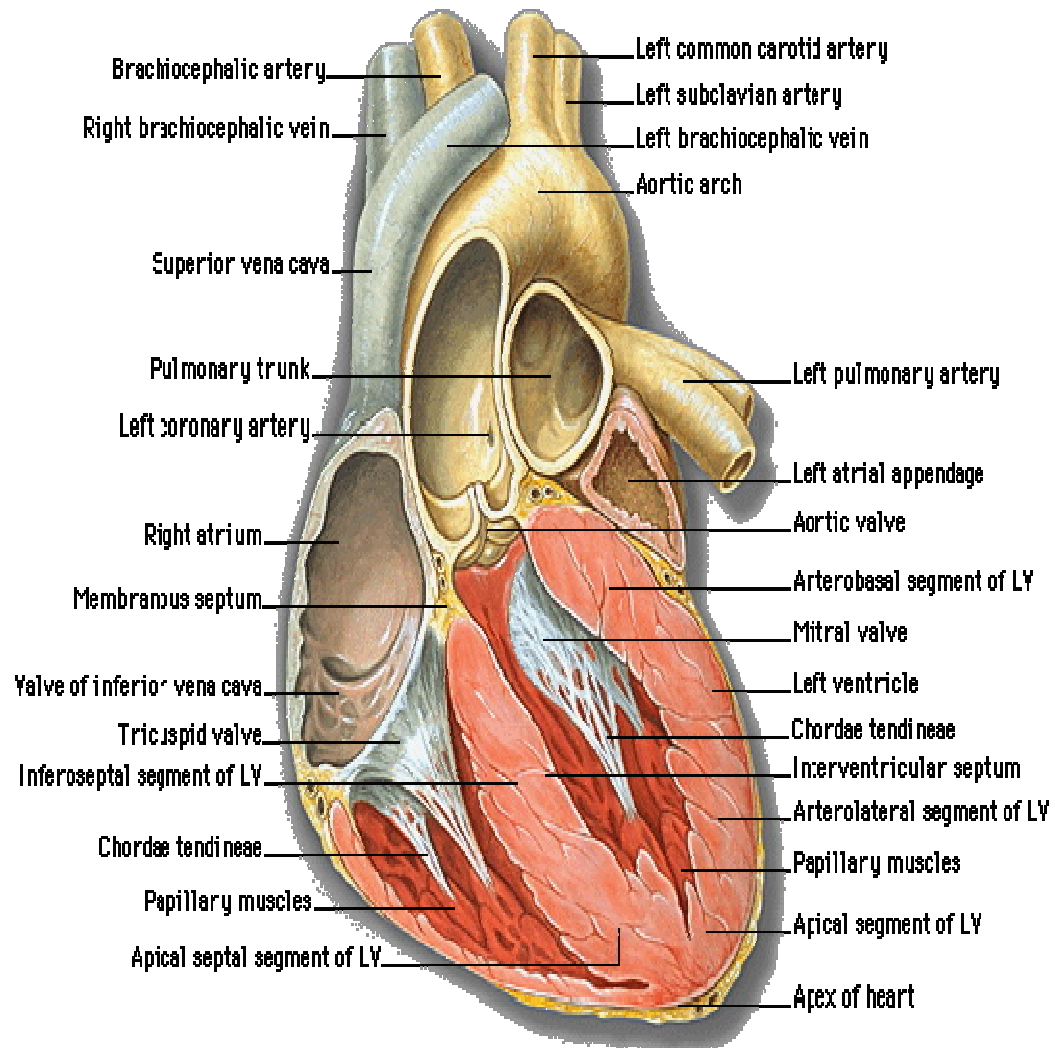
(superior view)

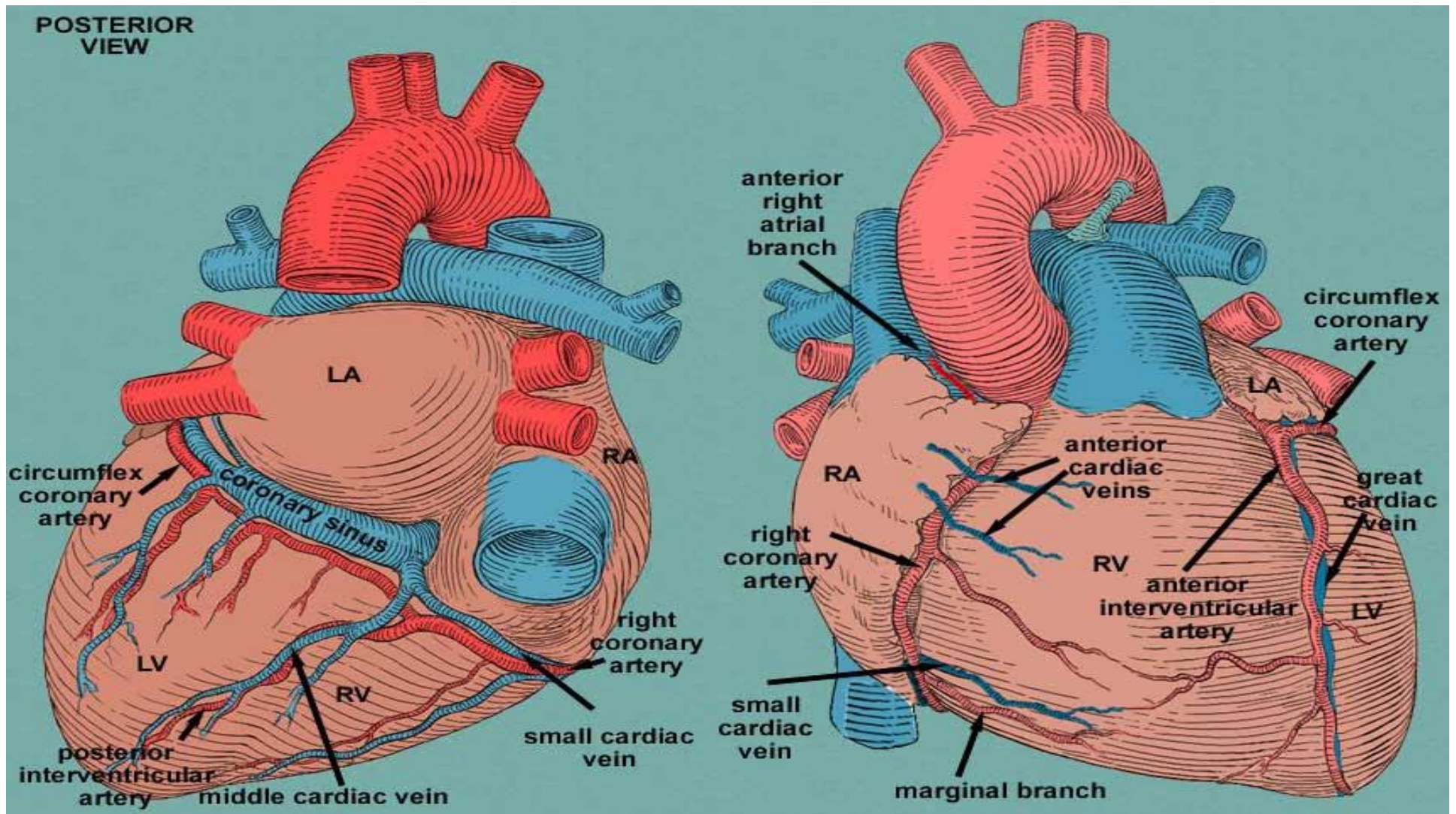




Exterior structures of the heart







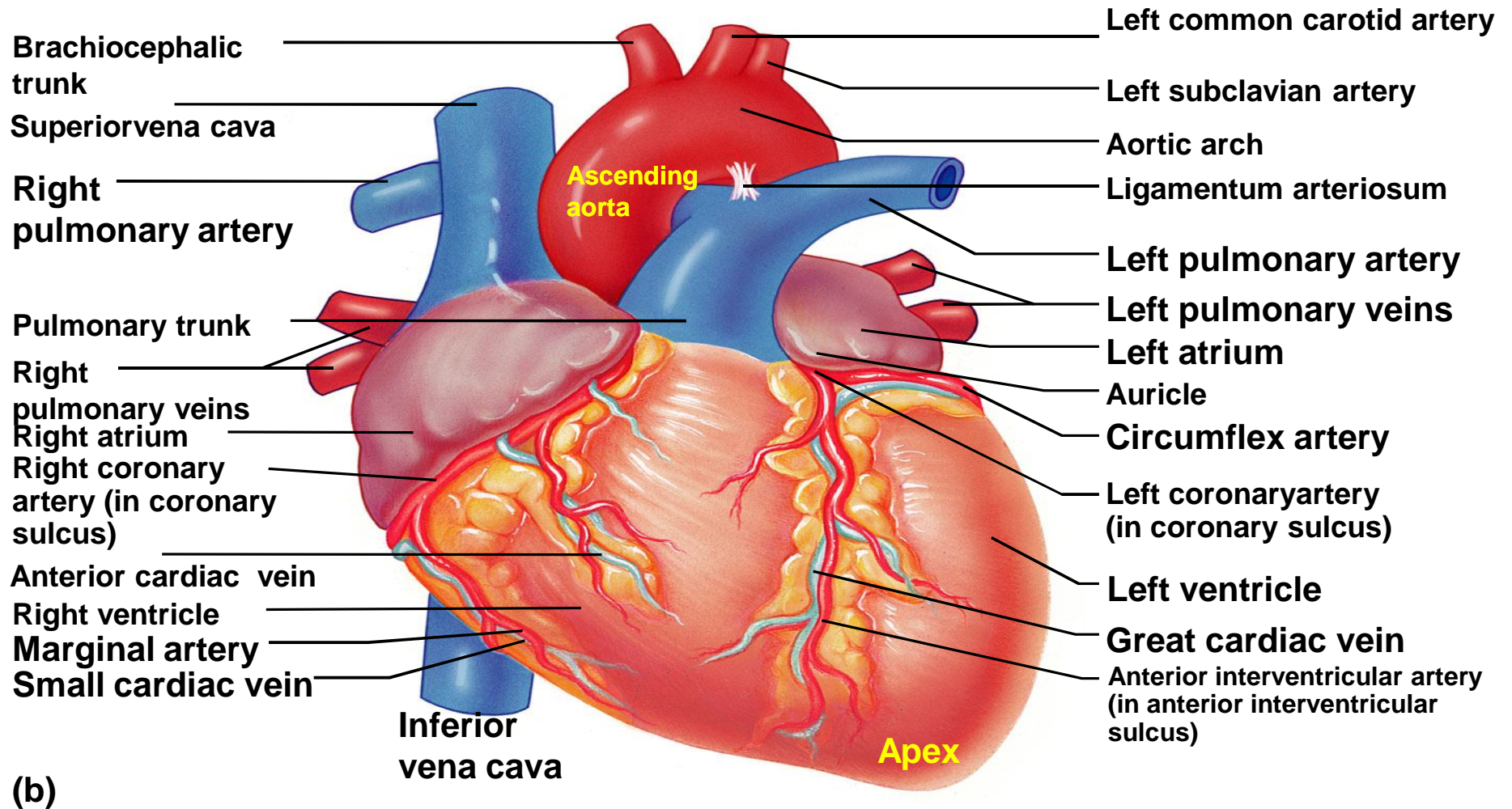


Figure 18.4b

External Heart: Major Vessels of the Heart (Posterior View)

- **Vessels returning blood to the heart include:**
 - ▣ Right and left pulmonary veins
 - ▣ Superior and inferior venae cavae
- **Vessels conveying blood away from the heart include:**
 - ▣ Aorta
 - ▣ Right and left pulmonary arteries

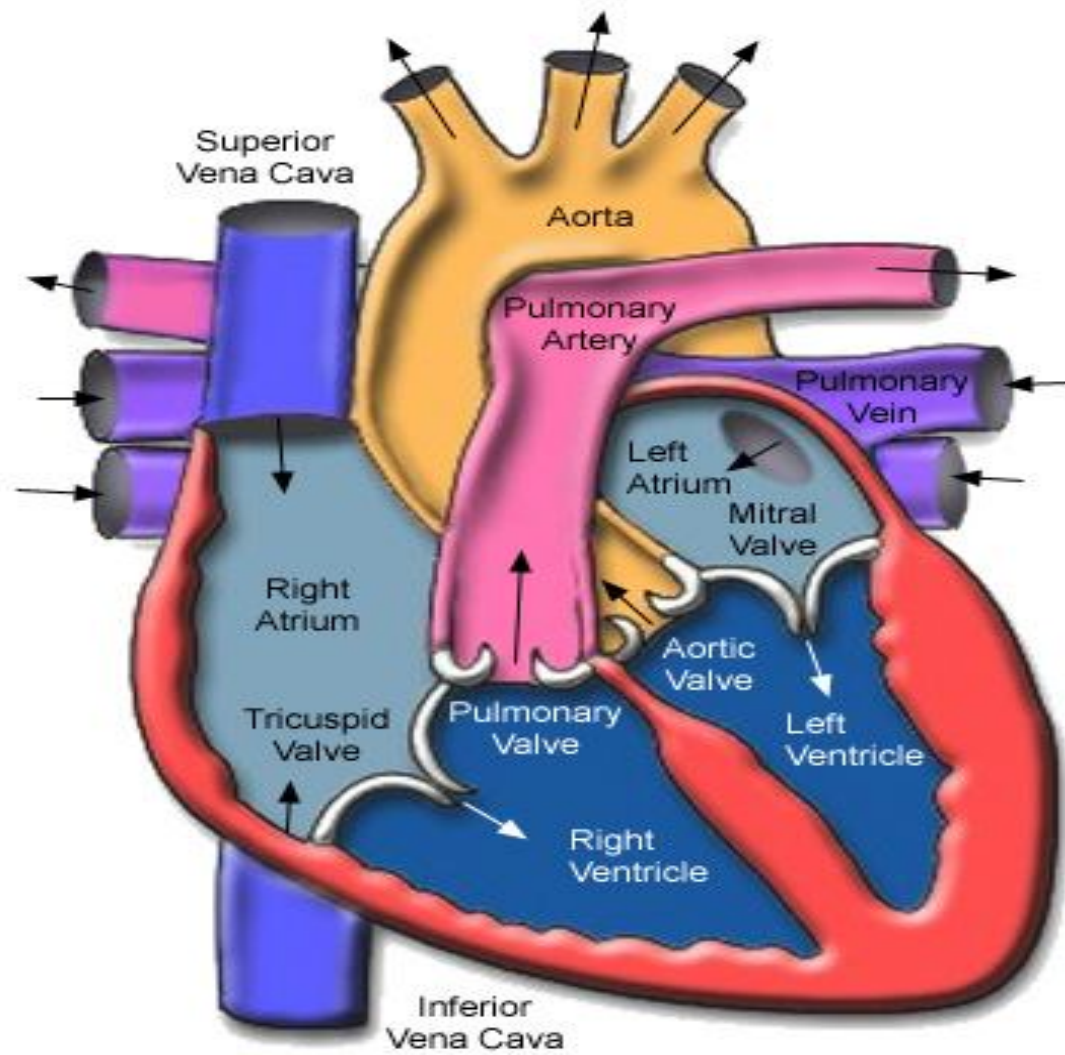
External Heart: Vessels that Supply/Drain the Heart (Posterior View)

□ Arteries –

- right coronary artery (in atrioventricular groove)
- the posterior interventricular artery (in interventricular groove)

□ Veins –

- great cardiac vein,
- posterior vein to left ventricle,
- coronary sinus,
- middle cardiac vein



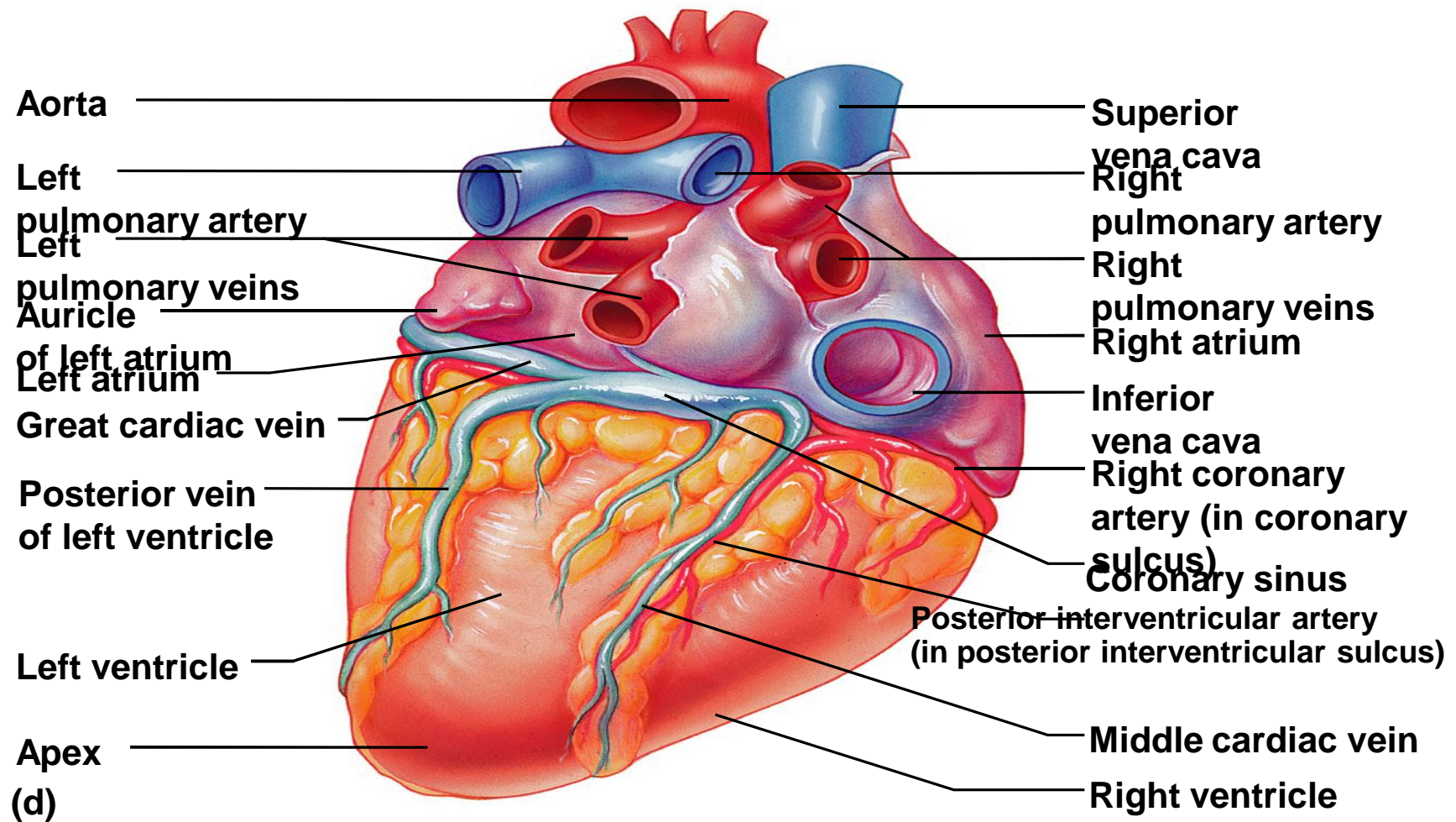


Figure 18.4d

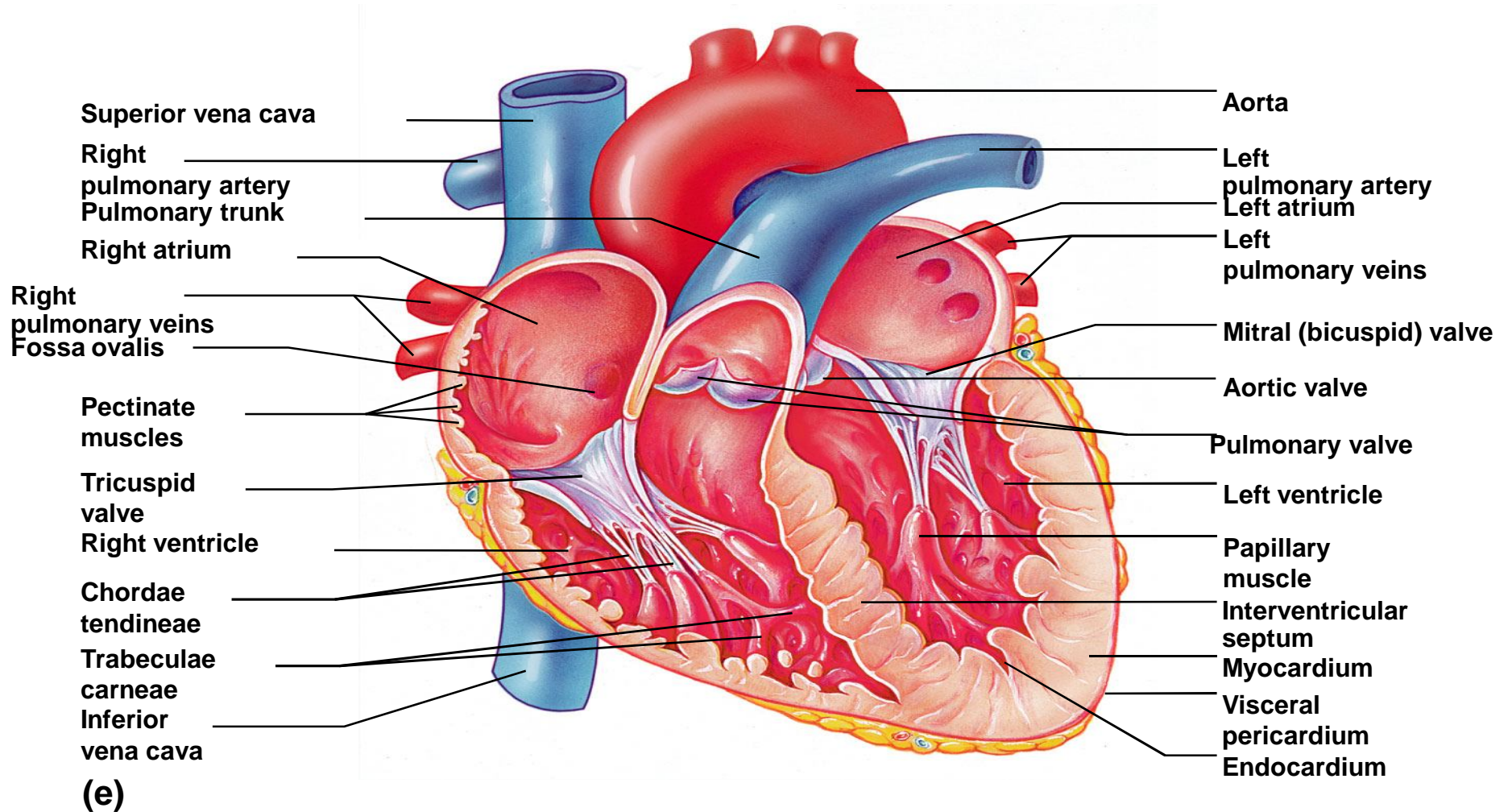


Figure 18.4e

Atria of the Heart

- ❑ Atria are the receiving chambers of the heart
- ❑ Each atrium has a protruding auricle
- ❑ Pectinate muscles mark atrial walls
- ❑ Blood enters right atria from superior and inferior venae cavae and coronary sinus
- ❑ Blood enters left atria from pulmonary veins

Ventricles of the Heart

- ❑ Ventricles are the discharging chambers of the heart
- ❑ Papillary muscles and trabeculae carneae muscles mark ventricular walls
- ❑ Right ventricle pumps blood into the pulmonary trunk
- ❑ Left ventricle pumps blood into the aorta

Right and Left Ventricles

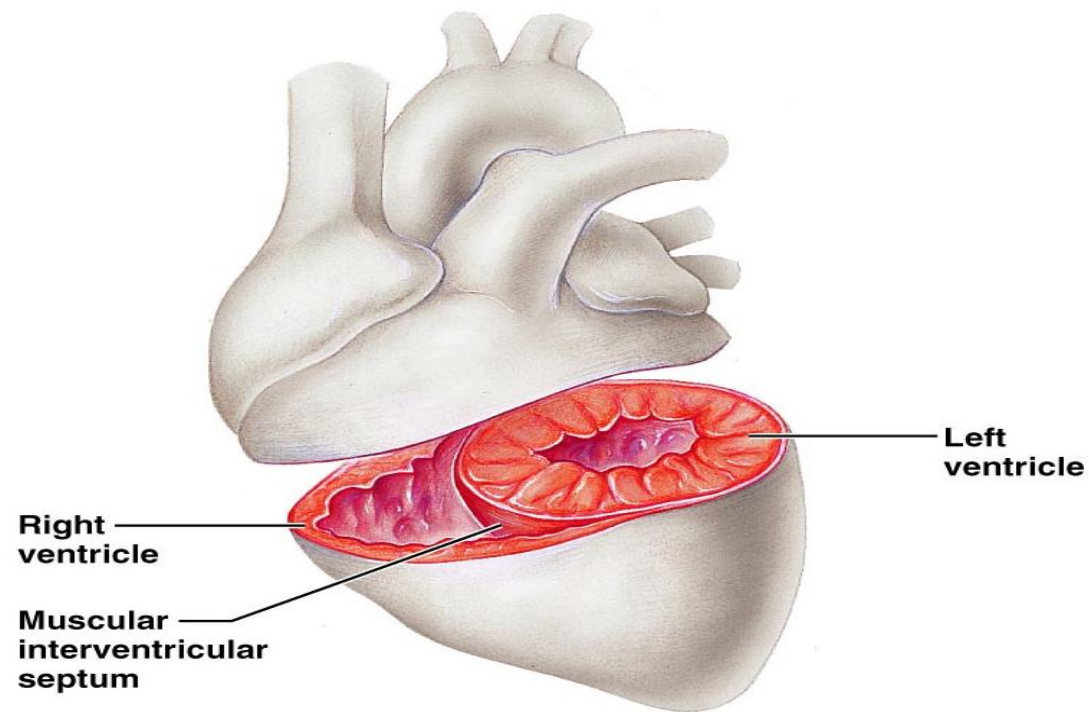


Figure 18.6

Pathway of Blood Through the Heart and Lungs

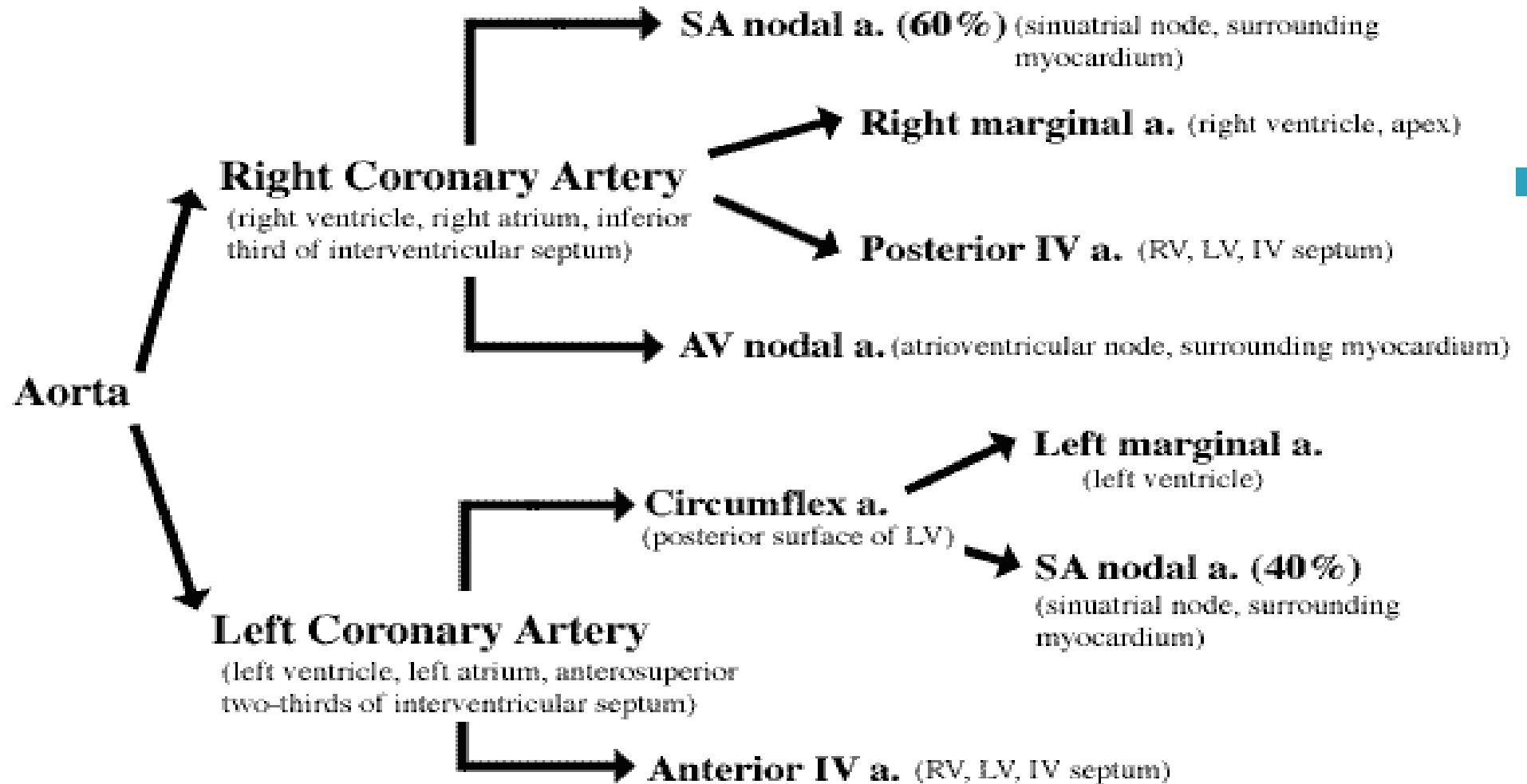
- **Right atrium → tricuspid valve → right ventricle**
- **Right ventricle → pulmonary semilunar valve → pulmonary arteries → lungs**
- **Lungs → pulmonary veins → left atrium**
- **Left atrium → bicuspid valve → left ventricle**
- **Left ventricle → aortic semilunar valve → aorta**
- **Aorta → systemic circulation**

Coronary circulation



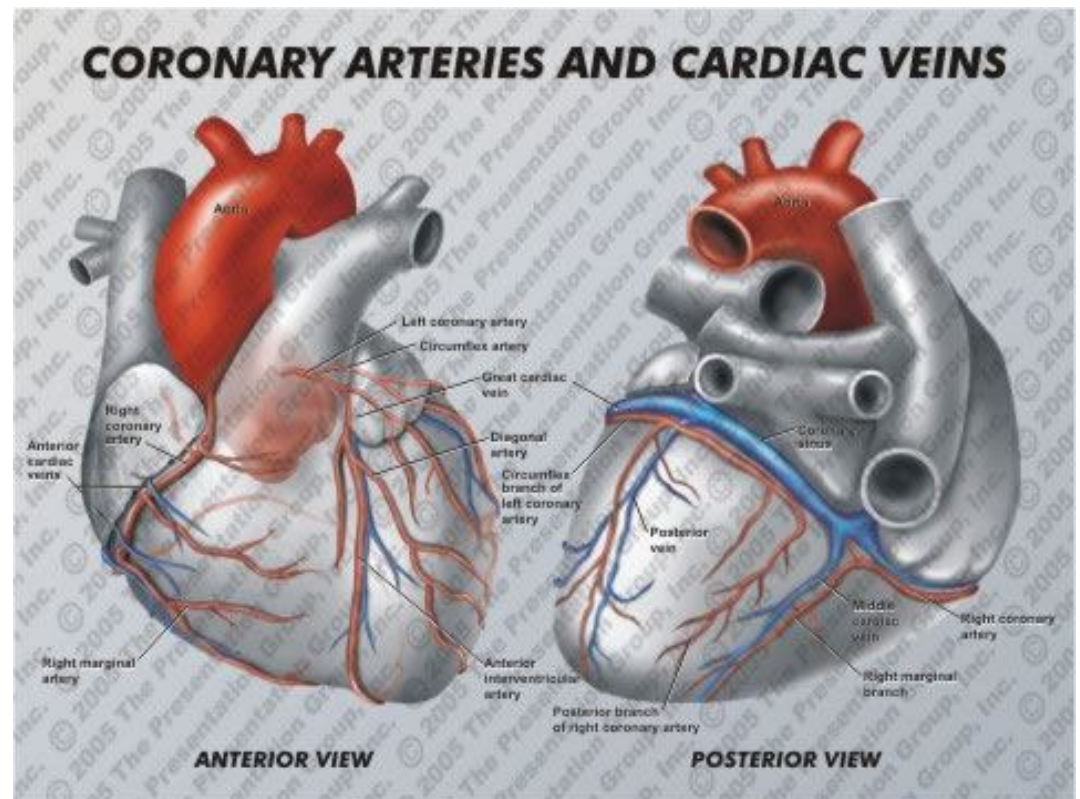
Coronary Circulation

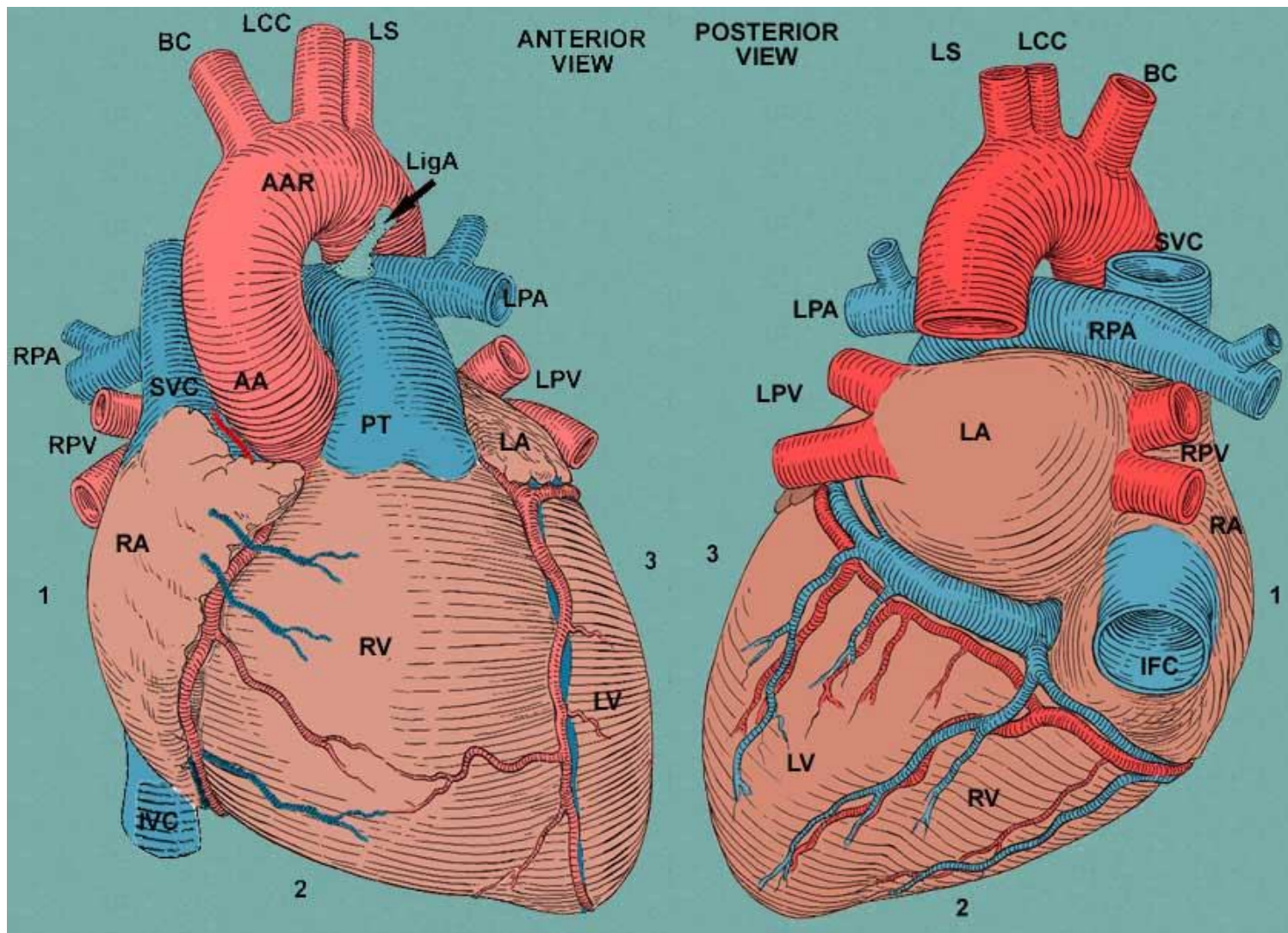
- ❑ Coronary circulation is the functional blood supply to the heart muscle itself
- ❑ Collateral routes ensure blood delivery to heart even if major vessels are occluded



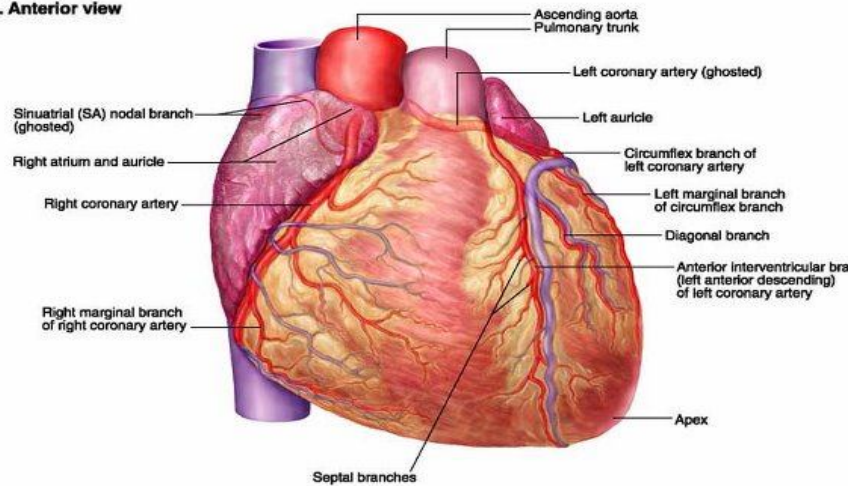
External Heart: Vessels that Supply/Drain the Heart (Anterior View)

- **Arteries** – right and left coronary (in atrioventricular groove), marginal, circumflex, and anterior interventricular arteries
- **Veins** – small cardiac, anterior cardiac, and great cardiac veins

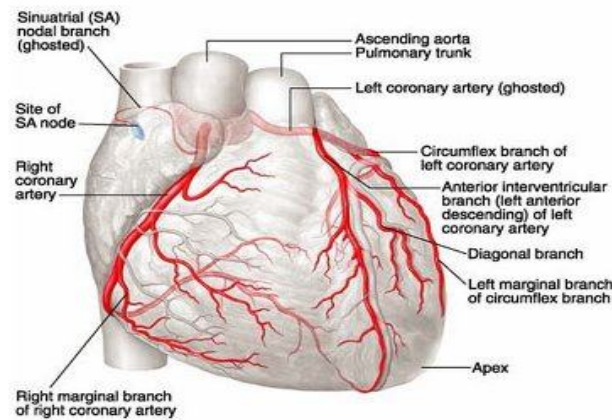




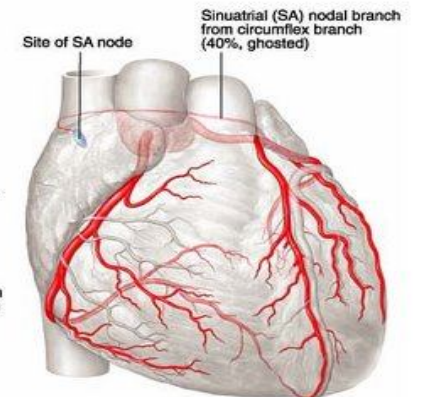
A. Anterior view



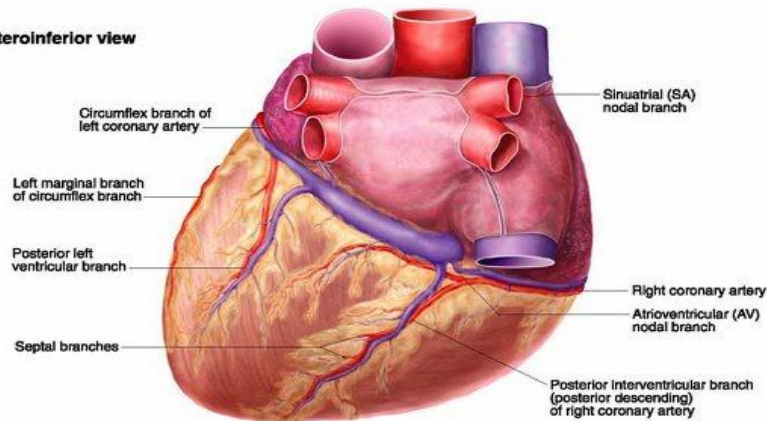
A. Normal arterial pattern, anterior view



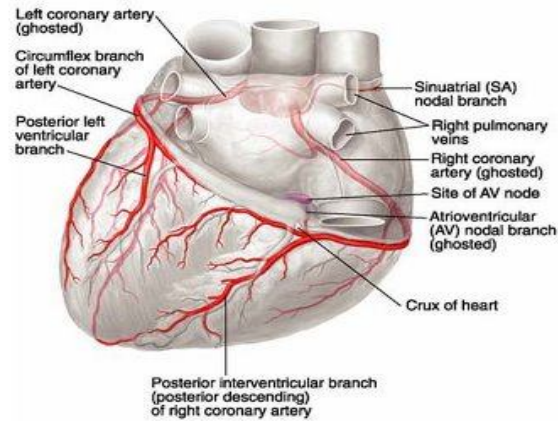
B. Variation, anterior view



B. Posteroinferior view



C. Normal arterial pattern, posteroinferior view



D. Variation, posteroinferior view

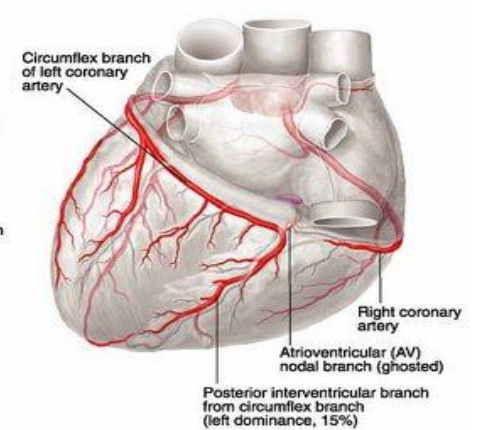
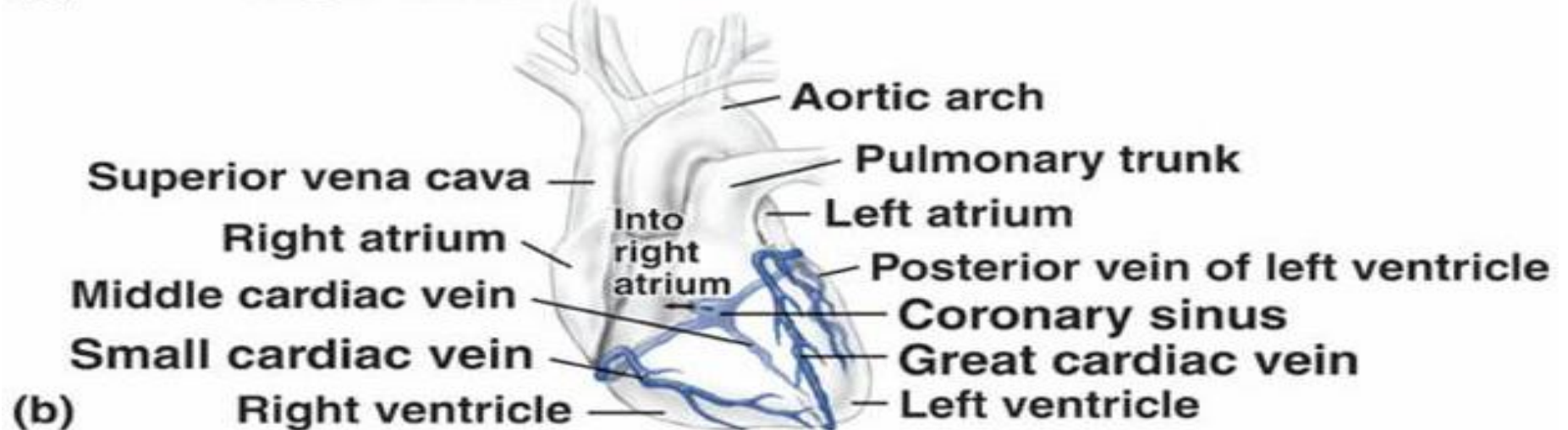
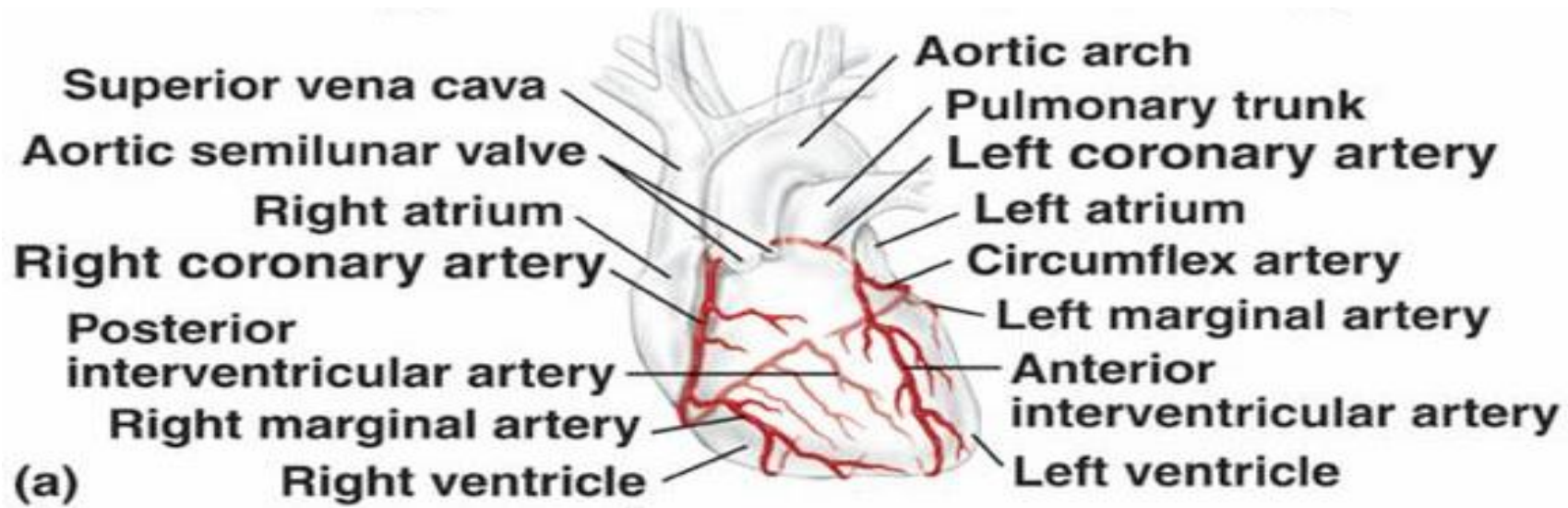
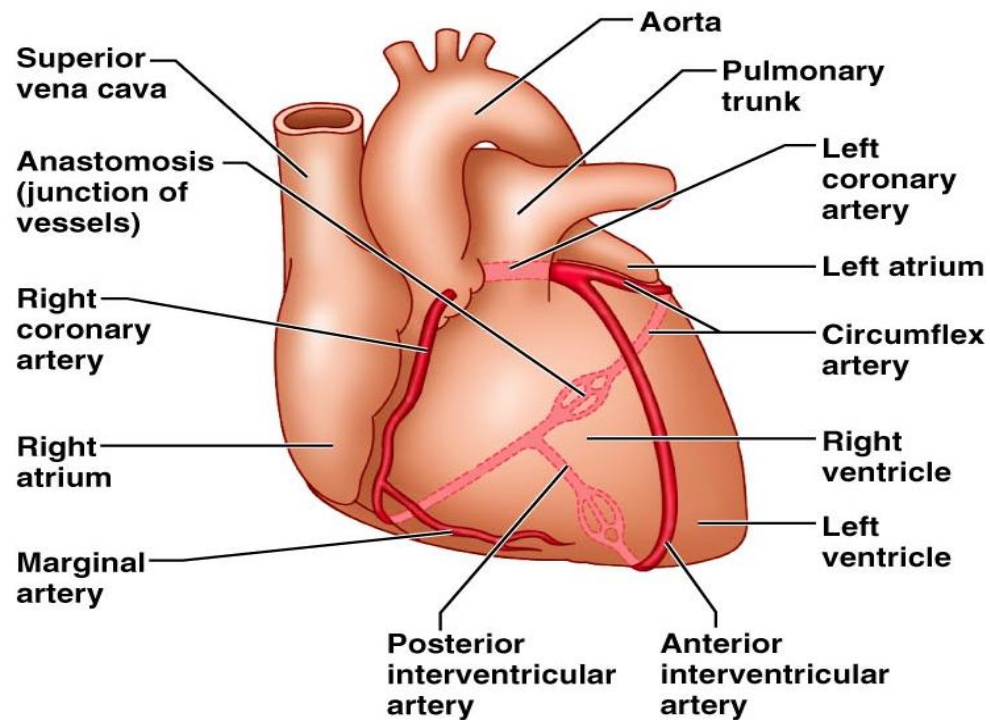


Plate 4-22 Coronary Arteries

Plate 4-23 Coronary Arteries, Normal Patterns and Variations

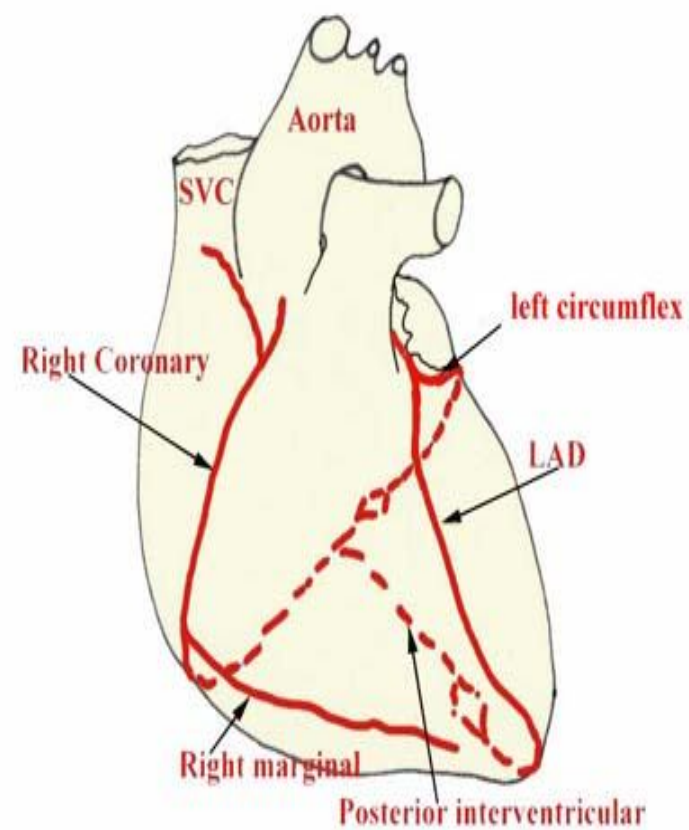
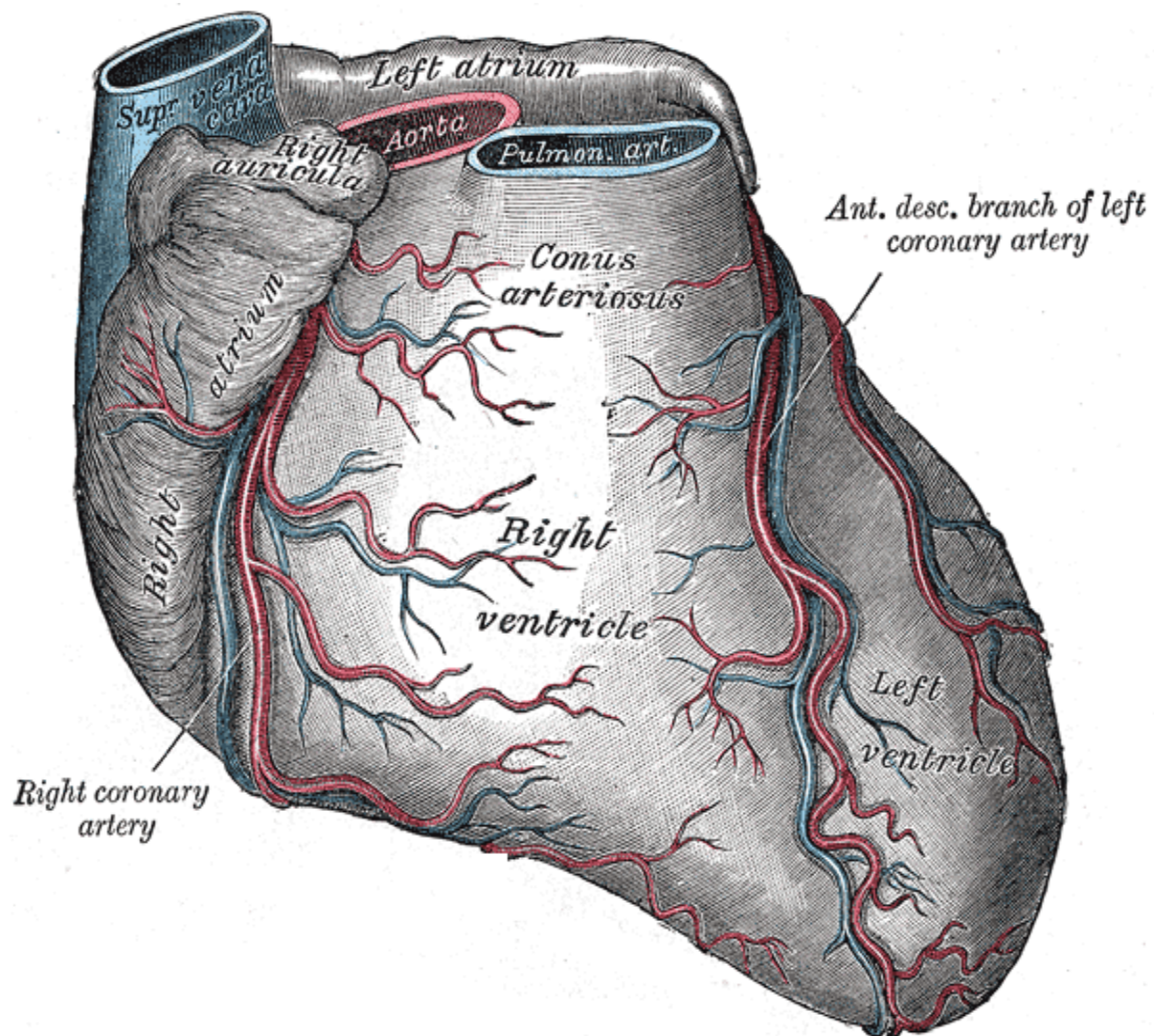


Coronary Circulation: Arterial Supply

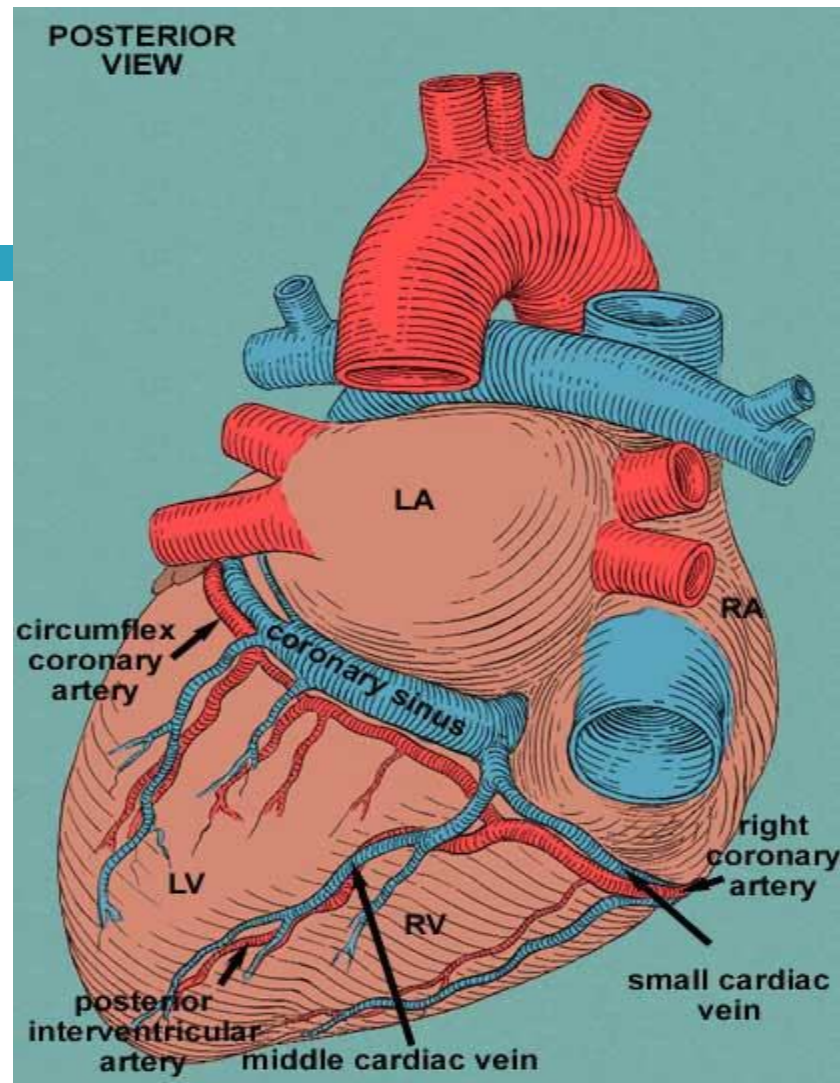
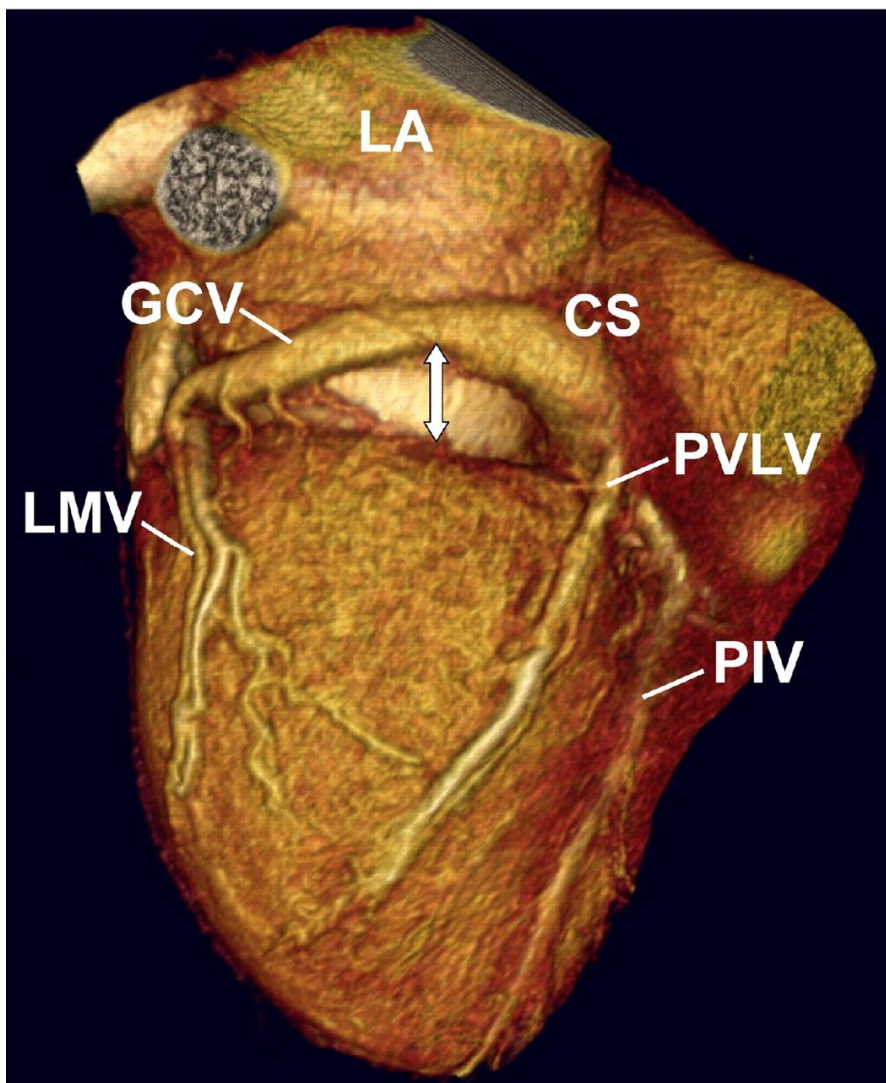


(a)

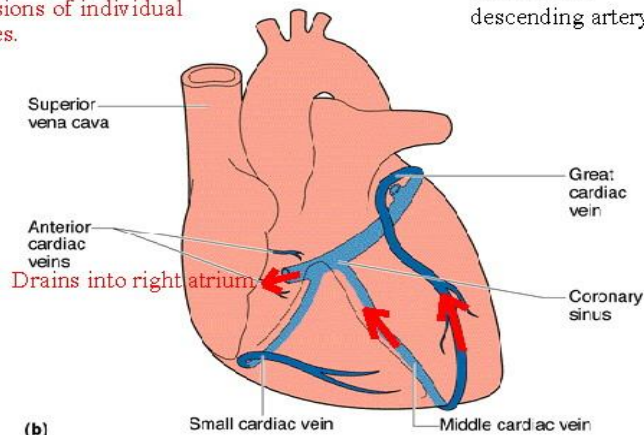
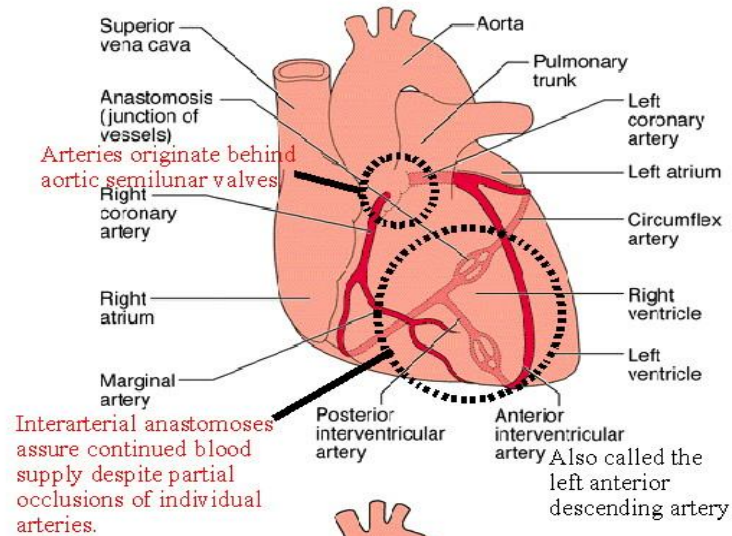
Figure 18.7a



CORONARY SINUS

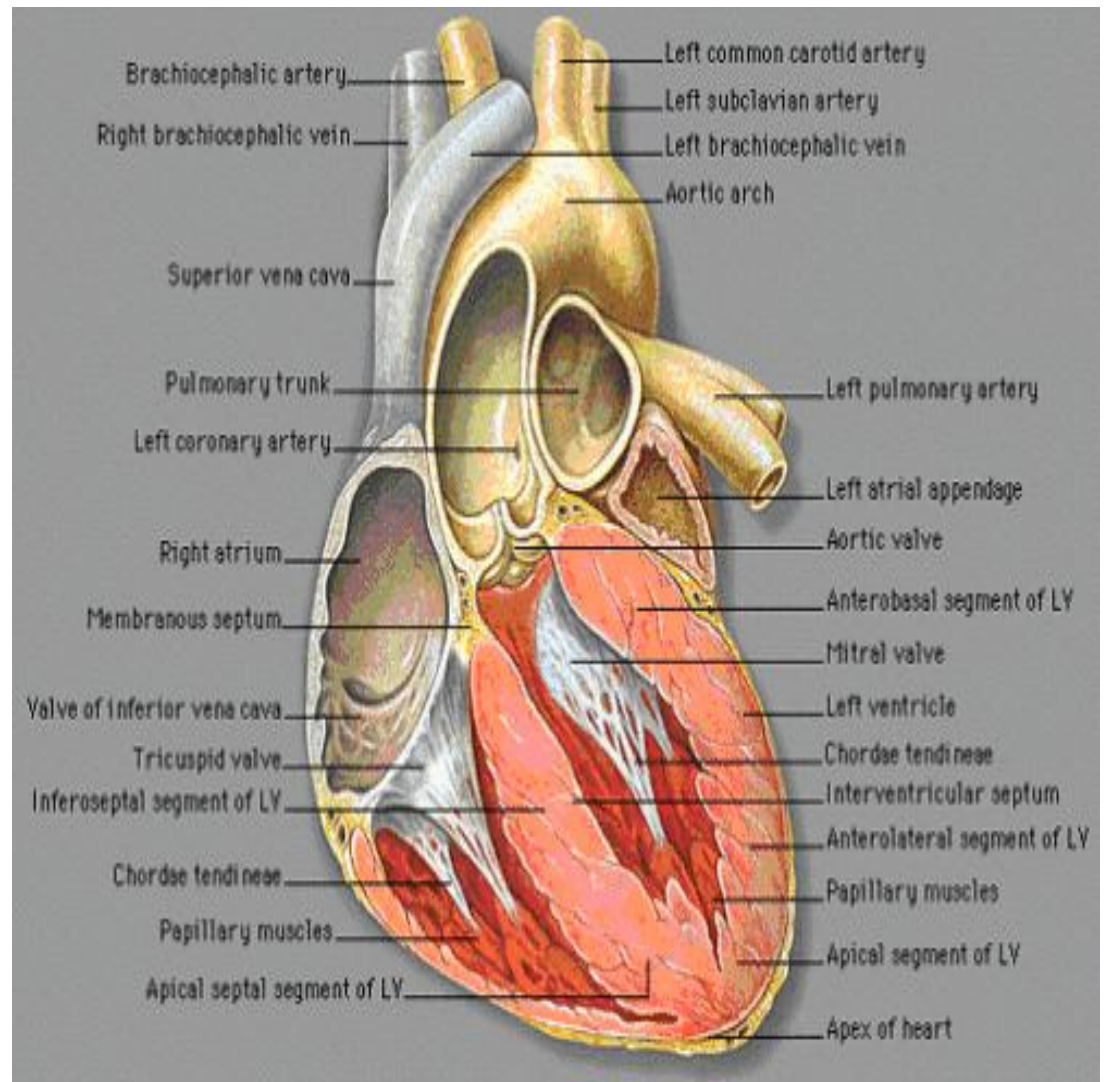


The Coronary Circulation

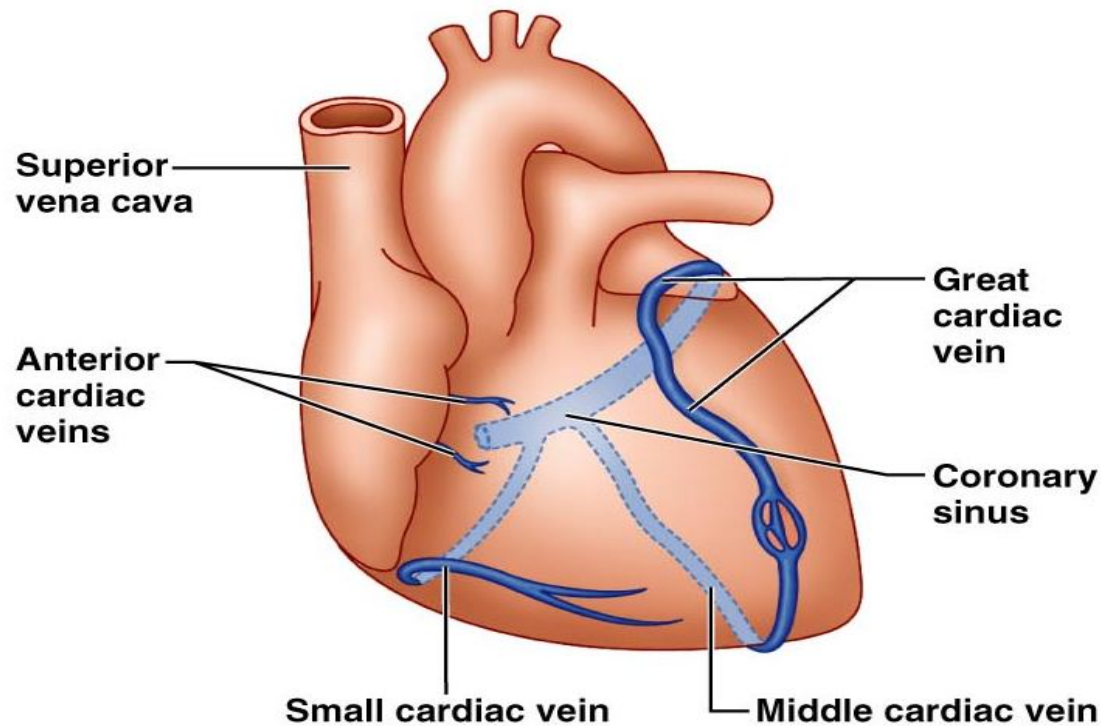


(b)

© BENJAMIN CLUMMIN 3S



Coronary Circulation: Venous Supply



(b)

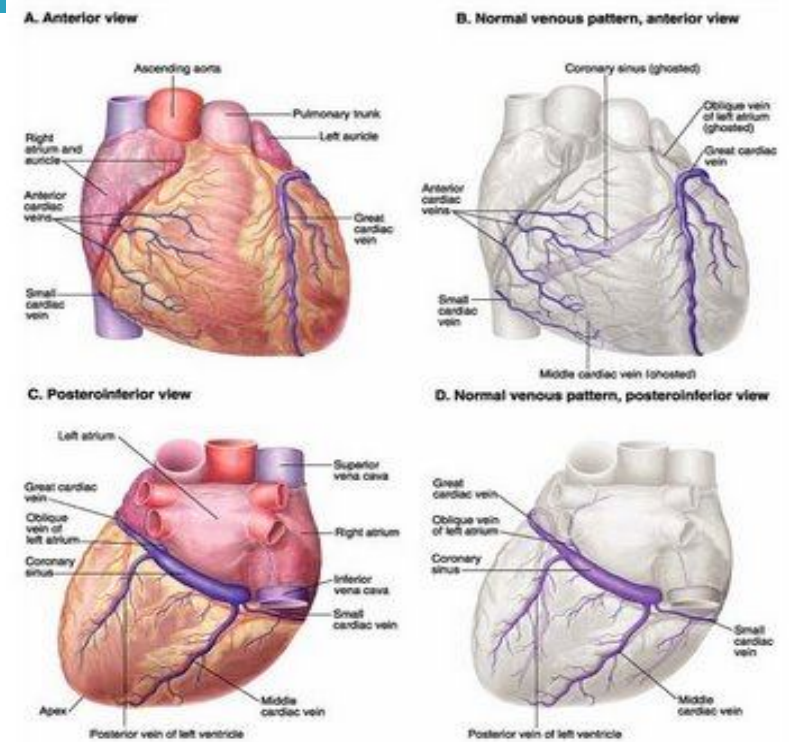
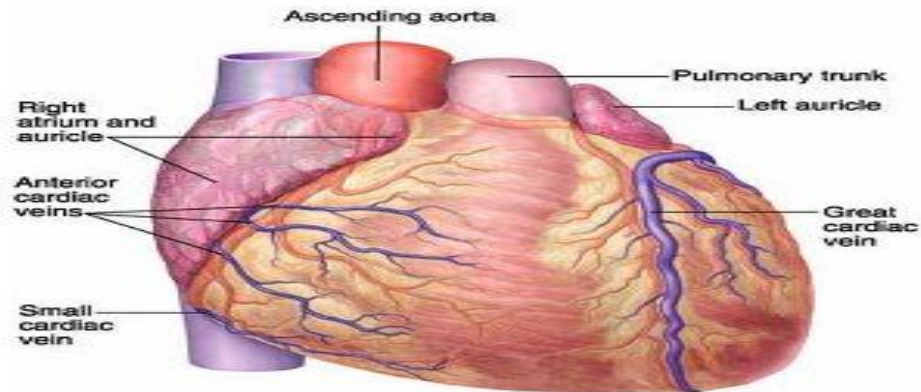
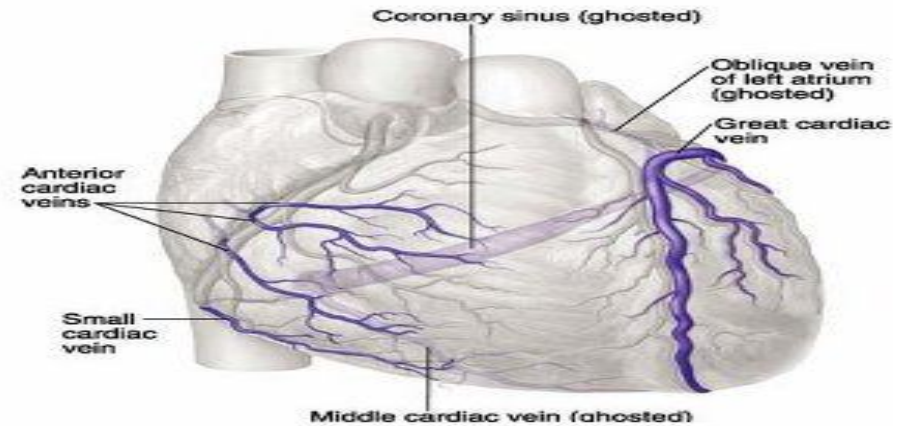


Plate 4-24 Cardiac Veins

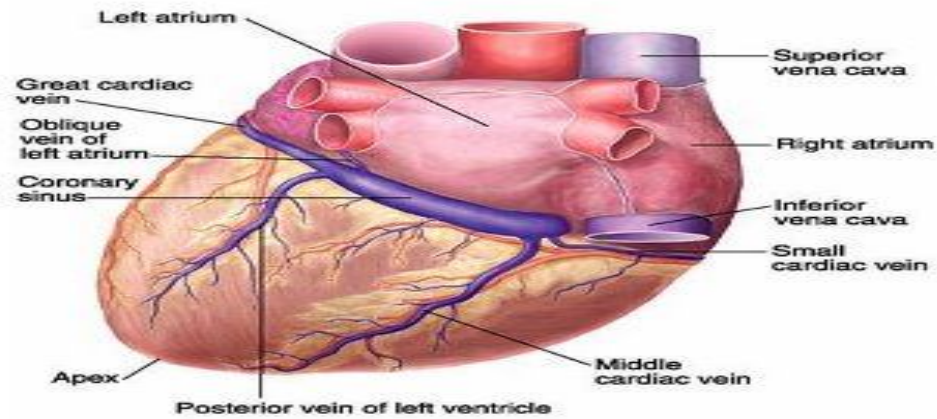
A. Anterior view



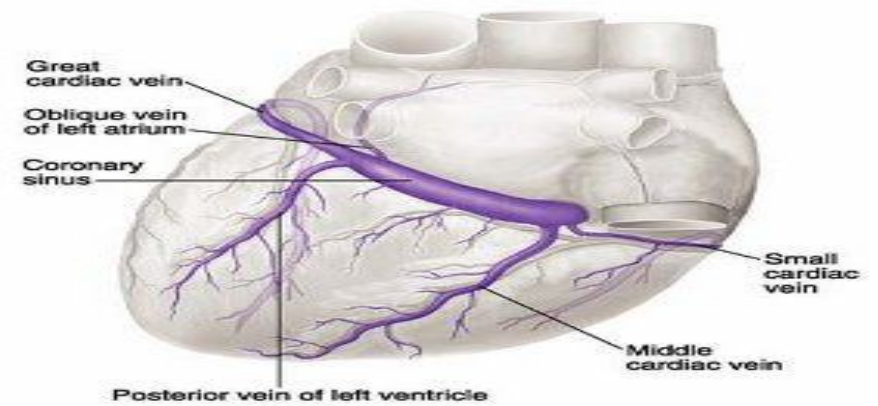
B. Normal venous pattern, anterior view



C. Posteroinferior view



D. Normal venous pattern, posteroinferior view



Cardiac valves



Heart Valves

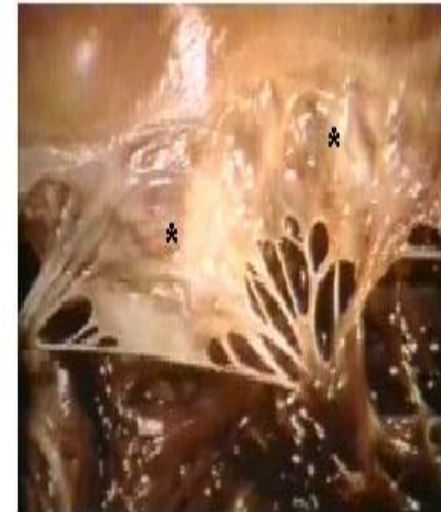- ❑ Heart valves ensure unidirectional blood flow through the heart
- ❑ Atrioventricular (AV) valves lie between the atria and the ventricles
- ❑ AV valves prevent backflow into the atria when ventricles contract
- ❑ Chordae tendineae anchor AV valves to papillary muscles

Valves

- **AV atrioventricular valves**
 - ▣ Tricuspid
 - ▣ Mitral or bicuspid
- **Semilunar valves**
 - ▣ Aortic
 - ▣ Pulmonic

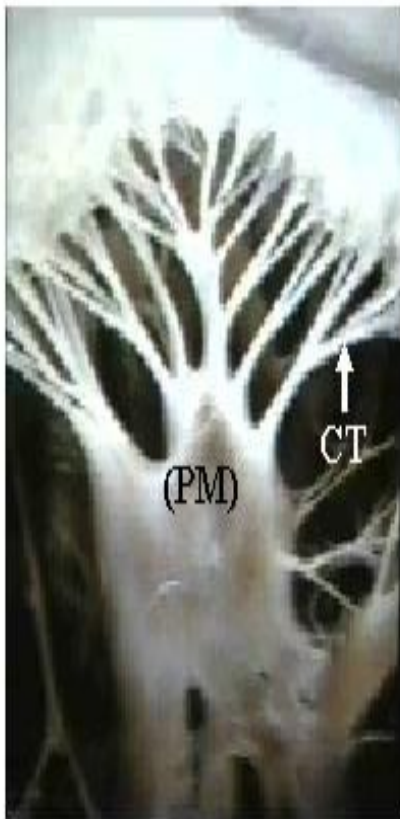
PAMT

ATRIOVENTRICULAR VALVES (A-V)



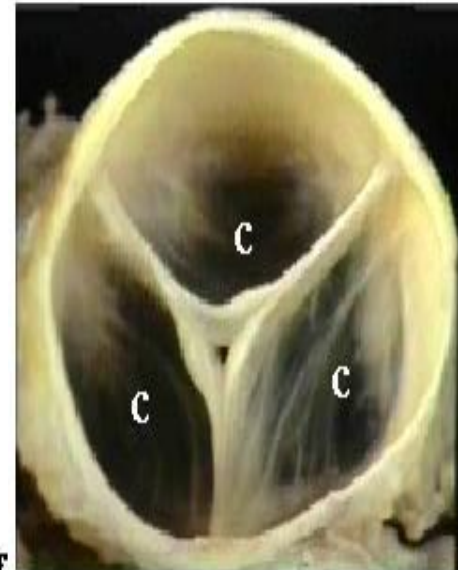
The A-V valves are formed from flap-like extensions of the endocardium called cusps (asterisks). In the right A-V valve there are three cusps - the tricuspid valve. In the left A-V valve there are two cusps - the bicuspid (mitral) valve. They are located between the atria and ventricles on each side of the heart. They prevent a backflow of blood from the ventricle to the atrium. Each cusp is restrained from bending the wrong way, i.e., prolapsing by tendinous cords, the chordae tendineae.

CHORDAE TENDINEAE

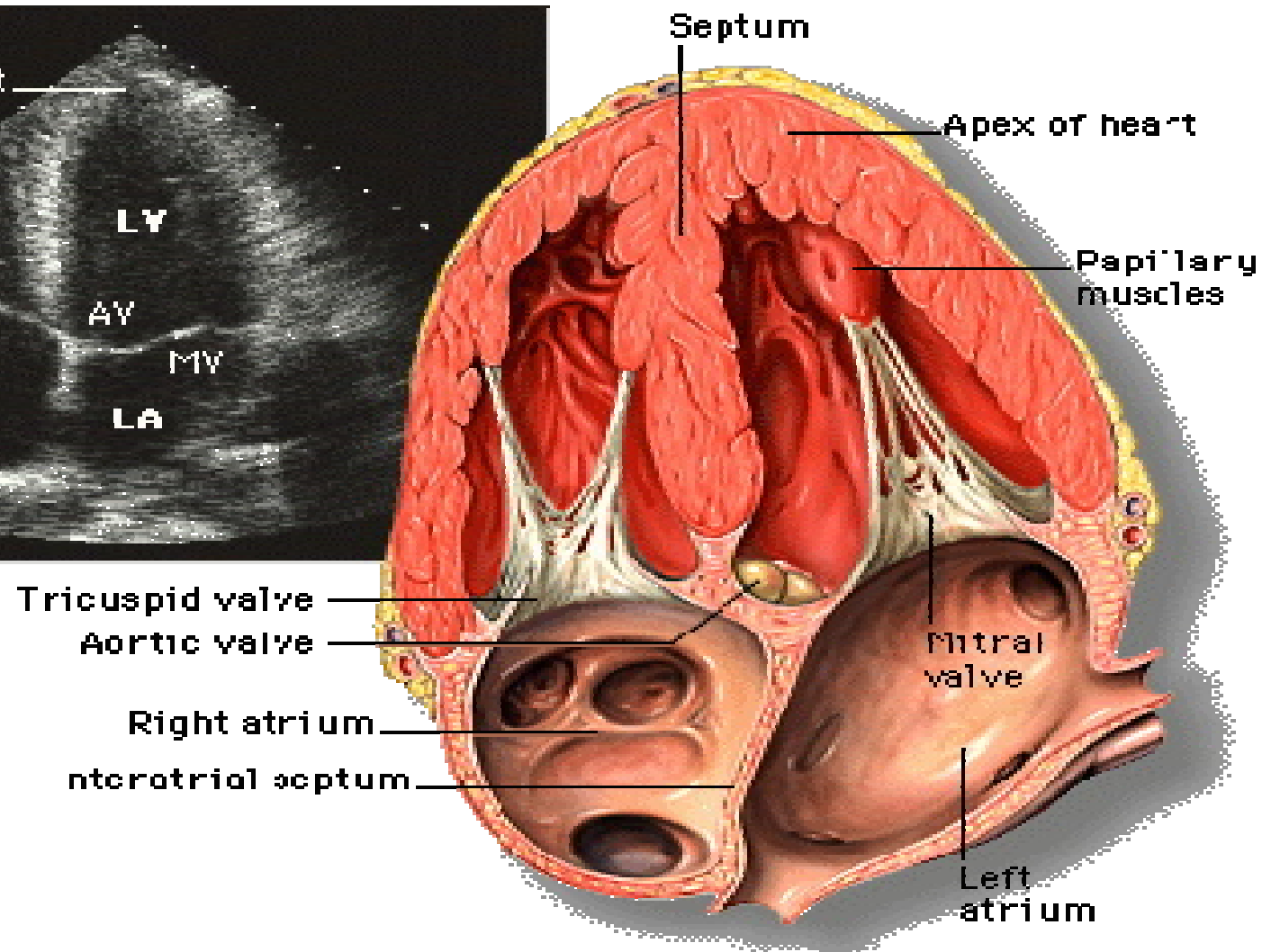
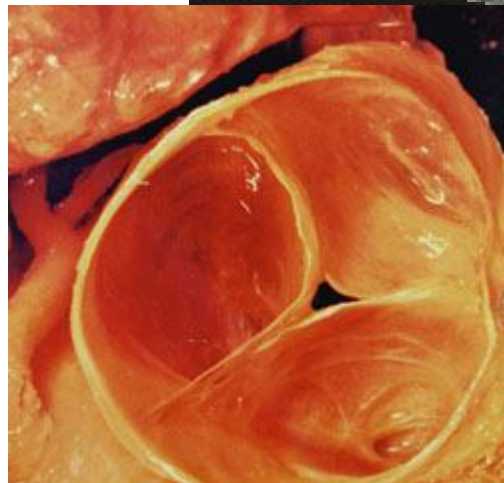
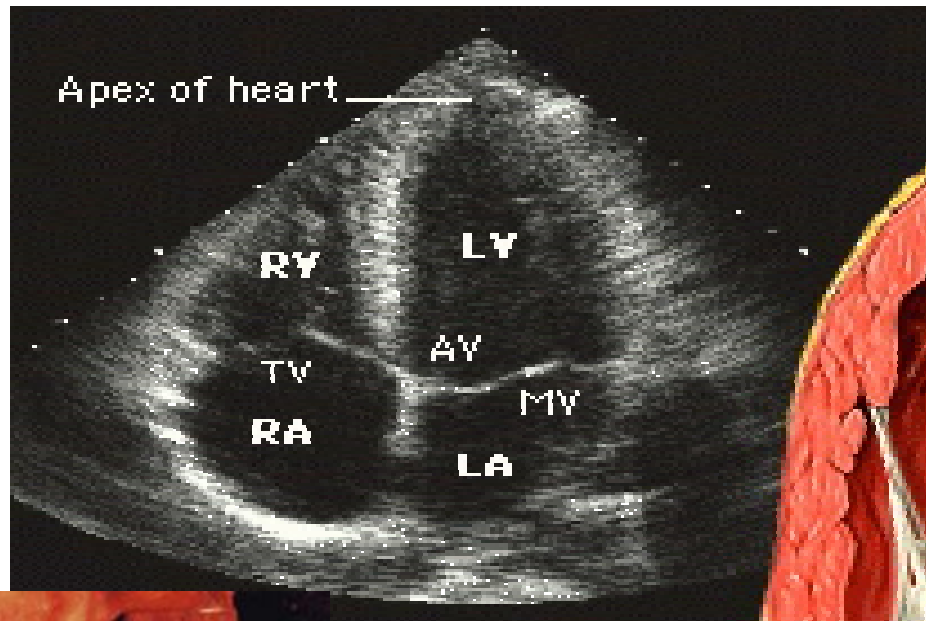


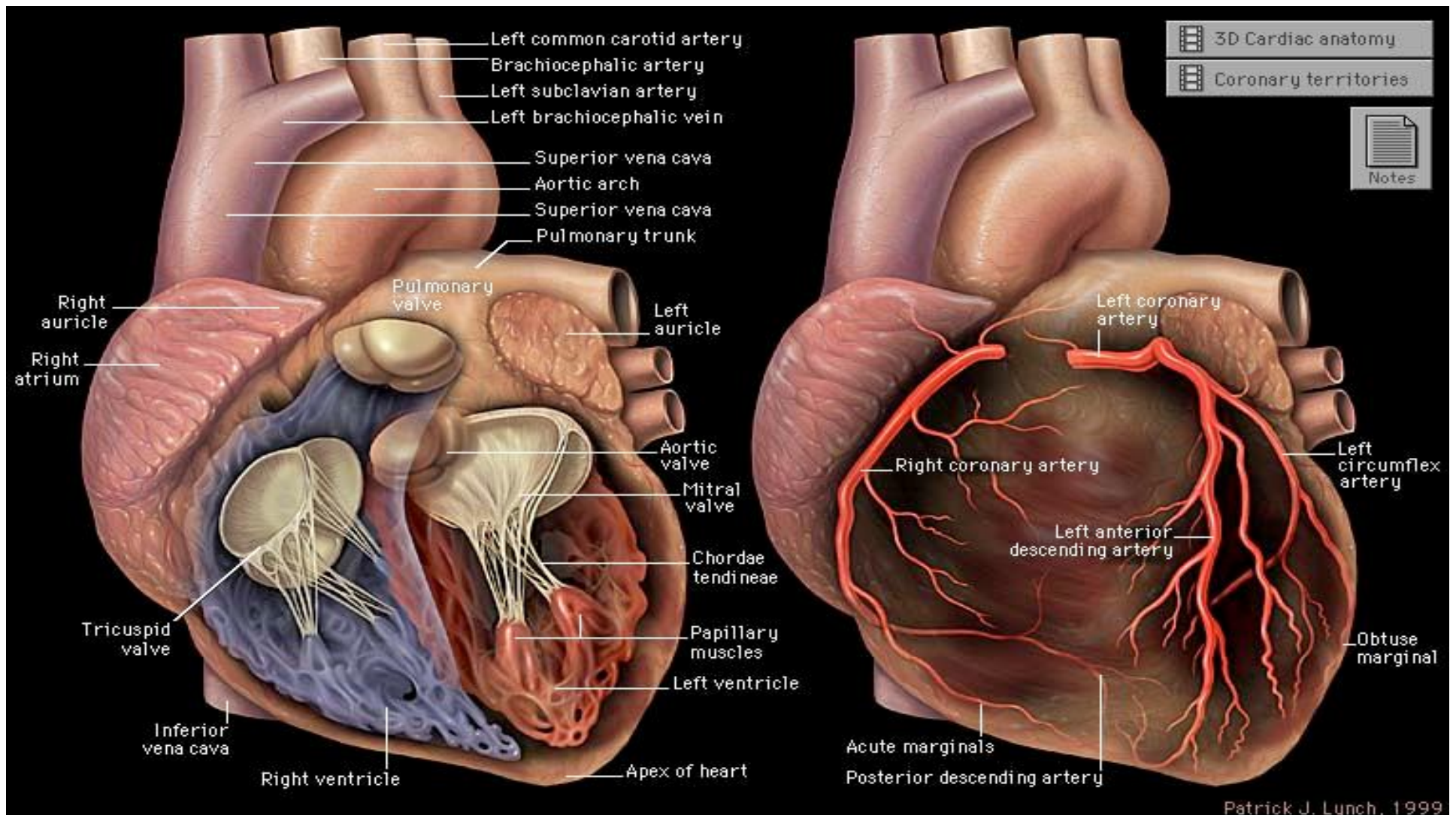
The papillary muscles (PM) anchoring the cords to the heart wall will contract to counter any stretch in the cordae tendineae (CT) during vigorous pumping of the heart.

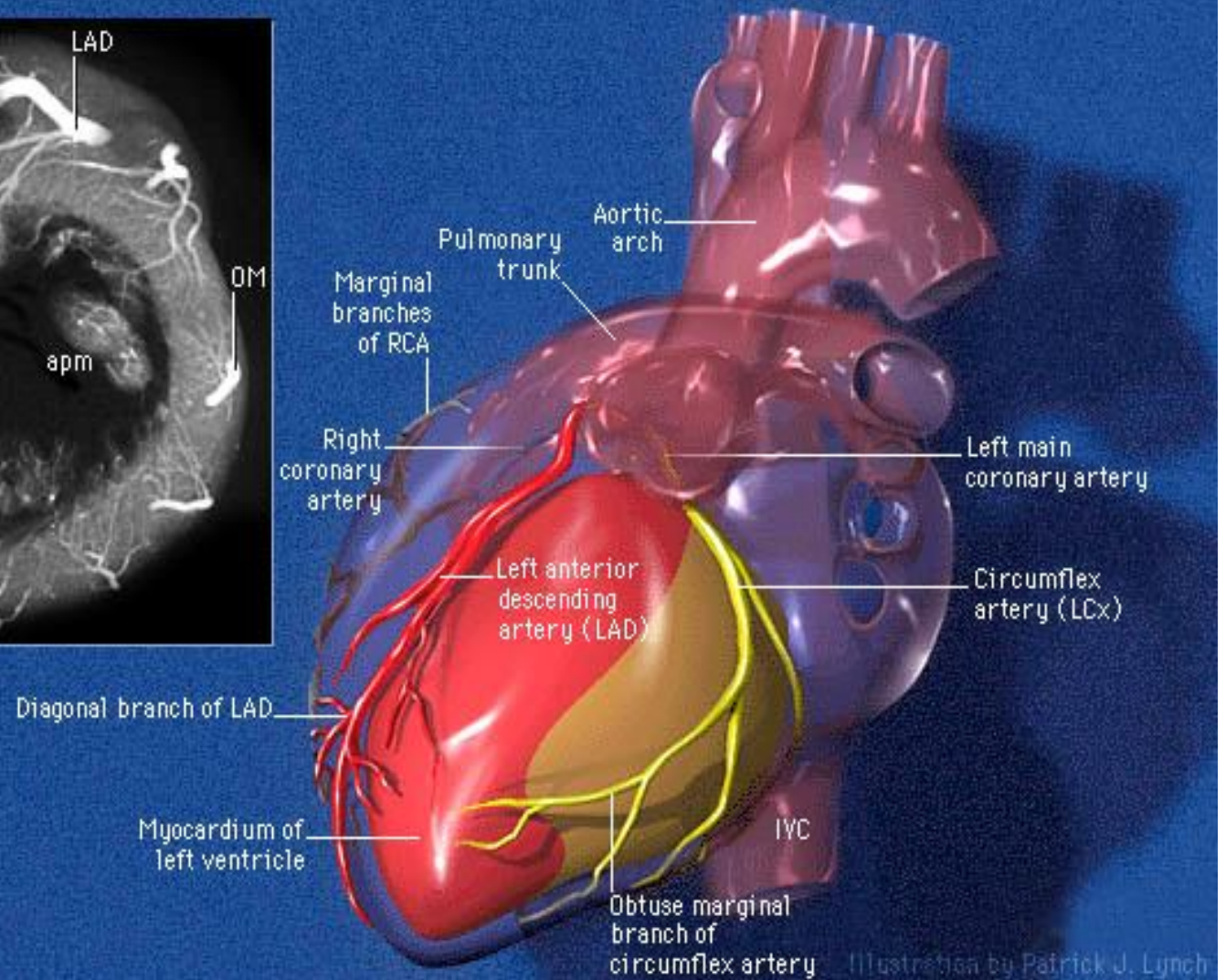
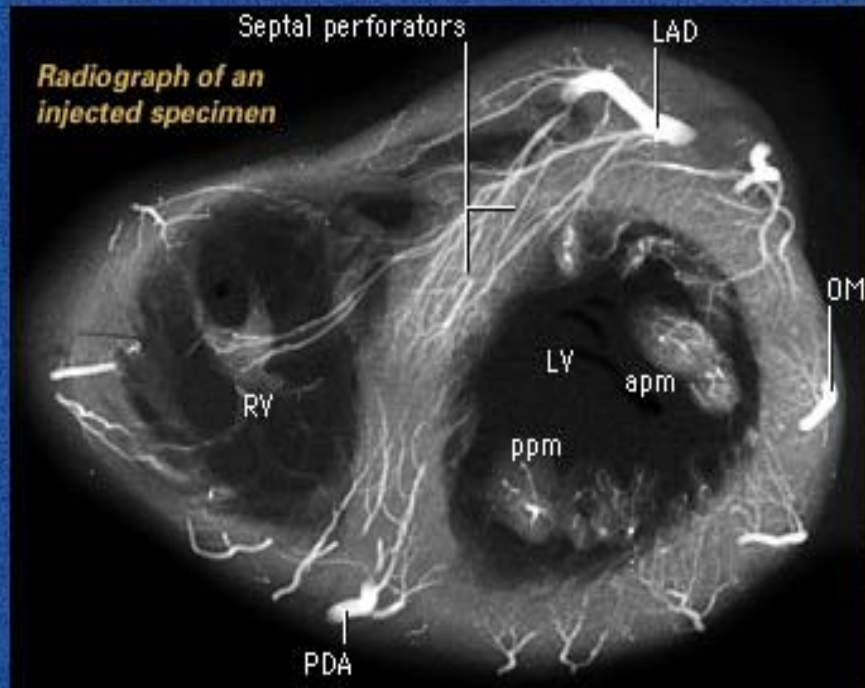
SEMILUNAR VALVES



The semilunar valves are found lining the walls of the pulmonary trunk (pulmonary valve) and the aorta (aortic valve). Each valve consists of three pocket-like endocardial cusps (c). During contraction of the ventricles (ventricular systole), the pockets are flattened against the walls of the ejecting vessels. As the ventricles begin to relax (diastole), the blood in the large arteries begins to fall back down into the ventricles. This causes the cusps to fill with blood and billow out closing the vessel and preventing a backflow.








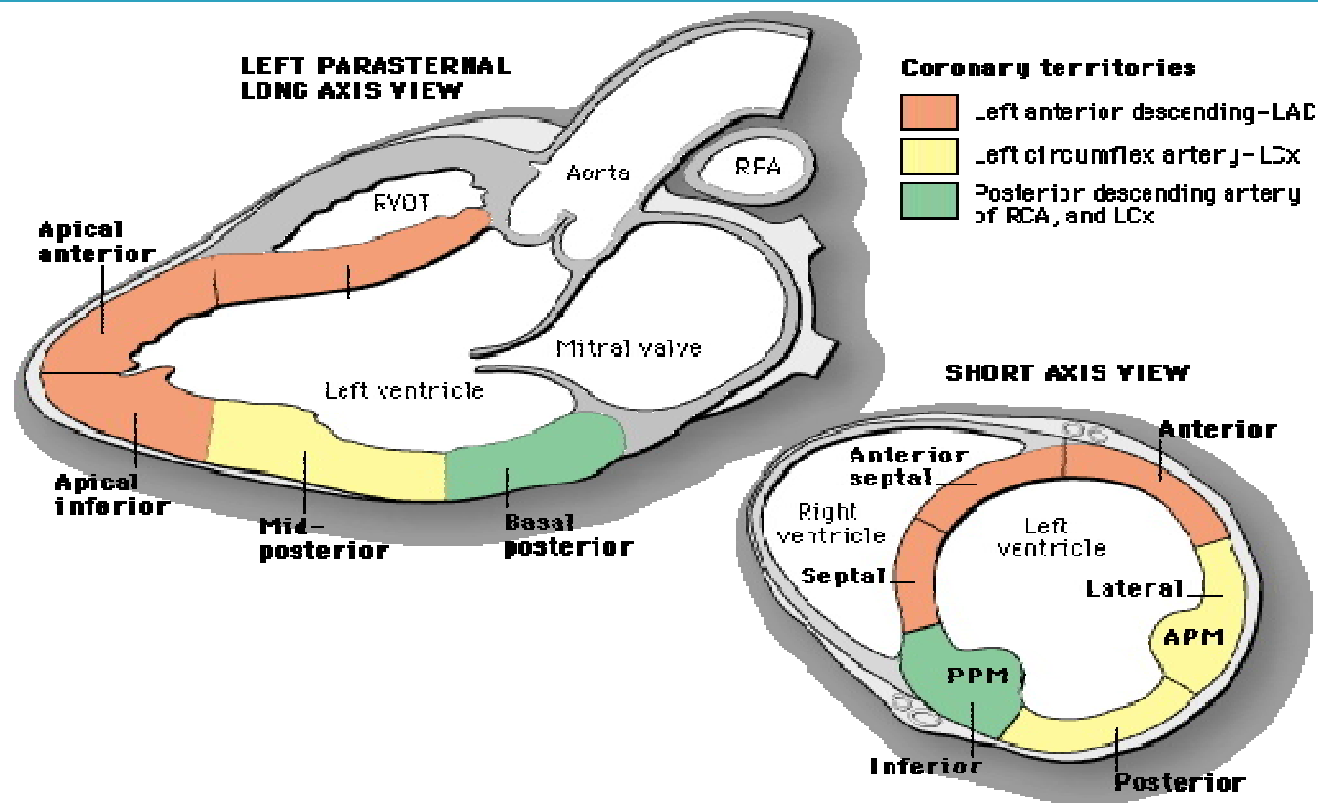
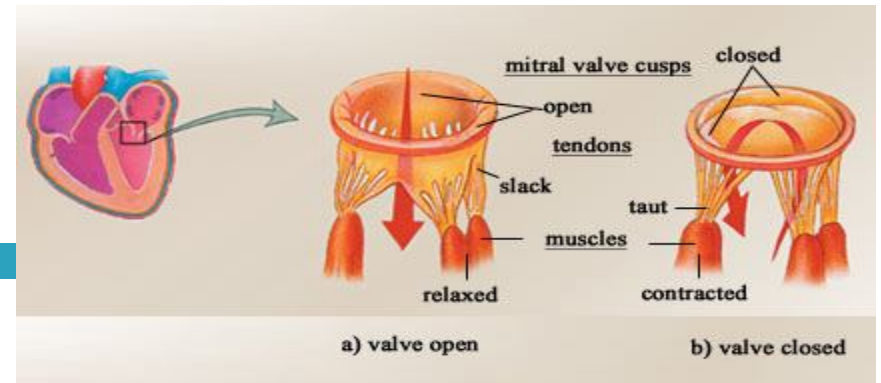
 3D Model Animation

Illustration by Patrick J. Lynch

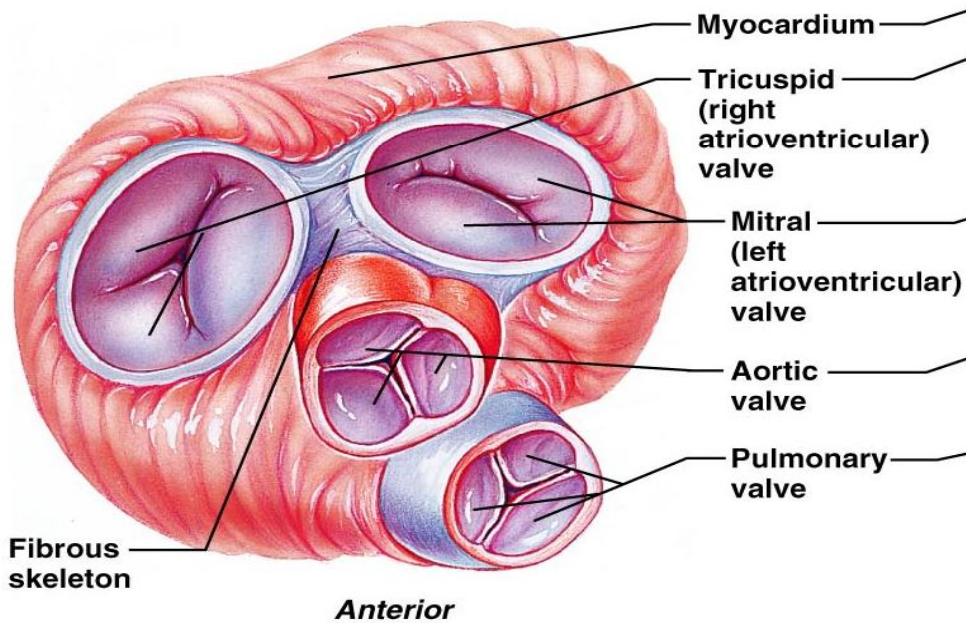
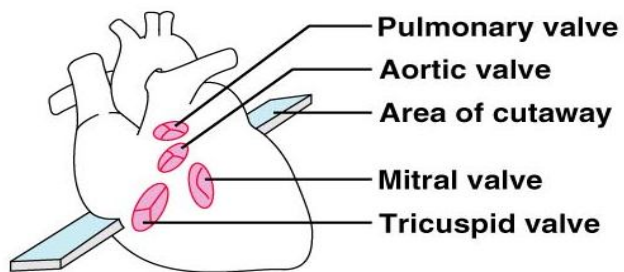
Myocardial Segment Anatomy



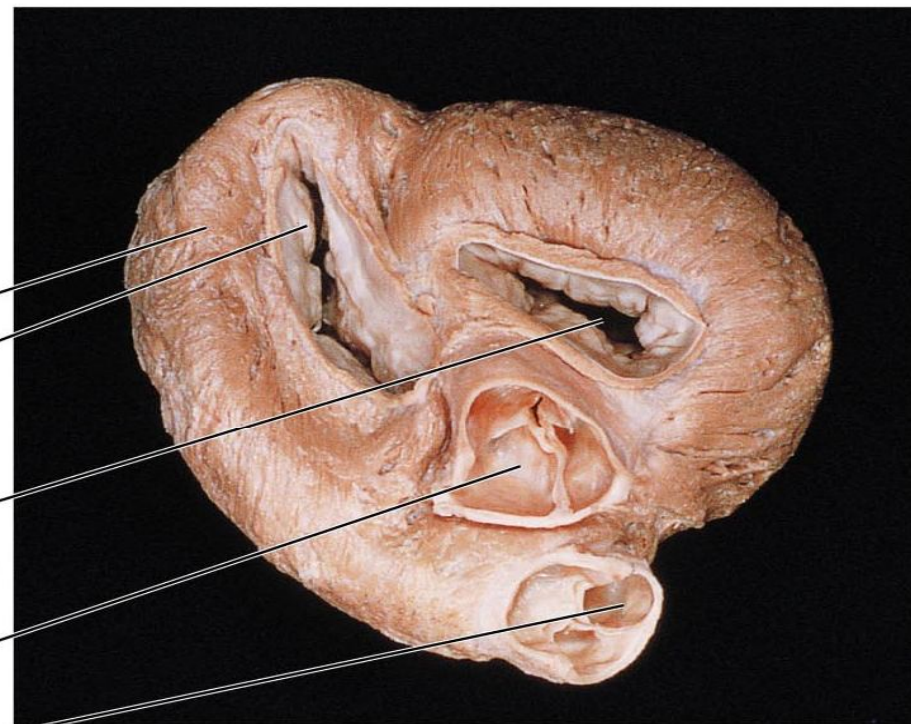
Heart Valves



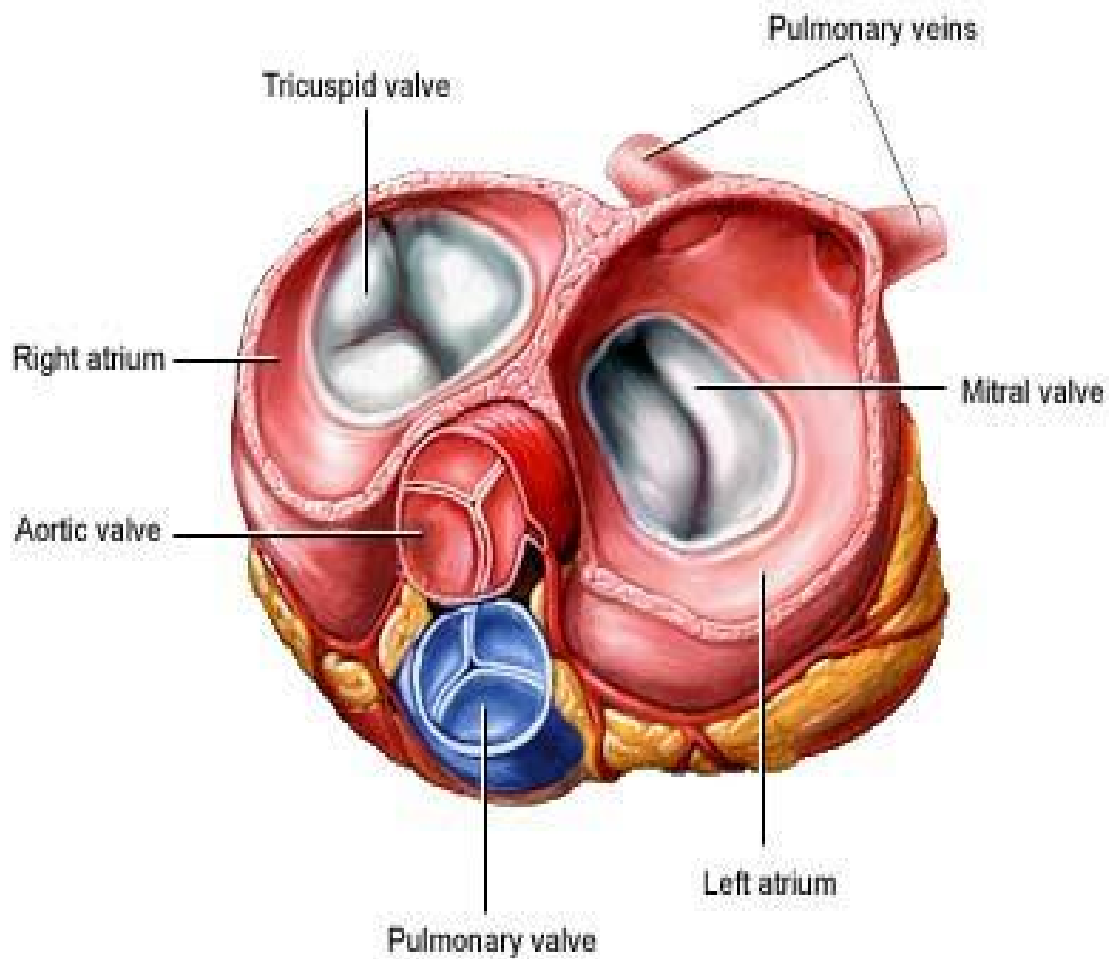
- ❑ Aortic semilunar valve lies between the left ventricle and the aorta
- ❑ Pulmonary semilunar valve lies between the right ventricle and pulmonary trunk
- ❑ Semilunar valves prevent backflow of blood into the ventricles



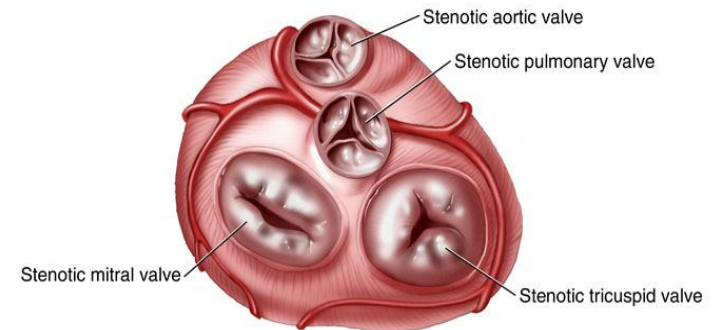
(a)



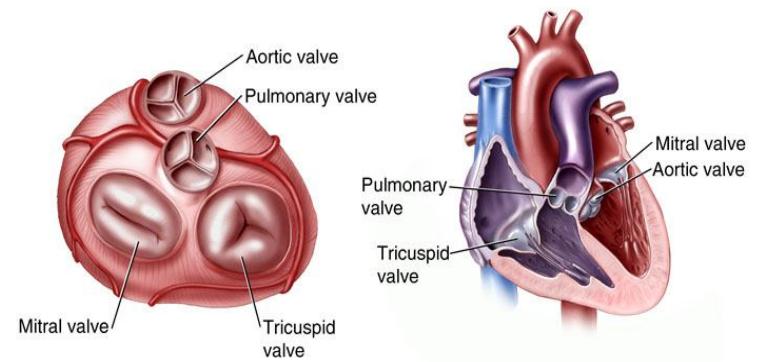
(b)



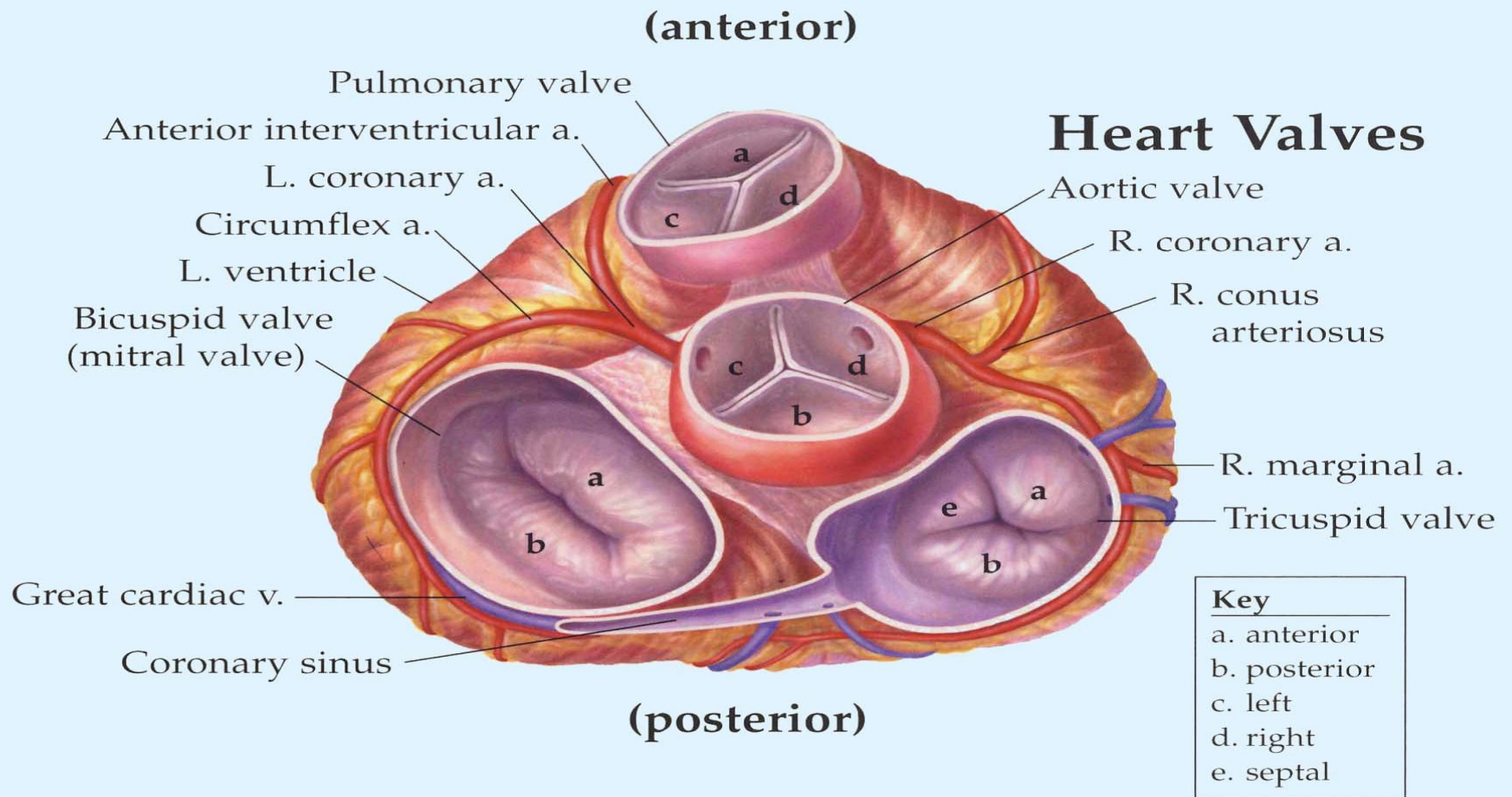
Normal and Diseased Heart Valves

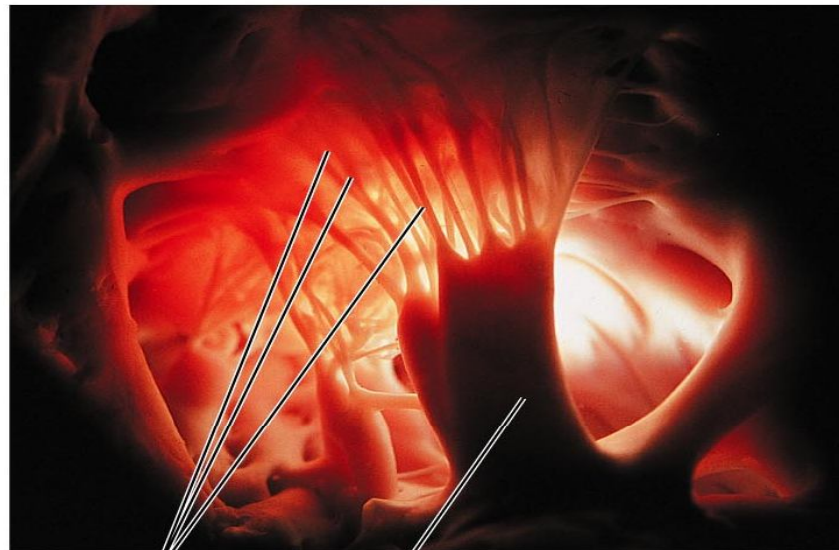


Diseased Heart Valves



Normal Heart Valves

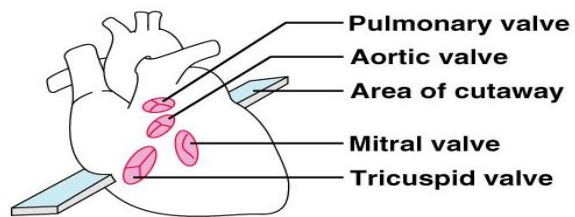




Chordae tendineae attached to tricuspid valve flap

Papillary muscle

(c)



Pulmonary valve

Aortic valve

Area of cutaway

Mitral valve

Tricuspid valve

Opening of superior vena cava

Tricuspid valve

Myocardium of right ventricle

Papillary muscles

(d)

Mitral valve

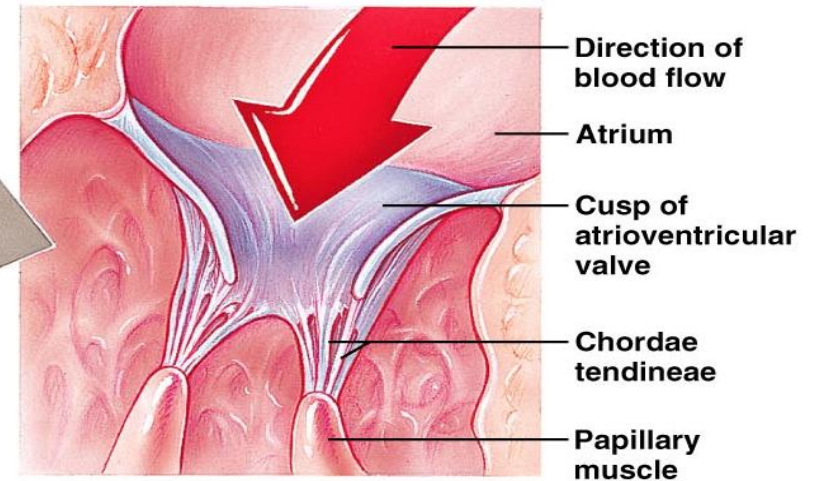
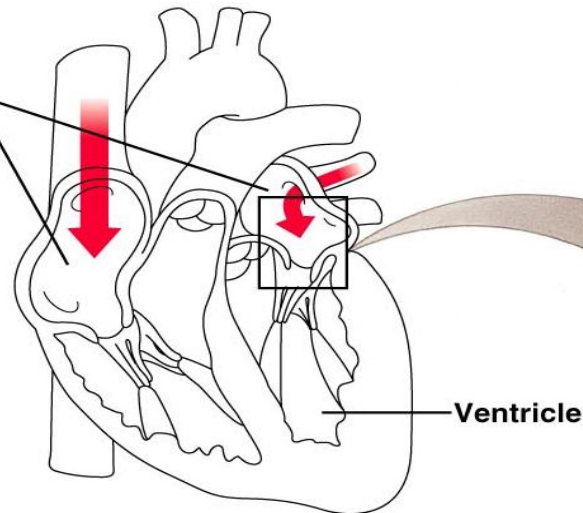
Chordae tendineae

Interventricular septum

Myocardium of left ventricle

Figure 18.8c, d

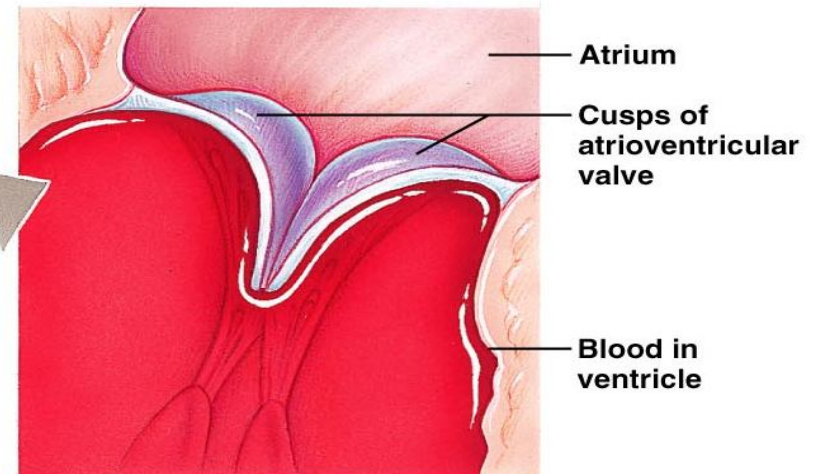
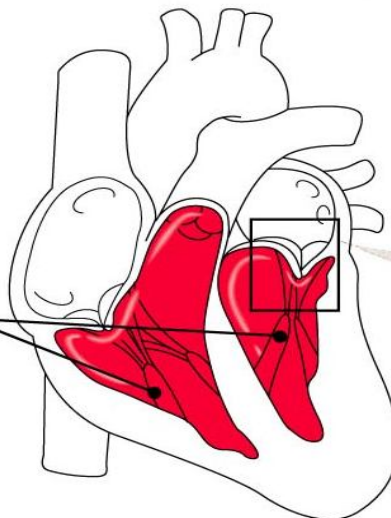
- ① Blood returning to the heart fills atria, putting pressure against atrioventricular valves; atrioventricular valves are forced open.
- ② As ventricles fill, atrioventricular valve flaps hang limply into ventricles.
- ③ Atria contract, forcing additional blood into ventricles.



Atrioventricular valve open

(a)

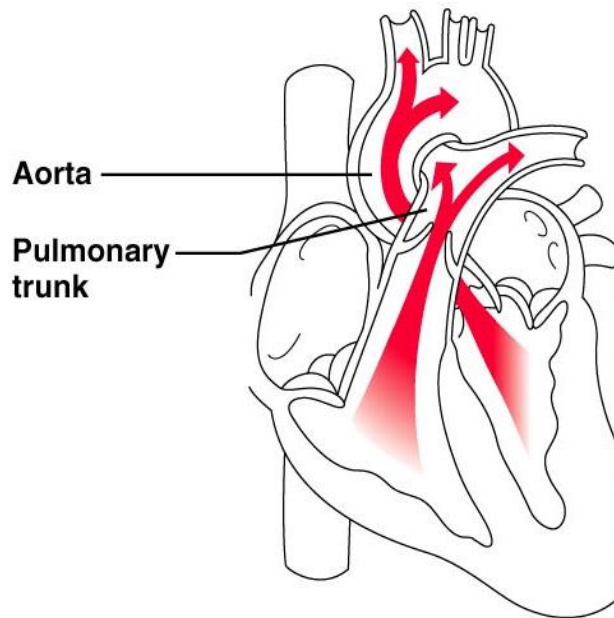
- ① Ventricles contract, forcing blood against atrioventricular valve cusps.
- ② Atrioventricular valves close.
- ③ Papillary muscles contract and chordae tendineae tighten, preventing valve flaps from everting into atria.



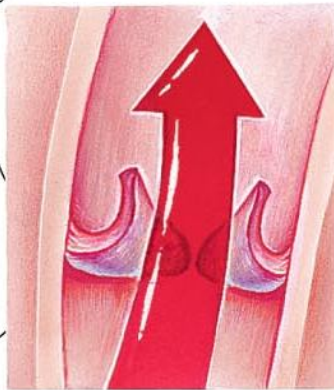Atrioventricular valve closed

(b)

Semilunar Valve Function

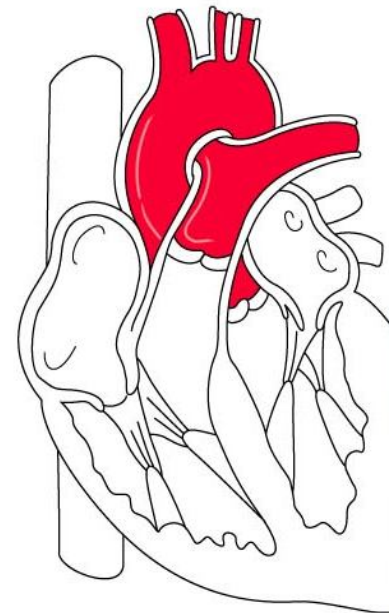


As ventricles contract and intraventricular pressure rises, blood is pushed up against semilunar valves, forcing them open.

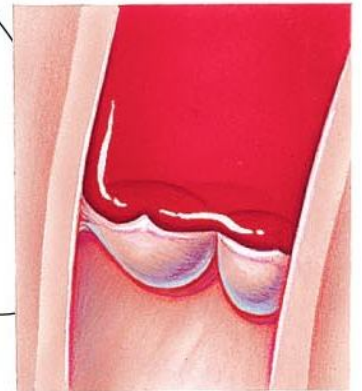


Semilunar valve open

(a)



As ventricles relax and intraventricular pressure falls, blood flows back from arteries, filling the cusps of semilunar valves and forcing them to close.



Semilunar valve closed

(b)

