ESOPHAGUS, STOMACH
GI ANATOMY PART 2

D.HAMMOUDI.MD

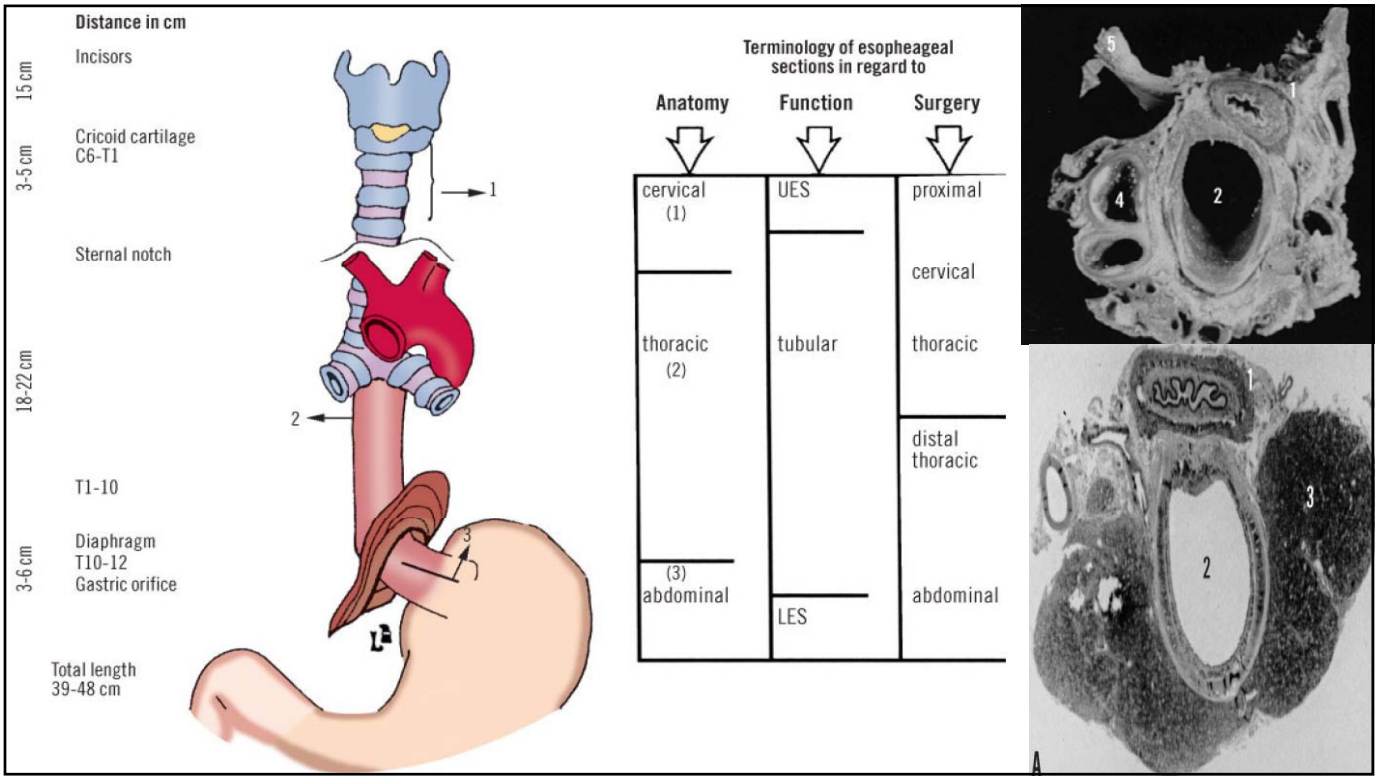

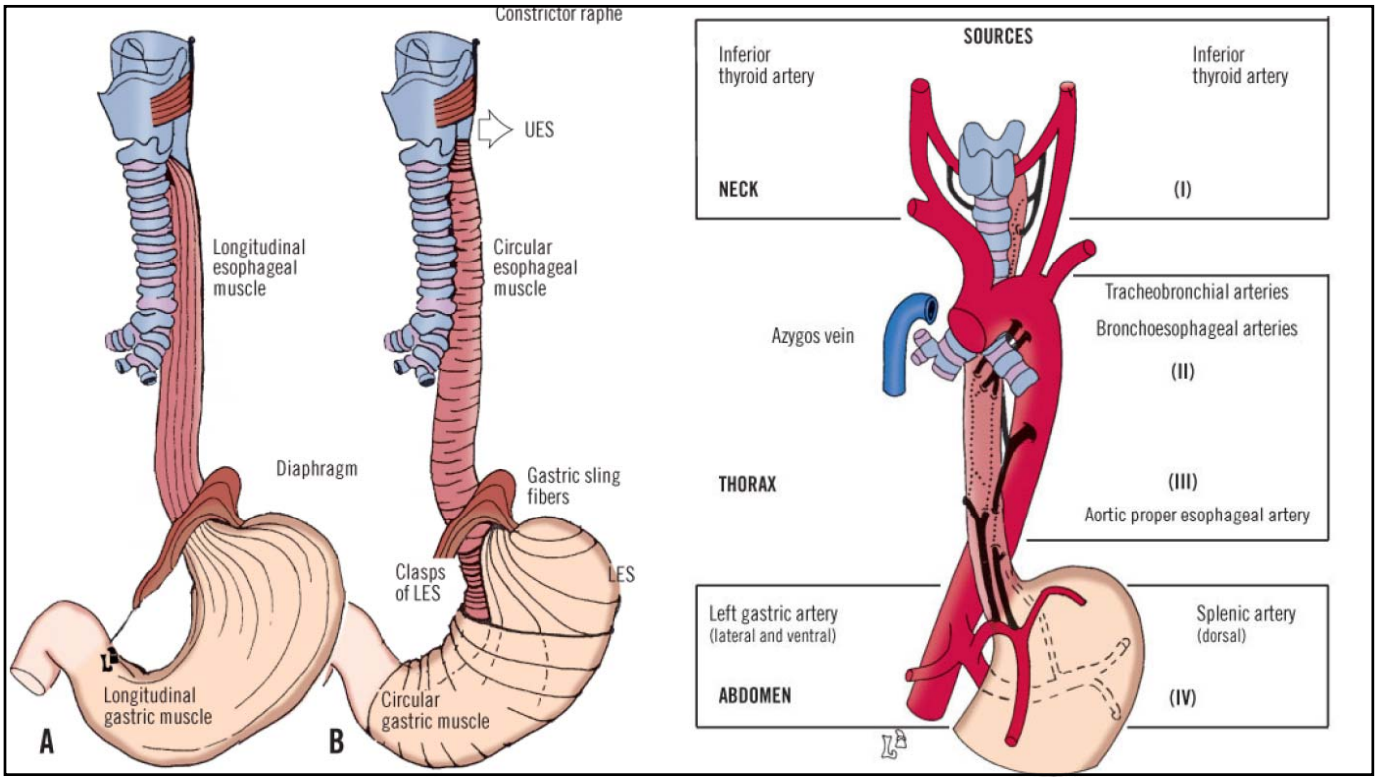
Constrictor raphe
UES
Longitudinal esophageal muscle
Circular esophageal muscle
Diaphragm
Gastric sling fibers
Clasps of LES
LES
Longitudinal gastric muscle
Circular gastric muscle
A
B
SOURCES
Inferior thyroid artery
Inferior thyroid artery
NECK
(I)
Tracheobronchial arteries
Bronchoesophageal arteries
Azygos vein
(II)
THORAX
(III)
Aortic proper esophageal artery
Left gastric artery (lateral and ventral)
Splenic artery (dorsal)
ABDOMEN
(IV)

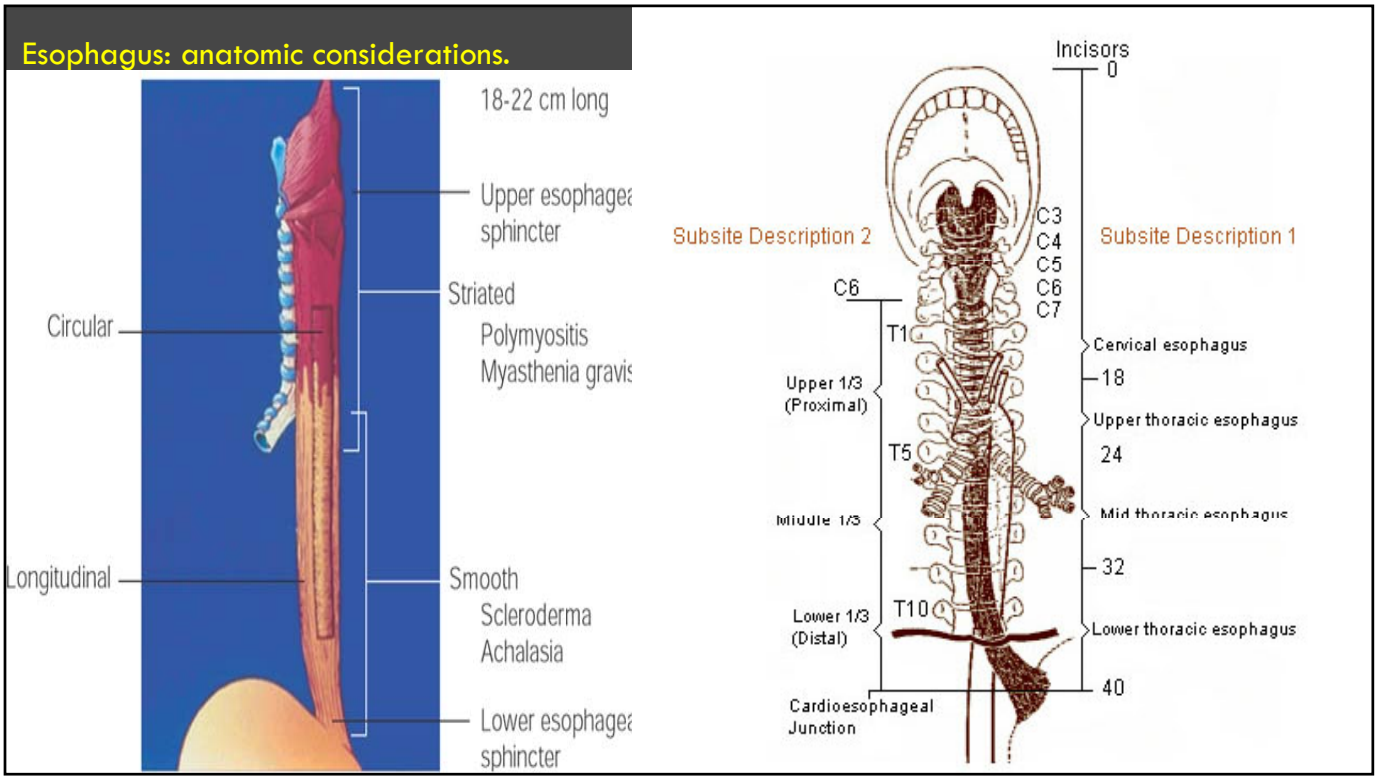
Esophagus: anatomic considerations.
18-22 cm long
Upper esophagea sphincter
Striated
Polymyositis
Myasthenia gravis
Circular
Longitudinal
Smooth
Scleroderma
Achalasia
Lower esophagea sphincter
Incisors
0
Subsite Description 2
Subsite Description 1
C3
C4
C5
C6
C7
C6
T1
Cervical esophagus
18
Upper 1/3 (Proximal)
Upper thoracic esophagus
T5
24
Middle 1/3
Mid thoracic esophagus
32
T10
Lower 1/3 (Distal)
Lower thoracic esophagus
40
Cardioesophageal Junction

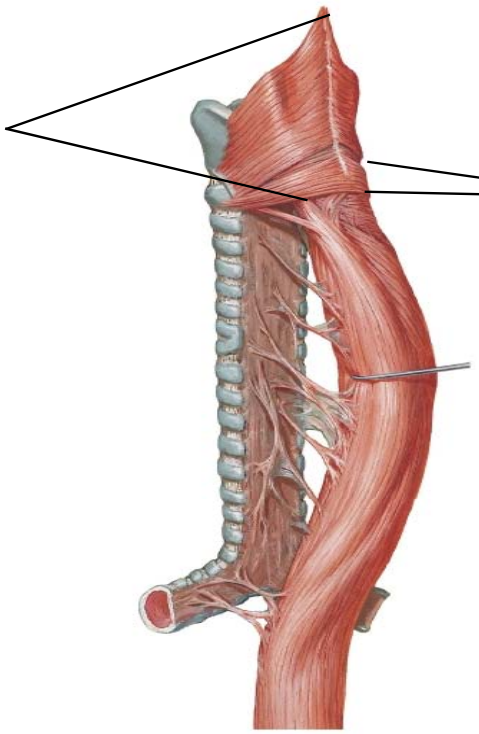

Lower esophageal sphincter

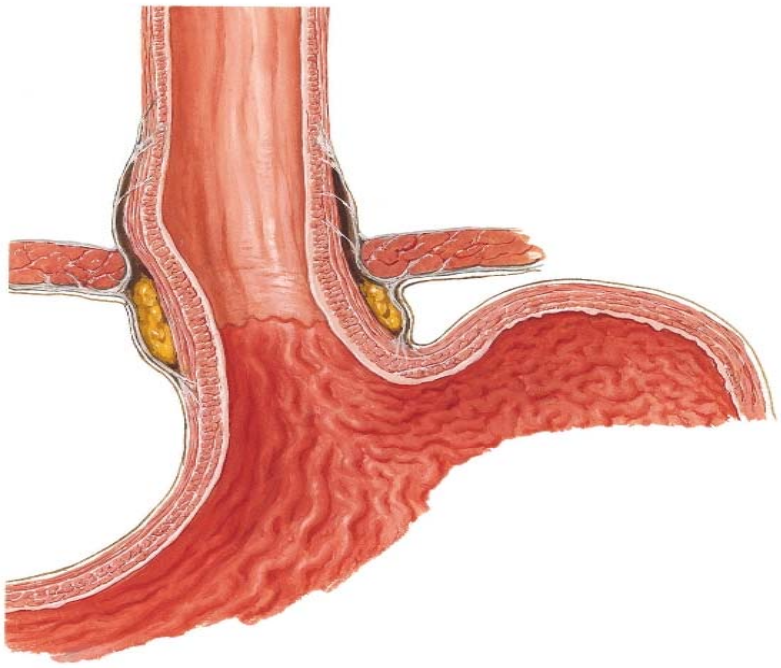

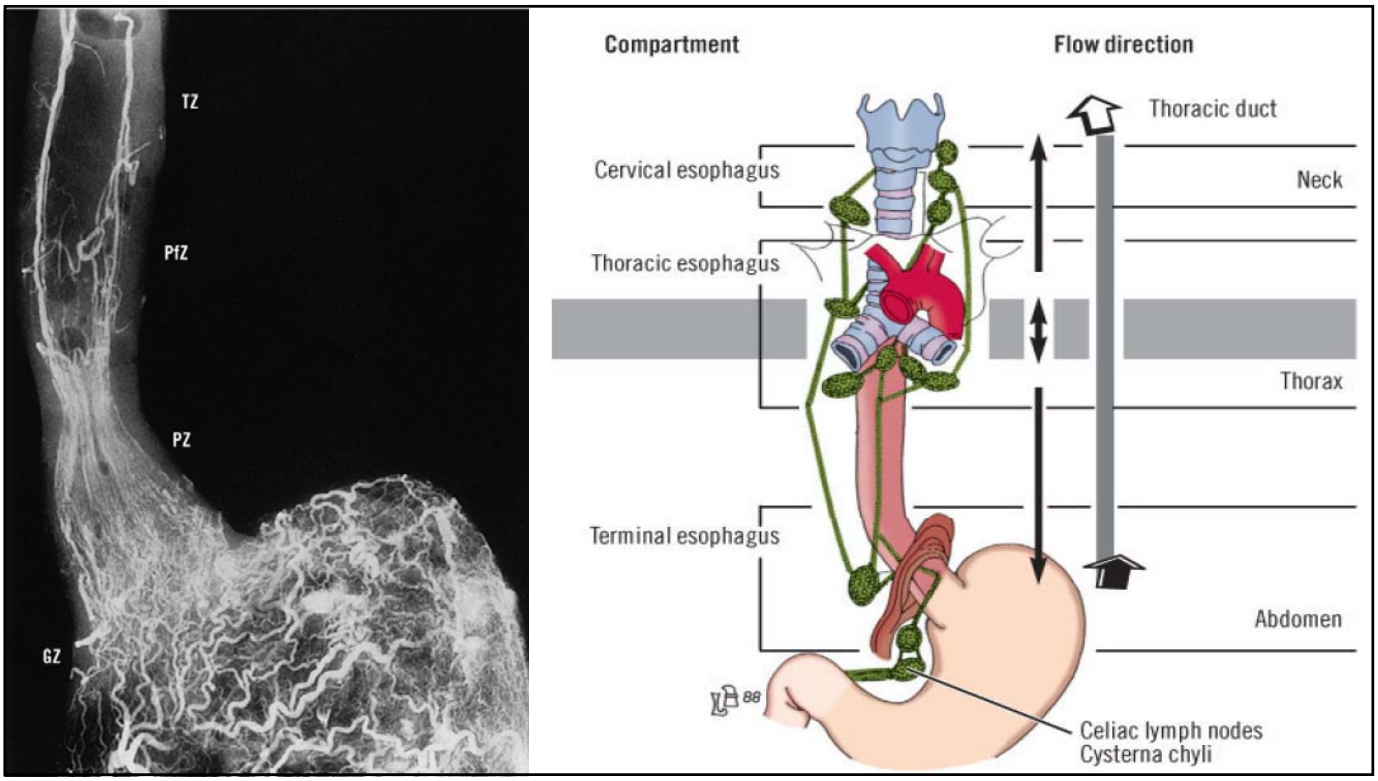

ESOPHAGUS

- Muscular tube going from the laryngopharynx to the stomach
- Travels through the mediastinum and pierces the diaphragm
- Joins the stomach at the cardiac orifice

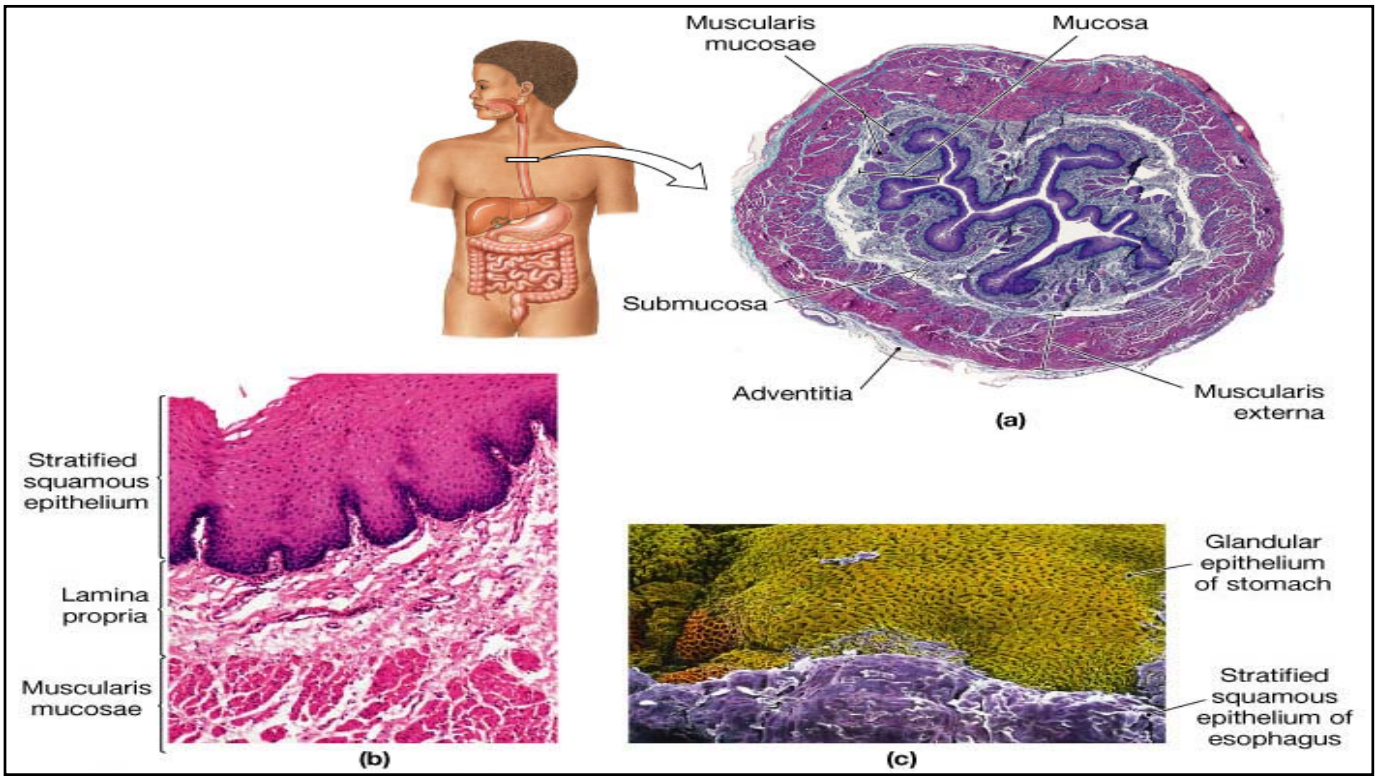
Muscularis mucosae
Mucosa
Submucosa
Adventitia
Muscularis externa
(a)
Stratified squamous epithelium
Lamina propria
Muscularis mucosae
(b)
Glandular epithelium of stomach
Stratified squamous epithelium of esophagus
(c)

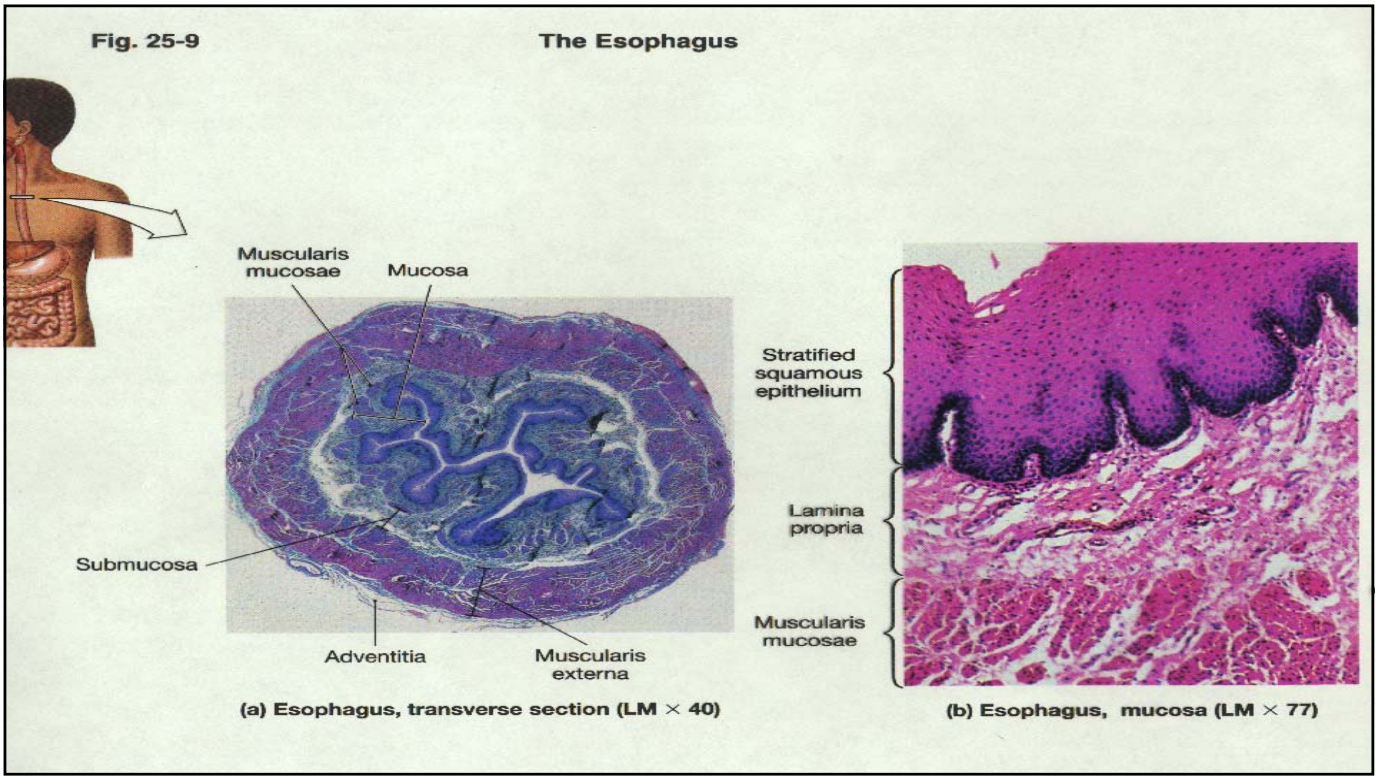
Fig. 25-9
The Esophagus
Muscularis mucosae
Mucosa
Submucosa
Adventitia
Muscularis externa
(a) Esophagus, transverse section (LM × 40)
Stratified squamous epithelium
Lamina propria
Muscularis mucosae
(b) Esophagus, mucosa (LM × 77)

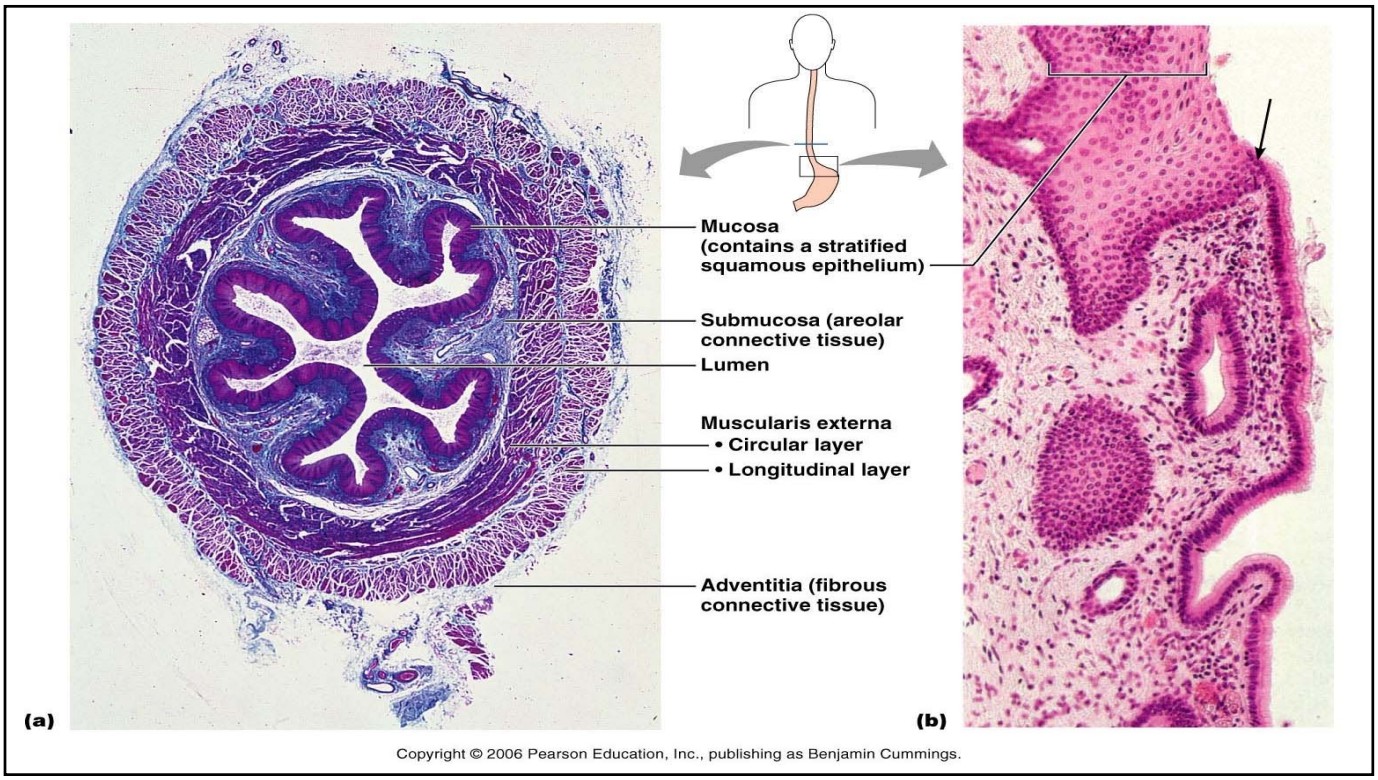

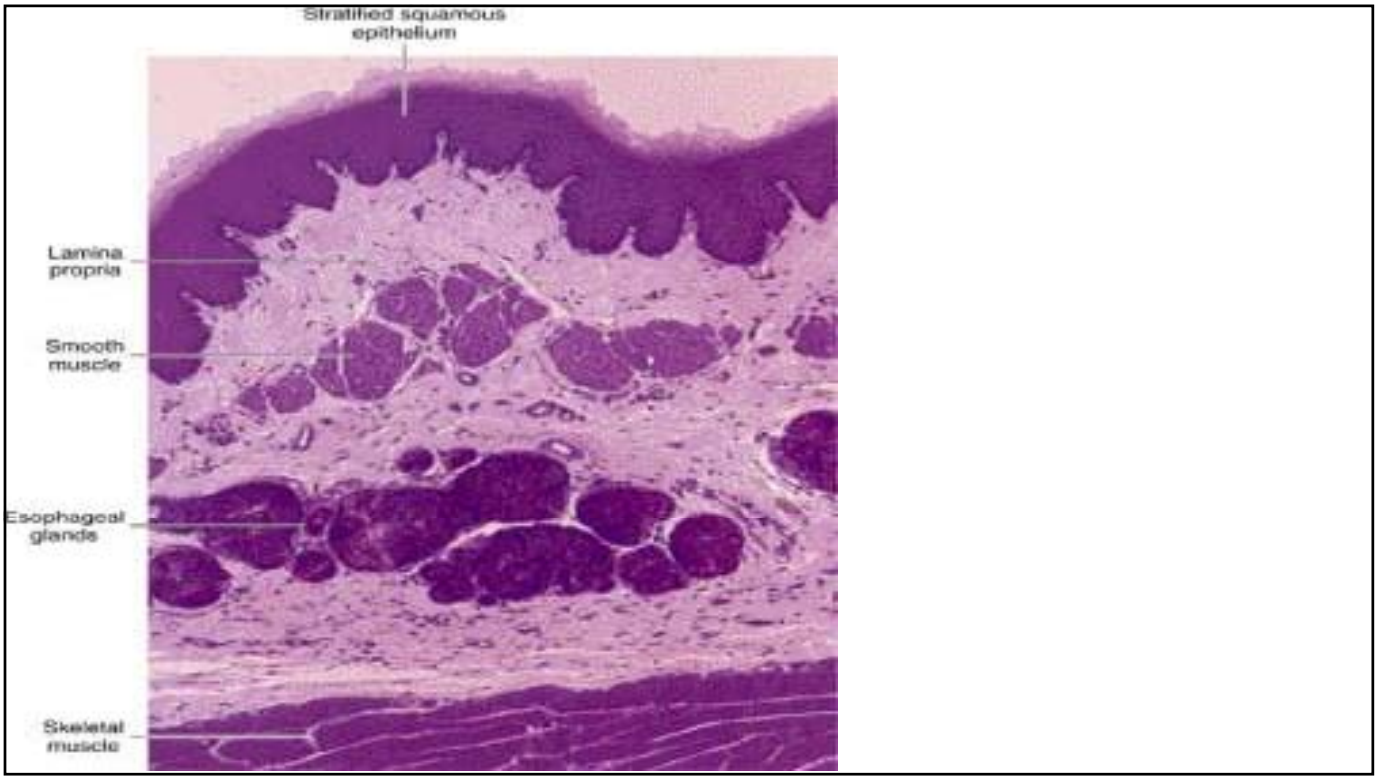

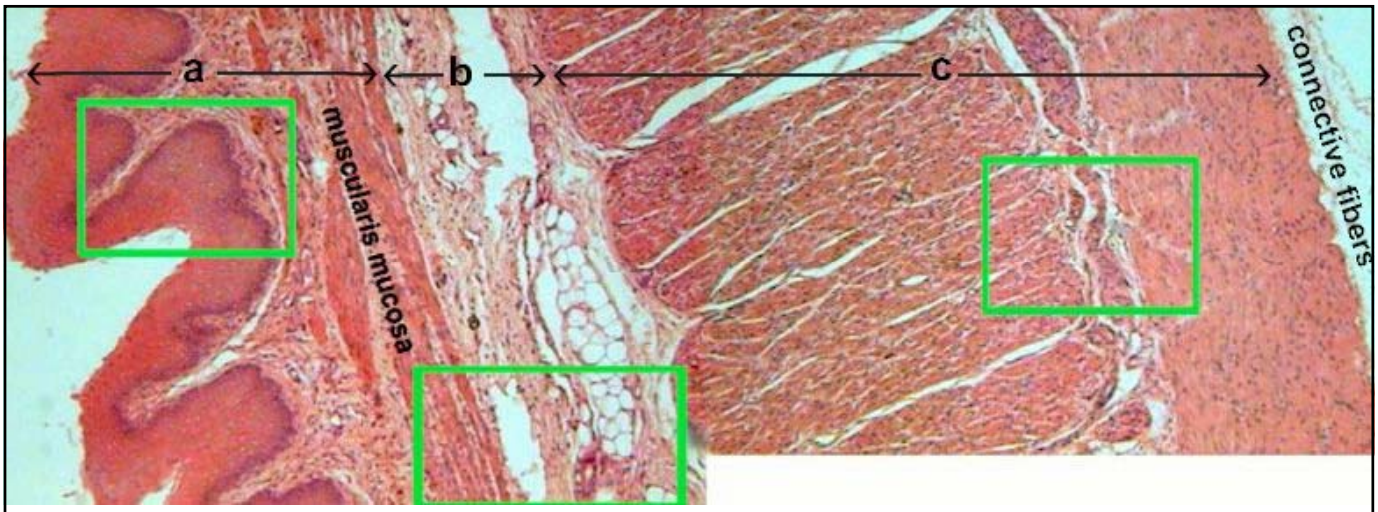

a. Mucosal layer on the surface is made up of stratified squamous epithelial cells, glands and muscularis mucosa.

b. Submucosa containing adipose, fibrous connective tissue and blood vessels.

c. Muscularis with circular and longitudinal muscle layers.

The internal surface of the esophagus is made up of **stratified squamous epithelial cells** which protect the esophagus from the abrasive flow of the undigested food to the stomach.

The **lamina propria and the basement membrane** together give connective tissue support to the epithelial layer.

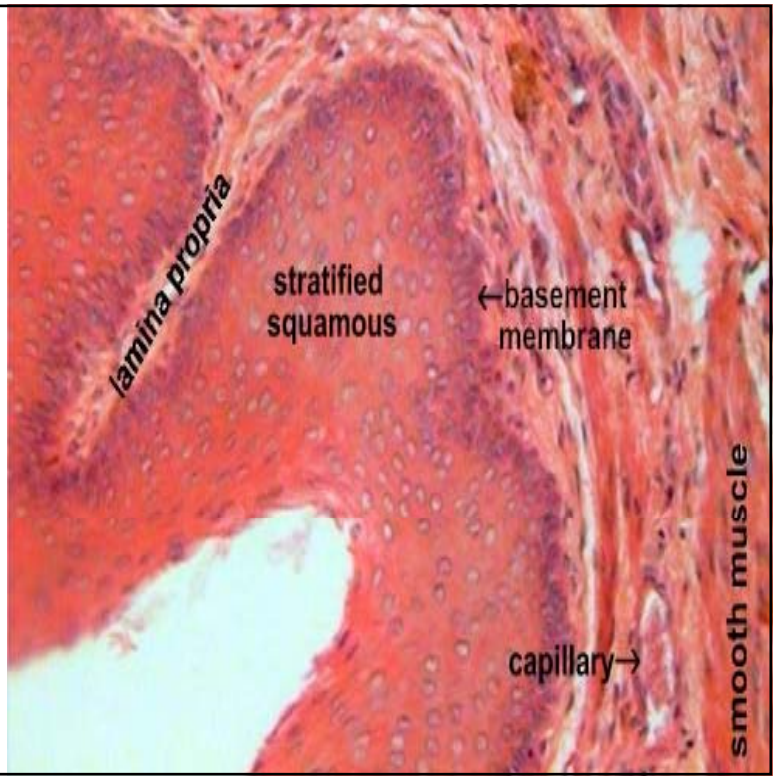

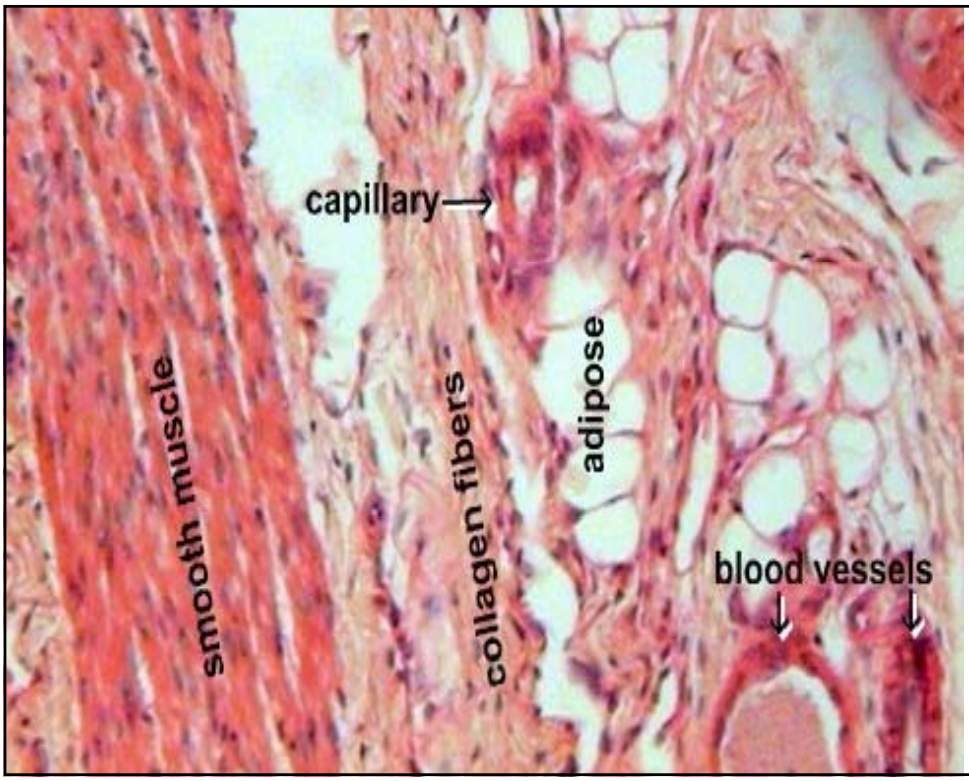

The above submucosal layer as evidenced by the various tissue types has many functions which includes support (collagen), nutrition (blood vessels & adipose) as well as movement (smooth muscle).

ESOPHAGUS

Stained with haematoxylin and eosin

1 - tunica mucosa
2 - tunica submucosa
3 - tunica muscularis propria
4 - tunica adventitia
5 - epithelium of the mucosa
6 - lamina propria of the mucosa
7 - muscularis mucosae
8 - glands in the lamina propria

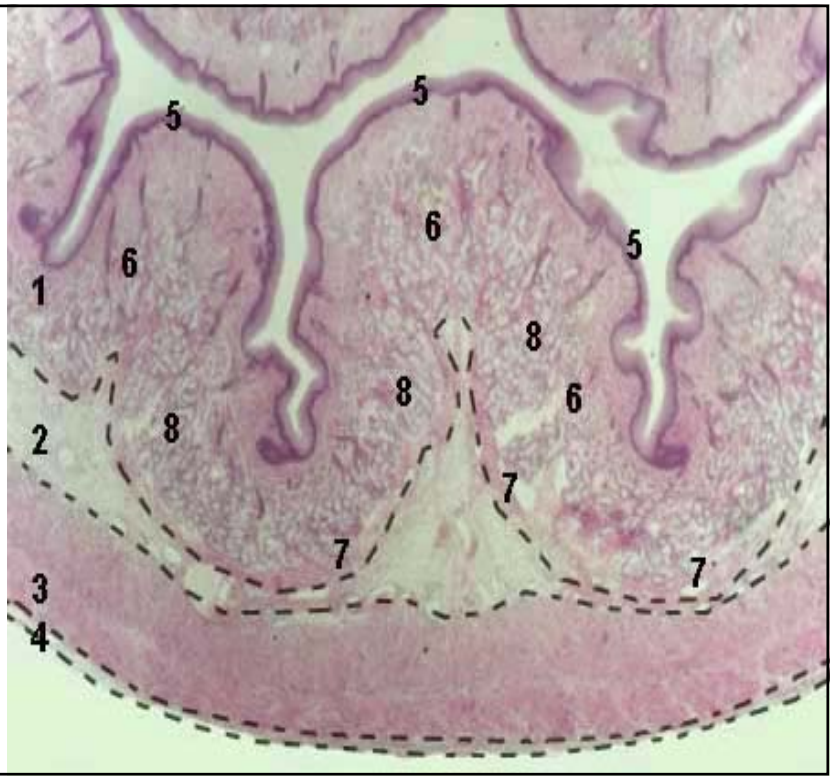

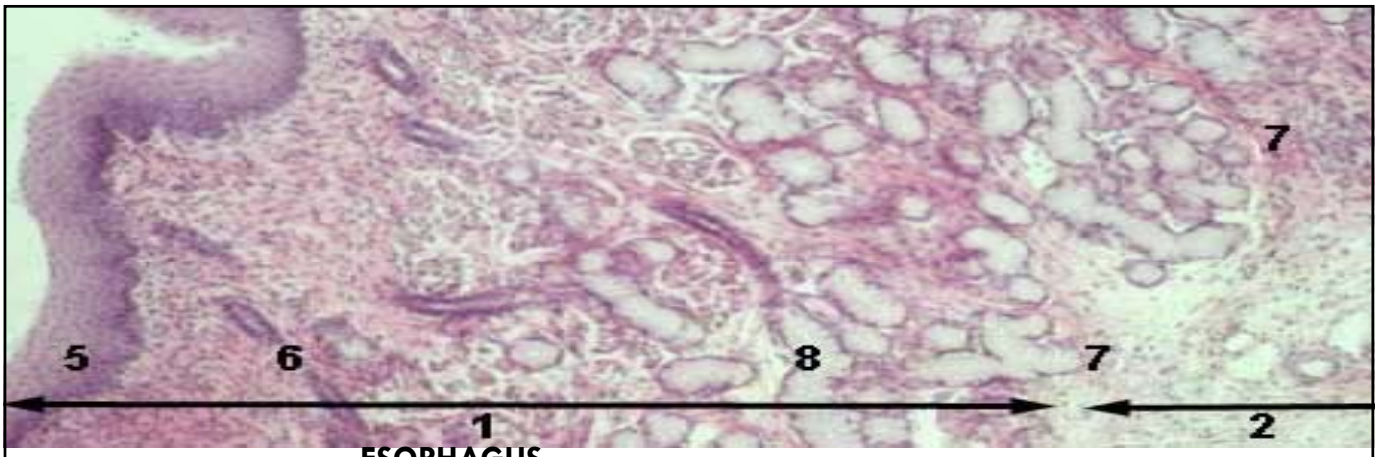

ESOPHAGUS

Stained with haematoxylin and eosin

1 - tunica mucosa
2 - tunica submucosa
5 - epithelium of the mucosa
6 - lamina propria of the mucosa
7 - muscularis mucosae
8 - glands in the lamina propria

ESOPHAGUS

Stained with haematoxylin and eosin

1 - tunica mucosa
2 - tunica submucosa
3 - tunica muscularis propria
4 - tunica adventitia
5 - epithelium of the mucosa
6 - lamina propria of the mucosa
7 - muscularis mucosae
8 - glands in the lamina propria

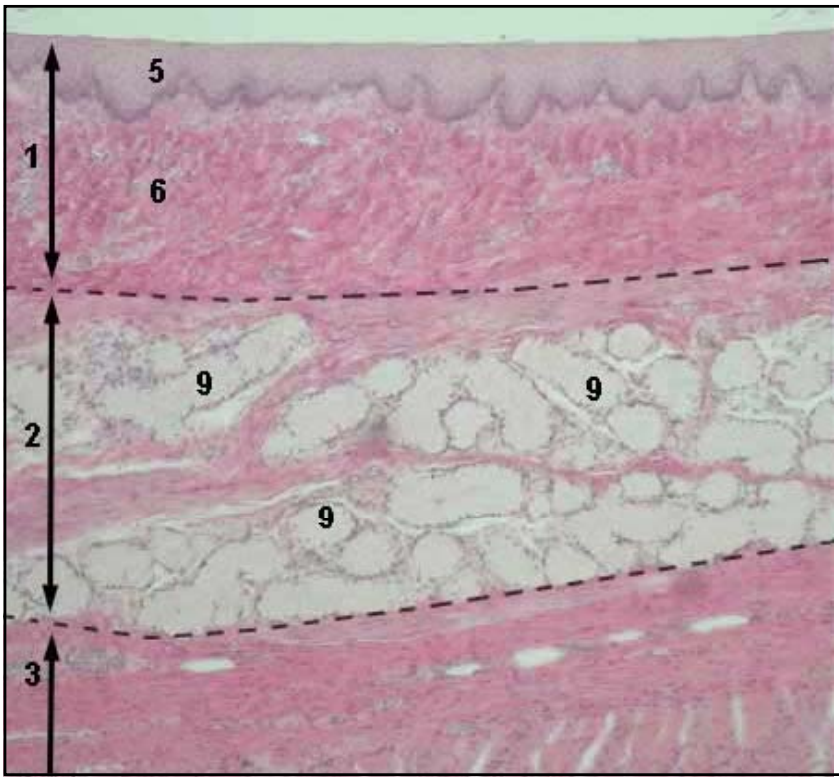

ESOPHAGUS

Stained with haematoxylin and eosin

1 - tunica mucosa
2 - tunica submucosa
3 - tunica muscularis propria
5 - epithelium of the mucosa
6 - lamina propria of the mucosa
9 - glands in the submucosa

Esophagus (Skeletal Muscle)

Muscularis externa – has inner circular and outer longitudinal layers (but "appears irregularly arranged in many areas" – p. 45, manual)

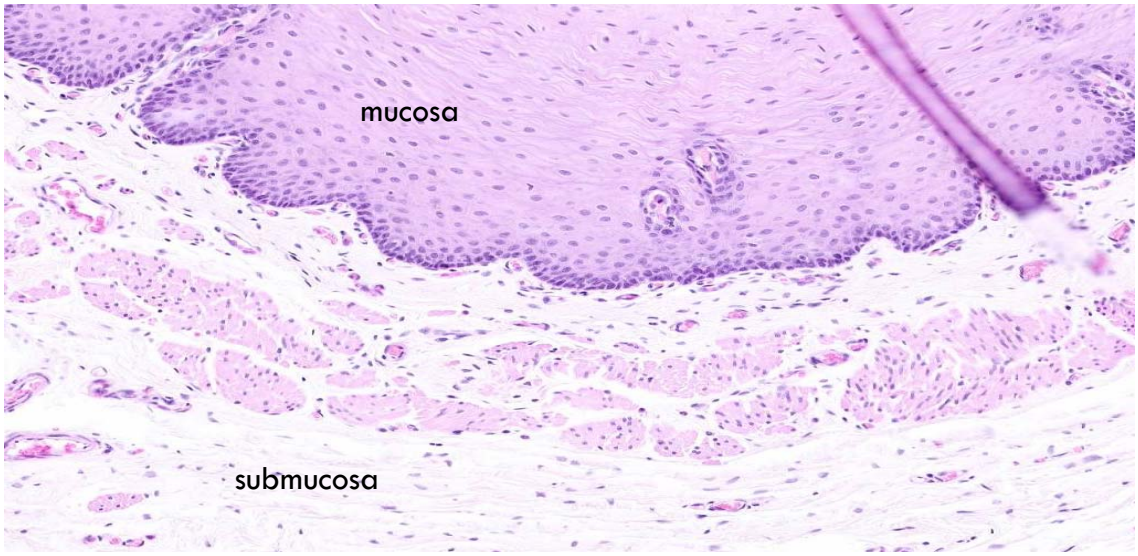

Mucosa – stratified squamous epithelium; cells are flat but contain nuclei; deepest layer is darkly stained and constitutes germinative layer

Submucosa – thick CT layer; contains large vessels, nerves, mucous glands (esophageal glands)

Esophagus, Upper Human MCO 0069

Myenteric ganglion a.k.a. Auerbach's plexus – situated between circular and longitudinal layers of muscle

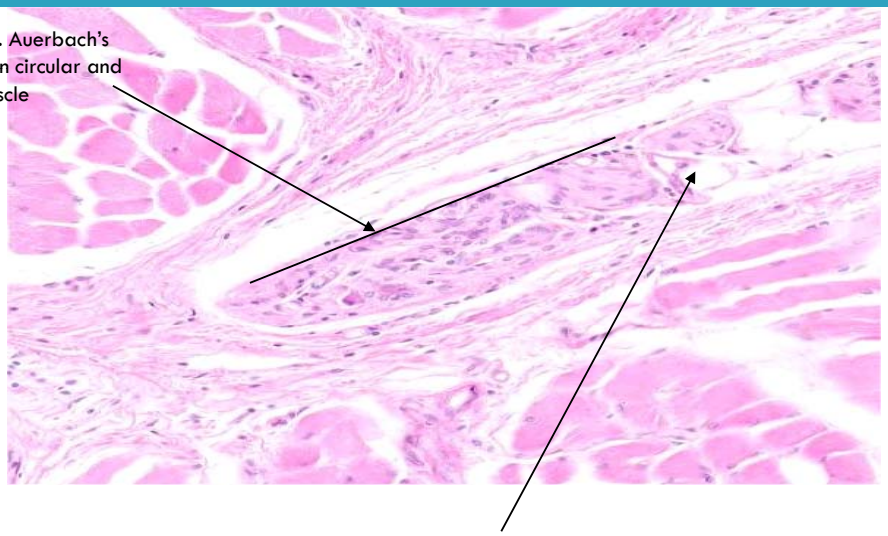

vessel

Middle Esophagus (MCO 0070) low mag

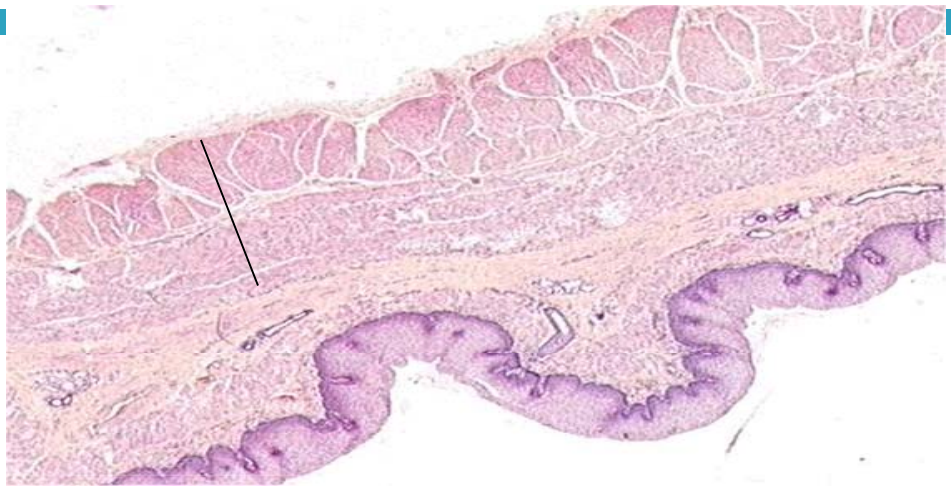

"the muscularis externa of the middle esophagus contains smooth and skeletal muscle, especially in the outer, longitudinal layer" –

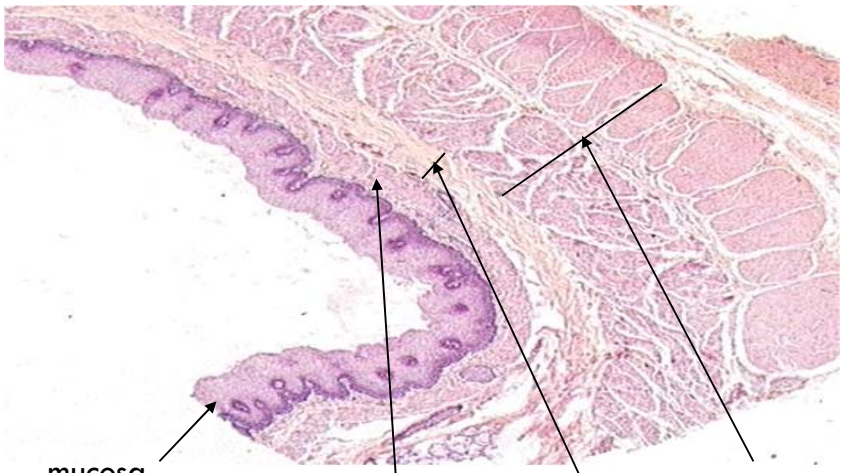

Tunica adventitia – loose areolar tissue to dense CT

mucosa

Muscle – find myenteric ganglion here

Lamina propria

submucosa

Esophageal-Stomach (cardia) junction – MCW 059

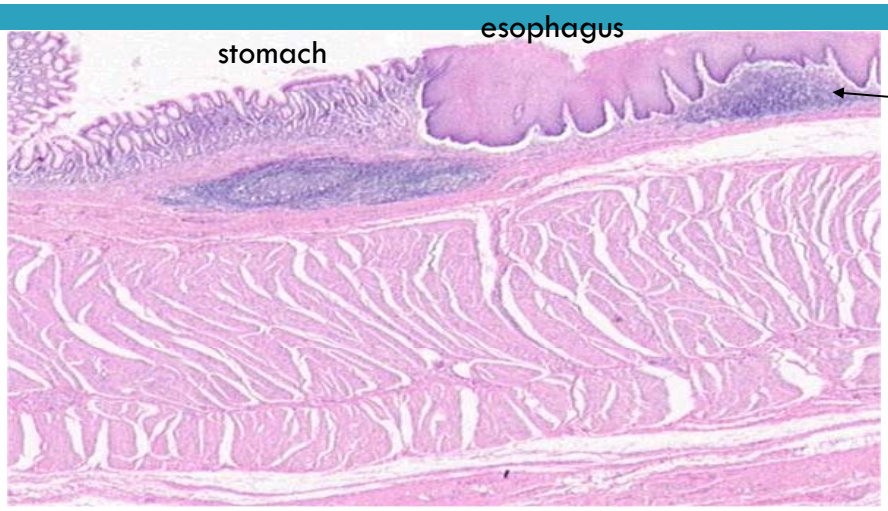

NOTE: muscularis externa of lower esophagus is all smooth muscle

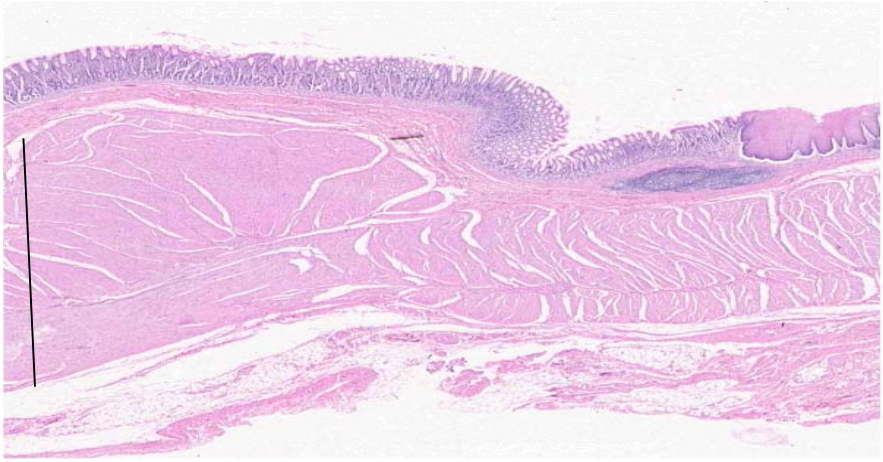

Muscularis externa of stomach – has inner oblique, middle circular, and outer longitudinal

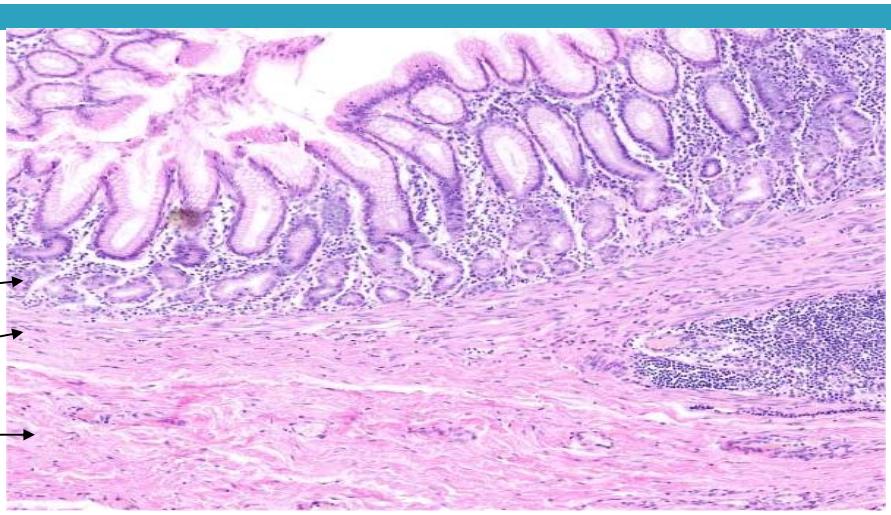

Lamina propria (has glands)

submucosa

muscle

Muscularis mucosa –thin - difficult to find

MCO 071 – esophageal-stomach junction

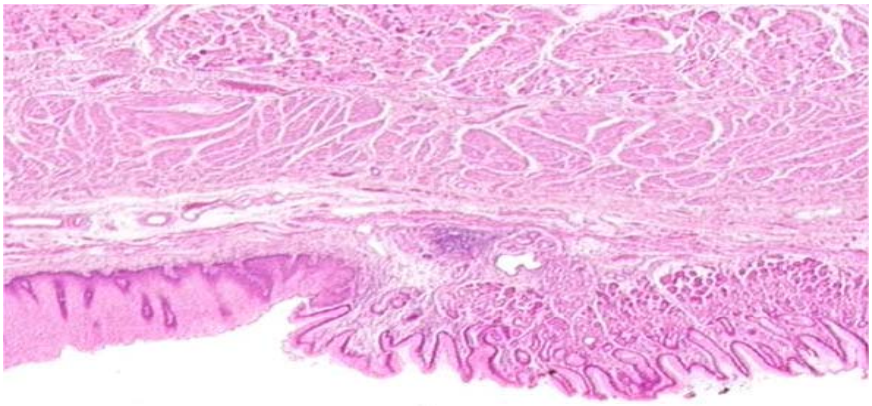

Esophagus (stratified squamous)

Stomach (simple columnar)

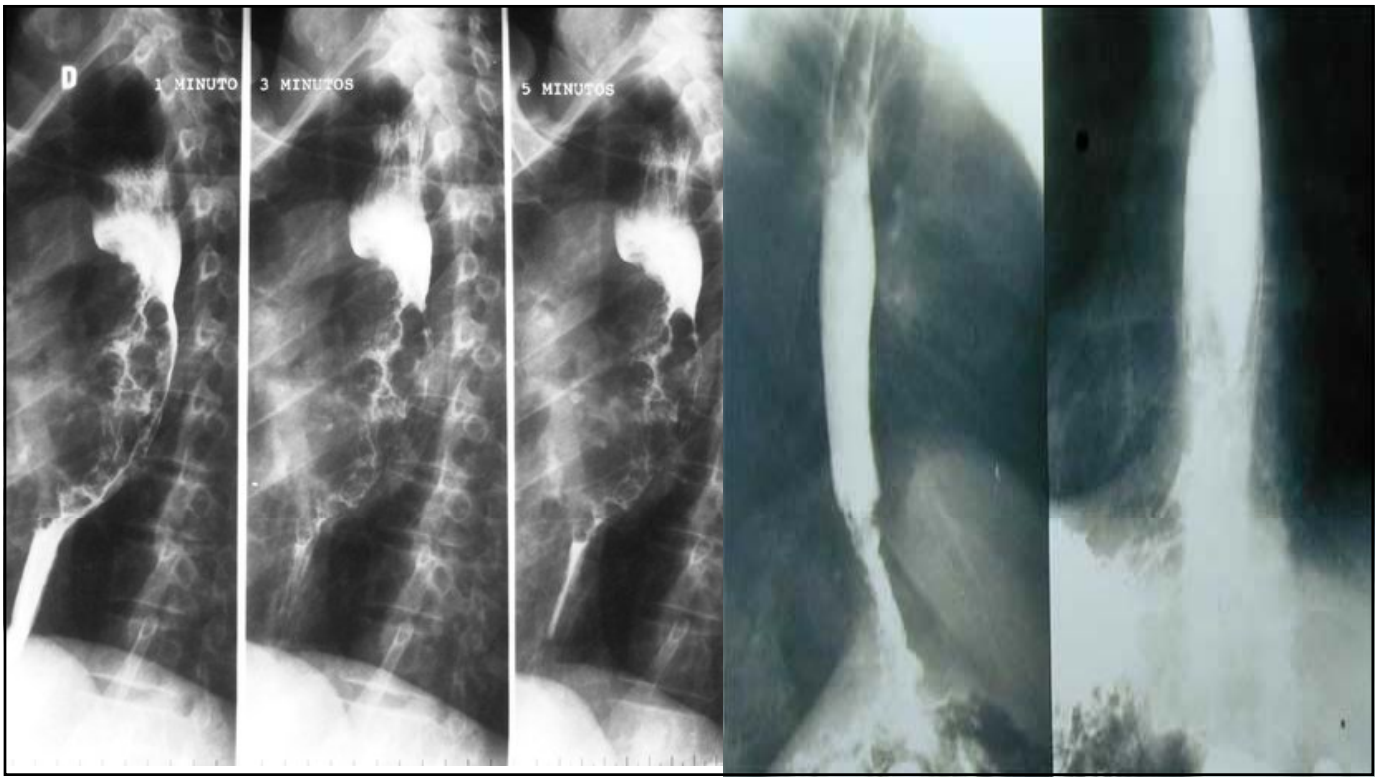
D
1 MINUTO
3 MINUTOS
5 MINUTOS

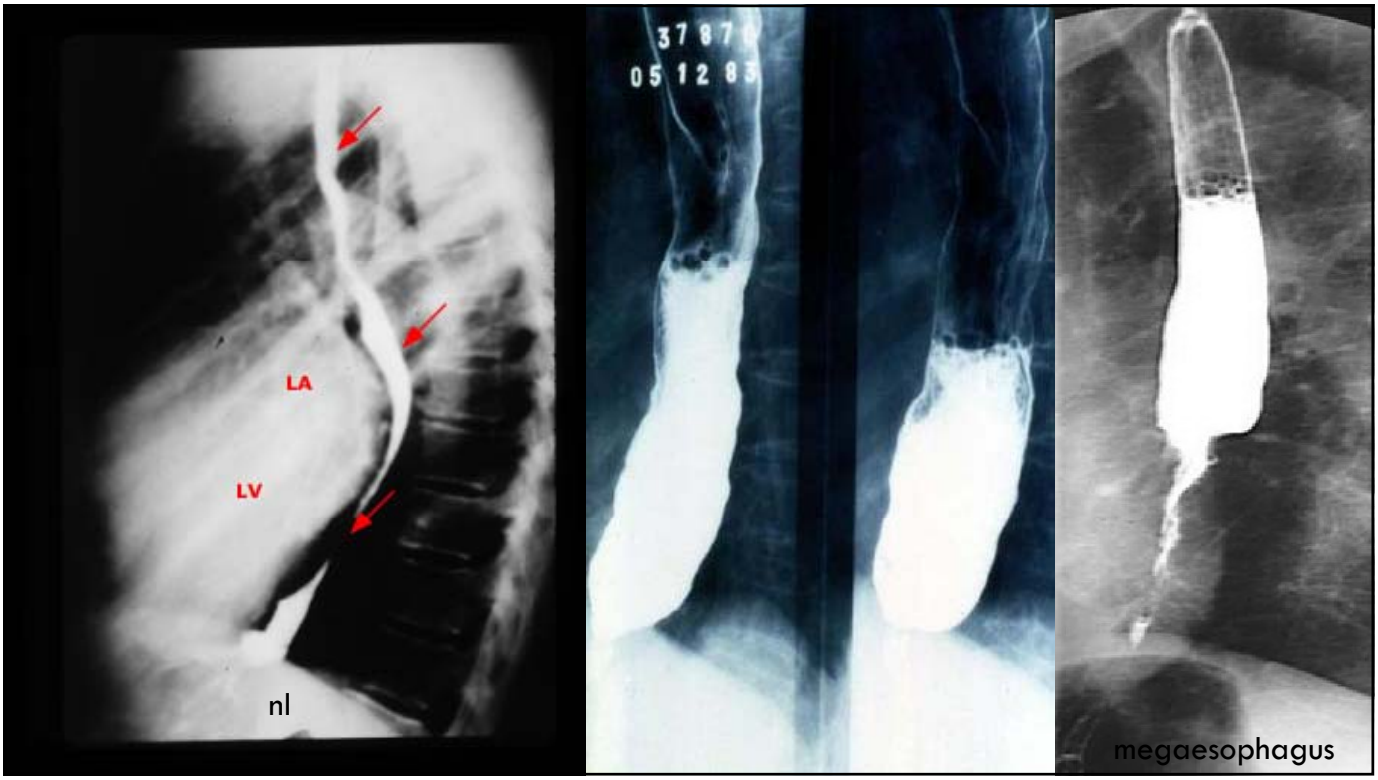
LA
LV
nl
05 12 83
megaesophagus

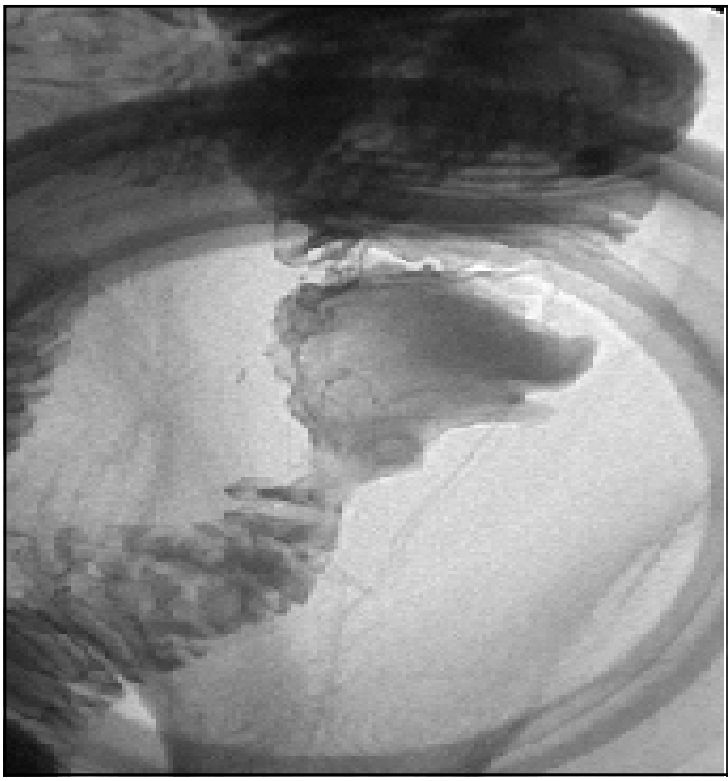

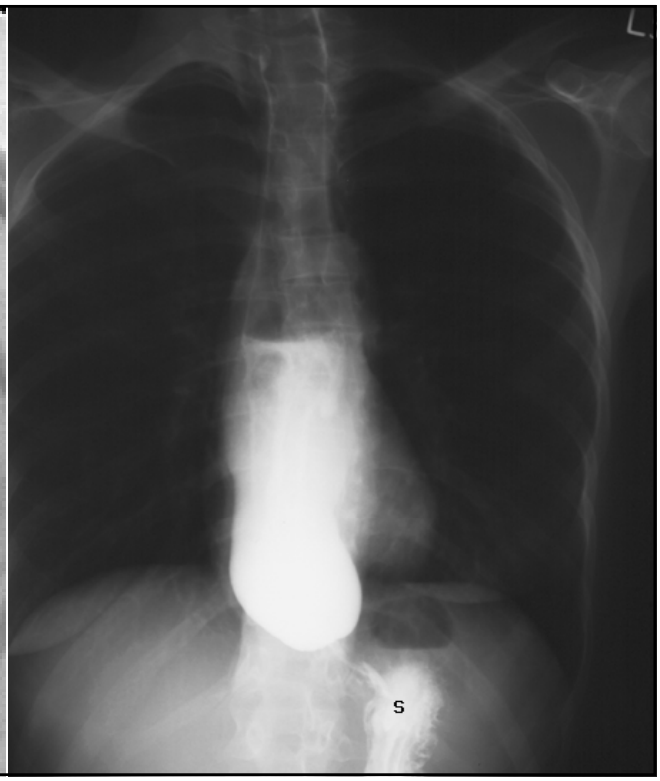

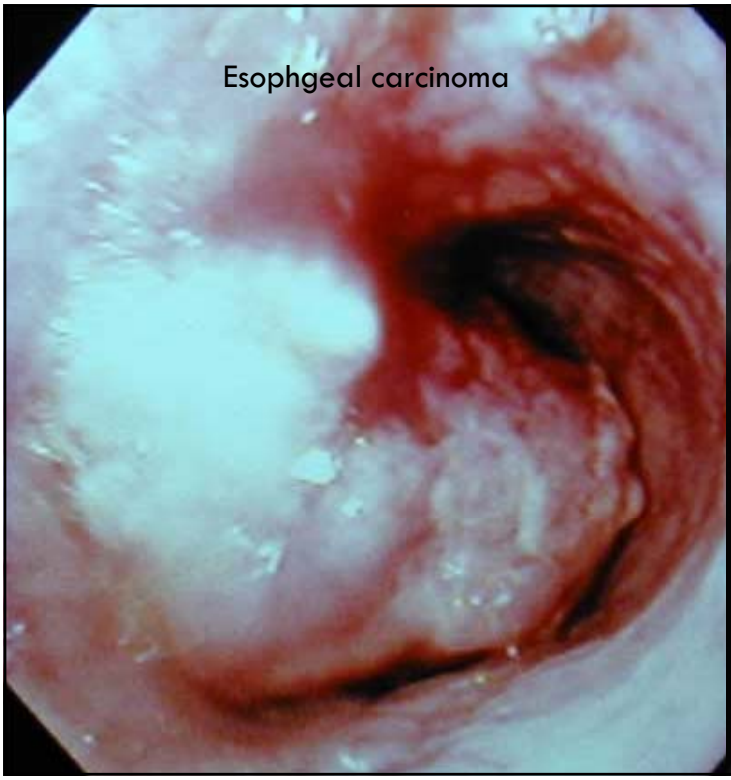
Esophgeal carcinoma

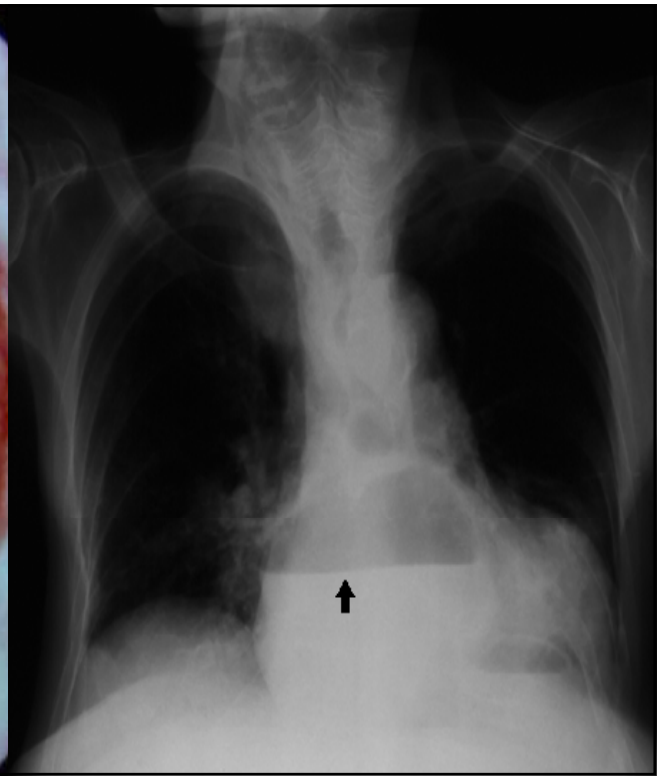

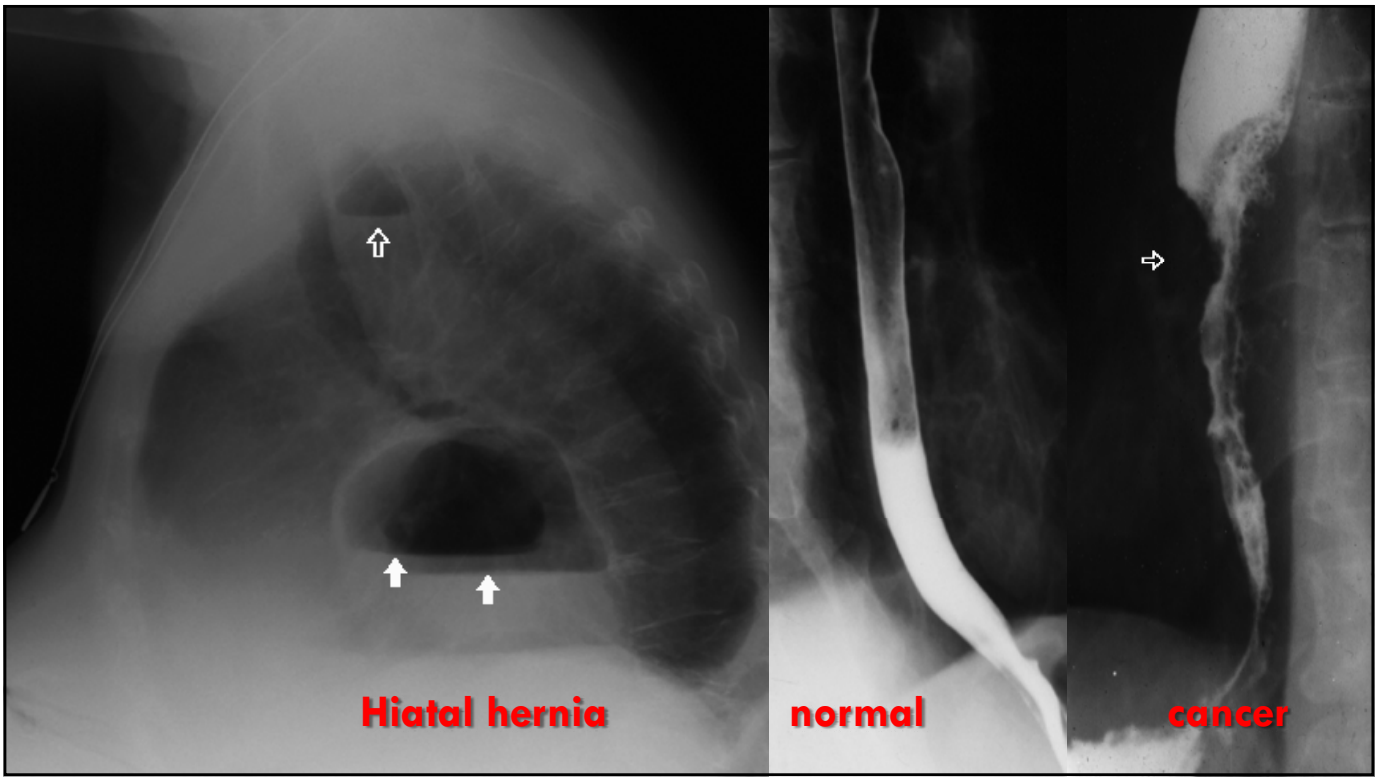
Hiatal hernia
normal
cancer

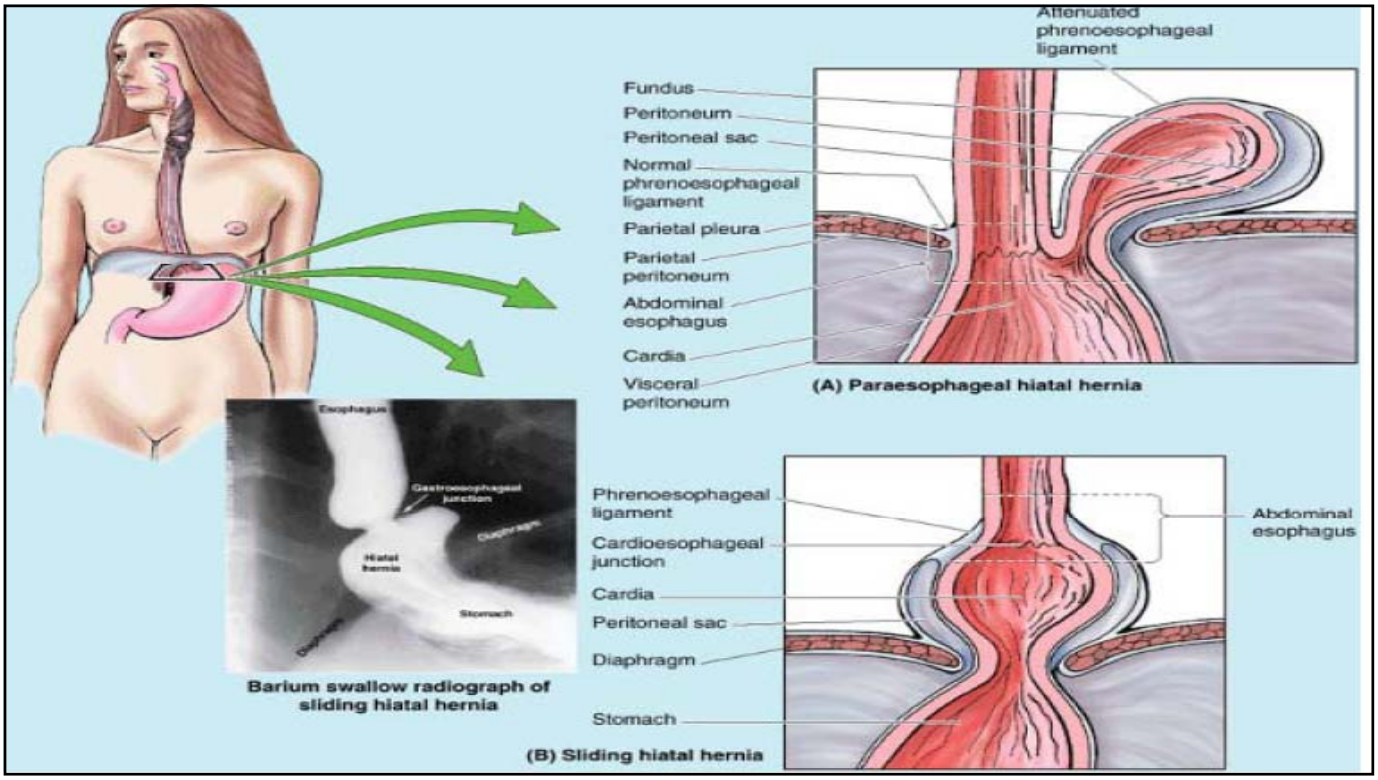
Attenuated phrenoesophageal ligament
Fundus
Peritoneum
Peritoneal sac
Normal phrenoesophageal ligament
Parietal pleura
Parietal peritoneum
Abdominal esophagus
Cardia
Visceral peritoneum
(A) Paraesophageal hiatal hernia
Esophagus
Gastroesophageal junction
Diaphragm
Hiatal hernia
Stomach
Barium swallow radiograph of sliding hiatal hernia
Phrenoesophageal ligament
Cardioesophageal junction
Cardia
Peritoneal sac
Diaphragm
Stomach
Abdominal esophagus
(B) Sliding hiatal hernia

Abdominal cavity

Peritoneum and Peritoneal Cavity

- **Peritoneum** – serous membrane of the abdominal cavity
  - Visceral – covers external surface of most digestive organs
  - Parietal – lines the body wall
  - Is a **serous membrane lined by mesothelial cells.**

- **Peritoneal cavity**
  - **Lubricates digestive organs**
  - **Allows them to slide across one another**

Is a **potential space between the parietal and visceral peritoneum.**

Contains a film of fluid that lubricates the surface of the peritoneum and facilitates free movements of the viscera.

Is a completely closed sac in the male but is open in the female through the uterine tubes, uterus, and vagina.

Is divided into the lesser and greater sacs.

- **A. Parietal peritoneum**
- Lines the abdominal and pelvic walls and the inferior surface of the diaphragm.
- Is innervated by the :
  - somatic nerves such as the phrenic,
  - lower intercostal, subcostal, iliohypogastric, and ilioinguinal nerves.

- **B. Visceral peritoneum**
  - Covers the viscera, is innervated by visceral nerves, and is insensitive to pain.

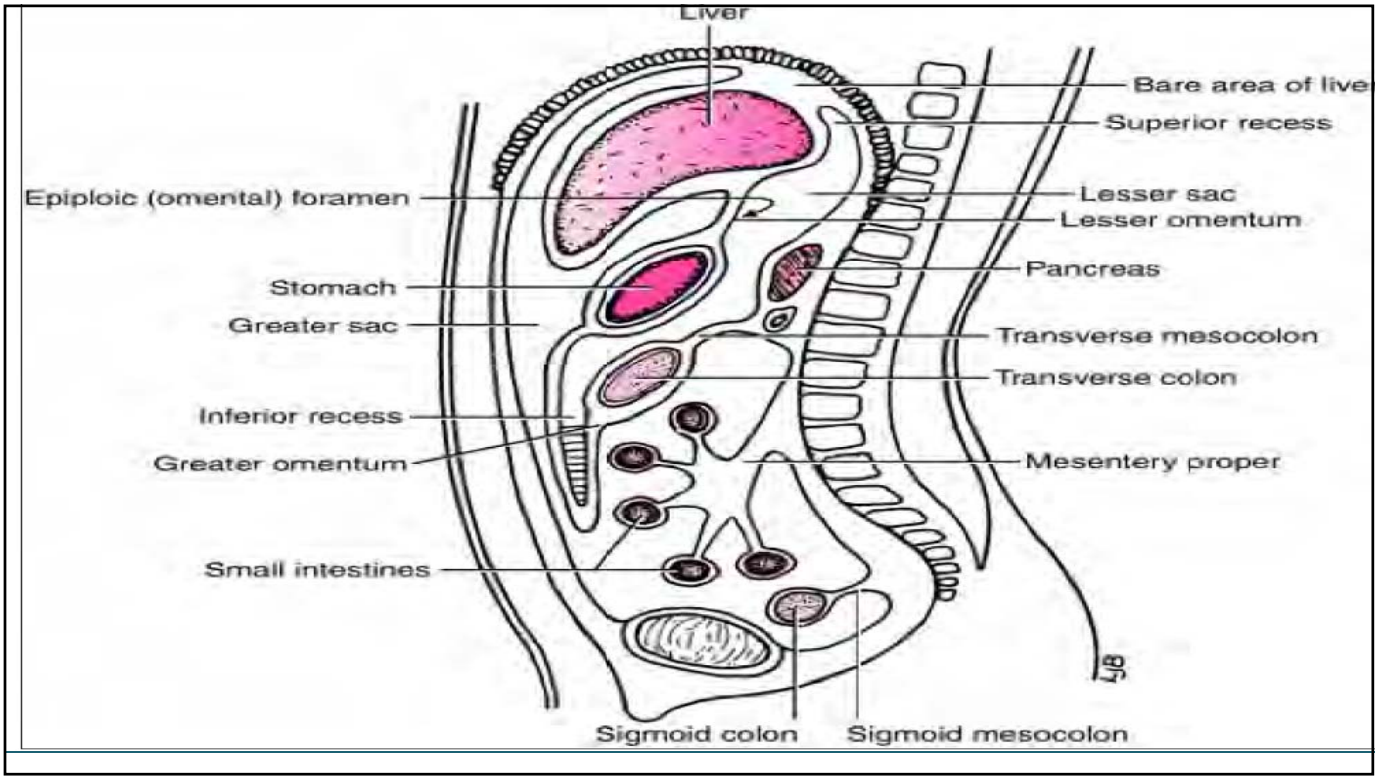

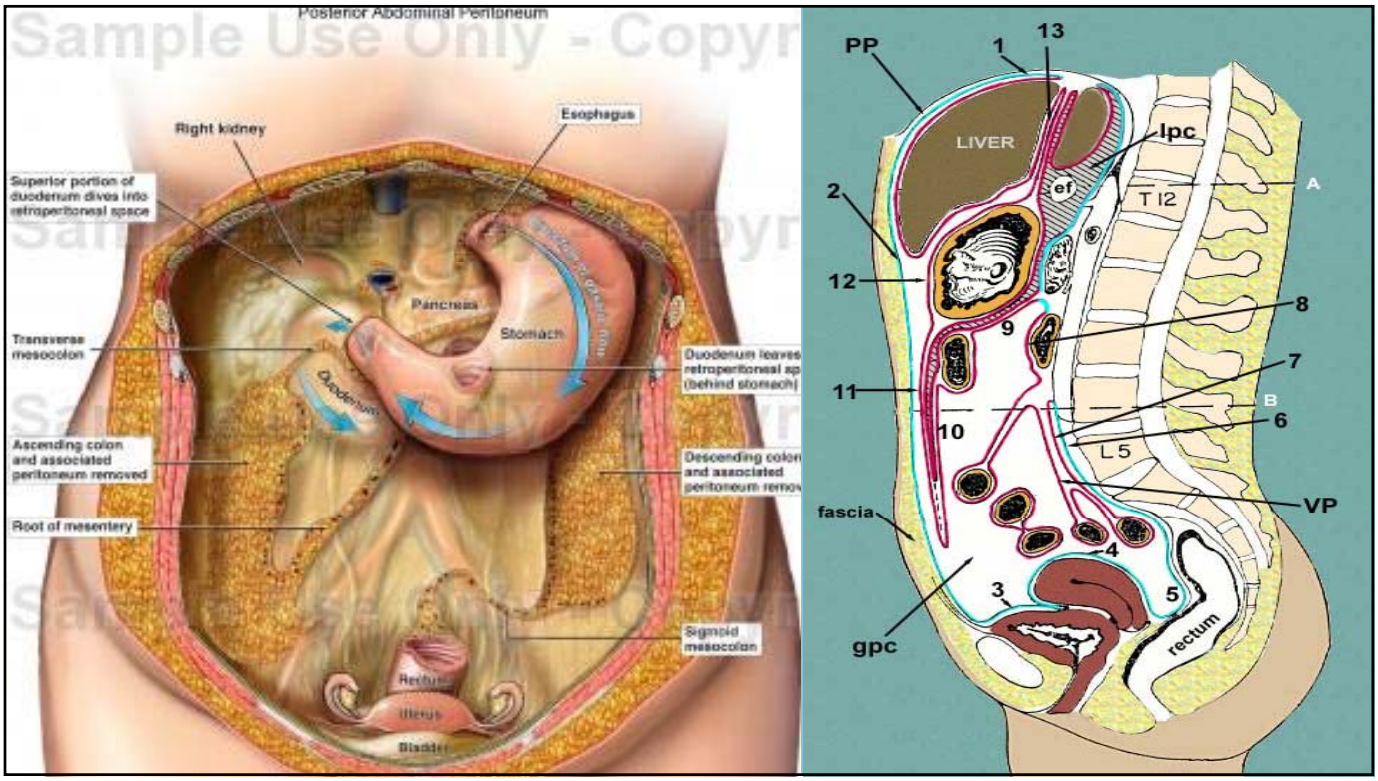
Posterior Abdominal Peritoneum
Right kidney
Esophagus
Superior portion of duodenum dives into retroperitoneal space
Pancreas
Stomach
Transverse mesocolon
Duodenum
Ascending colon and associated peritoneum removed
Root of mesentery
Sigmoid mesocolon
Rectum
Uterus
Bladder
PP
1
13
LIVER
lpc
ef
T 12
A
2
12
8
9
7
11
B
6
10
L 5
VP
fascia
4
3
5
gpc
rectum

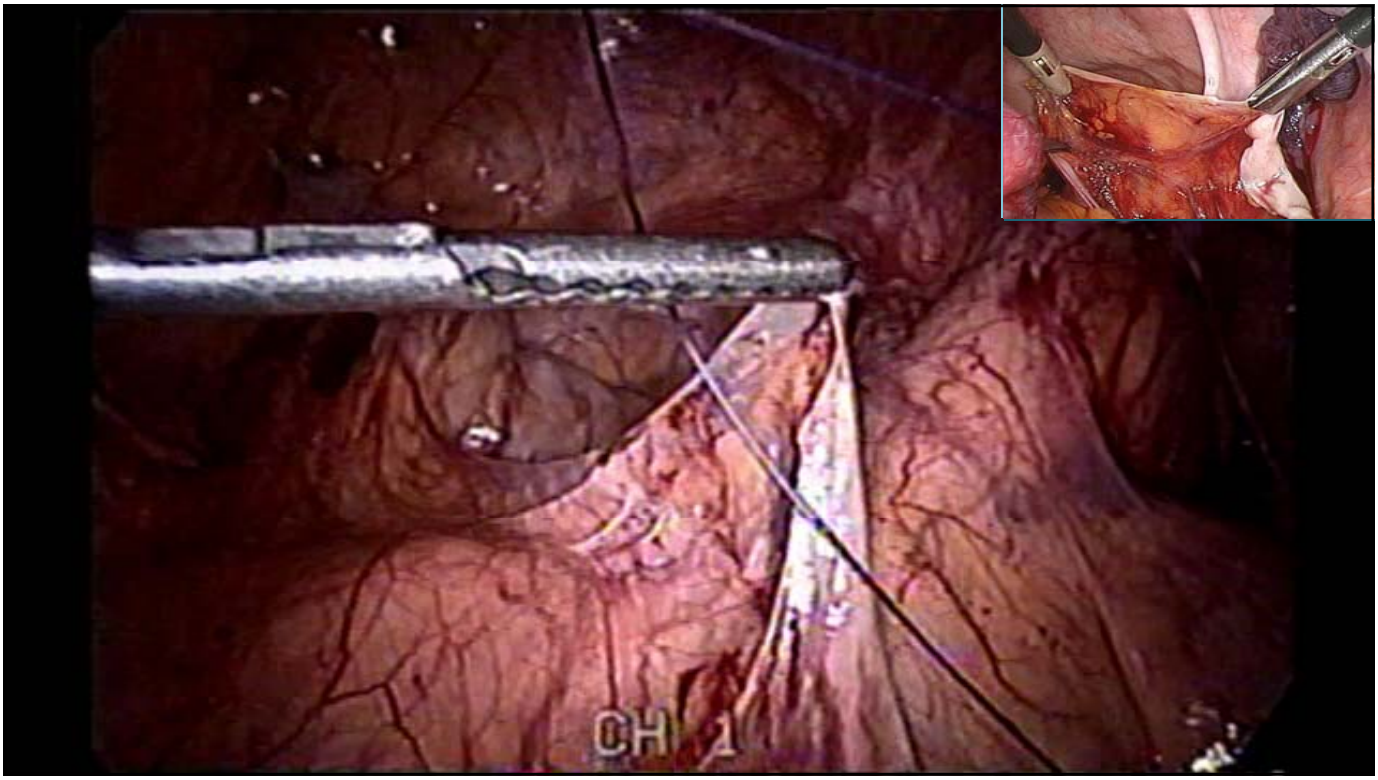
CH 1

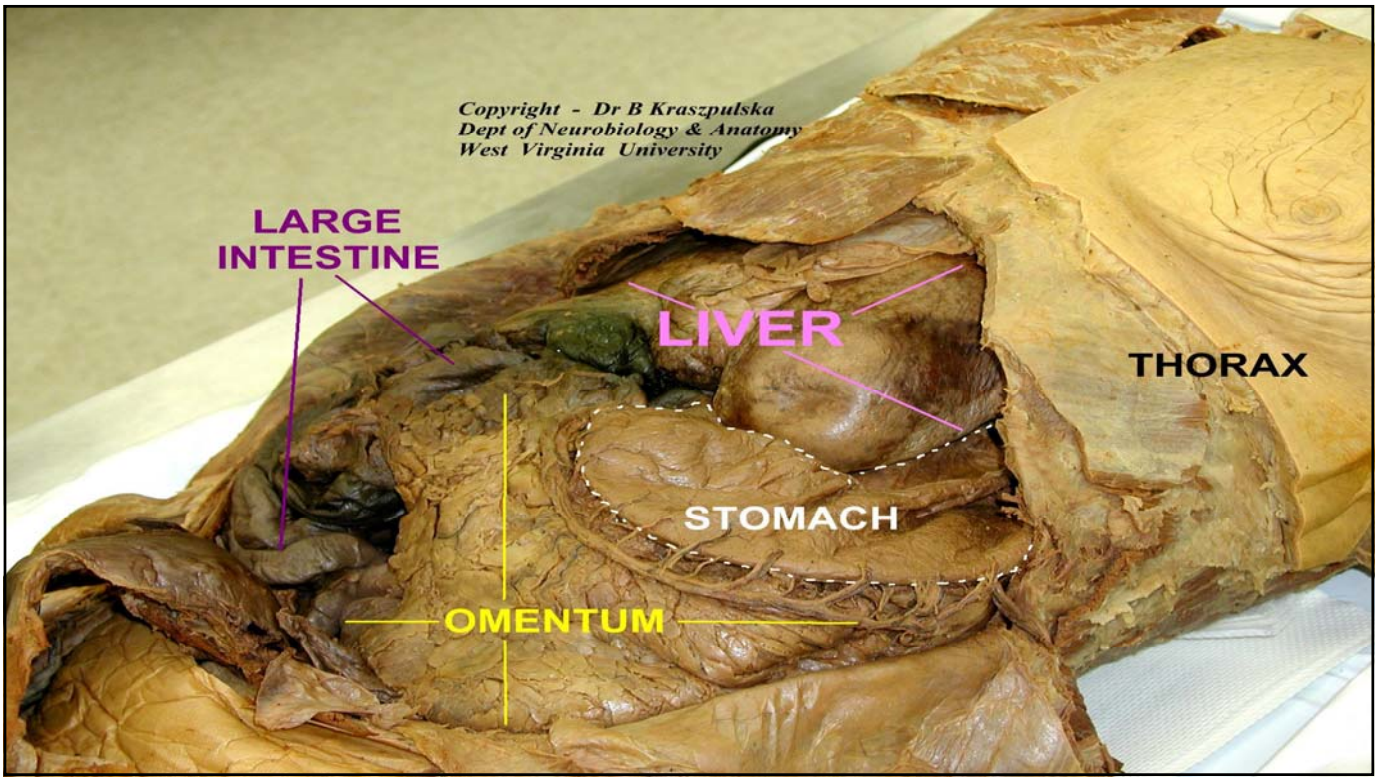
Copyright - Dr B Kraszpulska
Dept of Neurobiology & Anatomy
West Virginia University
LARGE INTESTINE
LIVER
THORAX
STOMACH
OMENTUM

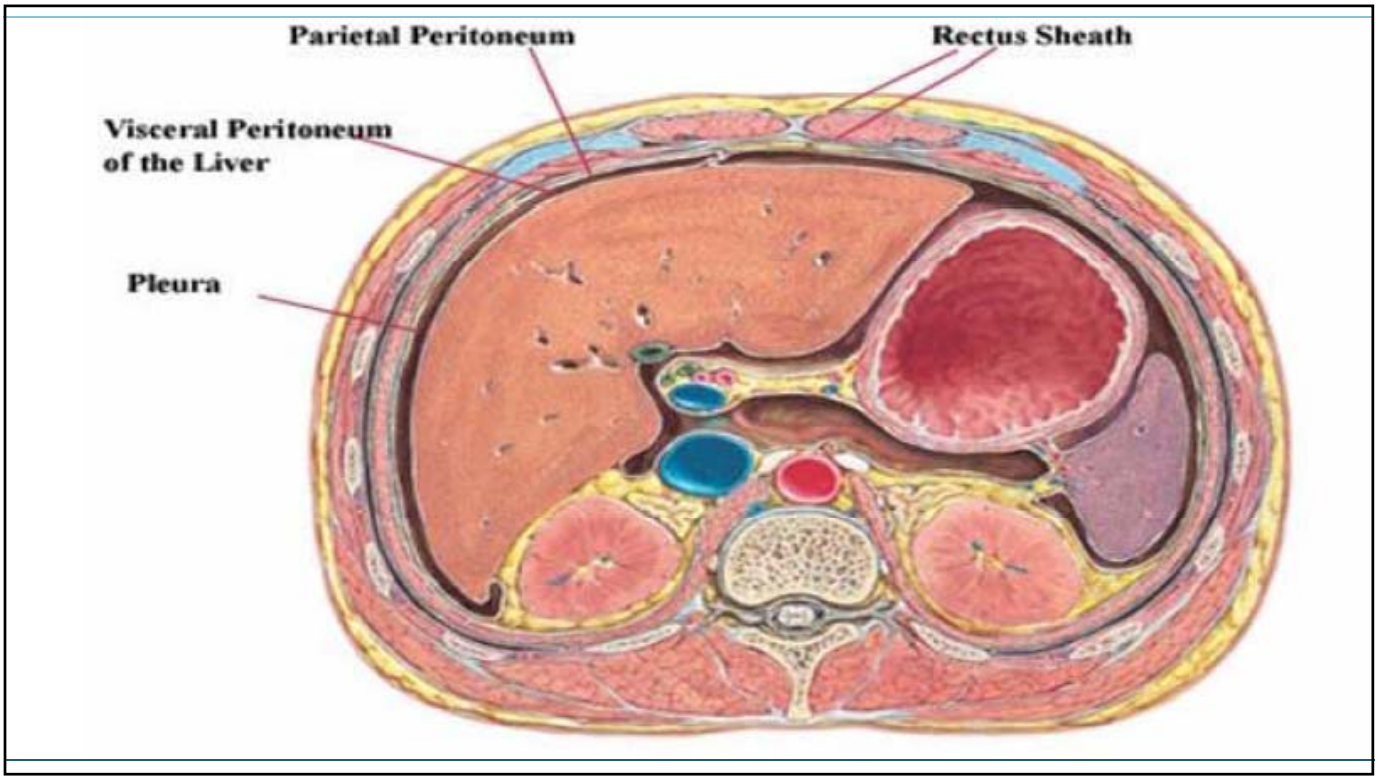
Parietal Peritoneum
Rectus Sheath
Visceral Peritoneum of the Liver
Pleura

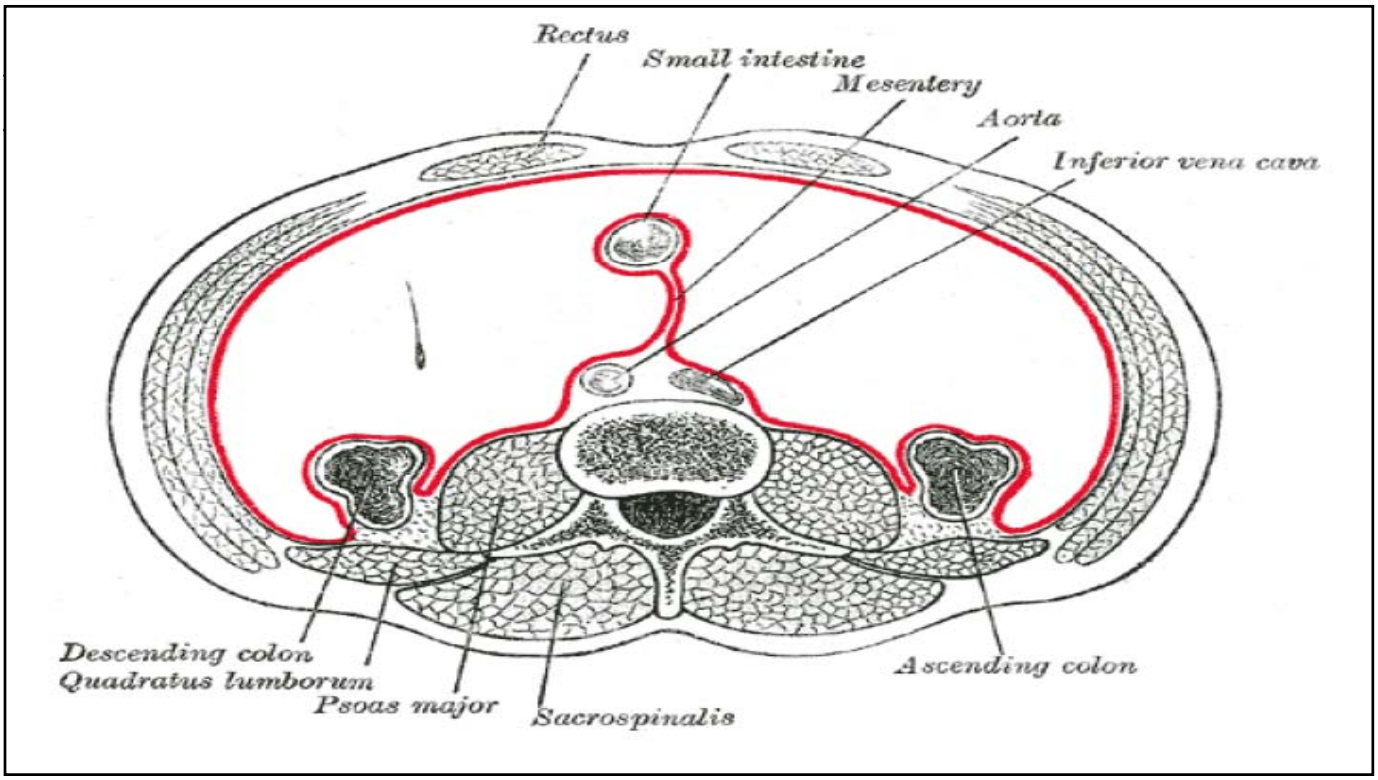
Rectus
Small intestine
Mesentery
Aorta
Inferior vena cava
Descending colon
Quadratus lumborum
Psoas major
Sacrospinalis
Ascending colon

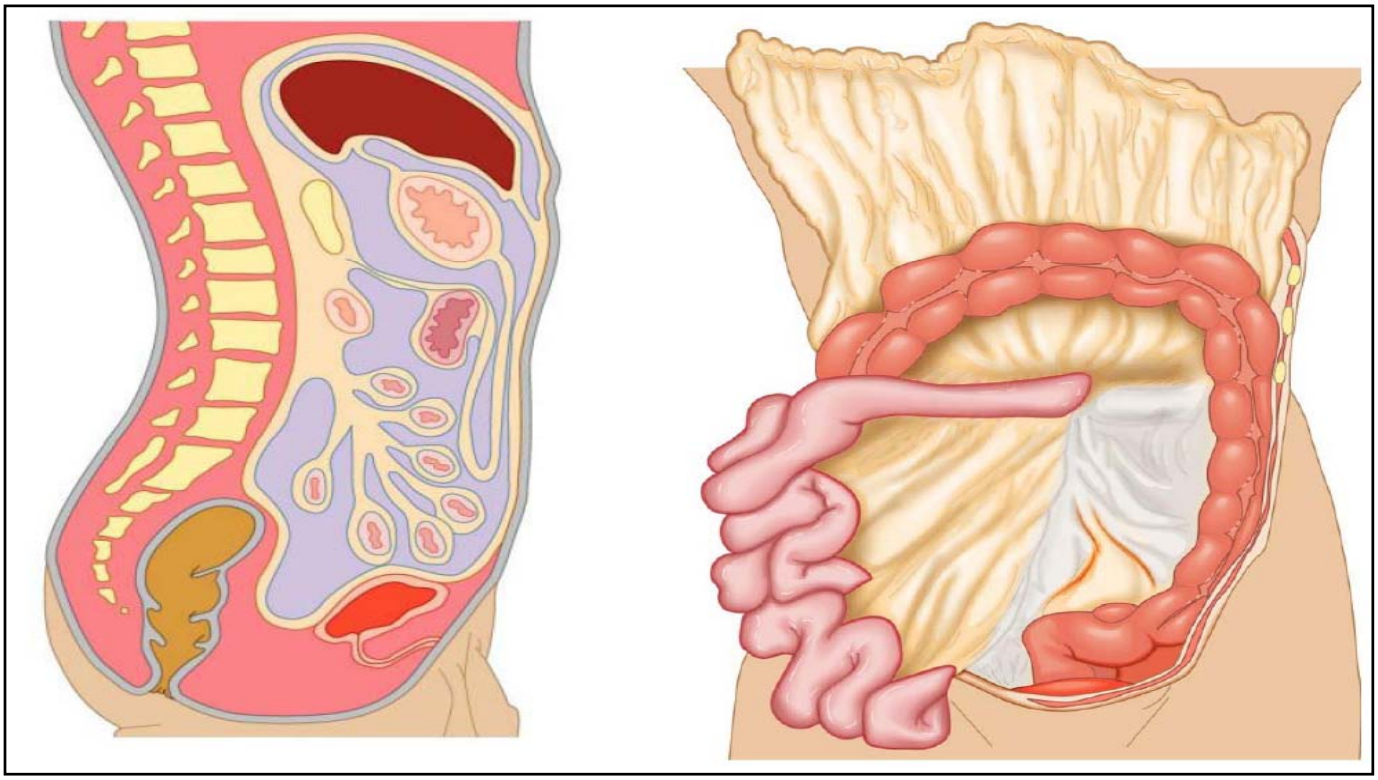

Peritoneum and Peritoneal Cavity

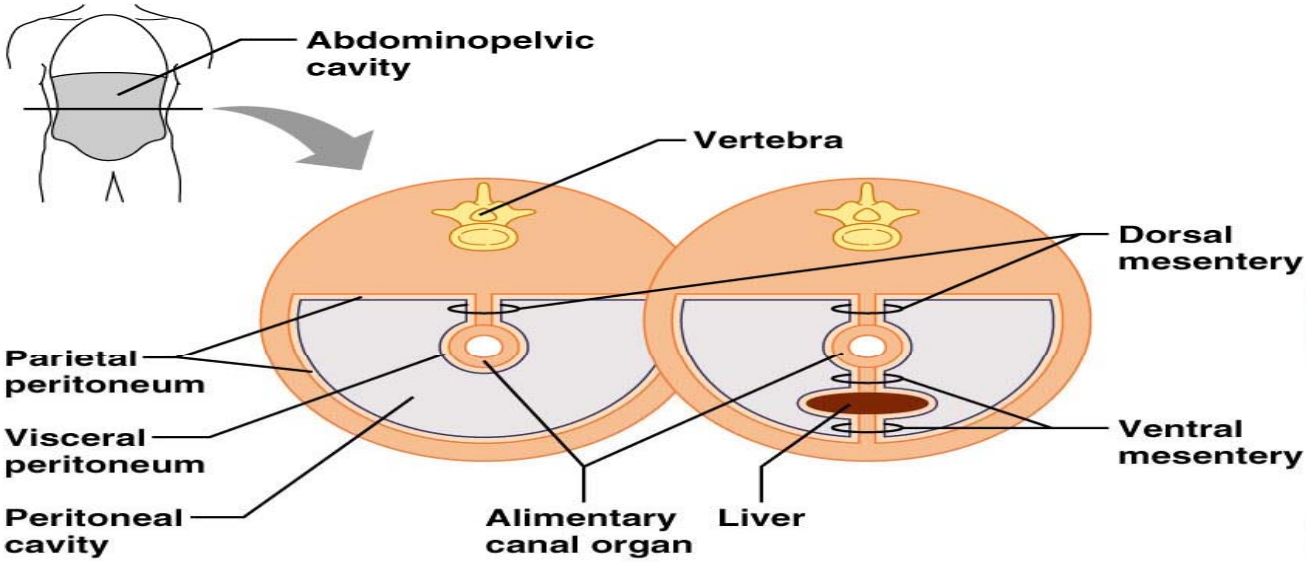

(a) Transverse section of abdominal cavity

Peritoneum and Peritoneal Cavity

- **Mesentery** – double layer of peritoneum that provides:
  - Vascular and nerve supplies to the viscera
  - Hold digestive organs in place and store fat
- **Retroperitoneal organs** – organs outside the peritoneum
- **Peritoneal organs (intraperitoneal)** – organs surrounded by peritoneum

Retroperitoneal organs

- Structures that lie behind the peritoneum are termed "retroperitoneal". These include:
- **Primarily retroperitoneal:**
  - urinary
    - adrenal glands
    - kidneys
    - ureter
    - bladder
  - circulatory
    - aorta
    - inferior vena cava
  - digestive
    - esophagus (part)
    - rectum
  - Reproductive
    - uterus

Secondarily retroperitoneal:

- the head and neck of the pancreas (but not the tail)
- the duodenum, except for the proximal first segment
- ascending and descending portions of the colon (but not the transverse or sigmoid

A useful mnemonic to aid recollection of the abdominal retroperitoneal viscera is SAD PUCKER:

S = **S**uprarenal glands (aka the adrenal glands)
A = **A**orta/IVC
D = **D**uodenum (second and third segments)
P = **P**ancreas
U = **U**reters
C = **C**olon (only the ascending and descending branches)
K = **K**idneys
E = **E**sophagus
R = **R**ectum

- **Greater omentum-** a sheet of fat that hangs from the left inferior margin (greater curvature) of the stomach and drapes over the transverse colon and coils of the intestine like a apron.
  - It contains many lymph nodes that combat infection that may occur in the abdominal cavity.
- **Lesser omentum-** perioteal fold that suspends the stomach (at the lesser curvature) and the duodenum form the liver

Greater Omentum

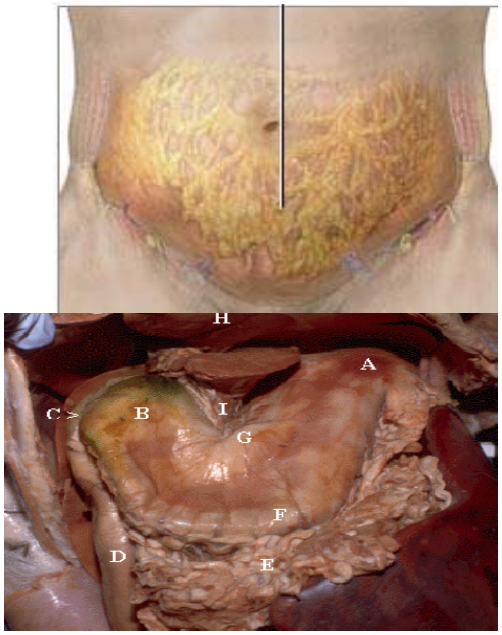

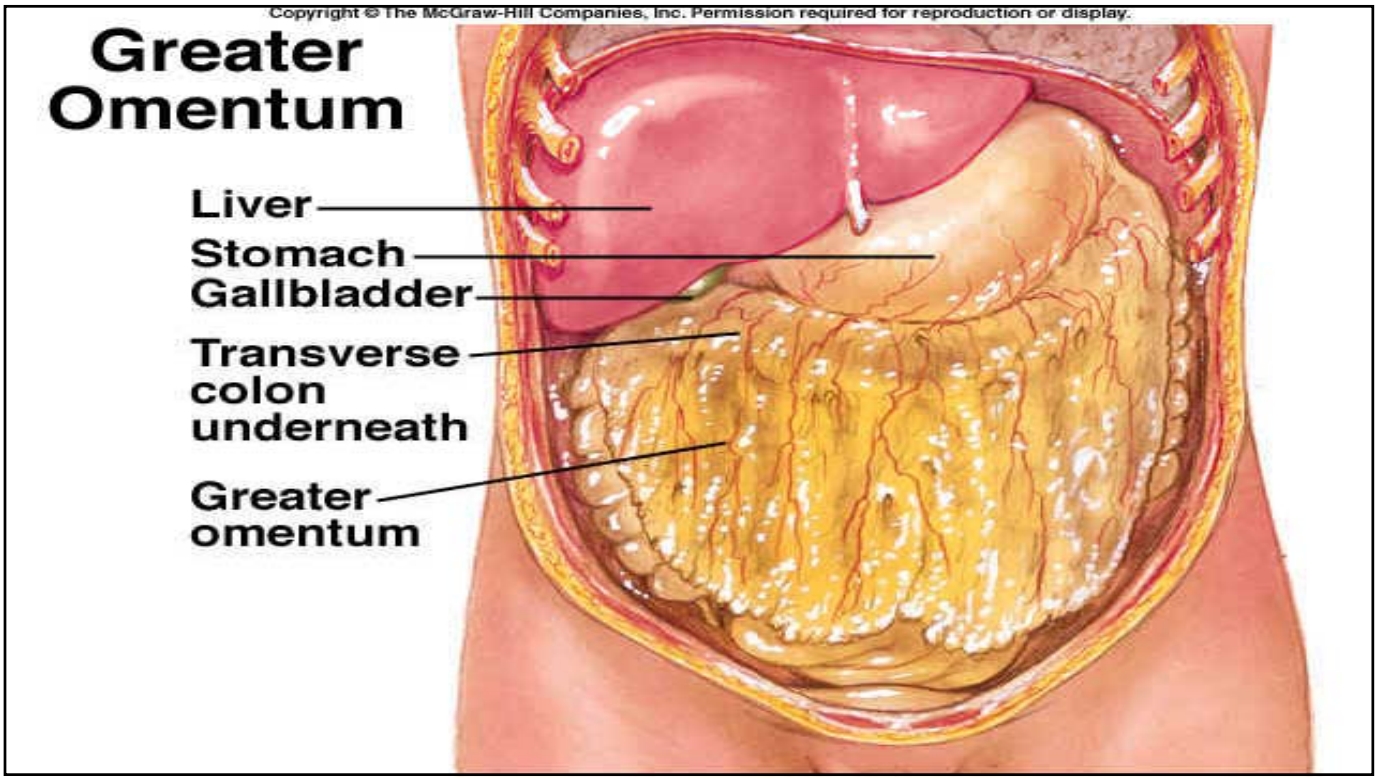
Copyright © The McGraw-Hill Companies, Inc. Permission required for reproduction or display.
Greater Omentum
Liver
Stomach
Gallbladder
Transverse colon underneath
Greater omentum

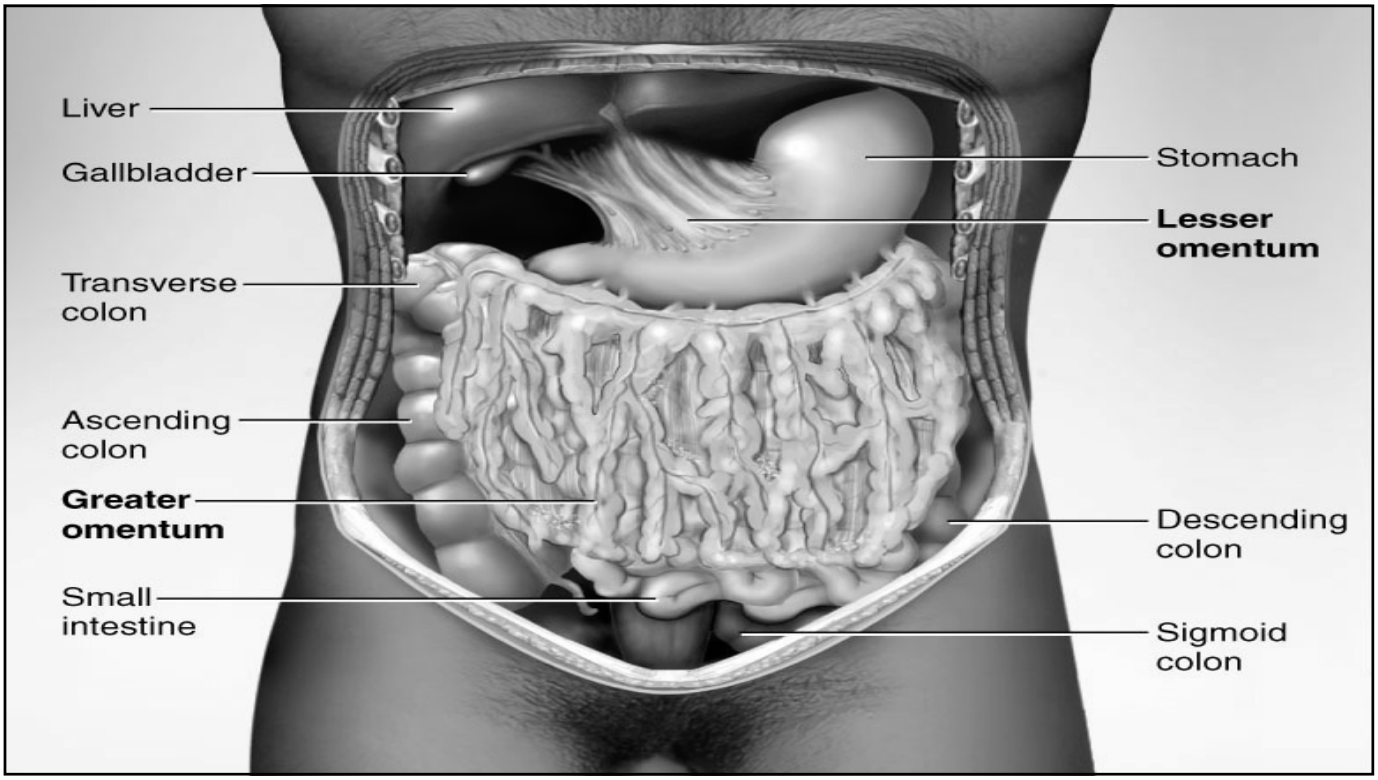
Liver
Gallbladder
Transverse colon
Ascending colon
Greater omentum
Small intestine
Stomach
Lesser omentum
Descending colon
Sigmoid colon

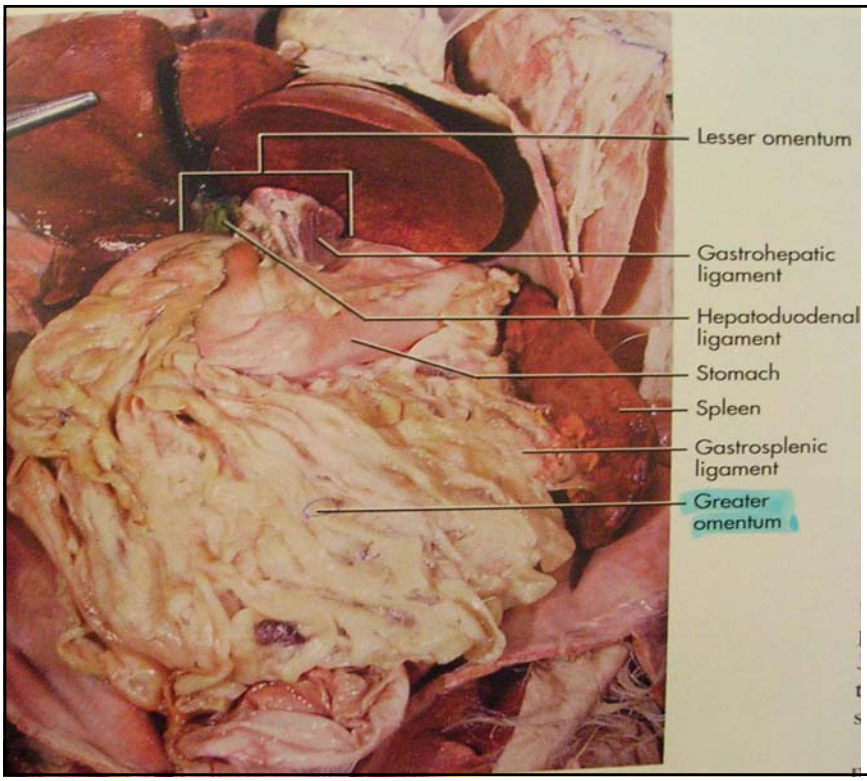

Lesser - attaches stomach to liver

- **Greater** - covers small intestines like an apron

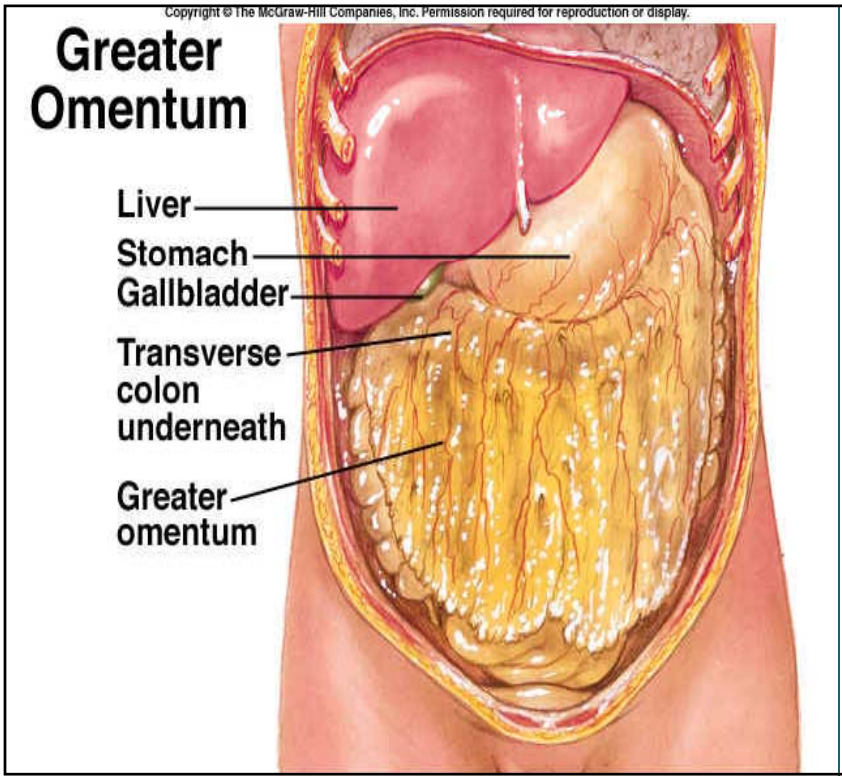

The **greater omentum** (also the **great omentum, omentum majus , gastrocolic omentum, epiploön,** or, especially in animals, **caul**) is a large fold of peritoneum that hangs down from the stomach, and extends from the stomach to the posterior abdominal wall after associating with the transverse colon.

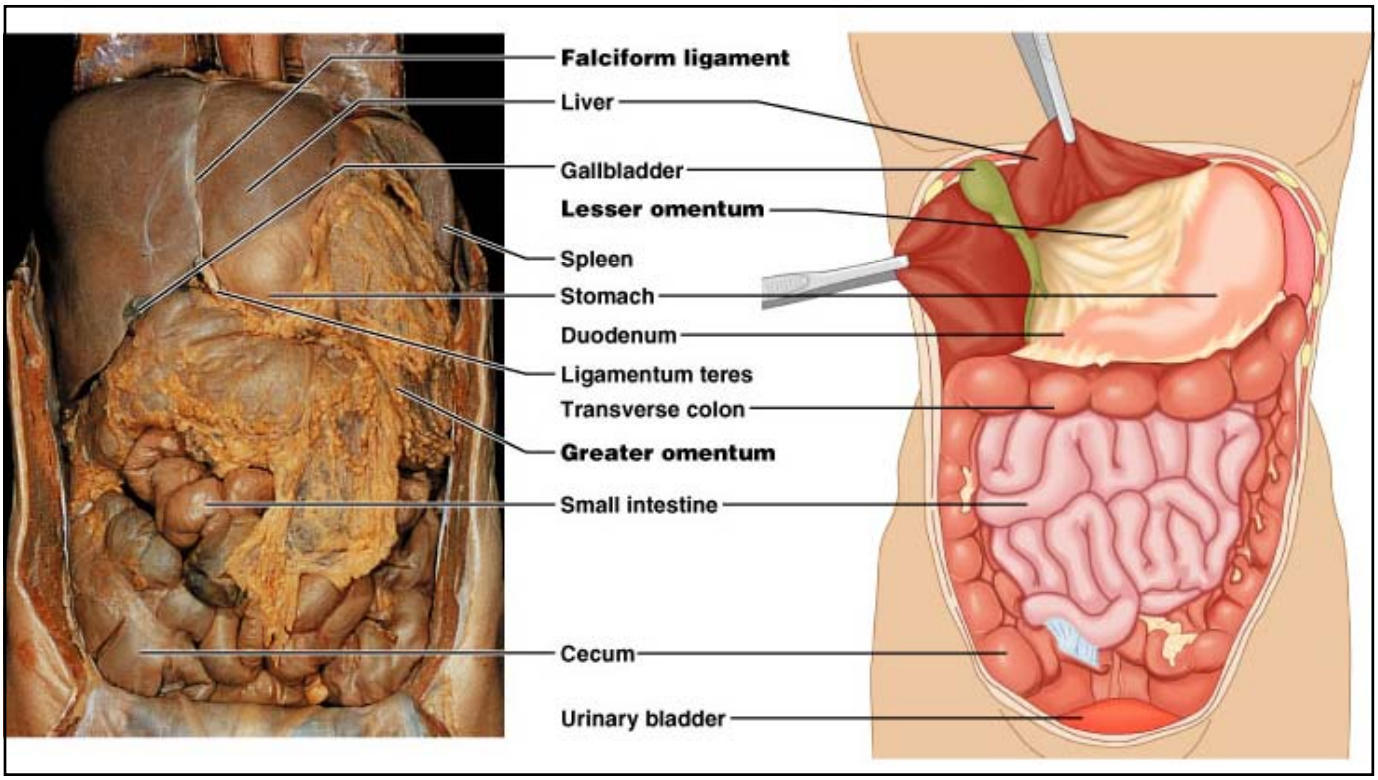
Falciform ligament
Liver
Gallbladder
Lesser omentum
Spleen
Stomach
Duodenum
Ligamentum teres
Transverse colon
Greater omentum
Small intestine
Cecum
Urinary bladder

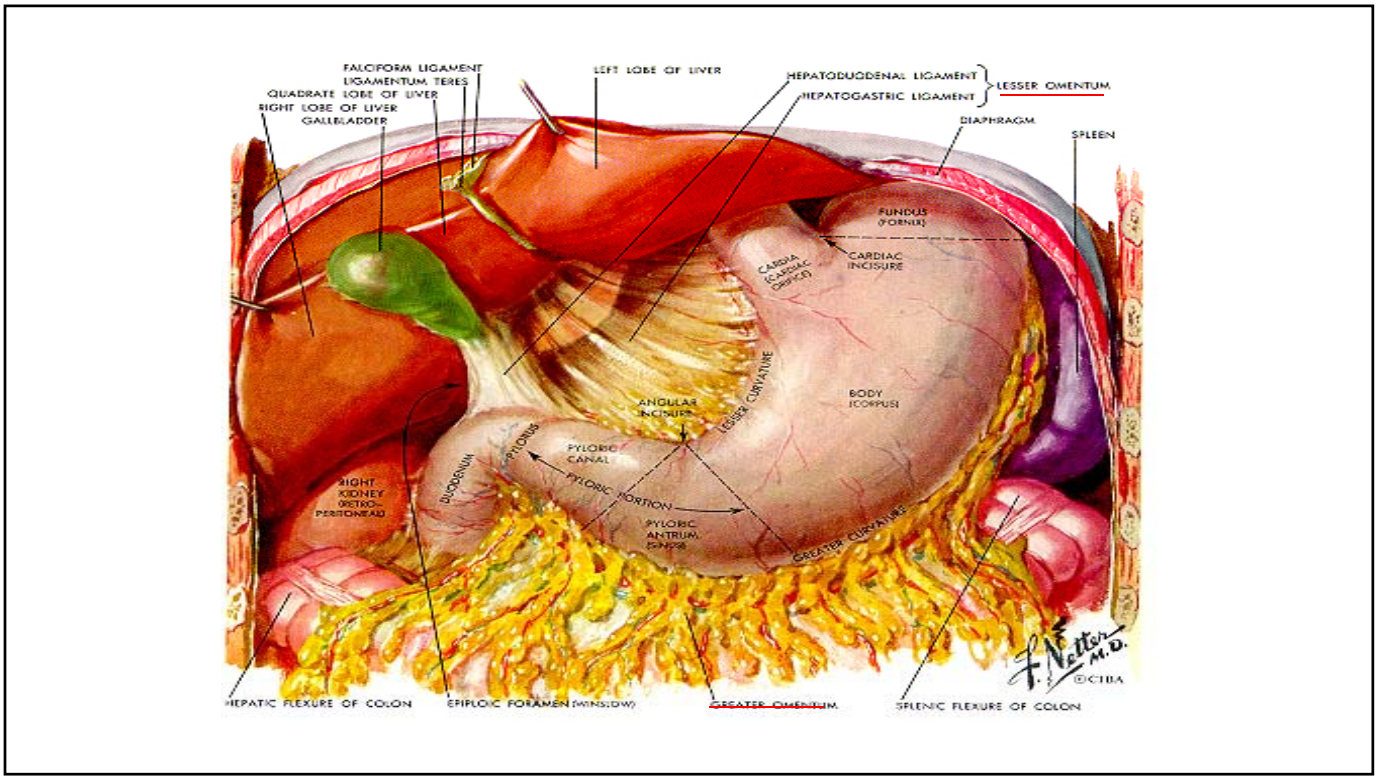
FALCIFORM LIGAMENT
LIGAMENTUM TERES
QUADRATE LOBE OF LIVER
RIGHT LOBE OF LIVER
GALLBLADDER
LEFT LOBE OF LIVER
HEPATODUODENAL LIGAMENT
HEPATOGASTRIC LIGAMENT
LESSER OMENTUM
DIAPHRAGM
SPLEEN
FUNDUS (FORNIX)
CARDIAC INCISURE
CARDIA (CARDIAC ORIFICE)
BODY (CORPUS)
LESSER CURVATURE
ANGULAR INCISURE
PYLORIC CANAL
PYLORIC PORTION
PYLORIC ANTRUM (SINUS)
PYLORUS
DUODENUM
RIGHT KIDNEY (RETRO-PERITONEAL)
GREATER CURVATURE
HEPATIC FLEXURE OF COLON
EPIPLOIC FORAMEN (WINSLOW)
GREATER OMENTUM
SPLENIC FLEXURE OF COLON
F. Netter M.D.
©CIBA

Blood Supply: Splanchnic Circulation

- Arteries and the organs they serve include
  - **The hepatic, splenic, and left gastric:** spleen, liver, and stomach
  - **Inferior and superior mesenteric:** small and large intestines

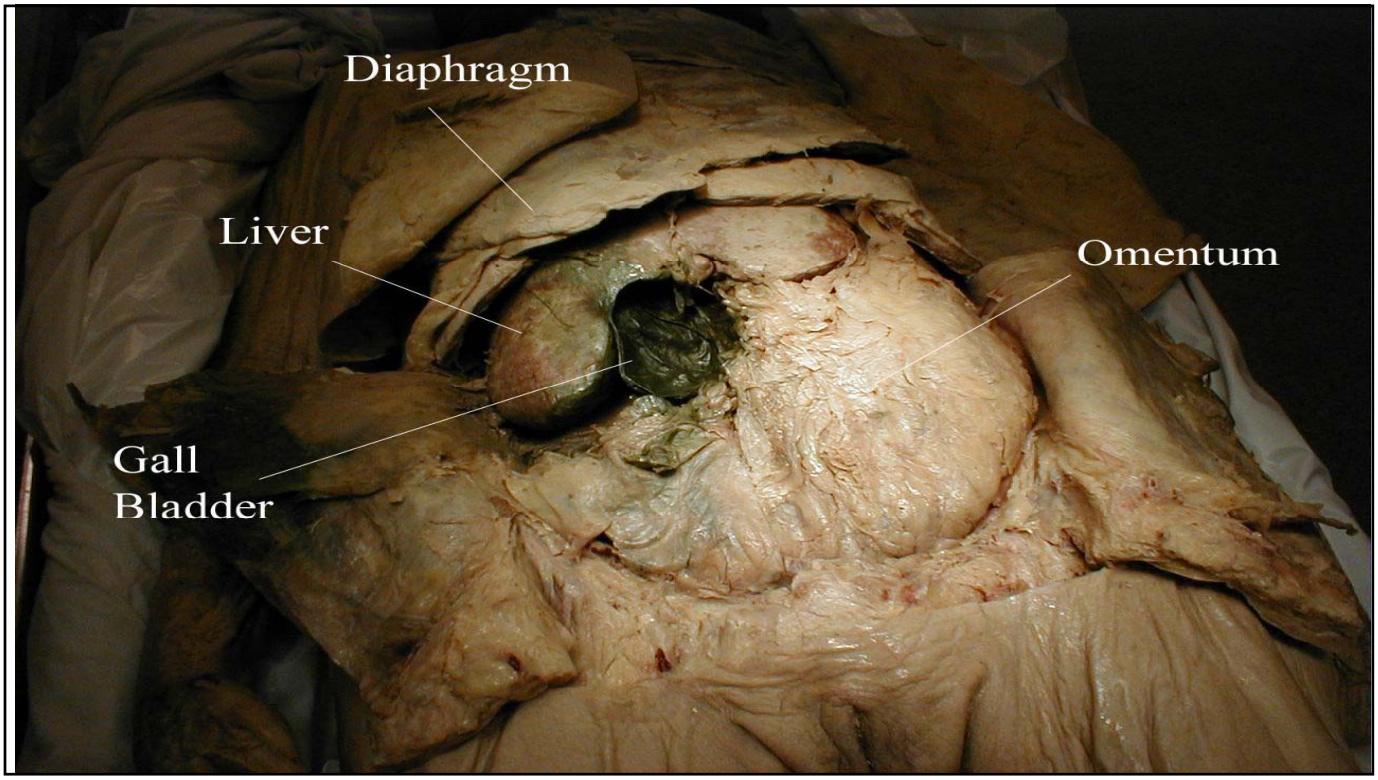

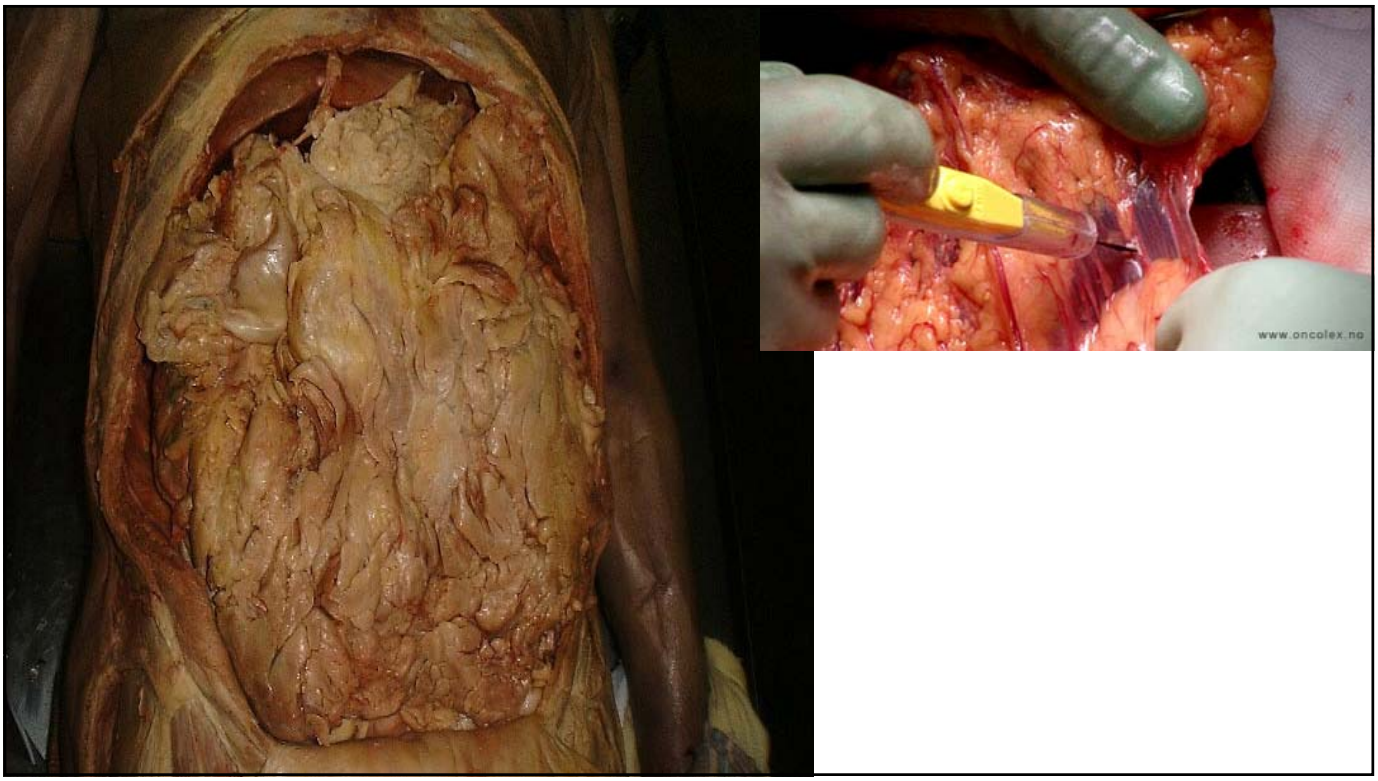
www.oncolex.no

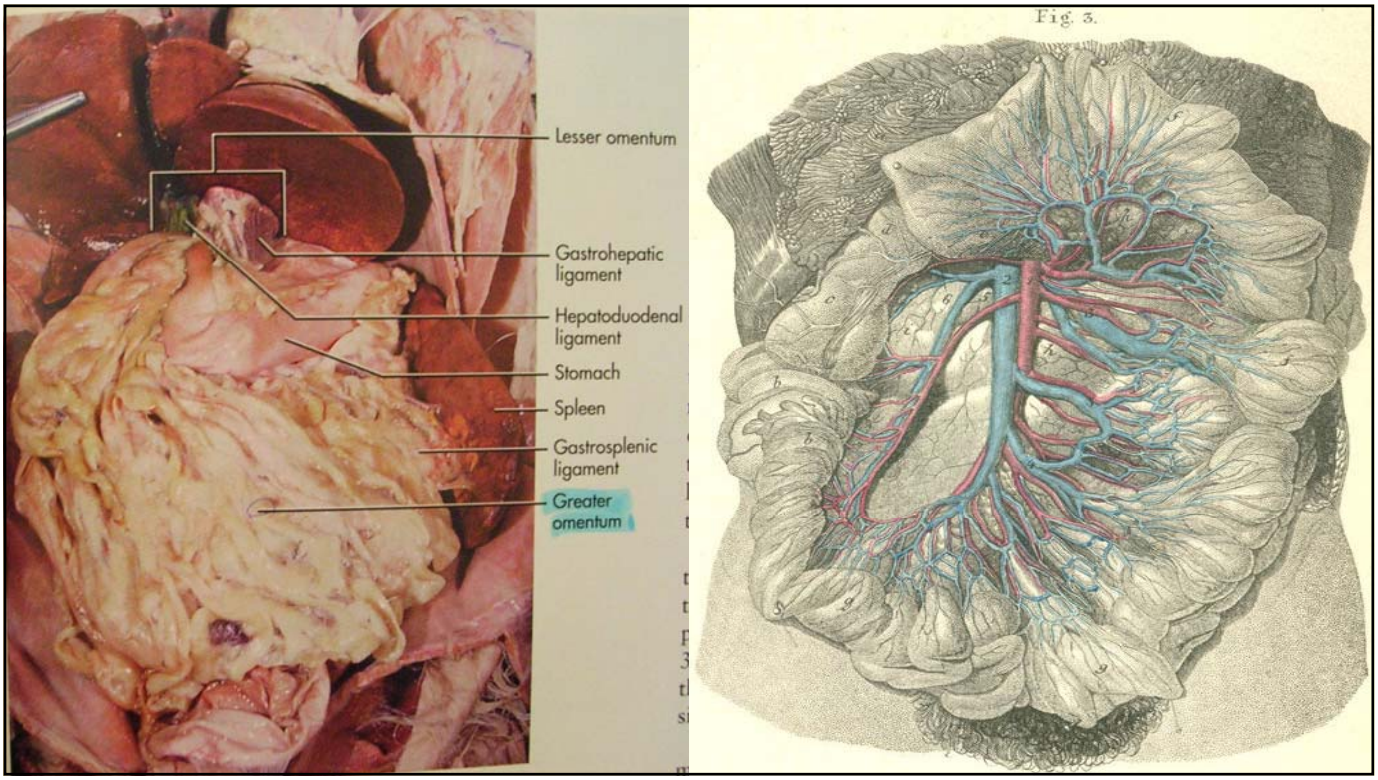
Lesser omentum
Gastrohepatic ligament
Hepatoduodenal ligament
Stomach
Spleen
Gastrosplenic ligament
Greater omentum
Fig. 3.

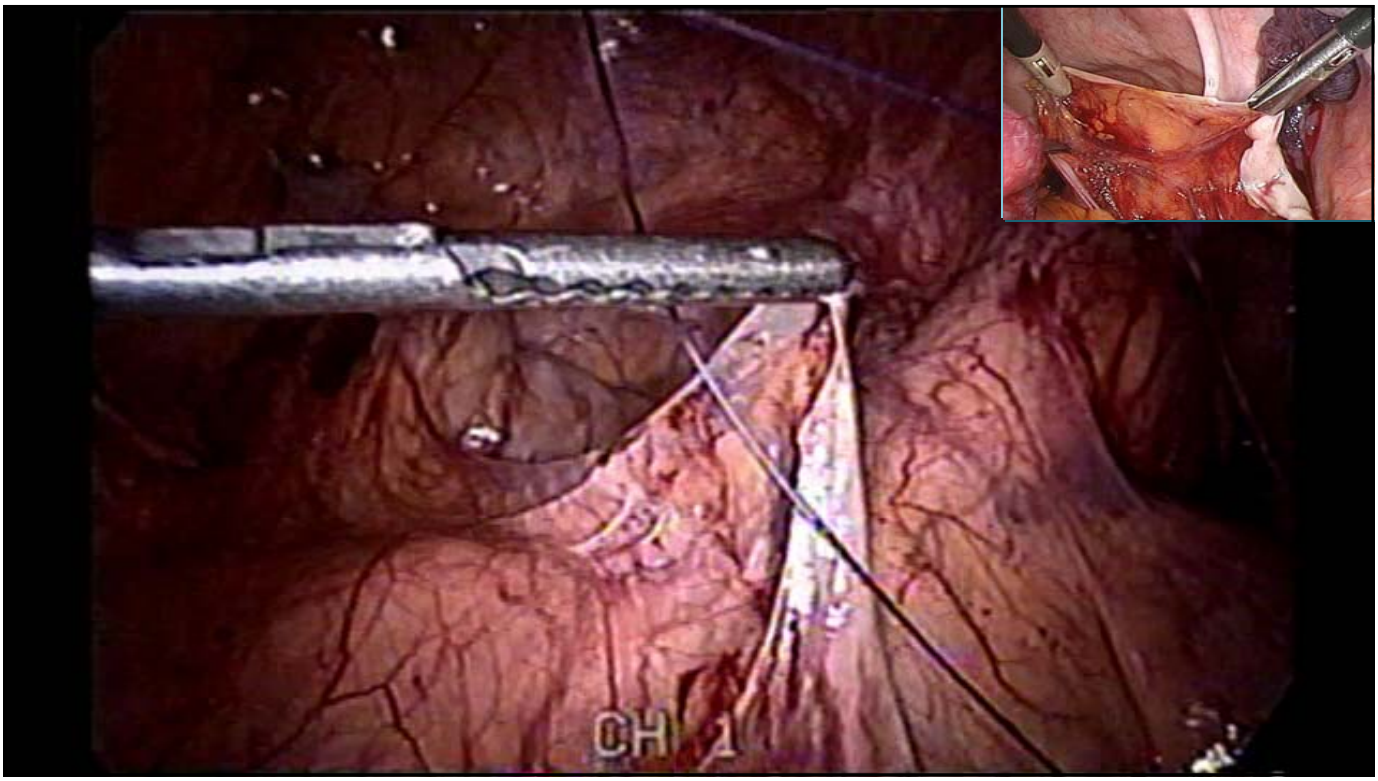

Subdivisions

The greater omentum is often defined to encompass a variety of structures.
Most sources include the following three:

- **Gastrocolic ligament - to transverse colon**
- **Gastrosplenic ligament - to spleen**
- **Gastrophrenic ligament - to thoracic diaphragm**
- **The splenorenal ligament (from the left kidney to the spleen) is occasionally considered part of the greater omentum**

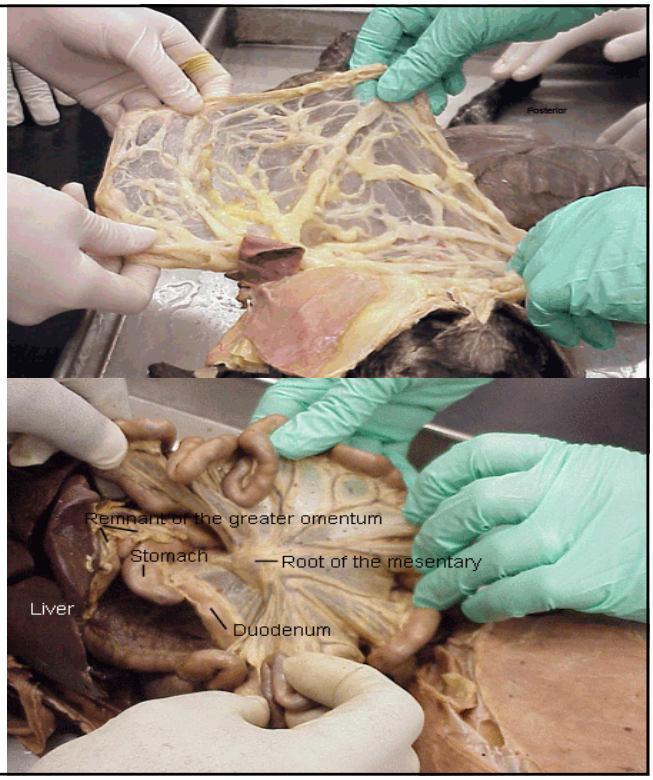

Stomach anatomy

STOMACH

cardiac orifice entrance and pyloric sphincter exit

lesser curvature (lesser omentum),
greater curvature (omentum),
body,
fundus,
pyloric
region, rugae.

gastric pits lined with: mucous neck cells mucus
880 chief cells pepsinogen
parietal cells HCl

distention of stomach causes release of **gastrin**
Gastrin stimulates release of gastric fluids from gastric pits
Peptic ulcers due 80% to *Helicobacter pylori*.

The **cardia is the part surrounding the cardial orifice, the trumpet-shaped opening of the esophagus into the stomach.**

☐ The **fundus is the dilated superior part of the stomach that is related to the left dome of the diaphragm and is limited** inferiorly by the horizontal plane of the cardial orifice. The superior part of the fundus usually reaches the level of the left 5th intercostal space.
The **cardial notch is between the esophagus and the fundus. The fundus may be dilated by gas, fluid,** food, or any combination of these.

☐ The **body, the major part of the stomach, lies between the fundus and the pyloric antrum.**

☐ The **pyloric part of the stomach is the funnel-shaped region; its wide part, the pyloric antrum, leads into the pyloric canal, its narrow part. The pylorus, the distal sphincteric region, is a thickening of the circular layer of smooth muscle,** which controls discharge of the stomach contents through the **pyloric orifice into the duodenum.**

☐ The **lesser curvature forms the shorter concave border of the stomach; the angular incisure (notch) is the sharp** indentation approximately two thirds of the distance along the lesser curvature that approximates the junction of the body and pyloric part of the stomach.

☐ The **greater curvature forms the longer convex border of the stomach.**

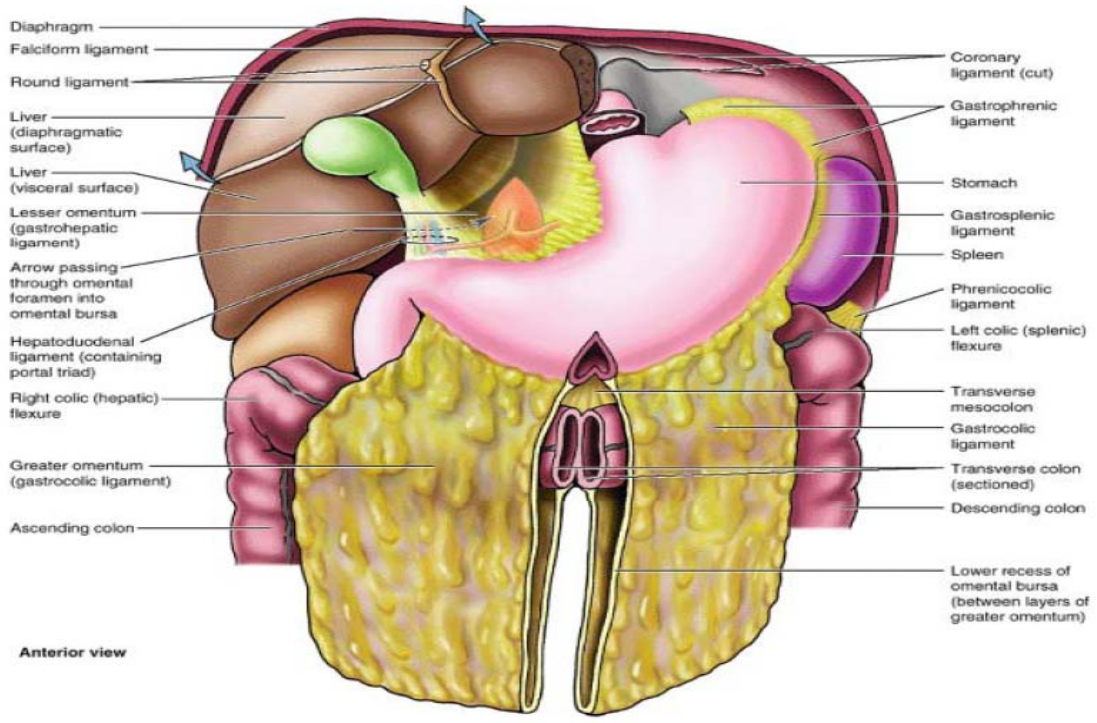

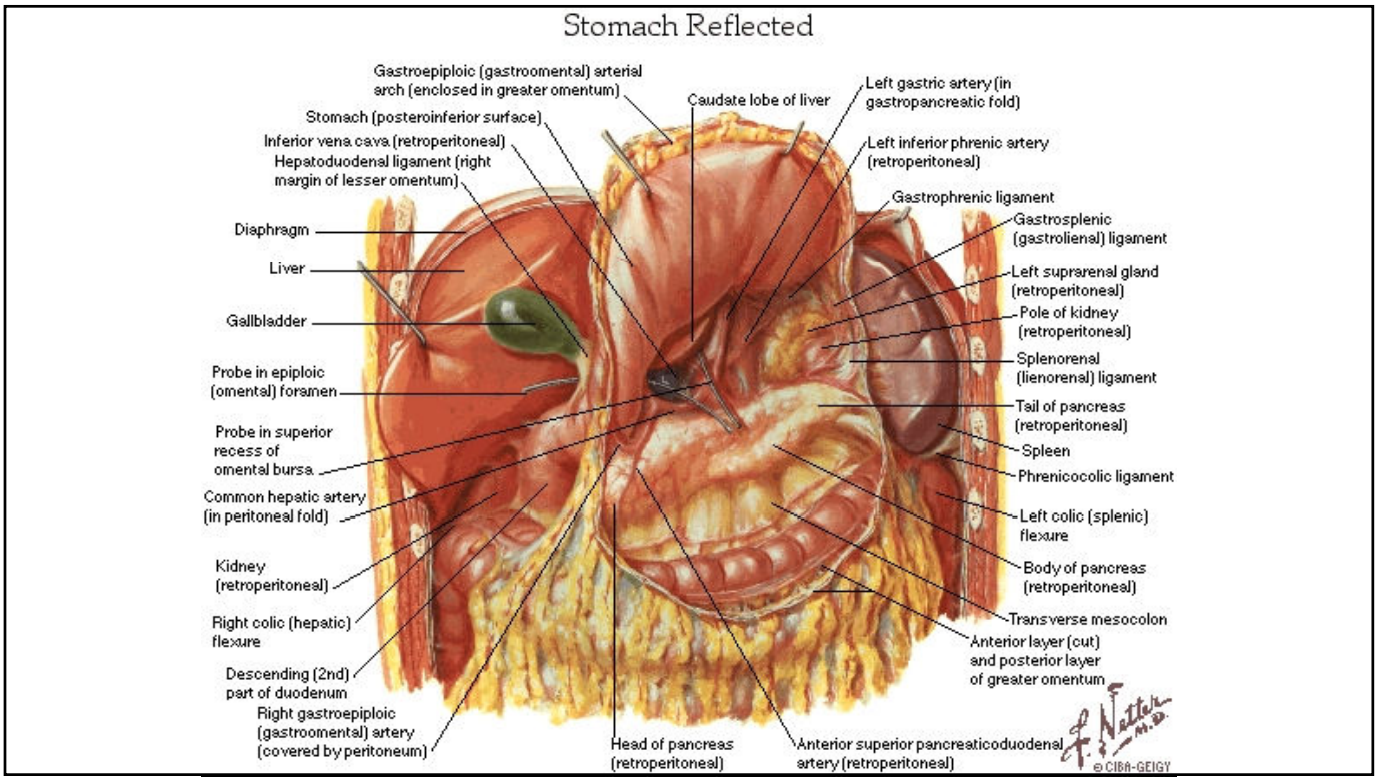
Stomach Reflected
Gastroepiploic (gastroomental) arterial arch (enclosed in greater omentum)
Stomach (posteroinferior surface)
Inferior vena cava (retroperitoneal)
Hepatoduodenal ligament (right margin of lesser omentum)
Diaphragm
Liver
Gallbladder
Probe in epiploic (omental) foramen
Probe in superior recess of omental bursa
Common hepatic artery (in peritoneal fold)
Kidney (retroperitoneal)
Right colic (hepatic) flexure
Descending (2nd) part of duodenum
Right gastroepiploic (gastroomental) artery (covered by peritoneum)
Caudate lobe of liver
Head of pancreas (retroperitoneal)
Anterior superior pancreaticoduodenal artery (retroperitoneal)
Left gastric artery (in gastropancreatic fold)
Left inferior phrenic artery (retroperitoneal)
Gastrophrenic ligament
Gastrosplenic (gastrolienal) ligament
Left suprarenal gland (retroperitoneal)
Pole of kidney (retroperitoneal)
Splenorenal (lienorenal) ligament
Tail of pancreas (retroperitoneal)
Spleen
Phrenicocolic ligament
Left colic (splenic) flexure
Body of pancreas (retroperitoneal)
Transverse mesocolon
Anterior layer (cut) and posterior layer of greater omentum
F. Netter M.D.
© CIBA-GEIGY

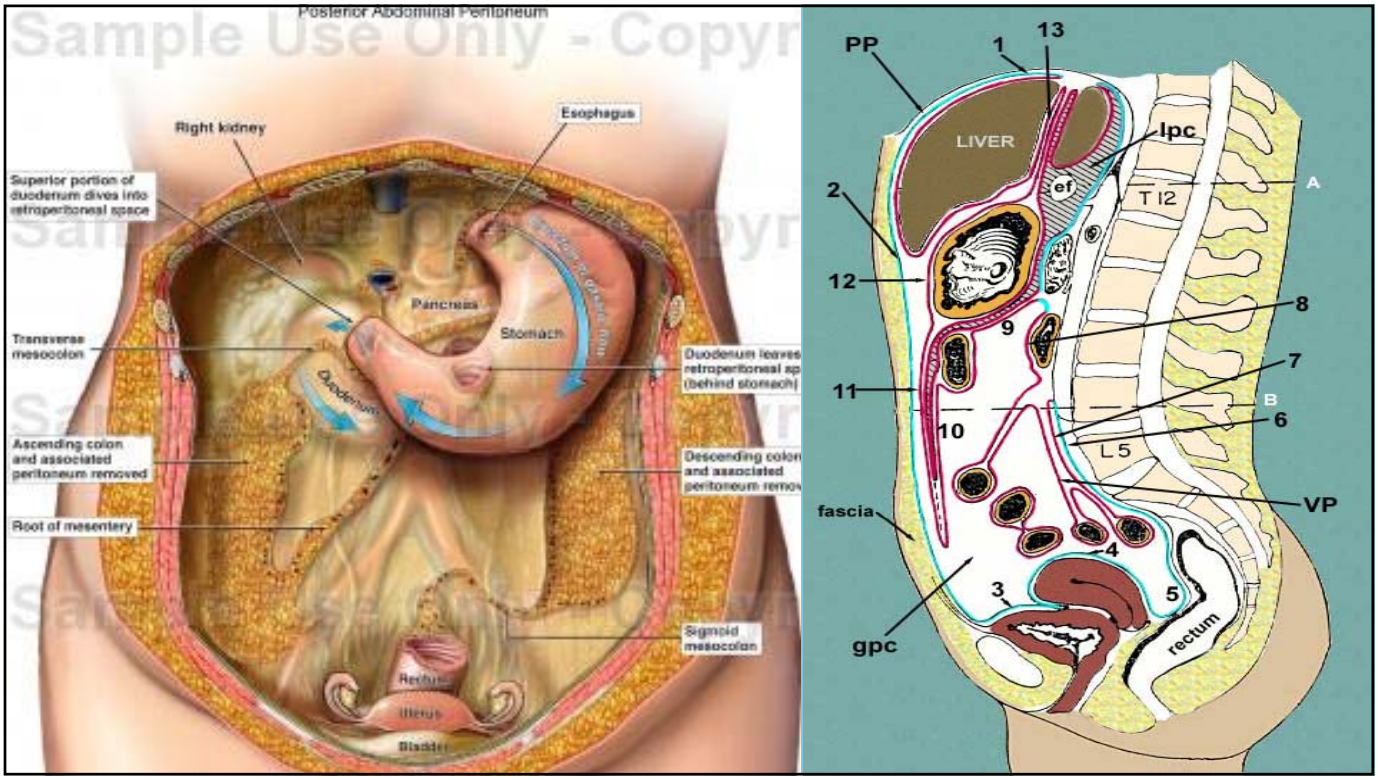
Posterior Abdominal Peritoneum
Sample Use Only - Copyr
Right kidney
Esophagus
Superior portion of duodenum dives into retroperitoneal space
Pancreas
Stomach
Transverse mesocolon
Duodenum
Duodenum leaves retroperitoneal sp (behind stomach)
Ascending colon and associated peritoneum removed
Descending colon and associated peritoneum remov
Root of mesentery
Sigmoid mesocolon
Rectum
Uterus
Bladder
PP
1
13
LIVER
lpc
ef
T 12
A
2
12
8
9
7
11
B
6
10
L 5
VP
fascia
4
3
5
gpc
rectum

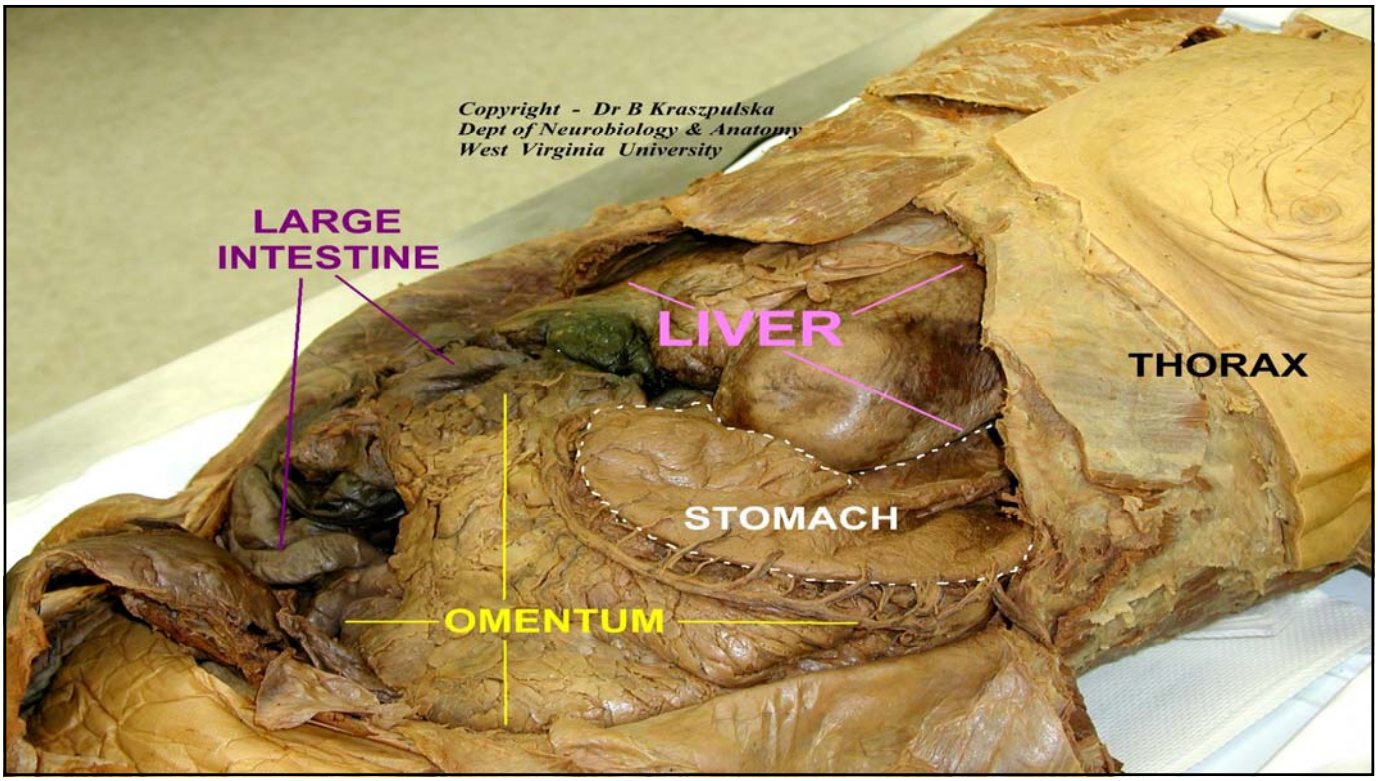
Copyright - Dr B Kraszpulska
Dept of Neurobiology & Anatomy
West Virginia University
LARGE INTESTINE
LIVER
THORAX
STOMACH
OMENTUM

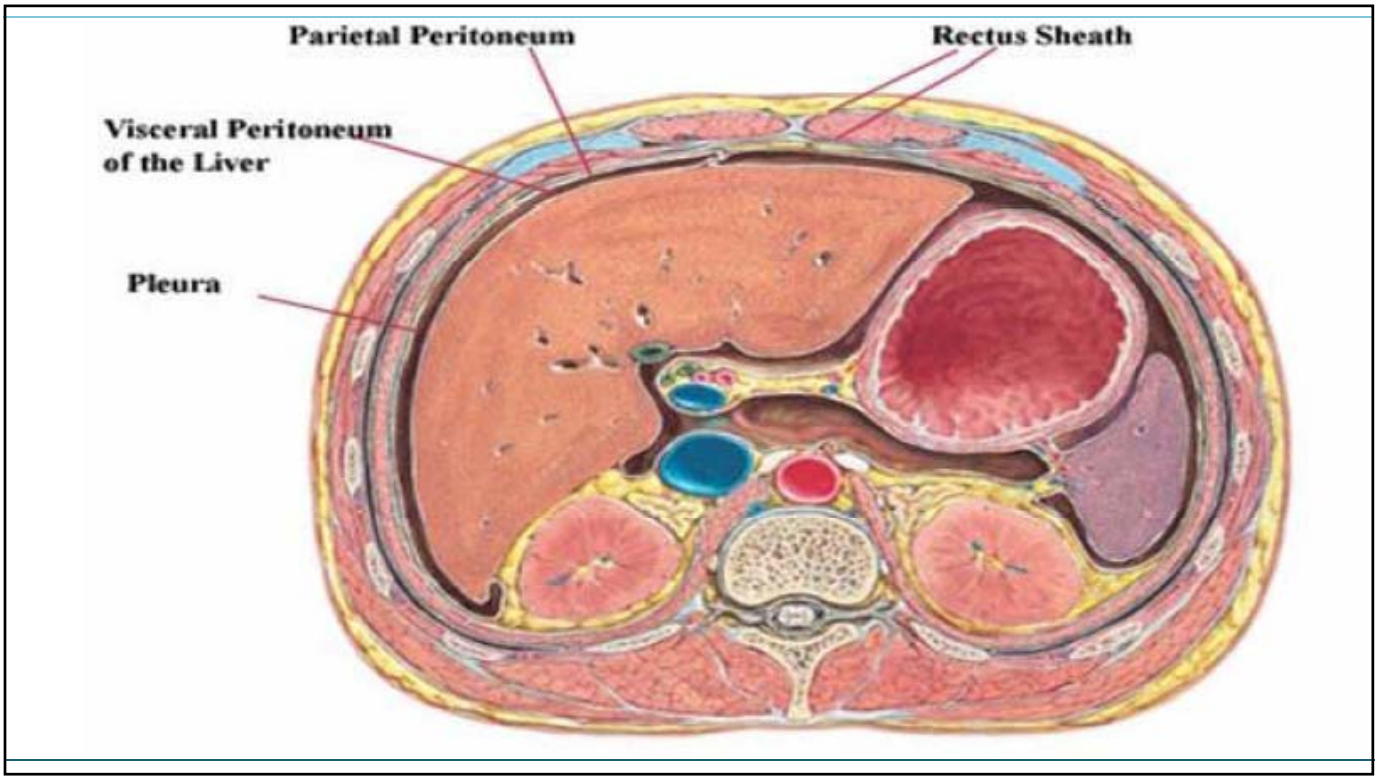
Parietal Peritoneum
Rectus Sheath
Visceral Peritoneum of the Liver
Pleura

stomach

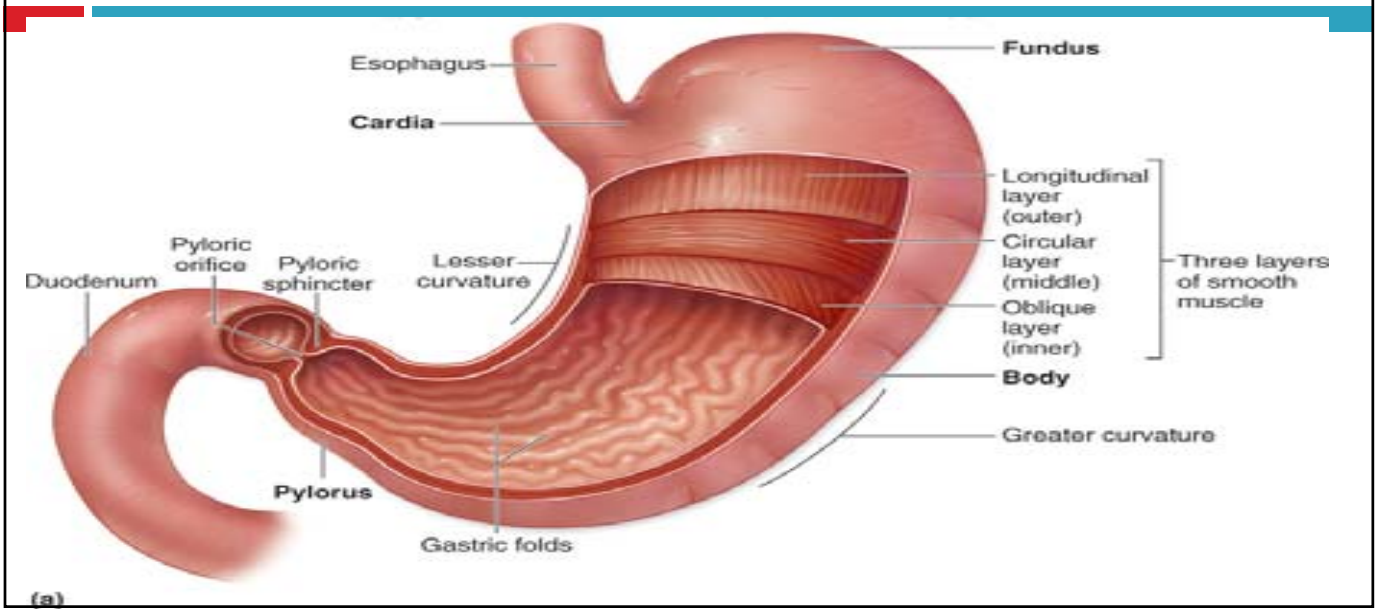
Esophagus
Fundus
Cardia
Longitudinal layer (outer)
Circular layer (middle)
Oblique layer (inner)
Three layers of smooth muscle
Pyloric orifice
Pyloric sphincter
Duodenum
Lesser curvature
Body
Greater curvature
Pylorus
Gastric folds
(a)

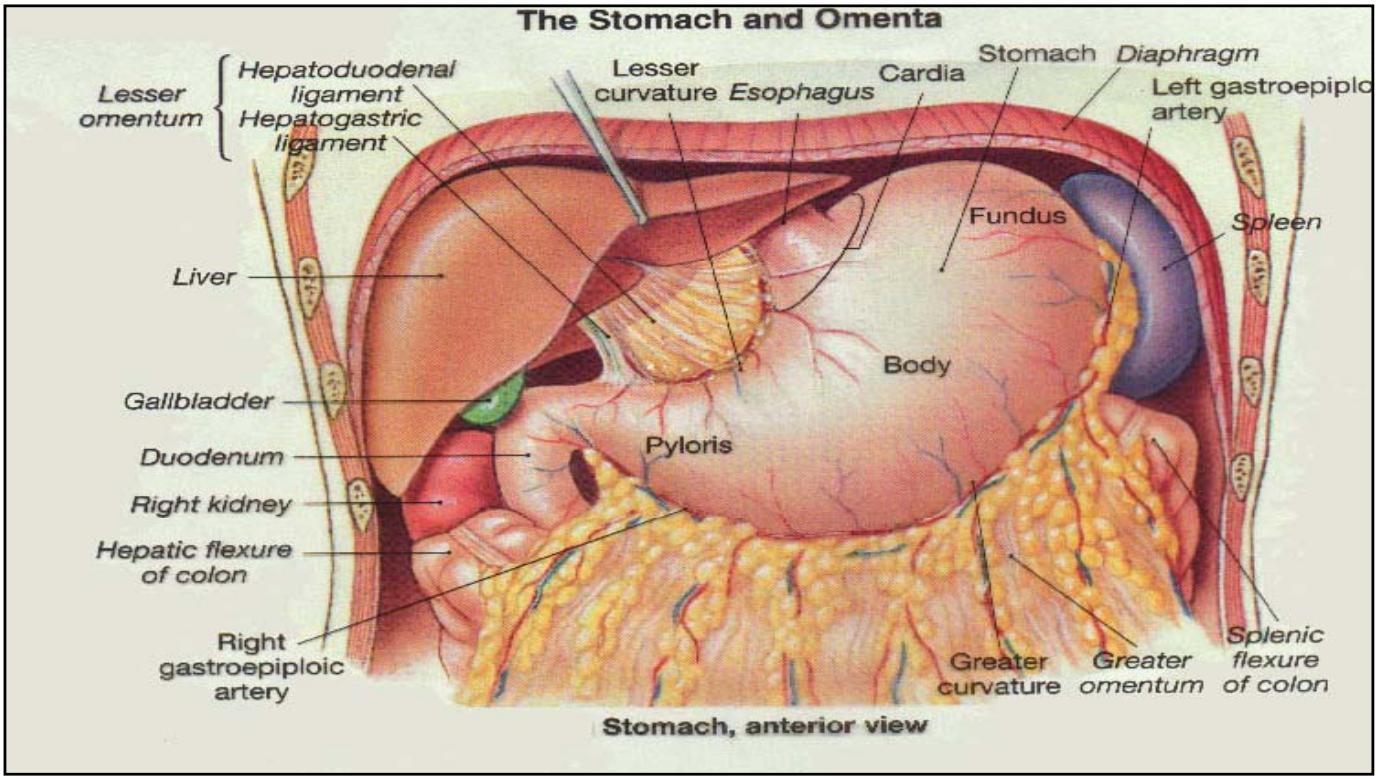
The Stomach and Omenta
Lesser omentum
Hepatoduodenal ligament
Hepatogastric ligament
Lesser curvature
Esophagus
Cardia
Stomach
Diaphragm
Left gastroepiploic artery
Fundus
Spleen
Liver
Body
Gallbladder
Pyloris
Duodenum
Right kidney
Hepatic flexure of colon
Right gastroepiploic artery
Greater curvature
Greater omentum
Splenic flexure of colon
Stomach, anterior view

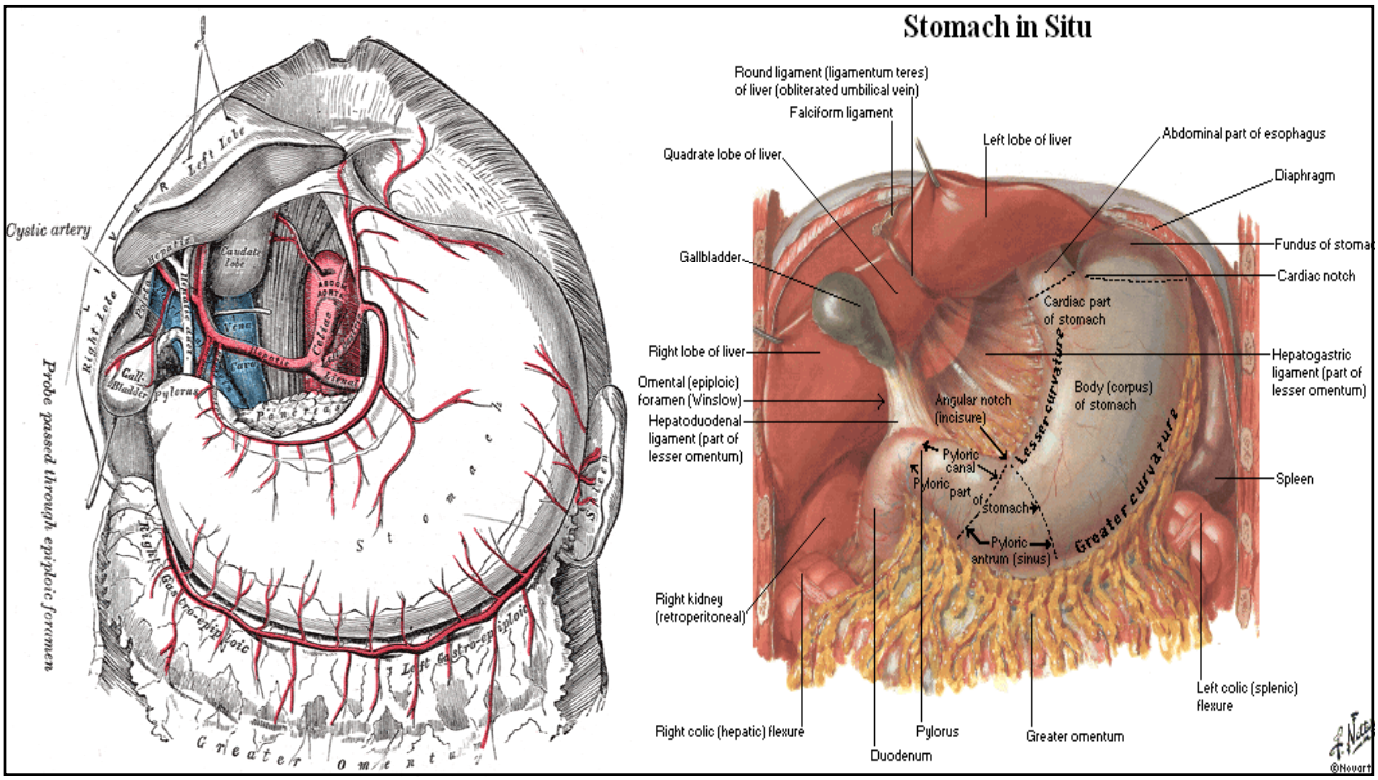
Cystic artery
Probe passed through epiploic foramen
Stomach in Situ
Round ligament (ligamentum teres) of liver (obliterated umbilical vein)
Falciform ligament
Quadrate lobe of liver
Left lobe of liver
Abdominal part of esophagus
Diaphragm
Gallbladder
Fundus of stomach
Cardiac notch
Cardiac part of stomach
Right lobe of liver
Hepatogastric ligament (part of lesser omentum)
Omental (epiploic) foramen (Winslow)
Hepatoduodenal ligament (part of lesser omentum)
Angular notch (incisure)
Body (corpus) of stomach
Lesser curvature
Greater curvature
Pyloric canal
Pyloric part of stomach
Pyloric antrum (sinus)
Spleen
Right kidney (retroperitoneal)
Left colic (splenic) flexure
Right colic (hepatic) flexure
Pylorus
Duodenum
Greater omentum
©Novart

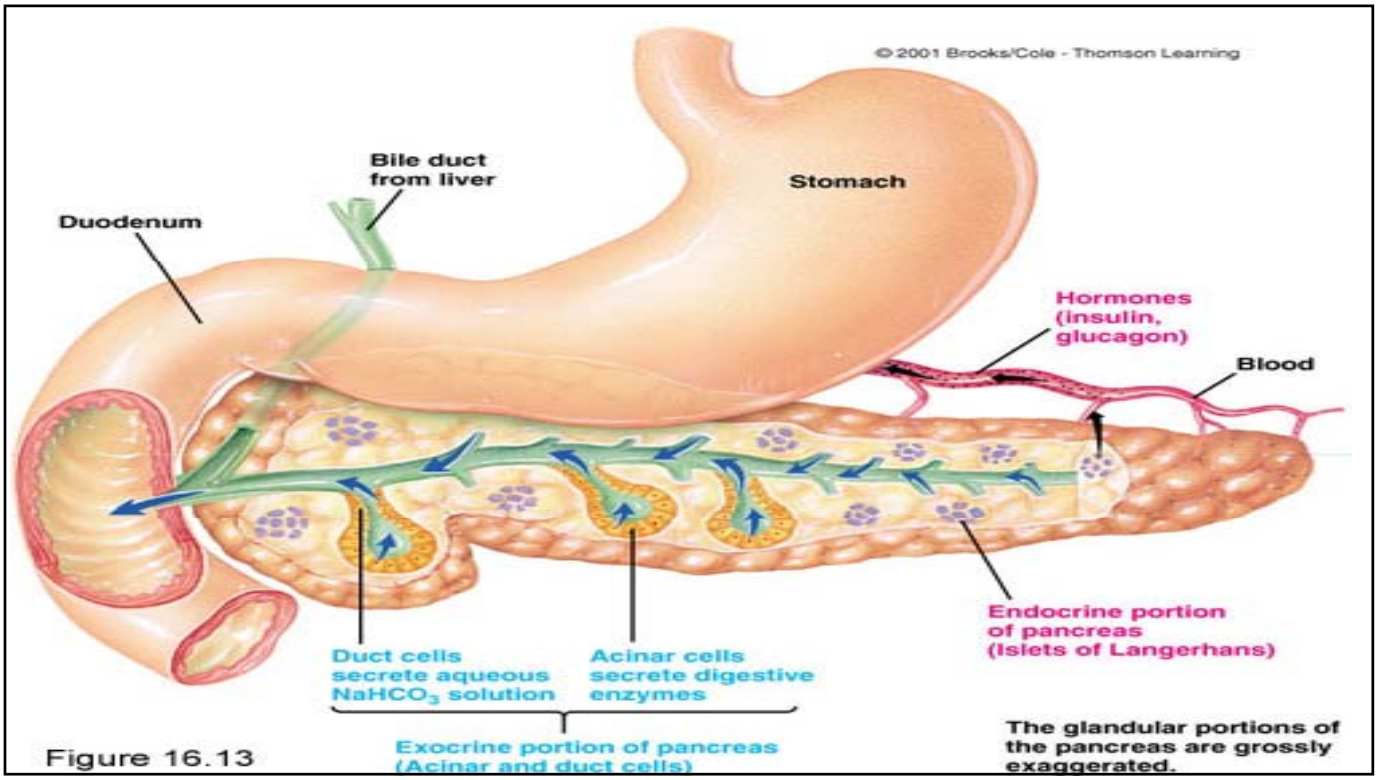
© 2001 Brooks/Cole - Thomson Learning
Bile duct from liver
Stomach
Duodenum
Hormones (insulin, glucagon)
Blood
Duct cells secrete aqueous $NaHCO_3$ solution
Acinar cells secrete digestive enzymes
Endocrine portion of pancreas (Islets of Langerhans)
Exocrine portion of pancreas (Acinar and duct cells)
The glandular portions of the pancreas are grossly exaggerated.

Figure 16.13

Stomach

74

- Usually "J" shaped
- Left side, anterior to the spleen
- Mucous membrane
  - G cells – make gastrin
  - Goblet cells – make mucous
  - Gastric pit – Oxyntic gland – Parietal cells – Make HCl
  - Chief cells – Zymogenic cells
    - Pepsin
    - Gastric lipase

Stomach

- 3 muscle layers
  - Oblique
  - Circular
  - Longitudinal
- Regions
  - Cardiac sphincter
  - Fundus
  - Antrum (pylorus)
  - Pyloric sphincter
- Vascular
- Inner surface thrown into folds – Rugae
- Contains enzymes that work best at pH 1-2

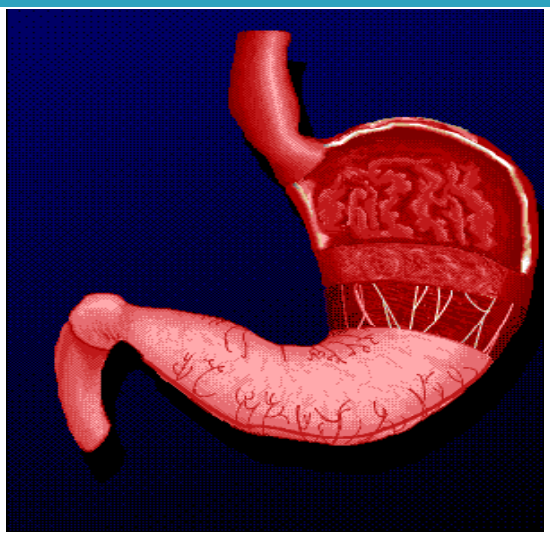

Anatomy of the Stomach

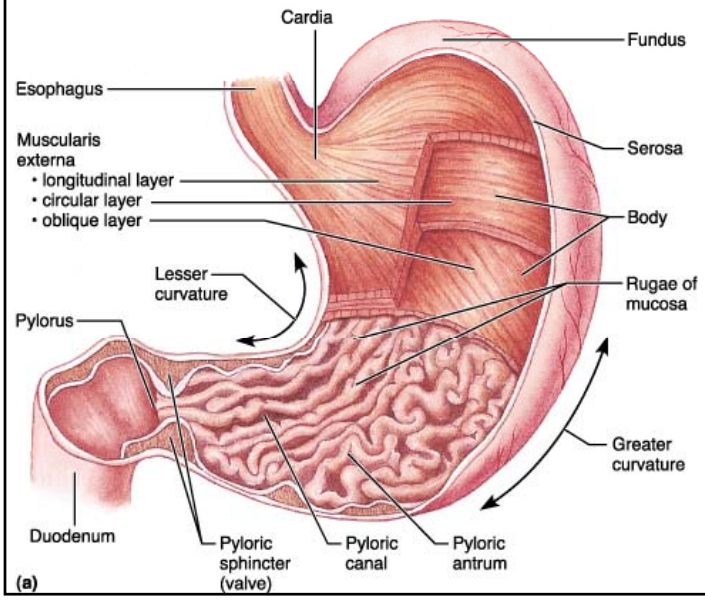

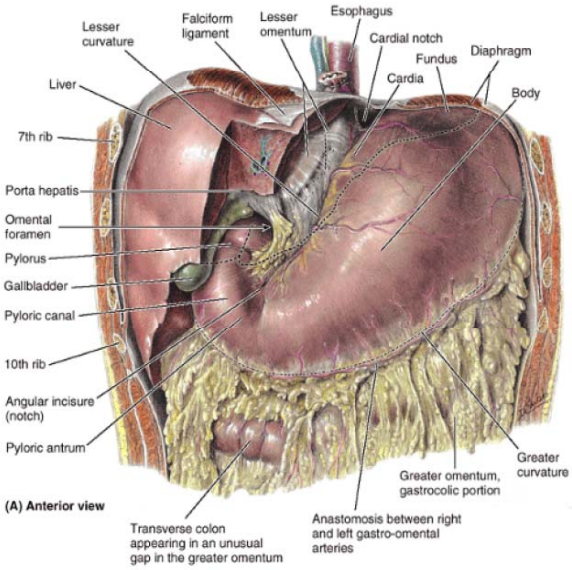

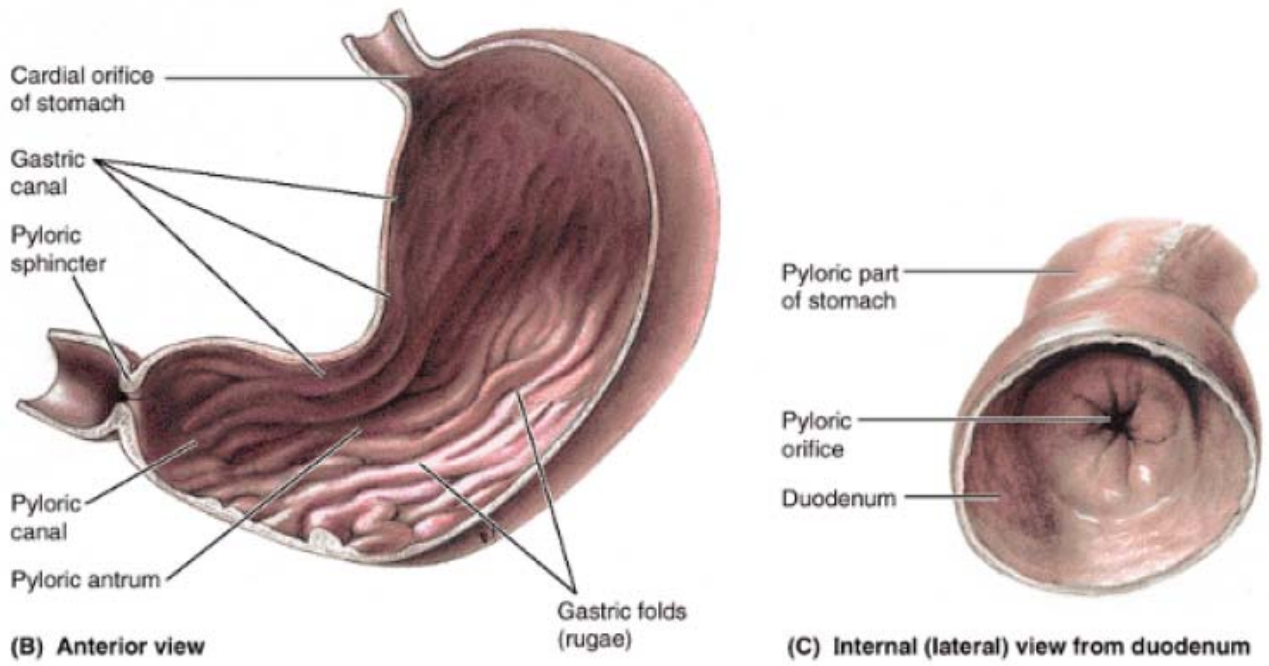

Stomach

- Functions
  - Mix food
  - Reservoir
  - Start digestion of
    - Protein
    - Nucleic acids
    - Fats
  - Activates some enzymes
  - Destroy some bacteria
  - Makes intrinsic factor – B 12 absorption
  - Destroys some bacteria
- Absorbs
  - Alcohol
  - Water
  - Lipophilic acid
  - B 12

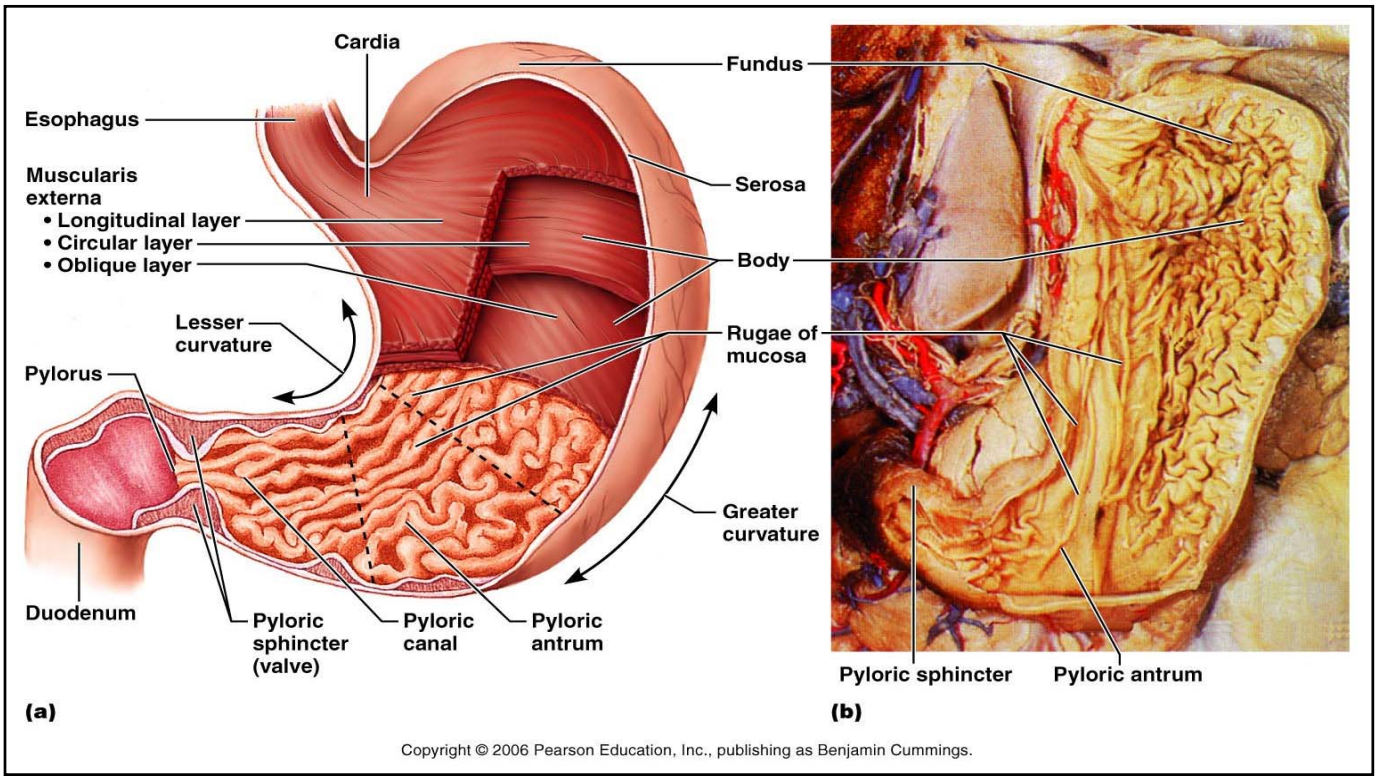

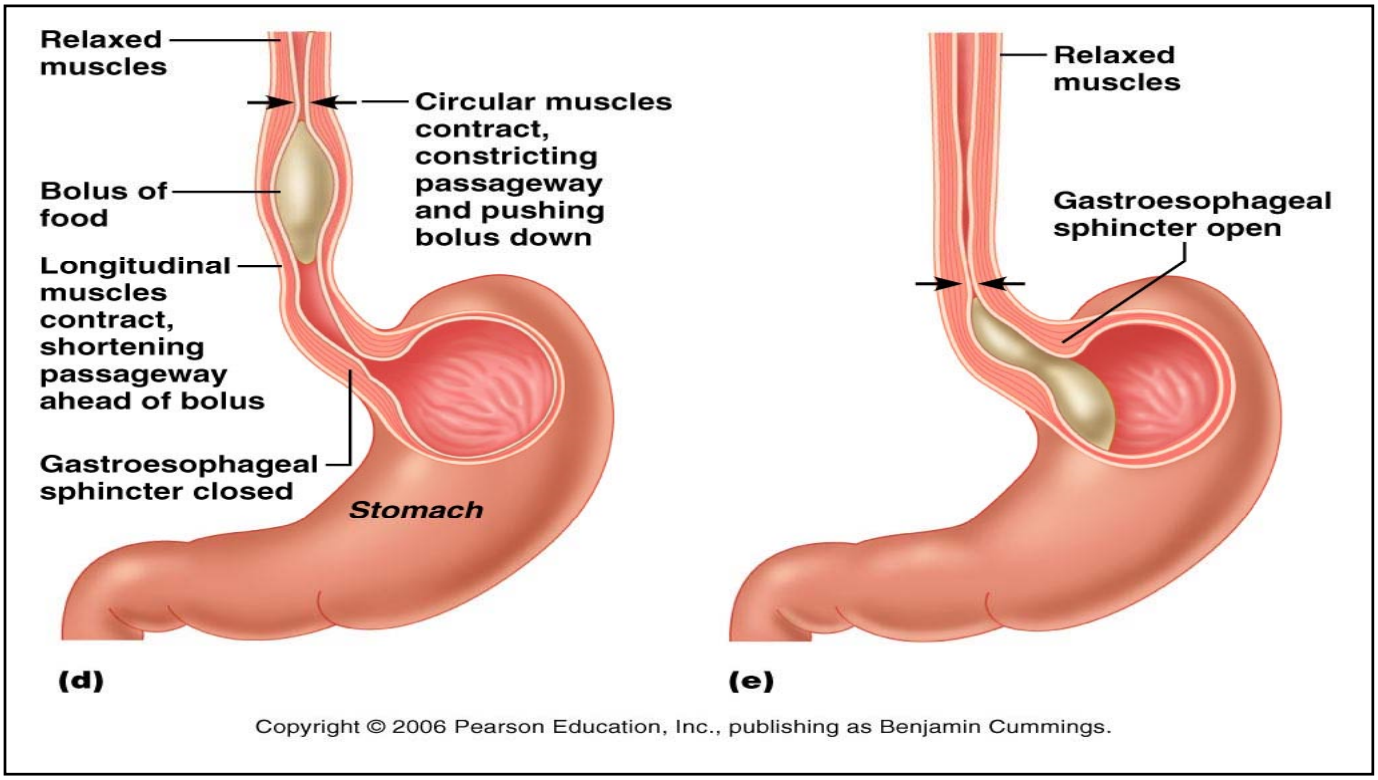

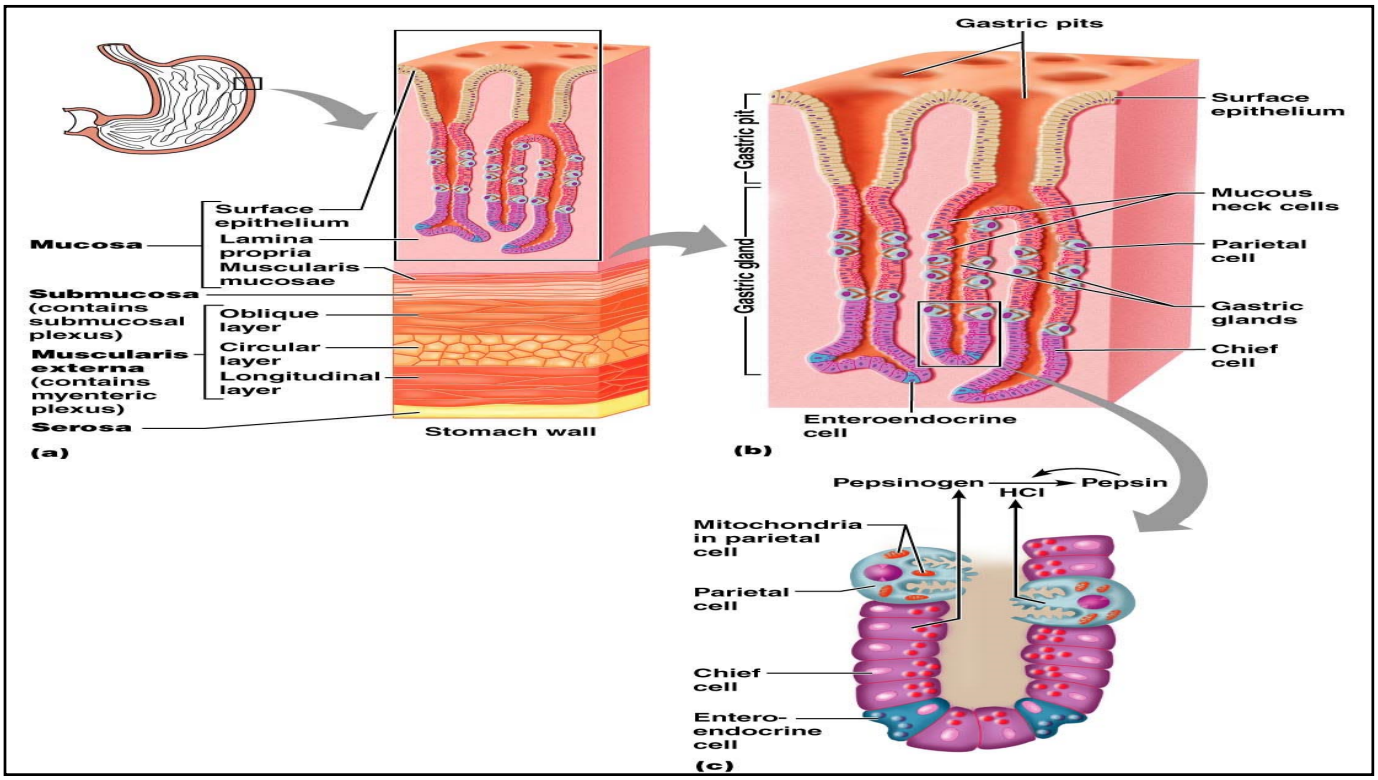

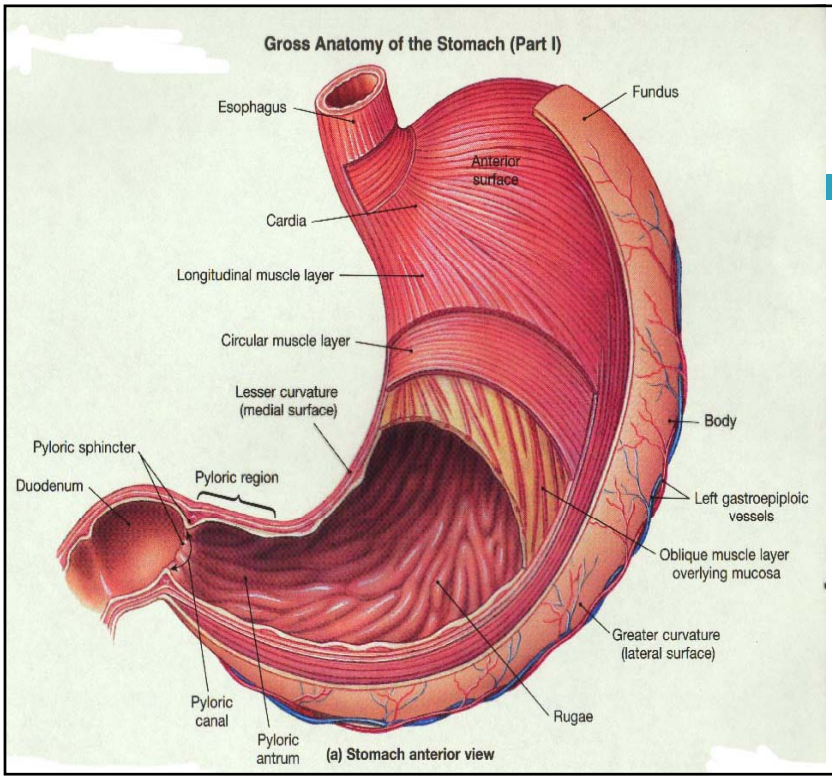

- **Stomach Histology, continued**
  - **muscularis: three layers**

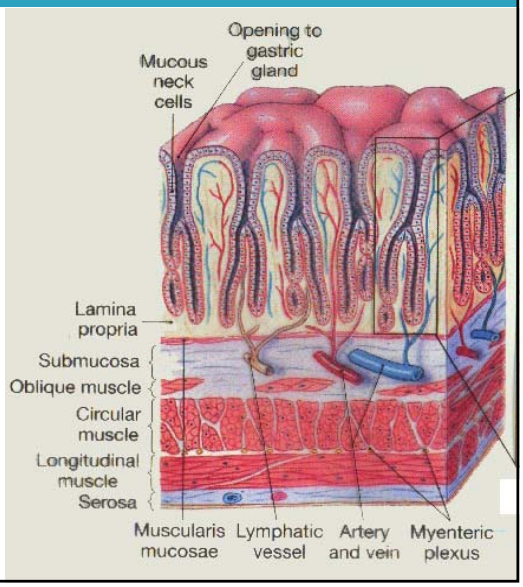

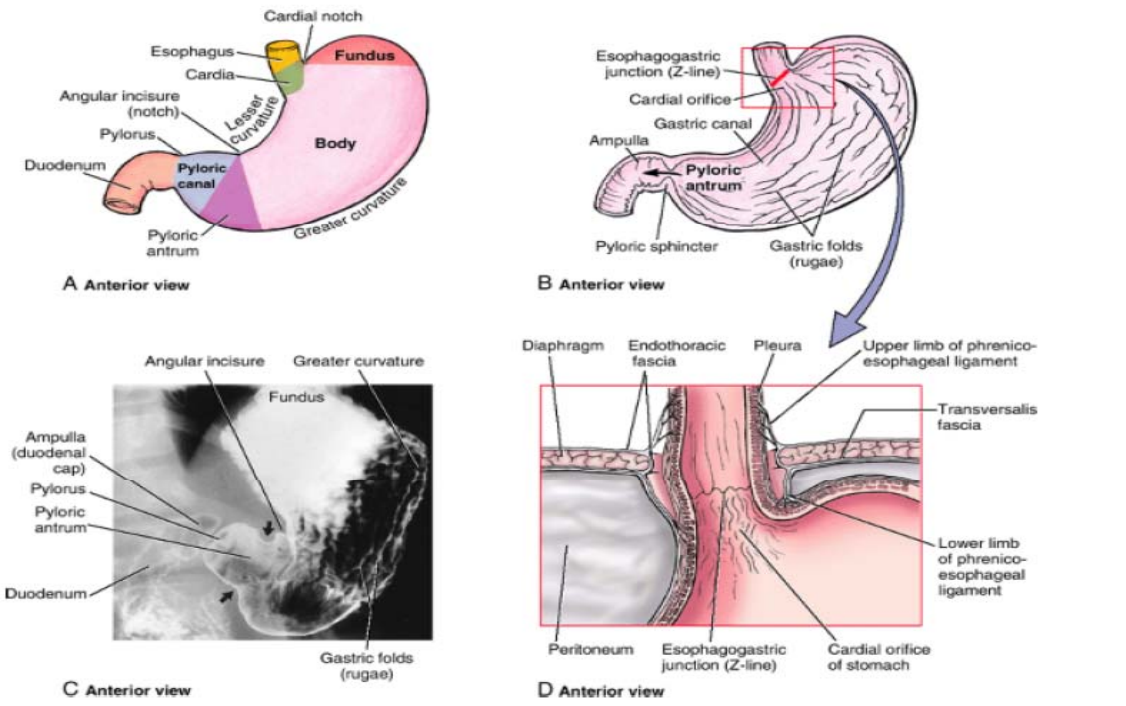

Gastric Secretions

- <u>3 Main cells</u>:
  1. Mucous cells – mucous
  2. chief – digestive enzymes
     a. Pepsin – digests protein
     b. Alkaline substance – protects lining
     c. Intrinsic factor – absorbs Vitamin B12
  3. parietal cells → hydrochloric acid

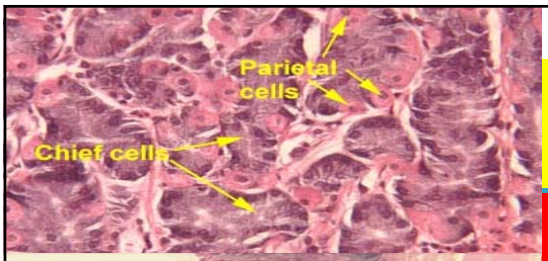

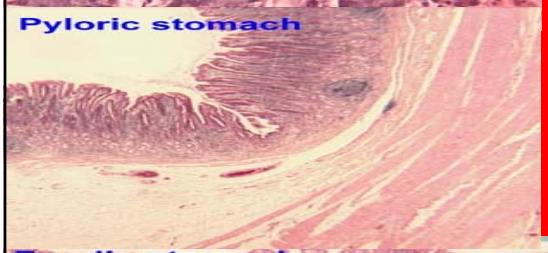

STOMACH PARIETAL CELLS

- MUCOUS CELLS
- ZYGOMATIC OR CHIEF CELLS
- OXYNTIC OR PARIETAL CELLS
- ARGENTAFFIN CELLS

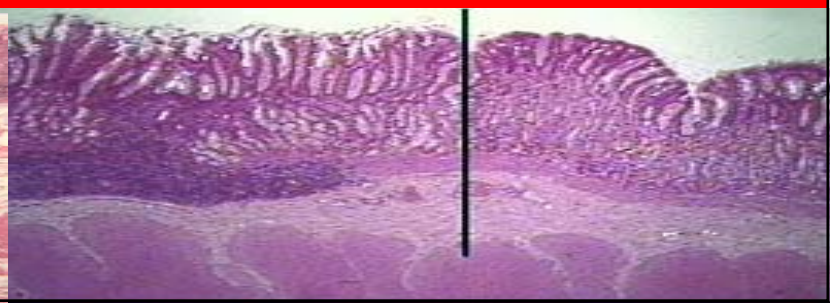

- Stomach Histology
  - mucosa: location of gastric glands

- gastric gland cells

  mucous cells

  parietal cells

  chief cells

  endocrine cells

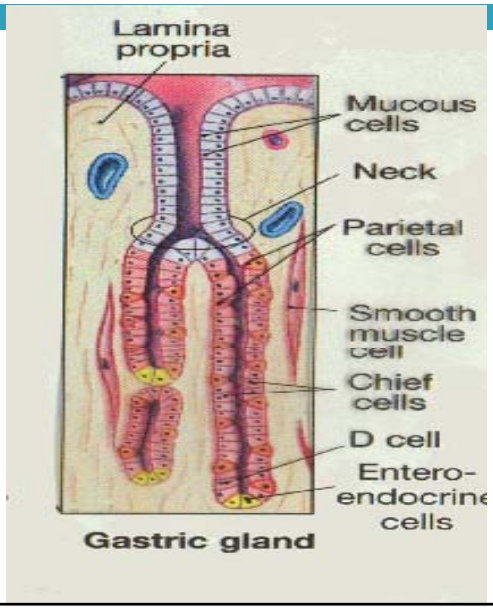

Parietal cells

(a) Secrete intrinsic factor and hydrochloric acids (HCl)

(b) HCl is produced by the secretion of two different molecules as the molecules would breakdown the cell too quickly

(c) Makes H2CO3 which quickly breaks down to H+ and HCO3-

(d) Chloride is diffused across the cellular membrane through open Cl channels

OXYNTIC OR PARIETAL CELLS

[hydrochloric acid, the secretory product of the parietal, or oxyntic cell.]

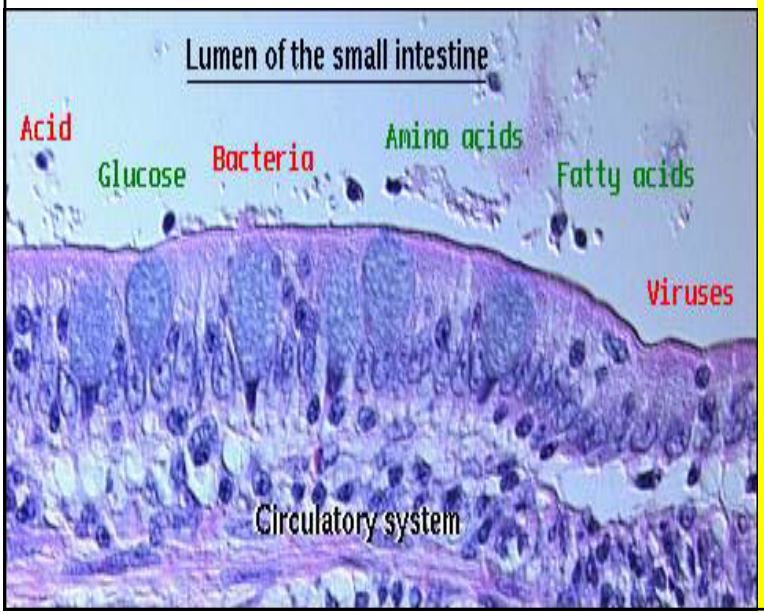

Parietal cells bear receptors for three stimulators of acid secretion, reflecting a triumverate of neural, paracrine and endocrine control:

- Acetylcholine (muscarinic type receptor)
- Gastrin
- Histamine (H2 type receptor)

Chief Cells

(a) Secrete pepsinogen - activated by H+ becomes pepsin
(b) Infants secrete rennin and gastric lipase

Pyloric glands

(a) Make hormone gastrin which stimulate the secretion of chief and parietal cells, coordinate the gastric wall muscle cells

(b) Make hormone somatostatin which counters gastrin

Chief Cells

- The "chief" cells synthesize and secrete pepsinogen,
- the precursor to the proteolytic enzyme pepsin.
- Pepsin cleaves peptide bonds, favoring those on the C-terminal side of tyrosine, phenylalanine, and tryptophan residues.
- Its action breaks long polypeptide chains into shorter lengths.
- Secretion by the gastric glands is stimulated by the hormone gastrin. Gastrin is released by endocrine cells in the stomach in response to the arrival of food.

Chief cells -- pepsinogen
Parietal cells -- HCl, Intrinsic factor
Mucous cells
Enteroendocrine cells -- gastrin

The Extrinsic Gastrointestinal Barrier
- Mucus and Bicarbonate
- Hormones and Cytokines

The gastrointestinal barrier is often discussed as having two components:
- The intrinsic barrier is composed of the epithelial cells lining the digestive tube and the tight junctions that tie them together.
- The extrinsic barrier consists of secretions and other influences that are not physically part of the epithelium, but which affect the epithelial cells and maintain their barrier function.

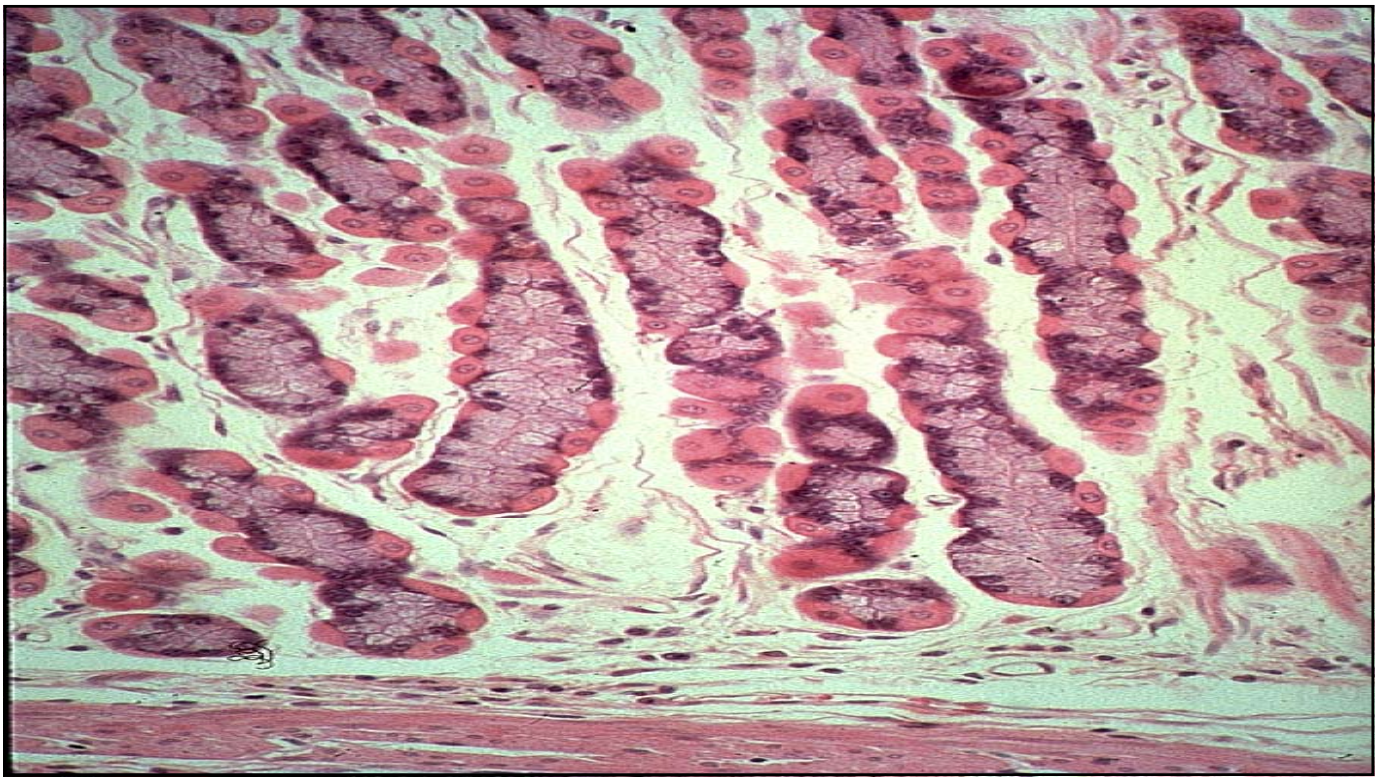

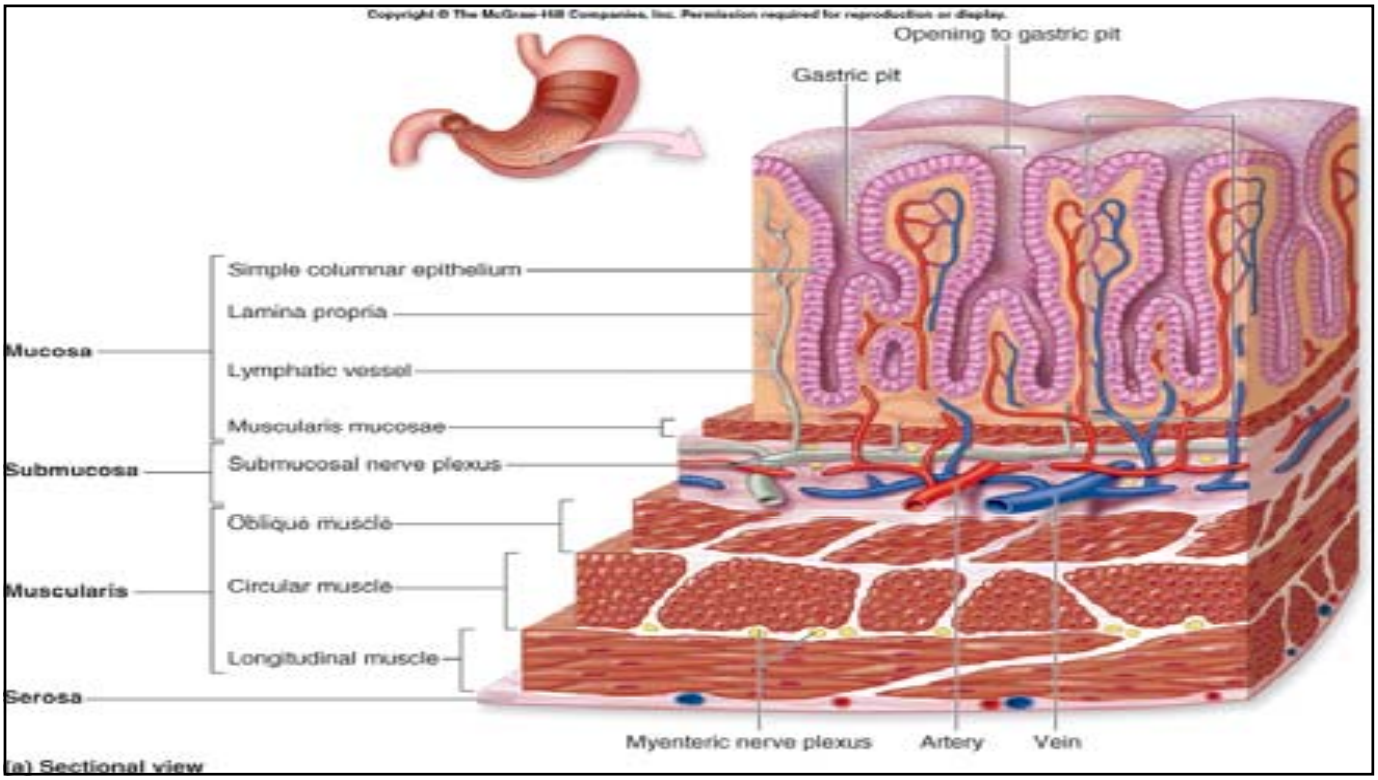
Opening to gastric pit
Gastric pit
Simple columnar epithelium
Lamina propria
Mucosa
Lymphatic vessel
Muscularis mucosae
Submucosa
Submucosal nerve plexus
Oblique muscle
Muscularis
Circular muscle
Longitudinal muscle
Serosa
Myenteric nerve plexus
Artery
Vein
(a) Sectional view

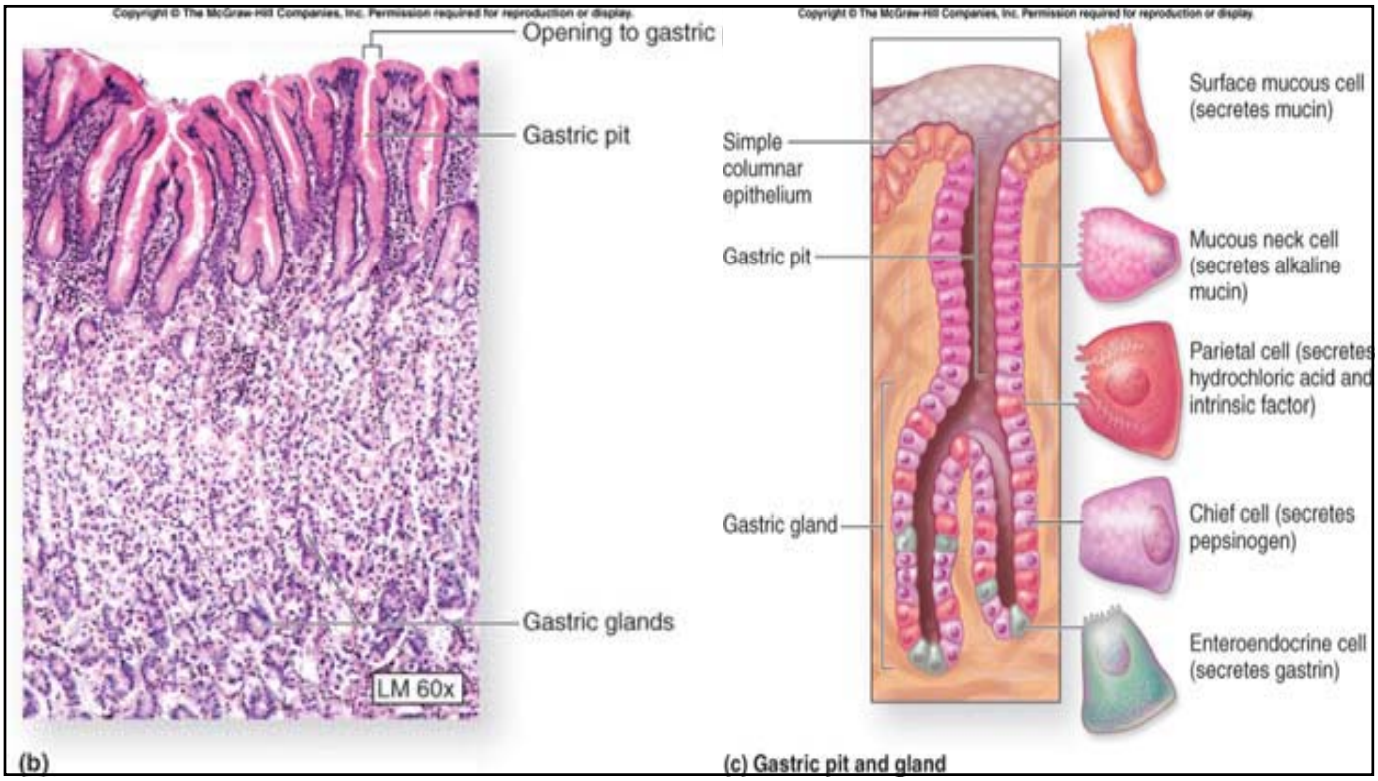

- **Stomach Histology**
  - **mucosa: location of gastric glands**

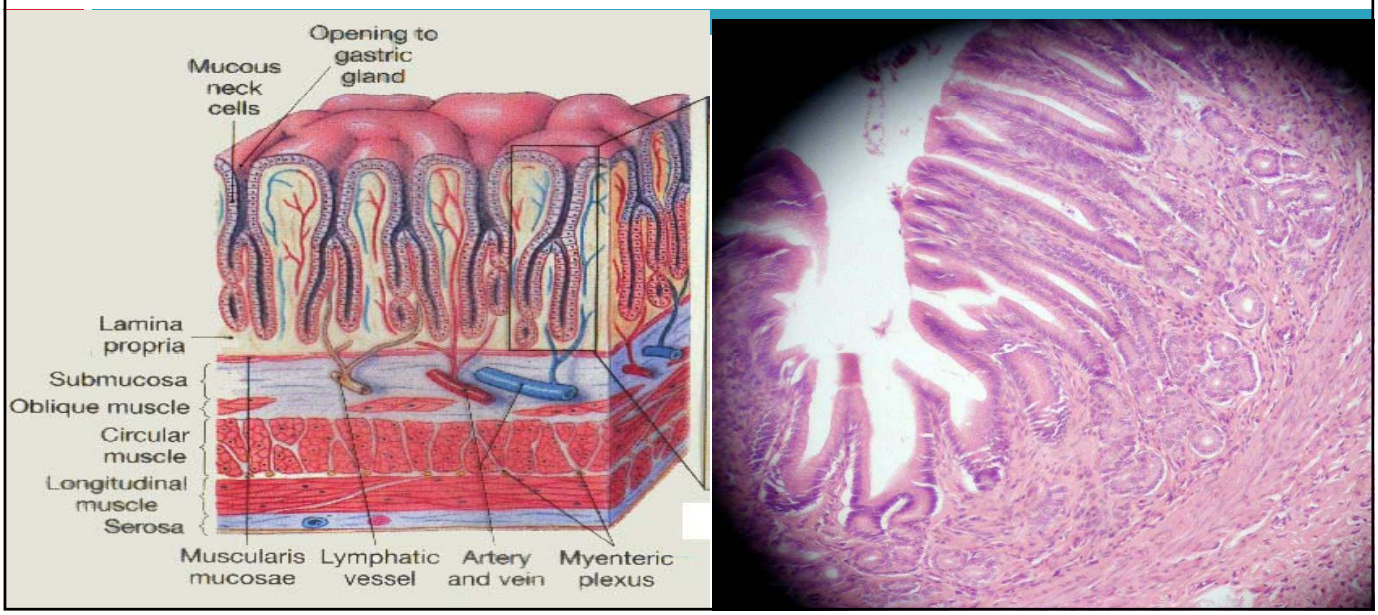

Stomach Histology

- mucosa: location of gastric glands

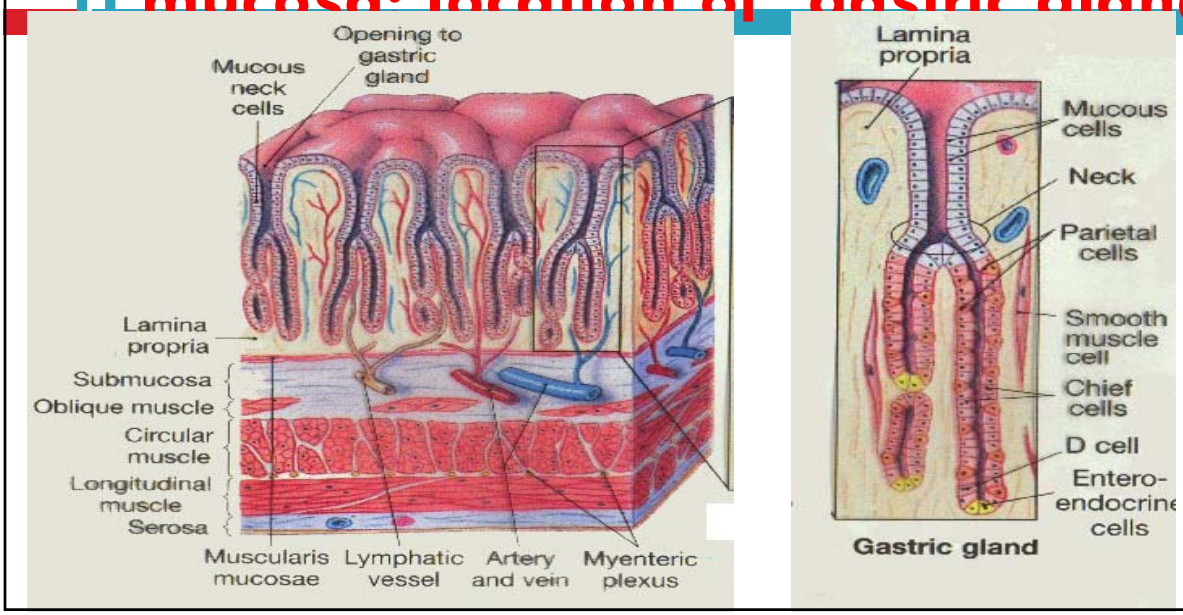

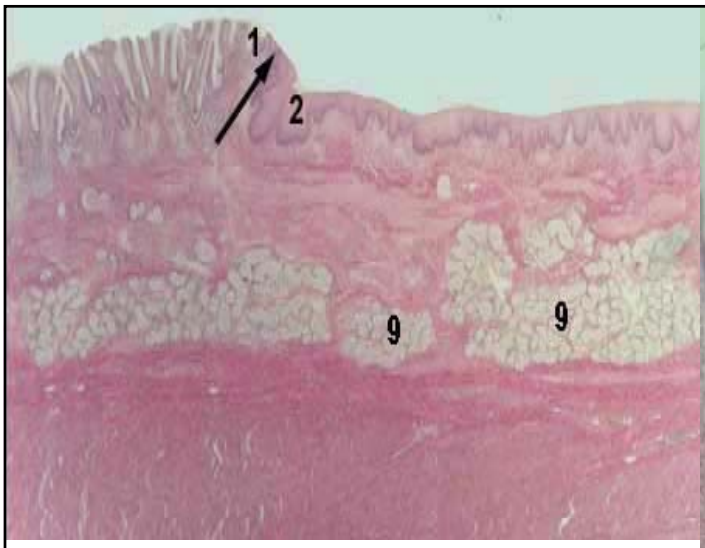

GASTRO-ESOPHAGEAL JUNCTION

Stained with haematoxylin and eosin

1 - stomach
2 - esophagus

FUNDAL PART OF THE STOMACH

Stained with haematoxylin and eosin

1 - tunica mucosa
2 - tunica submucosa
3 - tunica muscularis propria
4 - tunica serosa
5 - epithelium of the mucosa
6 - lamina propria of the mucosa (contains glands)
7 - muscularis mucosae

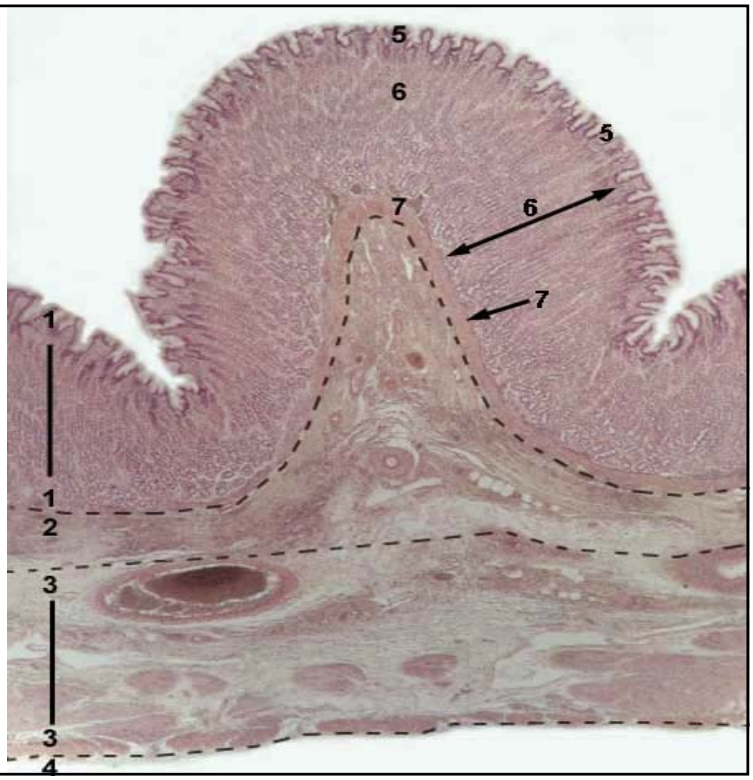

PYLORIC PART OF THE STOMACH

Stained with haematoxylin and eosin

1 - tunica mucosa
2 - tunica submucosa
3 - tunica muscularis propria
5 - lamina propria of the mucosa (contains glands)
7 - gastric pits in the mucosa
8 - muscularis mucosae

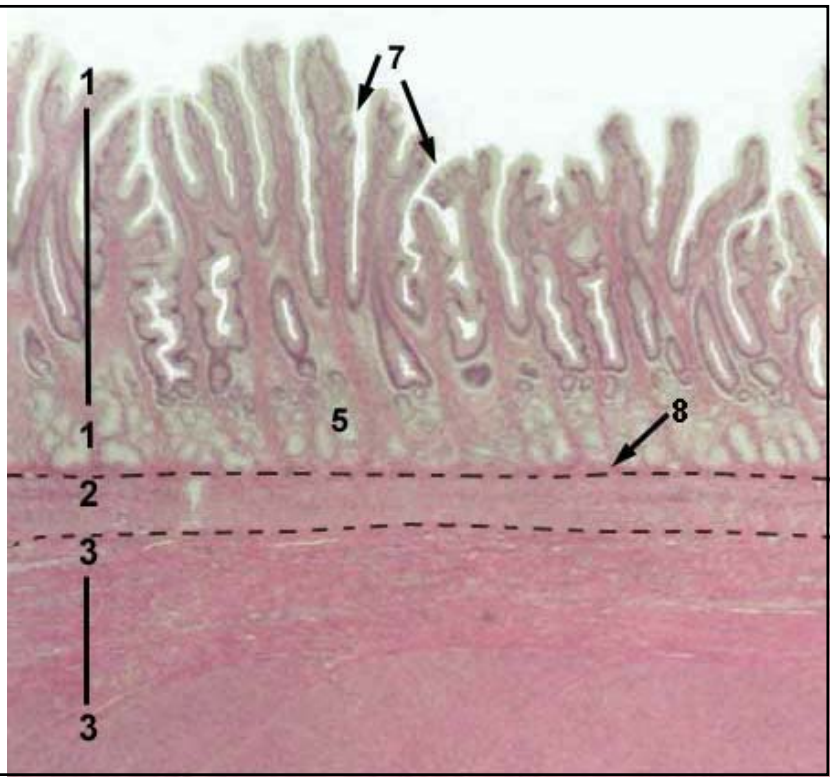

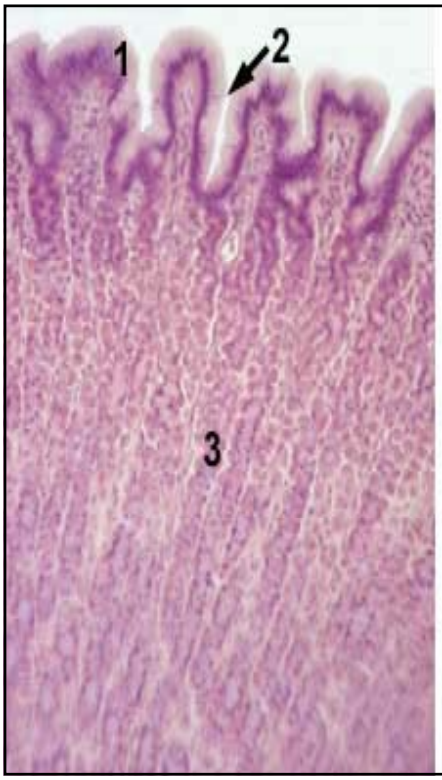

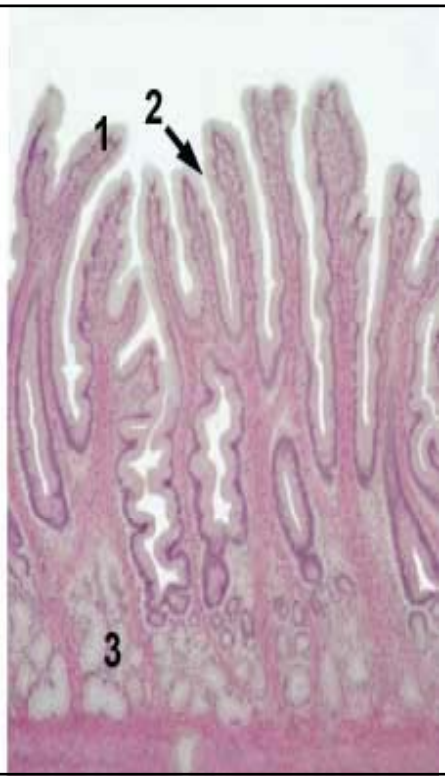

FUNDAL PART (left), PYLORIC PART (right) OF THE STOMACH

Stained with haematoxylin and eosin

1 - epithelium of the mucosa
2 - gastric pits in the mucosa
3 - glands in the lamina propria

Fundic stomach – MCW063 (low mag)

No goblet cells in stomach

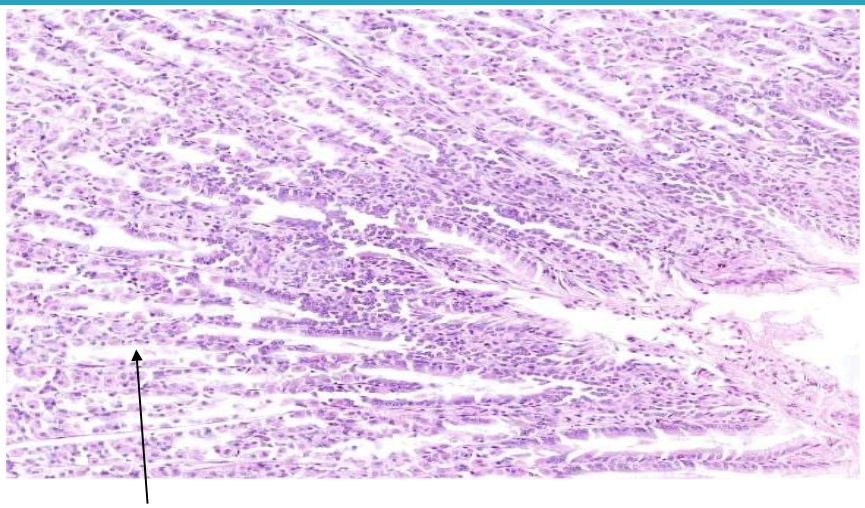

Chief cells

-at base of gland

-have basophilic zymogen granules

-principal cell type in basal portion of fundic gland (p. 47, manual)

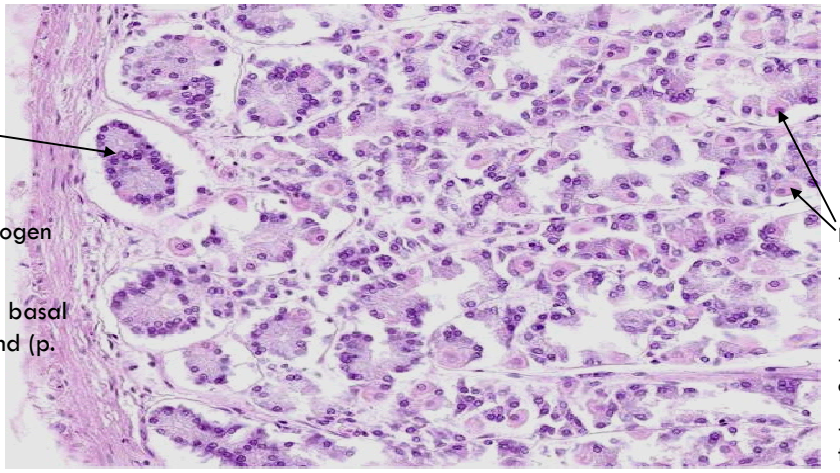

Parietal cells (?)

-eosinophilic,

-rounded

-found throughout full extent of gland

- produce HCl and intrinsic factor

Pyloric stomach – MCW 065 (low mag)

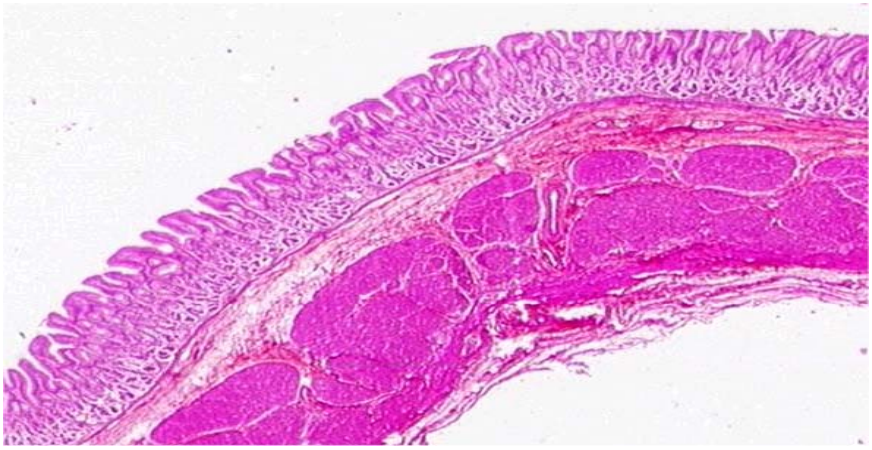

Pyloric portion – "long gastric pits (2/3) and relatively short gastric glands (1/3)" – p. 47. manual

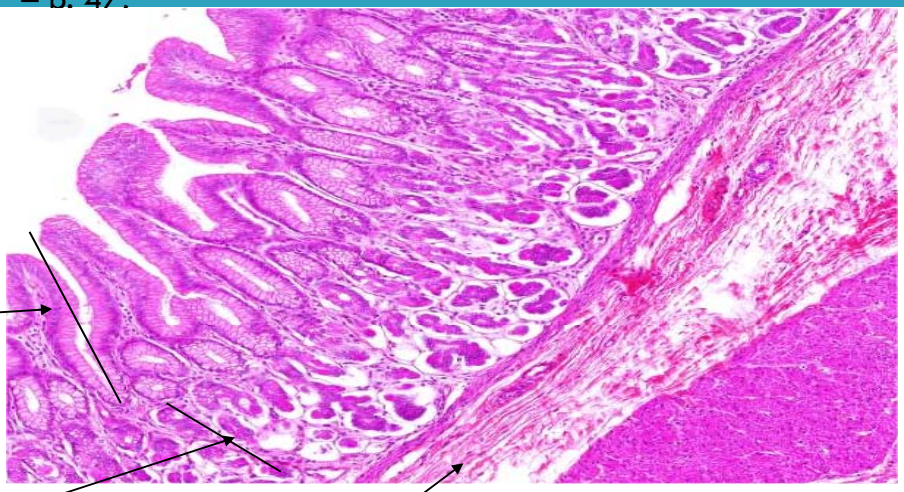

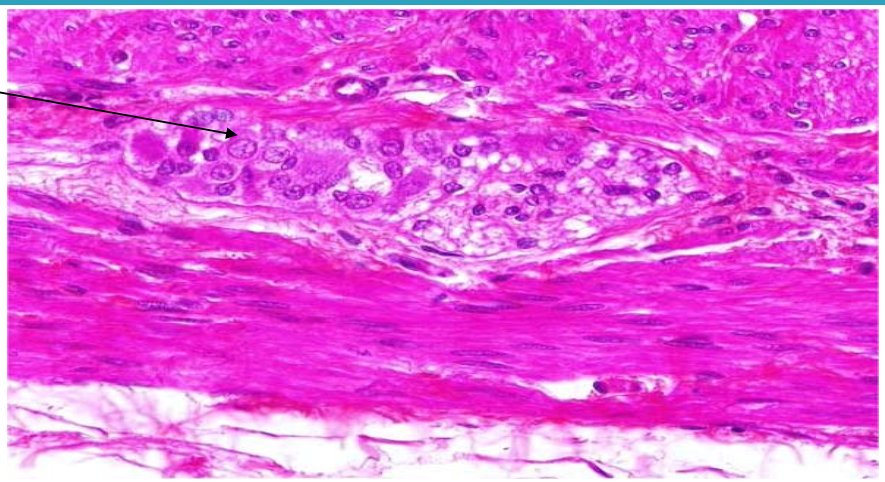

Mucous neck cells

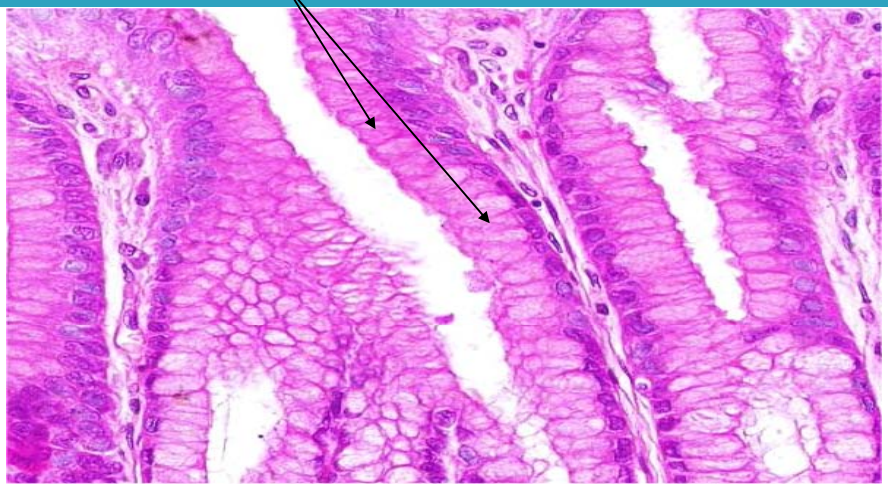

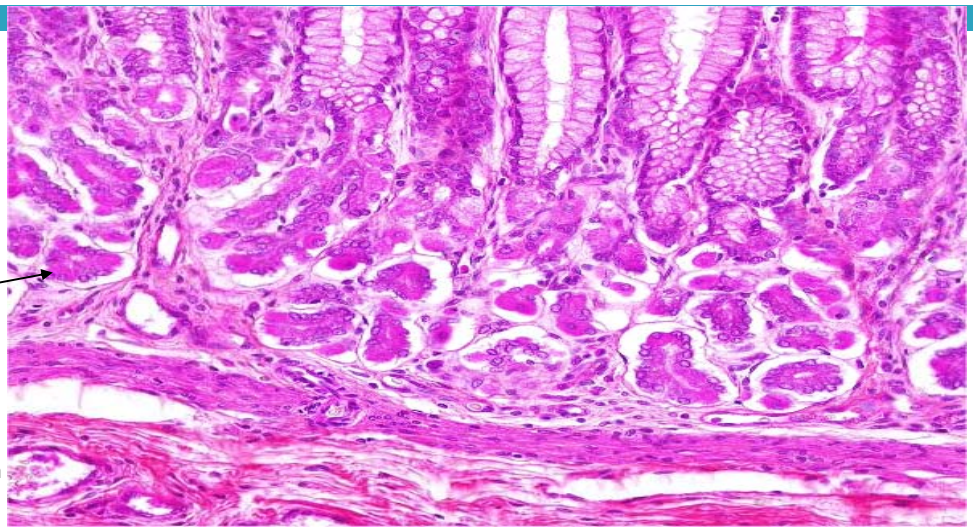

parietal cells

-eosinophilic

-scattered in the pyloric region

– fewer parietal cells compared with fundic region

Pyloric-duodenal junction UW046