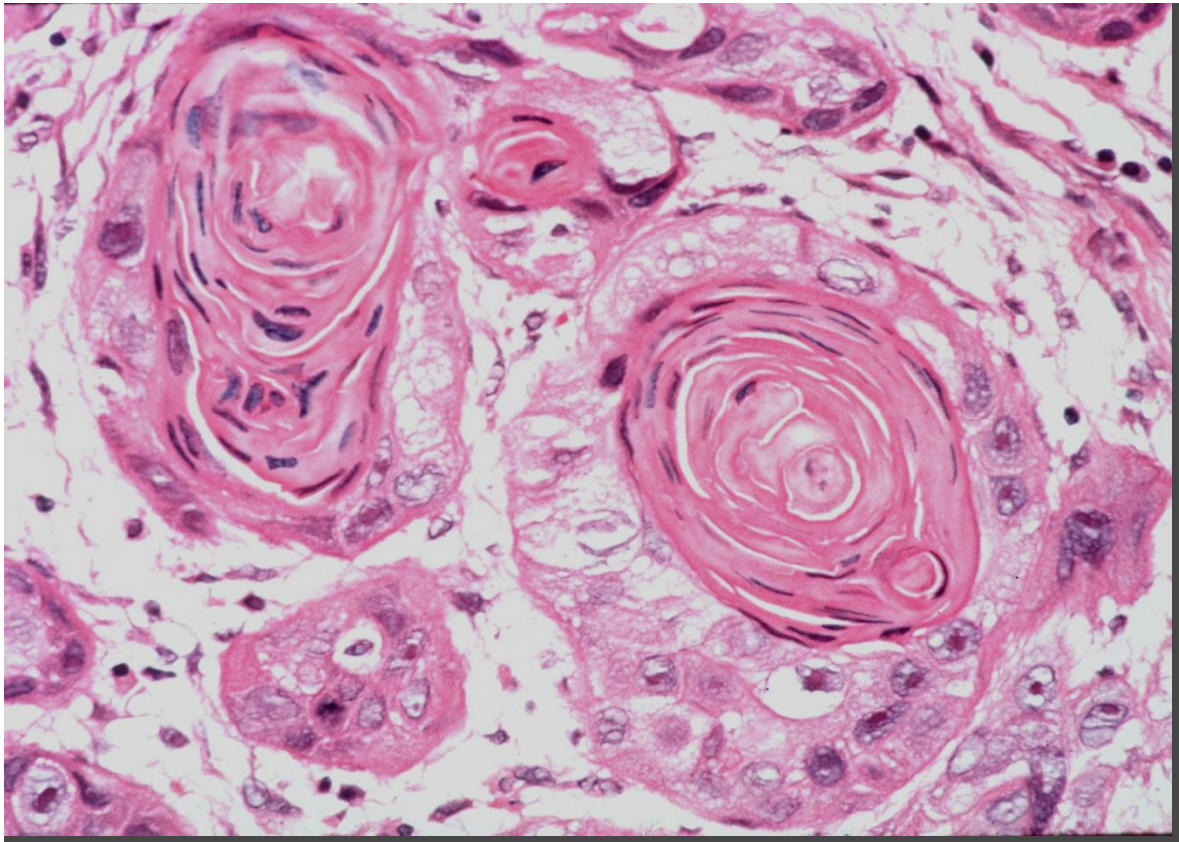

RESPIRATORY DISEASES

D.Hammoudi.MD



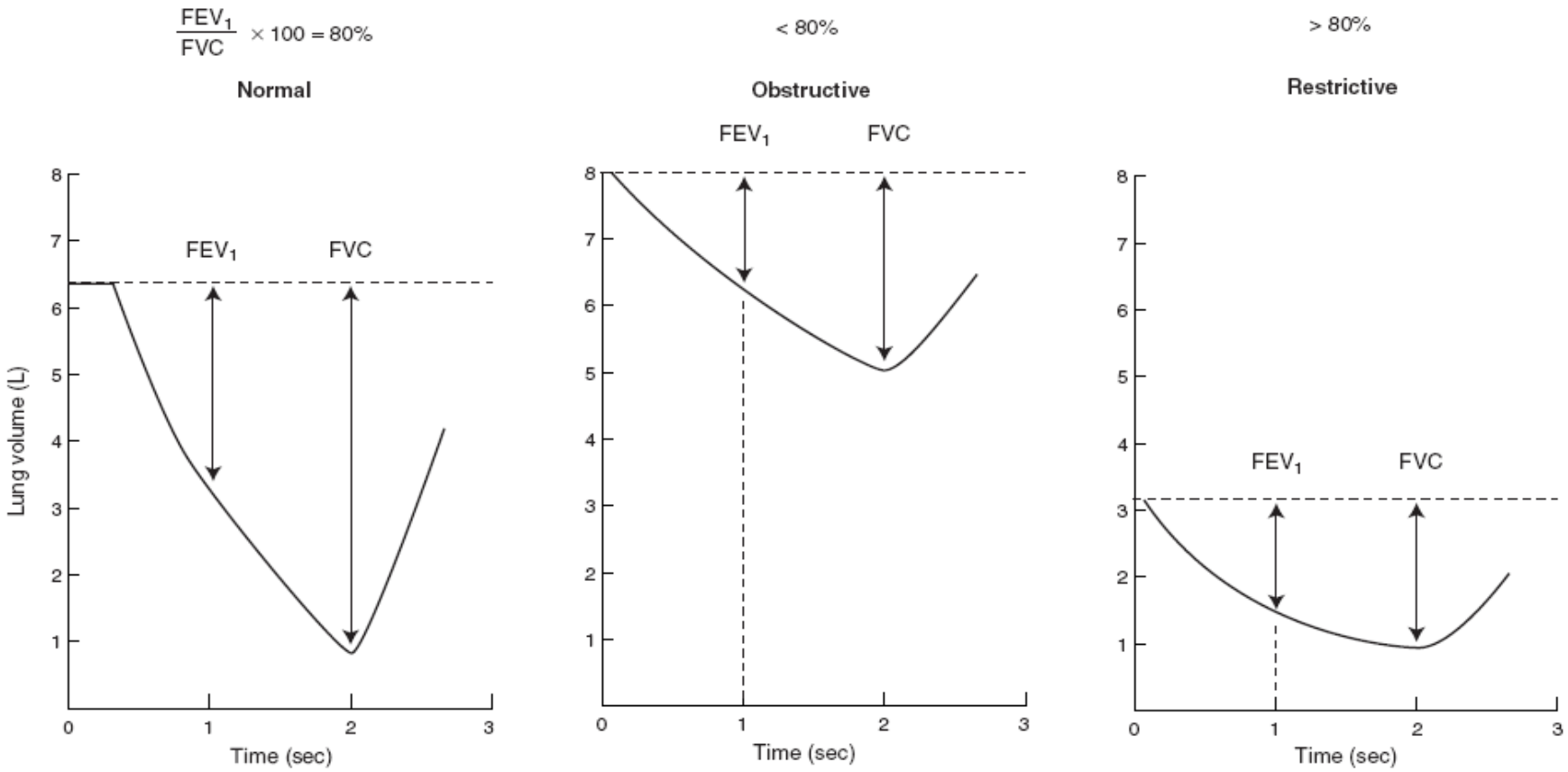

Note: Obstructive lung volumes > normal (↑ TLC, ↑ FRC, ↑ RV); restrictive lung volumes < normal. In both obstructive and restrictive, FEV_1 and FVC are reduced, but in obstructive, FEV_1 is more dramatically reduced, resulting in a ↓ FEV_1/FVC ratio.

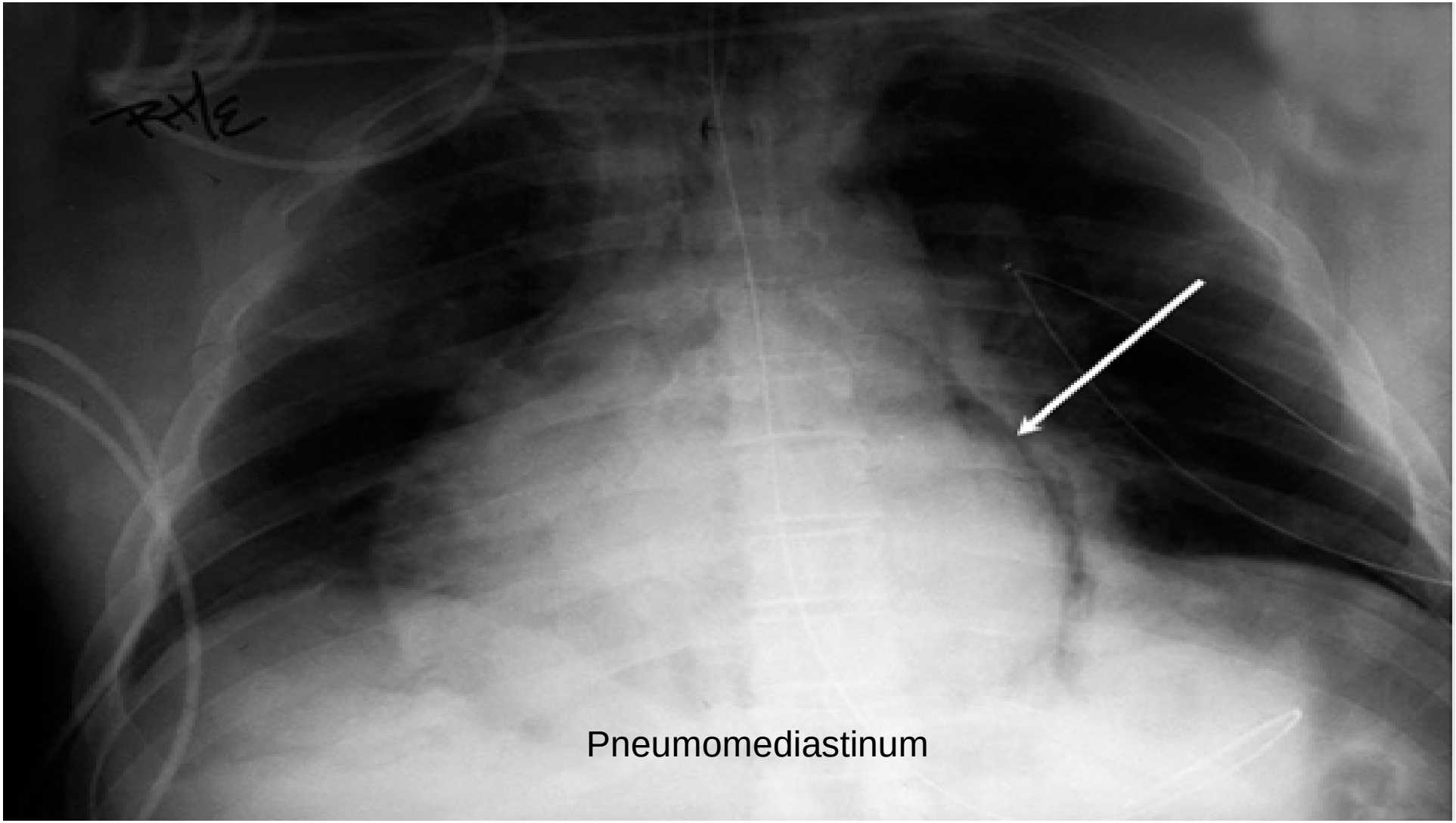
Pneumomediastinum

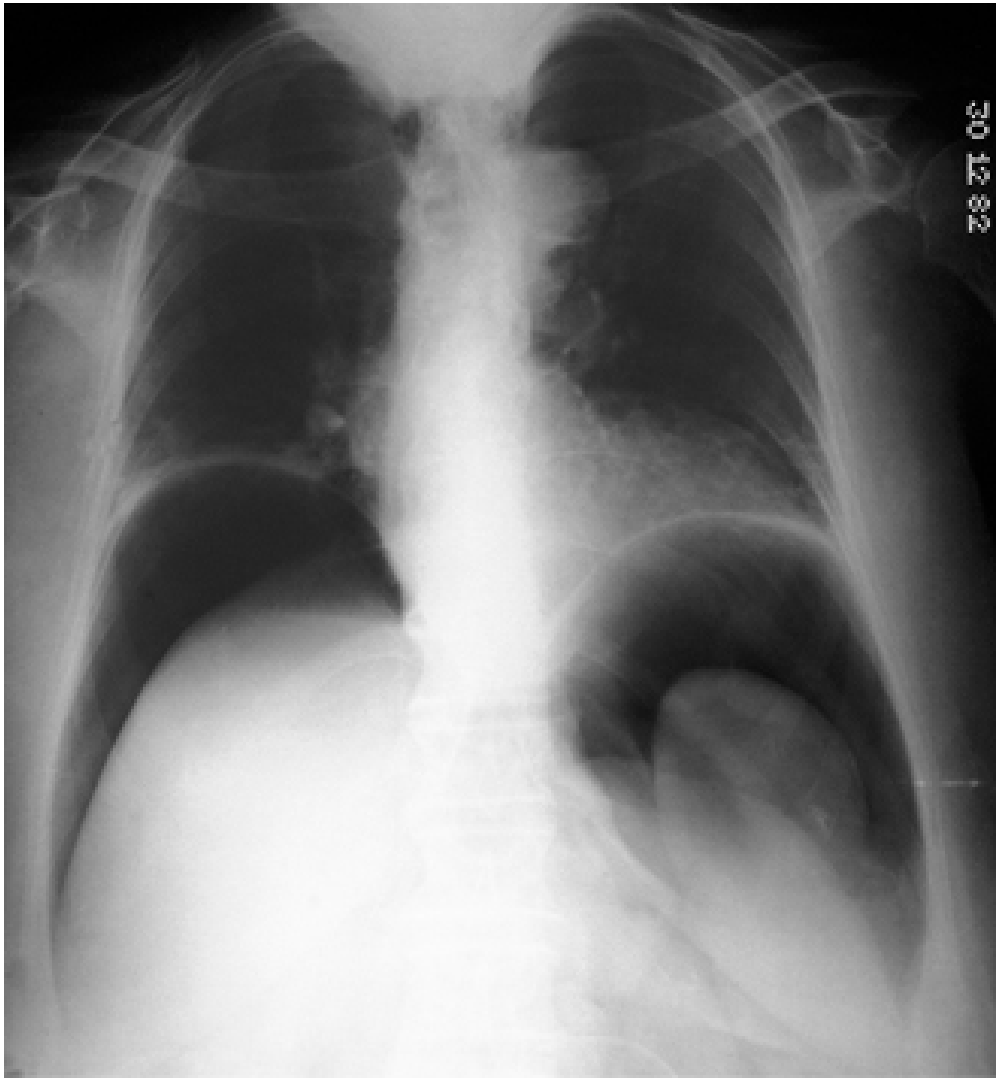

pneumoperitoneum showing the outline of the liver and spleen.

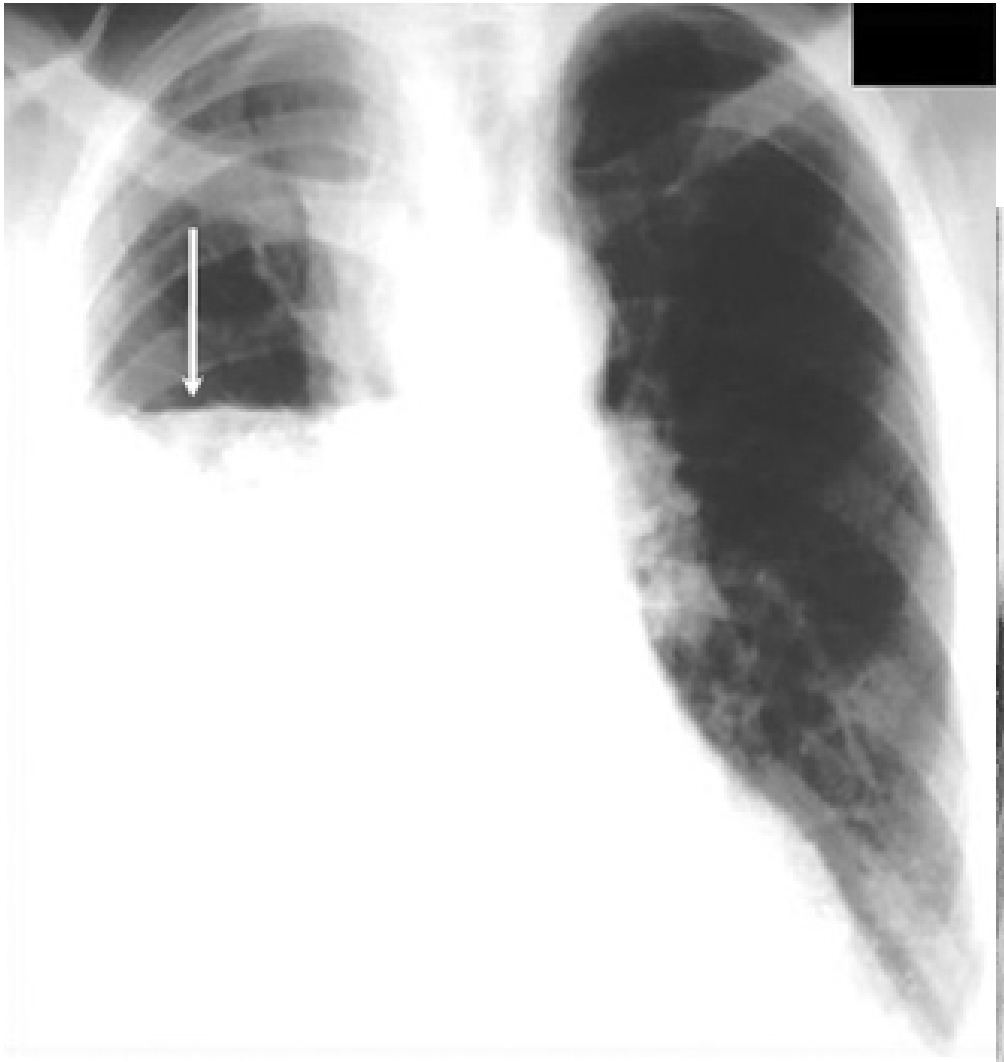

hydropneumothorax refers to the presence of both air and fluid within the pleural space

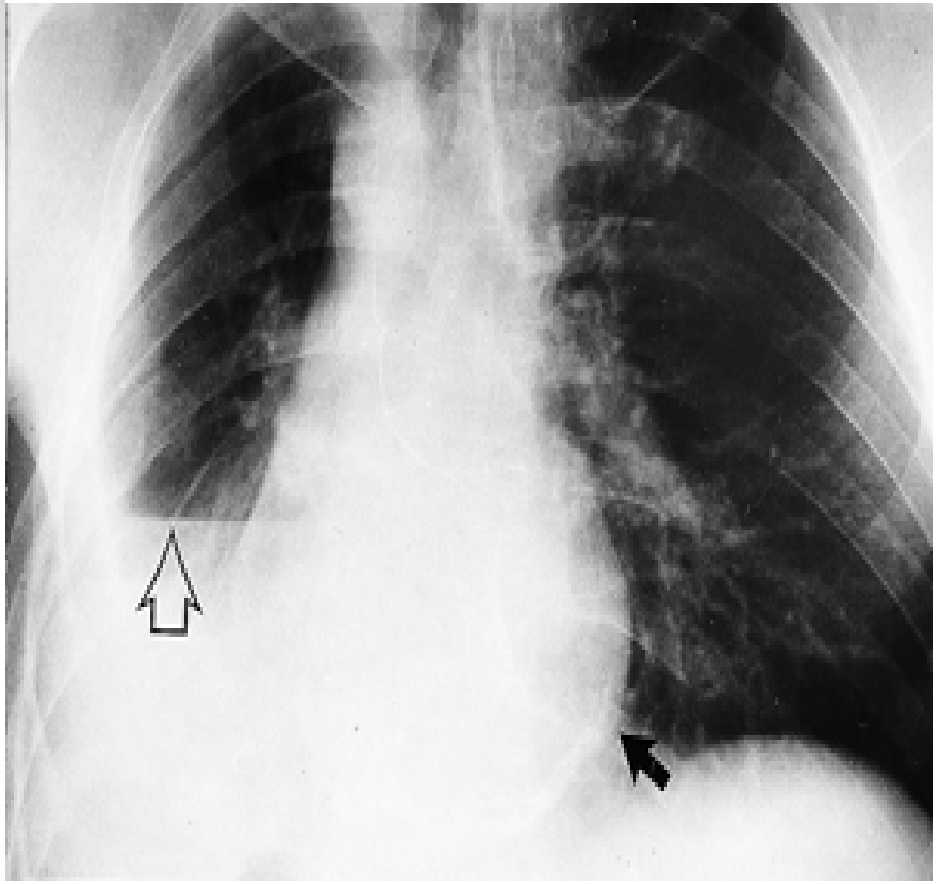

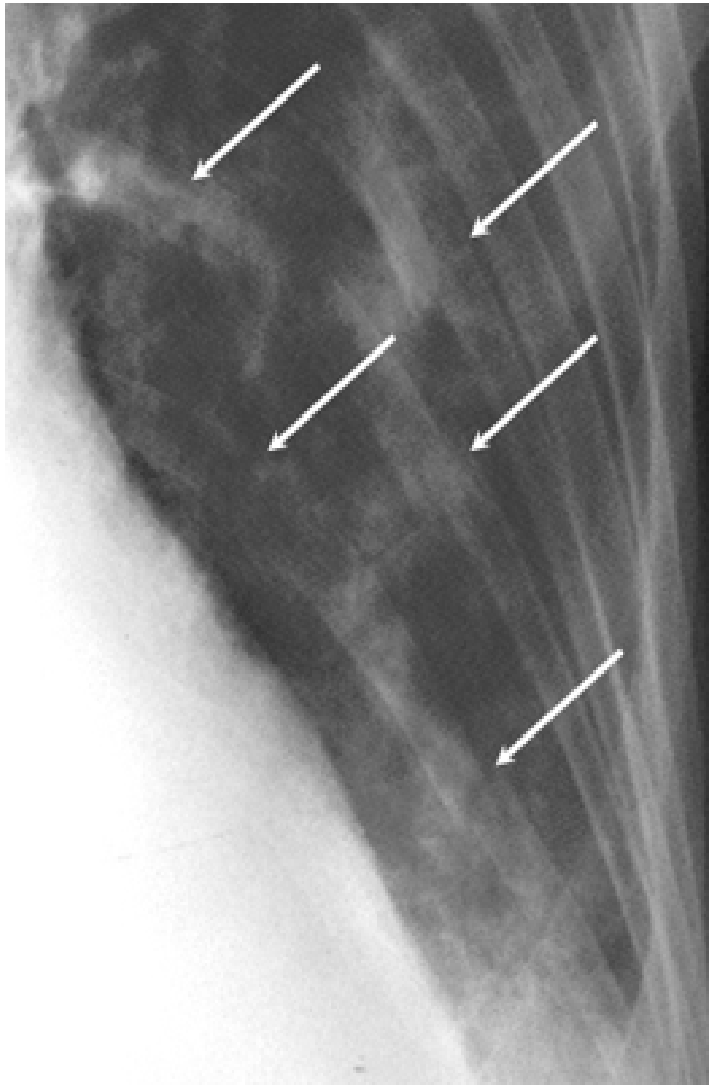

Flail chest is the paradoxical movement of a segment of chest wall caused by the fracture of at least 3 ribs broken in 2 or more places. During inspiration, the affected segment retracts, responding to the negative intrathoracic pressure that develops. It is most commonly found after significant blunt trauma to the thorax. On chest radiographs, rib fractures may be very difficult to assess and require multiple oblique views and close attention to detail. The image shown is a magnified view of a chest radiograph depicting a flail chest with rib fractures denoted by arrows. If fractures are suspected but cannot be confirmed with chest radiographs, then a computed tomography scan may be needed.

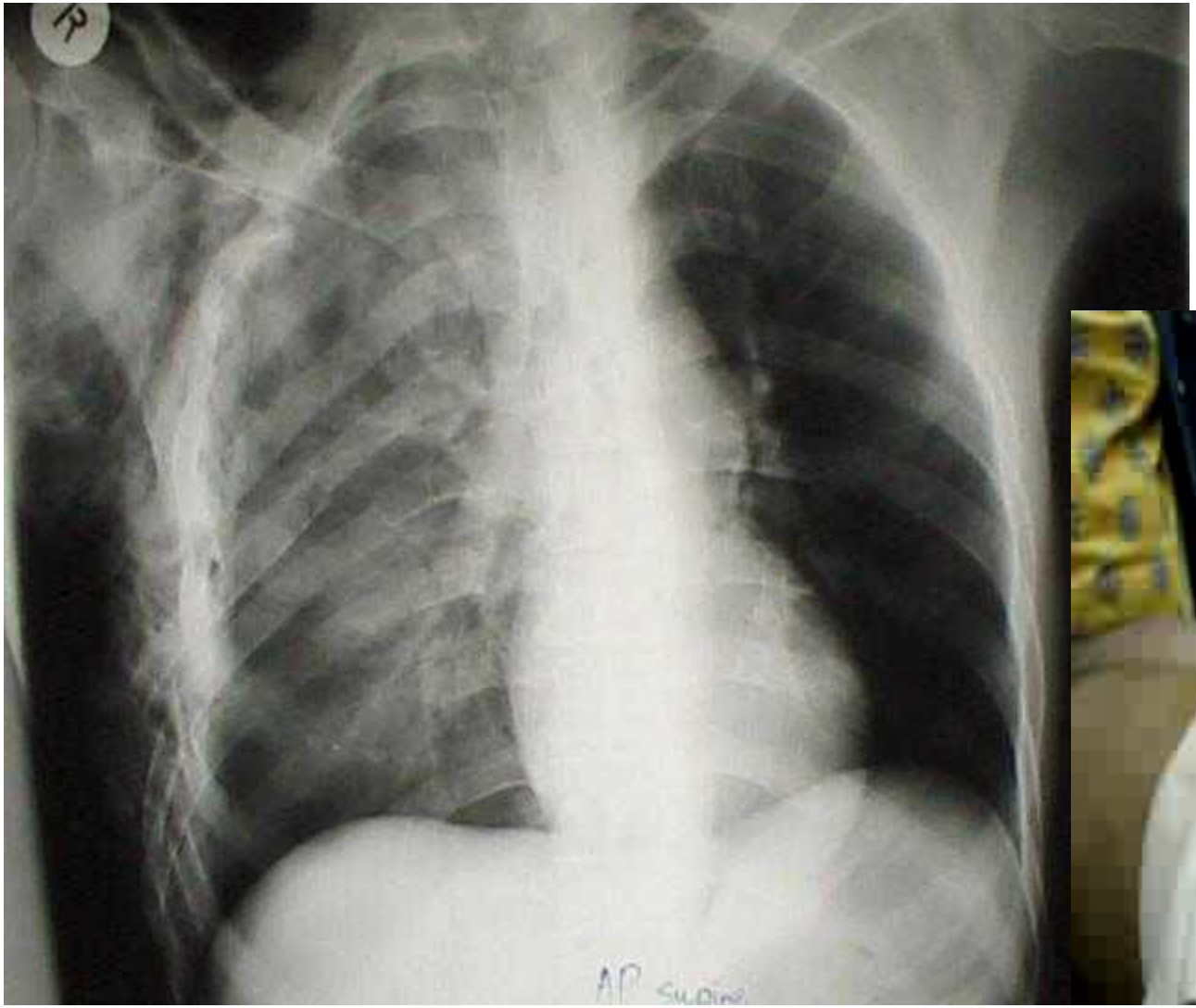

Flail chest

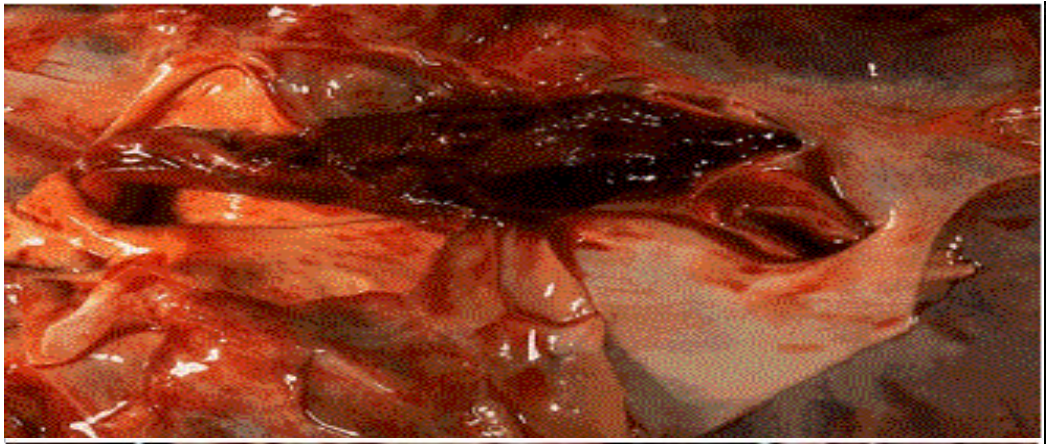

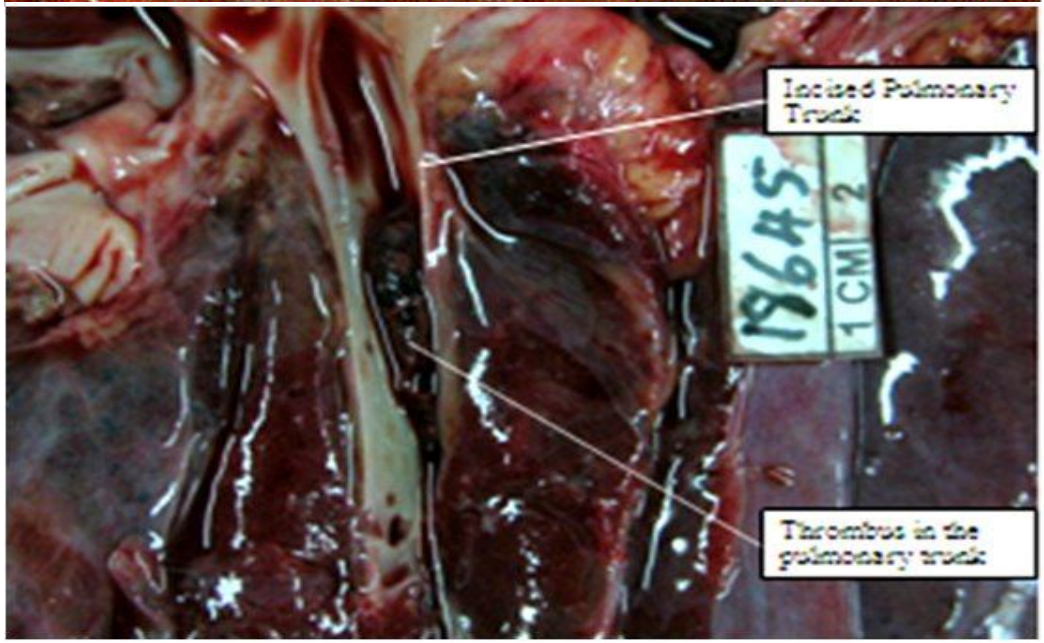
Incised Pulmonary Trunk
18645
1 CM 2
Thrombus in the pulmonary trunk

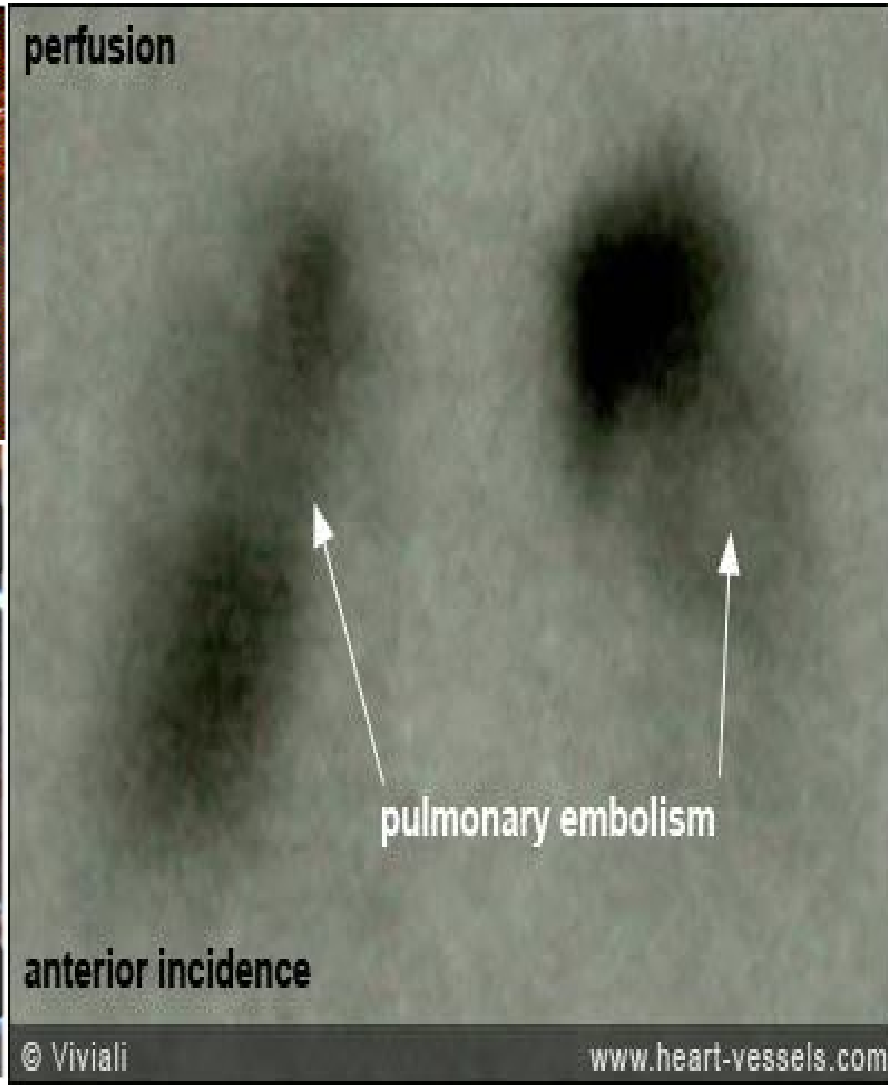
perfusion
pulmonary embolism
anterior incidence
© Viviali
www.heart-vessels.com

Presents with sudden-onset dyspnea, **pleuritic chest pain, low-grade fever,** cough, and hemoptysis (rarely).

- **Pulmonary embolism:**
- Hypoxia and hypocarbia with resulting respiratory alkalosis.
- Tachypnea, tachycardia, fever.
- Loud P2; prominent jugular a waves with right heart failure.
- **Venous thrombosis:** Unilateral swelling; Homans' sign (calf pain on forced dorsiflexion); cords on the calf.

DIAGNOSIS

- **ABG: Respiratory alkalosis** (due to hyperventilation) with PO2 < 80 mmHg.
- **CXR:** Usually normal, but may show atelectasis, pleural effusion, **Hampton's hump** (a wedge-shaped infarct), or **Westermark's sign** (oligemia in the embolized lung zone=reduced circulating intravascular volume).
- **ECG:** Not diagnostic; most commonly reveals **sinus tachycardia.** The classic triad of **S1Q3T3**—acute right heart strain with an S wave in lead I, a Q wave in lead III, and an inverted T wave in lead III—is uncommon.
- **V/Q scan:** May reveal segmental areas of mismatch. Results are reported with a designated probability of pulmonary embolism (low, indeterminate, high) and are interpreted on the basis of clinical suspicion.
- **Helical (spiral) CT with IV contrast:** Sensitive for pulmonary embolism in the proximal pulmonary arteries, but less so in the distal segmental arteries.
- **Angiogram:** Gold standard, but more invasive and rarely done


11.08.1979
DONG
M: 3/54
I: 21/54
LNDMK:
Scene: 1
W-B: 476
W-C: 34
X: 0.0
Y: 0.0

TABLE 2.15-5. Paraneoplastic Syndromes of Lung Cancer

Classification	Syndrome	Histologic Type
Endocrine/metabolic	Cushing's syndrome	Small cell
	SIADH	Small cell
	Hypercalcemia	Squamous cell
	Gynecomastia	Large cell
Connective tissue	Hypertrophic pulmonary osteoarthropathy	Non–small cell
Neuromuscular	Peripheral neuropathy	Small cell
	Subacute cerebellar degeneration	Small cell
	Myasthenia (Eaton-Lambert syndrome)	Small cell
	Dermatomyositis	All
Cardiovascular	Thrombophlebitis	Adenocarcinoma
	Nonbacterial verrucous endocarditis	Adenocarcinoma
Hematologic	Anemia	All
	DIC	All
	Eosinophilia	All
	Thrombocytosis	All
Cutaneous	Acanthosis nigricans	All
	Erythema gyratum repens	All

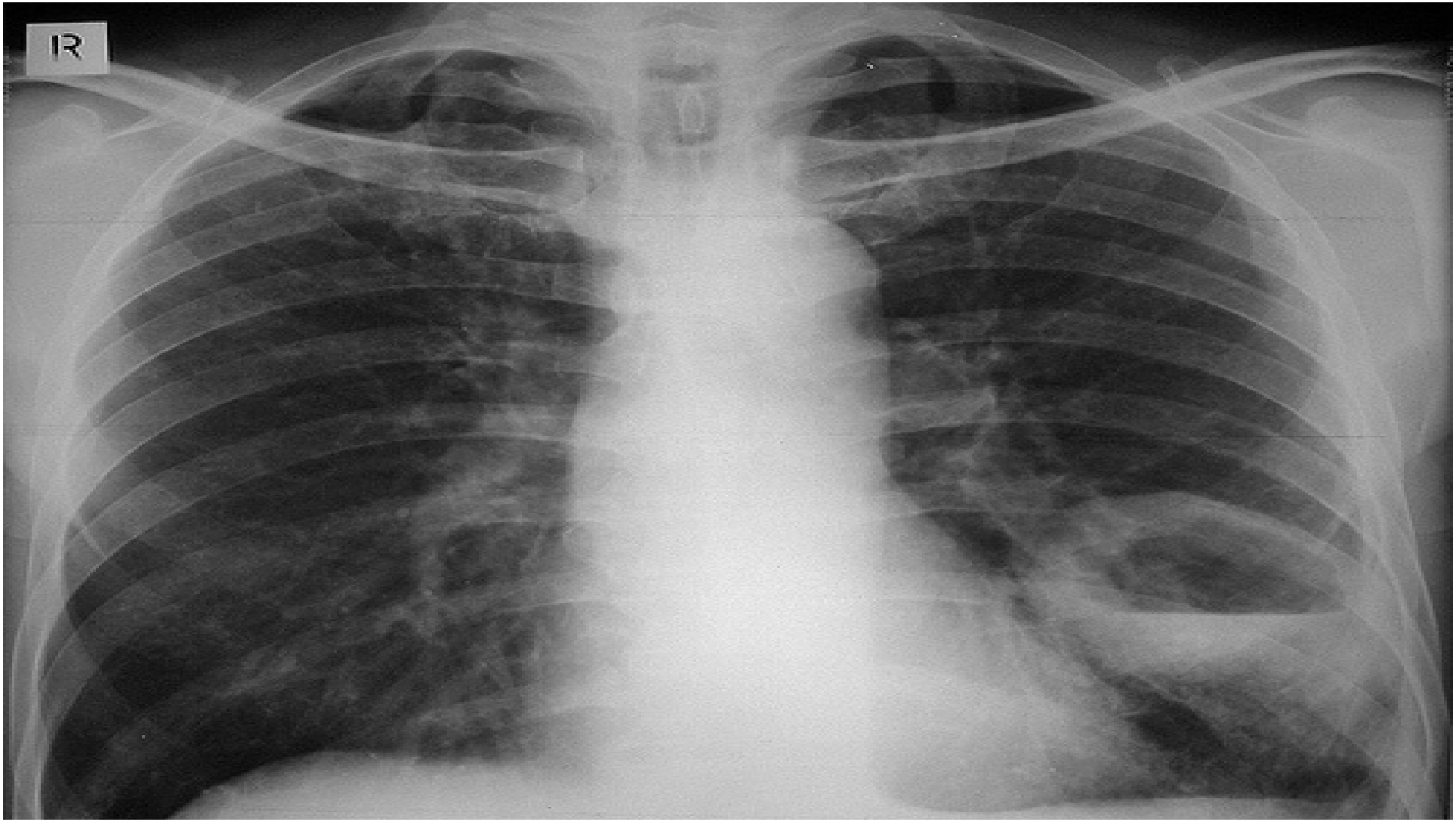
R

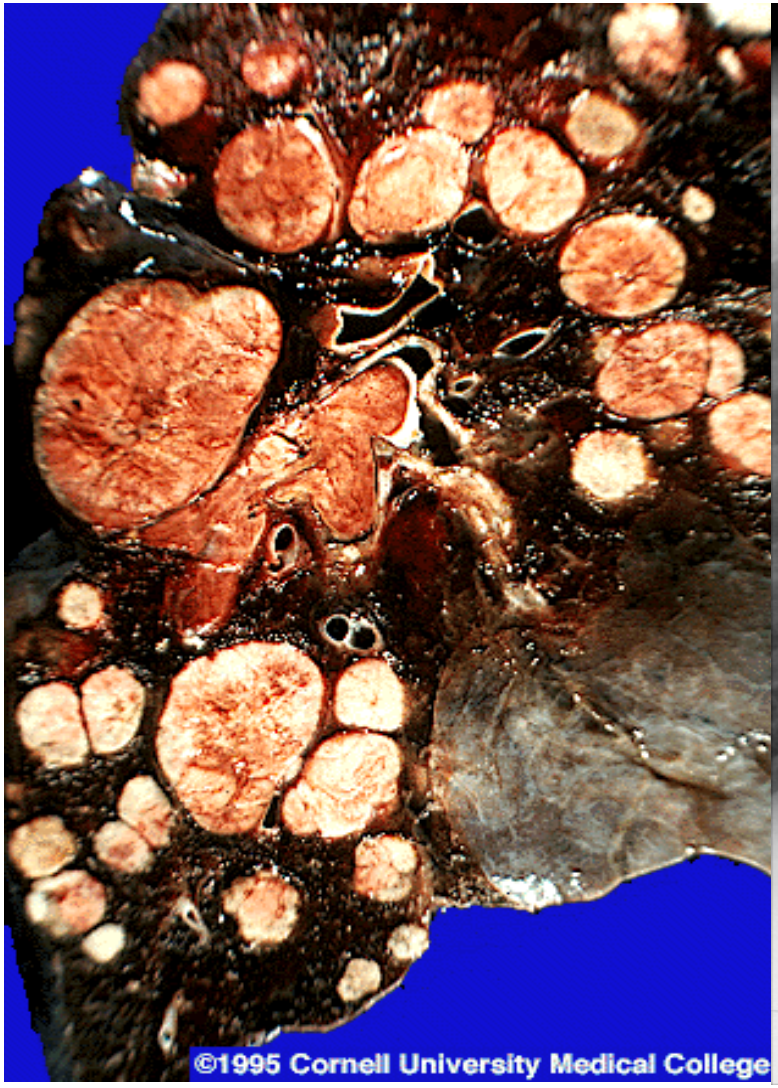
©1995 Cornell University Medical College

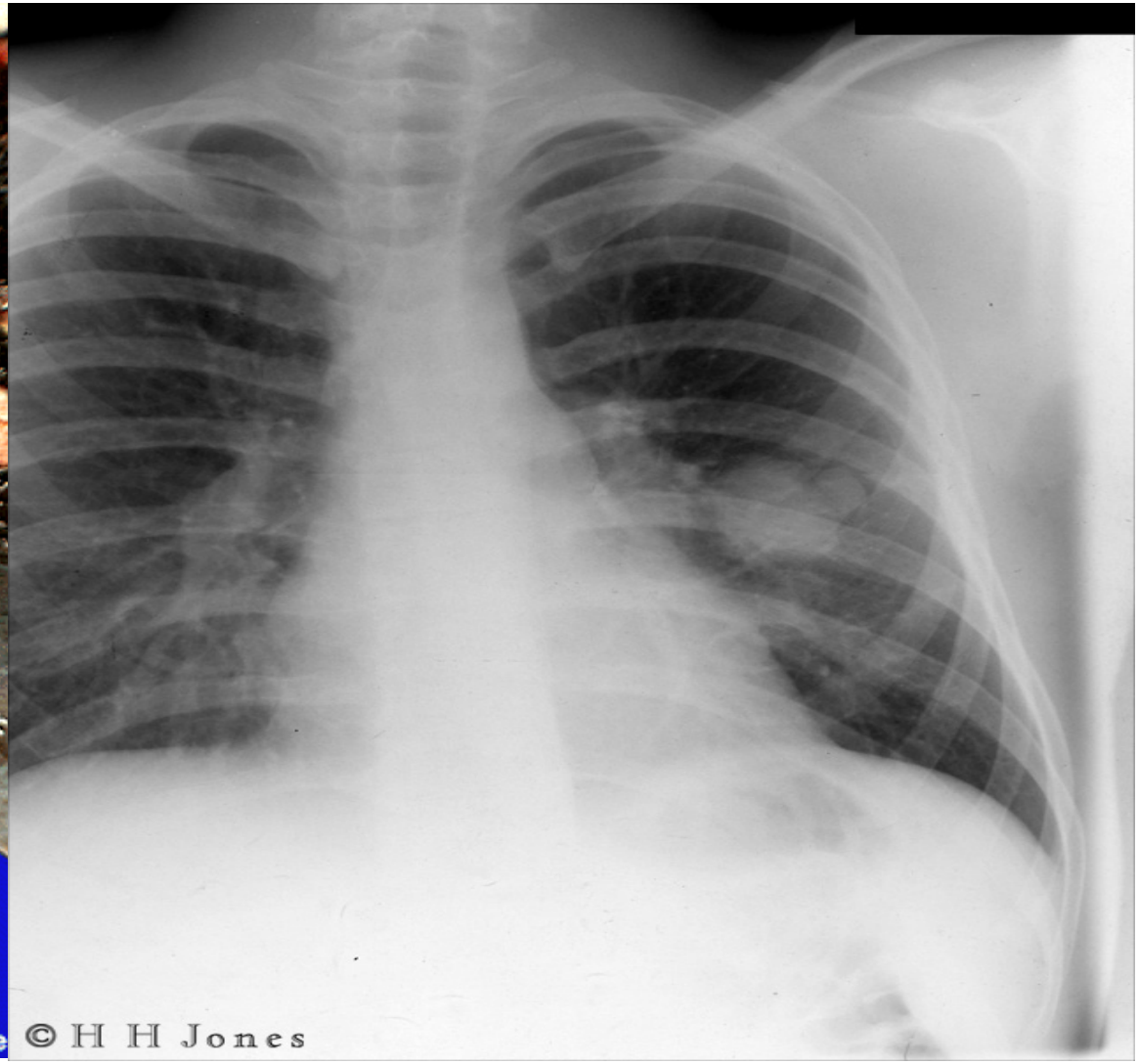
© H H Jones

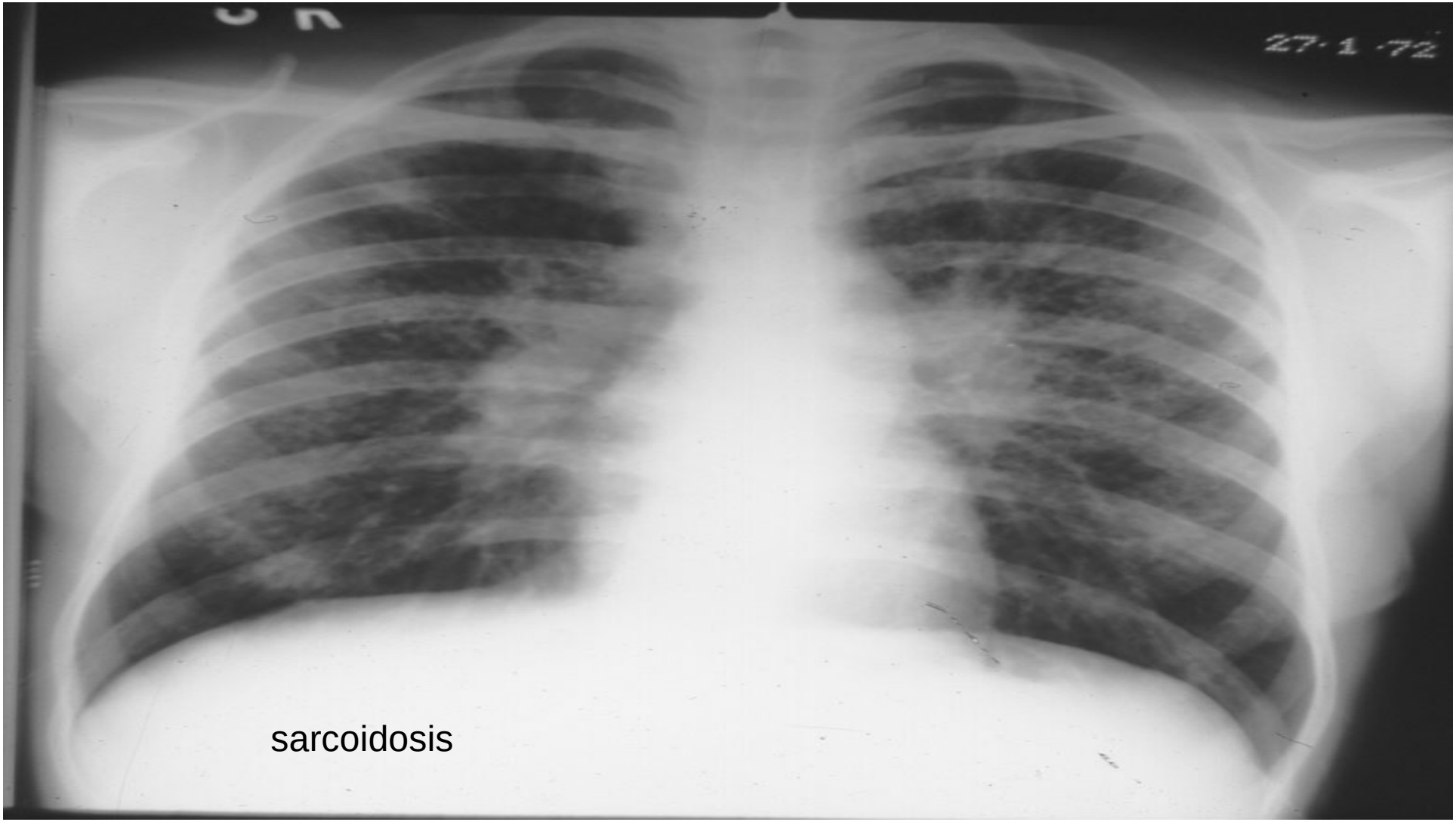

sarcoidosis

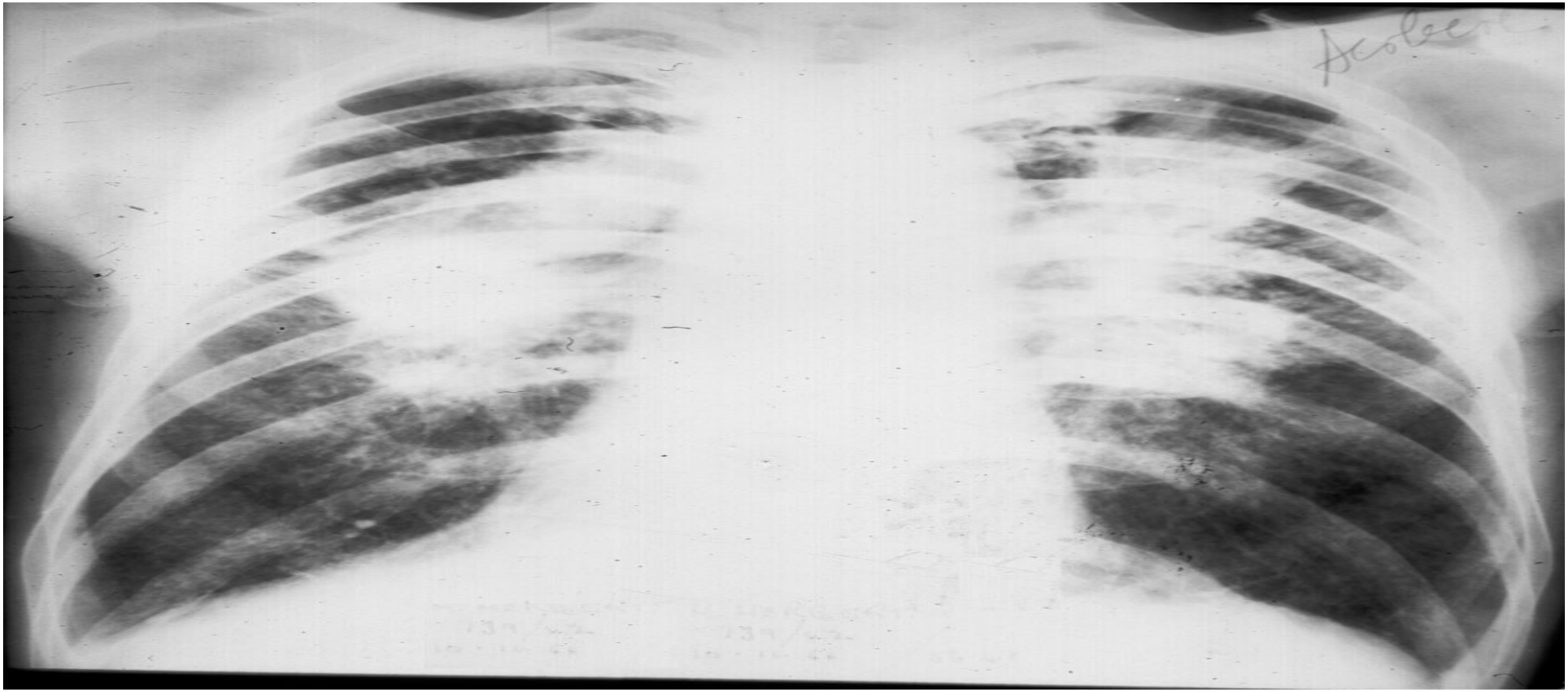

Clinical presentation:
58 year old male was a welsh coal miner from the age of 14 years.
He gave a history of increasing breathlessness.

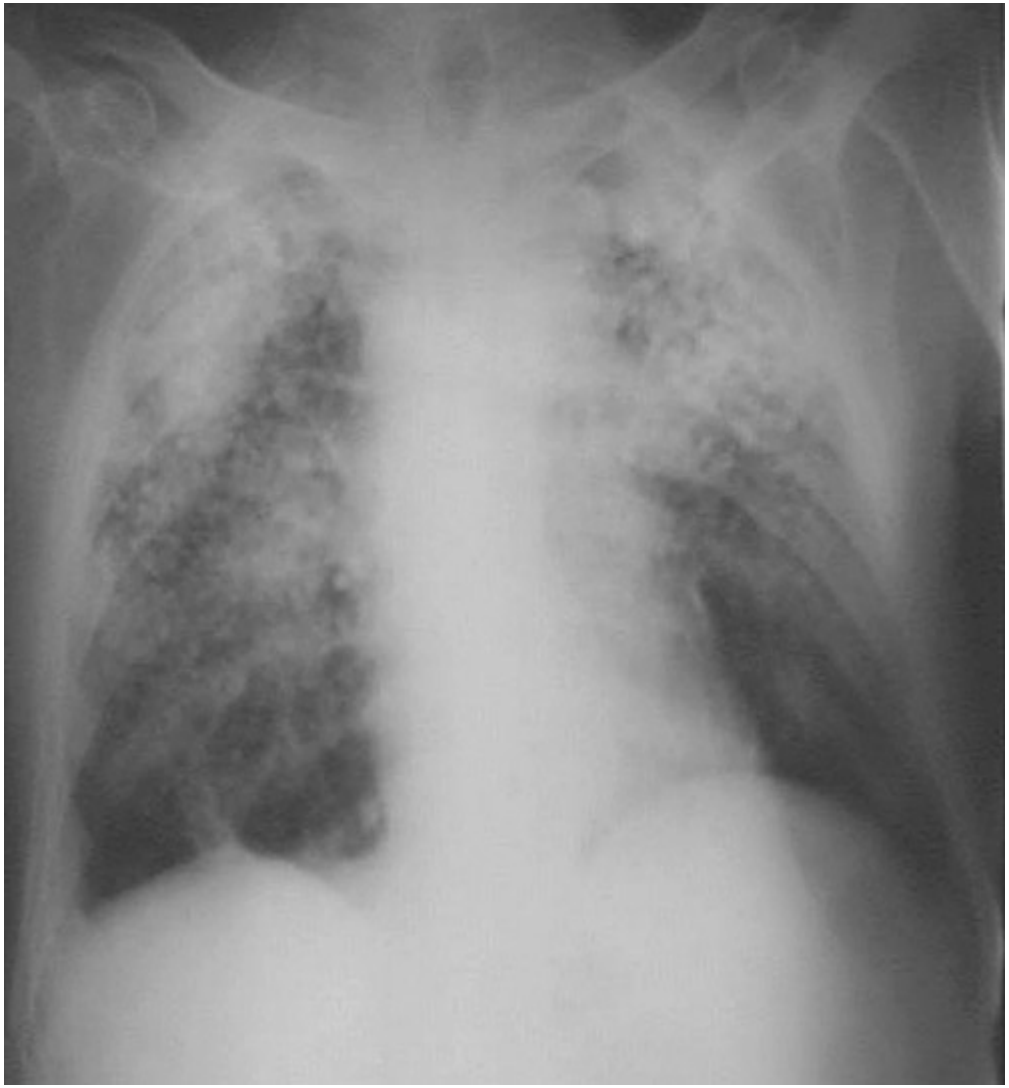

silicosis

Workers in many industries and occupations are at risk, including:

Construction, especially bridge, tunnel, and elevated highway
Wrecking and demolition
Concrete work
Surface mining and quarrying
Underground mining
Stone cutting
Milling stone
Agriculture
Foundry
Ceramics, clay, pottery
Vitreous enameling of china plumbing fixtures
Glass manufacturing
Manufacturing of concrete products and brick
Manufacturing of soaps and detergents
Shipyards, railroads
And much more

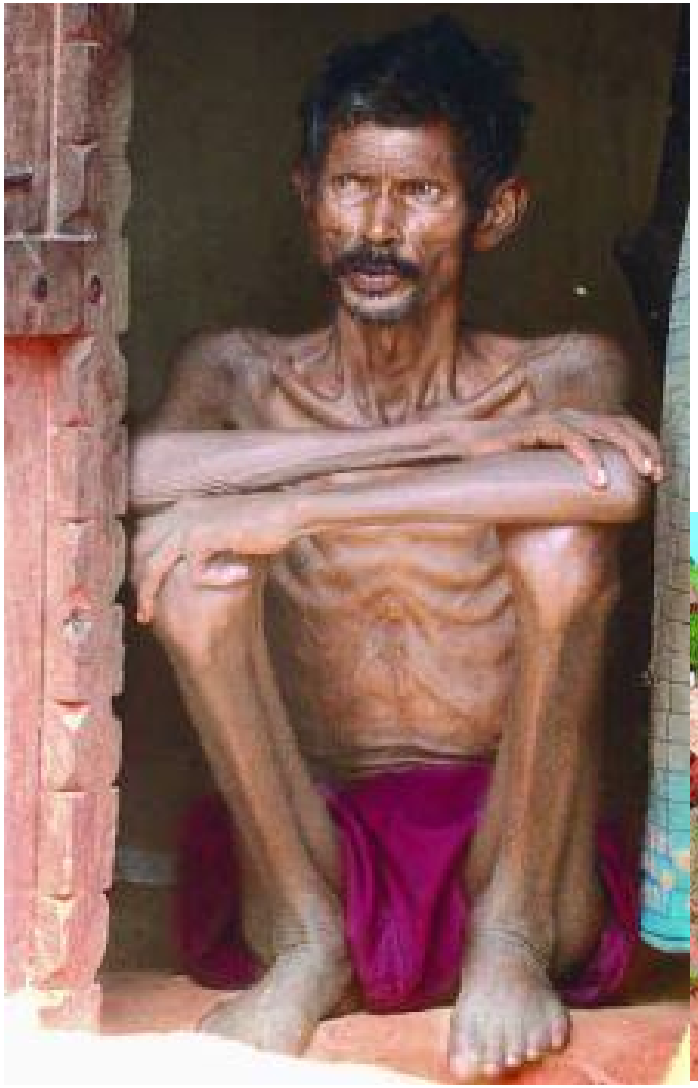

Most quarry workers suffering from silicosis do not even know what their disease is.

Asbestosis

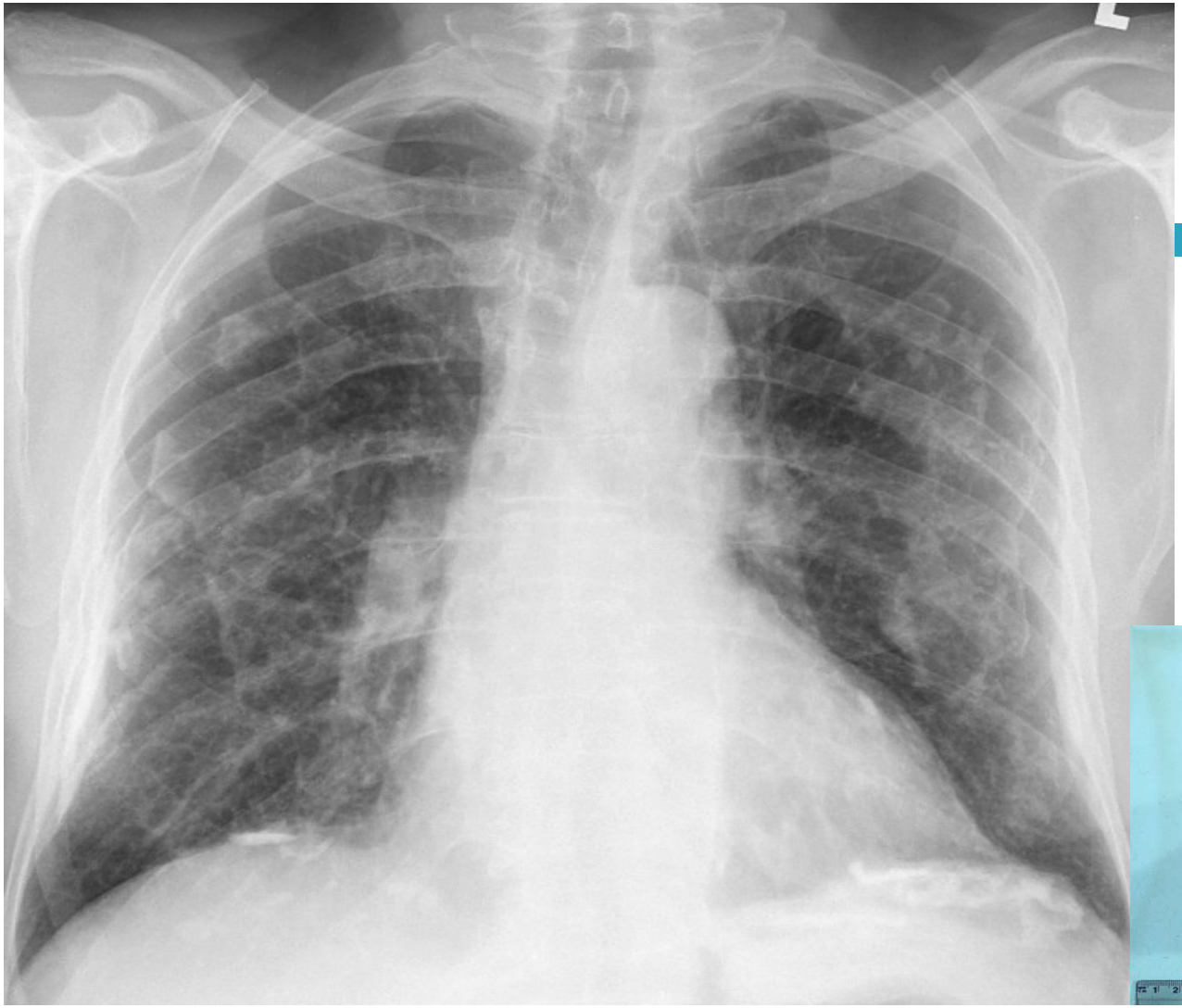

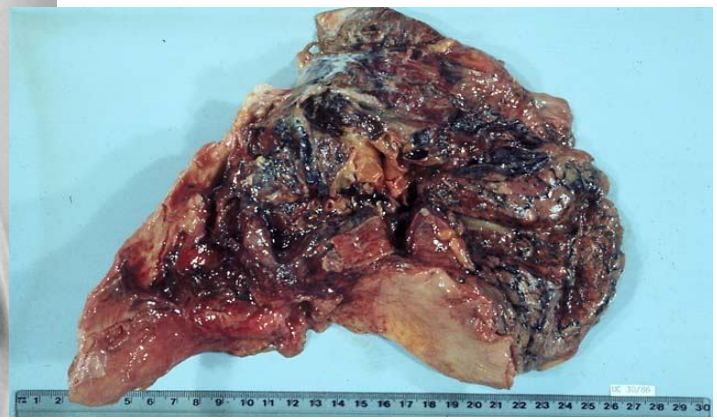

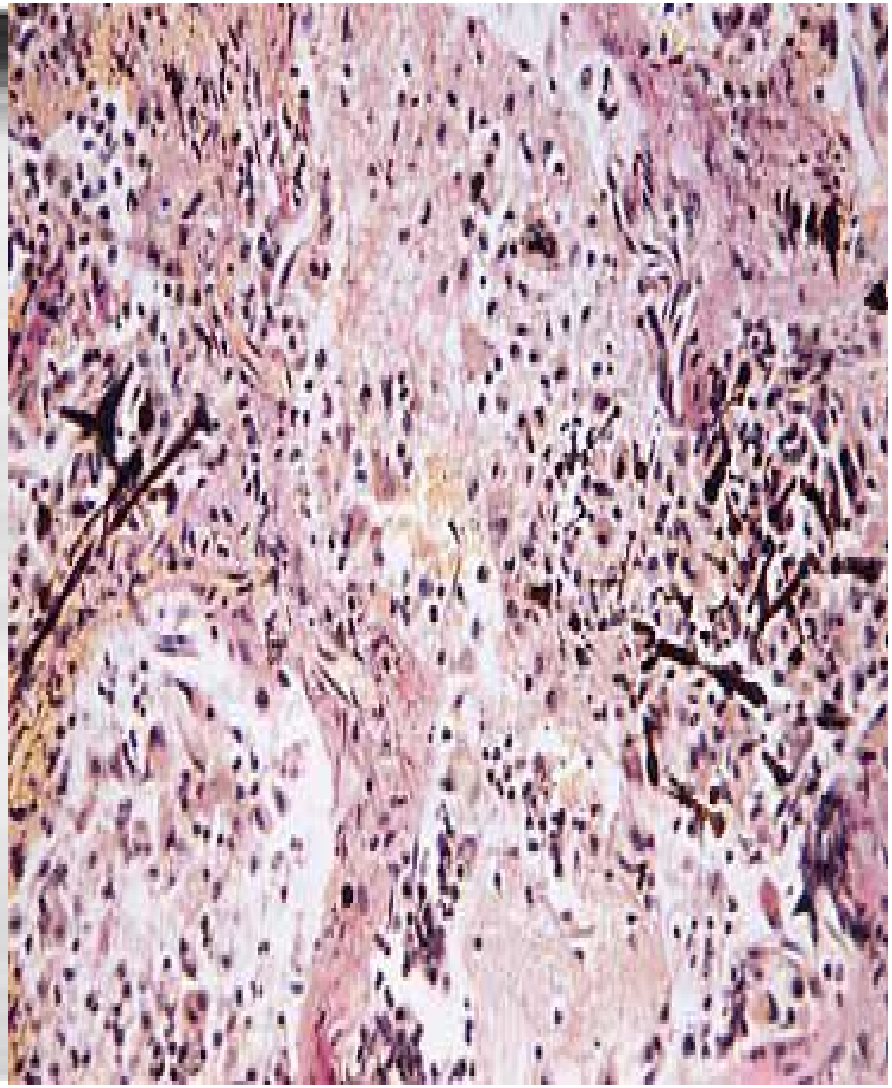

sarcoidosis

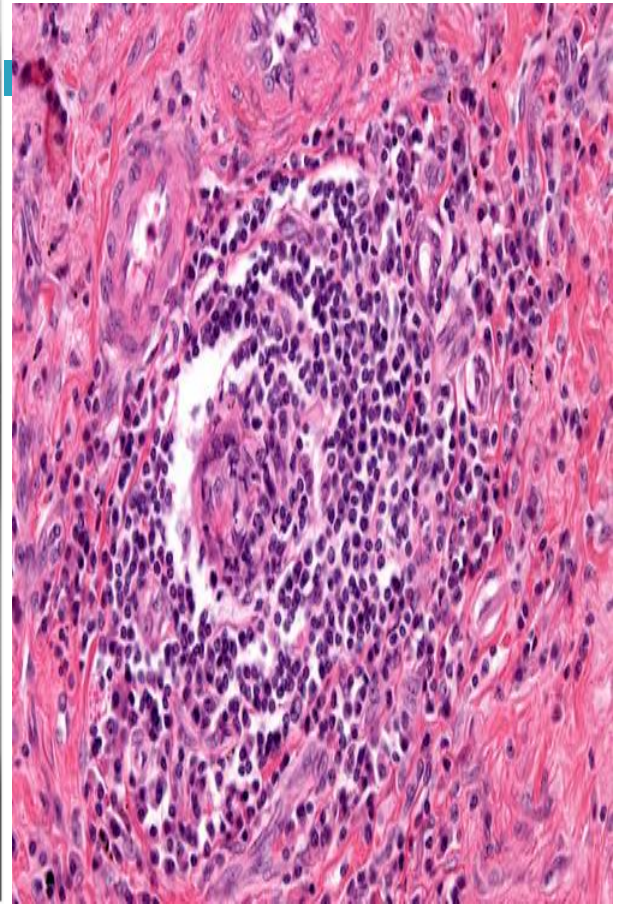

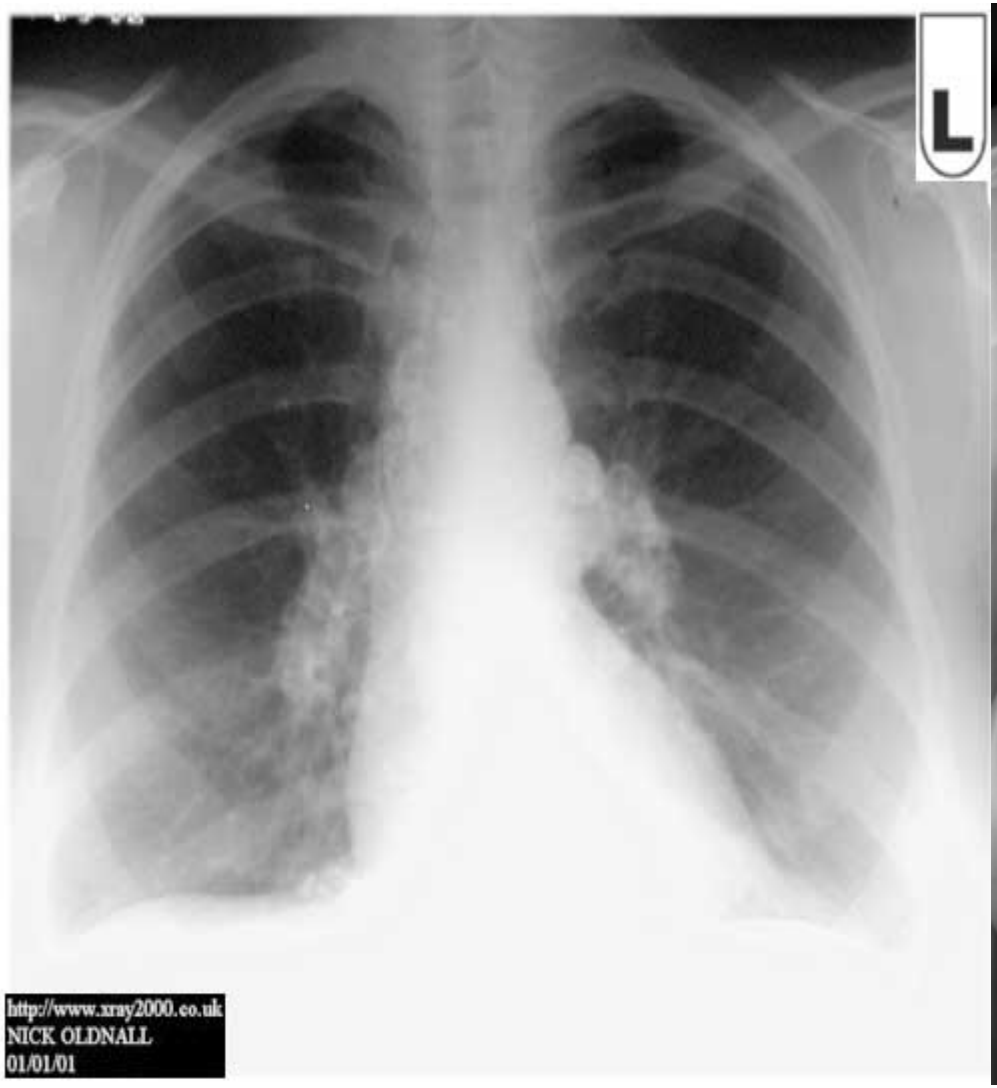
L
http://www.xray2000.co.uk
NICK OLDNALL
01/01/01

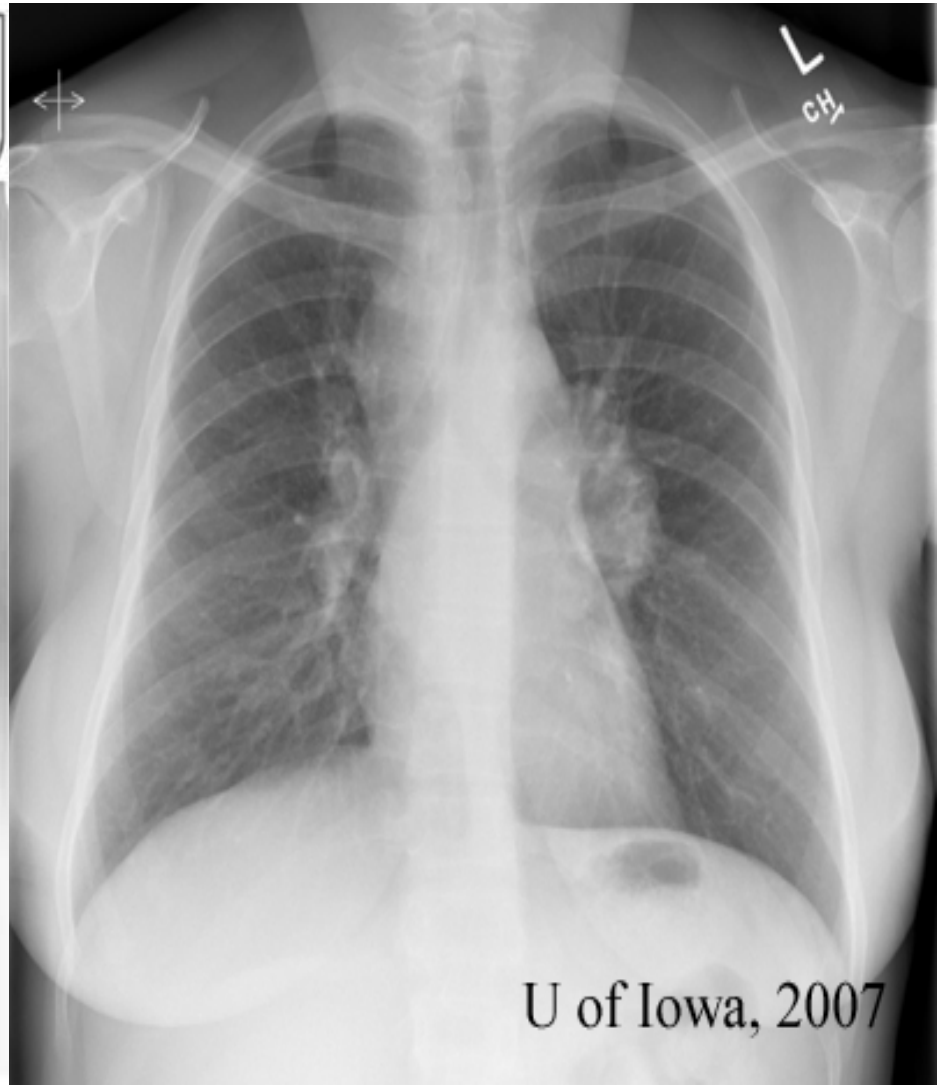
L
CH
U of Iowa, 2007

Bochdalek hernia


Miliary Tuberculosis

Ghon complex in lung,closer view,gross.

Cavitary tuberculosis in lung,



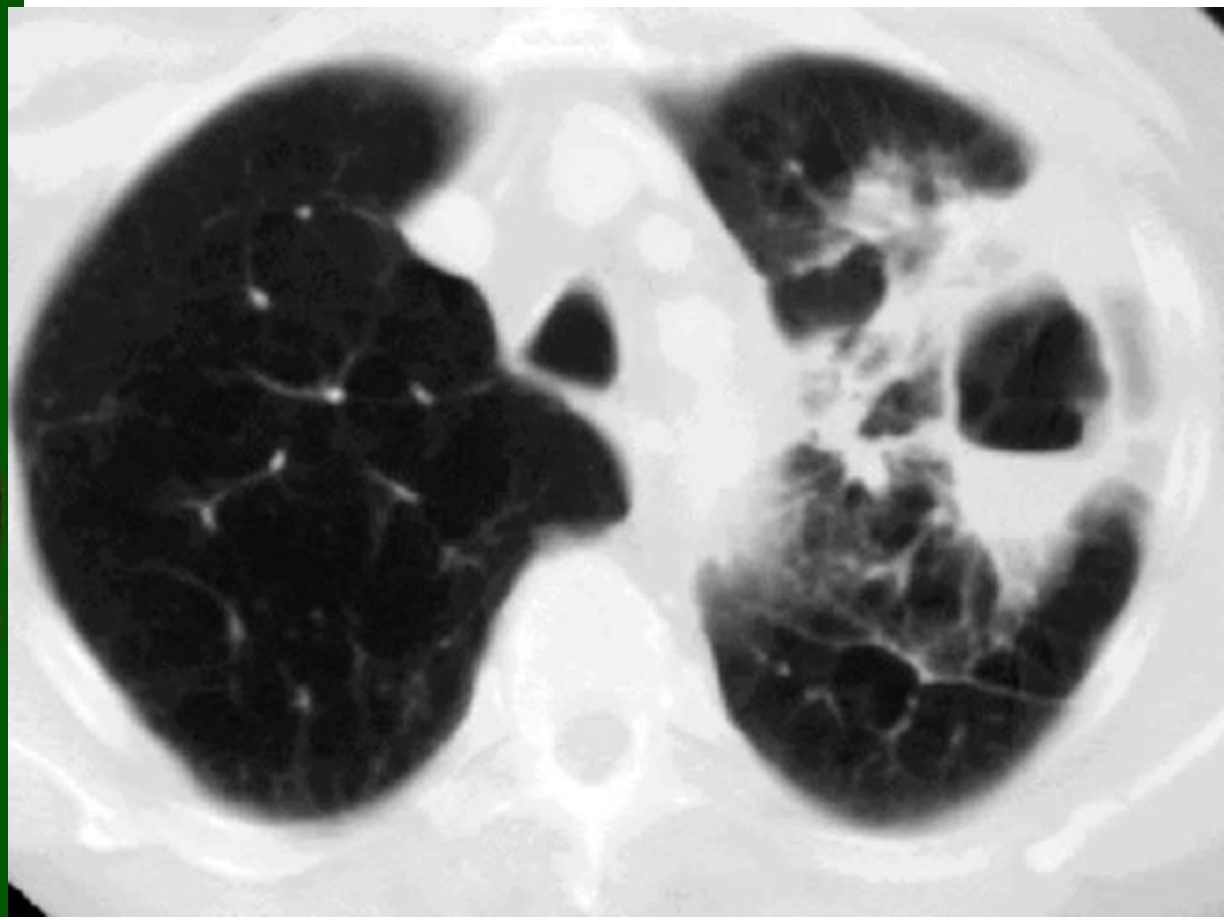

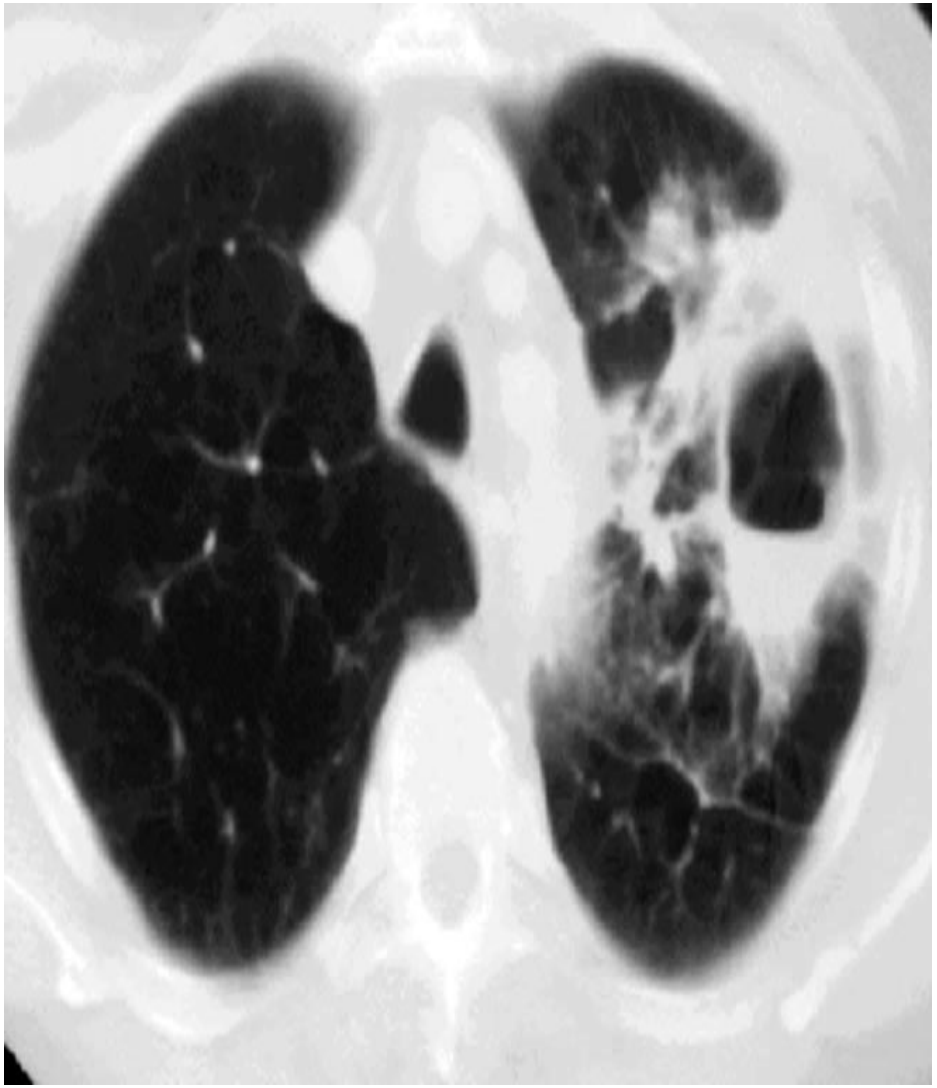

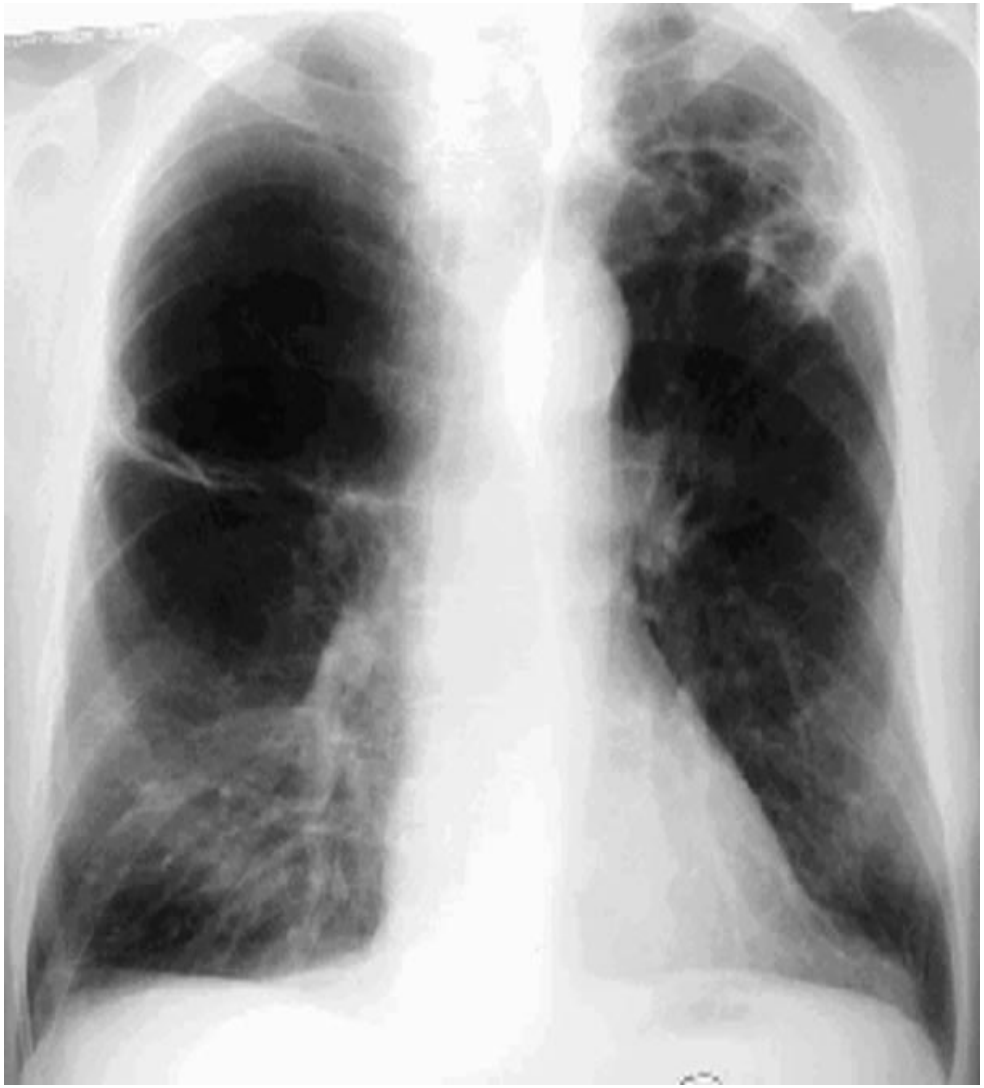

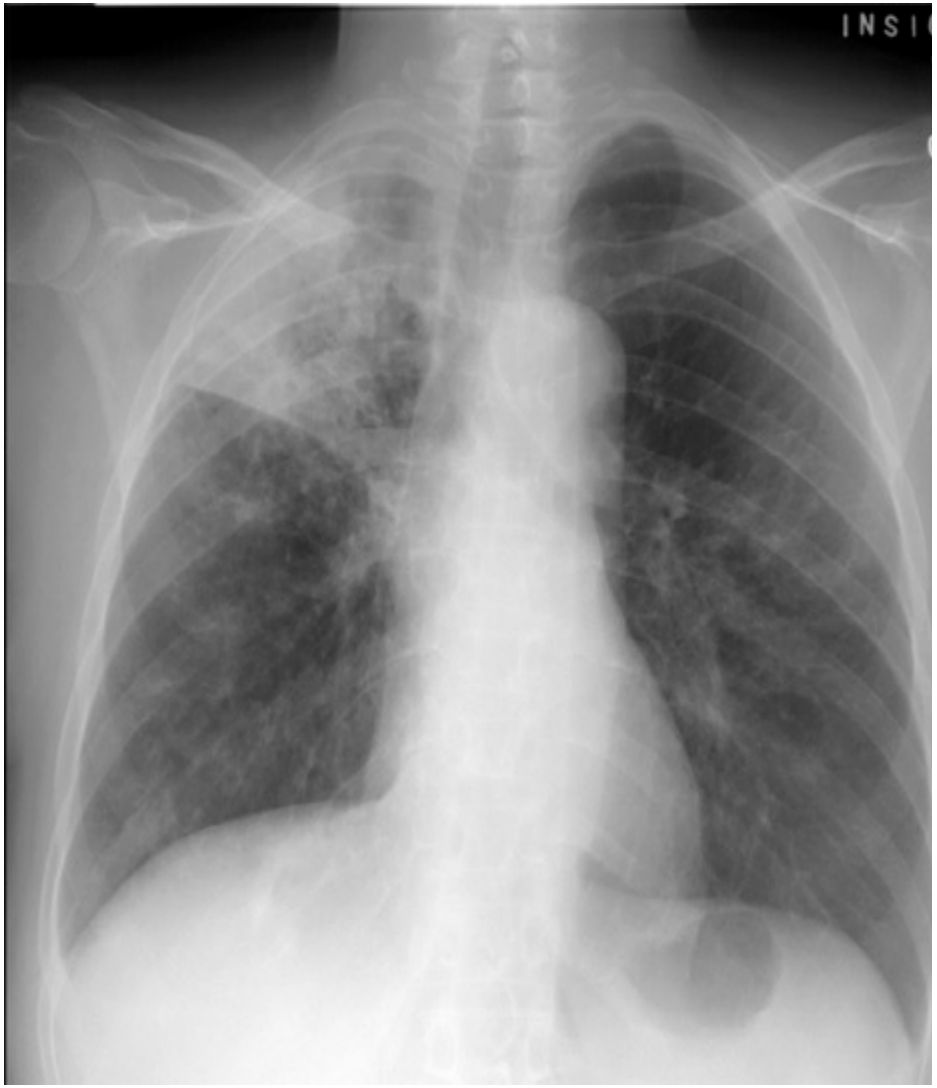

Fig. 286

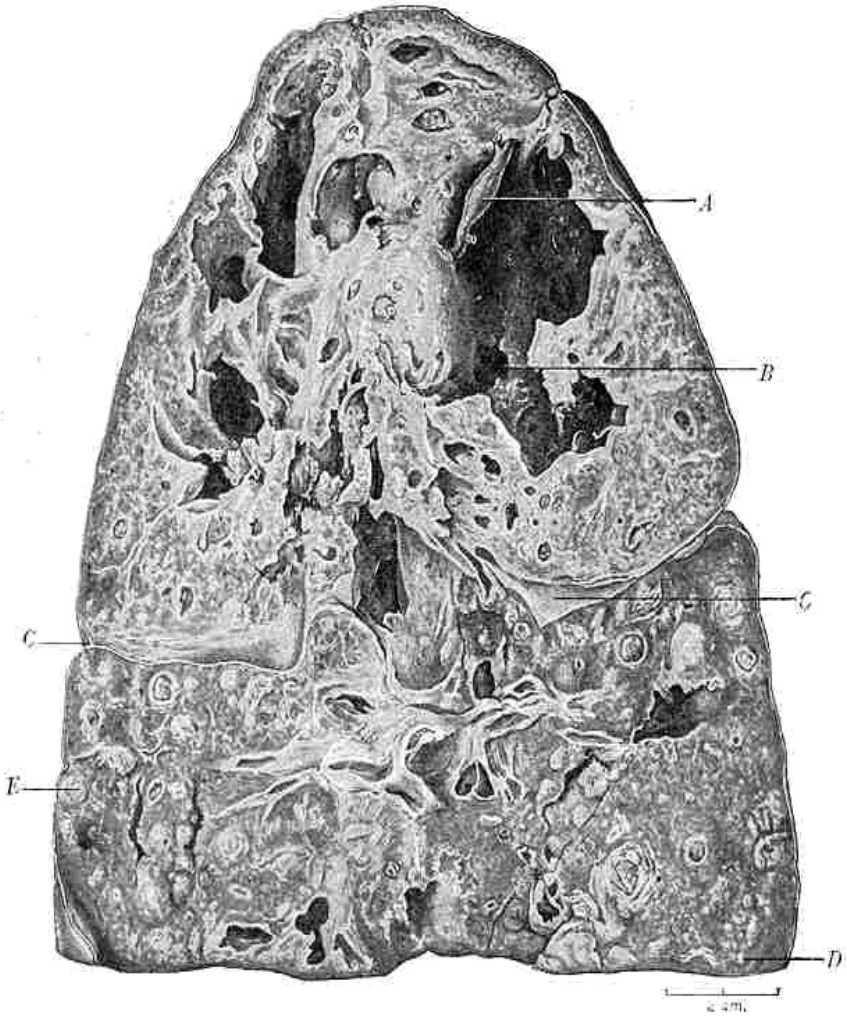

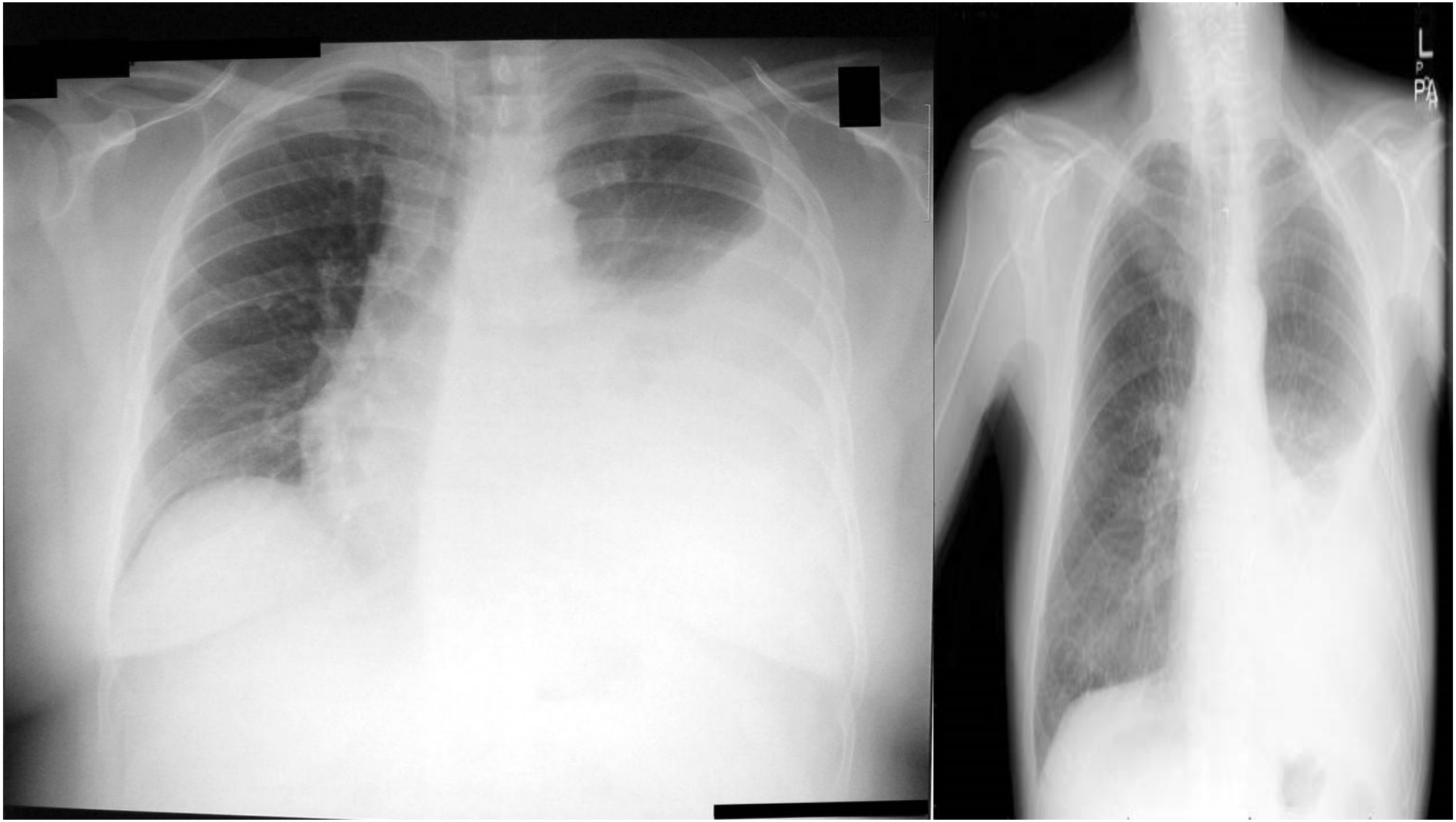
L
P
PA

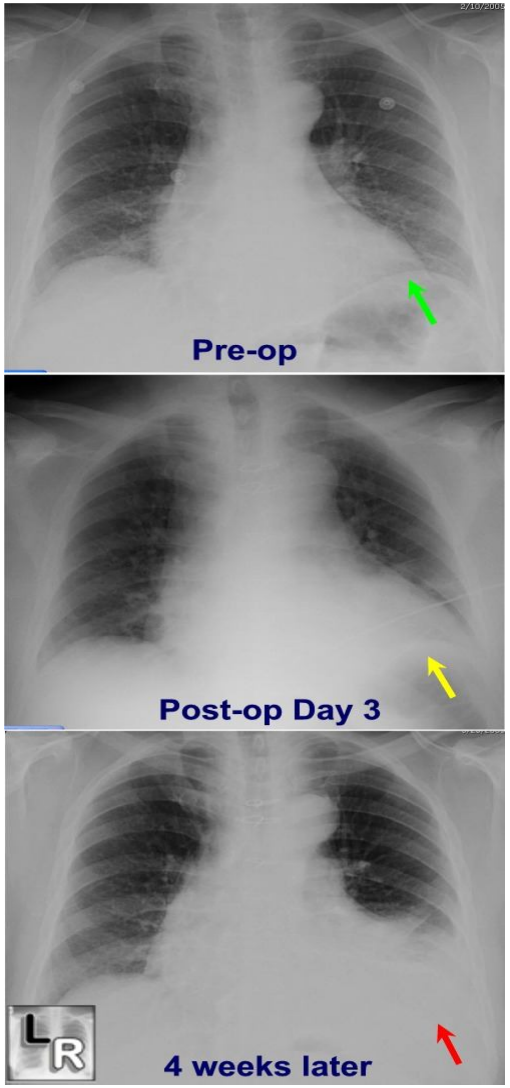

Dressler's Syndrome
Postmyocardial Infarction Syndrome/Postcardiotomy Syndrome

- Pleural effusions (83%)
- Parenchymal opacities (74%)
- Enlarged cardiac silhouette from pericardial effusion


N
cm
1
2
3
SPEC. 25927
DATE

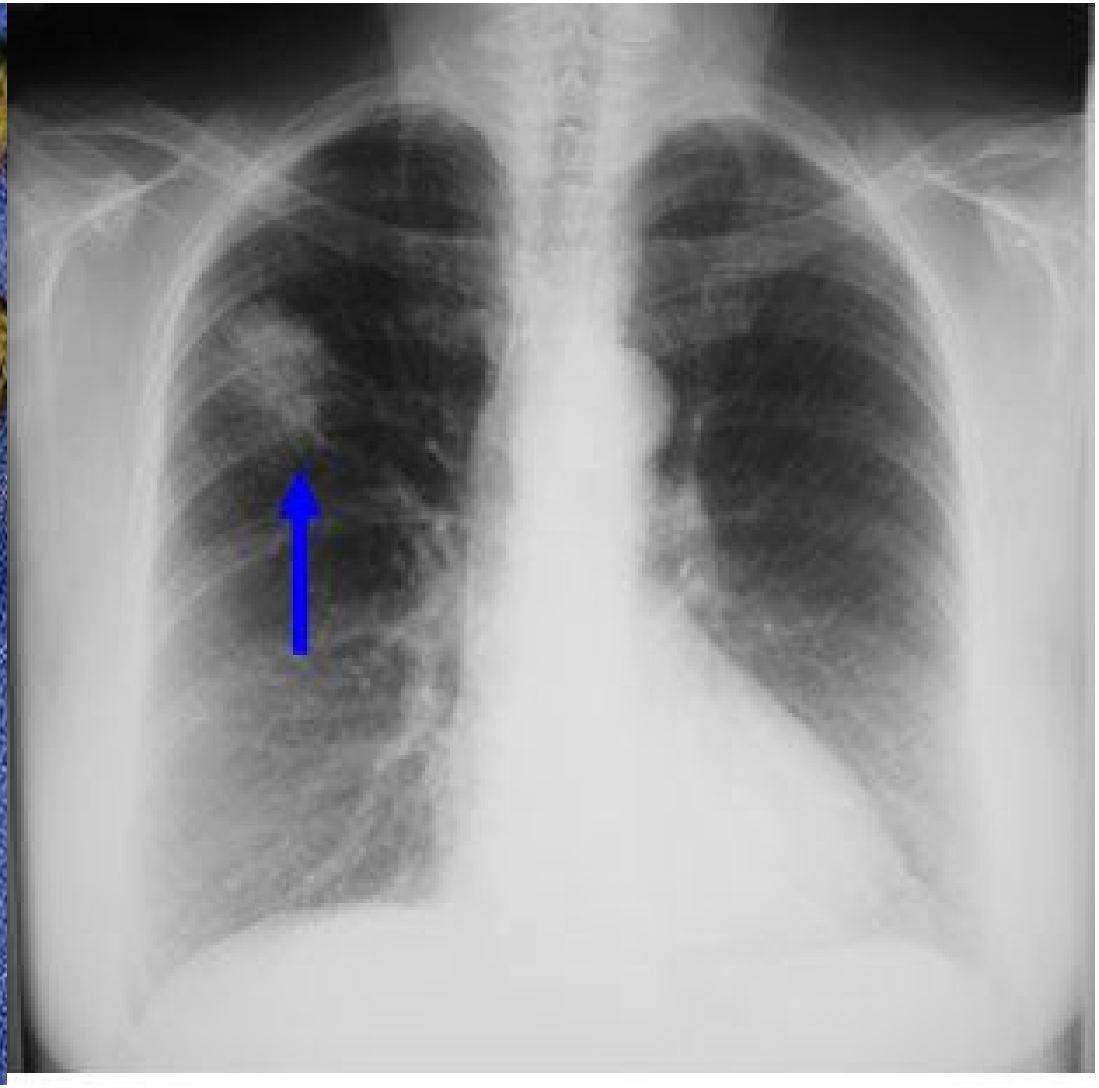

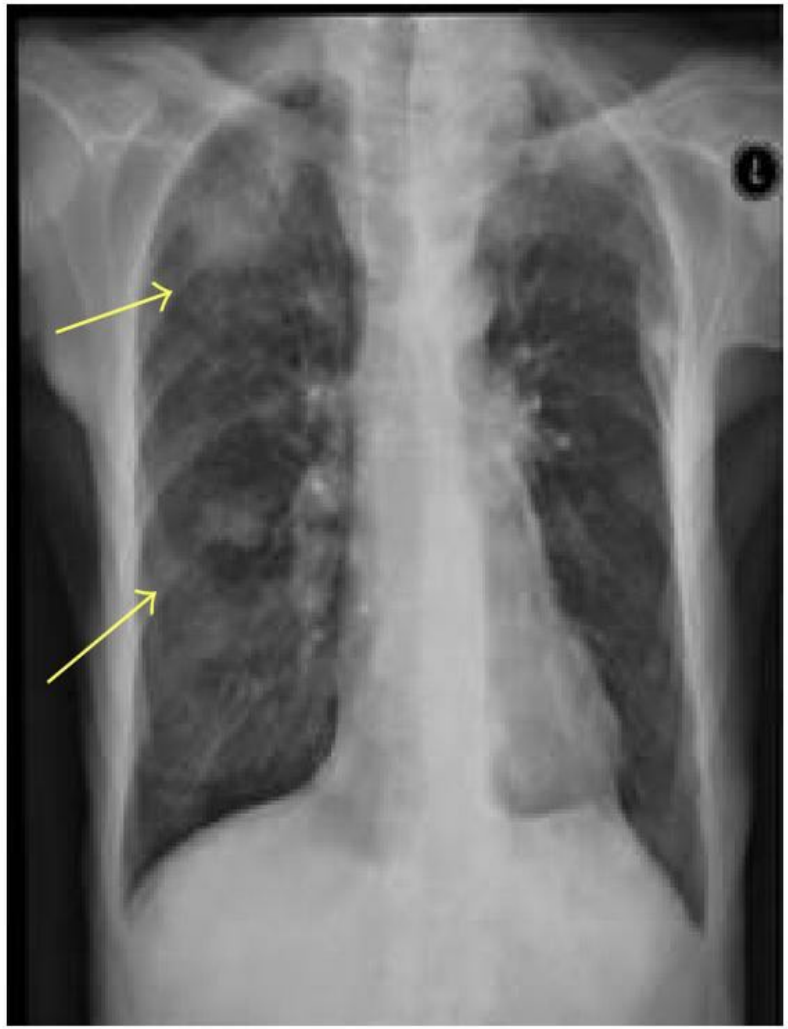
L

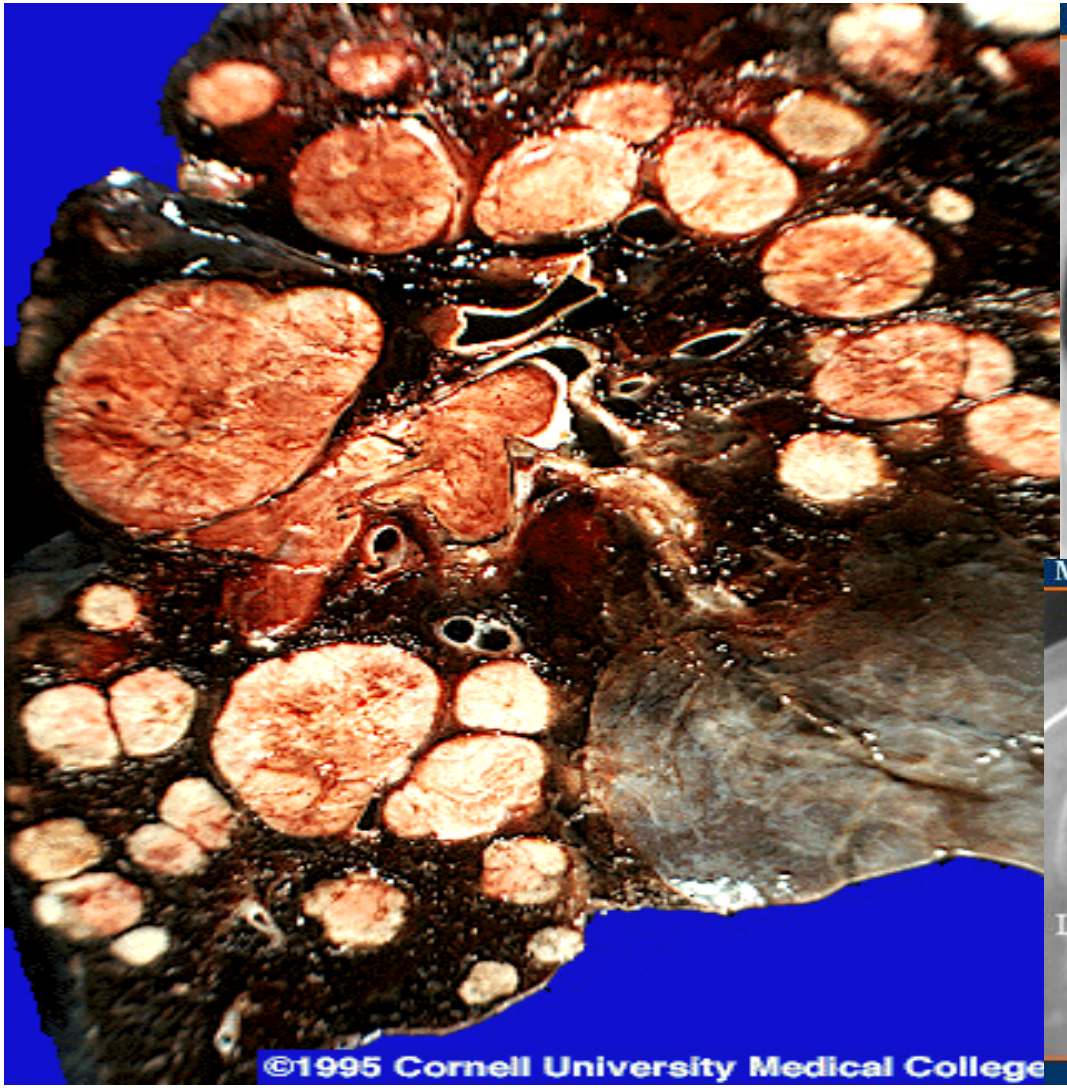
©1995 Cornell University Medical College

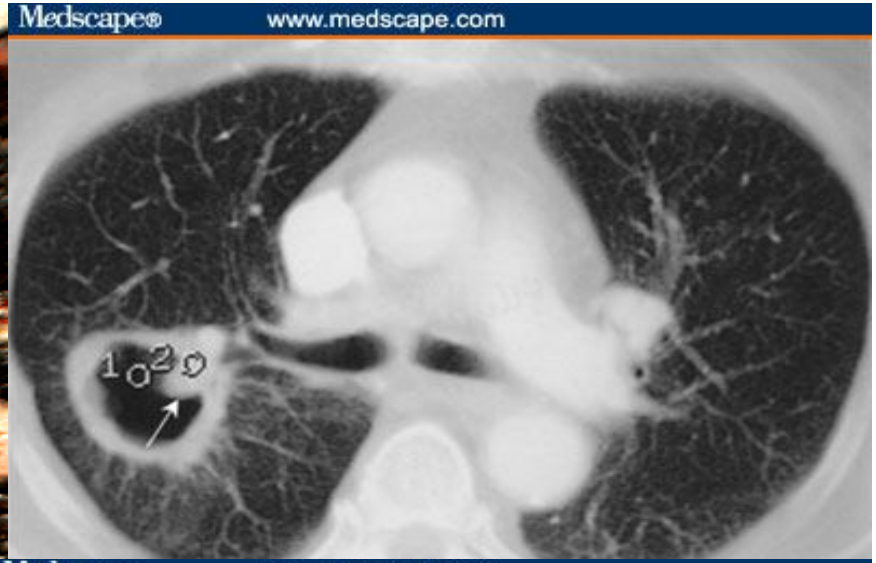
Medscape®
www.medscape.com

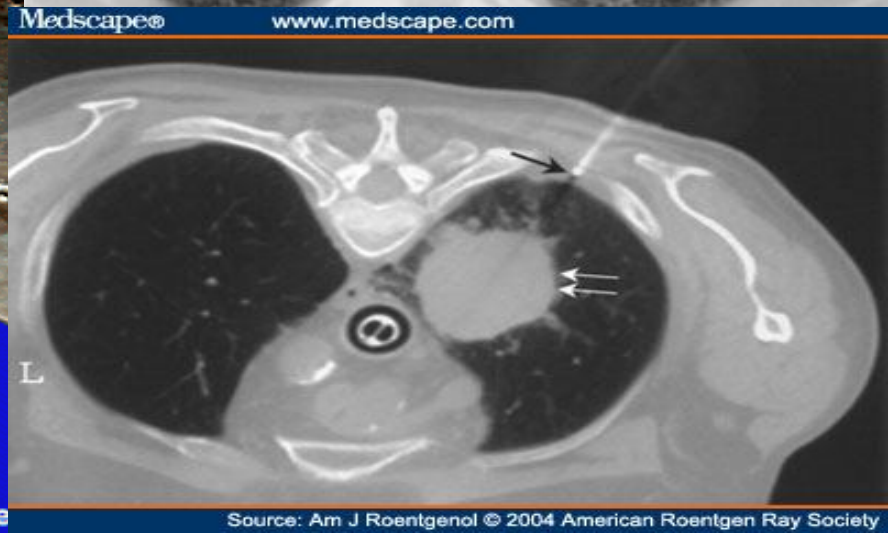
Medscape®
www.medscape.com
L
Source: Am J Roentgenol © 2004 American Roentgen Ray Society

Medscape®

www.medscape.com

Source: Am J Roentgenol © 2004 American Roentgen Ray Society

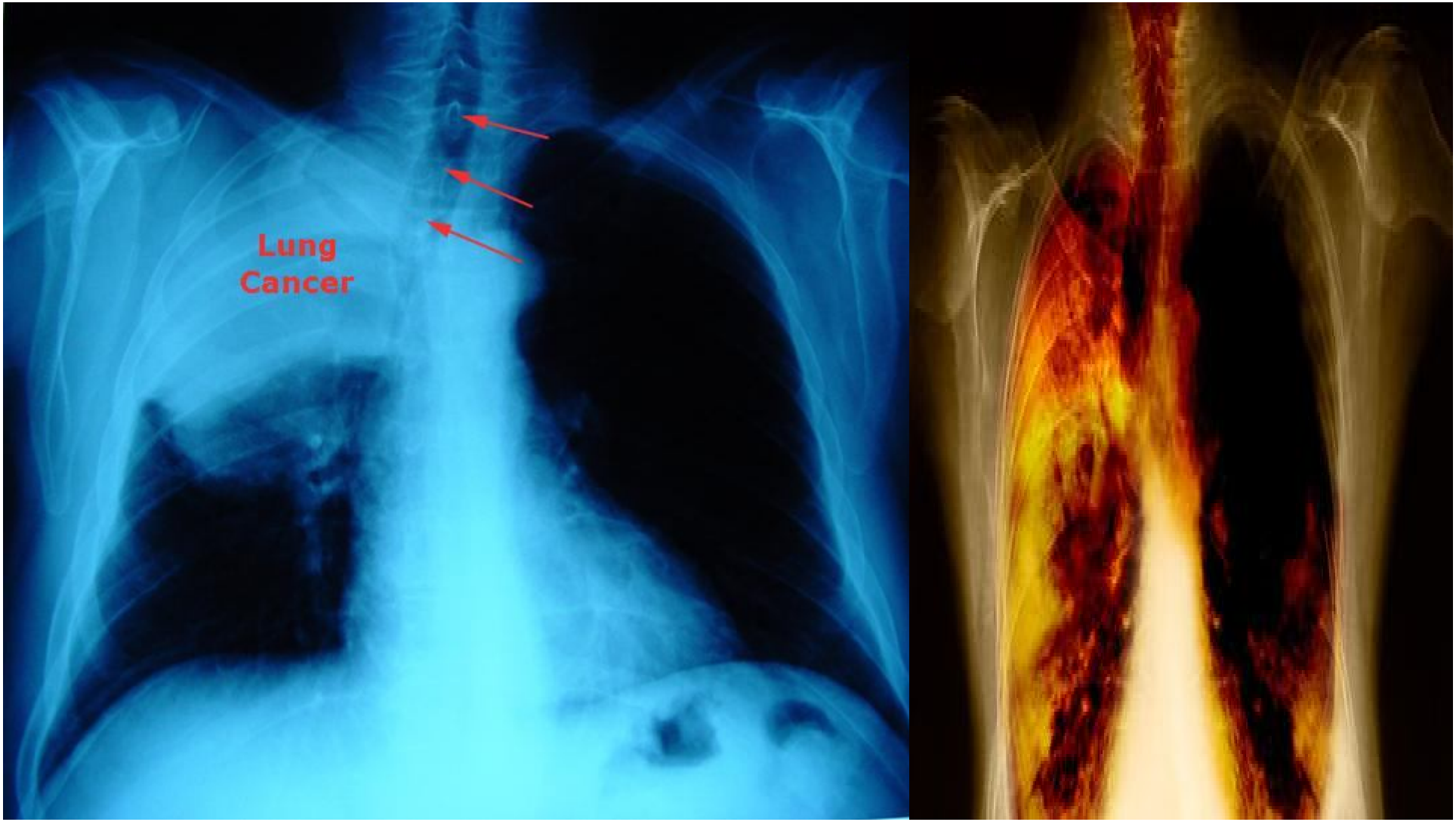
Lung
Cancer

Adenocarcinoma

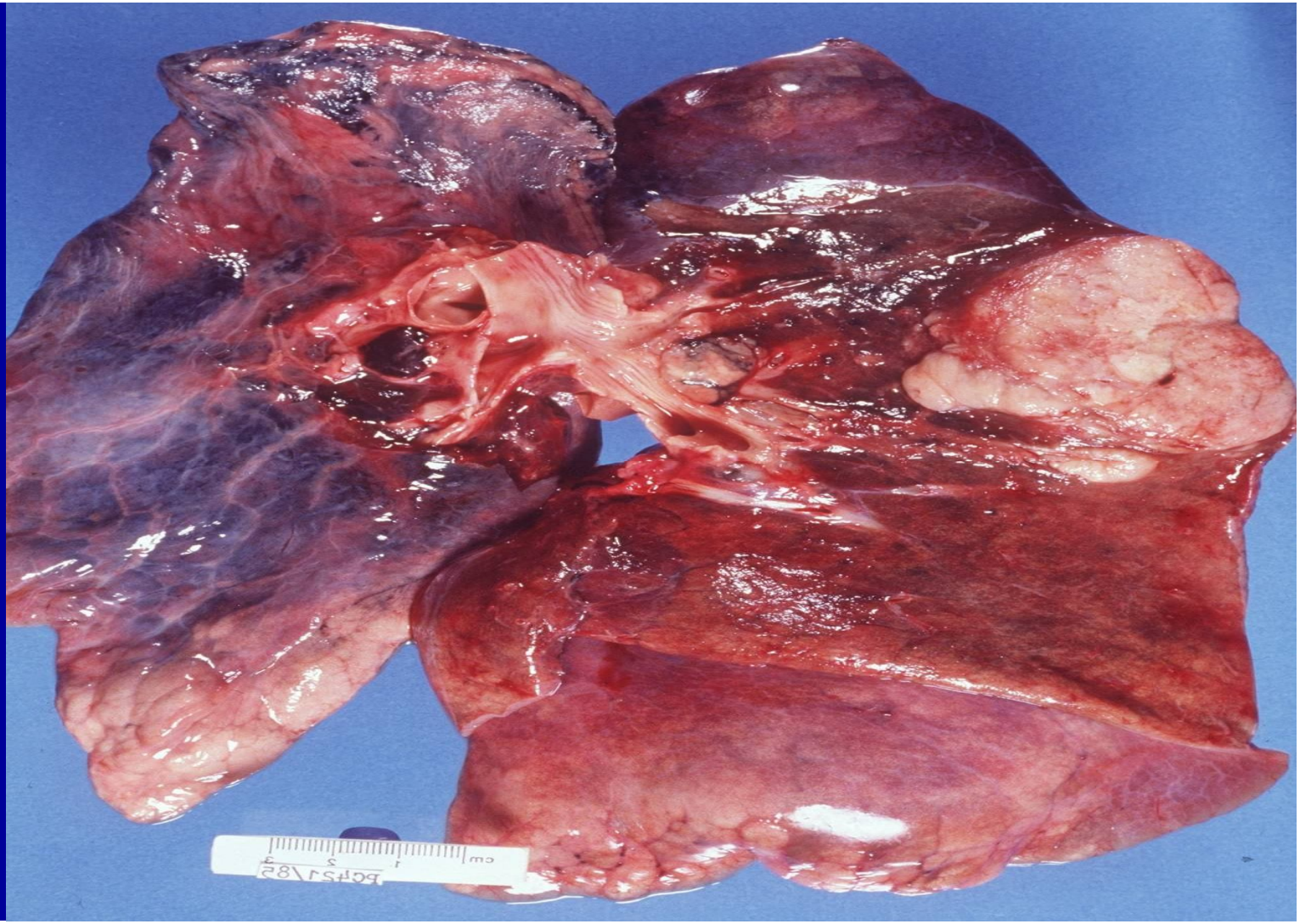

Mucinous adenocarcinoma

Adenocarcinoma

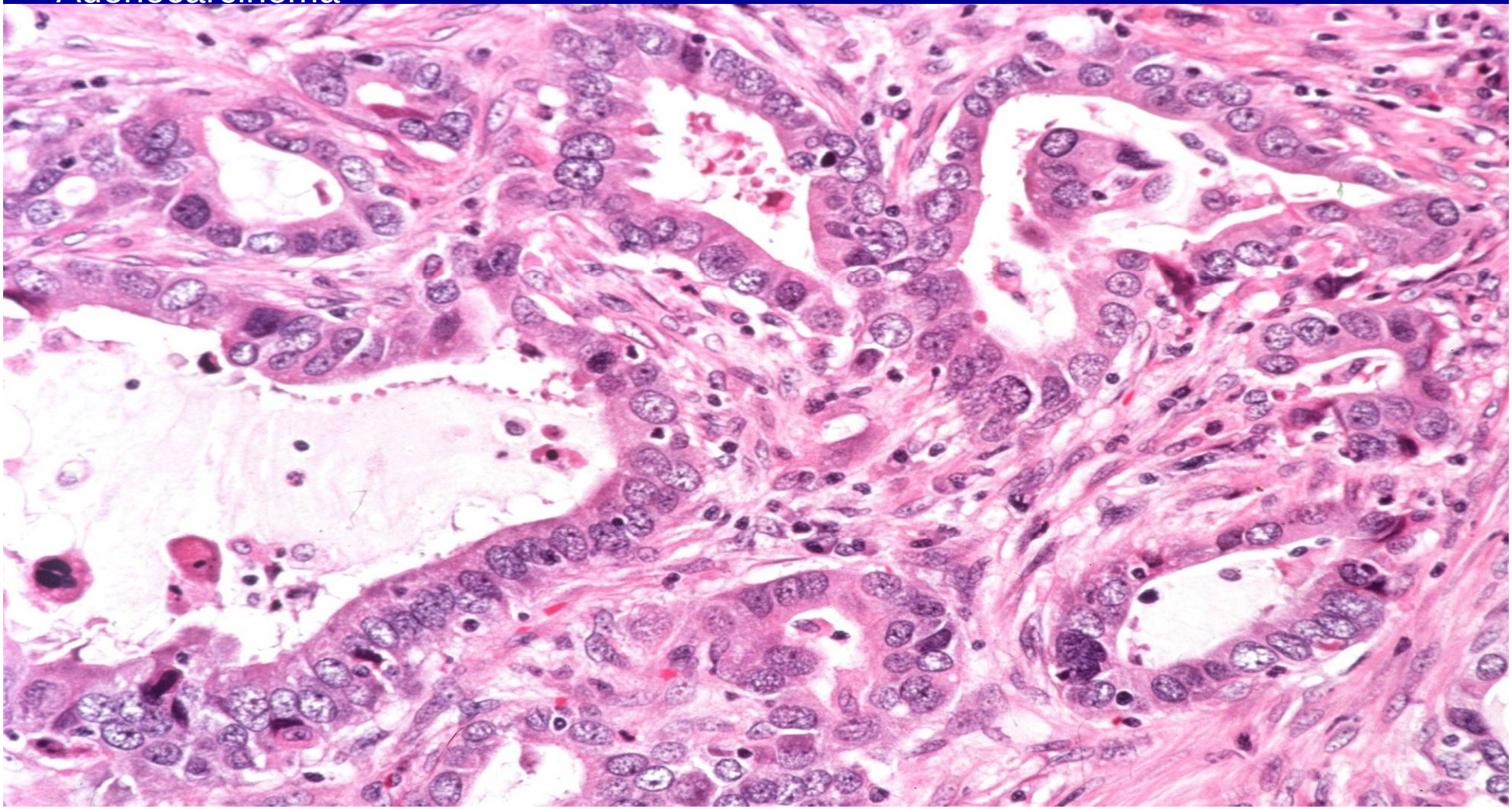


Adenocarcinoma
and emphysema
cm
1
2
3
PC1211/84

SMOKER'S LUNG (Continued)



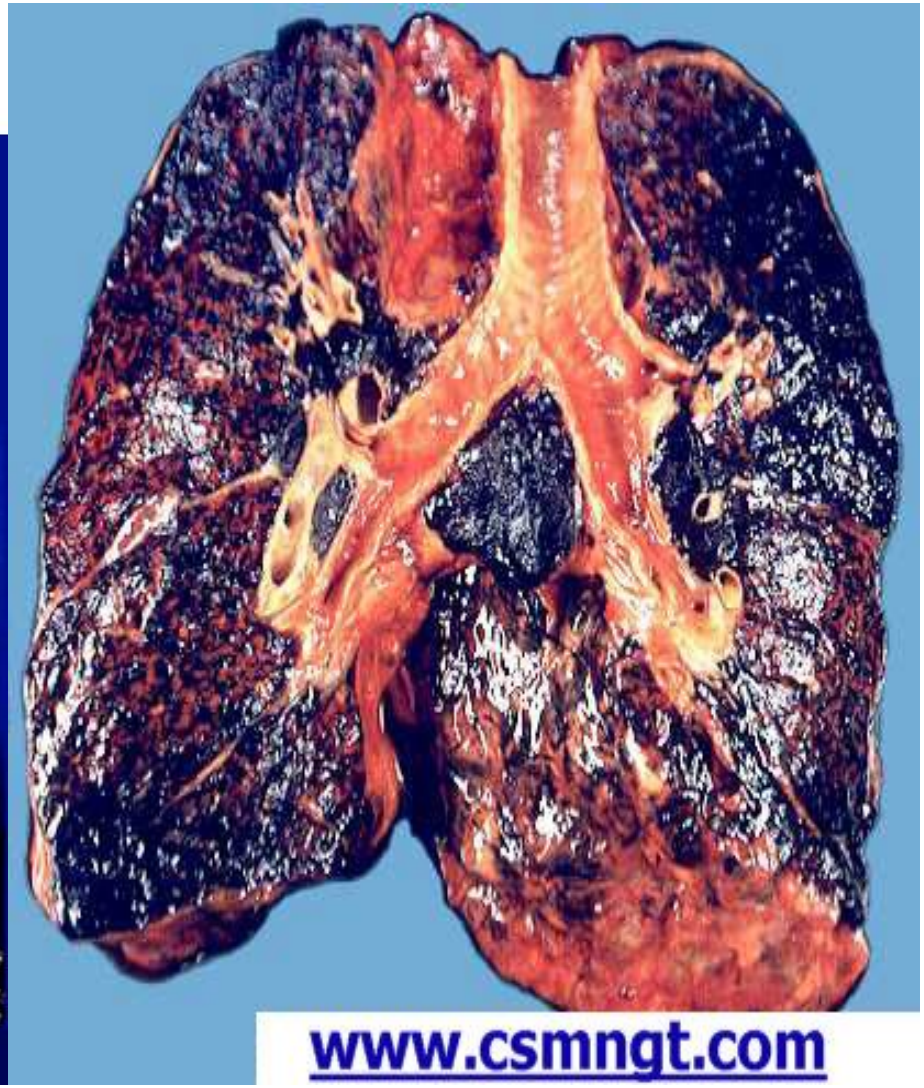

www.csmngt.com


Vat is the
diverance


cm
1
2
3
4
5
6
SPECIMEN A-73-309
DATE

Healthy Tissue



Healthy Tissue
90-year-old
schoolteacher

Progressive
massive fibrosis
40-year-old-miner


Larynx (squamous cell carcinoma)
right anterior vocal fold

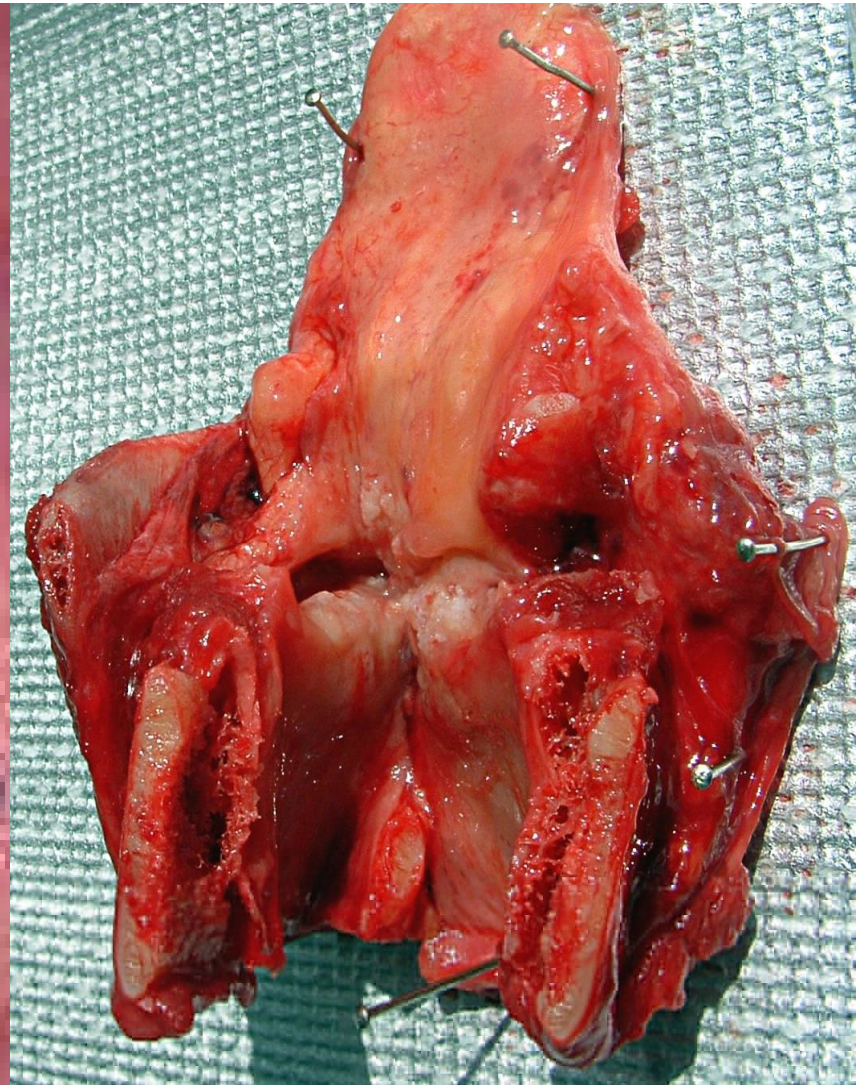

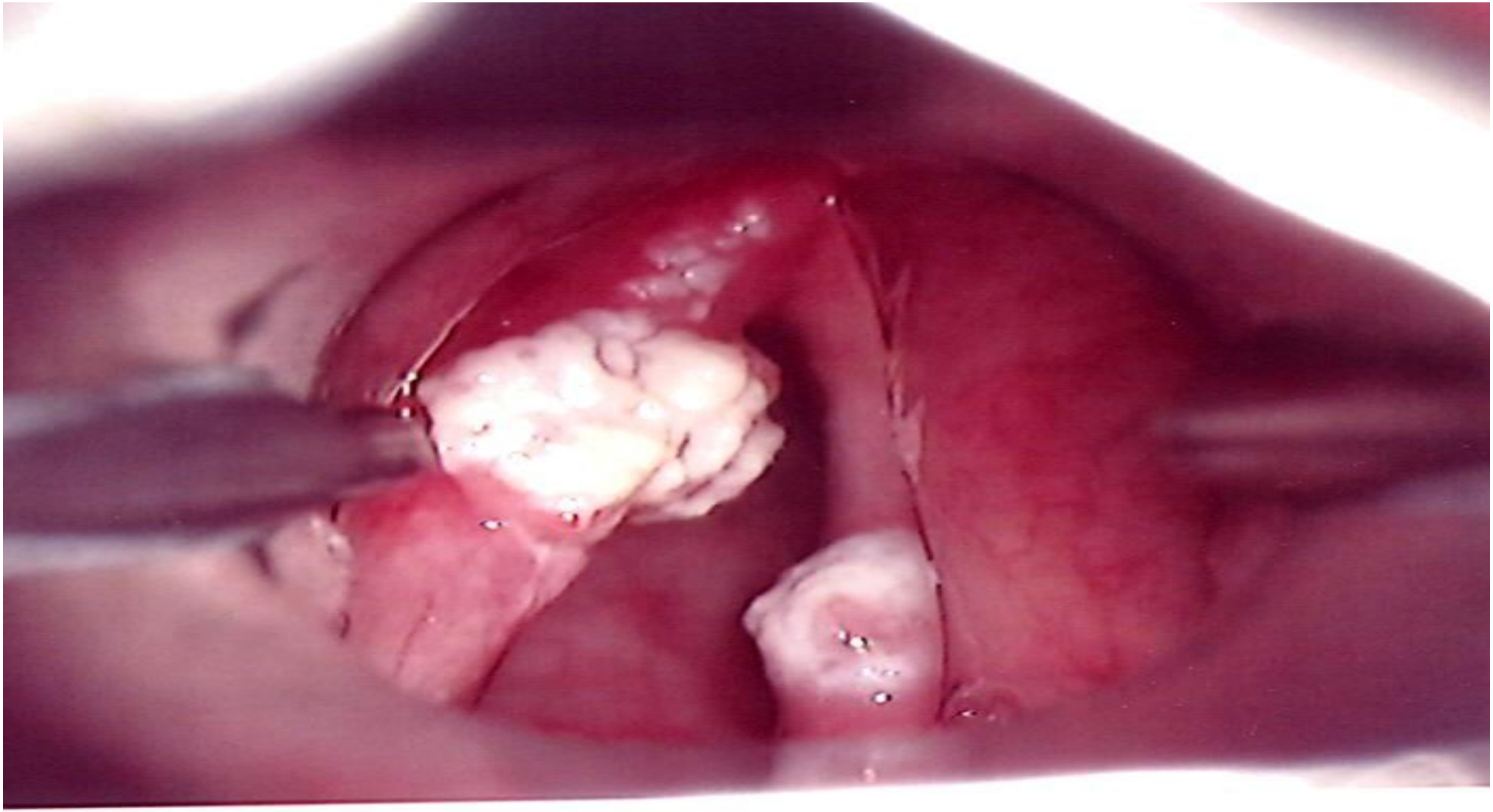

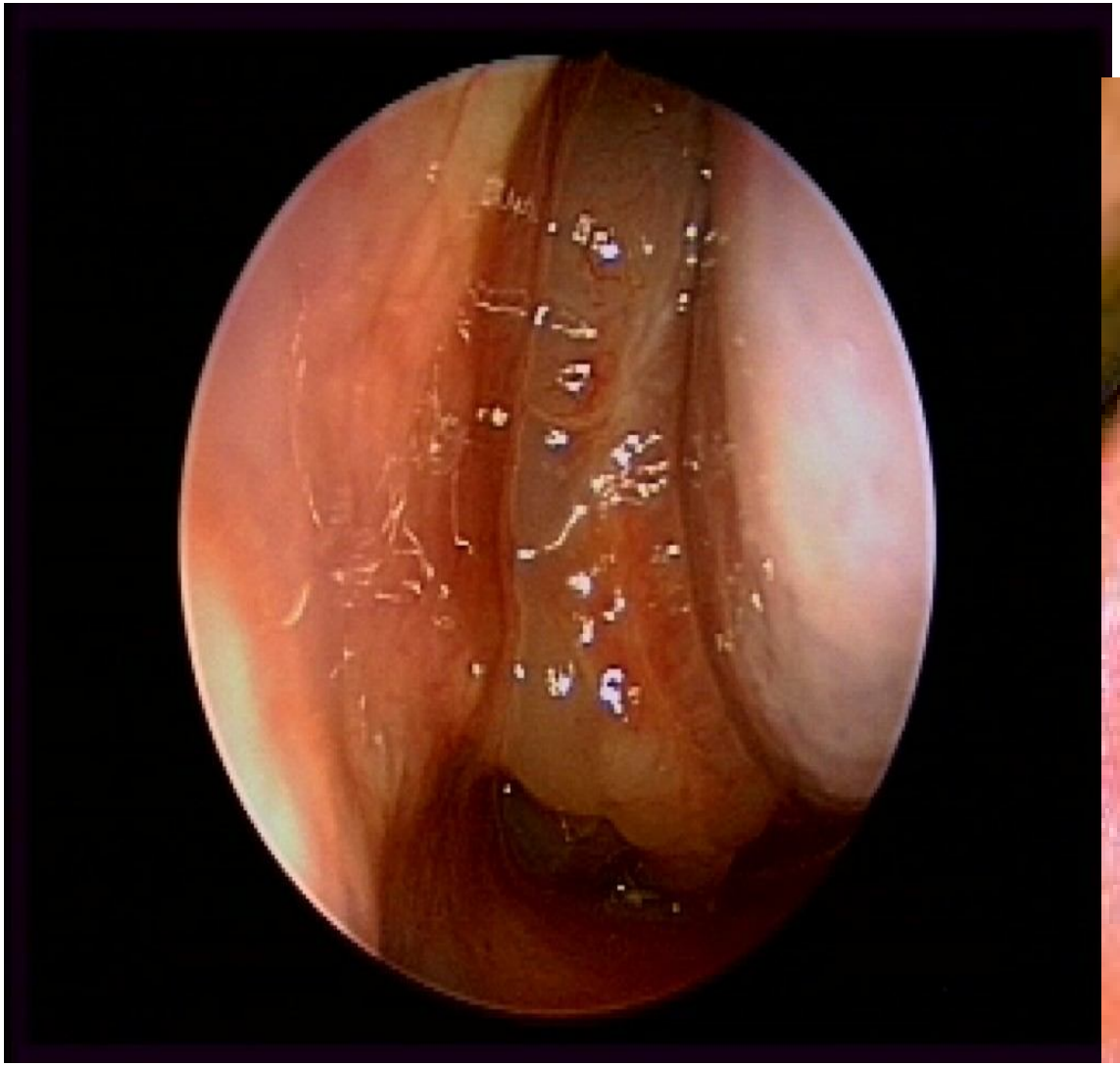

nasasl polyps

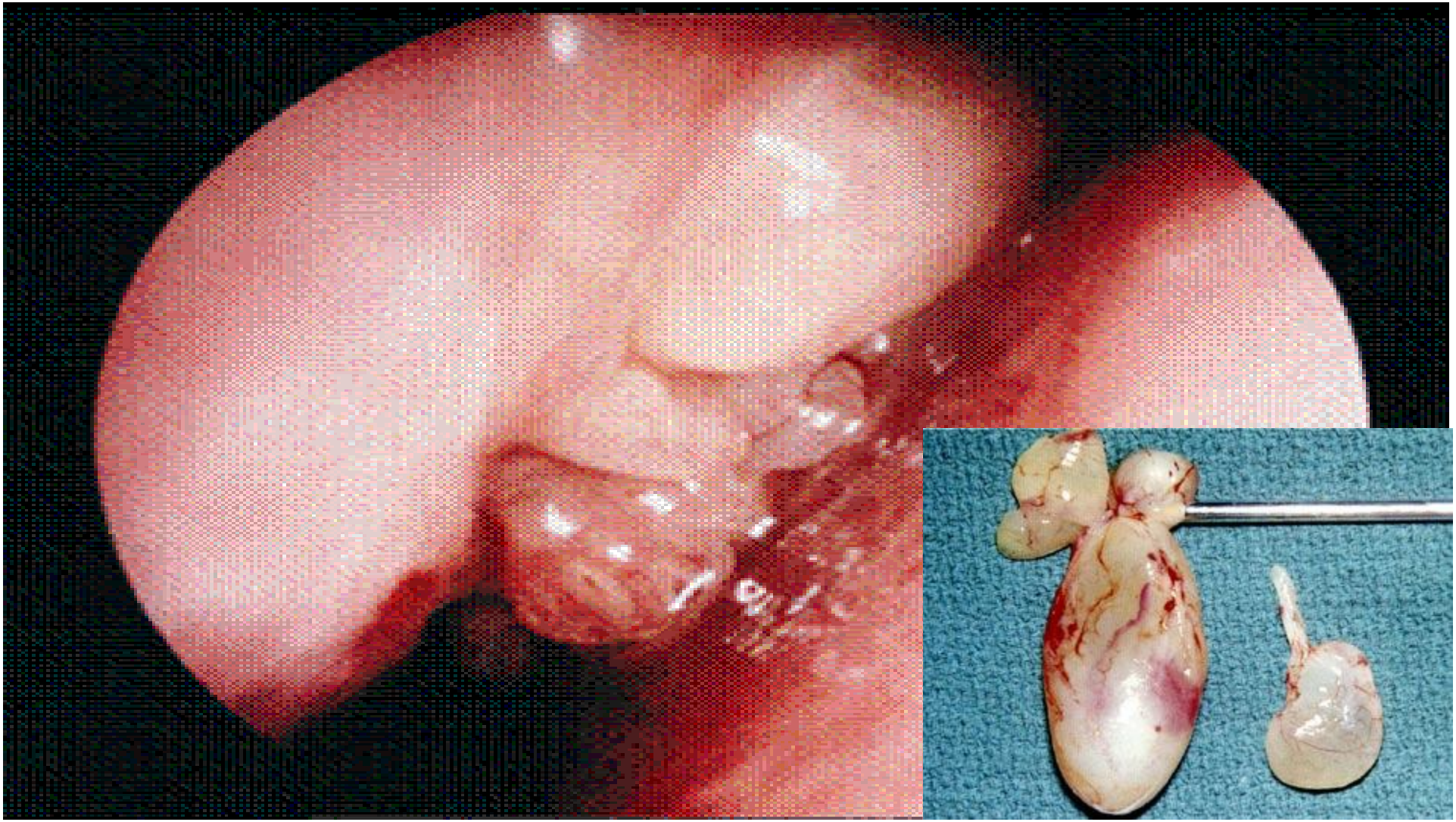

Normal lung

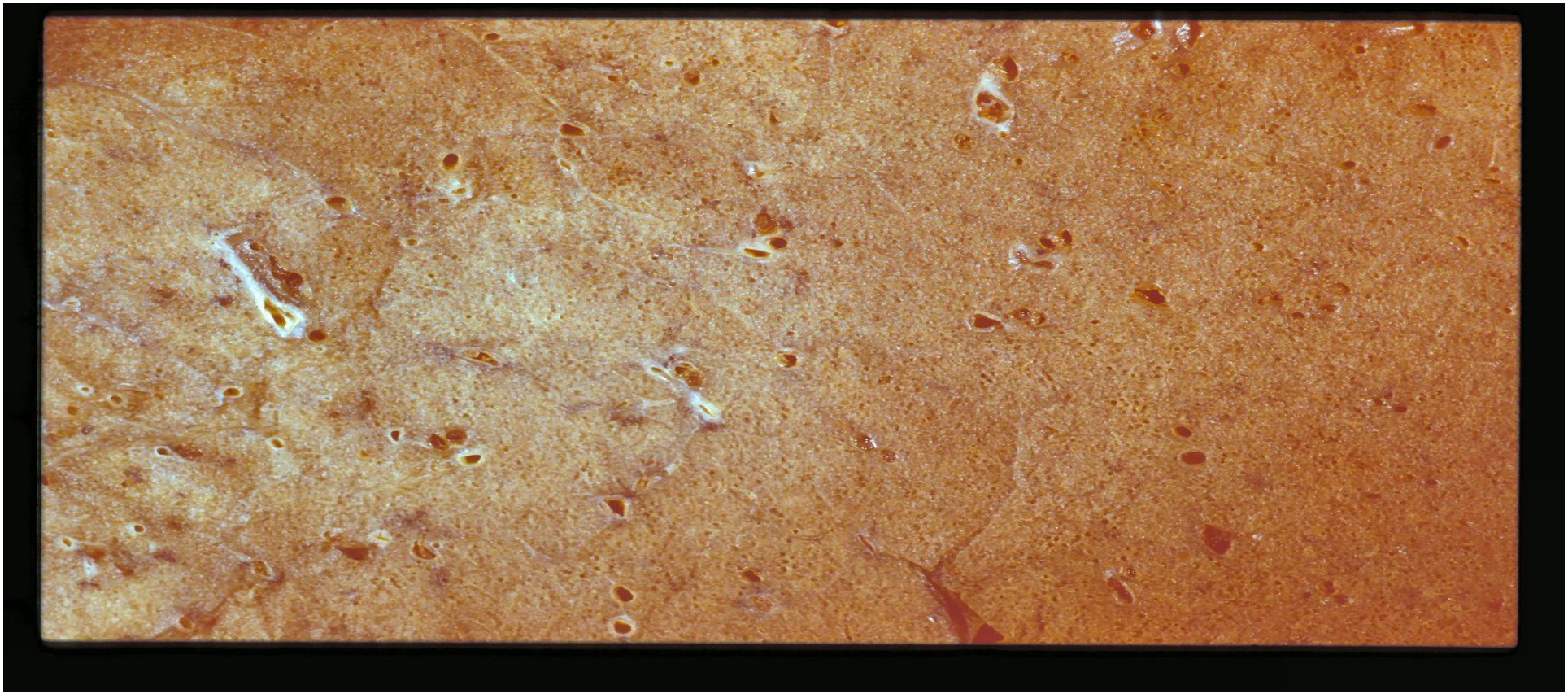

Centriacinar emphysema

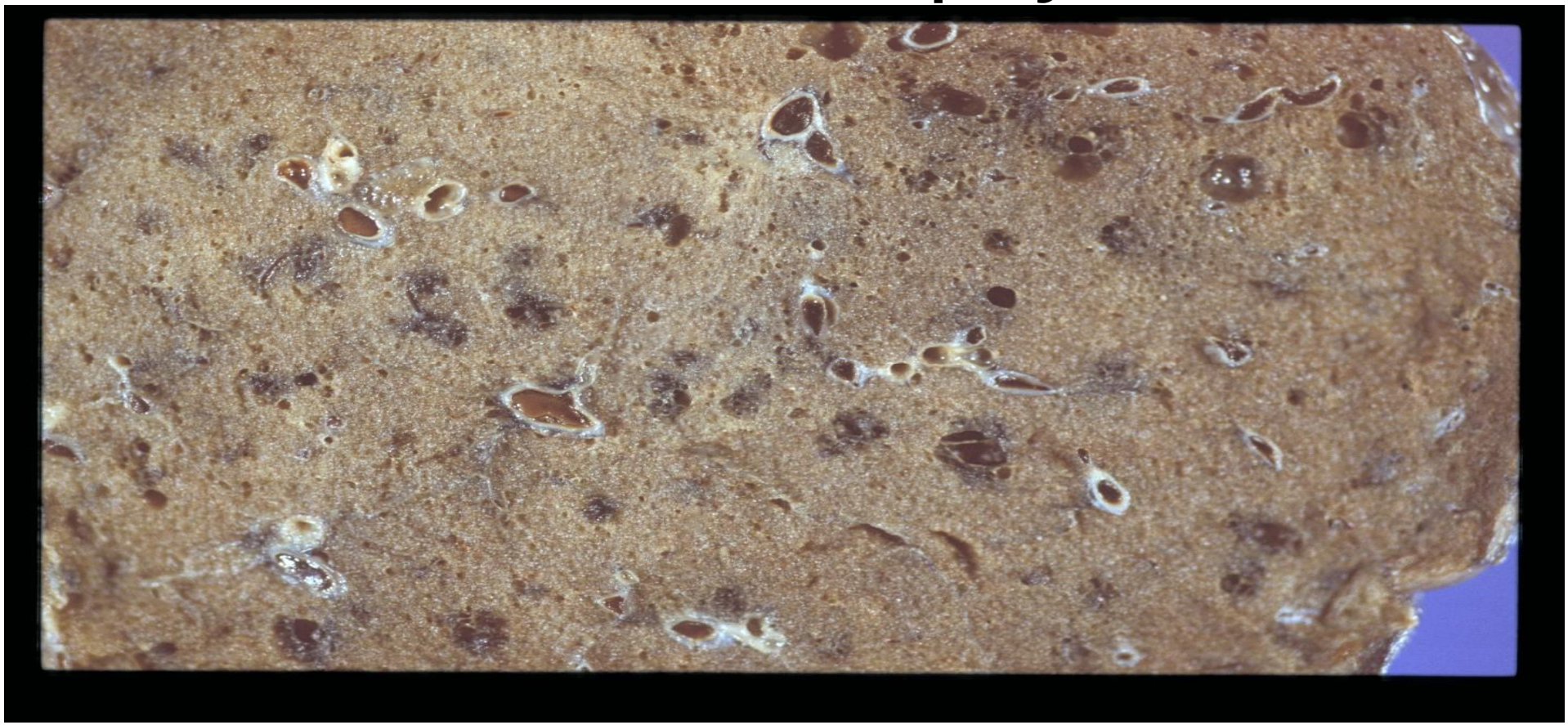

Panacinar emphysema 1

Panacinar emphysema 2

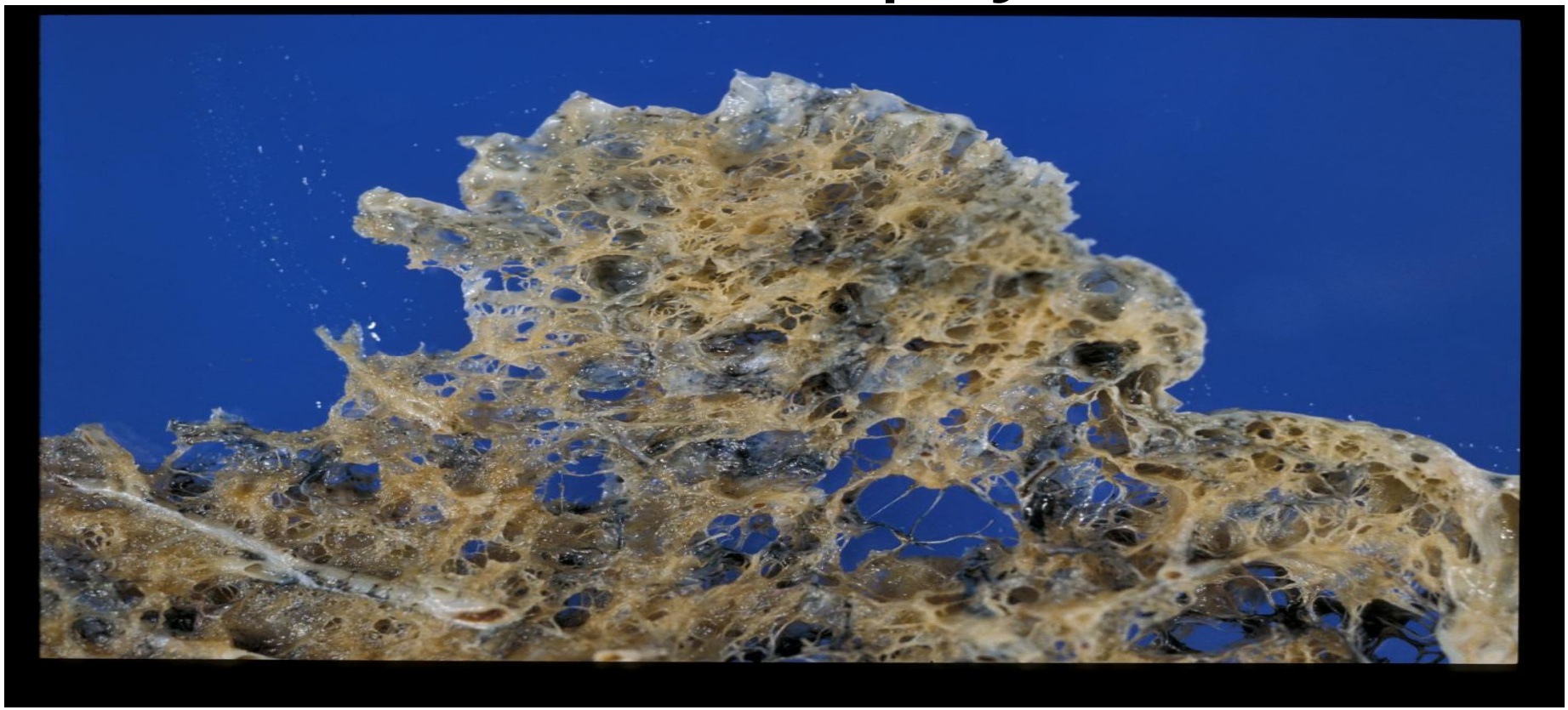

Opportunistic pneumonias

- Infections that affect immunosuppressed patients
- Associated disorders:
  - AIDS
  - Iatrogenic

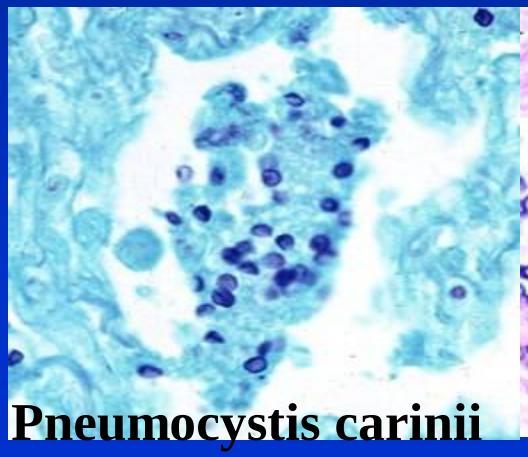

Pneumocystis carinii

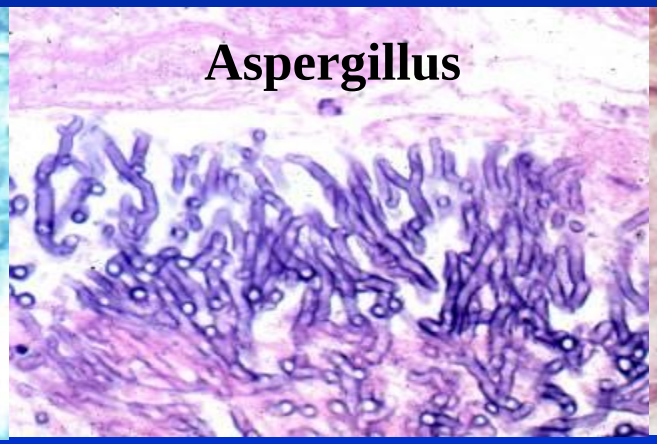

Aspergillus

Cytomegalovirus

Right-sided cardiac decompression in cor pulmonale or pulmunary hypertension

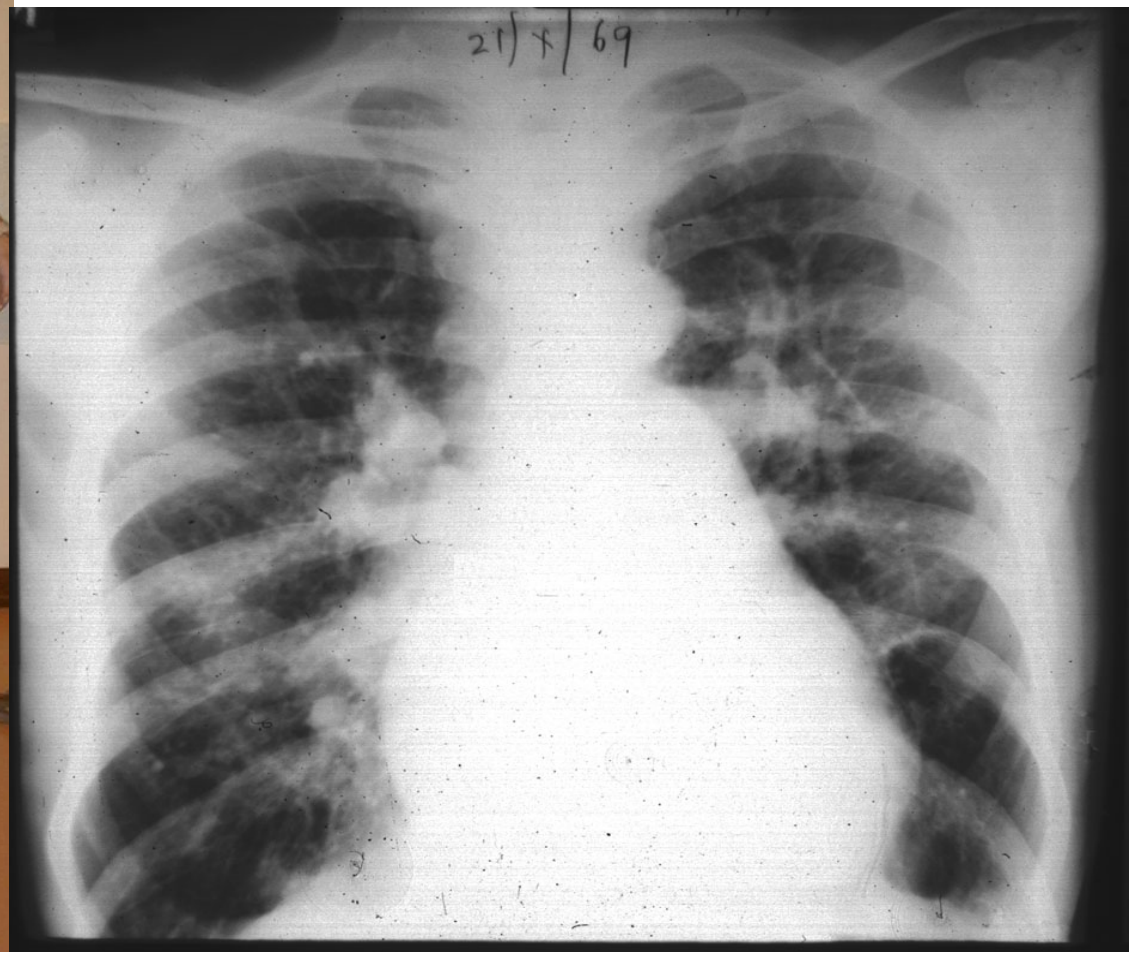

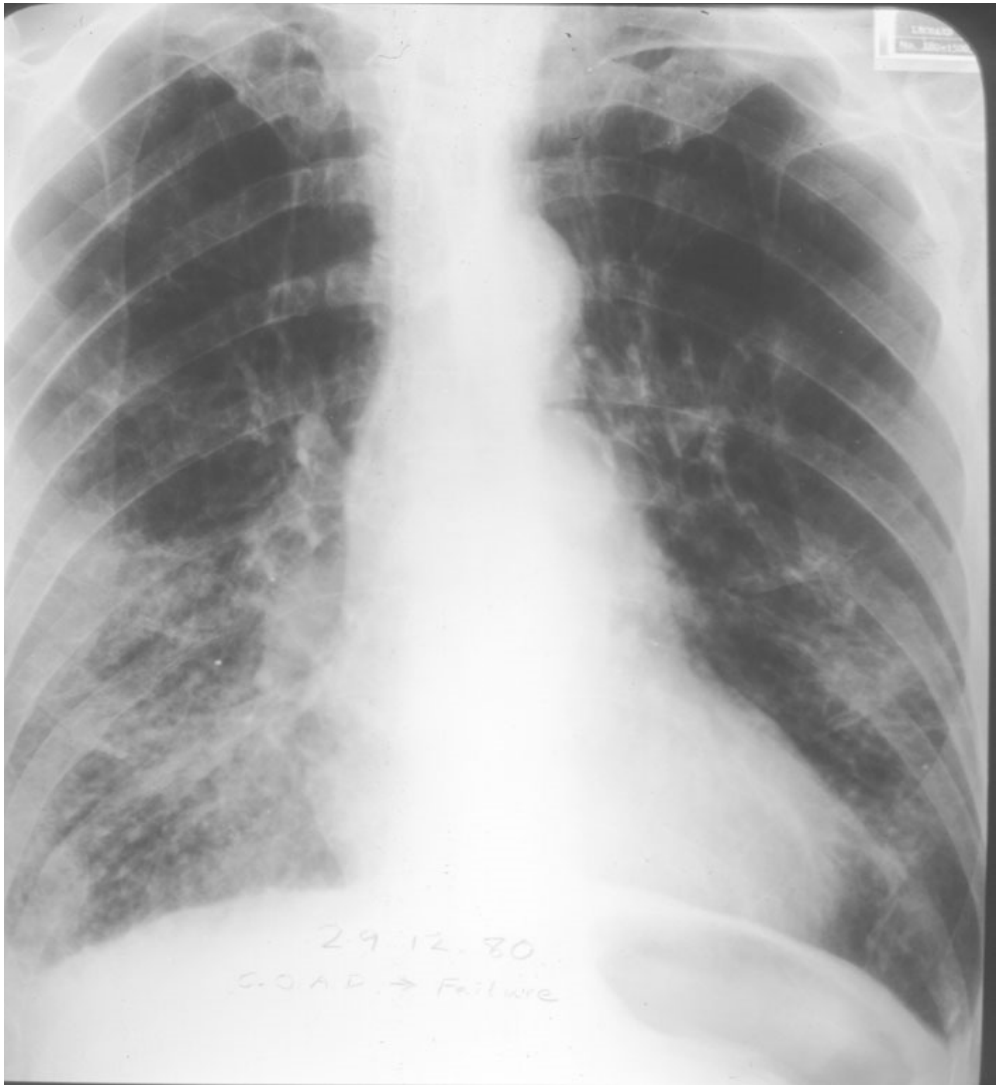

62 year old smoker with recent rapid increase in breathlessness.
The lungs are large volume. The heart diameter, normally 'stretched-out' by the lengthened mediastinum, appears bulky. The lung shadowing is reduced with a reduced vessel count and reduced density in both lungs. There is increase in density in the right lower zone. Pulmonary opacification in this area is discontinuous implying foci of normal or abnormal lung. Right lower lobe bronchial walls appear thickened, but appear blurred. The area of increased density is bounded above by the horizontal fissure. A thin-walled cavity (bulla) is noted in the left upper and lower lobes.