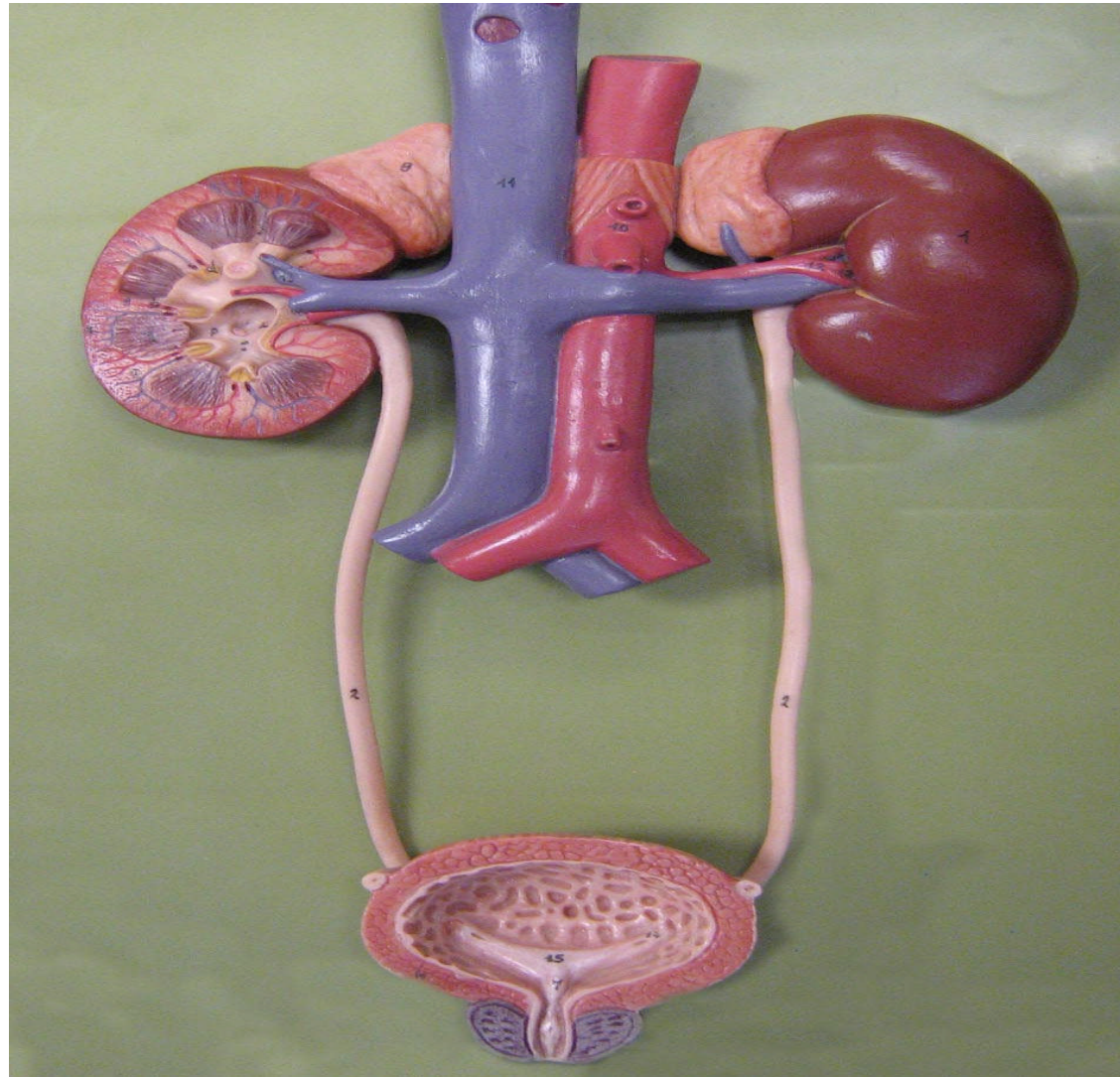
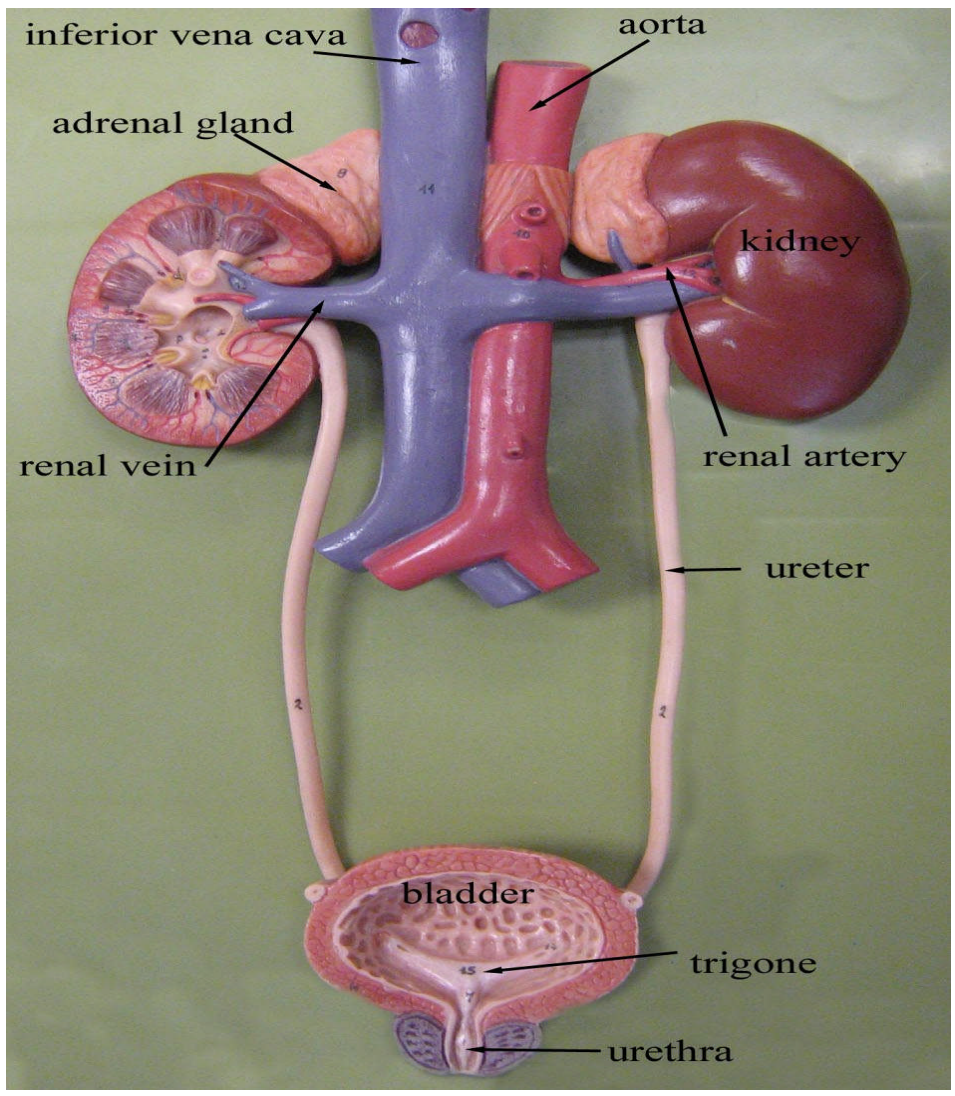

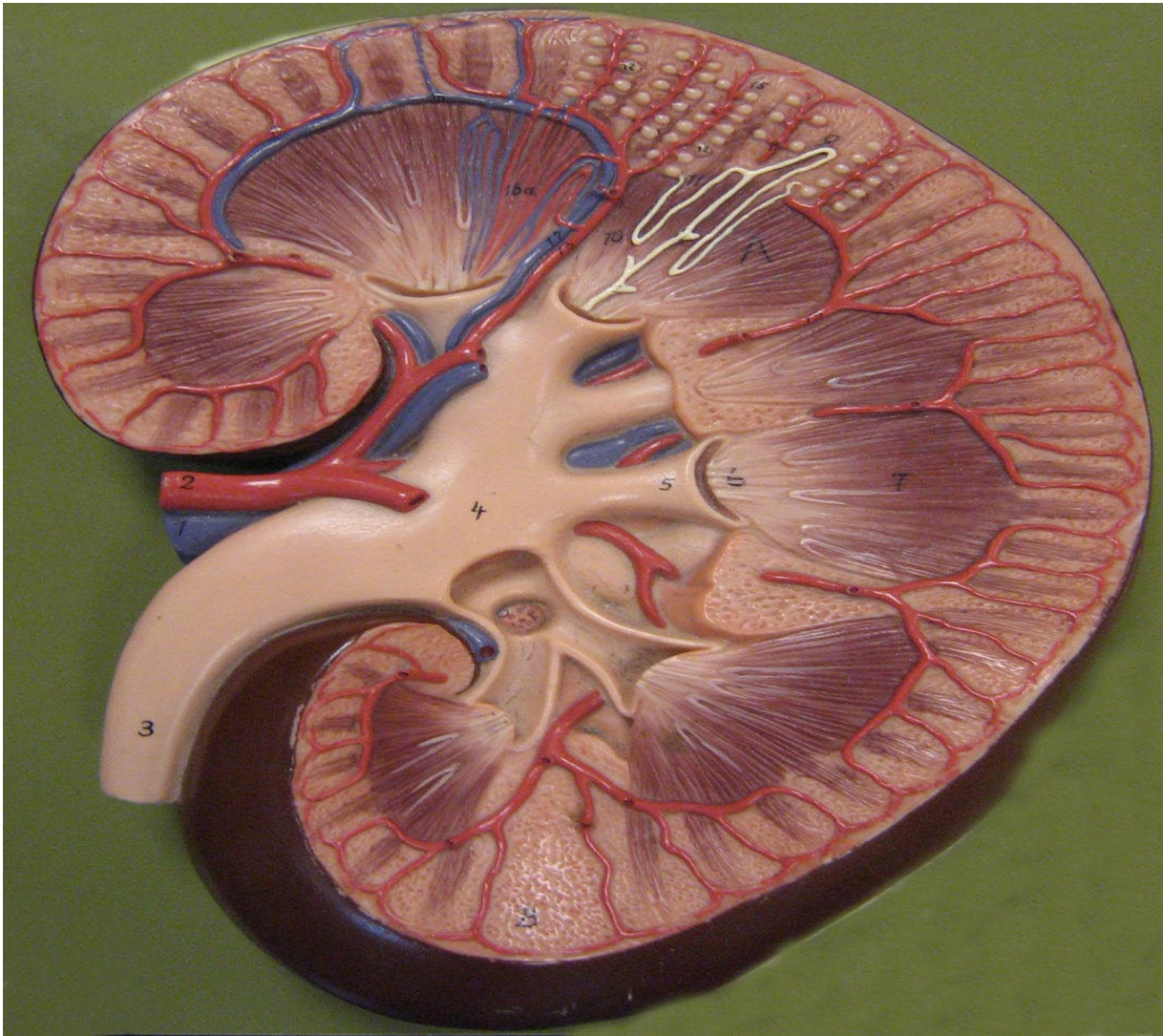
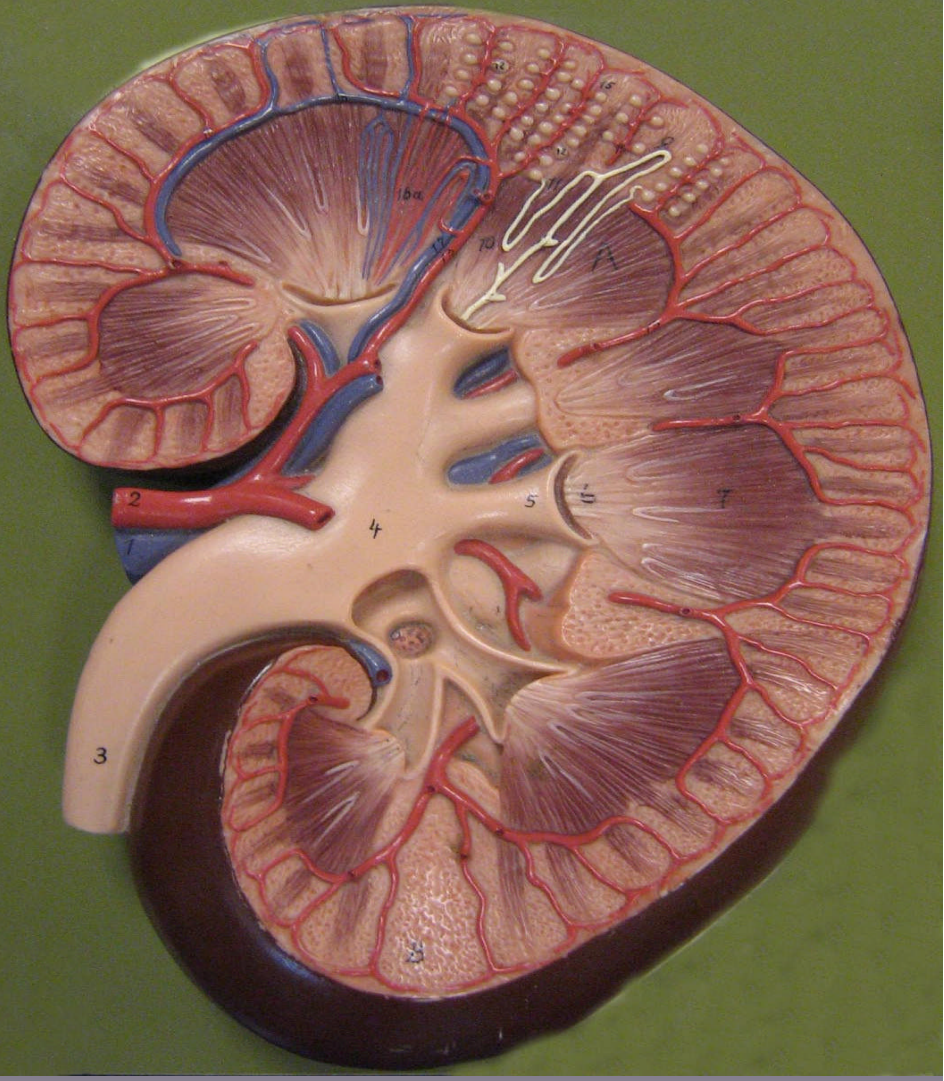
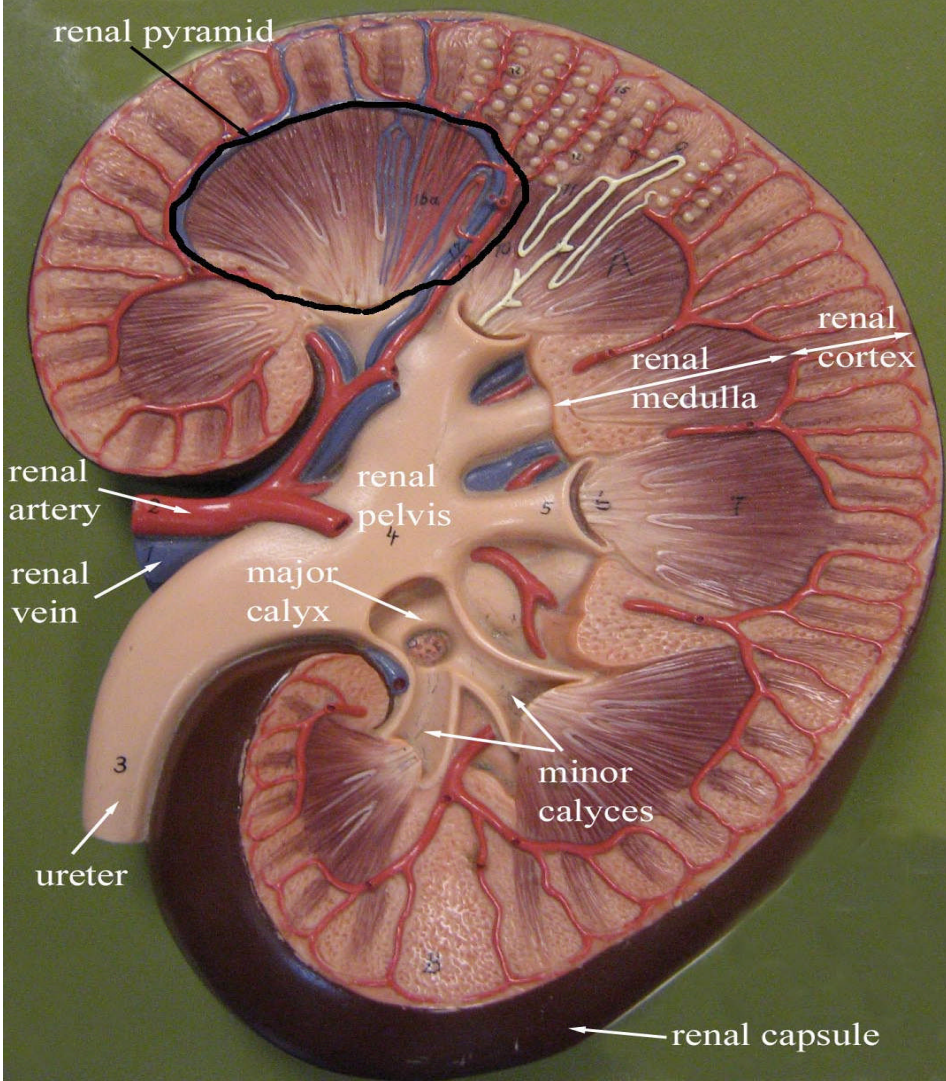



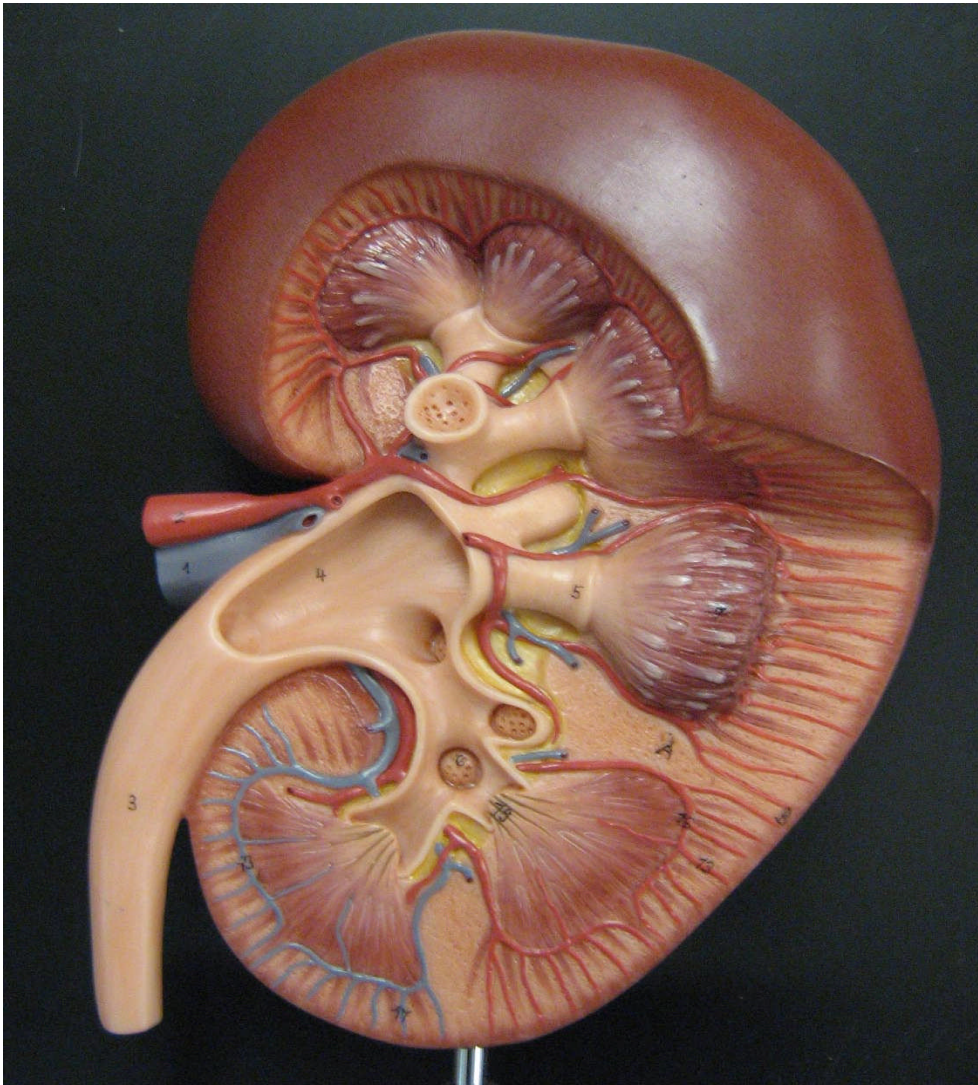
URINARY SYSTEM MODELS HISTOLOGY

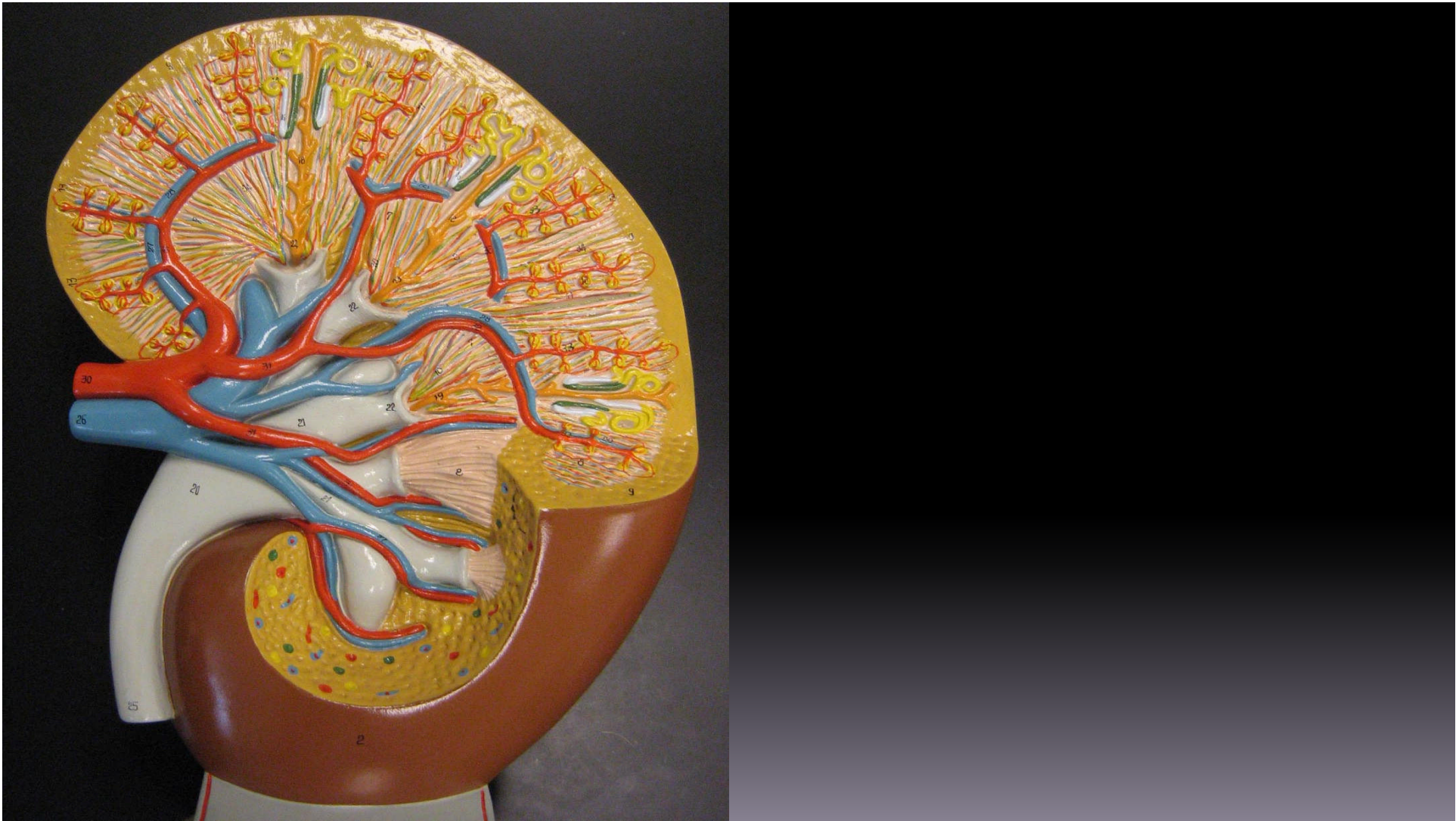



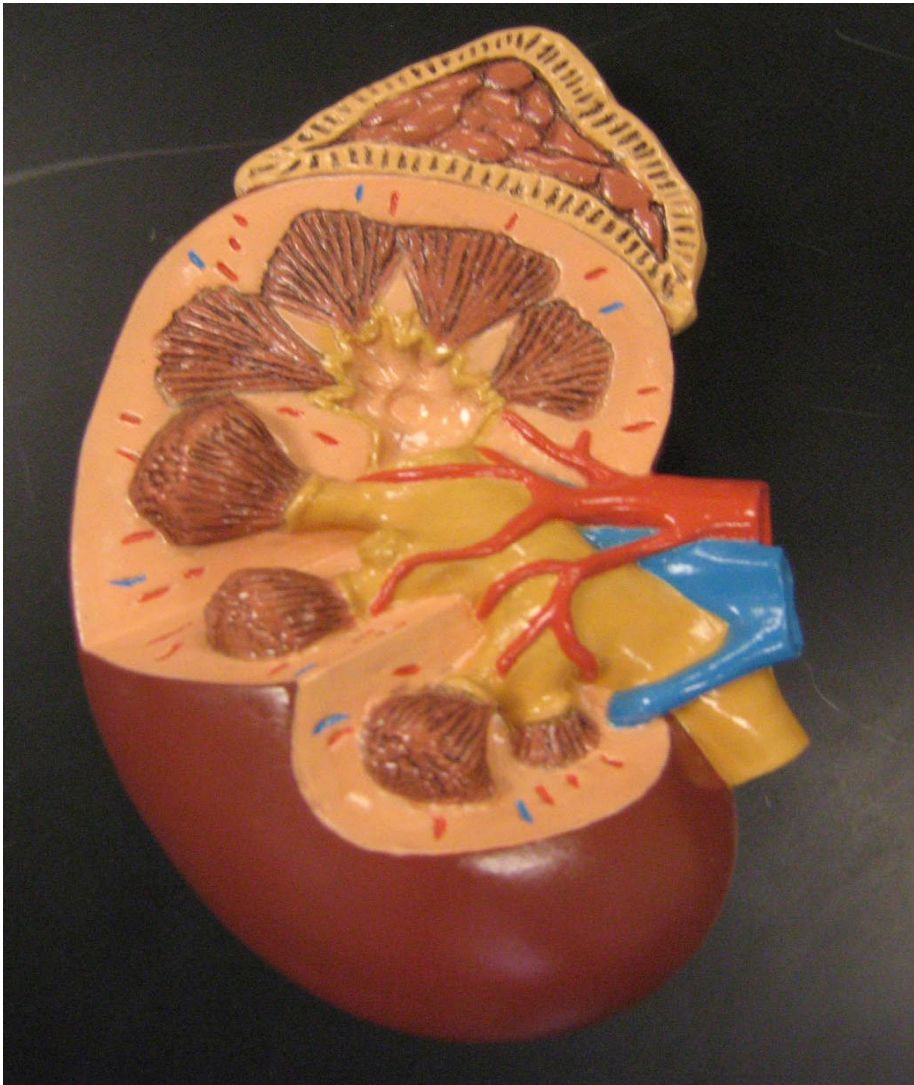


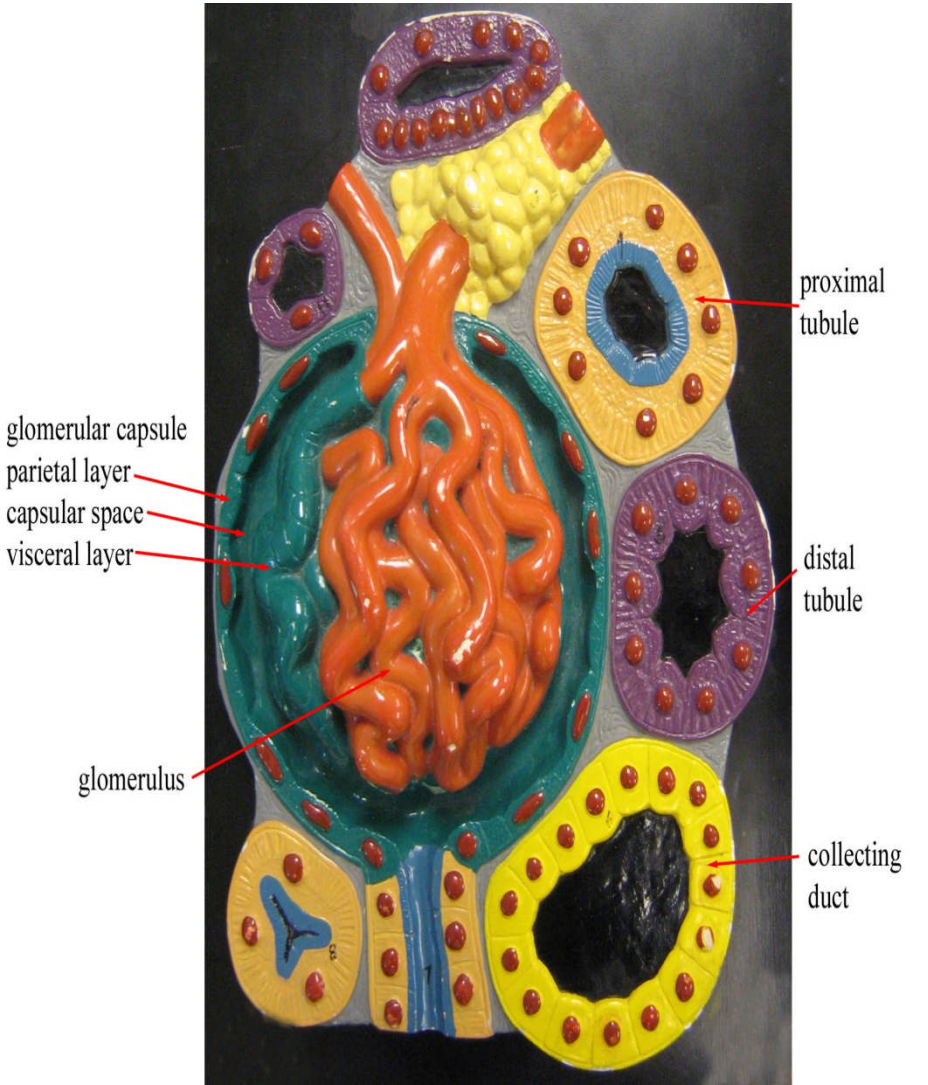
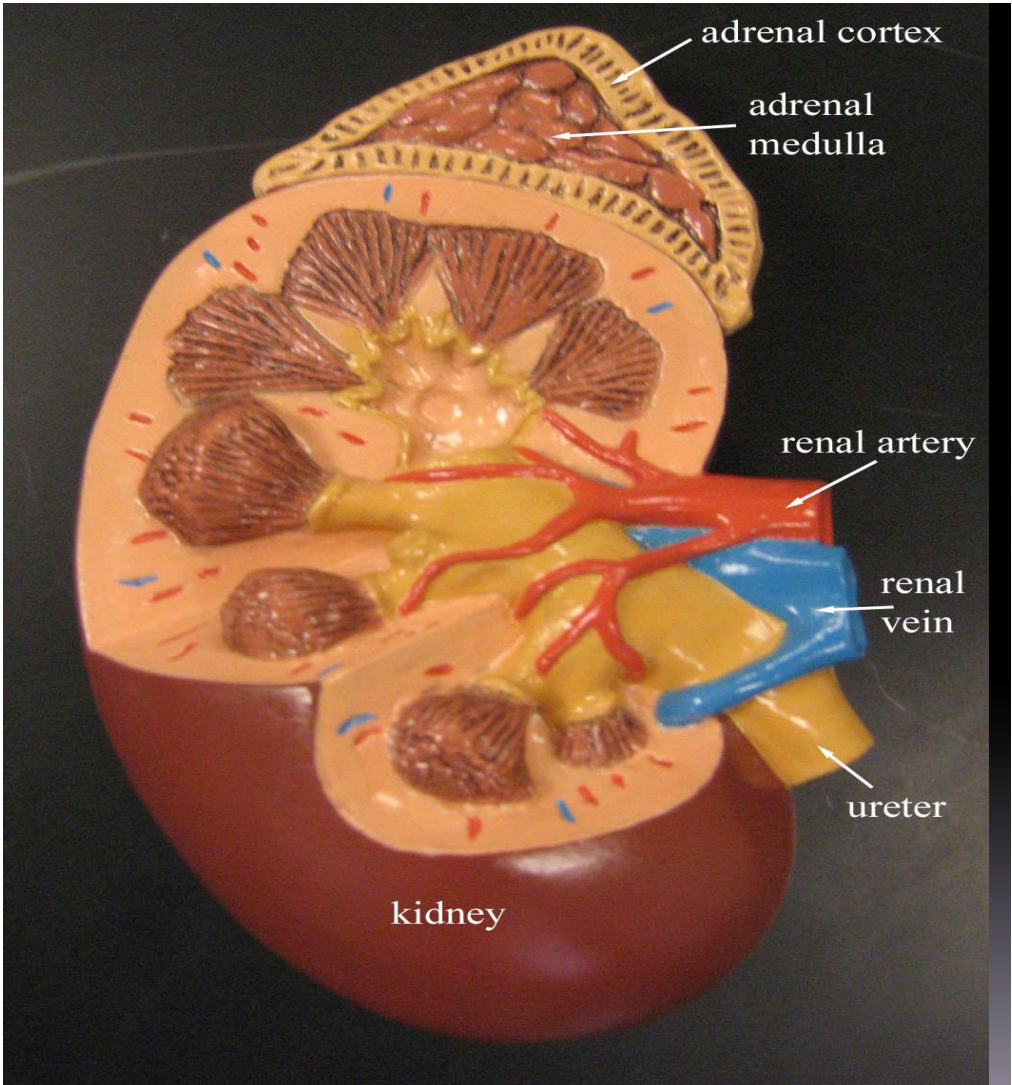


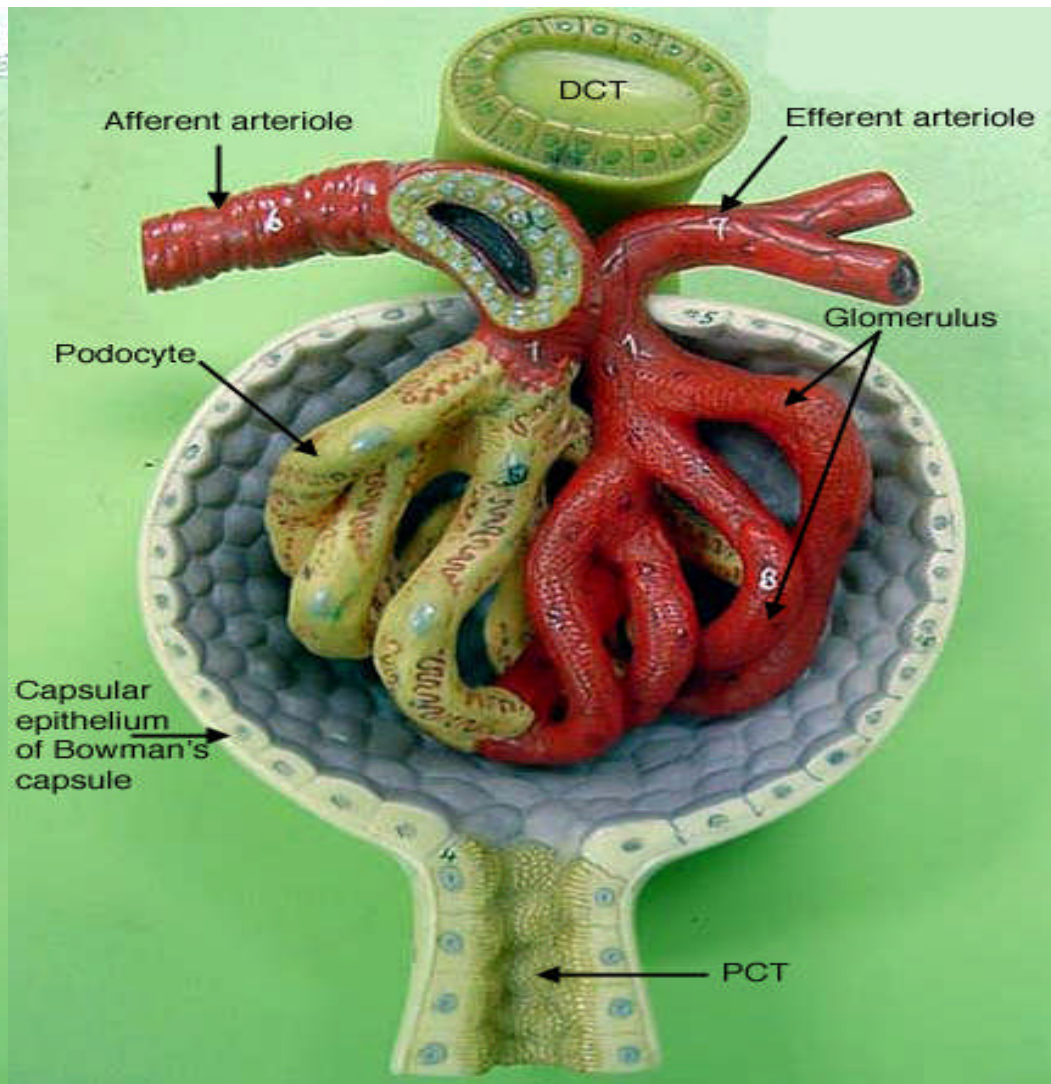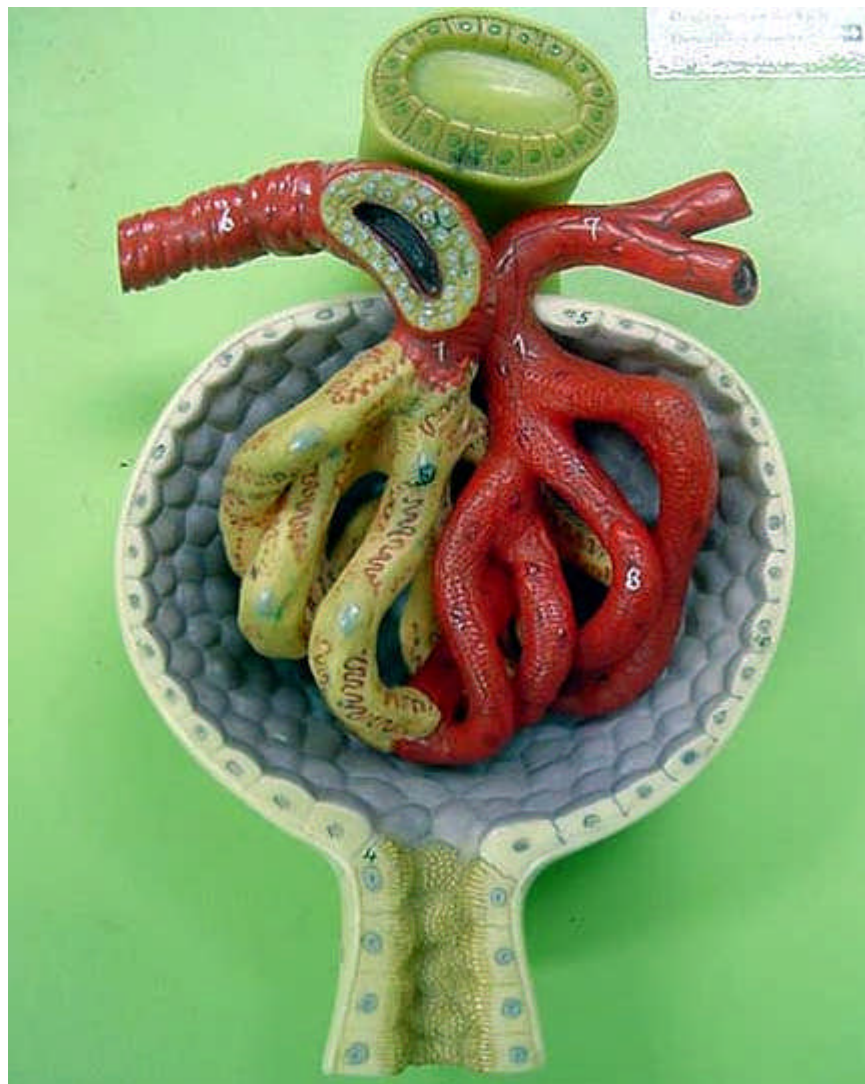


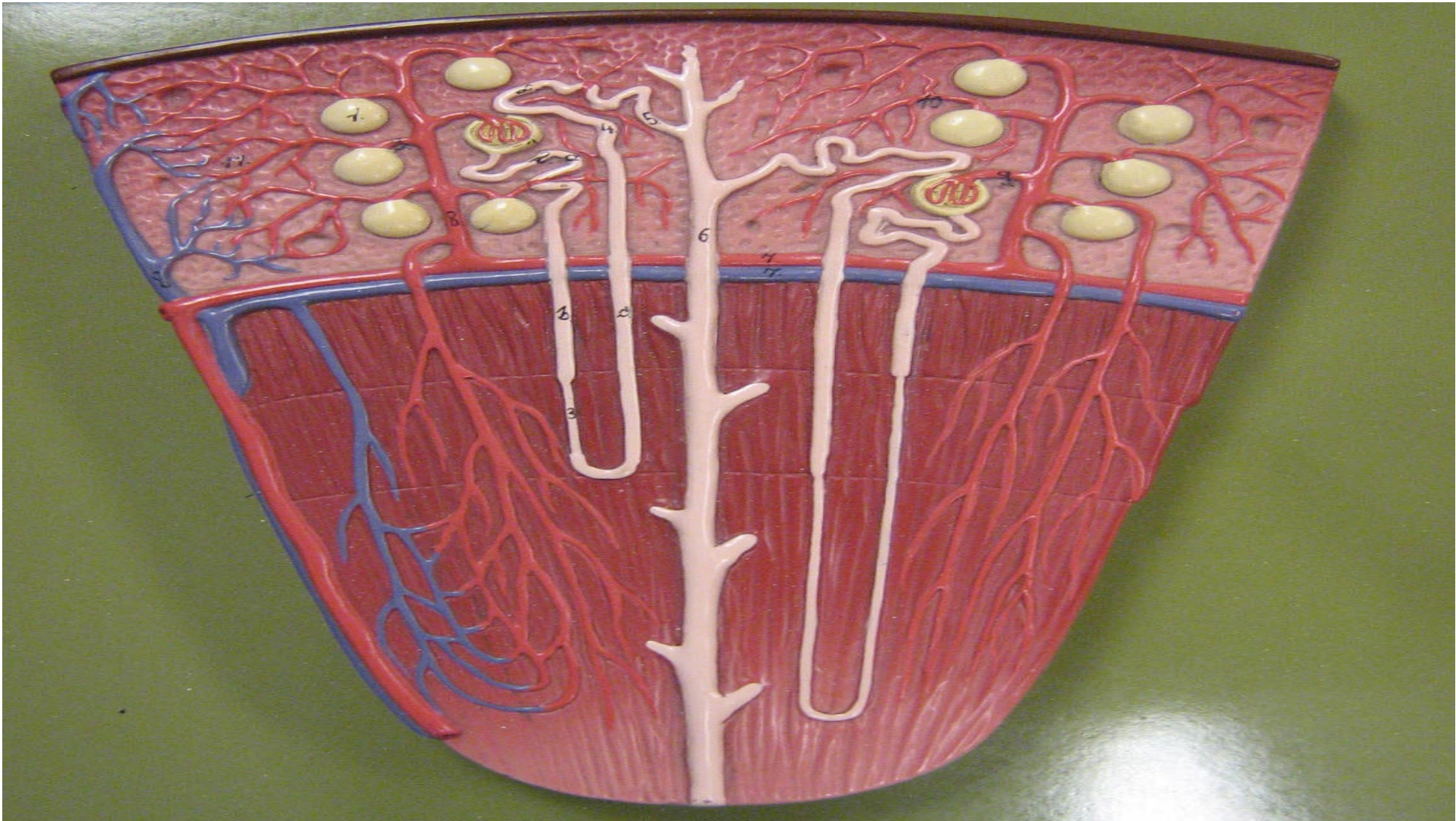


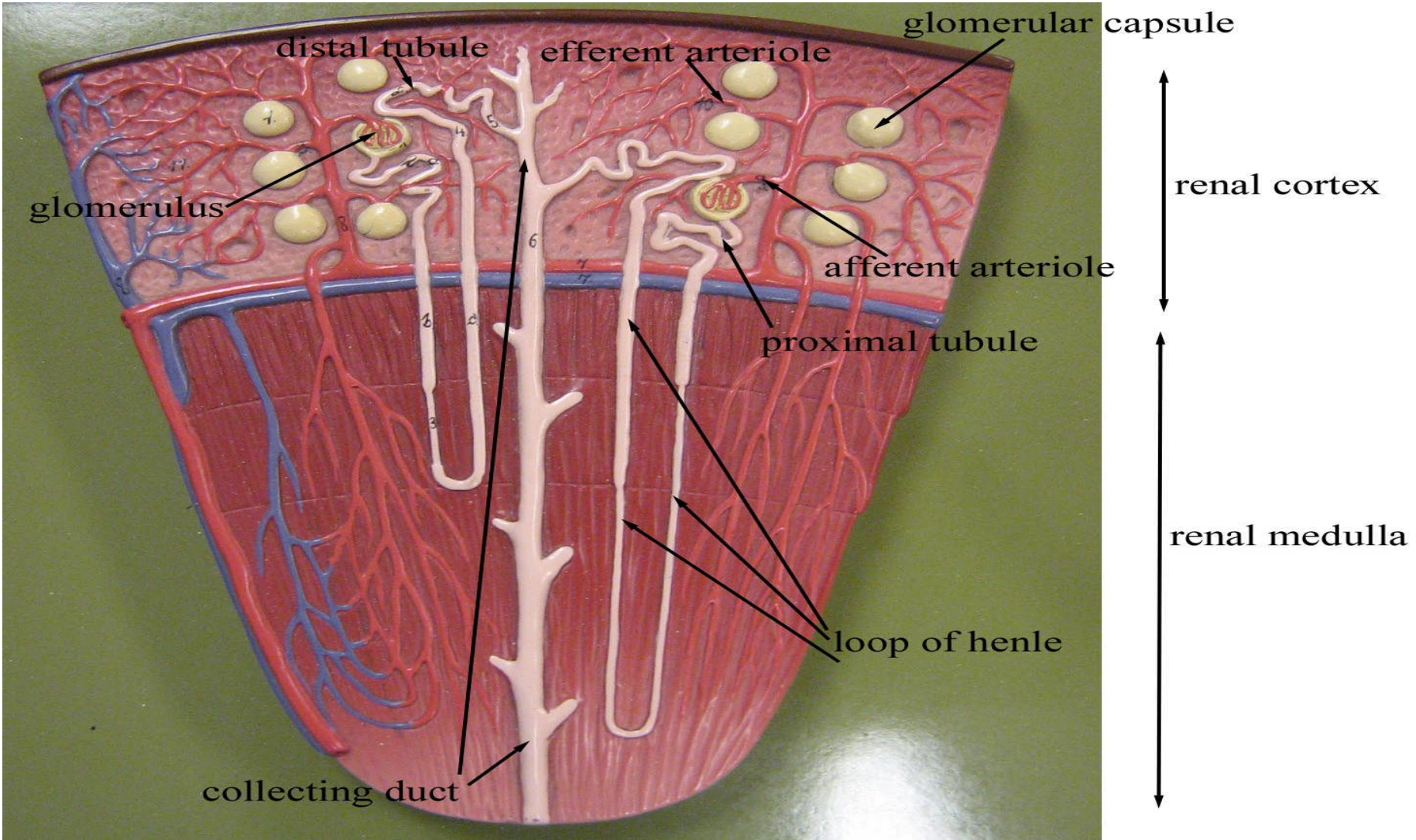


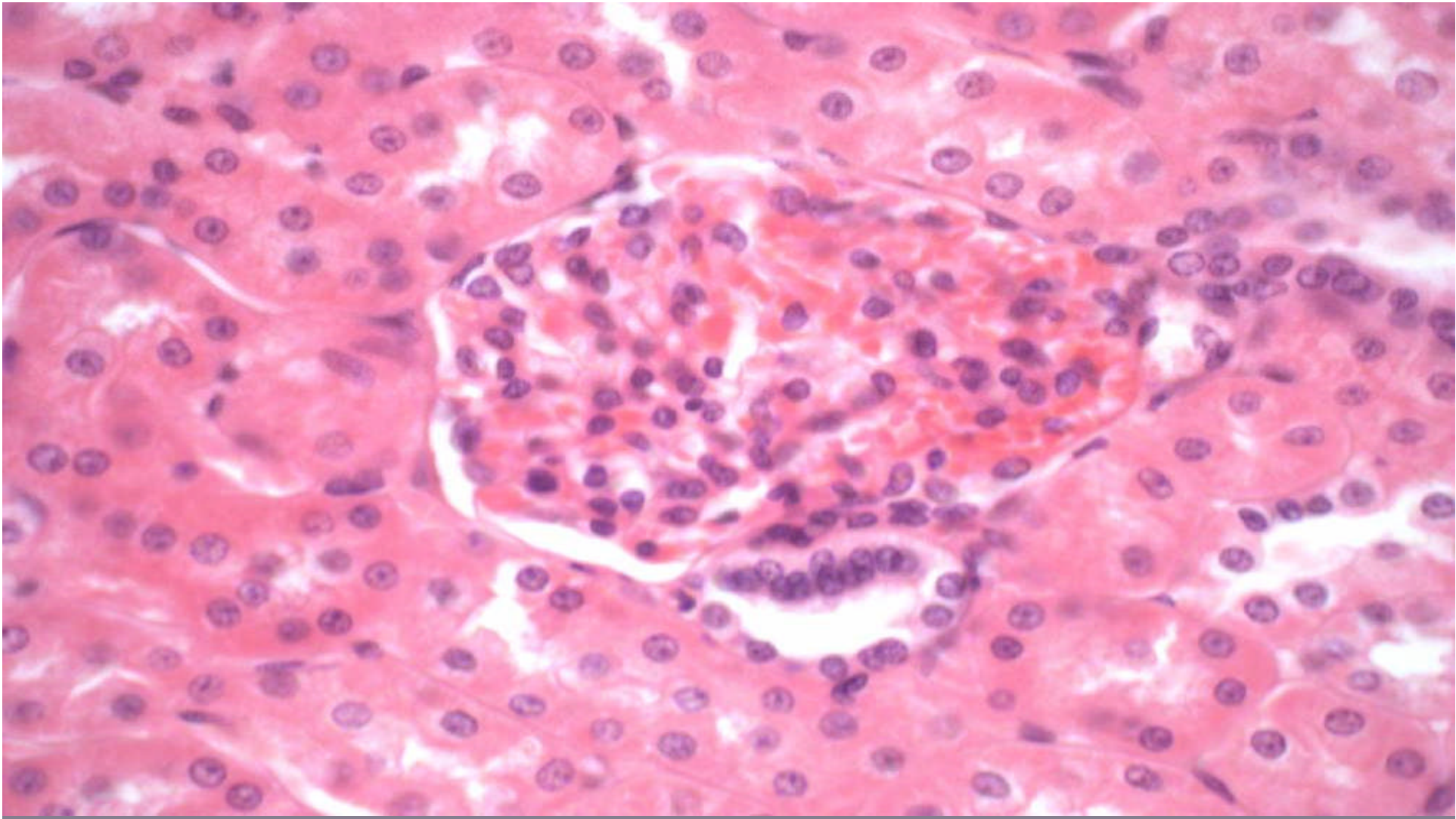


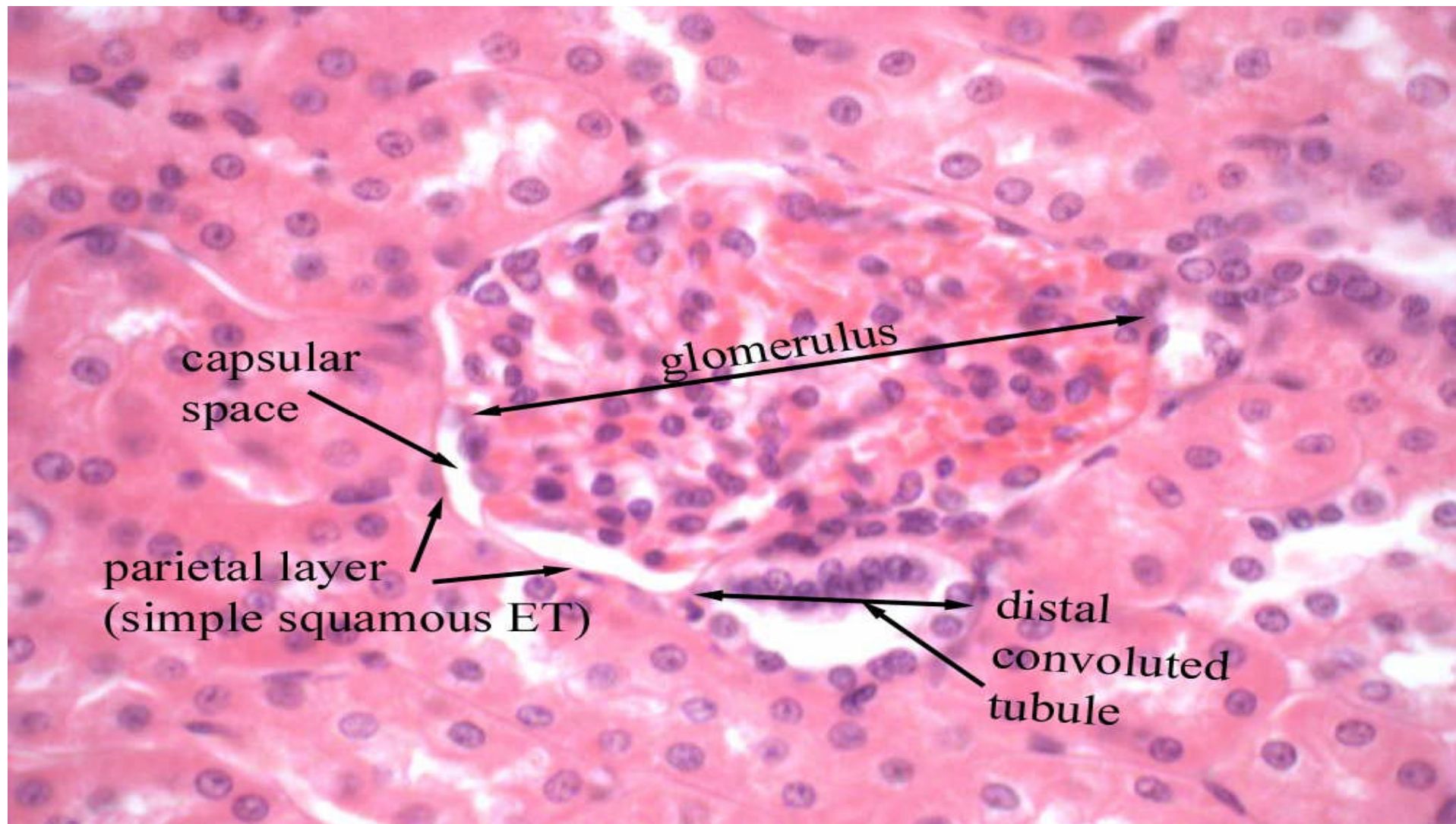


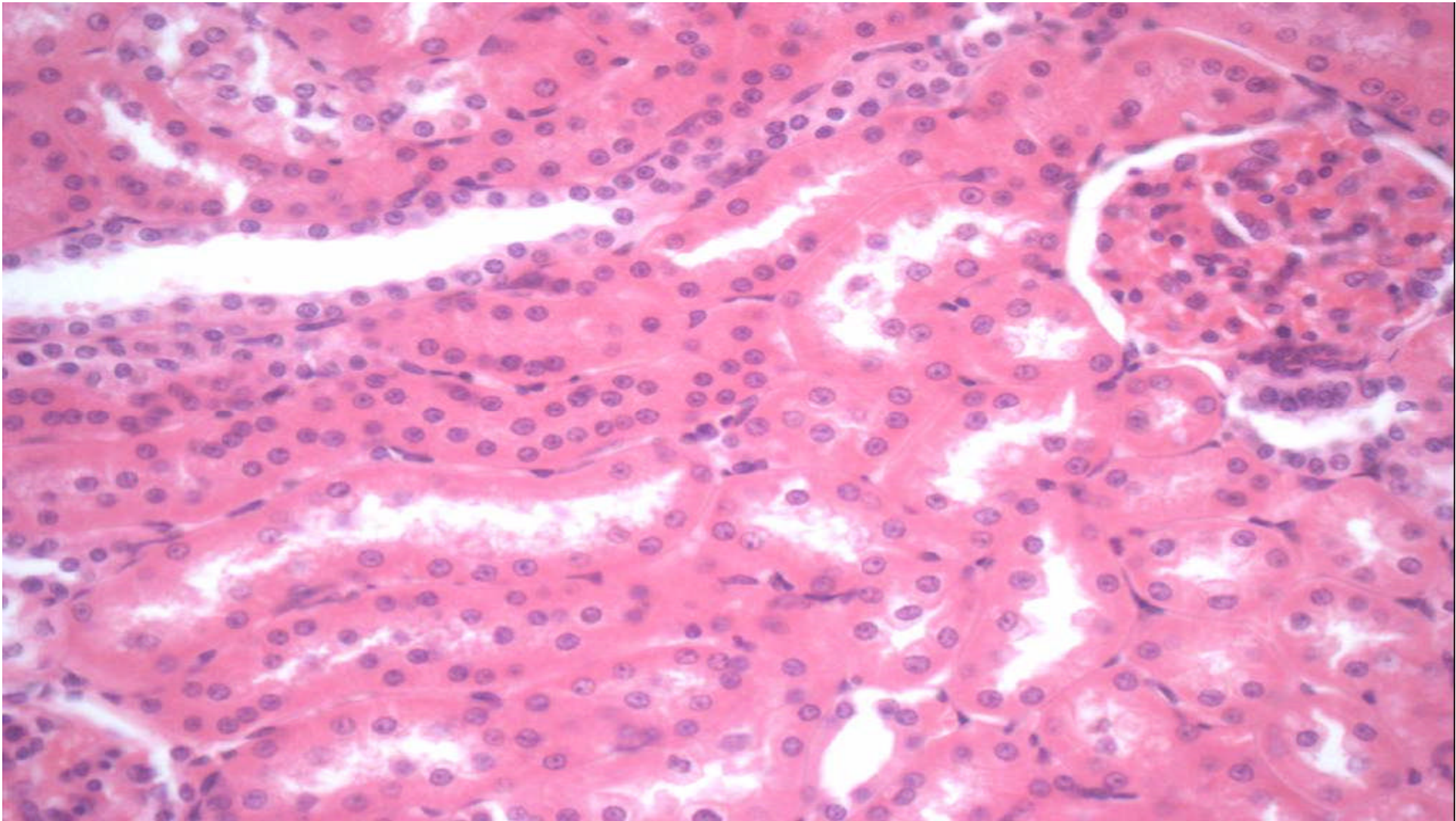


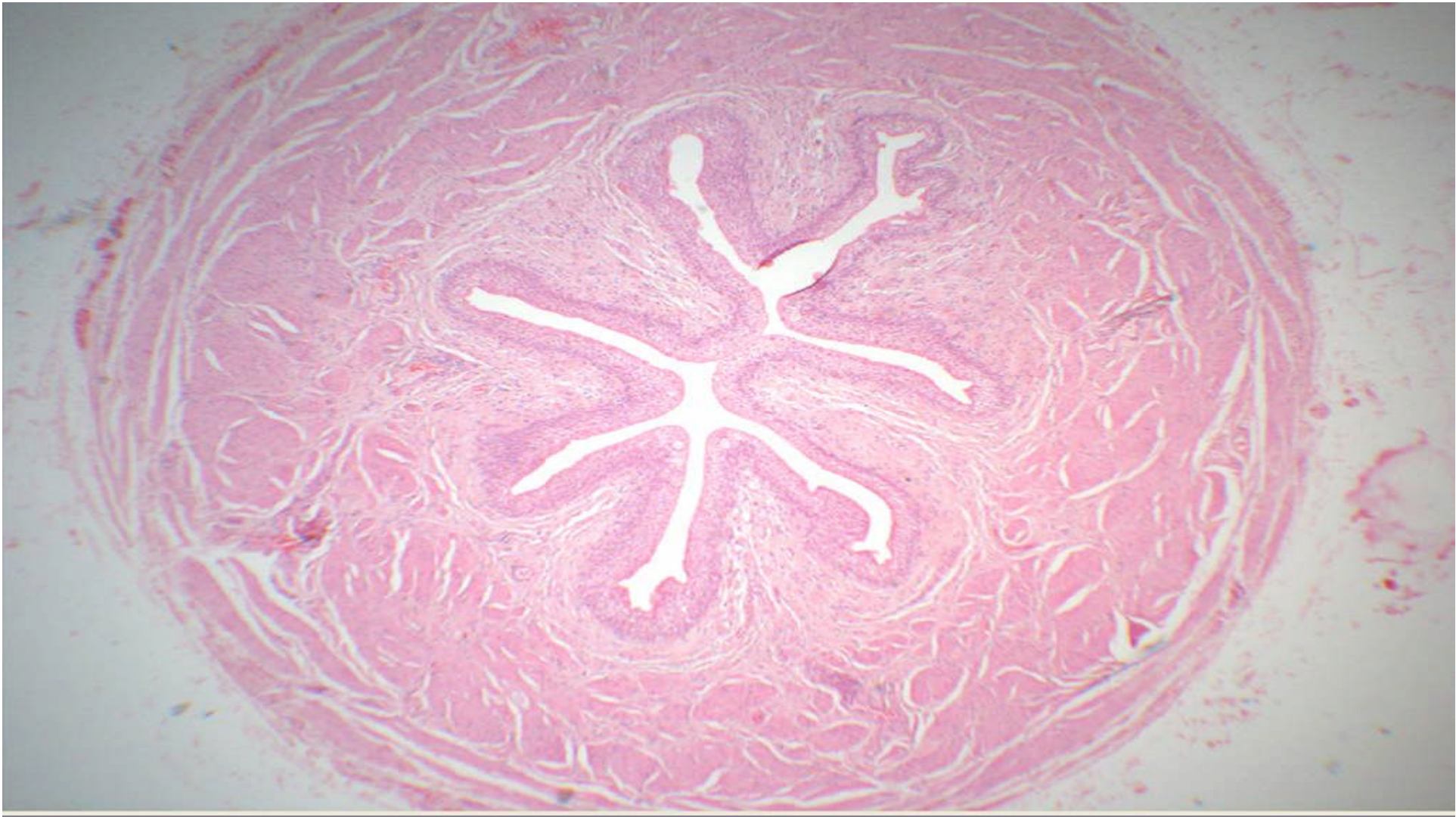


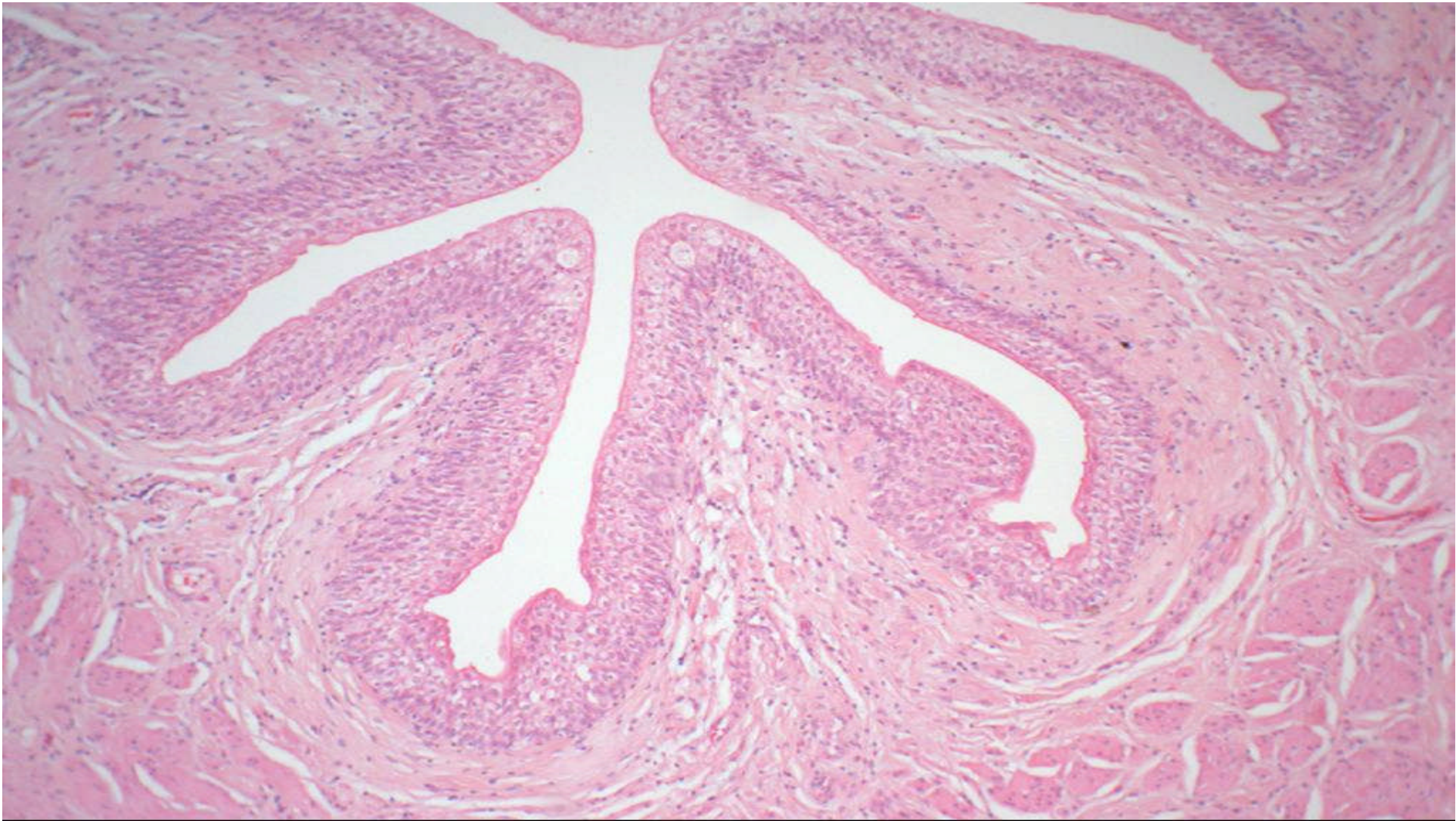

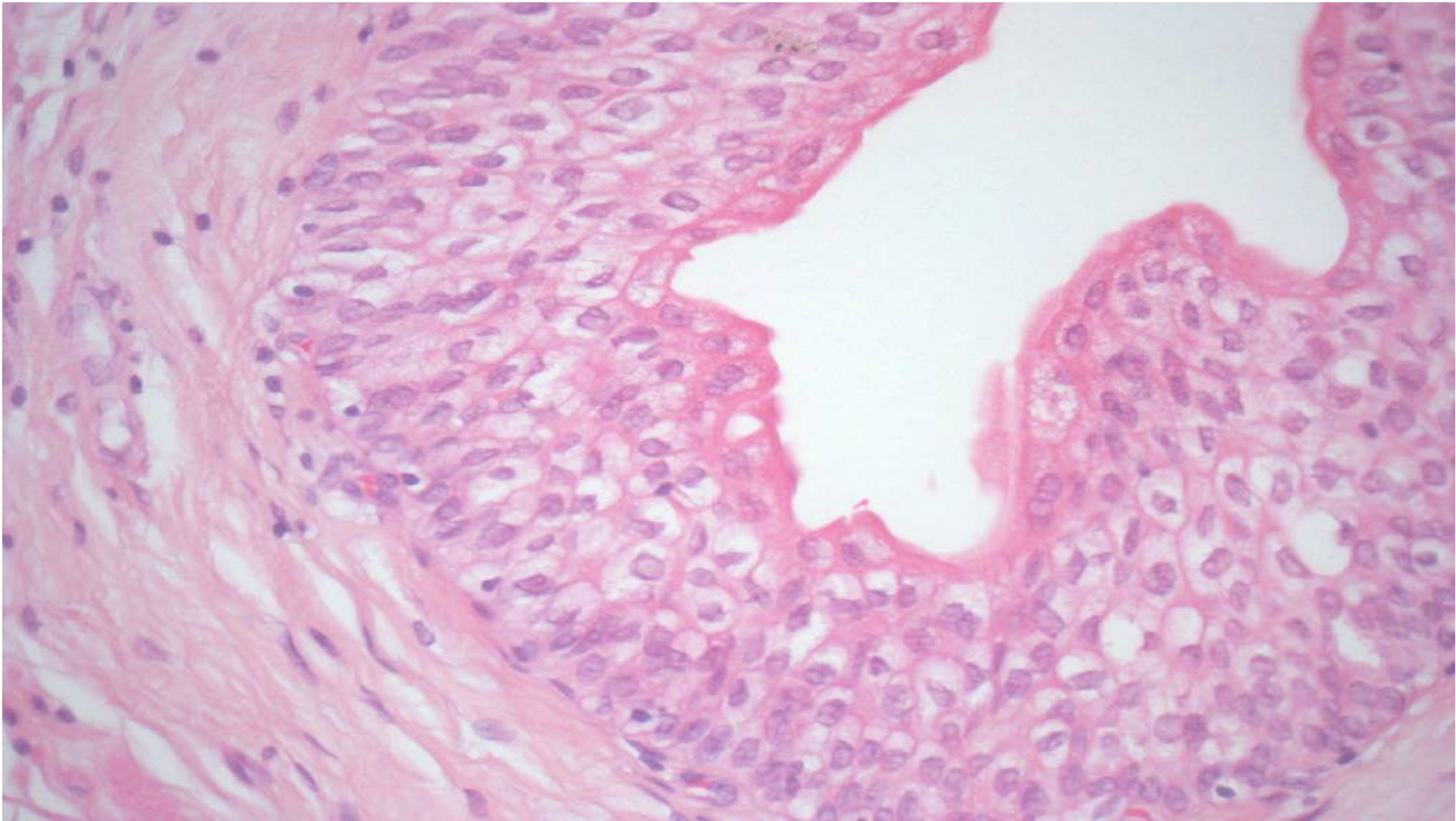


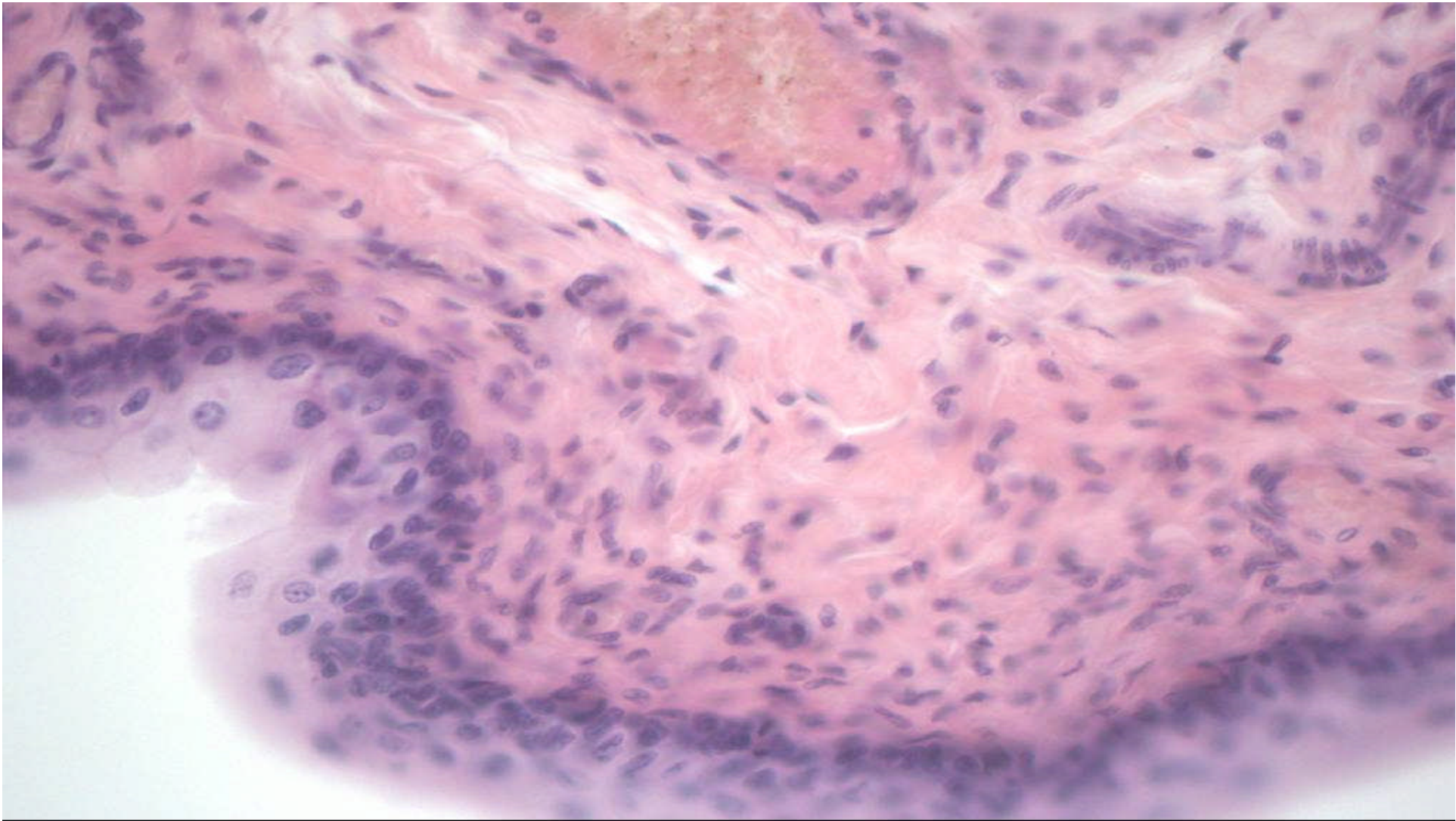


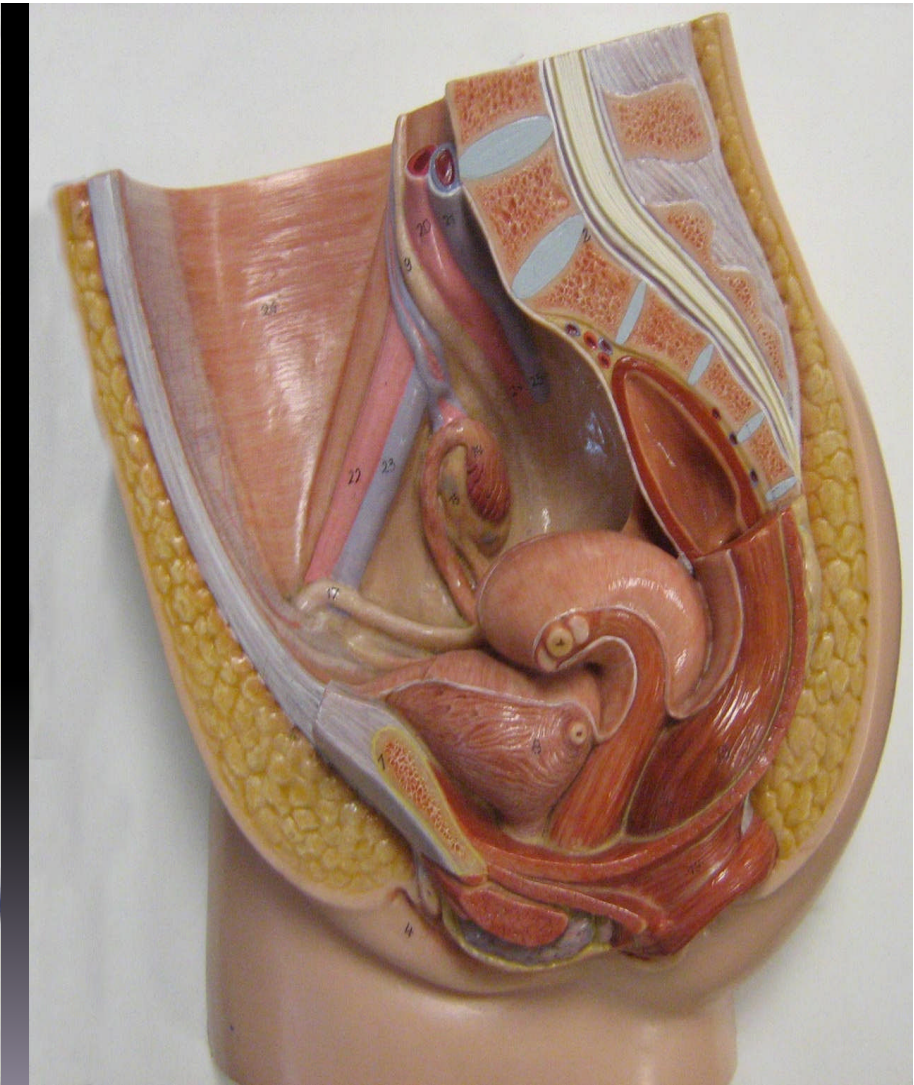
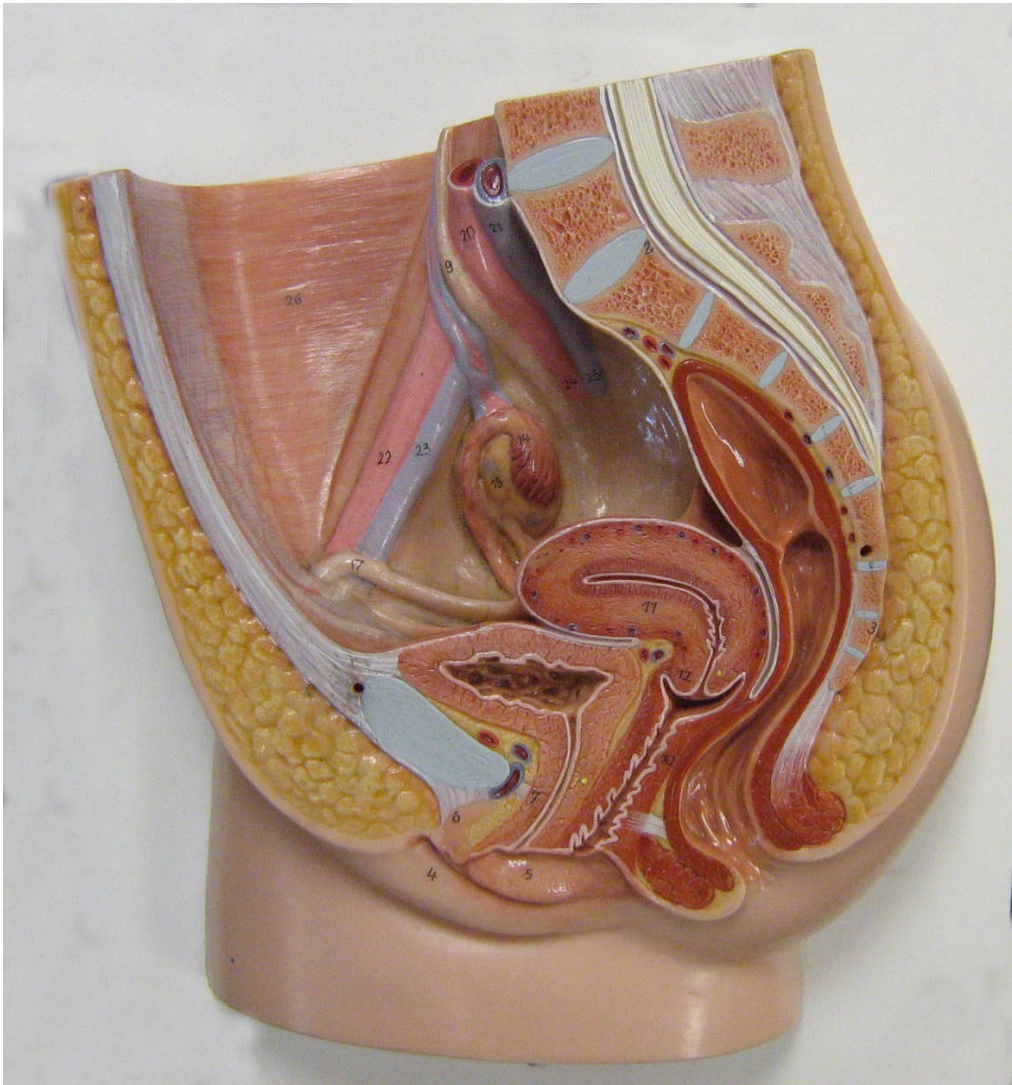


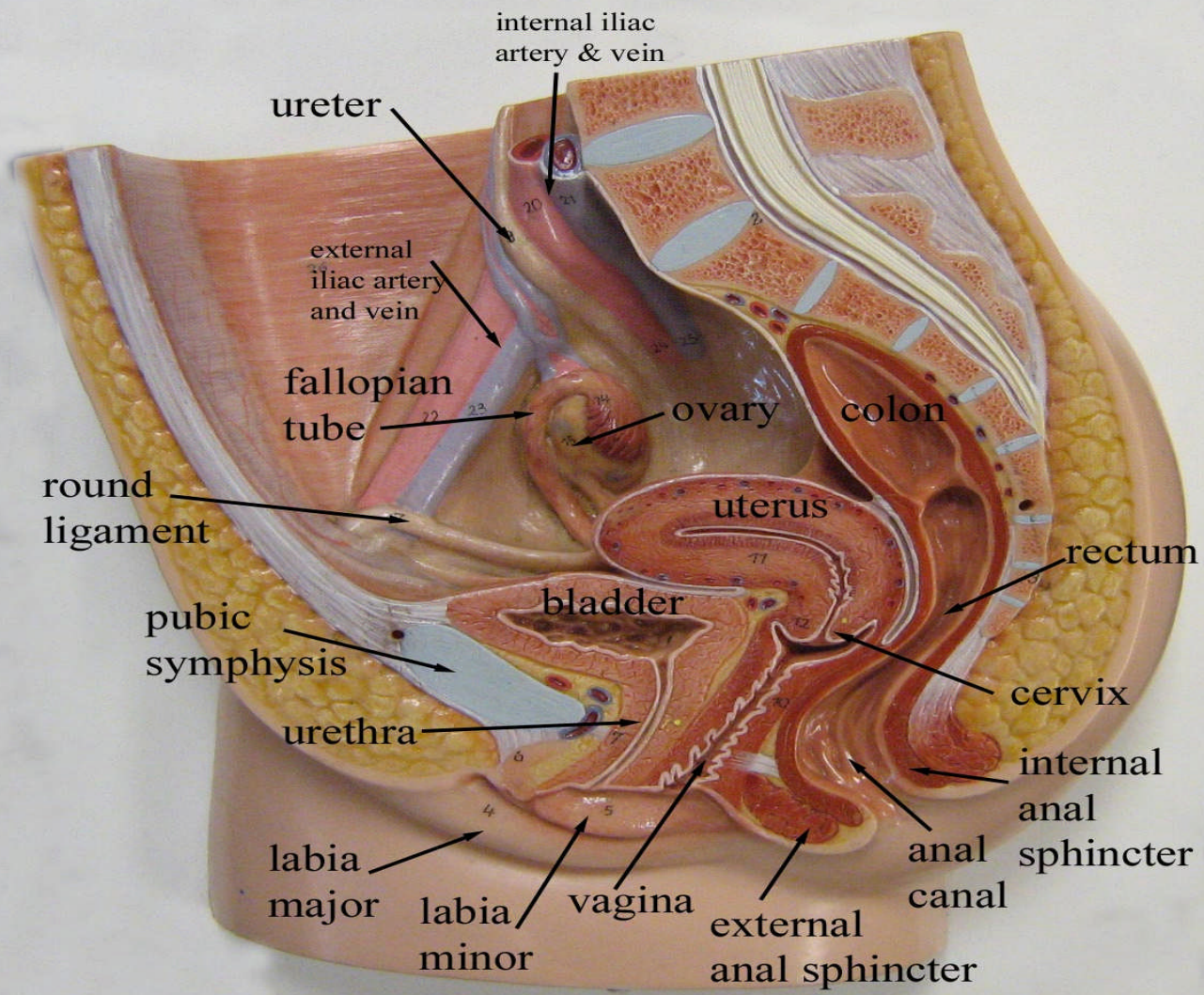


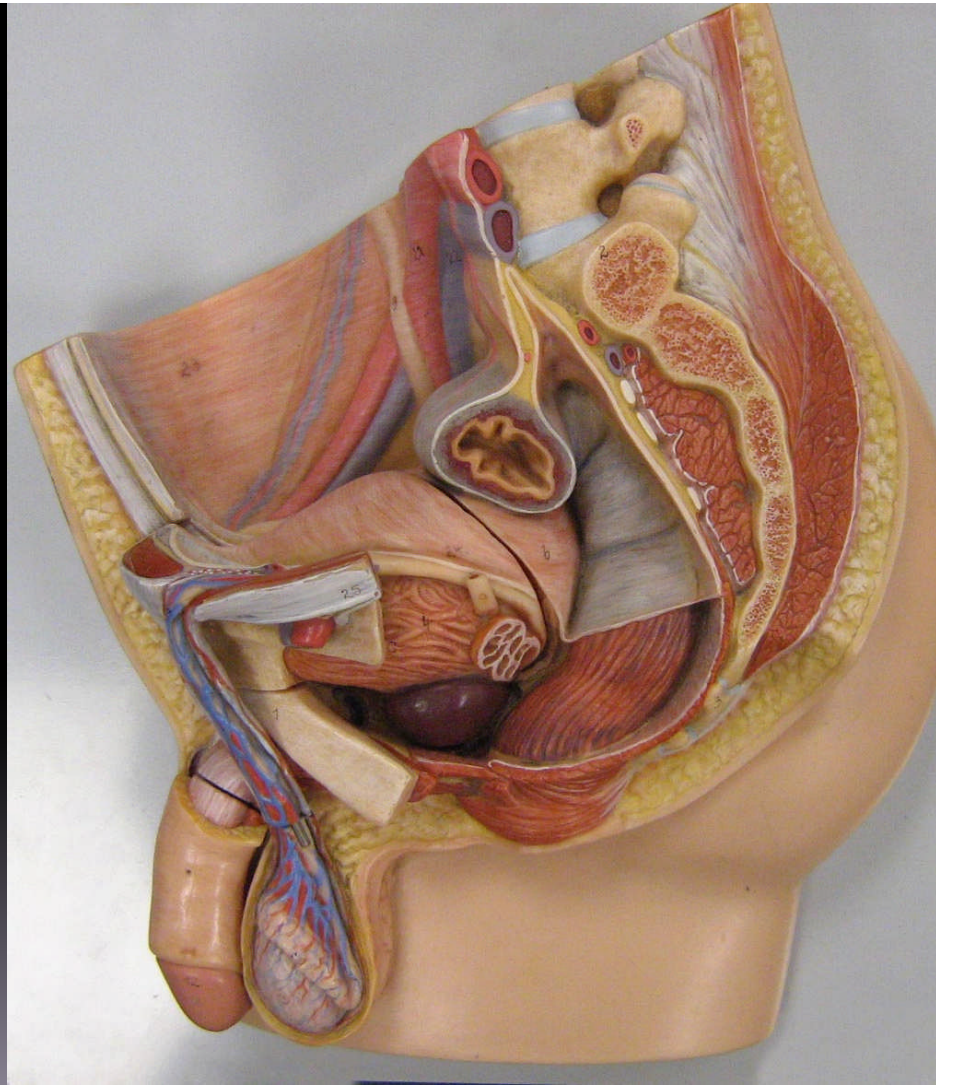
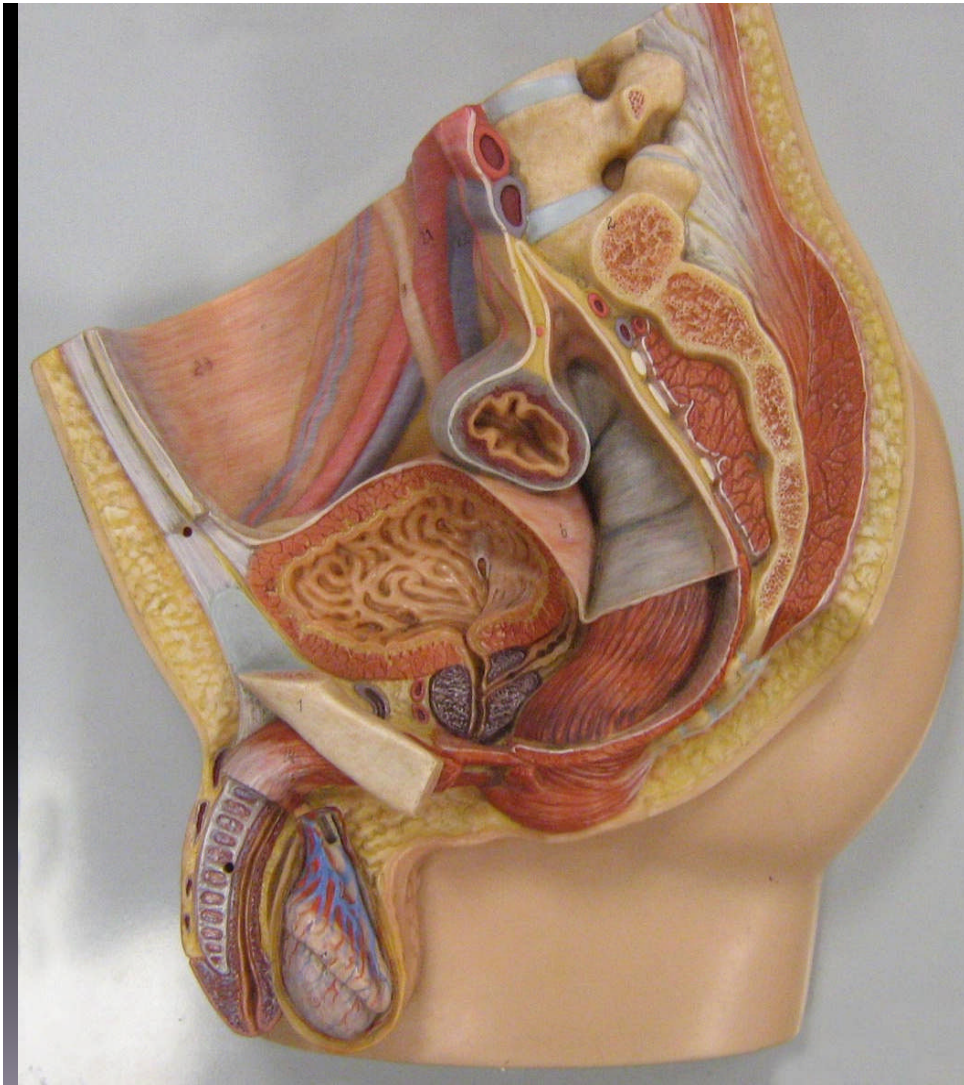


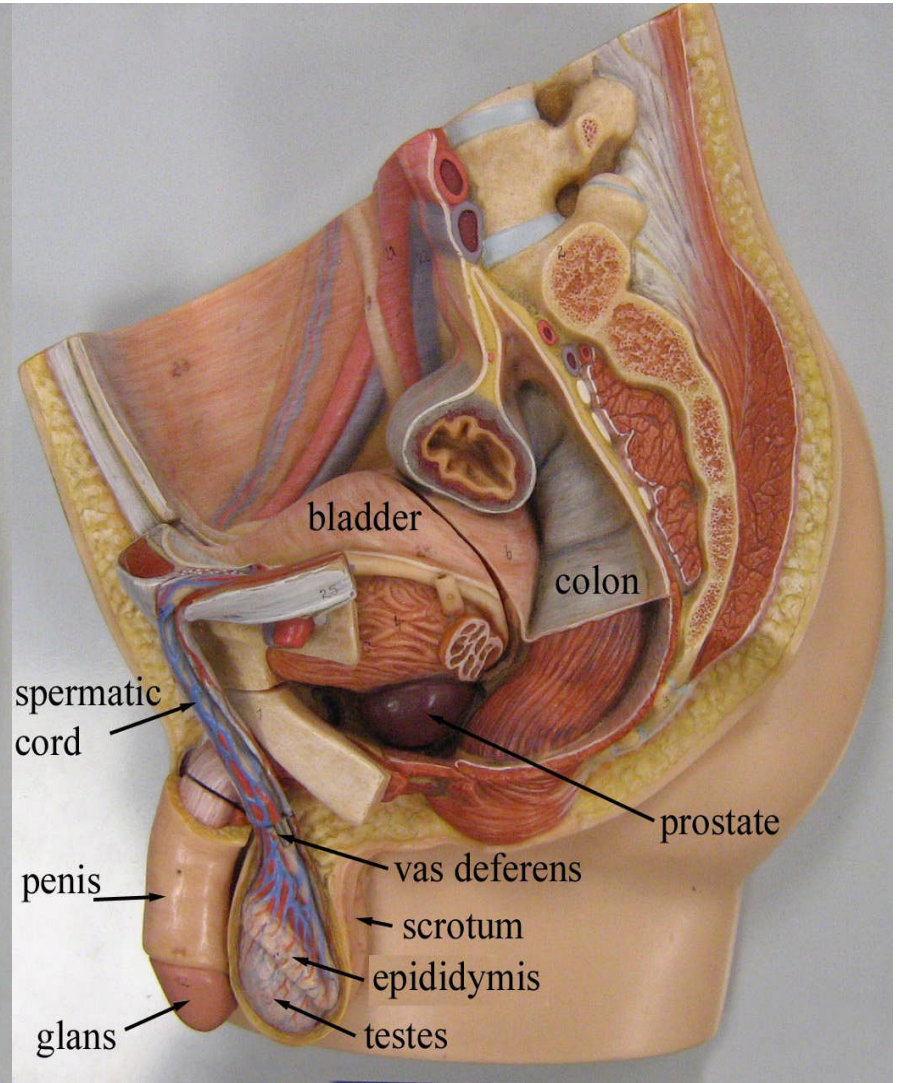
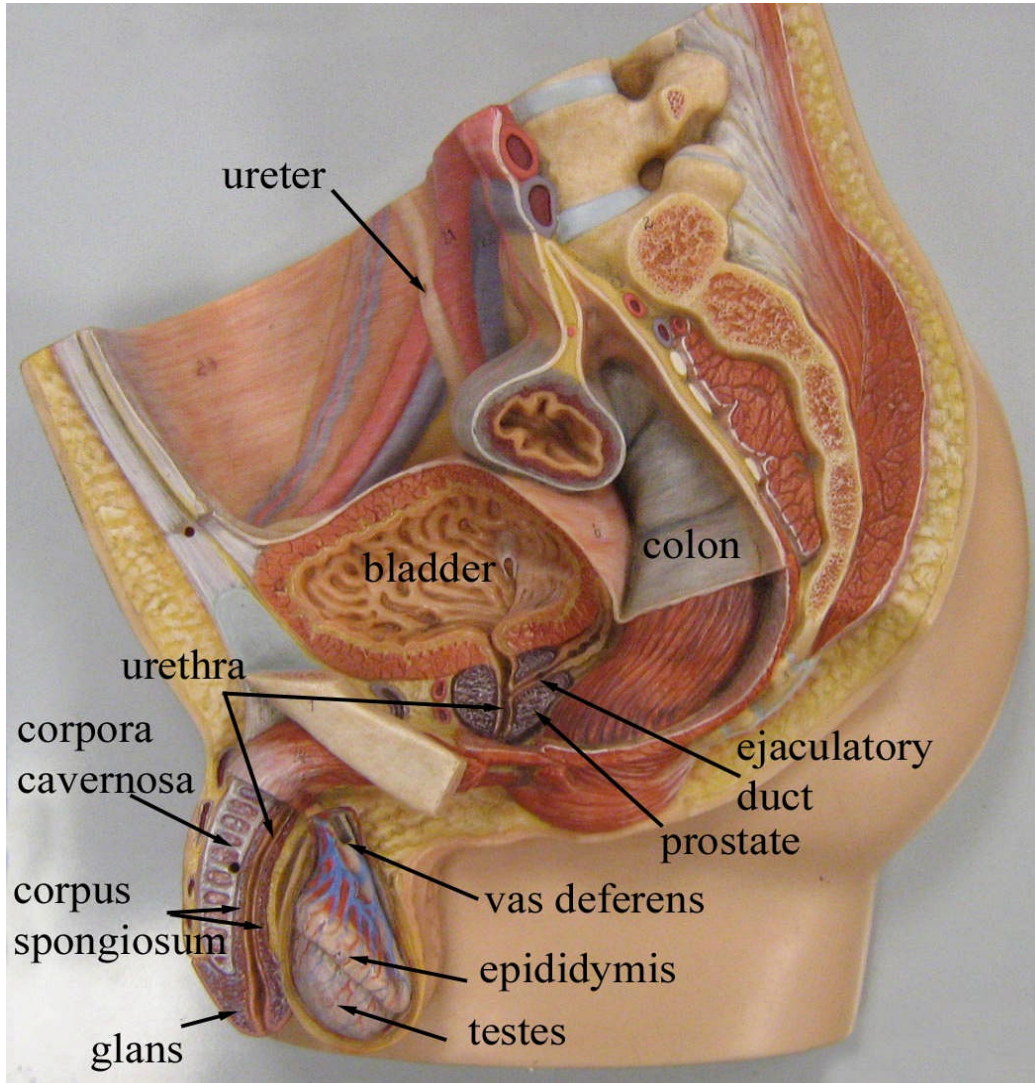


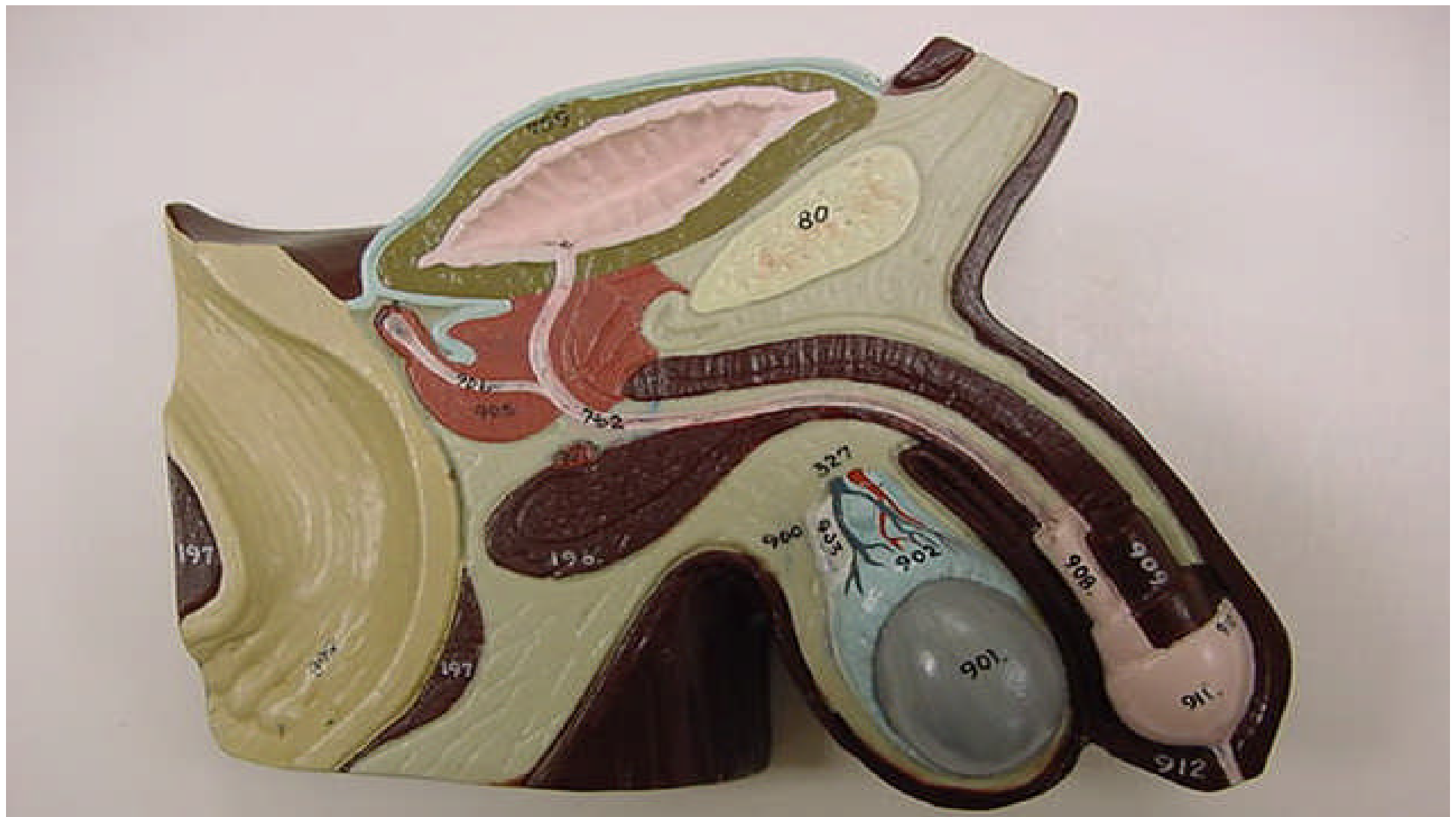


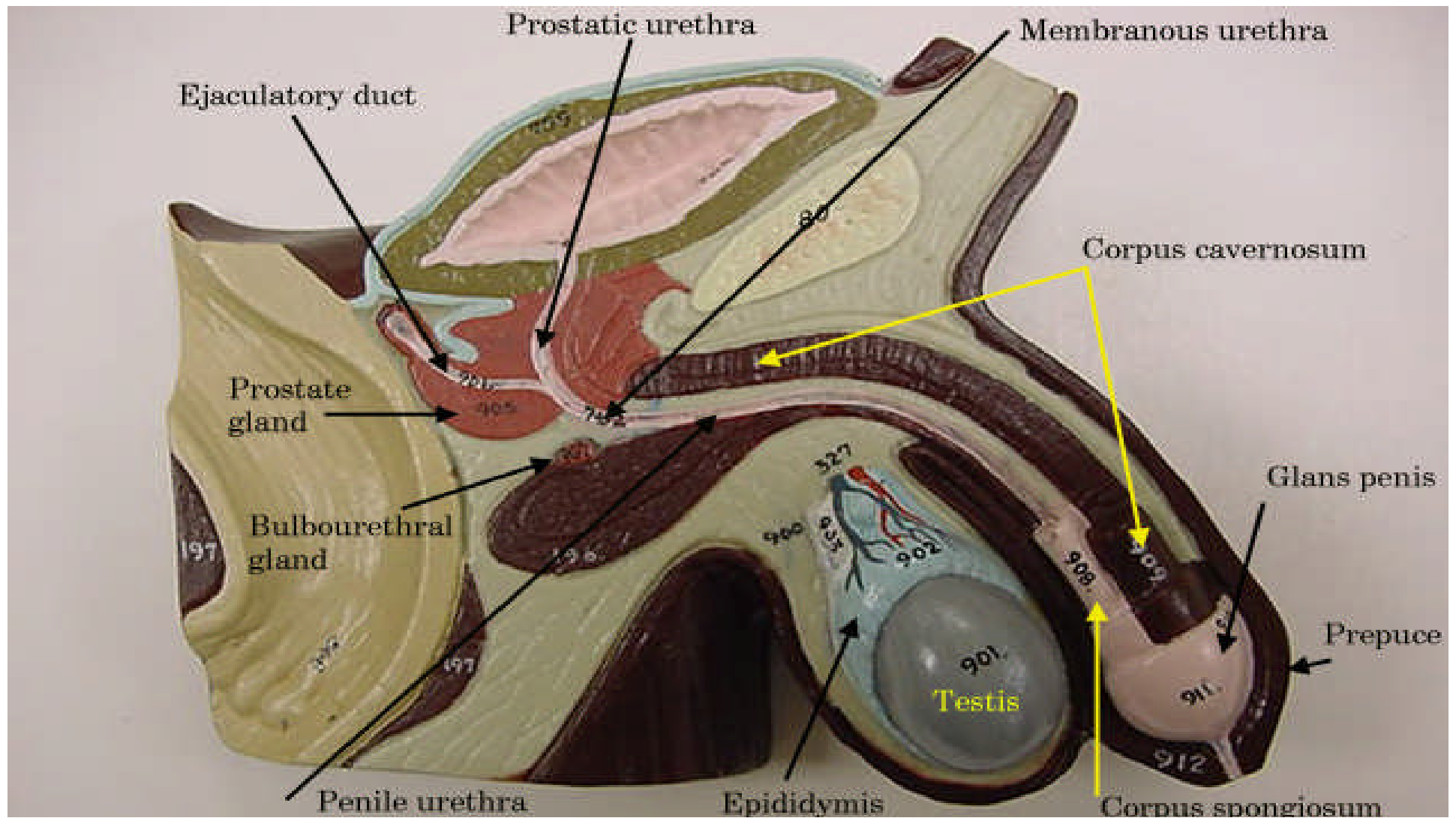


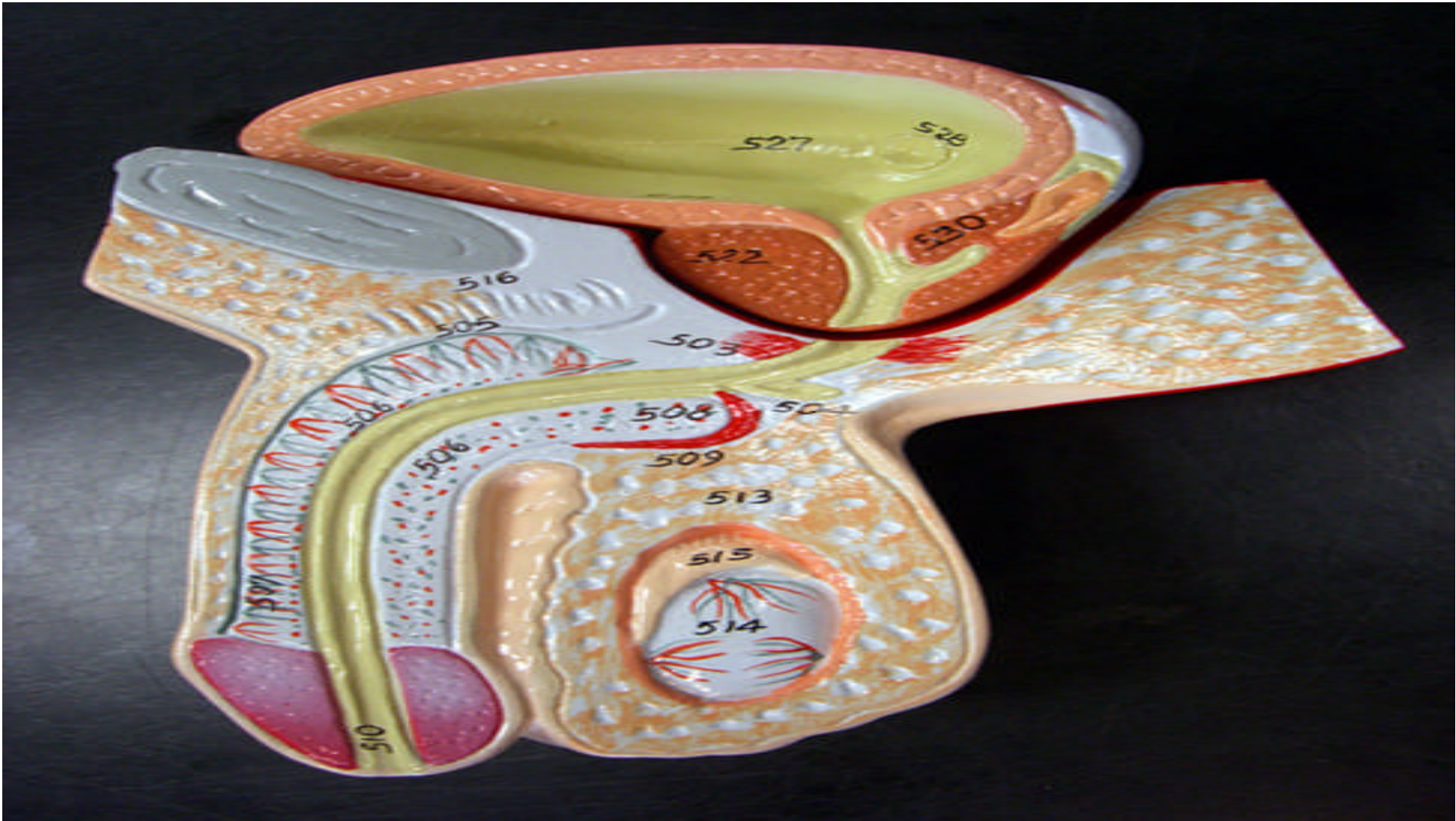


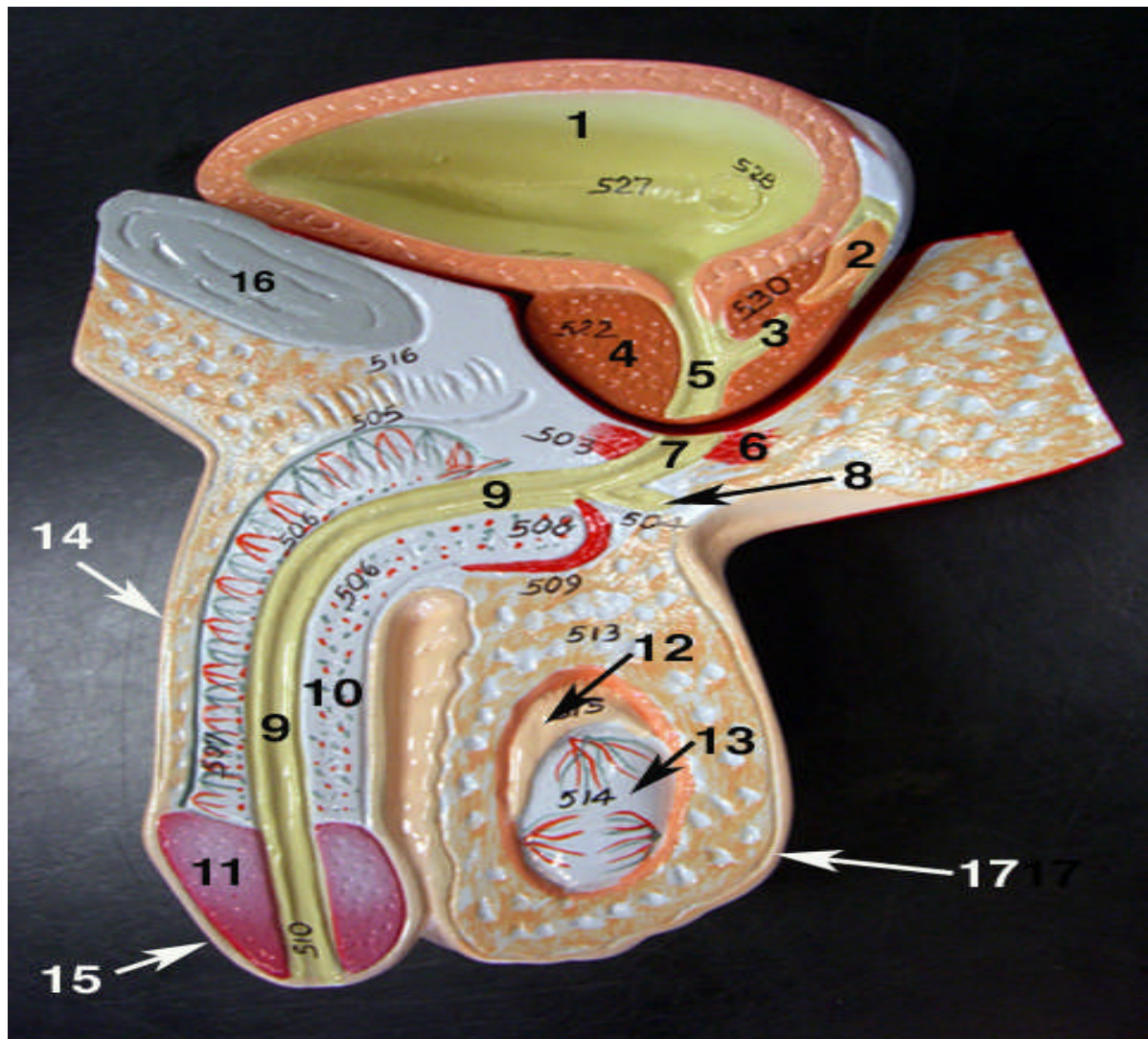




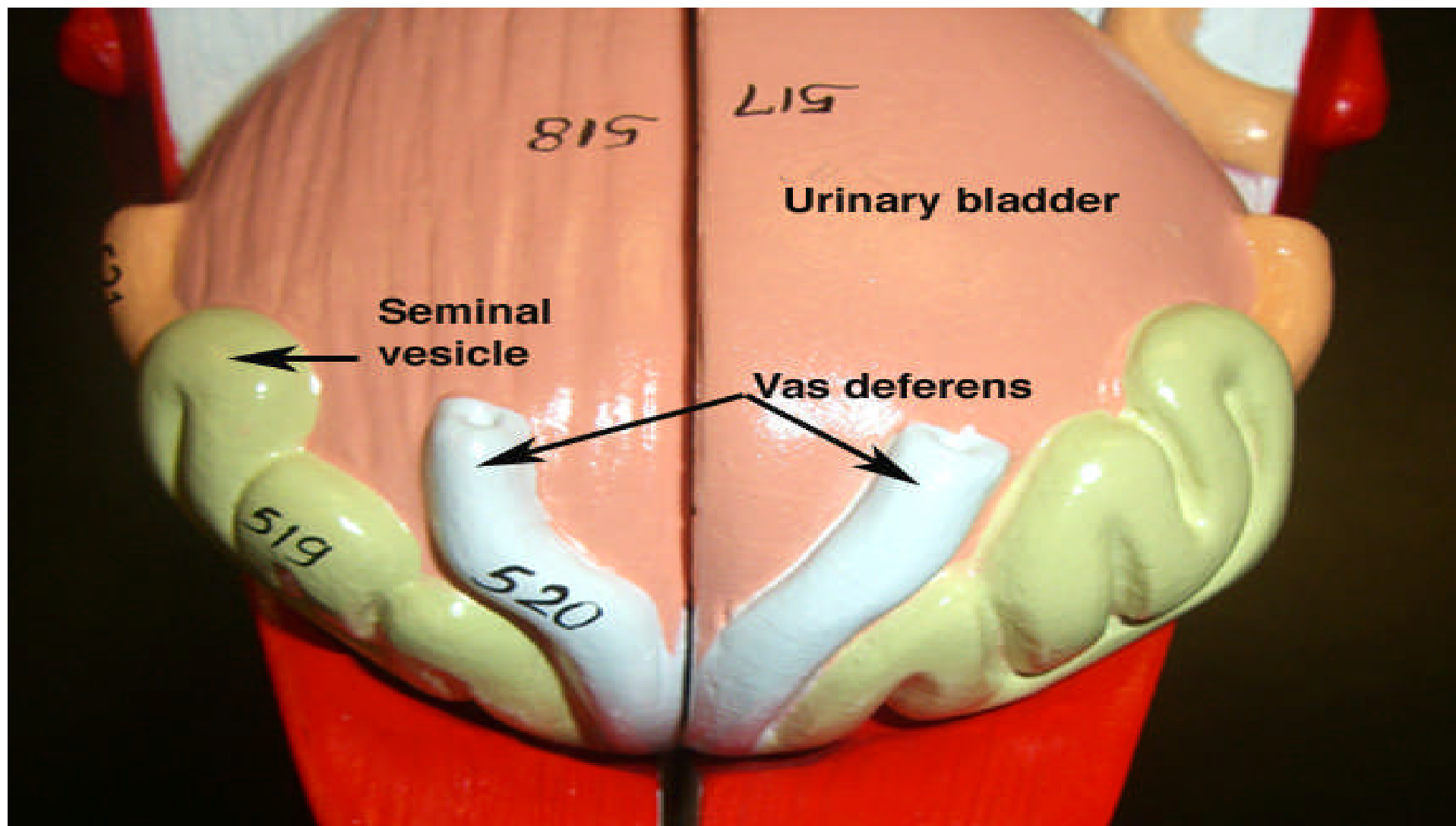




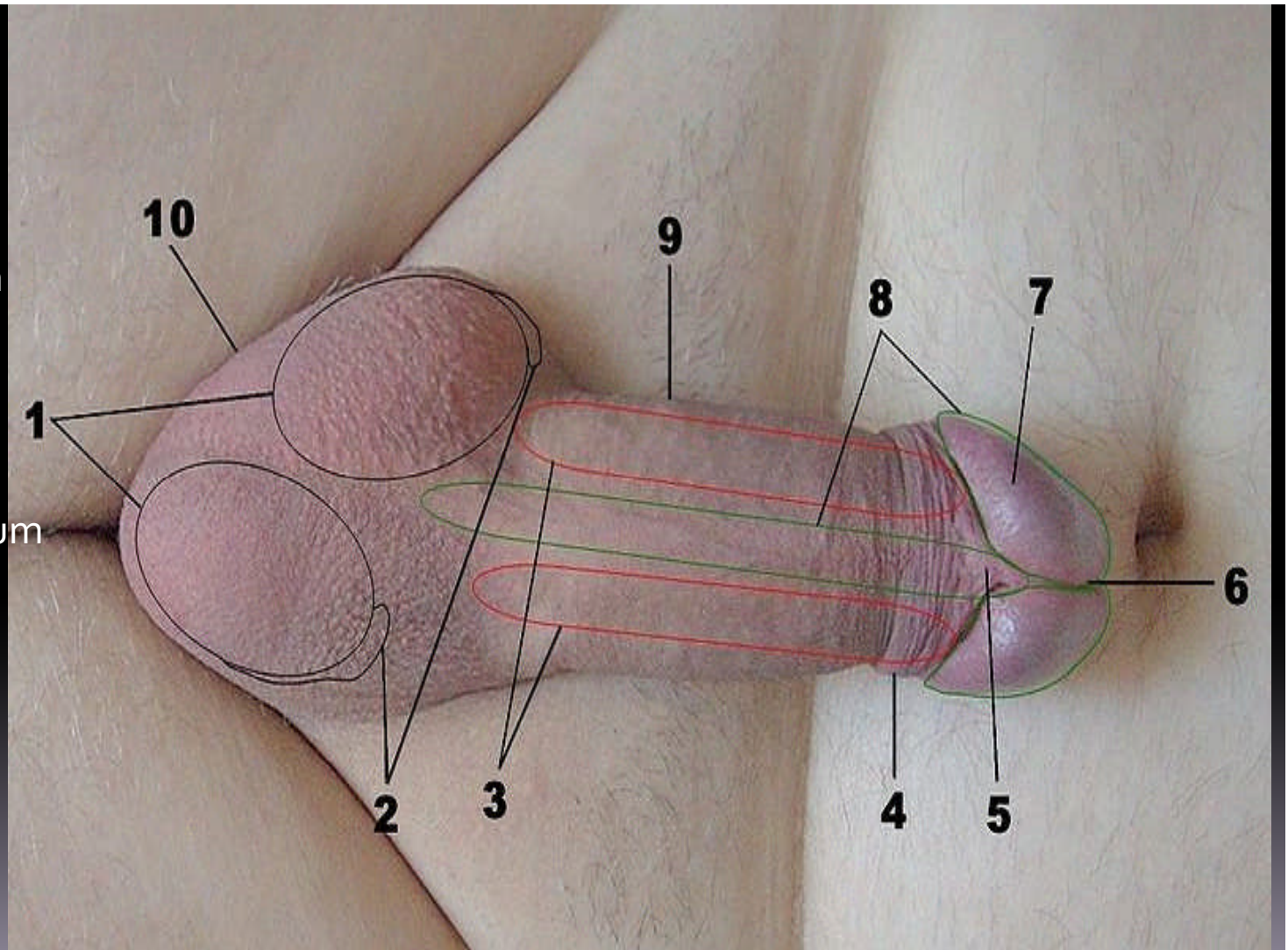



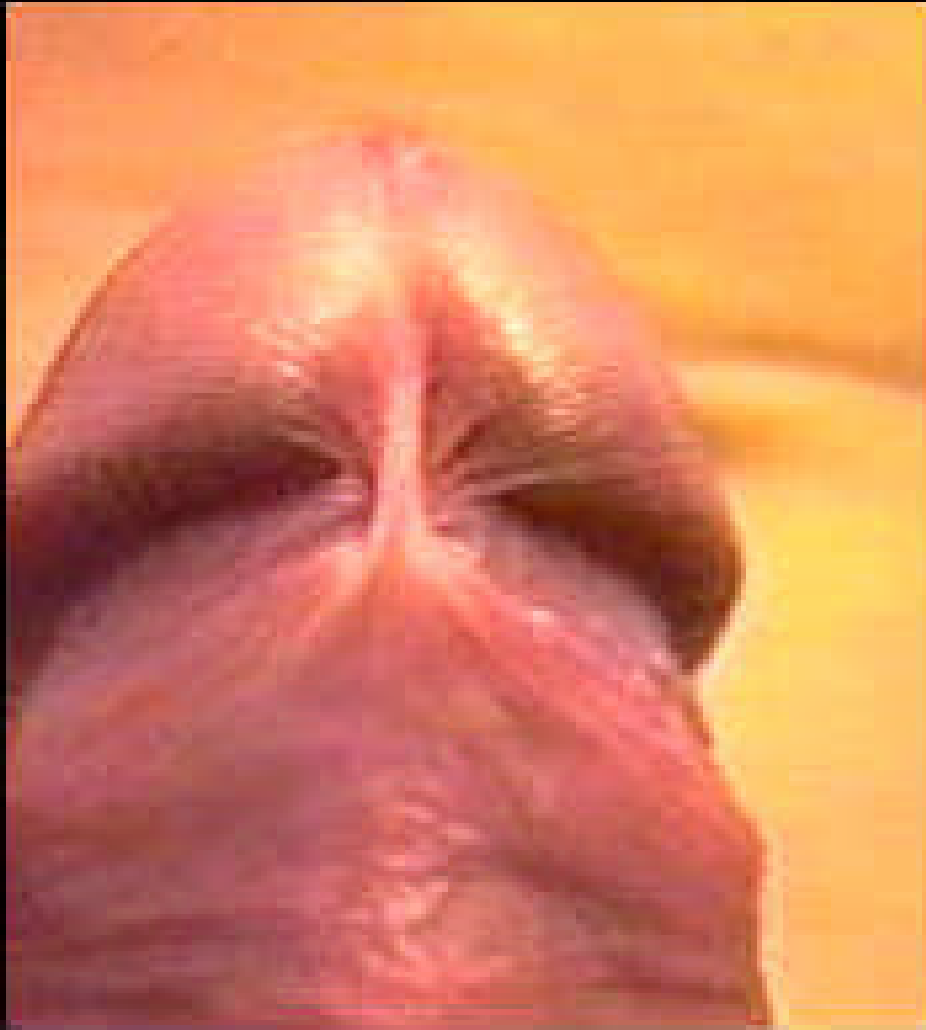
1. Urinary bladder
2. Ampulla of vas deferens
3. Ejaculatory duct
4. Prostate gland
5. Prostatic urethra
6. External urethral sphincter
7. Membranous urethra
8. Bulbourethral gland
9. Penile urethra
10. Corpus spongiosum
11. Glans penis
12. Epididymis
13. Testis
14. Penis
15. Prepuce
16. Pubic bone
17. Scrotum



1. Testicles
2. Epididymis
3. Corpus cavernosa
4. Foreskin
5. Frenulum
6. Urethral opening
7. Glans penis
8. Corpus spongiosum
9. Penis
10. Scrotum

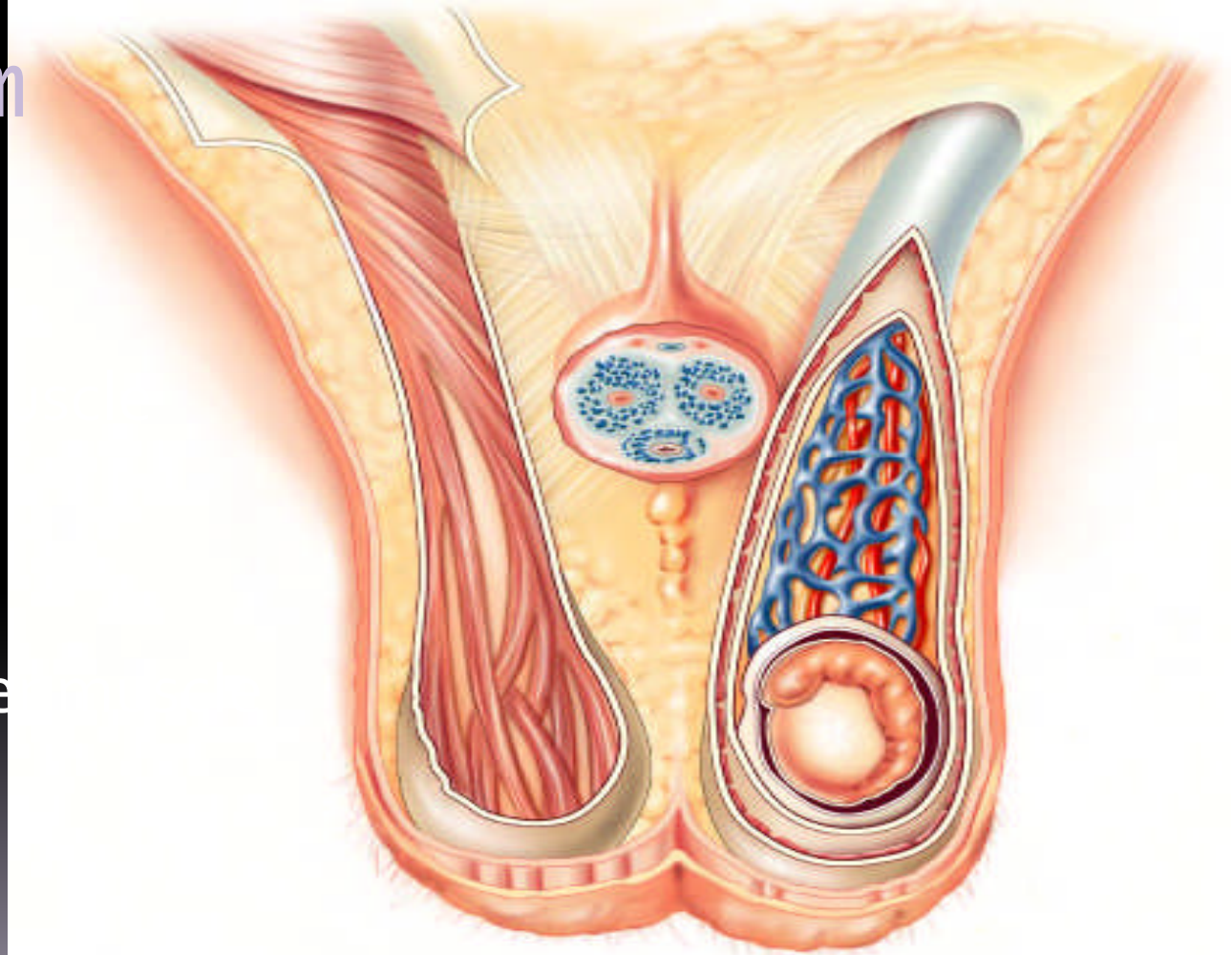




A view of the frenulum, foreskin retracted

Scrotum

- Skin
- Dartos m
(smooth)
- Septum
- Cremaster
(skeletal)



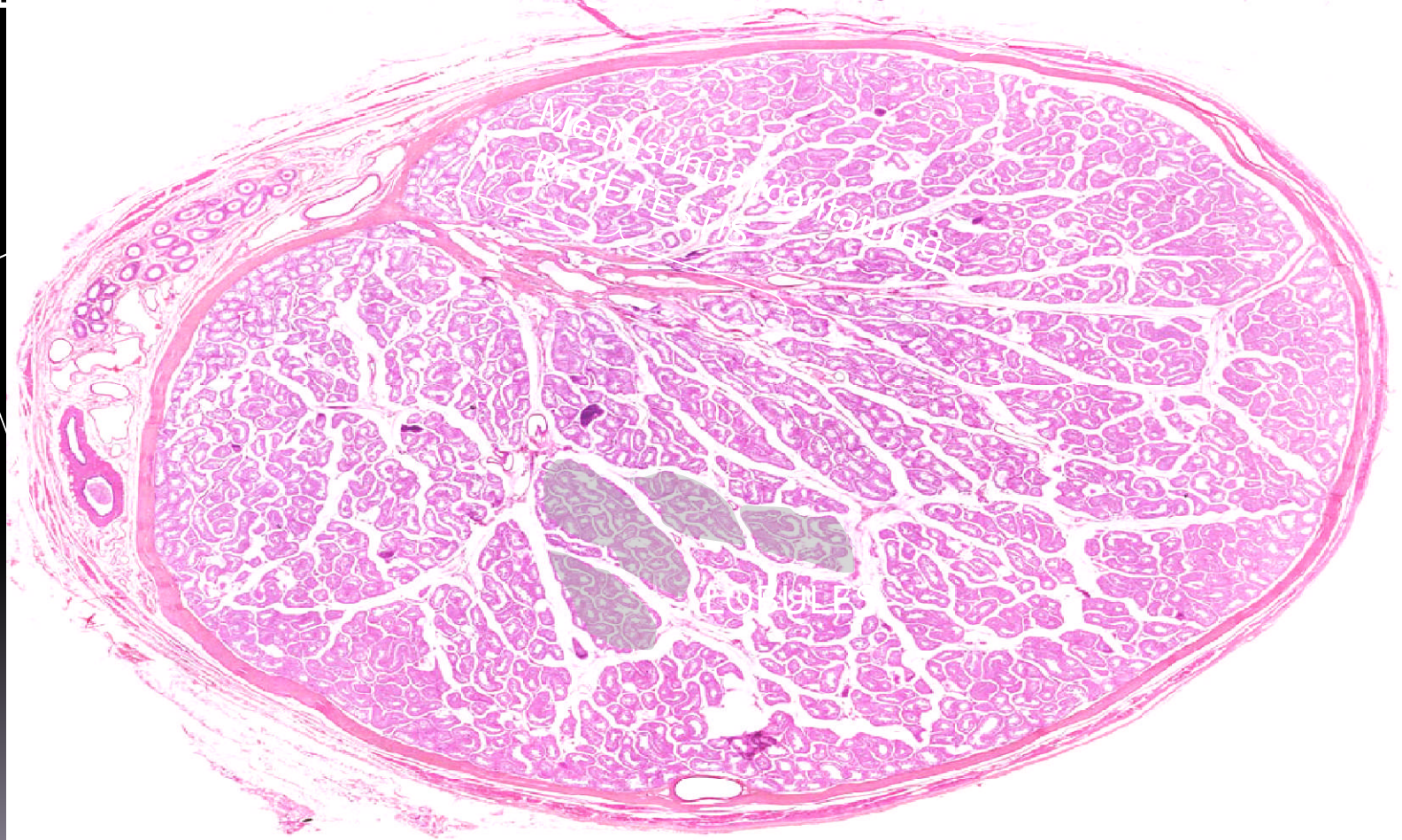
24.2

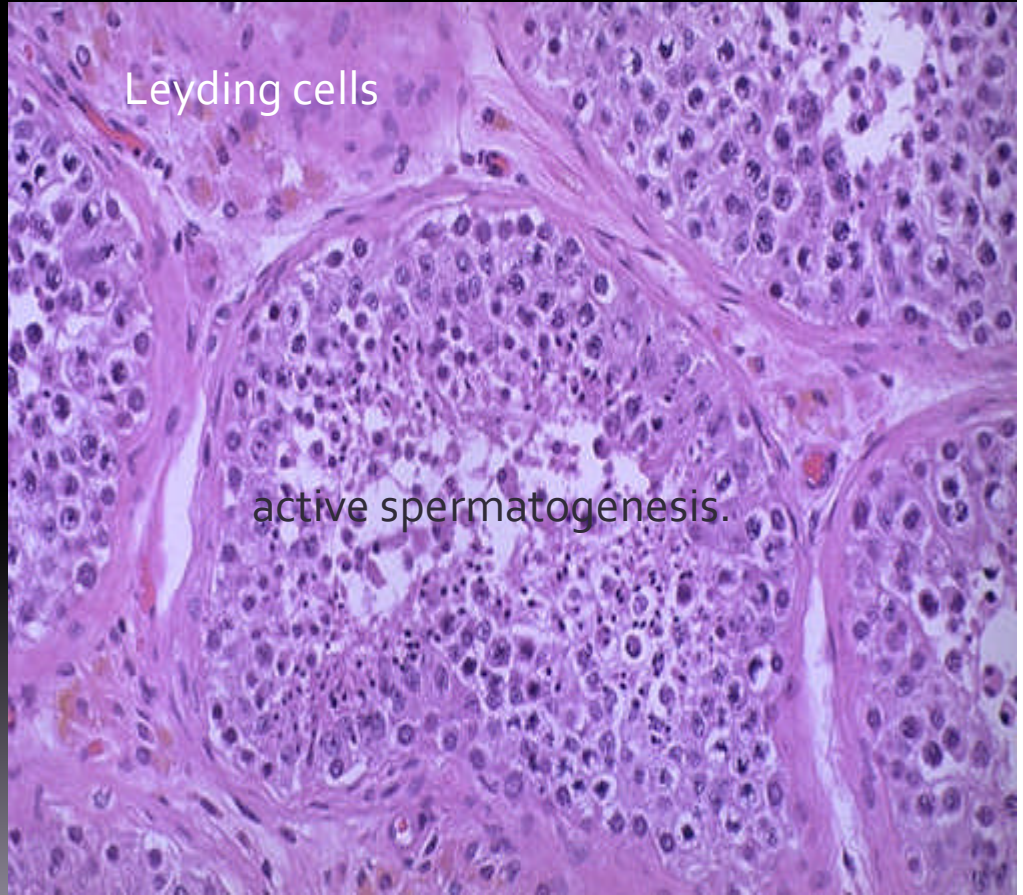
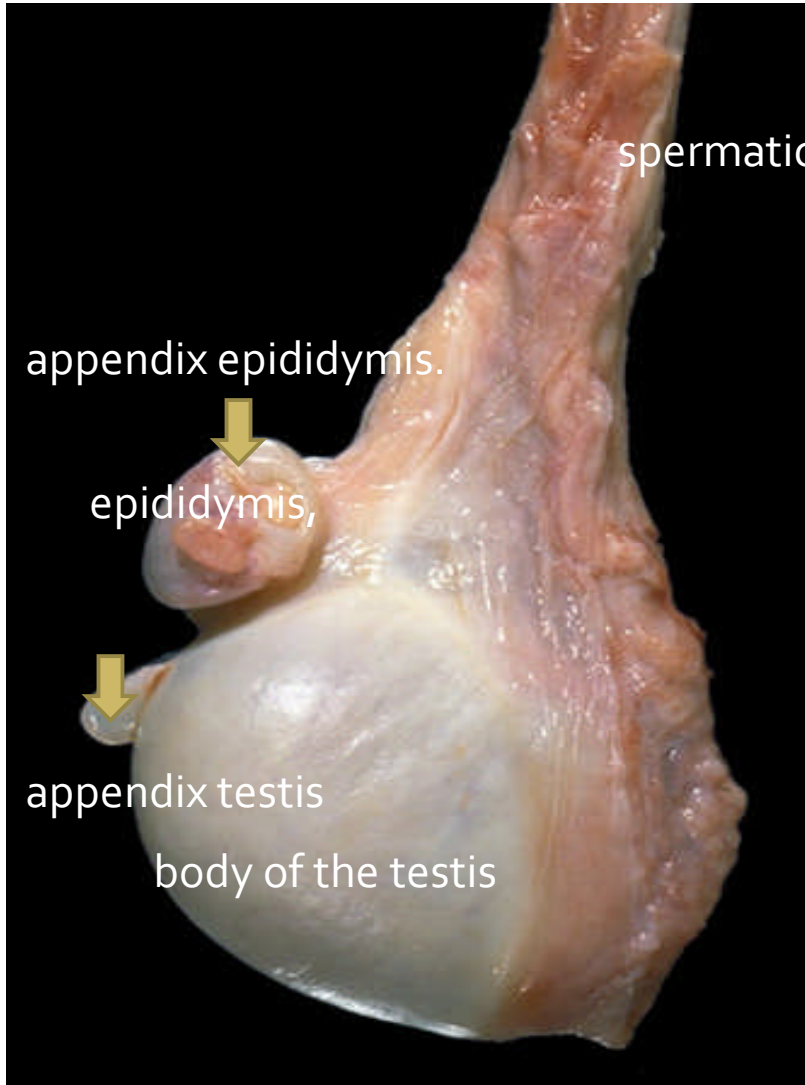
MALE REPRODUCTIVE SYSTEM

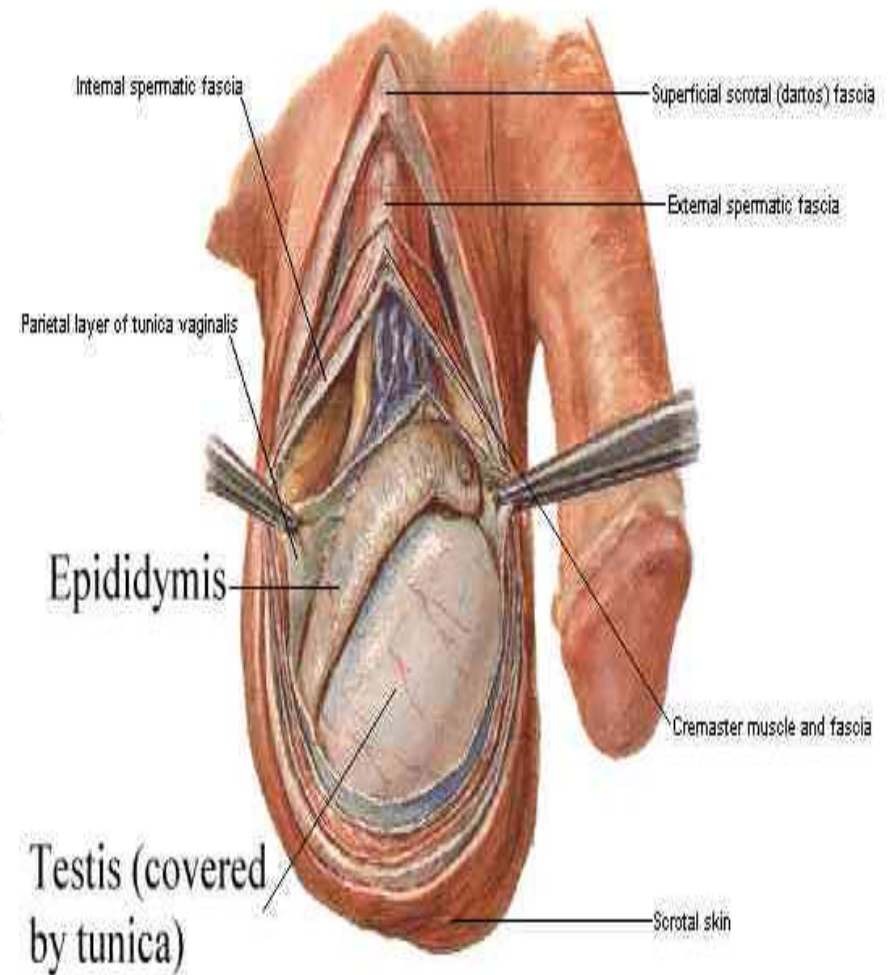
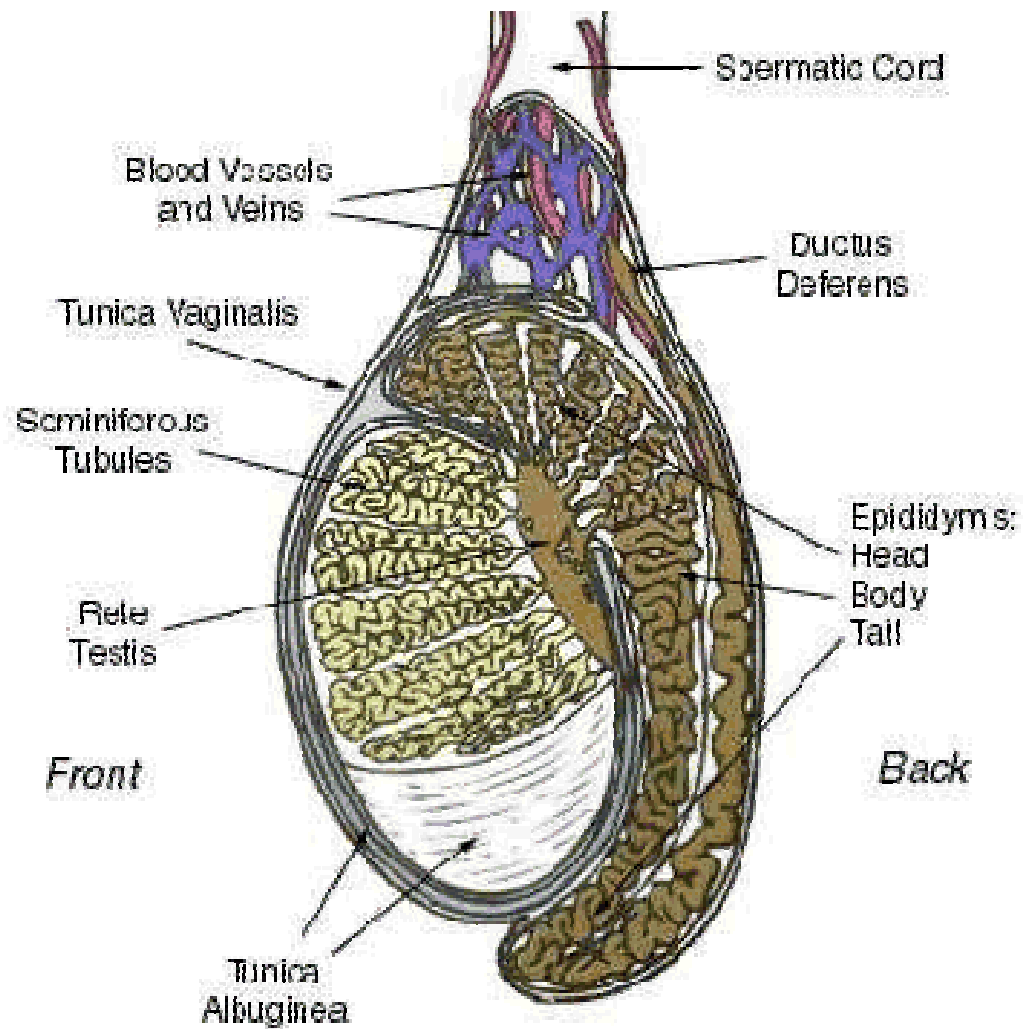
TUNICA

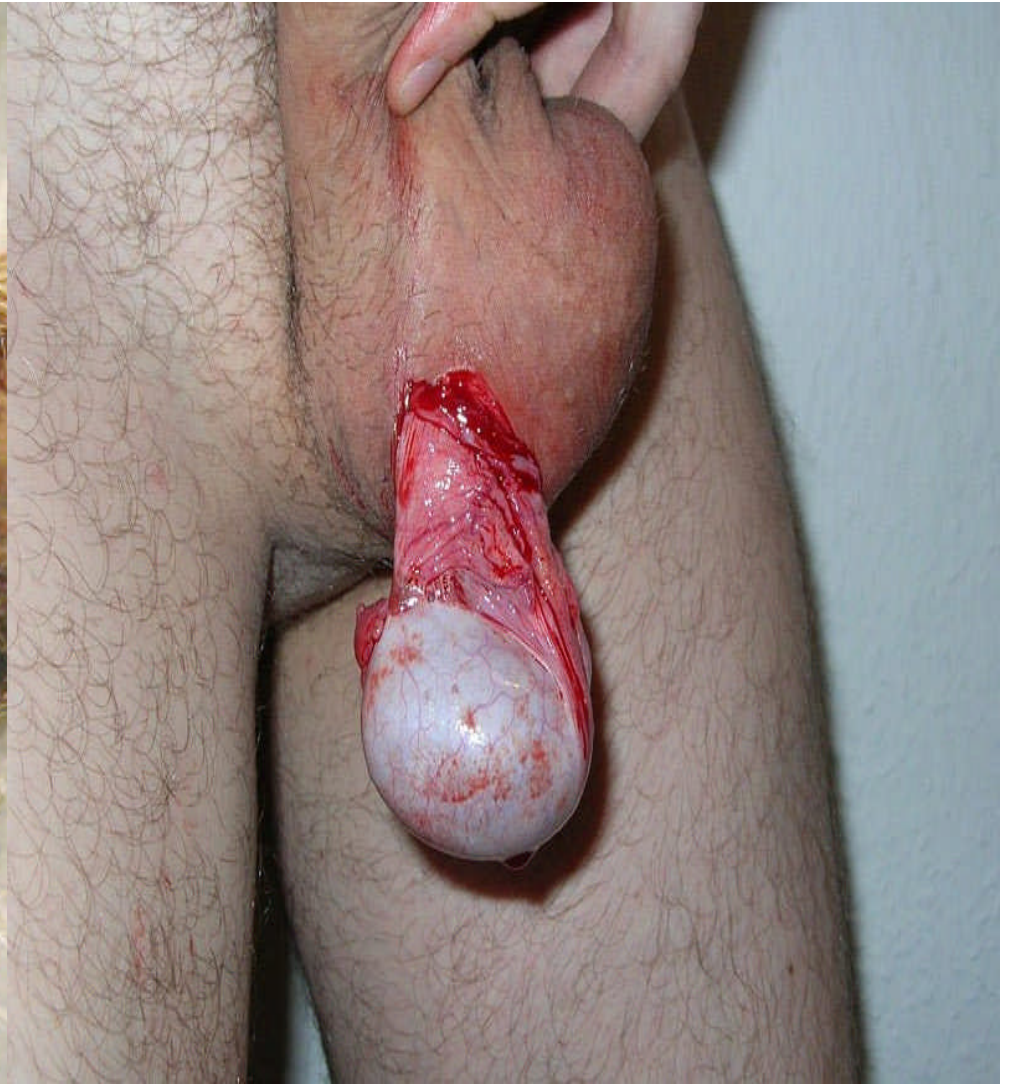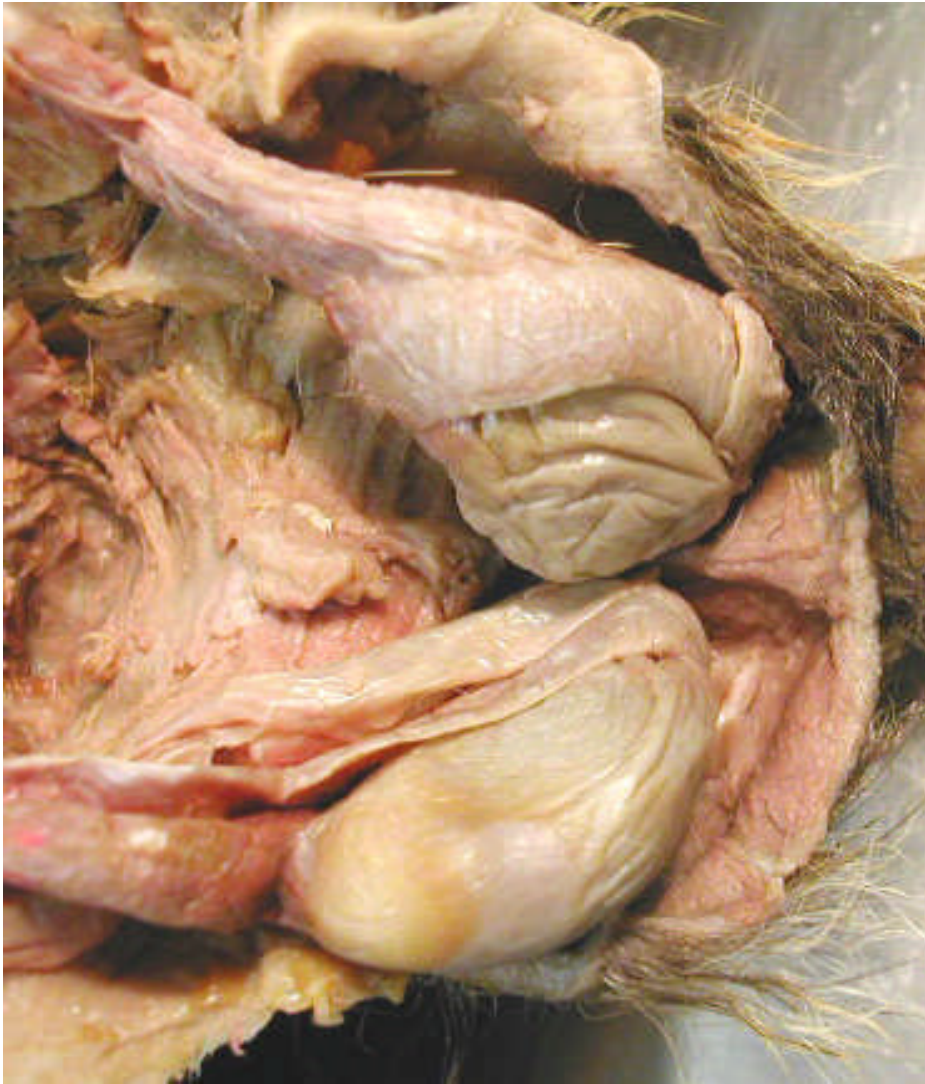• TESTIS

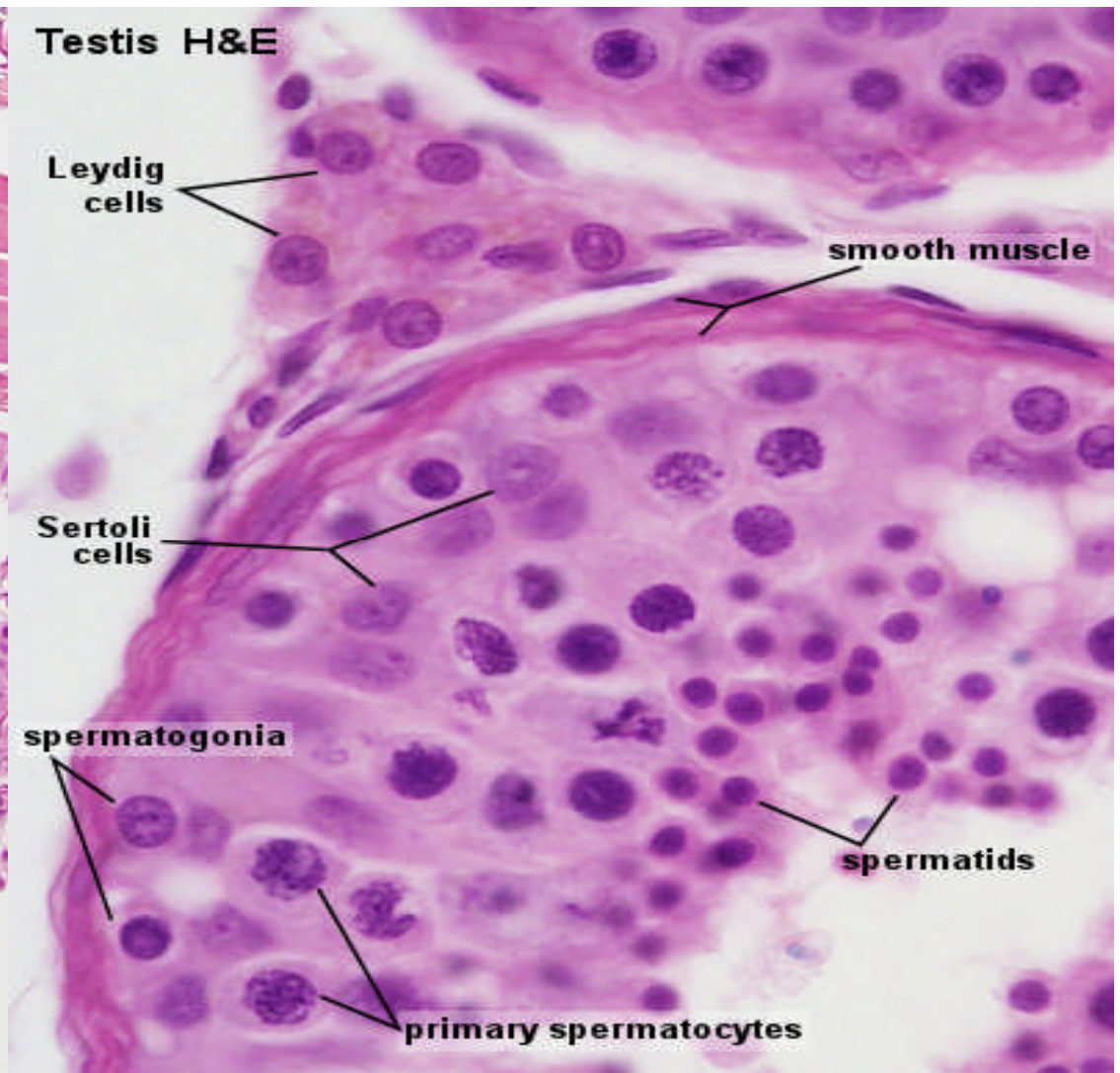
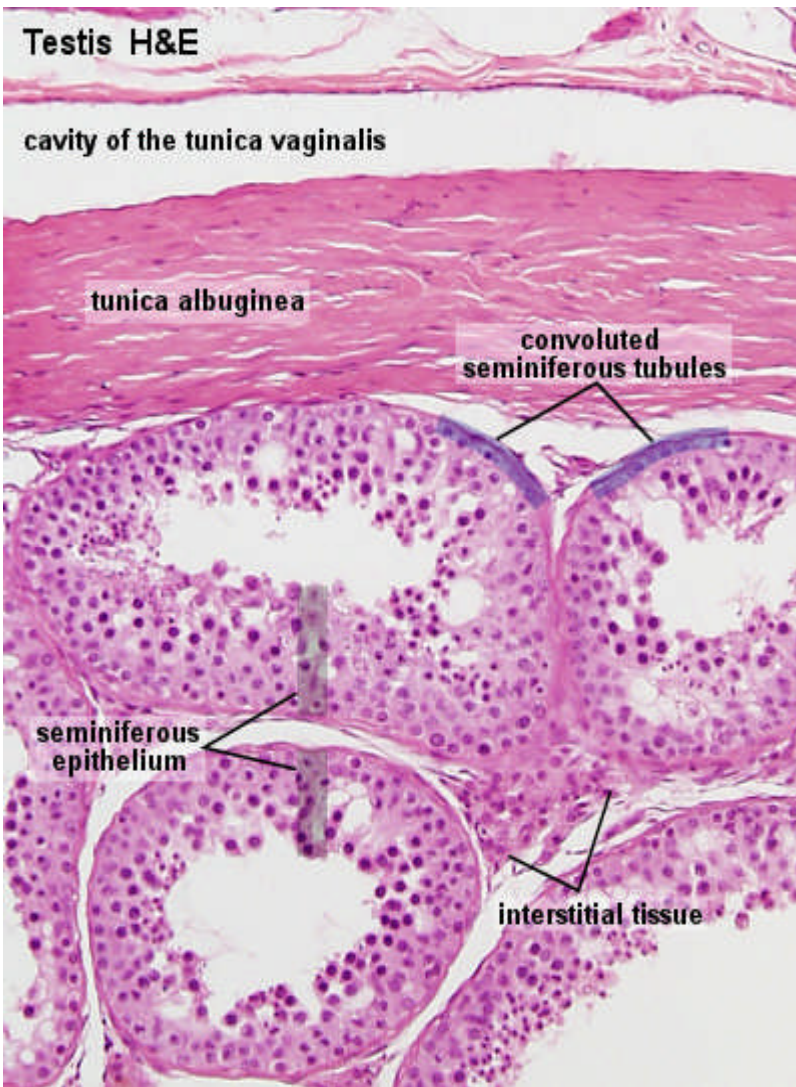
EPIDIDYMIS

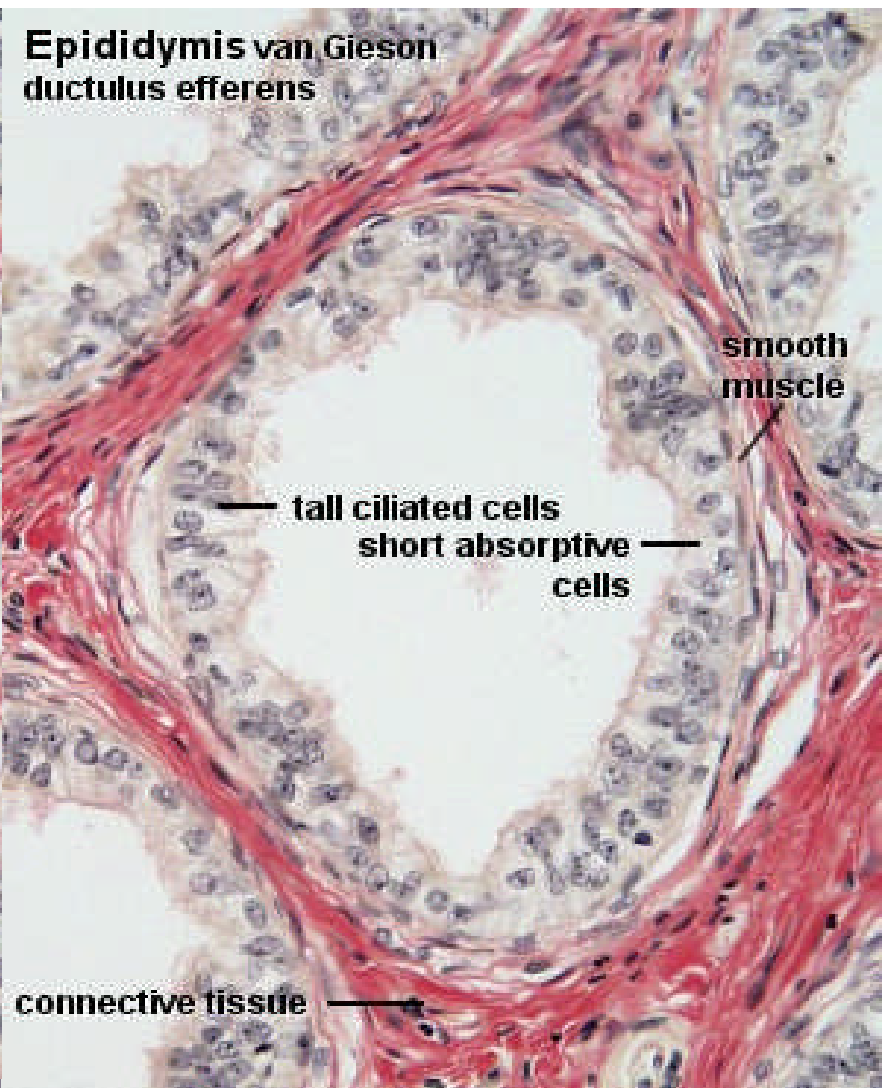
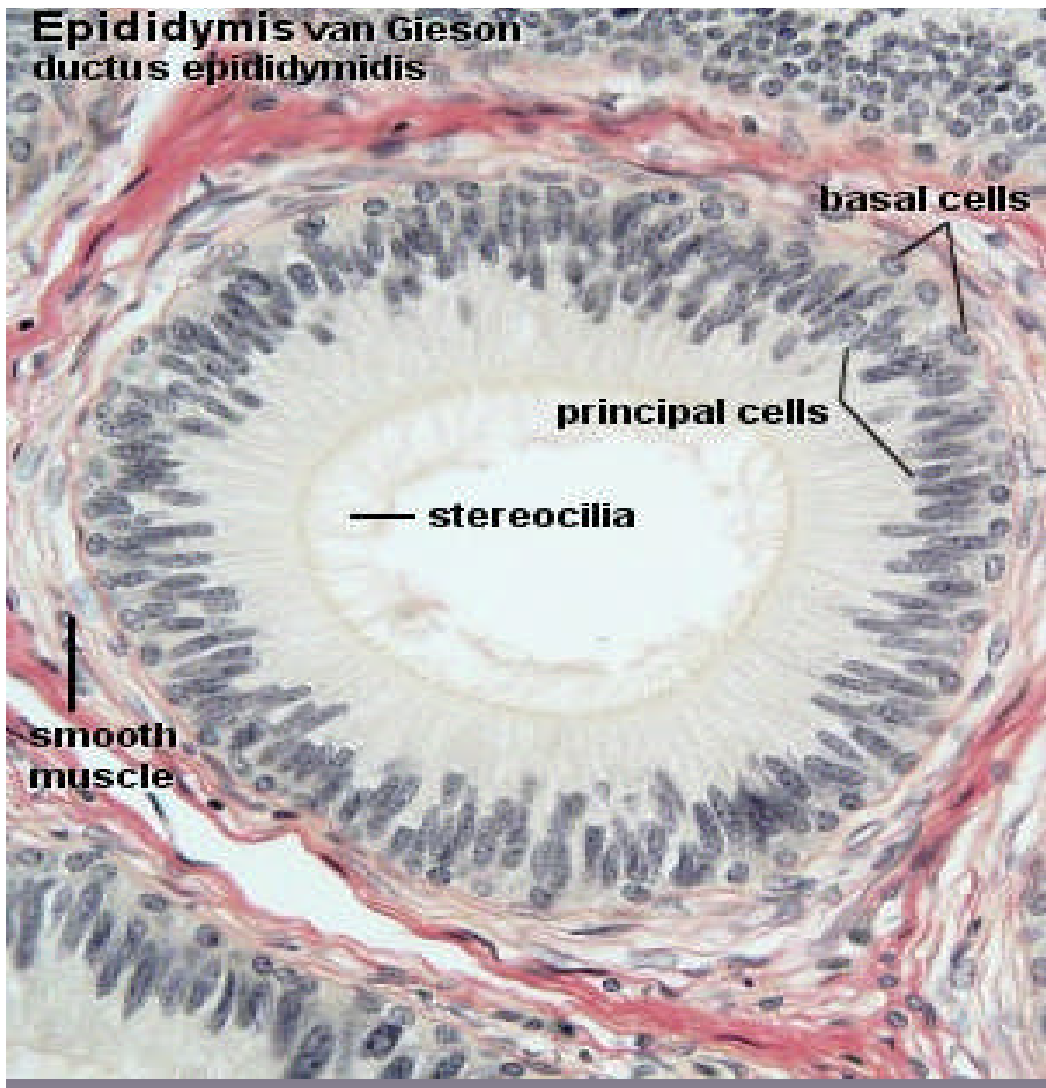




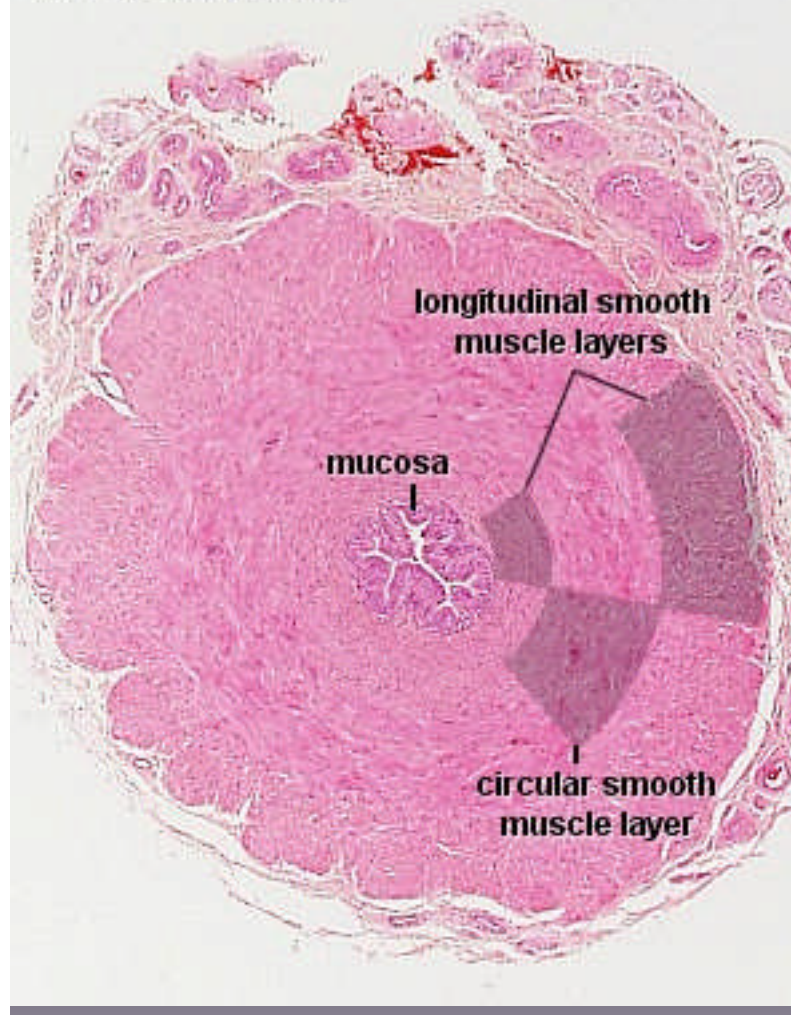




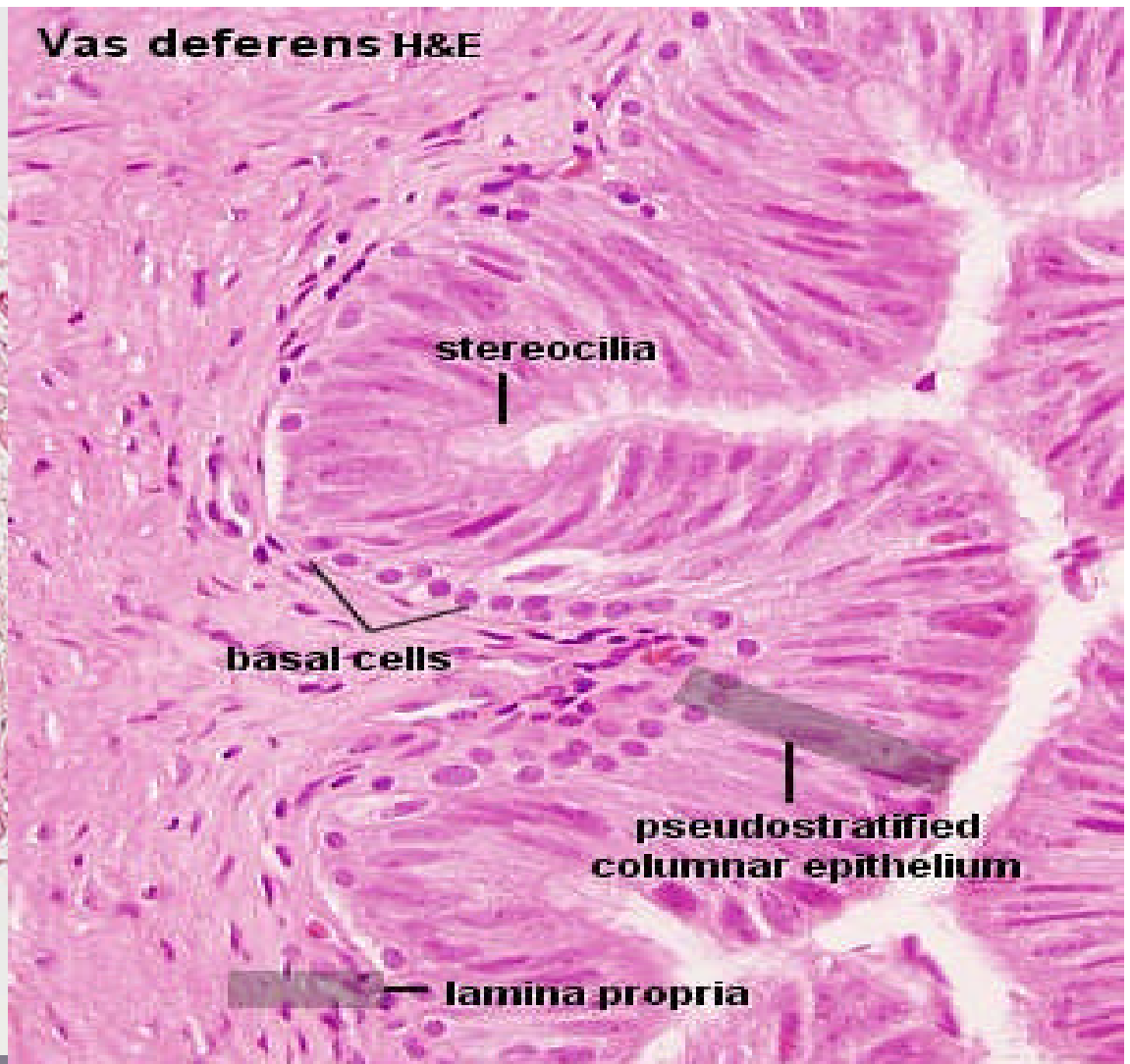


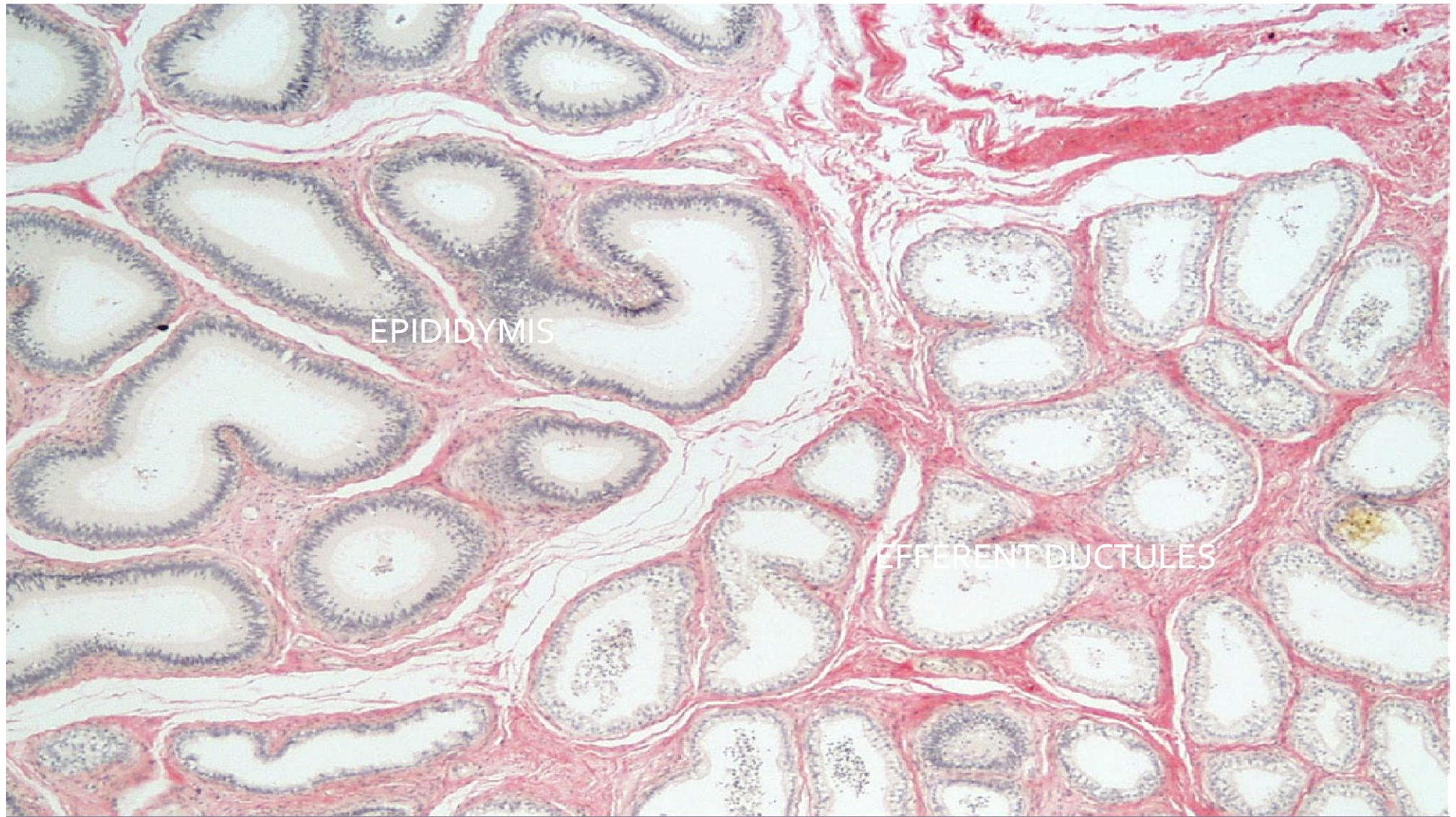


Vas deferens H&E



Vas deferens H&E

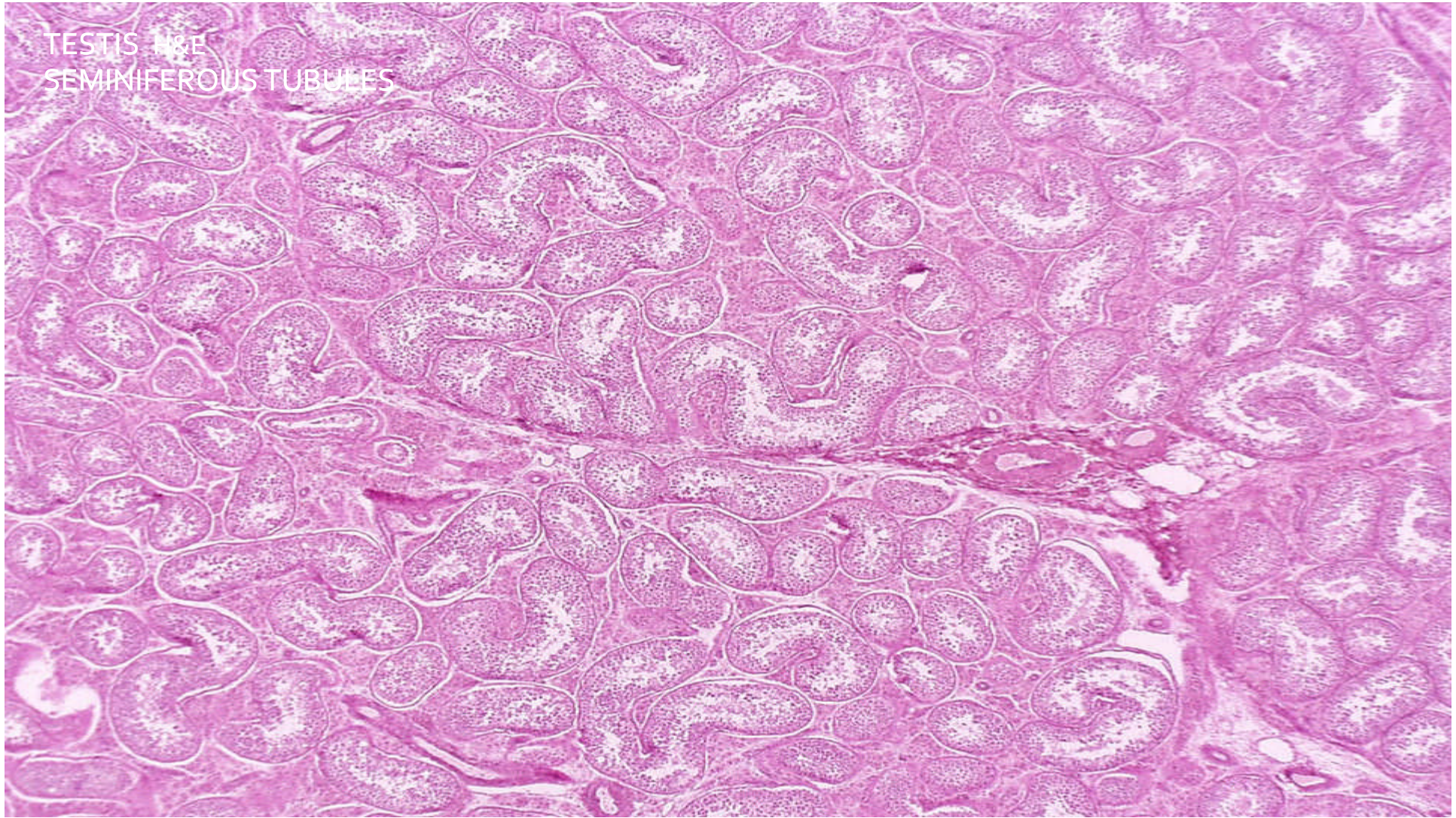




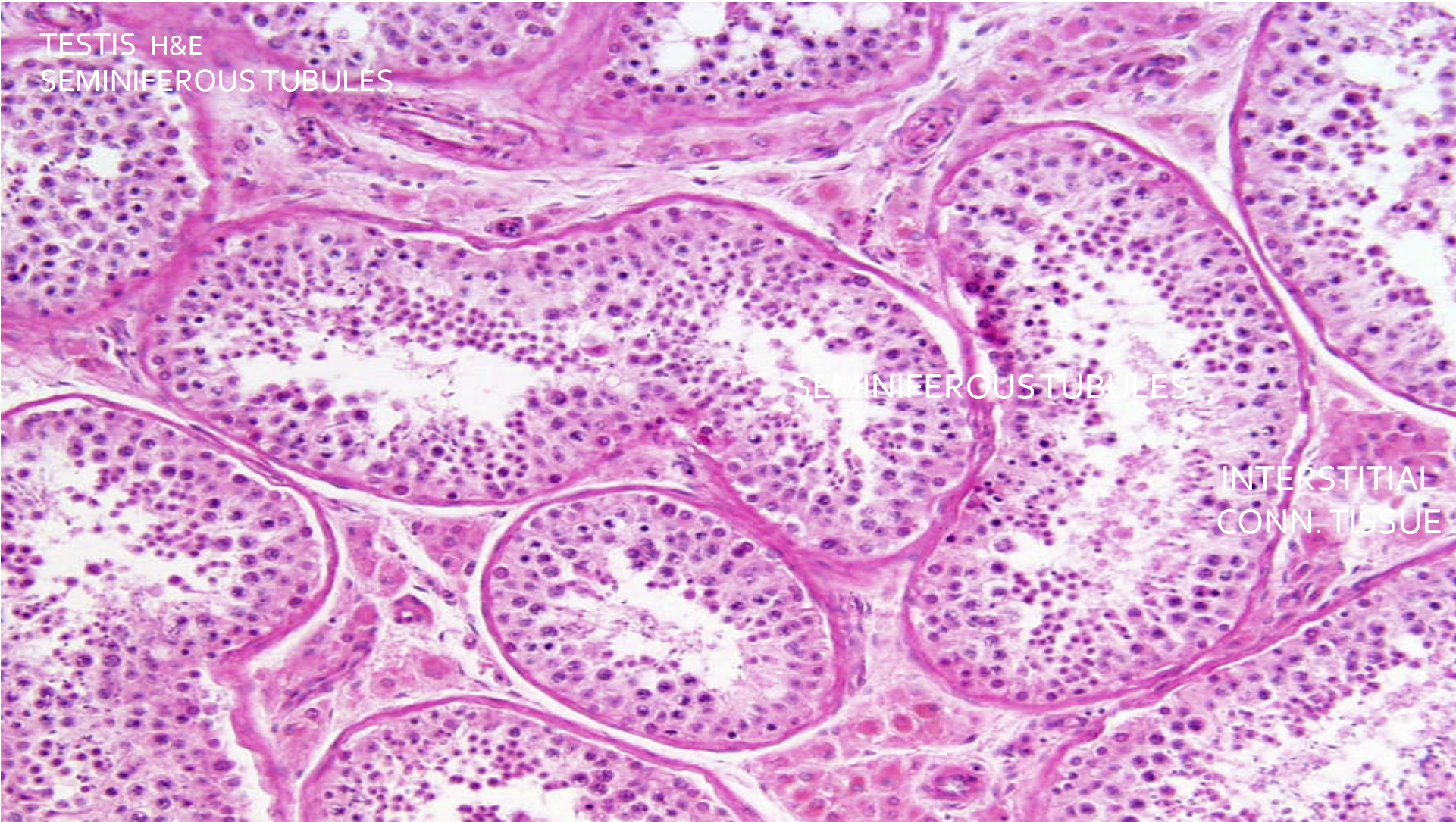
EPIDIDYMIS

EFFERENT DUCTULES

TESTIS H&E
SEMINIFEROUS TUBULES



TESTIS H&E
SEMINIFEROUS TUBULES



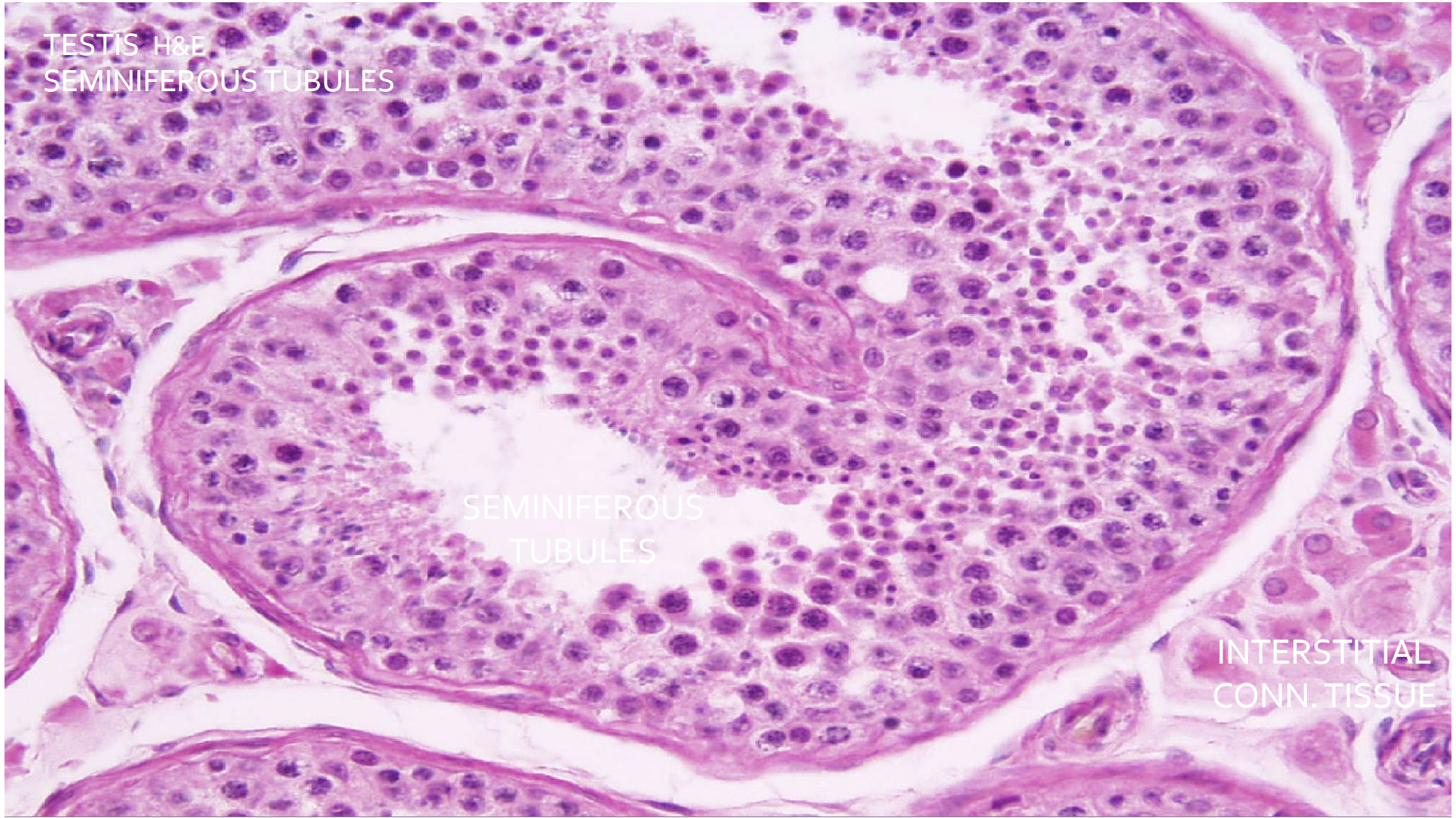
SEMINIFEROUS TUBULES

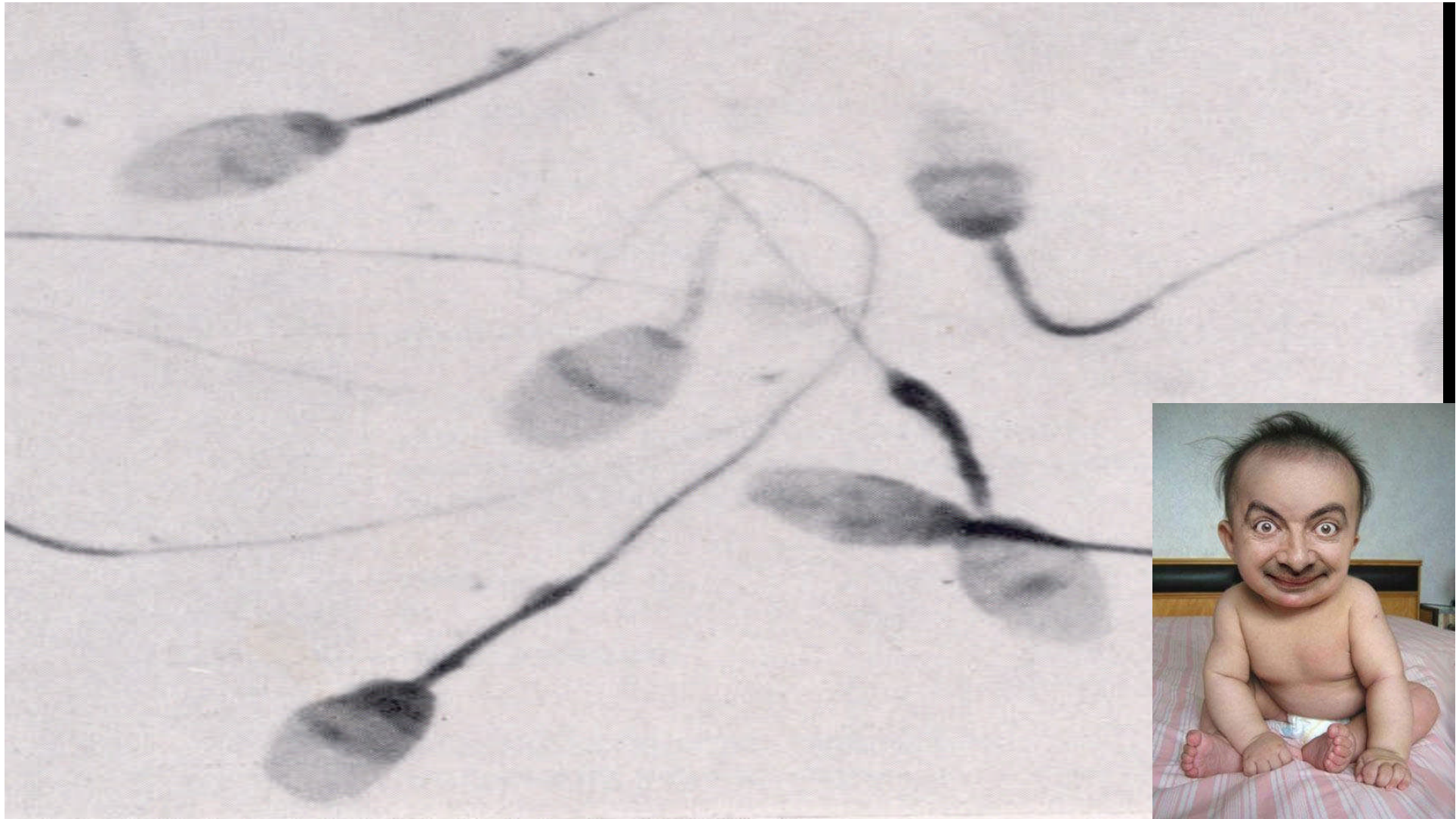
INTERSTITIAL
CONN. TISSUE

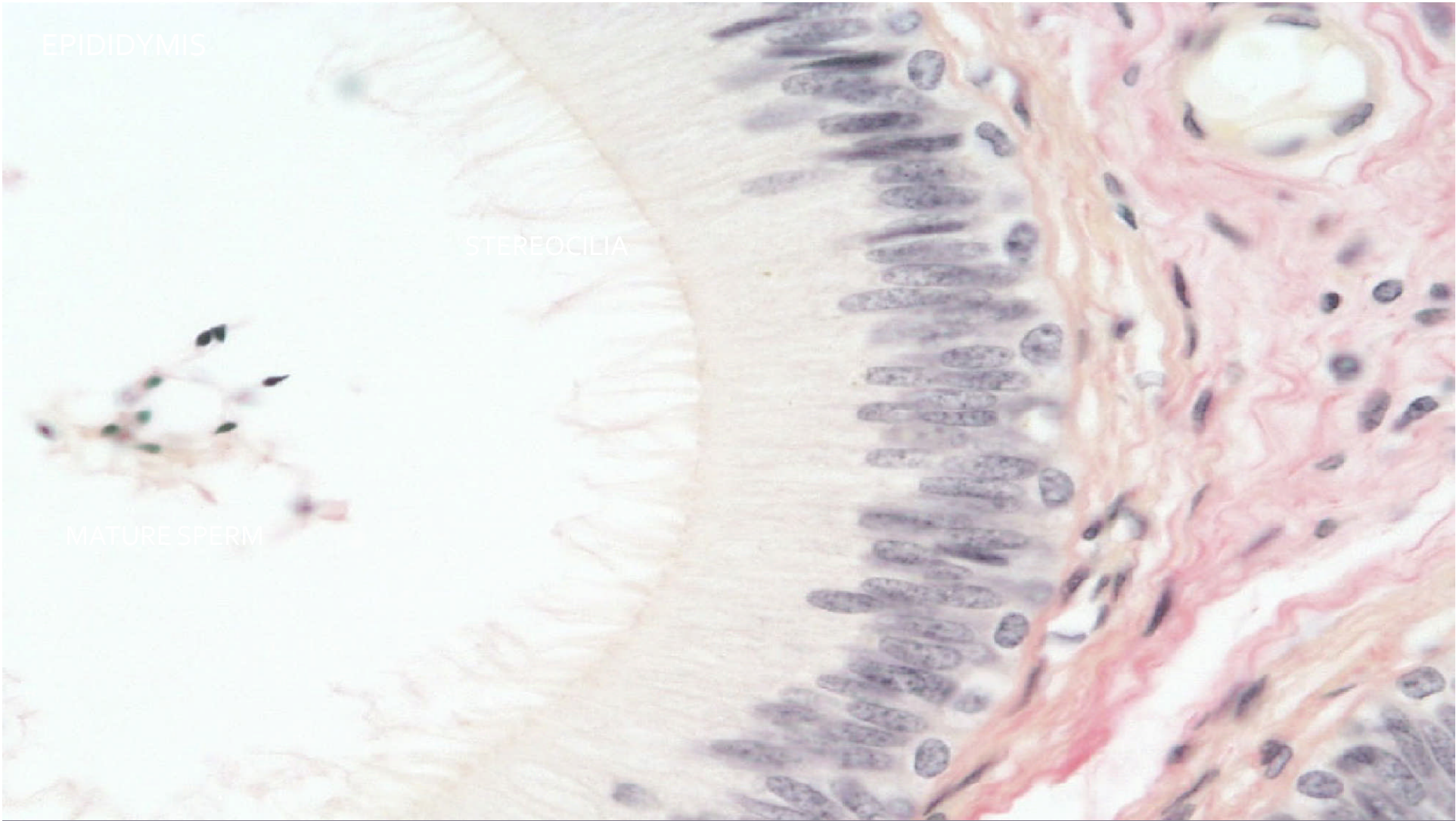
TESTIS H&E
SEMINIFEROUS TUBULES

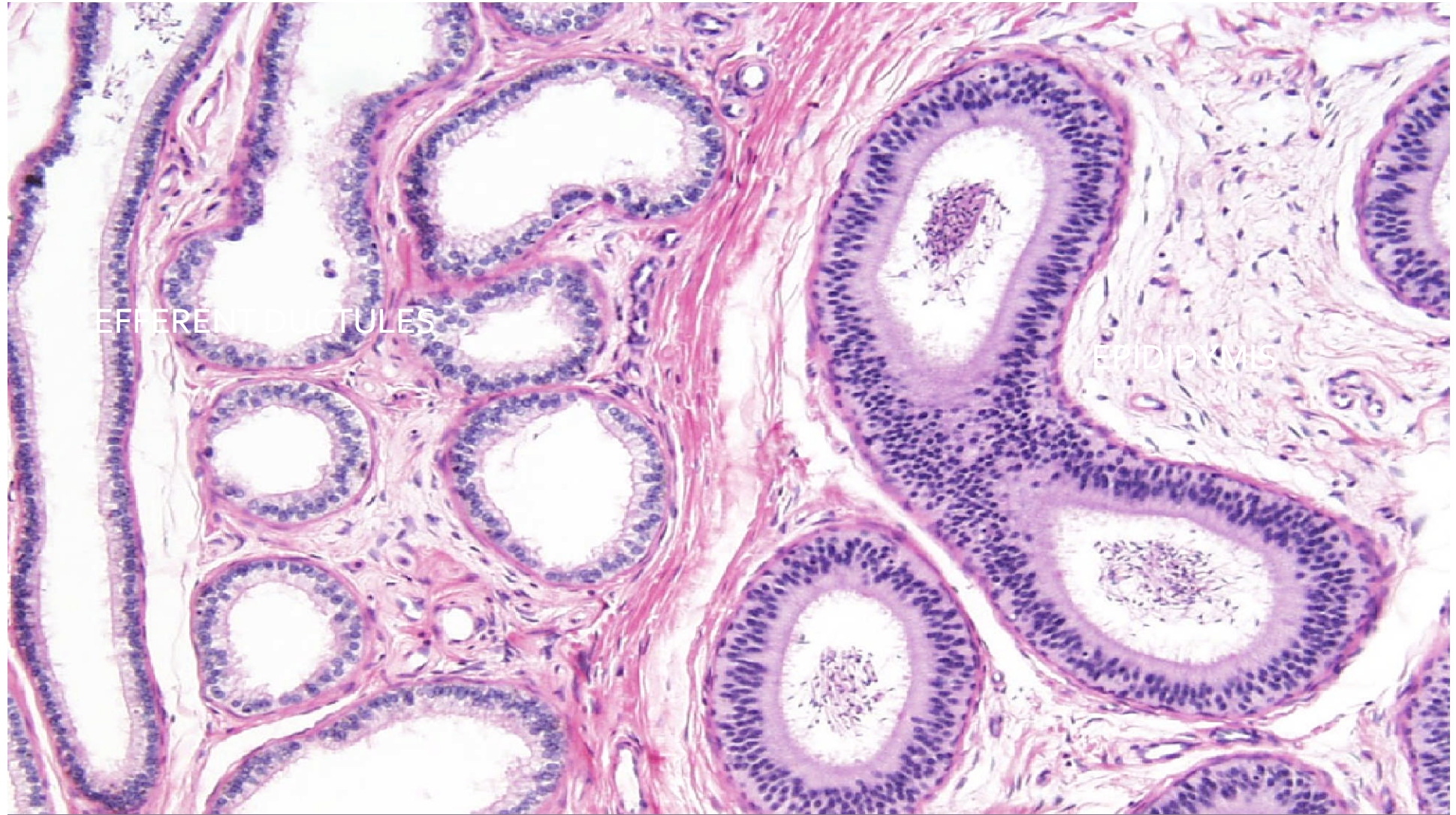
SEMINIFEROUS
TUBULES

INTERSTITIAL
CONN. TISSUE



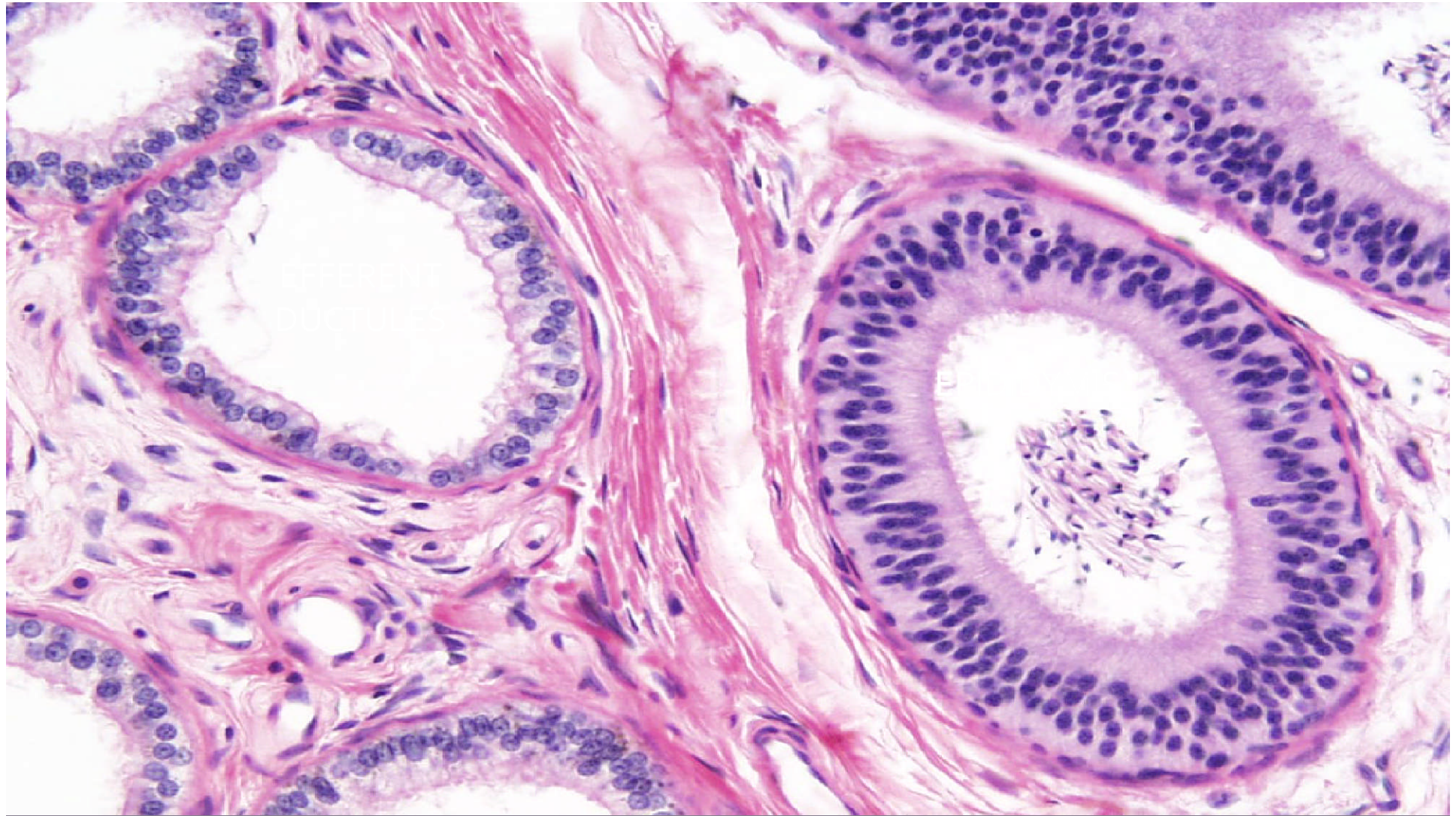


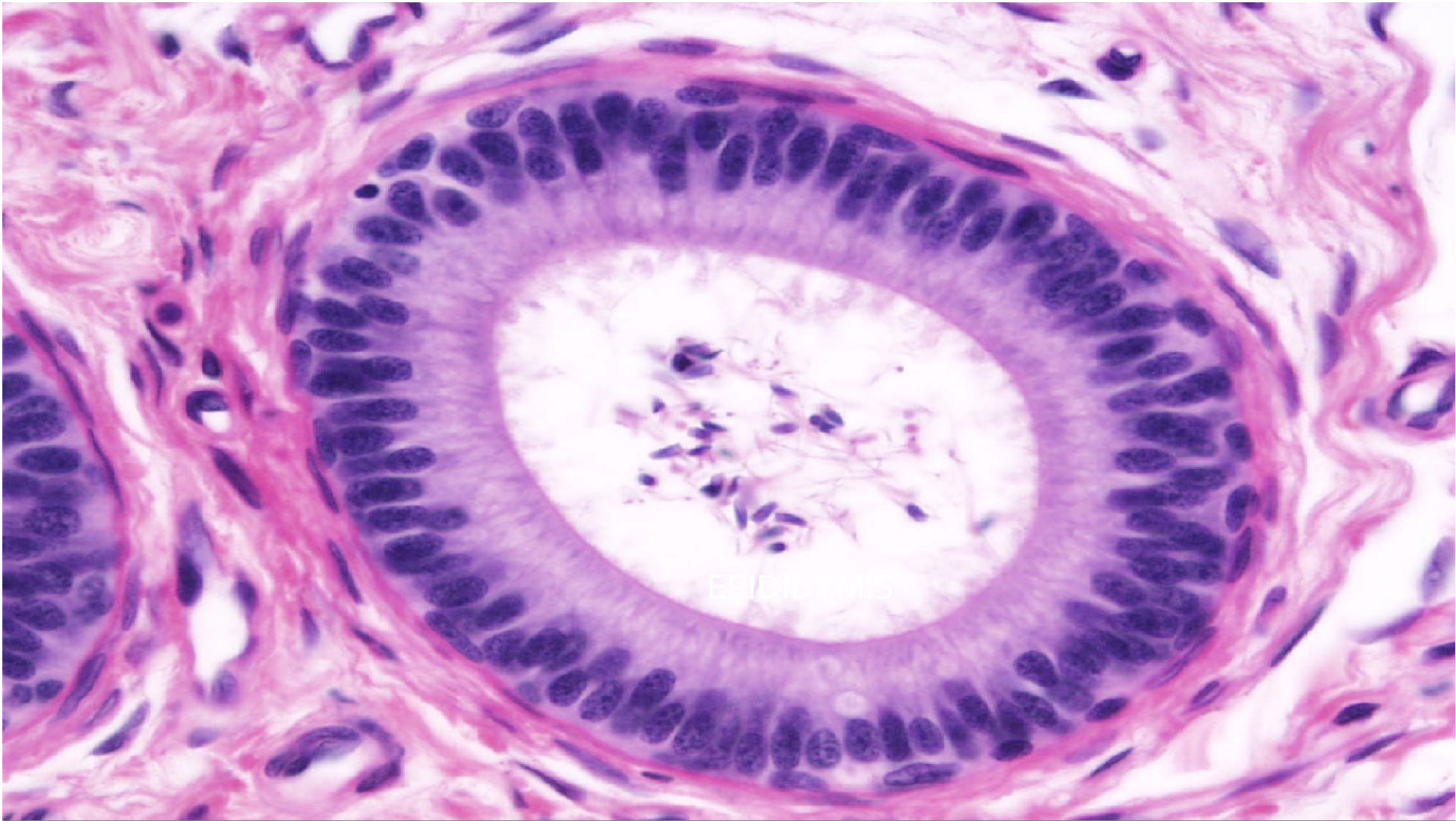




EFFERENT DUCTULES

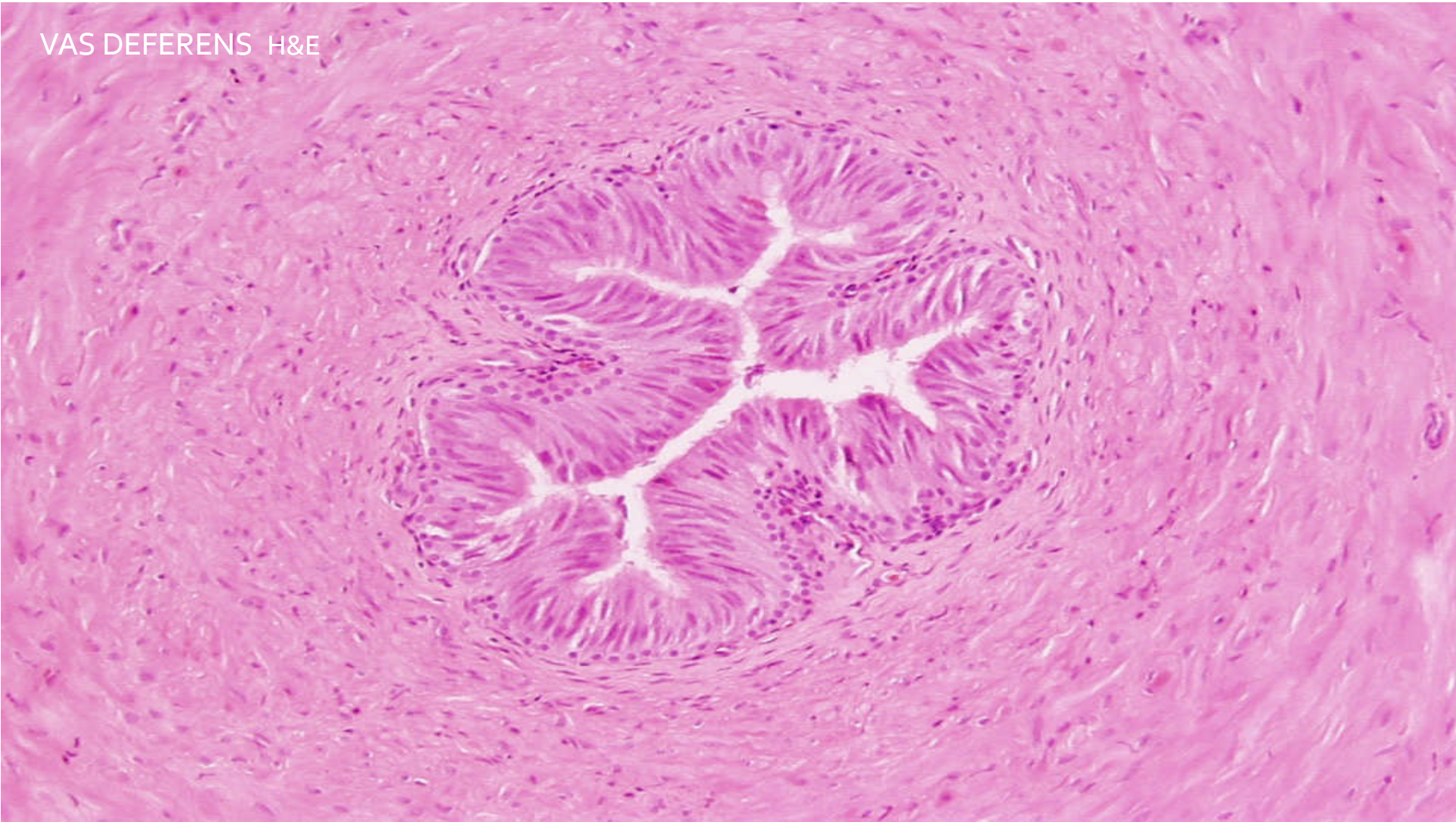
EPIDIDYMIS





EPIDIDYMIIS

VAS DEFERENS H&E

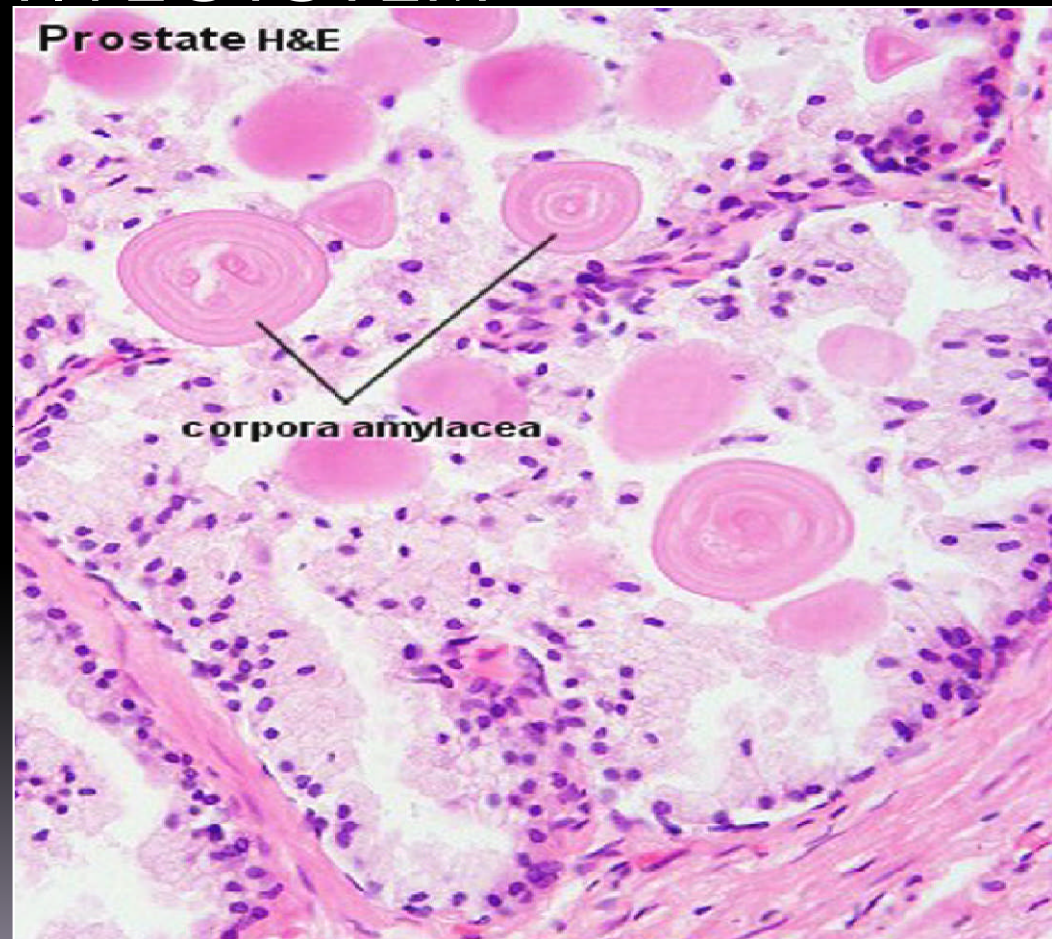

MALE REPRODUCTIVE SYSTEM

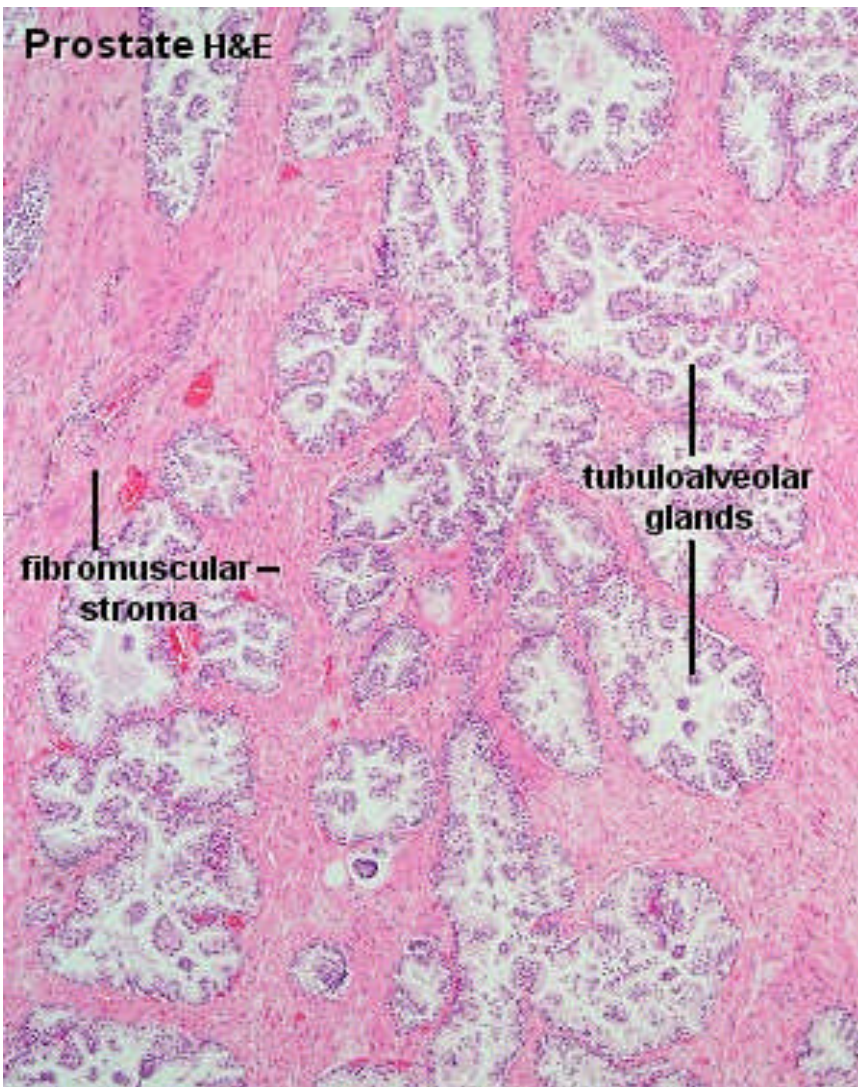
- PROSTATE

PROSTATIC CONCRETIONS

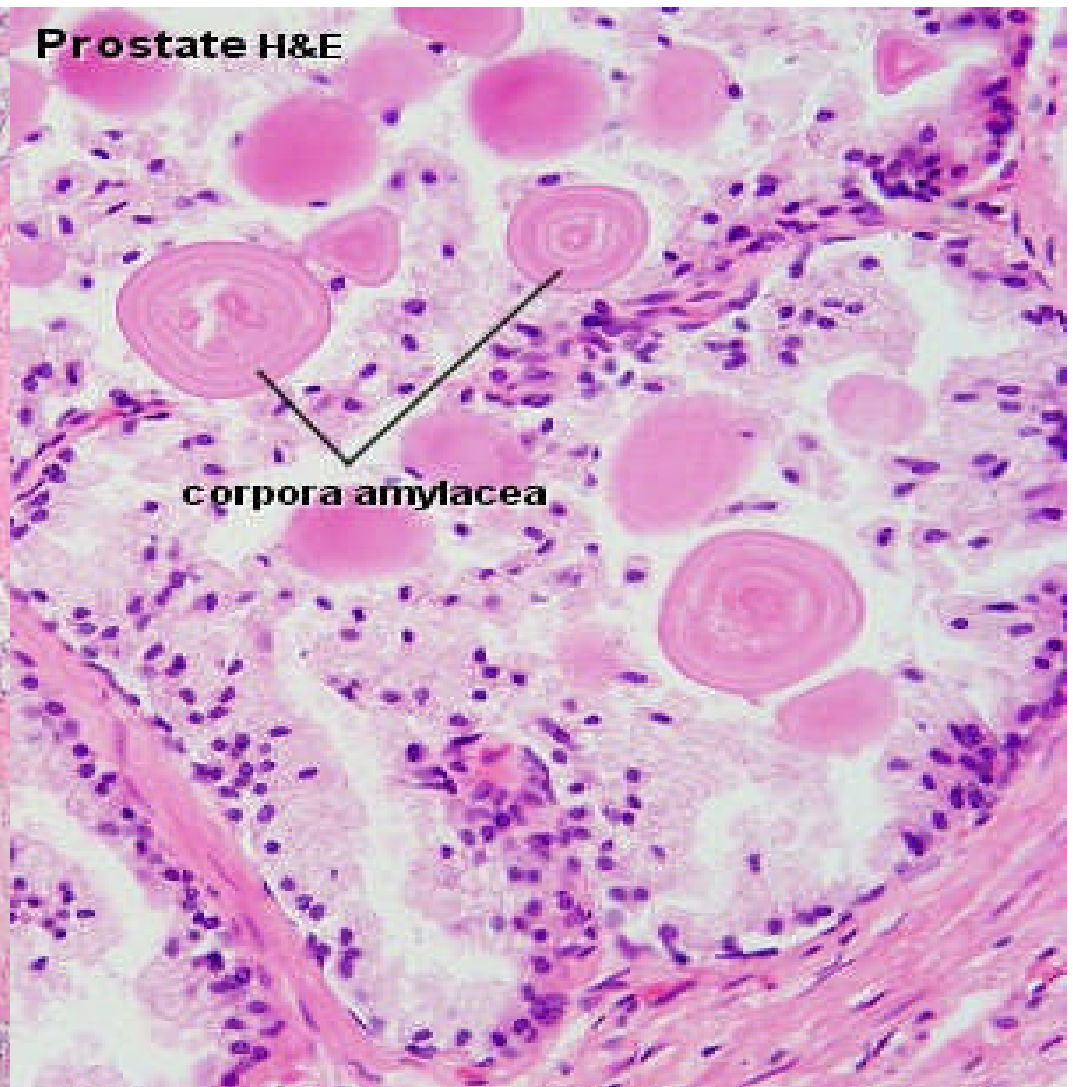
- *precipitation of secretory product*



Prostate H&E

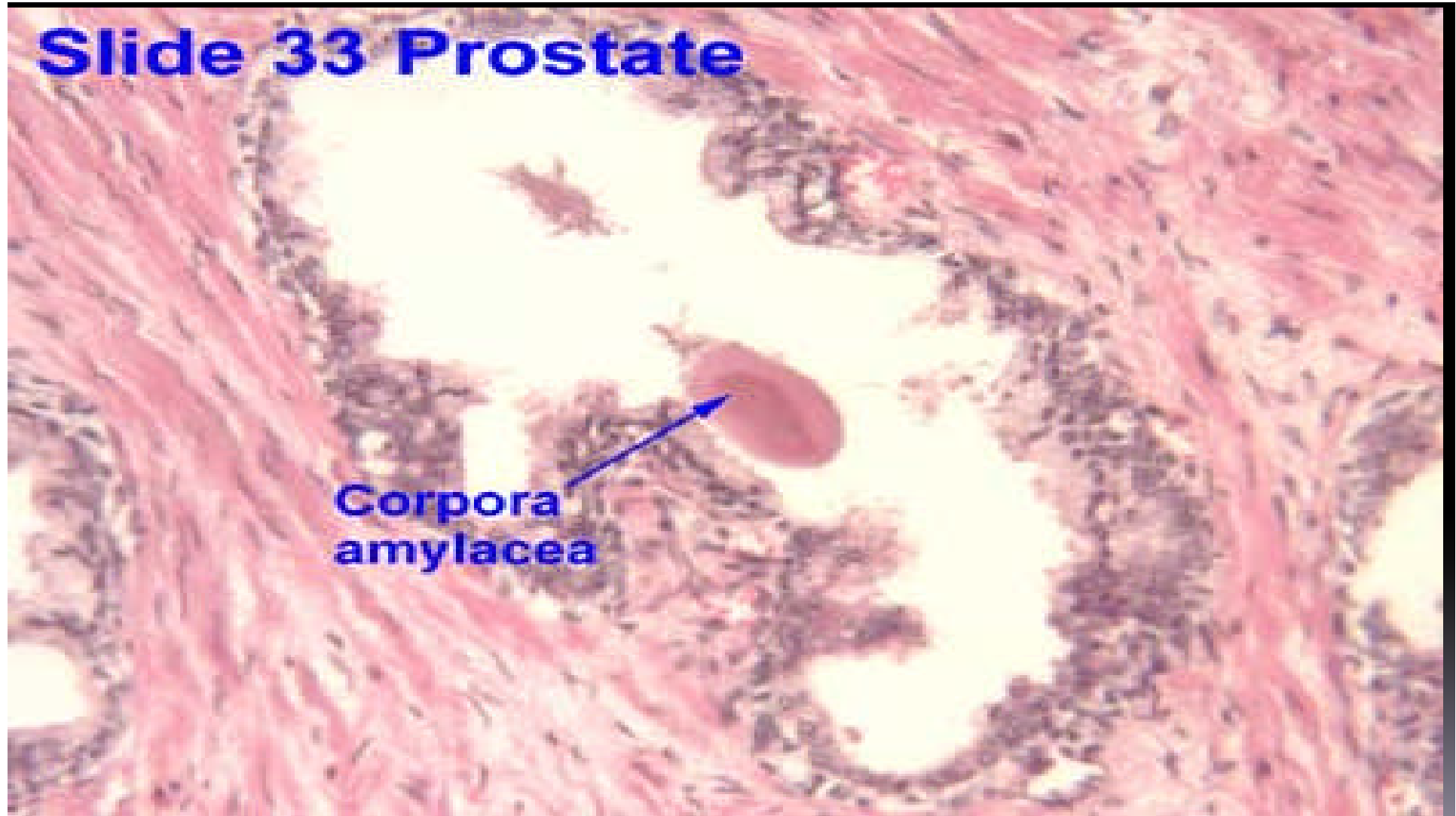


Prostate H&E

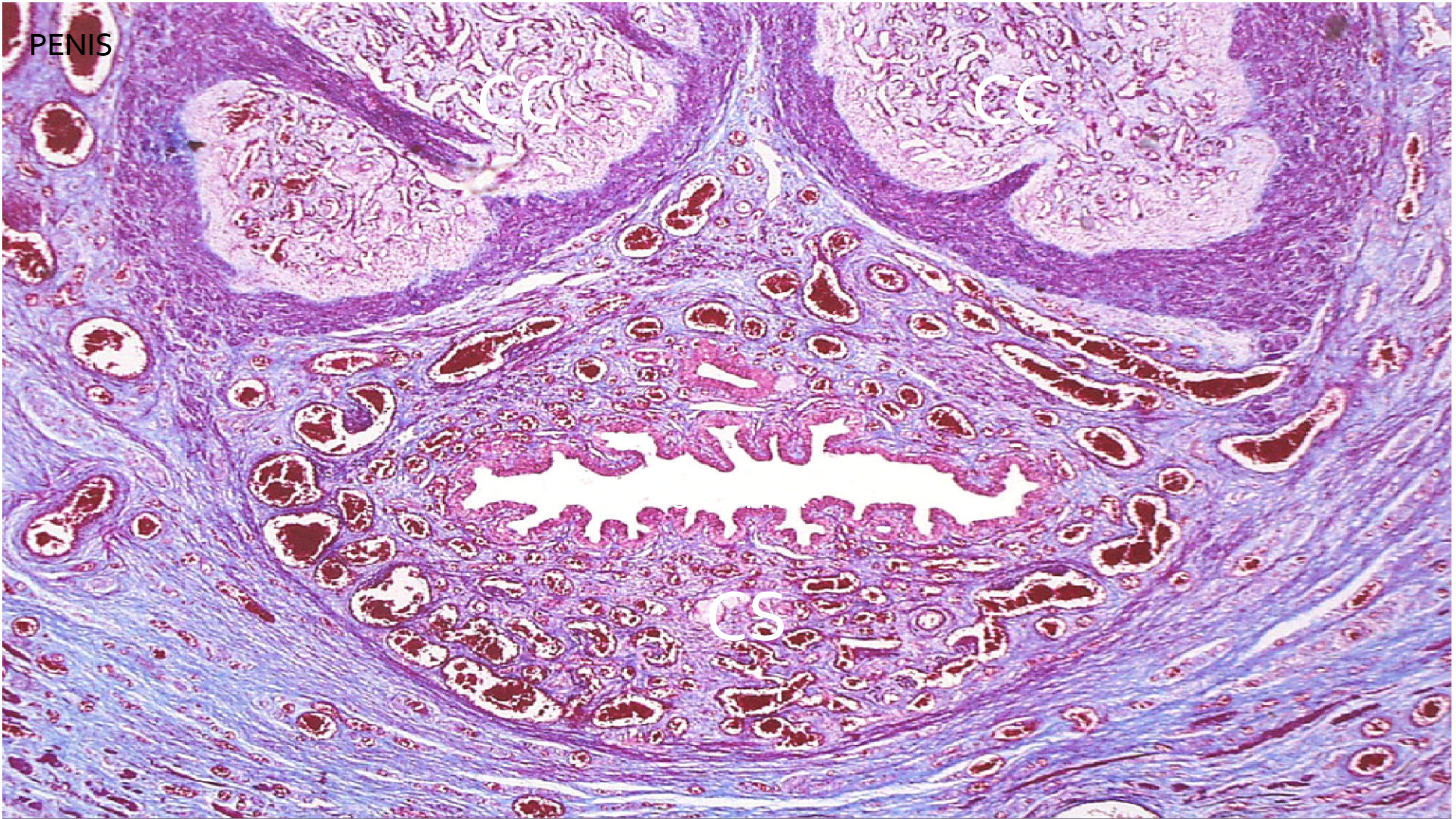


Slide 33 Prostate

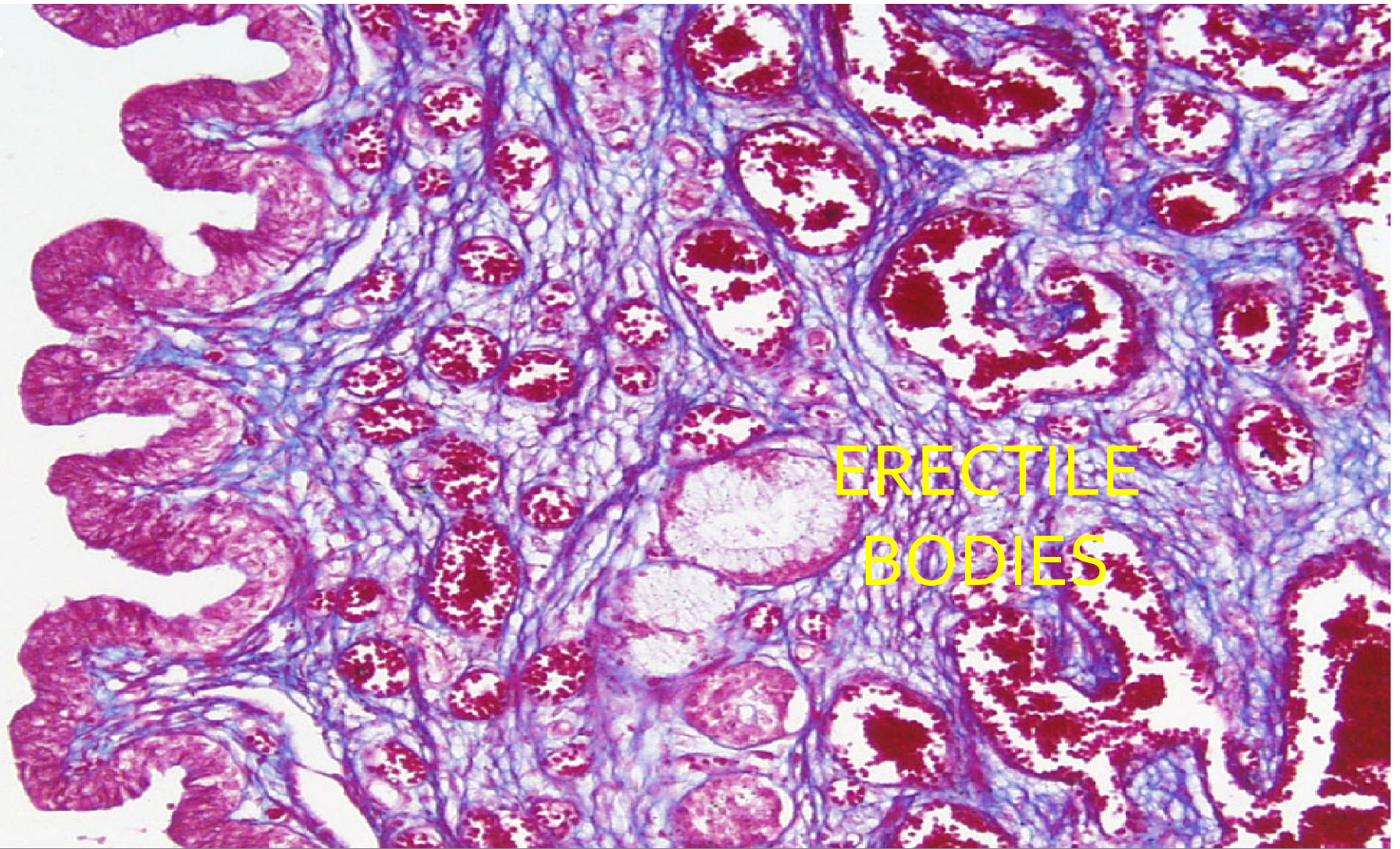
**Corpora
amylacea**



PENIS



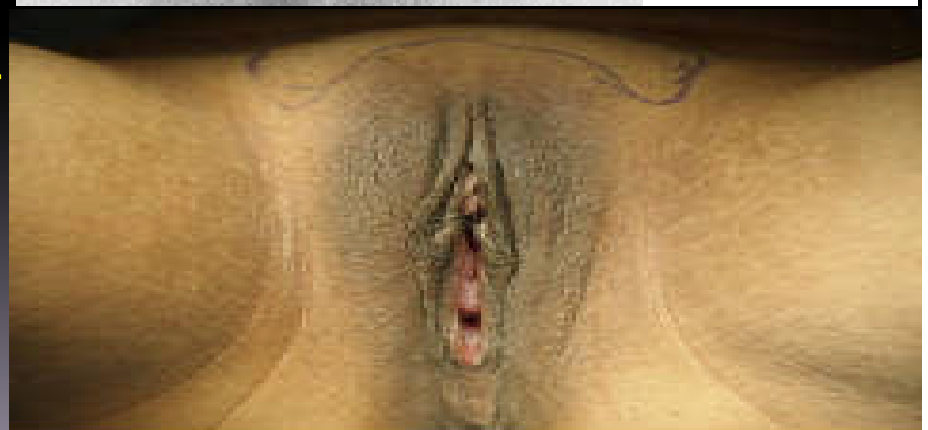
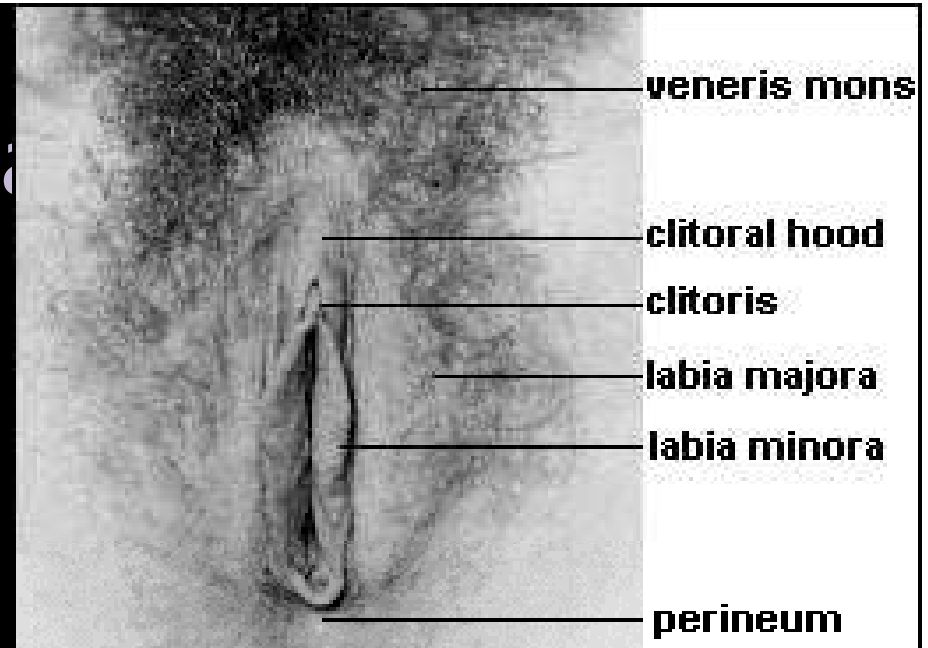
PENIS

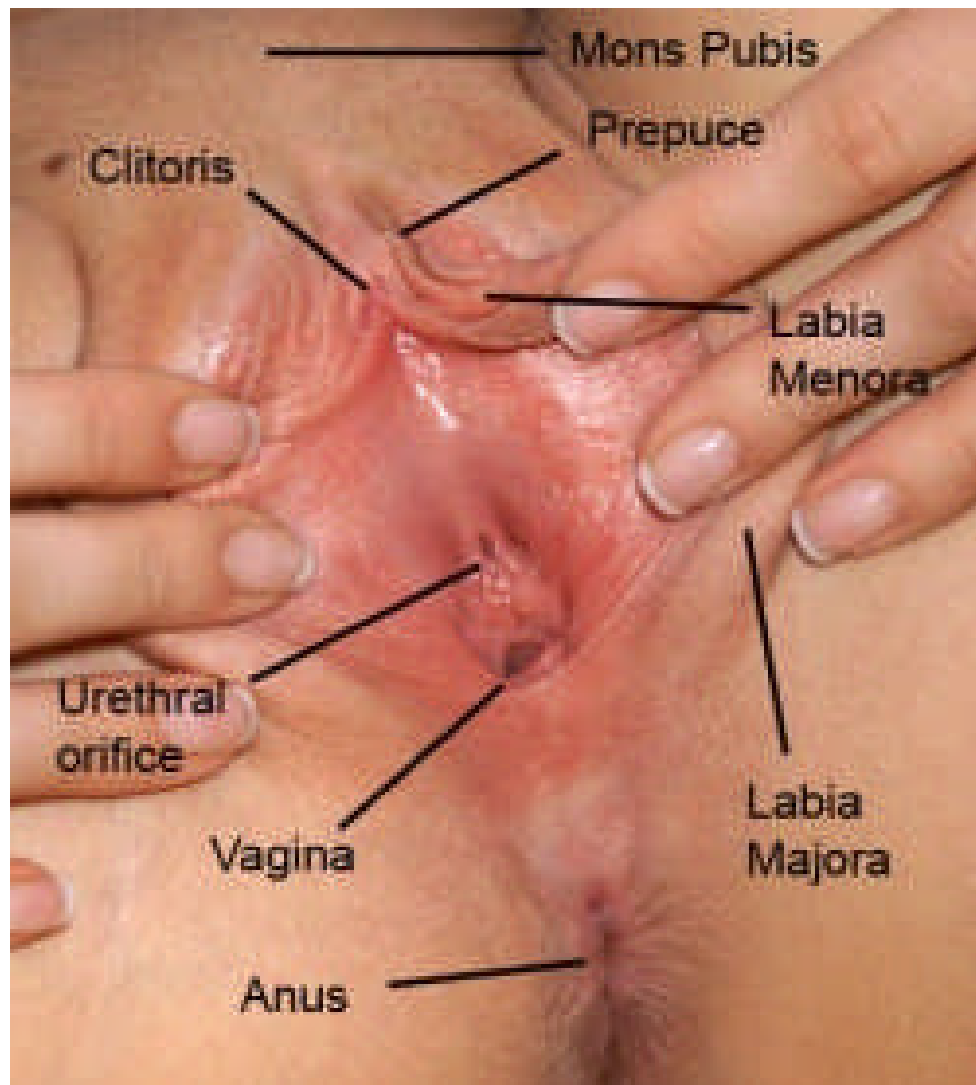

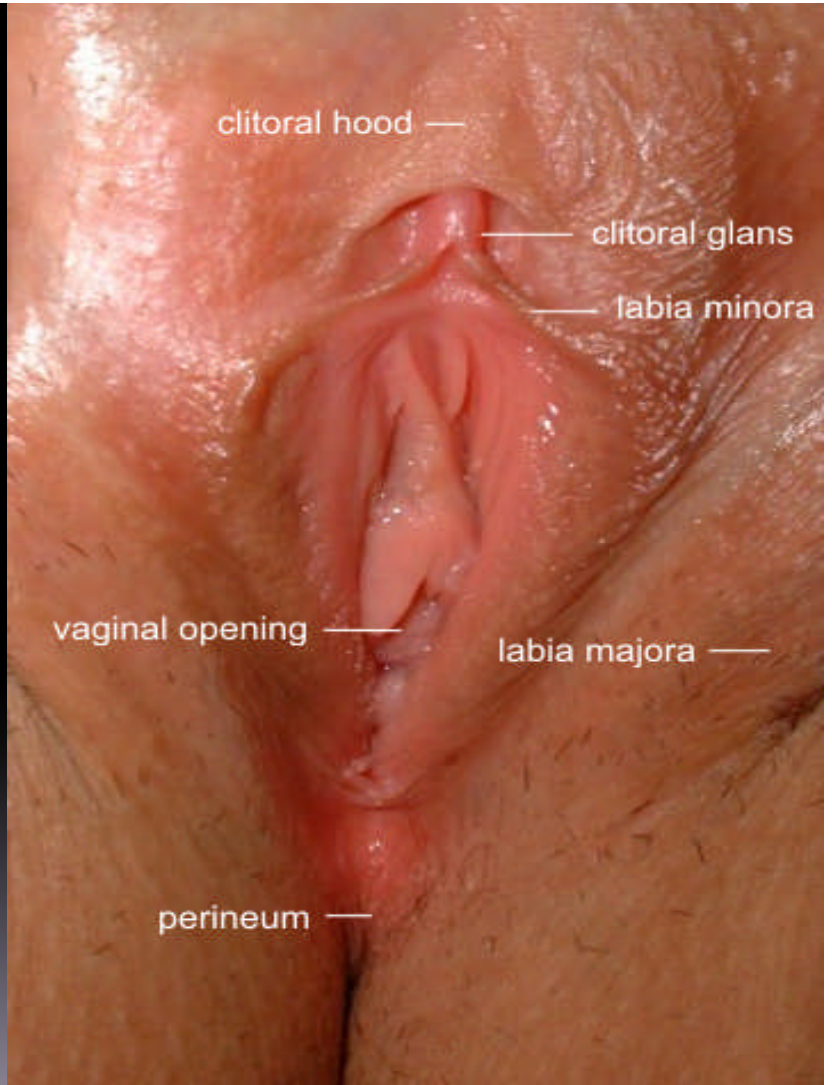
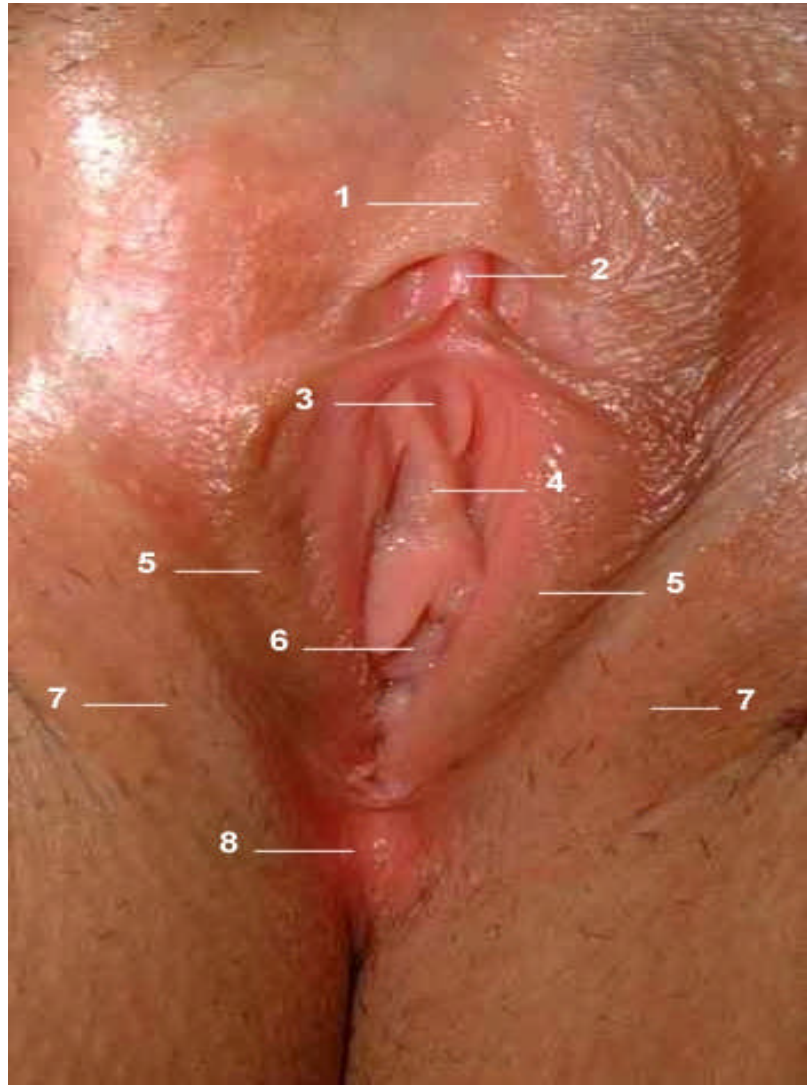
ERECTILE
BODIES

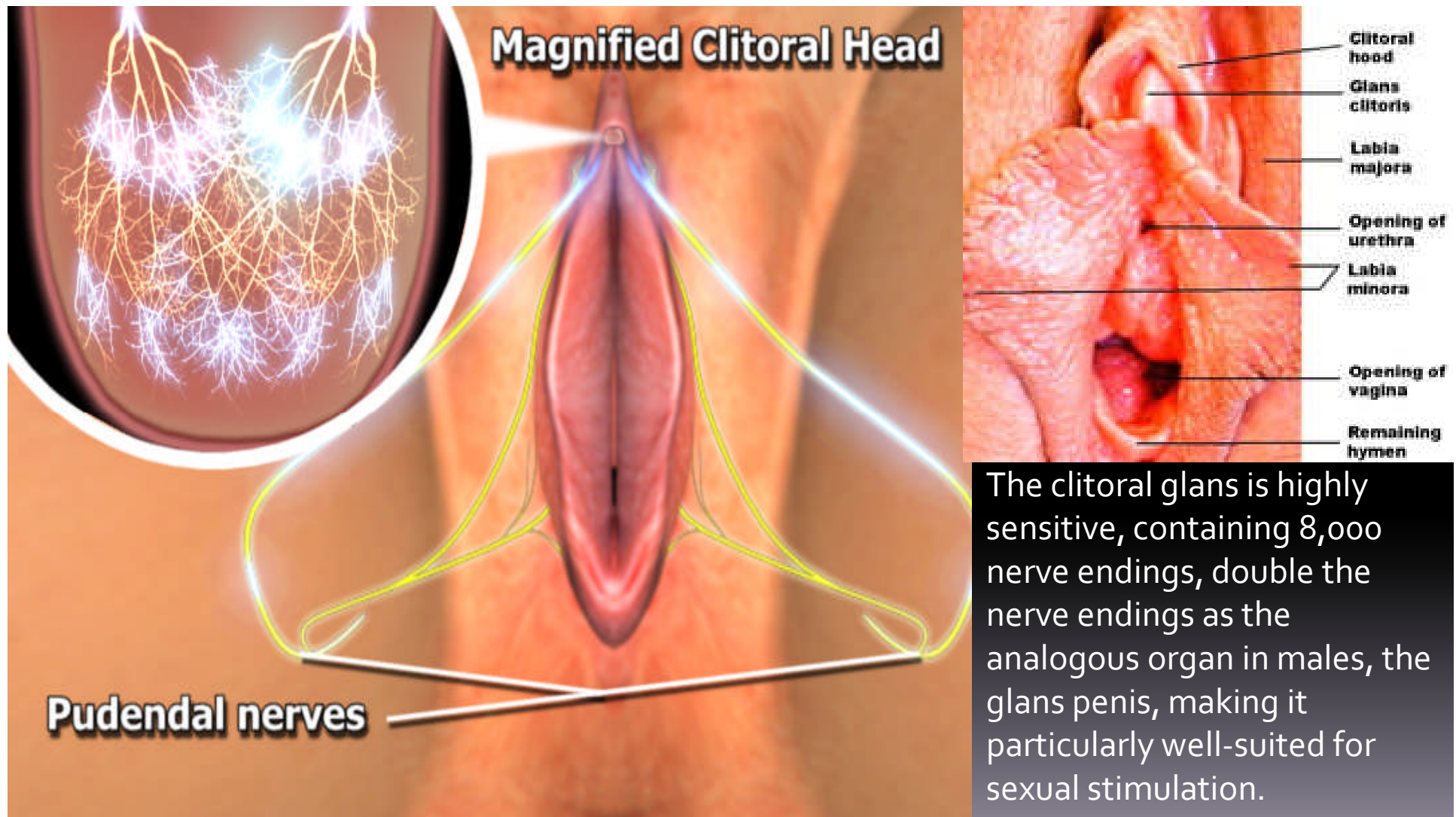
External genitalia

- **Vulva**
 - Vestibule
 - Labia minora and majora
 - Paraurethral glands
 - Clitoris
 - Lesser and greater vestibular glands









Clitoral cross-section

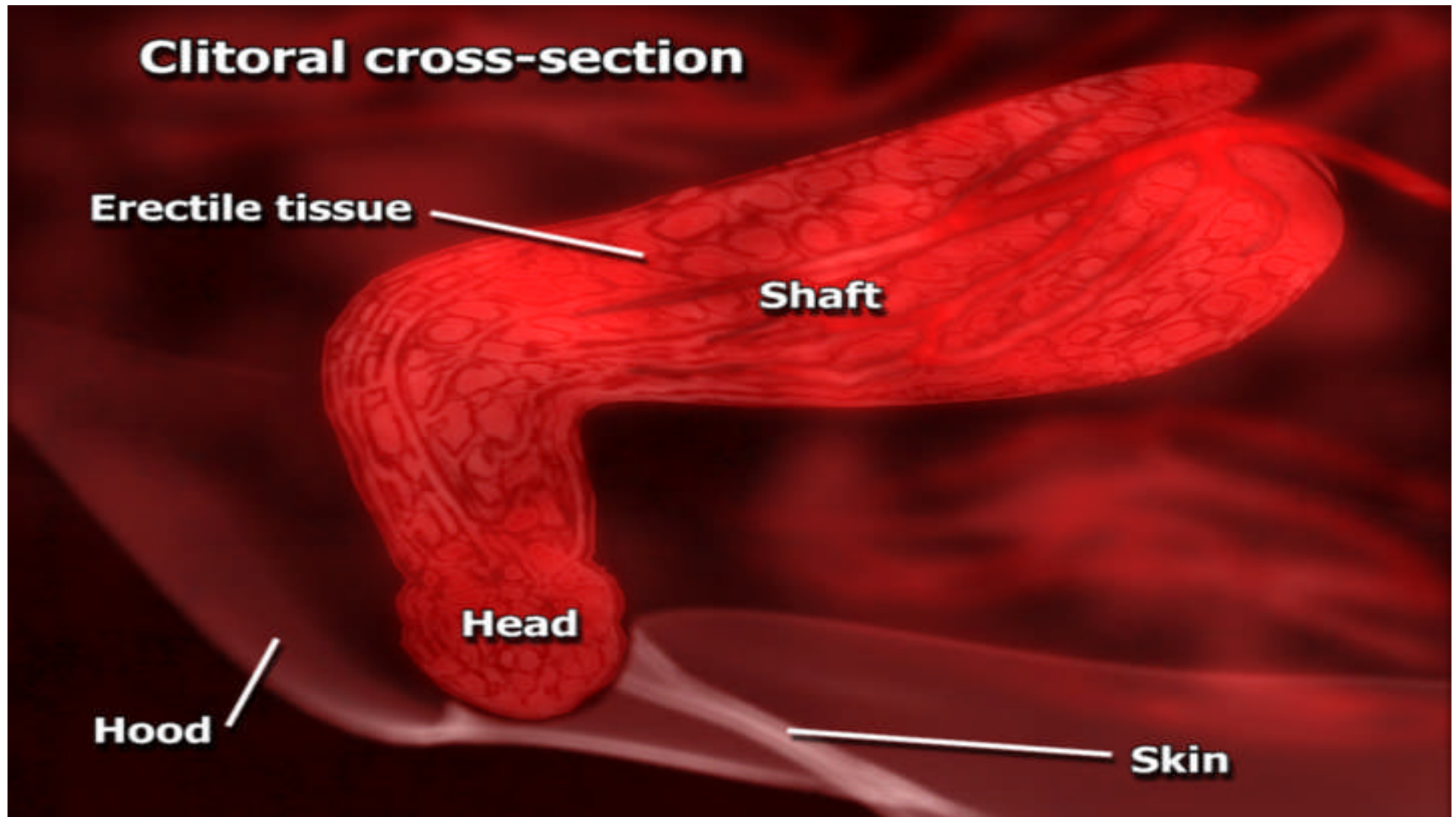
Erectile tissue

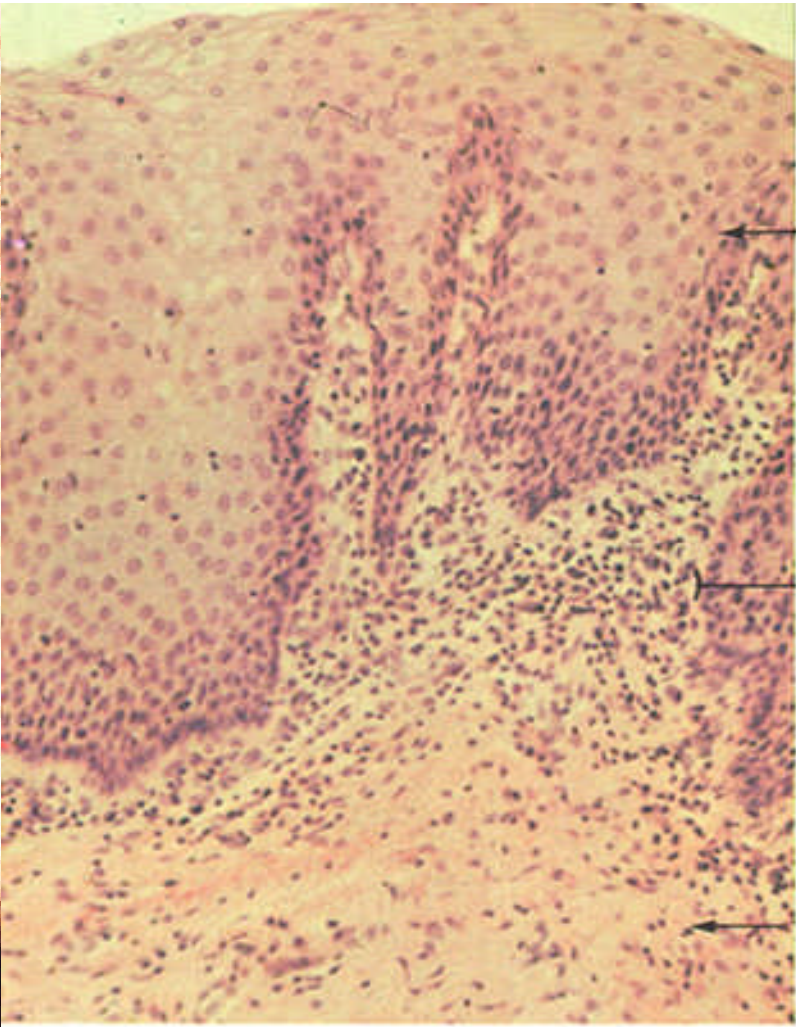
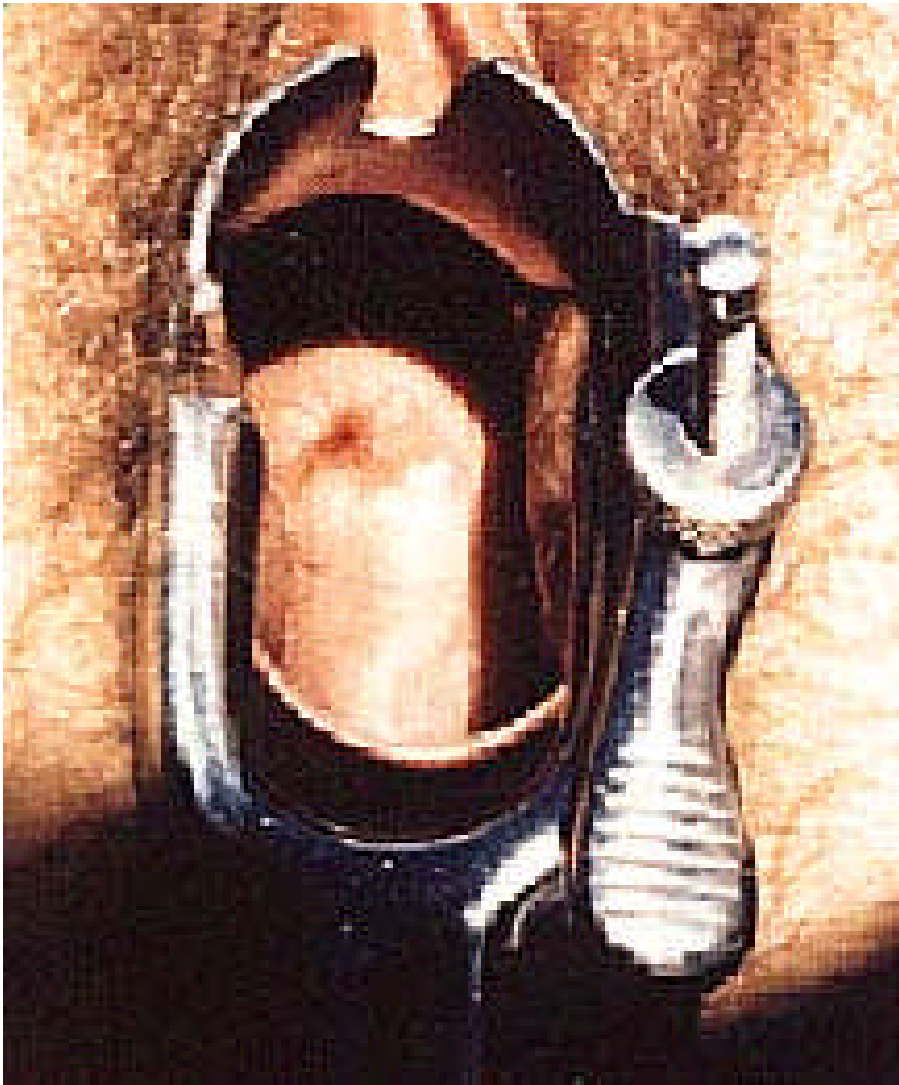Shaft

Head

Hood

Skin



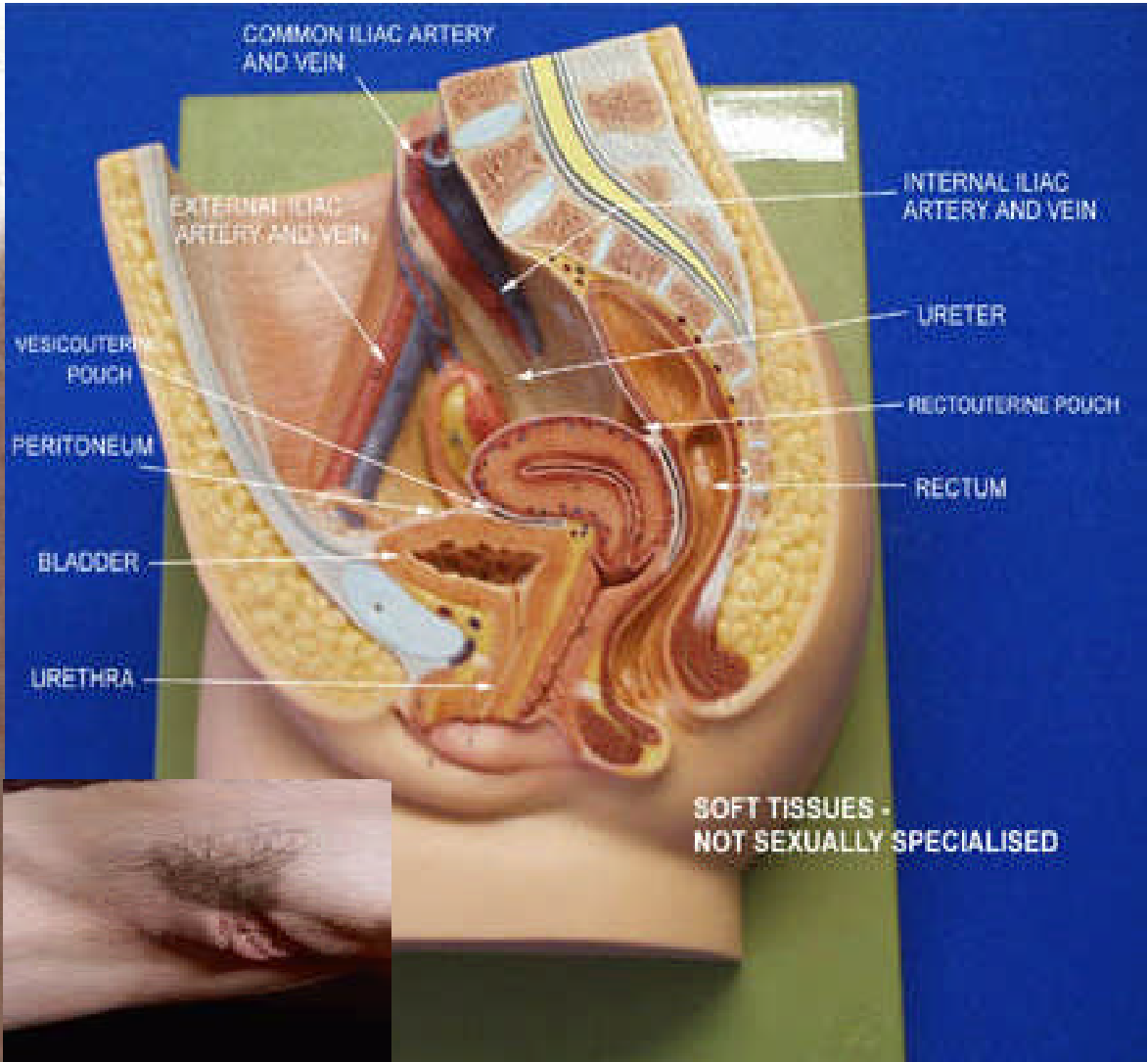
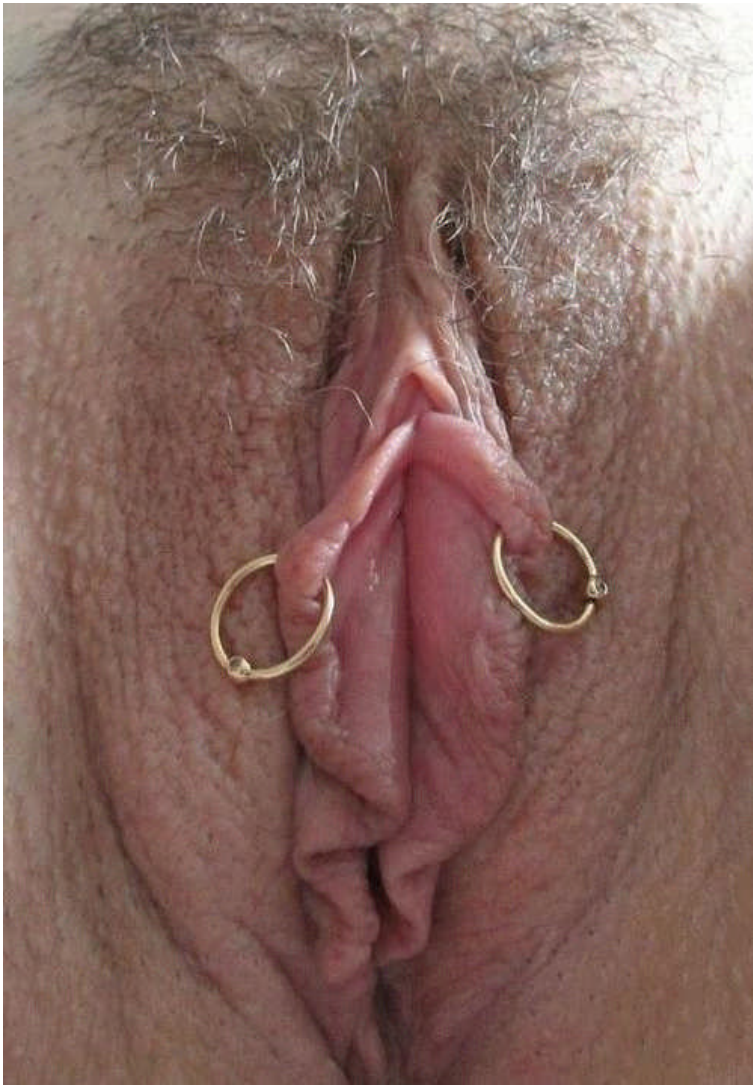

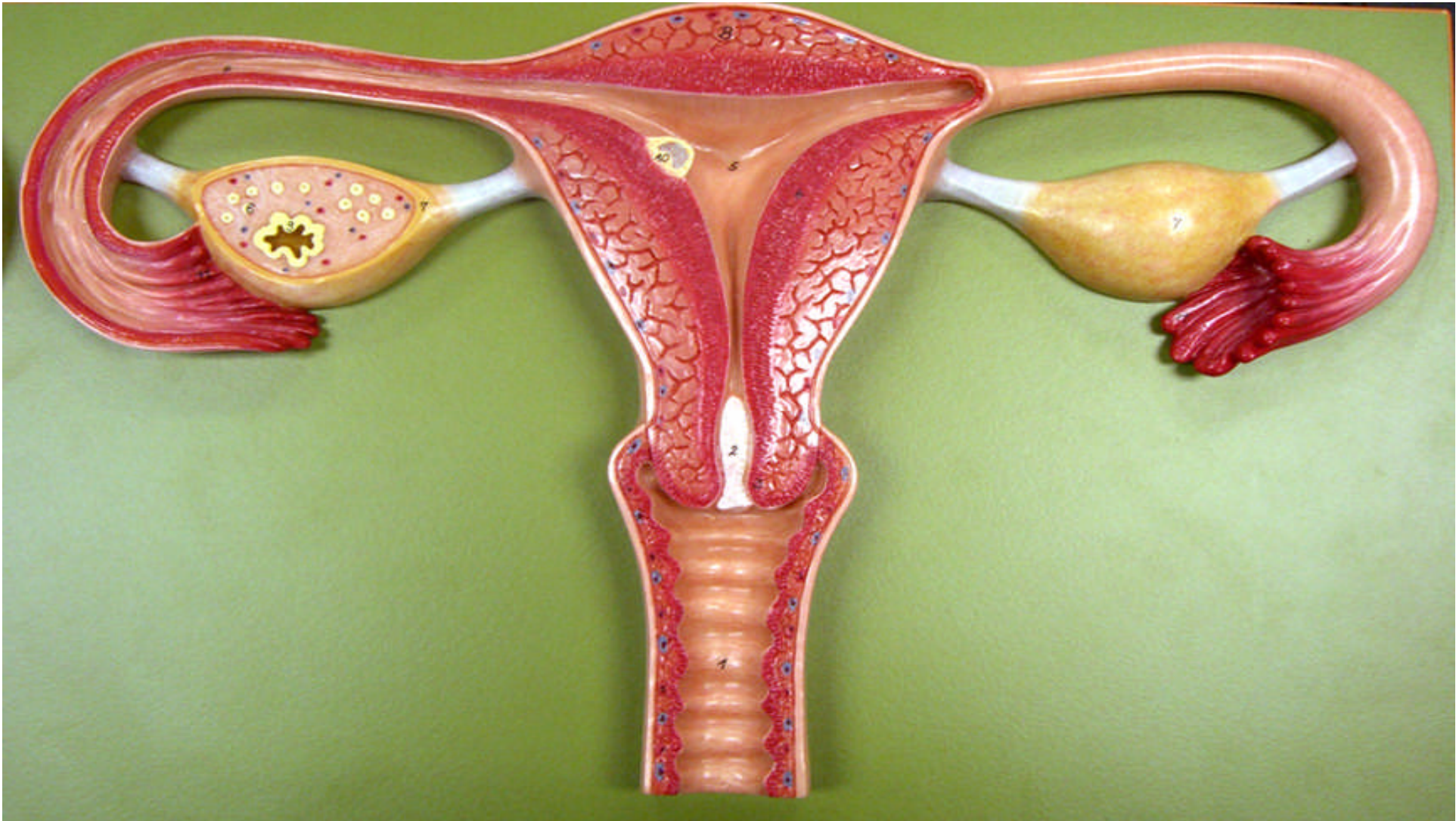
Stratified squamous epithelium

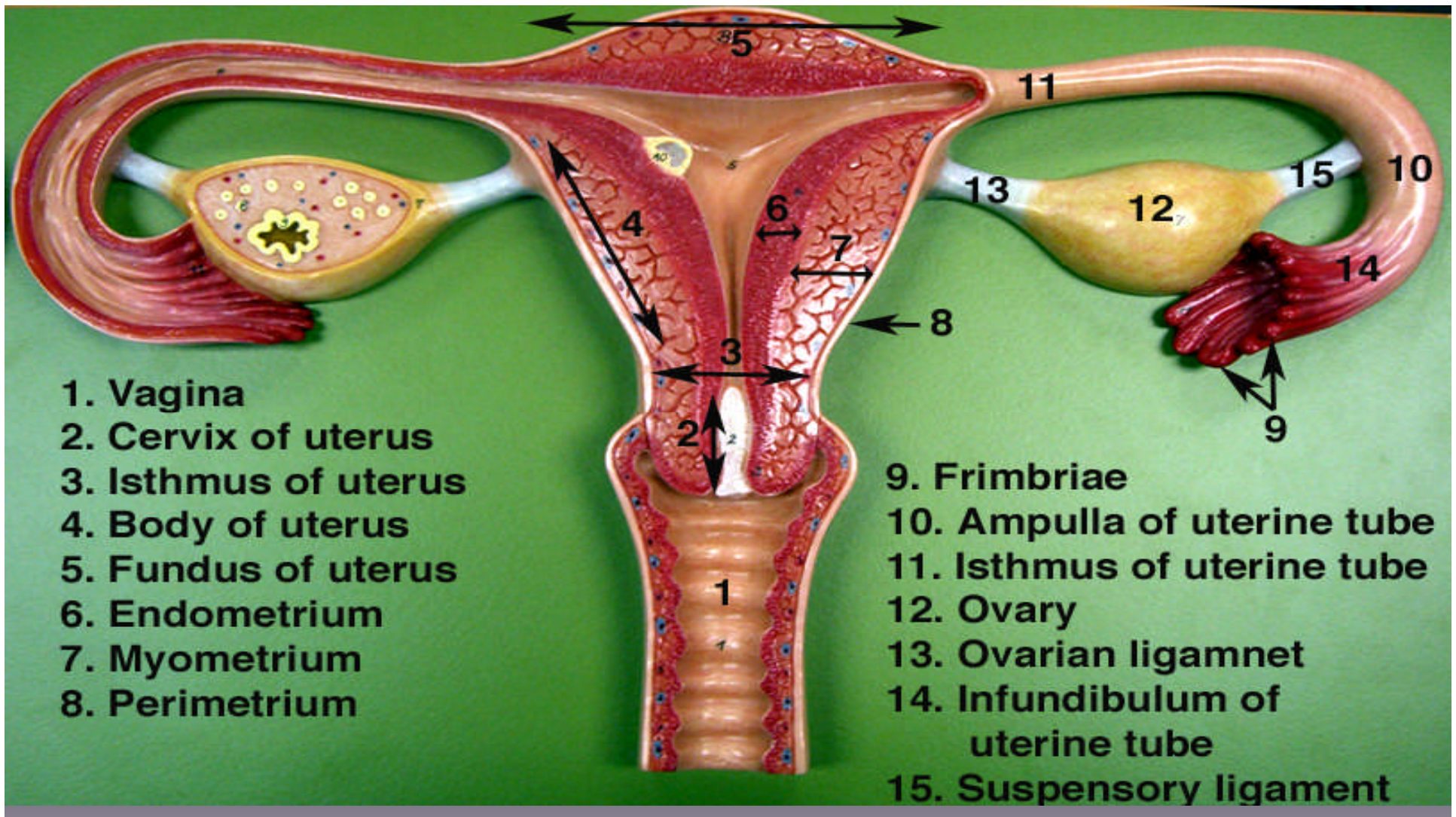
Lymphocytes

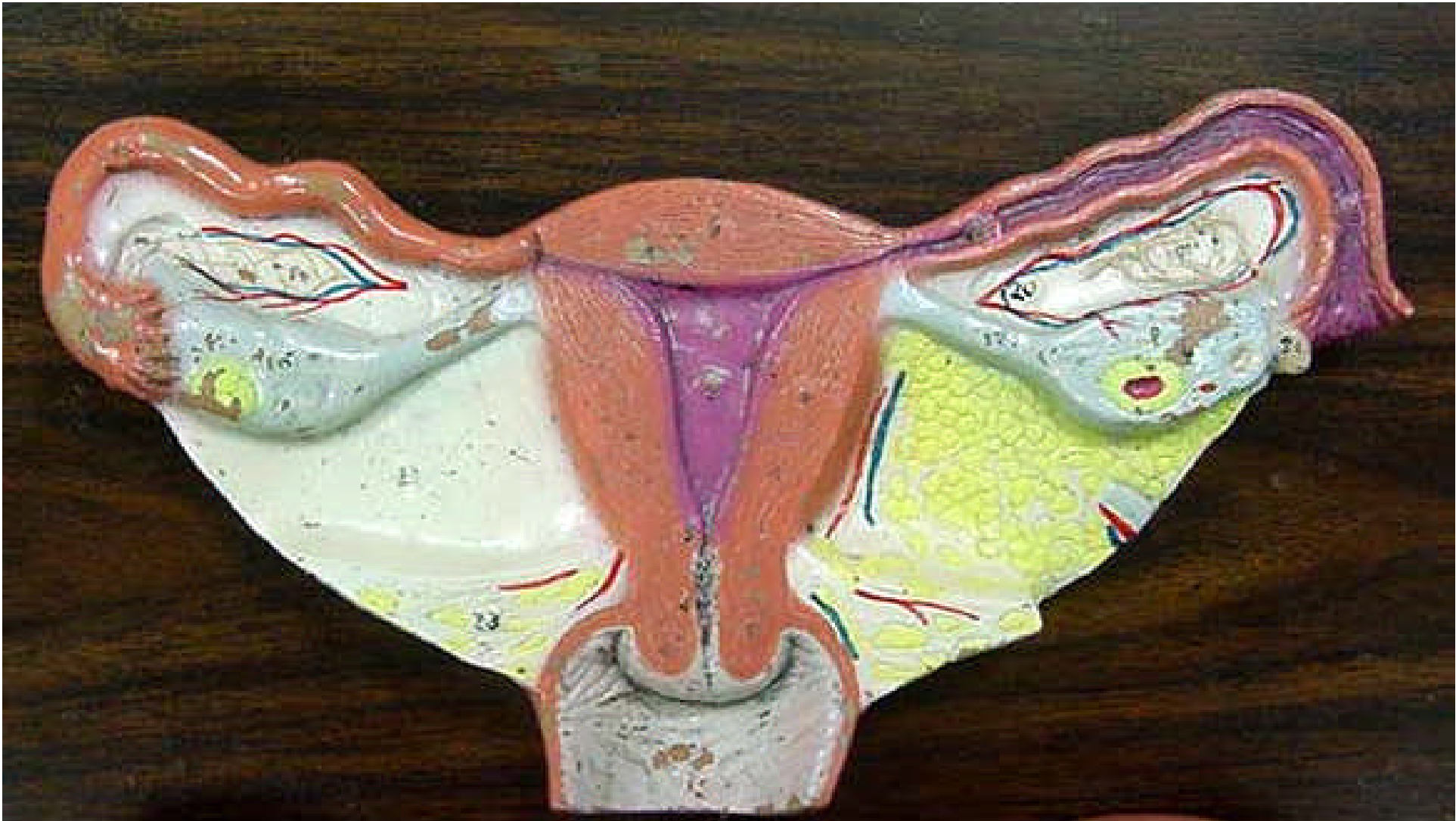Lamina propria

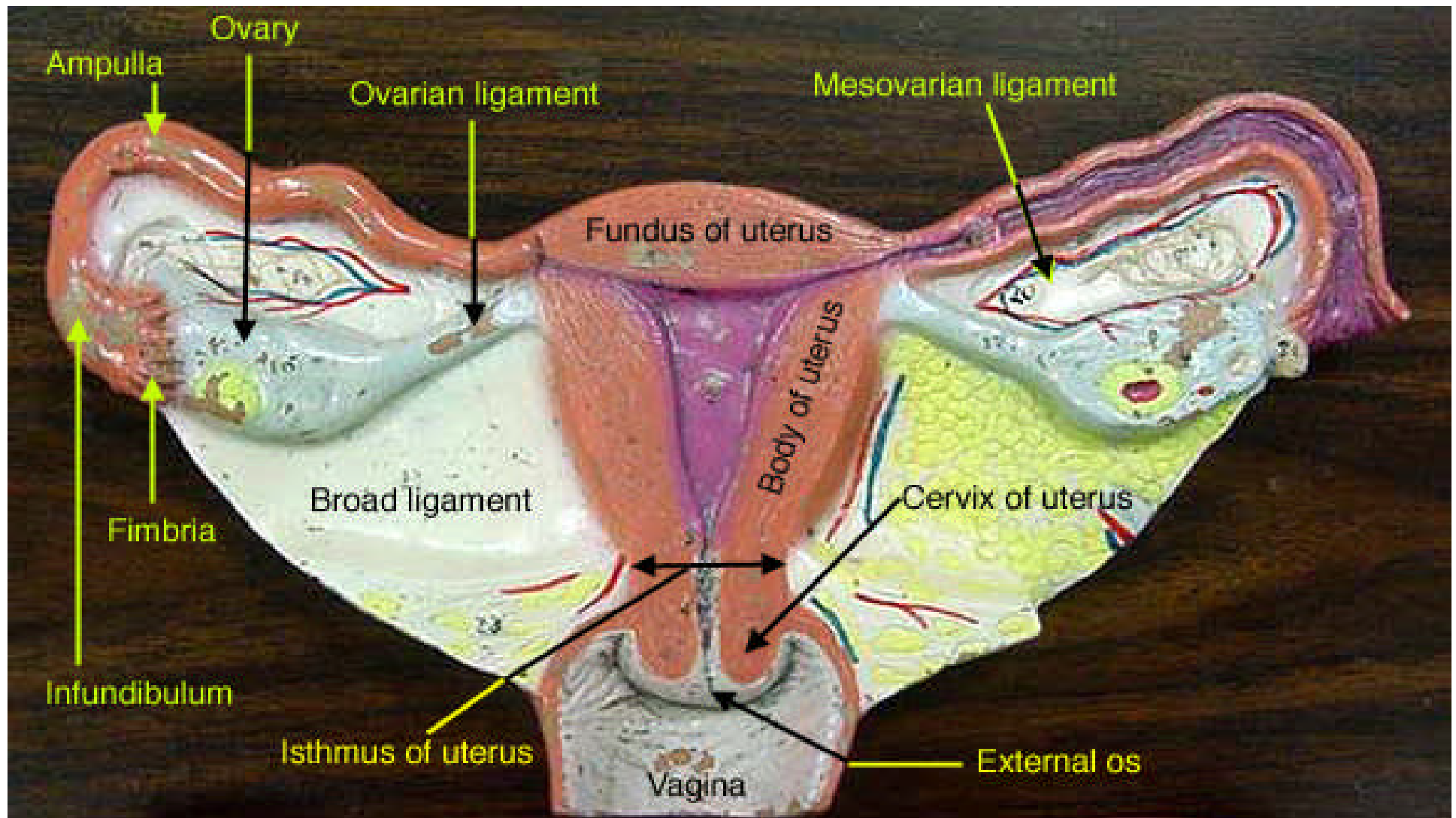
100 μ m

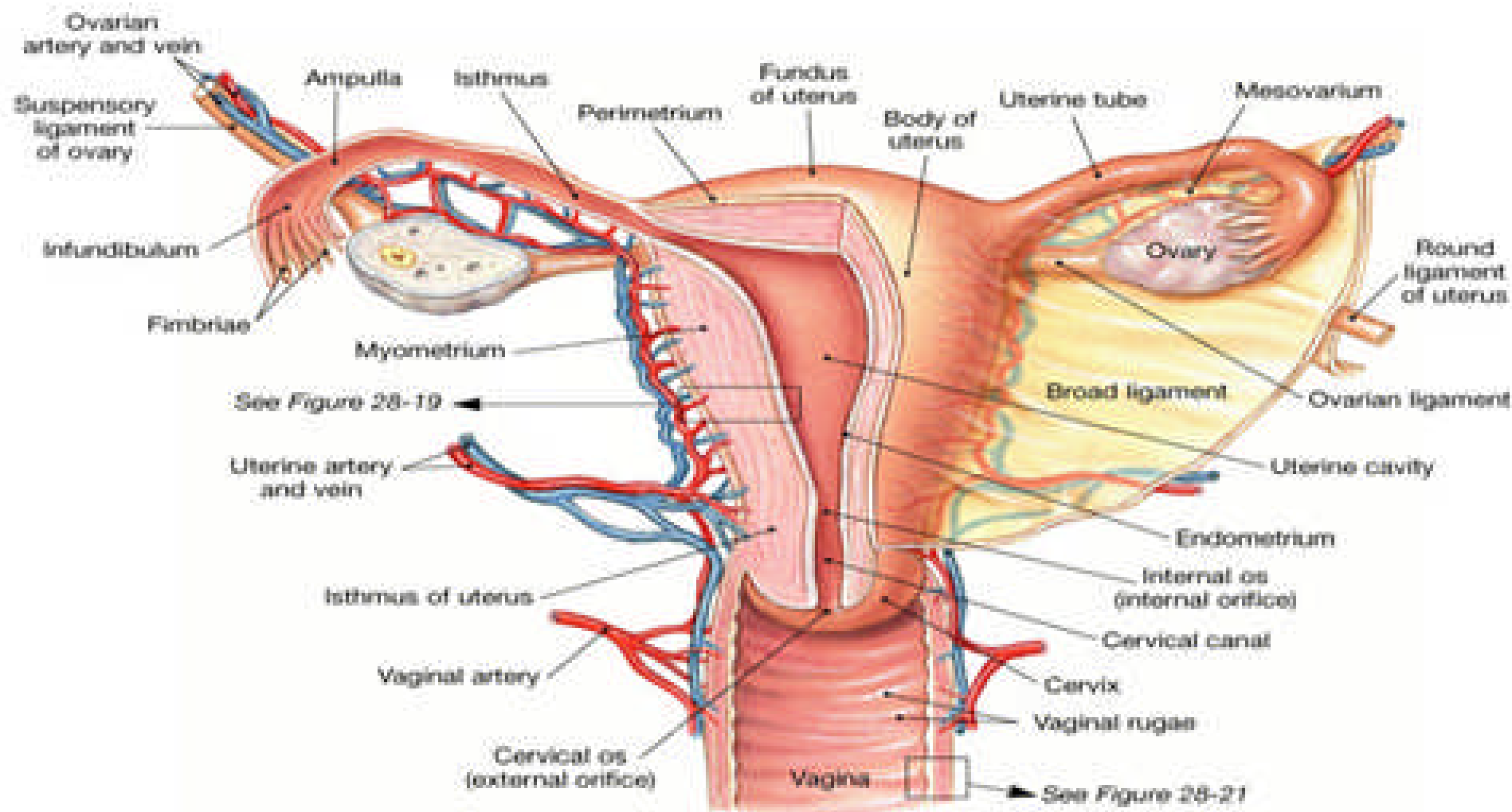




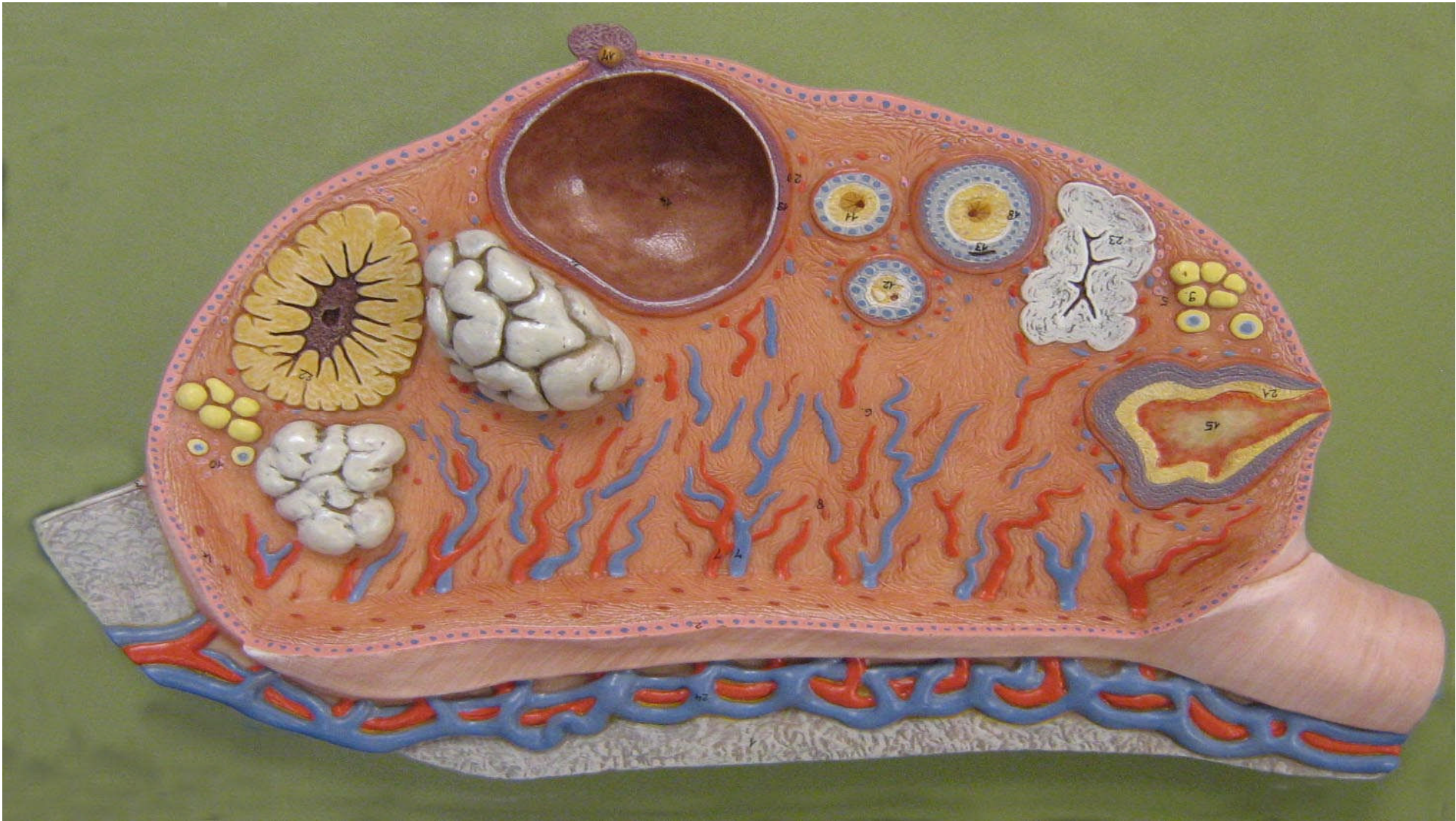

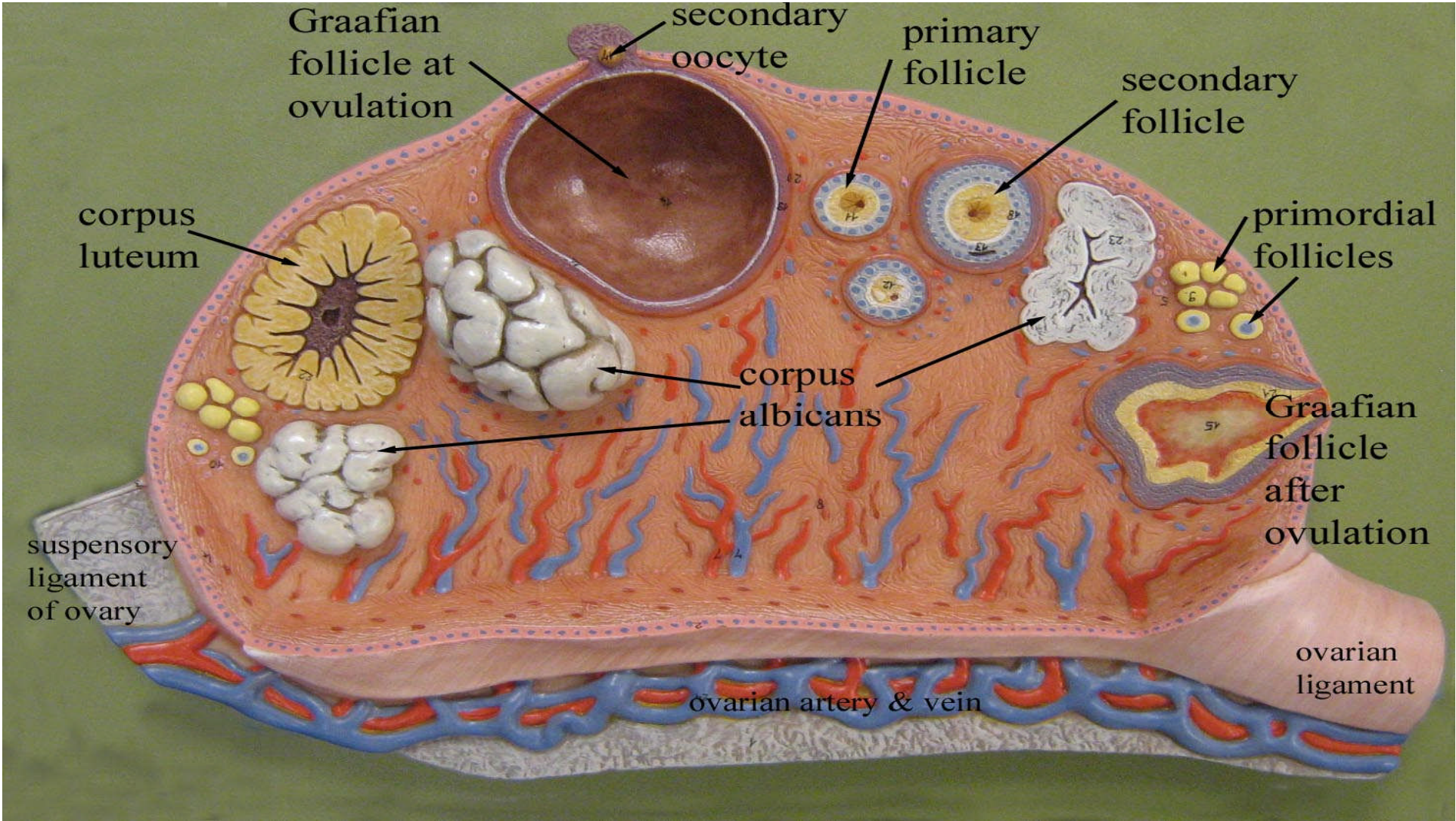




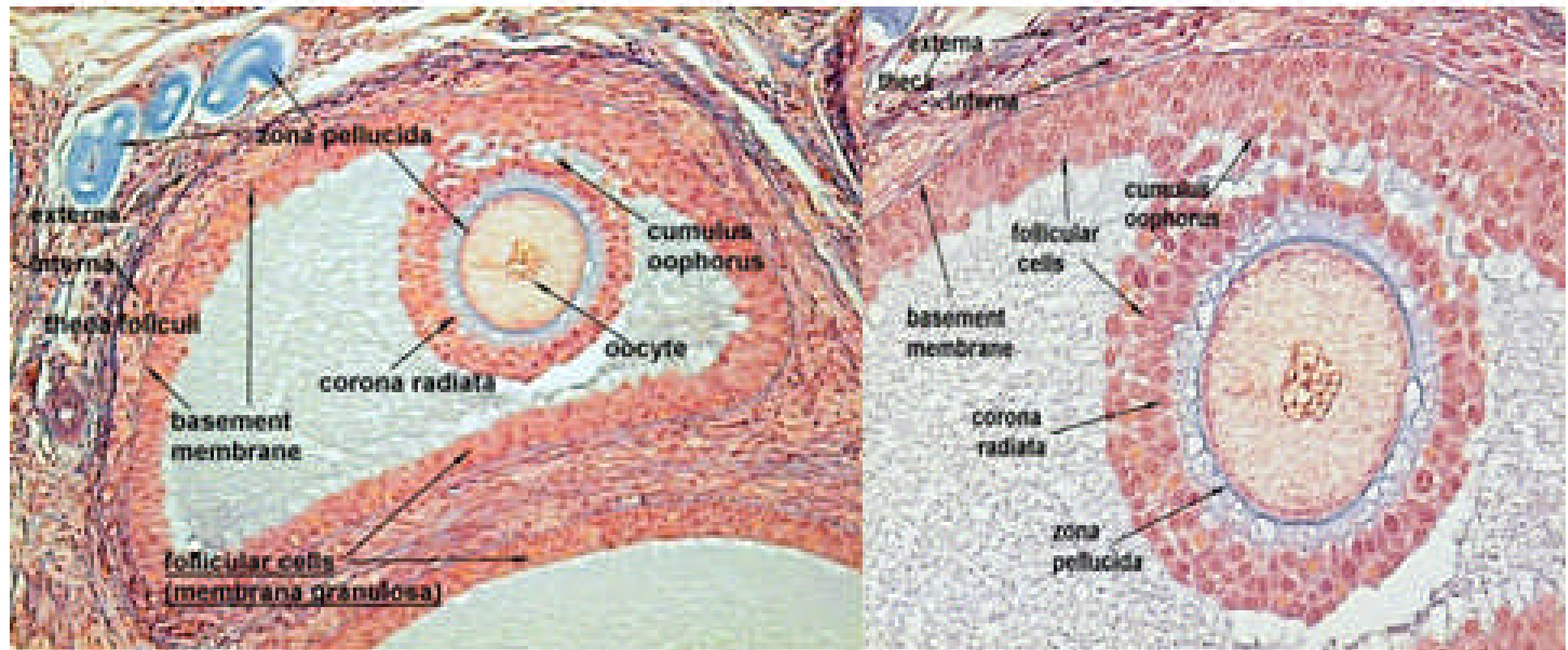


(c) Posterior view

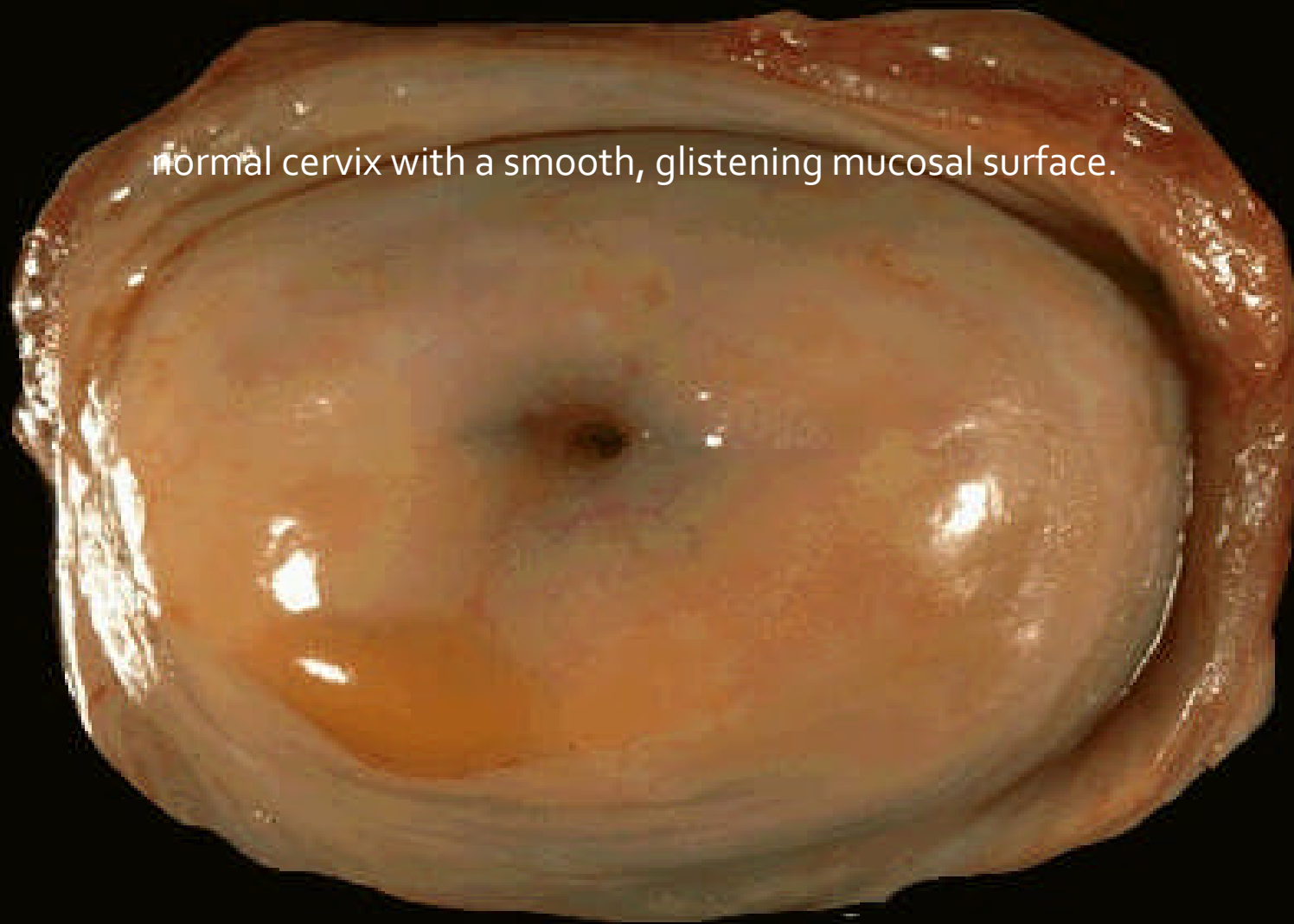



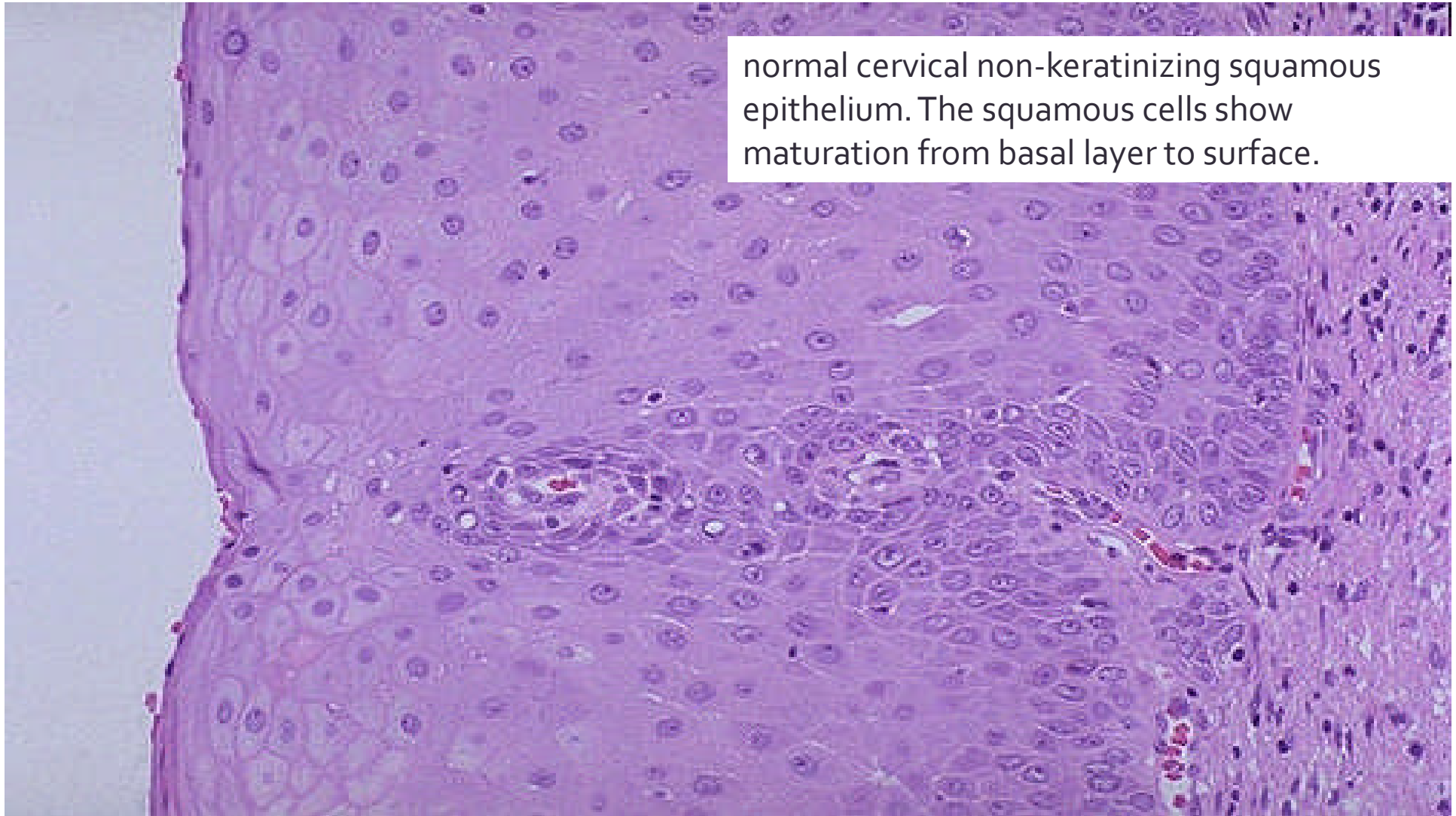
Ovaries



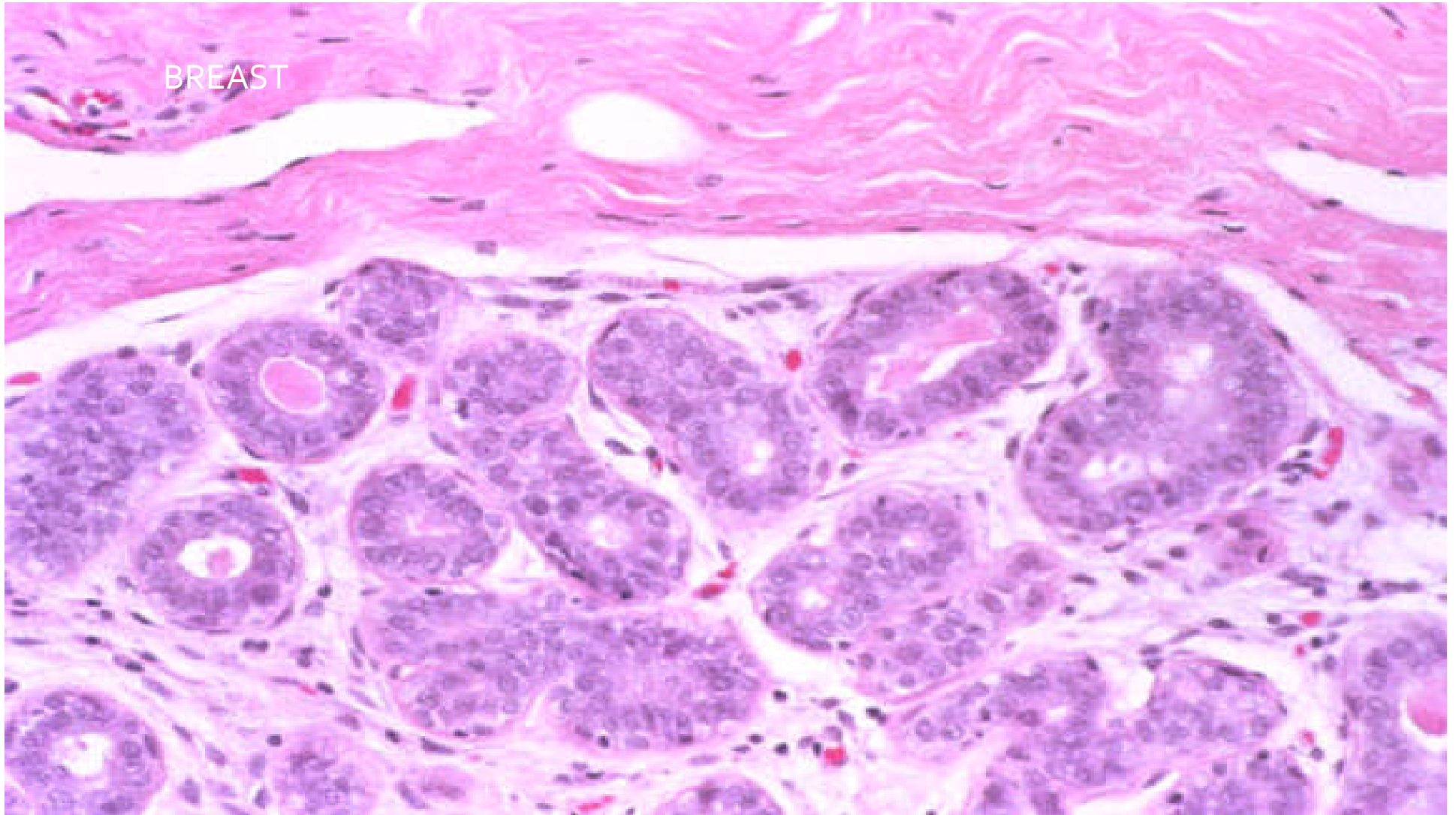
normal cervix with a smooth, glistening mucosal surface.



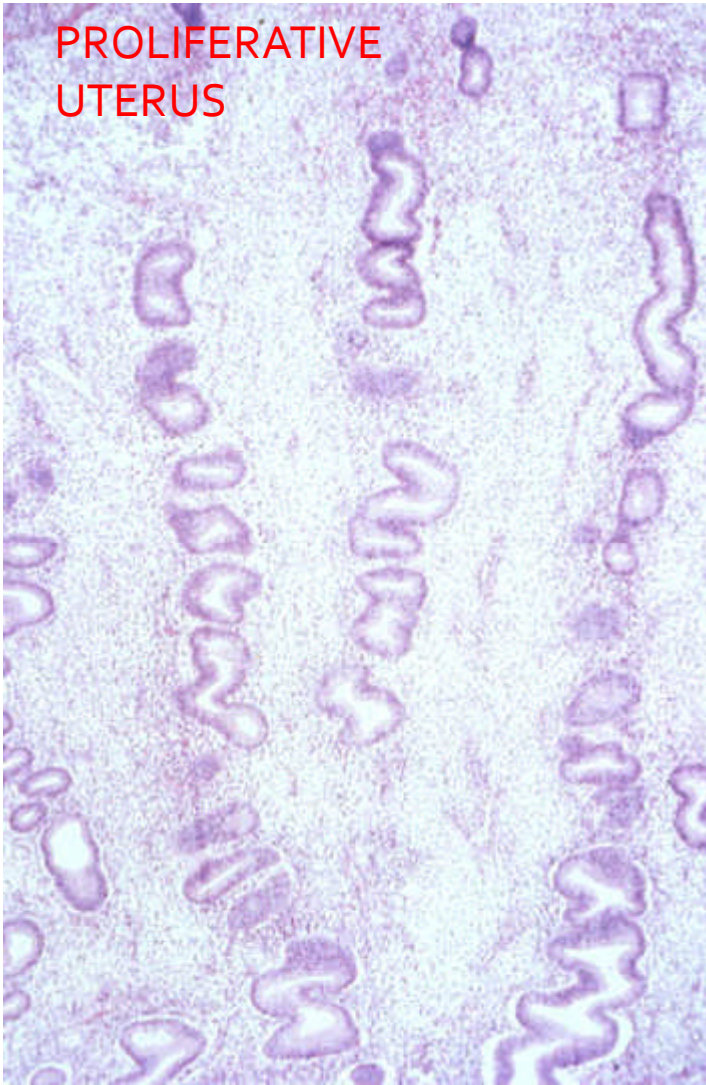
normal cervical non-keratinizing squamous epithelium. The squamous cells show maturation from basal layer to surface.



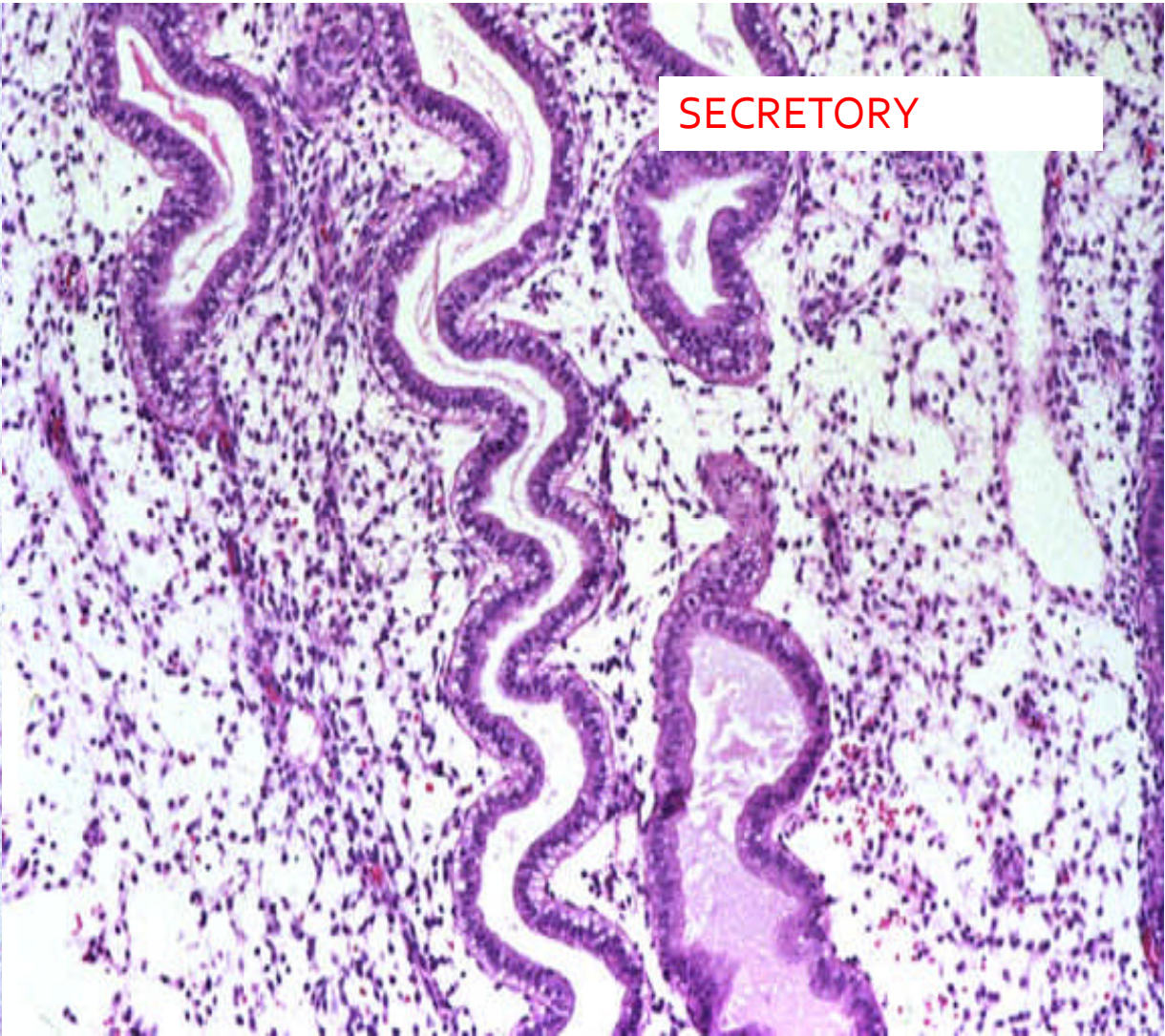
BREAST

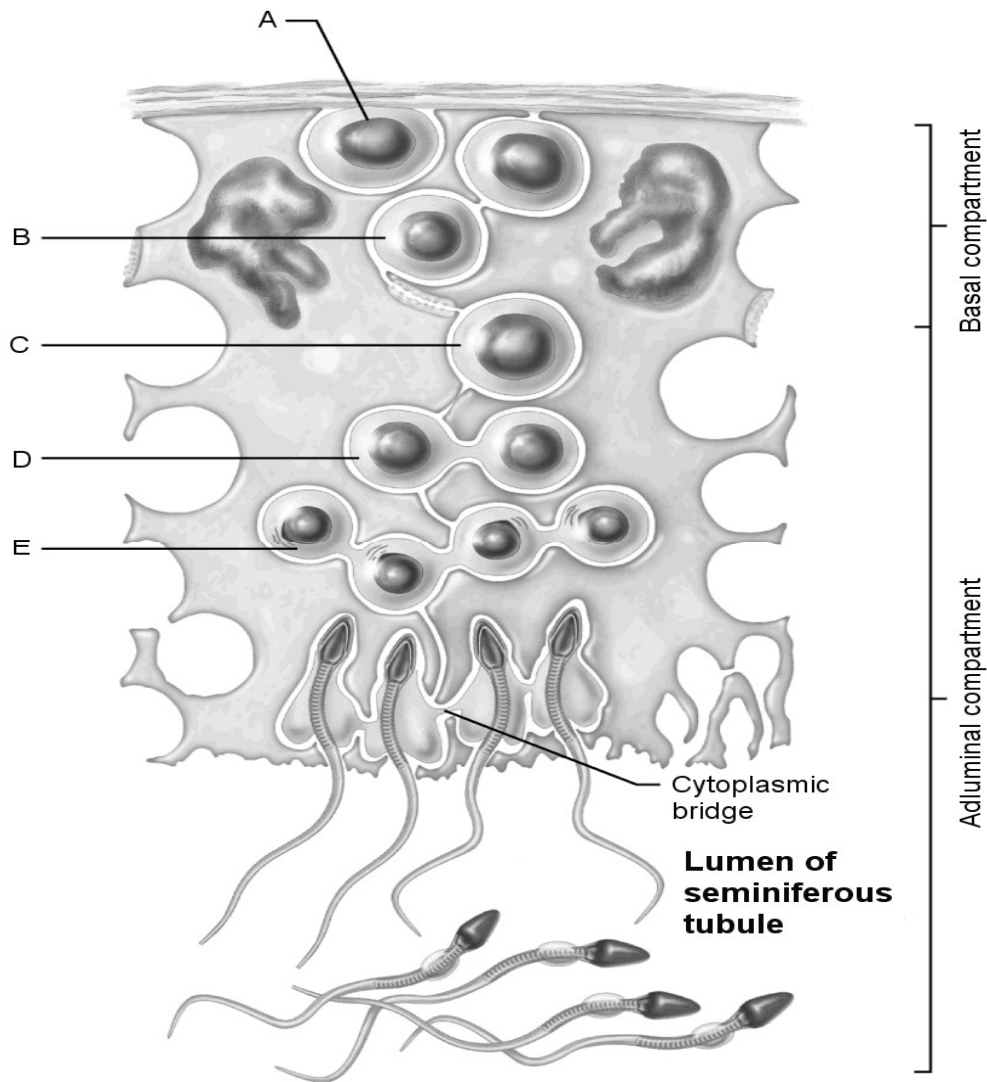


PROLIFERATIVE
UTERUS



SECRETORY





54) Stem cell.

Answer: A

55) First cells with n number of chromosomes.

Answer: D

56) Type B spermatogonia.

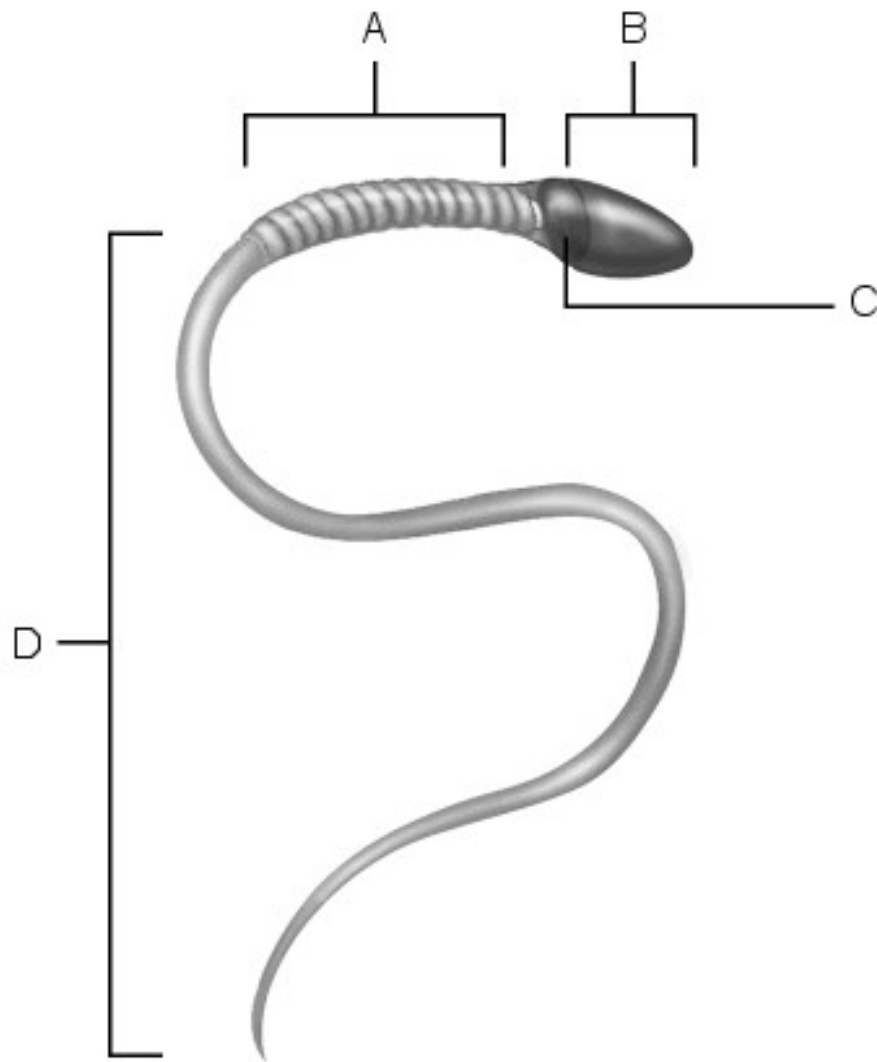
Answer: B

57) Early spermatids.

Answer: E

58) Primary spermatocyte.

Answer: C



match the following:

59) Acrosome.

Answer: B

60) Location of mitochondria.

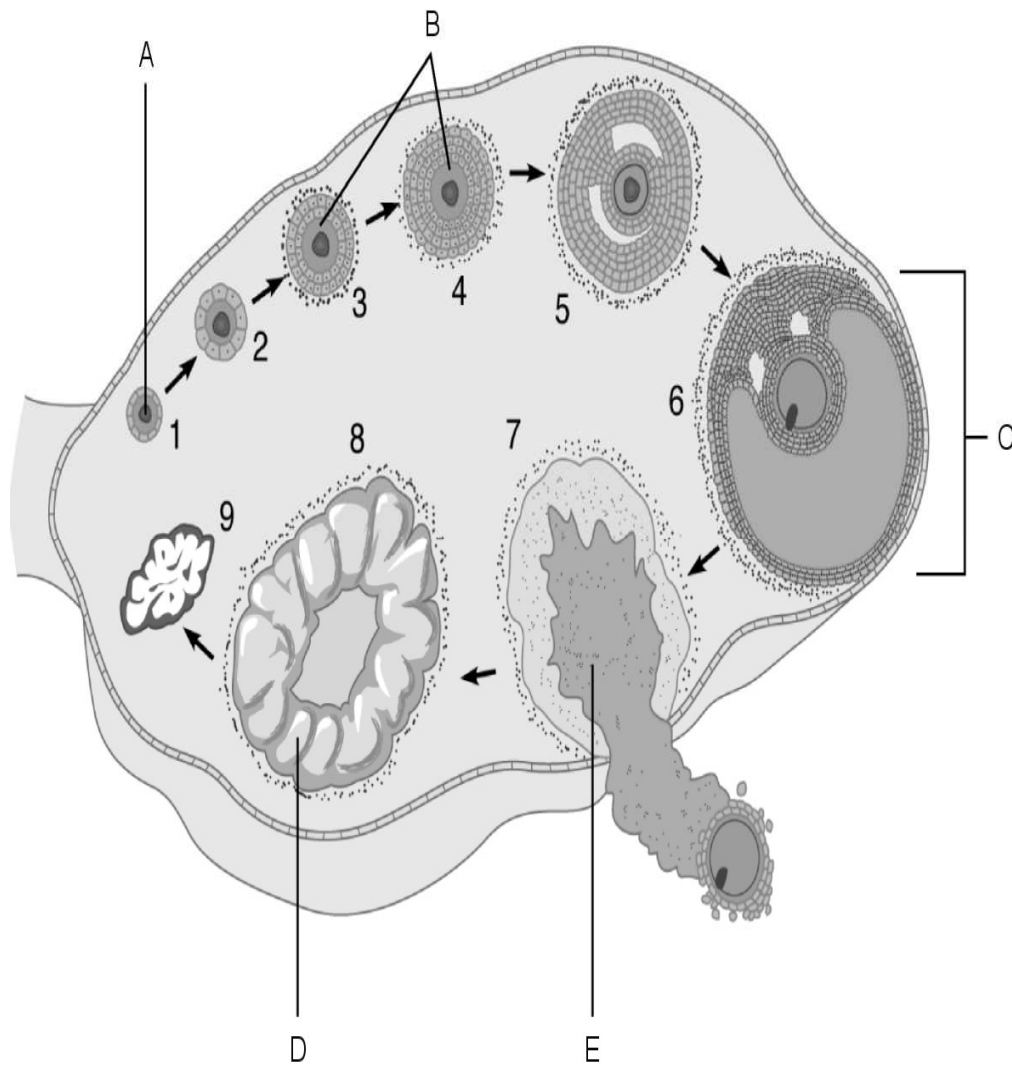
Answer: A

61) Midpiece.

Answer: A

62) Location of nucleus.

Answer: C



63) The stage called ovulation.

Answer: E

64) Vesicular (Graafian) follicle.

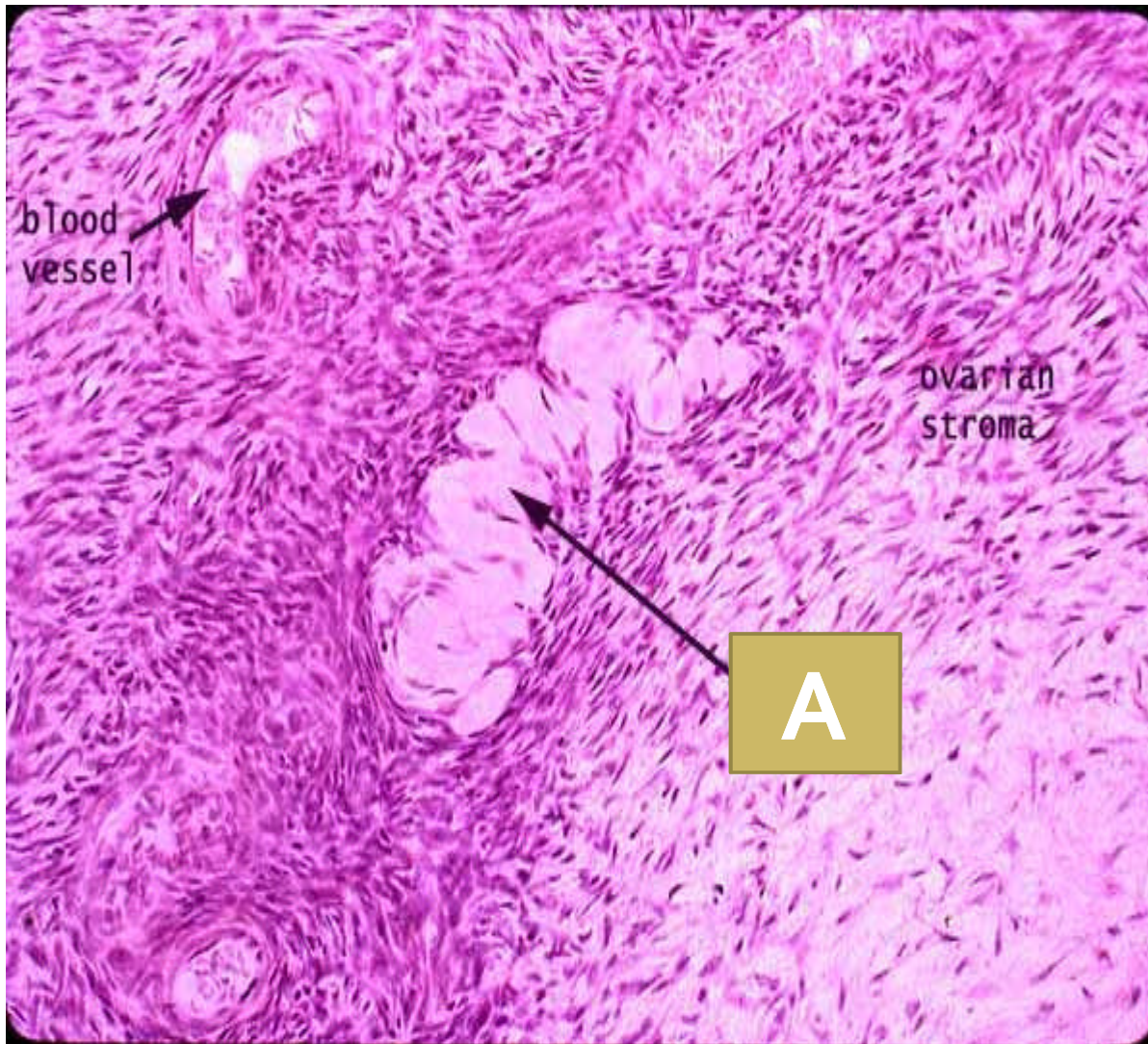
Answer: C

65) Primary follicles.

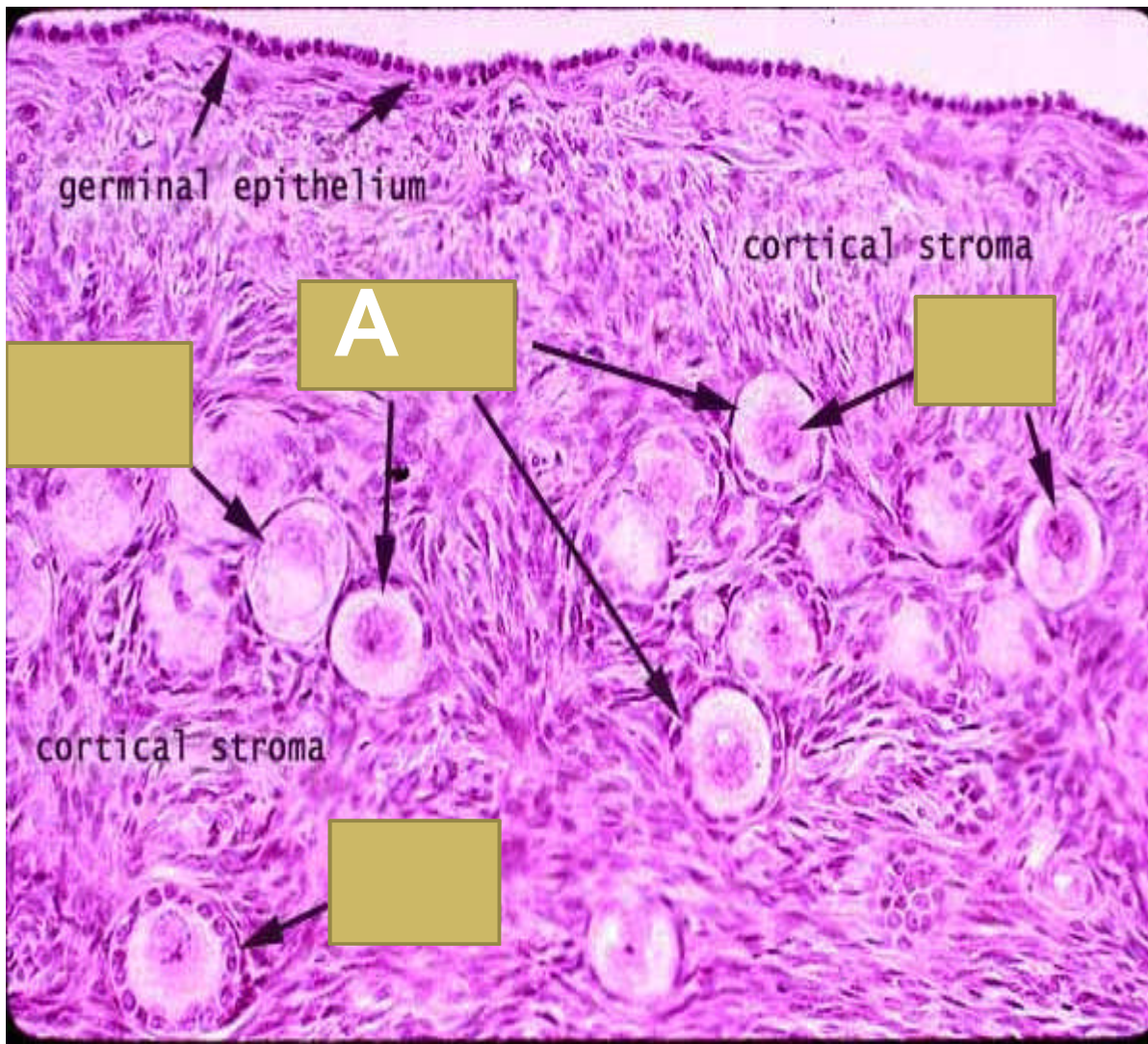
Answer: B

66) Primordial follicle.

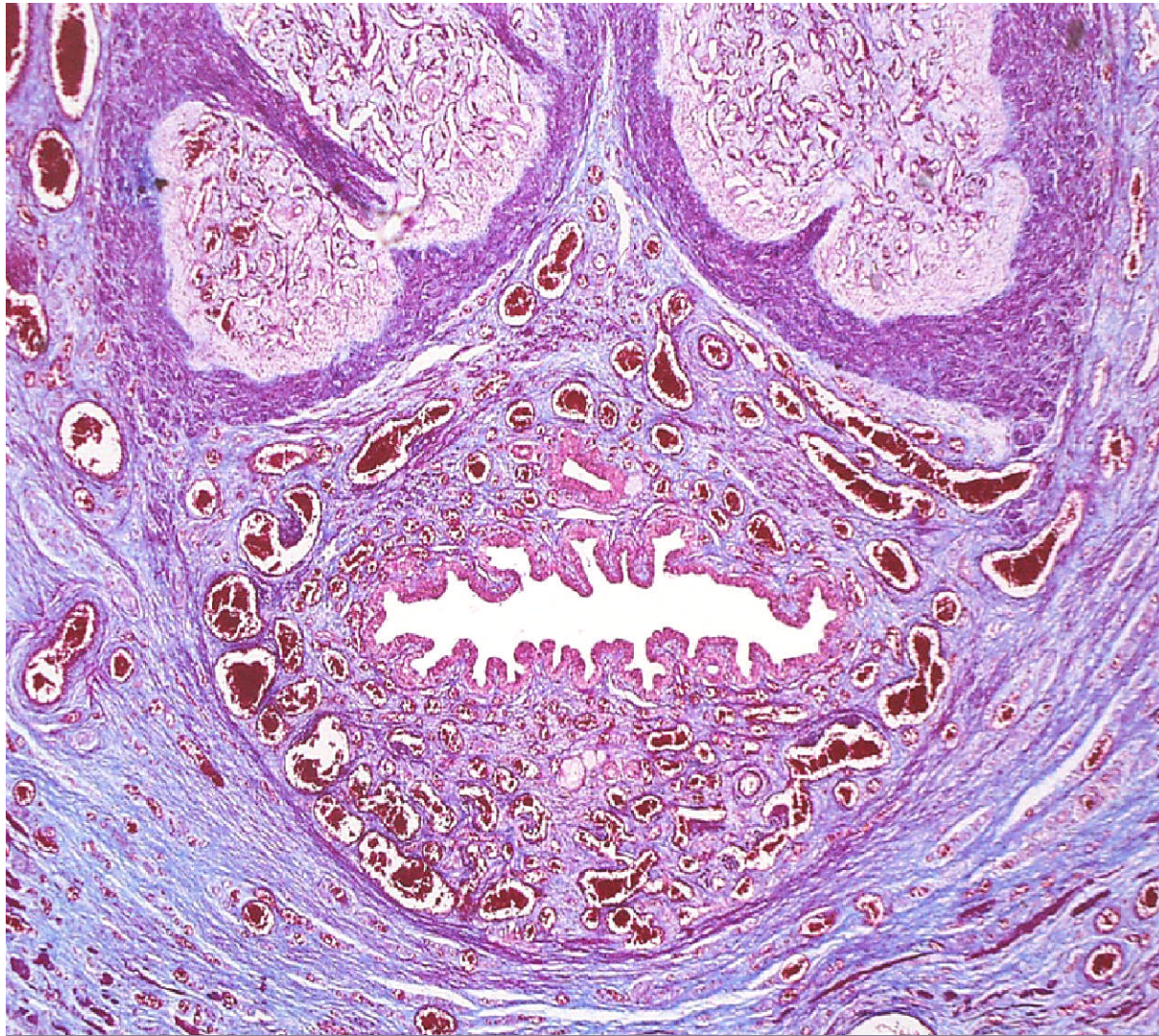
Answer: A



67/Identify structure A
A/CORPUS ALBICANS
B/CORPUS LUTEUM
C/CORPUS MAGELUM
D/GRAFIAN VESICLE
E/PRIMARY FOLLICLE



68/IDENTIFY A
A/SECONDARY FOLLICLES
B/PRIMARY FOLLICLE
C/TERTIARY FOLLICLES
D/ATRETIC FOLLICLE



73/Where this picture has been taken from?

A/VAGINA

B/BREAST

C/PENIS

D/URETHRA

E/URETER

83/ Identify 1

A/ Leydig cells

B/Sertoli cells

C/ interstitial cells

d/a,b correct

e/a,c correct

84/ FUNCTION OF #1

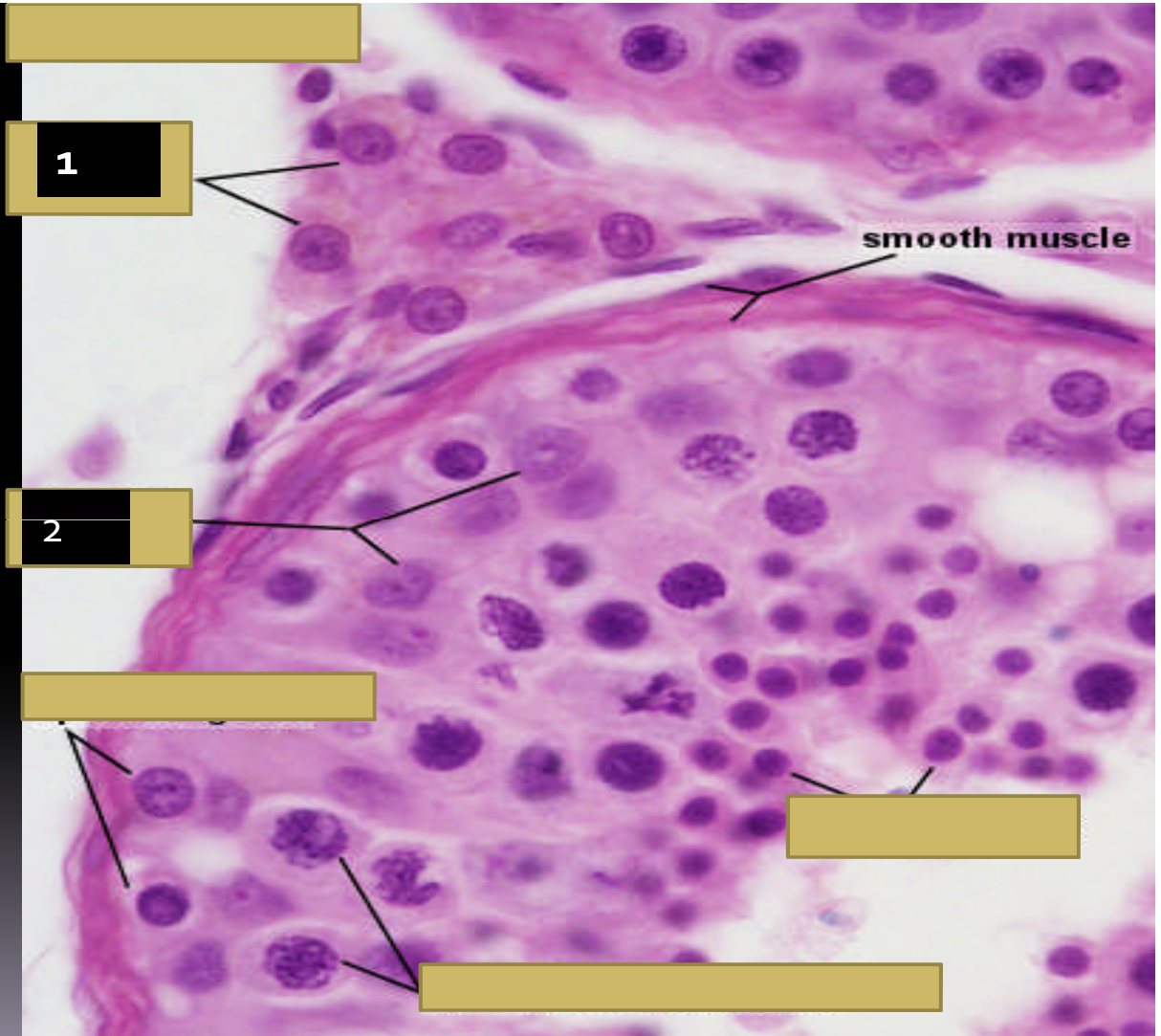
A/They produce testosterone in the presence of luteinizing hormone (LH).

B/They produce testosterone in the presence of FSH

C/Maintenance and protection

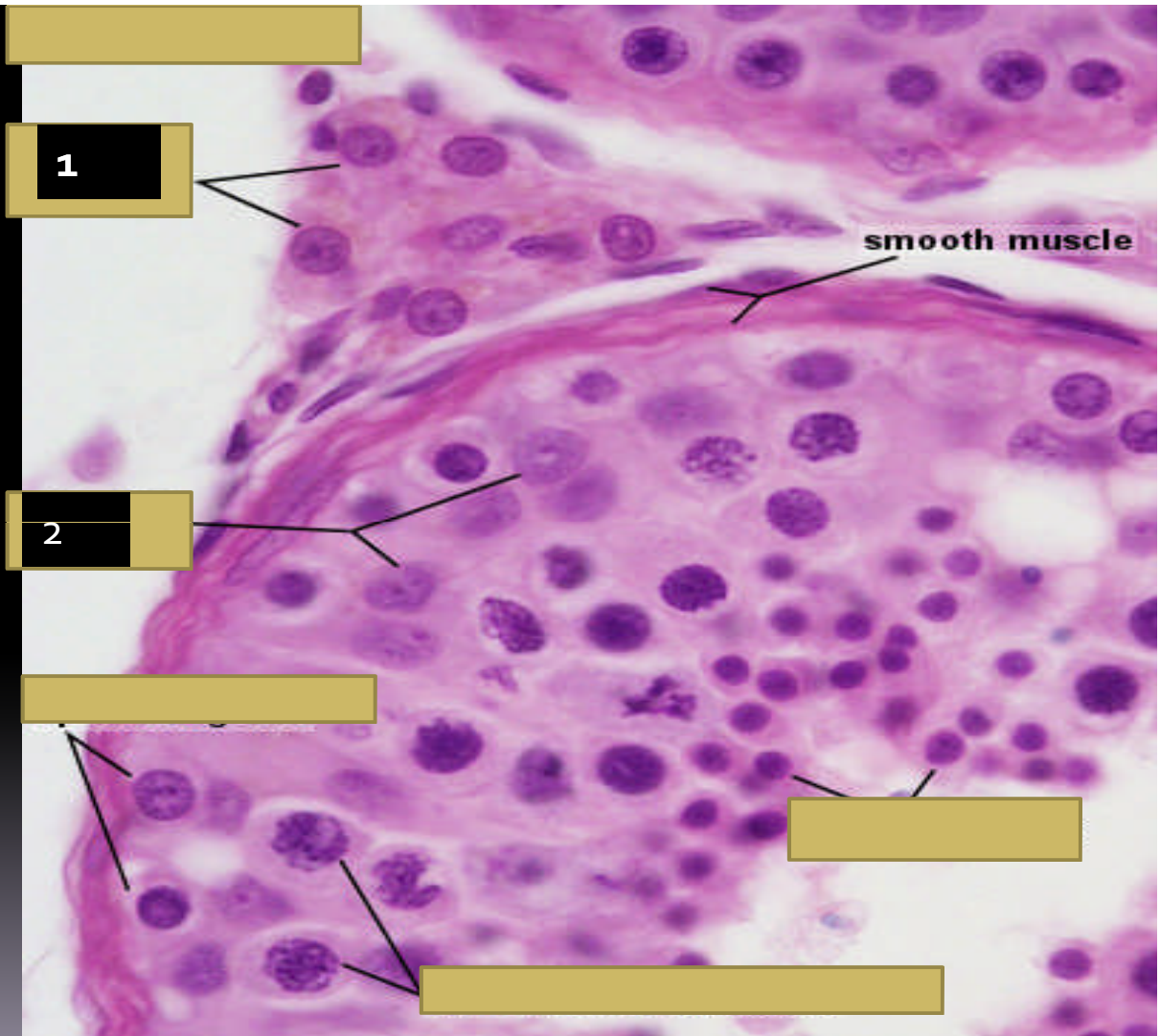
D/They produce Estrogen in the presence of luteinizing hormone (LH).

e/I am confused

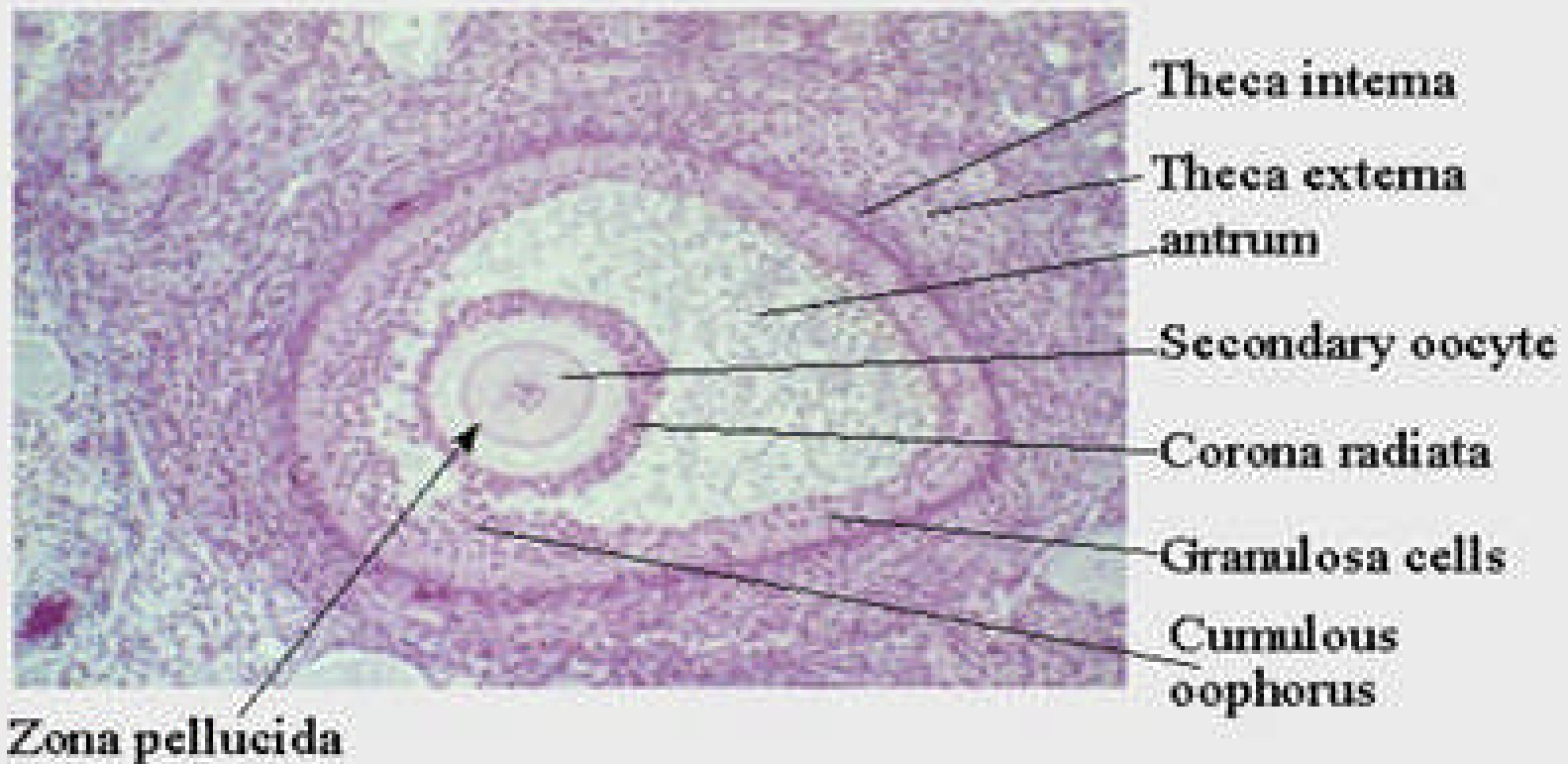


83/ Identify 1
A/ Leydig cells
B/Sertoli cells
C/ interstitial cells
d/a,b correct
e/a,c correct

84/ FUNCTION OF #1
A/They produce testosterone in the presence of luteinizing hormone (LH).
B/They produce testosterone in the presence of FSH
C/Maintenance and protection
D/They produce Estrogen in the presence of luteinizing hormone (LH).
e/I am confused



Mature (Vesicular) Follicle

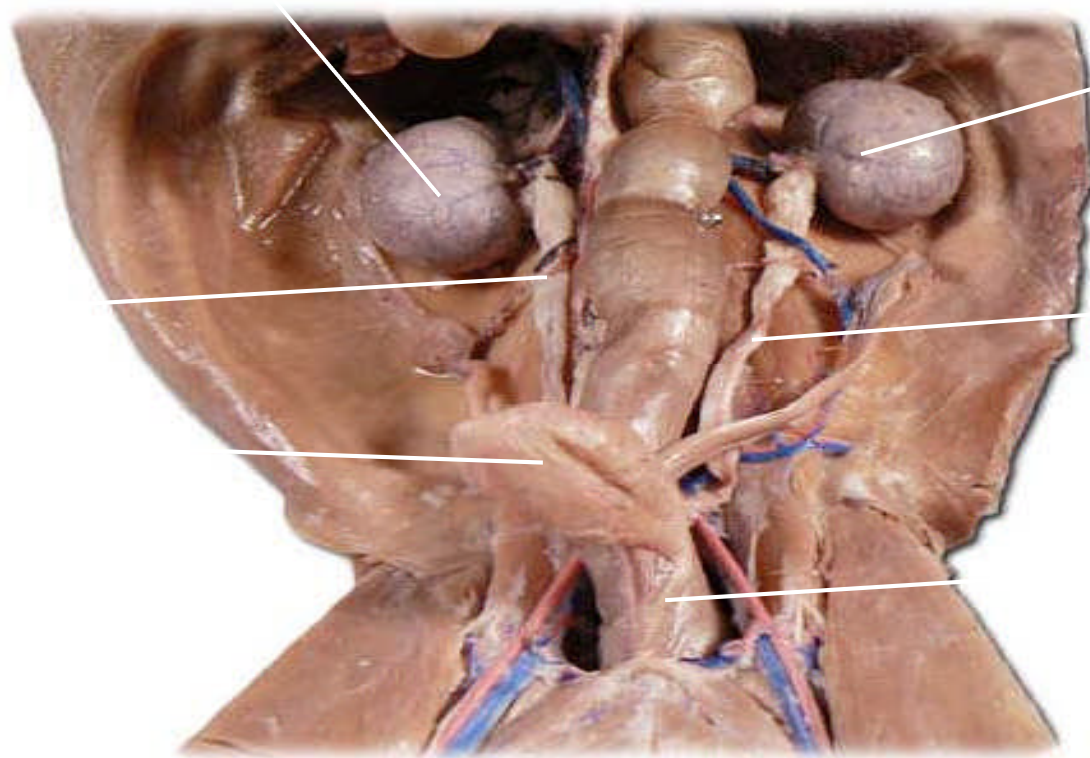




Urinary

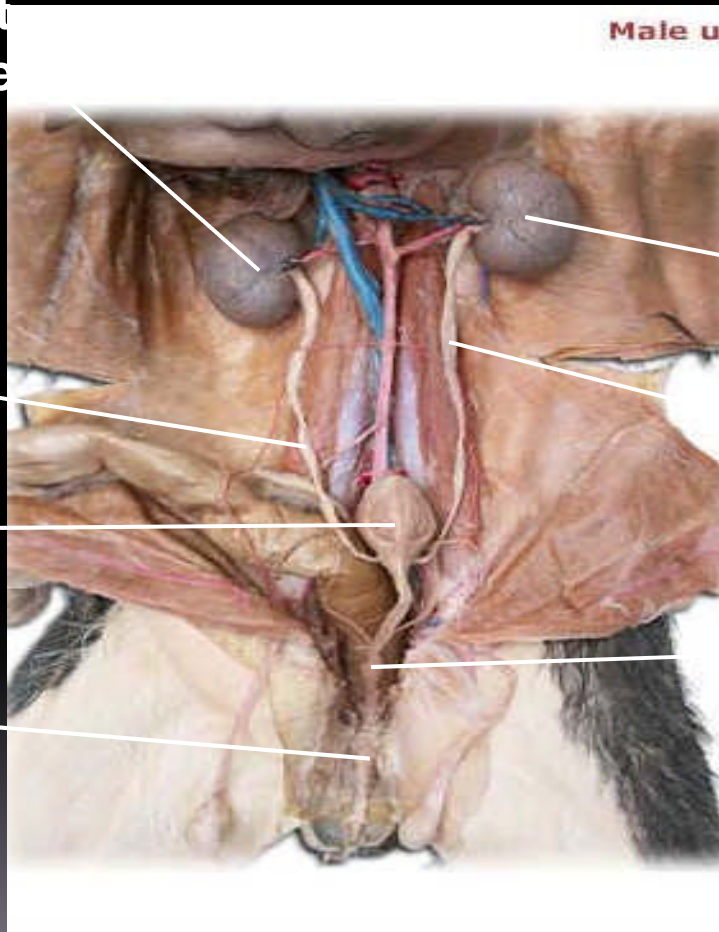
CAT DISSECTION

Female urinary system, anterior view



Right
kidney

Male u



Left kidney

Right ureter

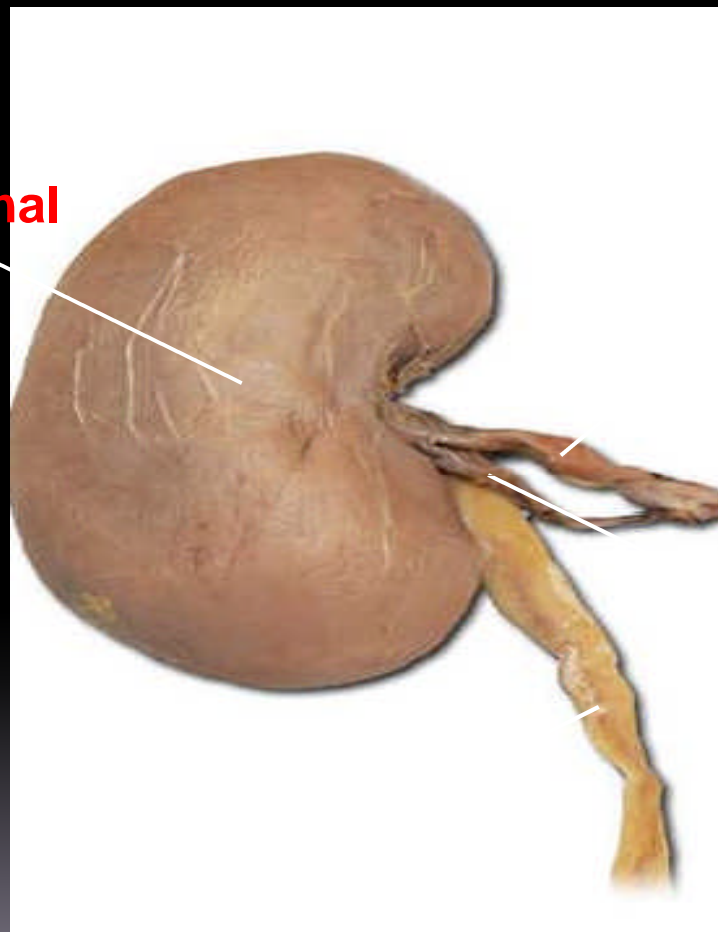
Left ureter

Urinary
bladder

Urethra

Penis

Sheep kidney within renal capsule



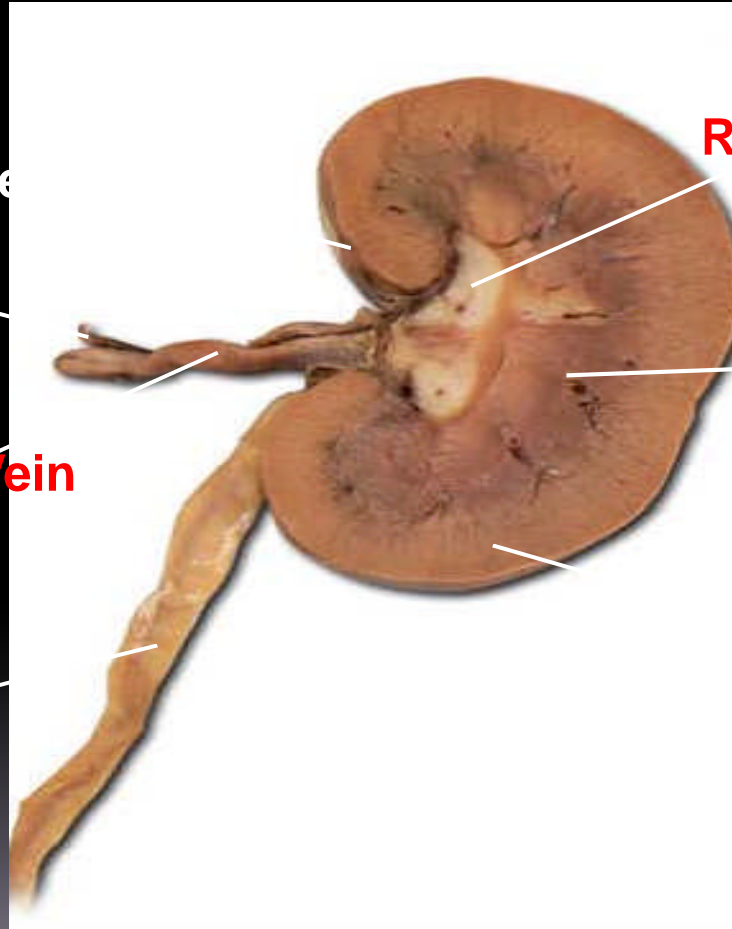
Renal vein

Renal artery

Renal capsule
Renal artery

Renal Vein

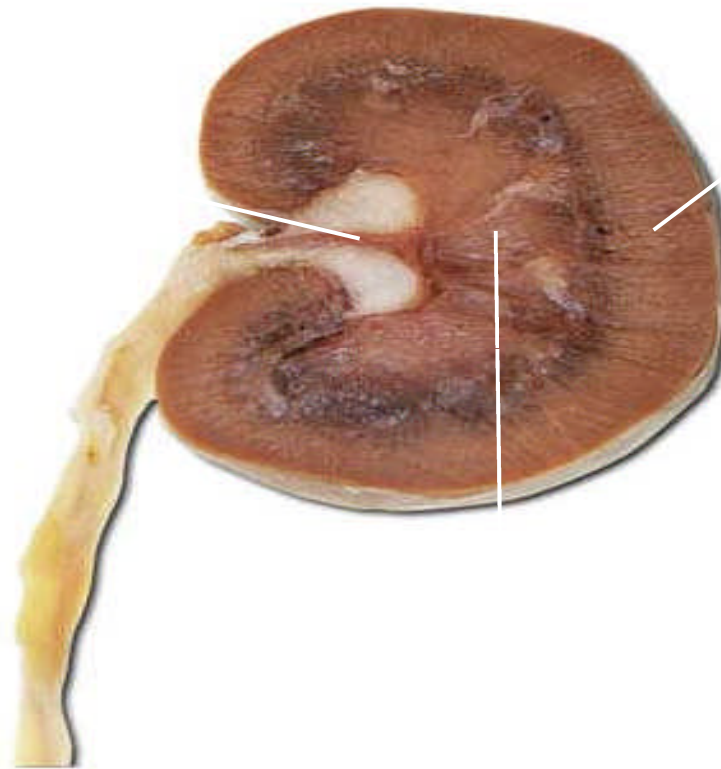
Ureter



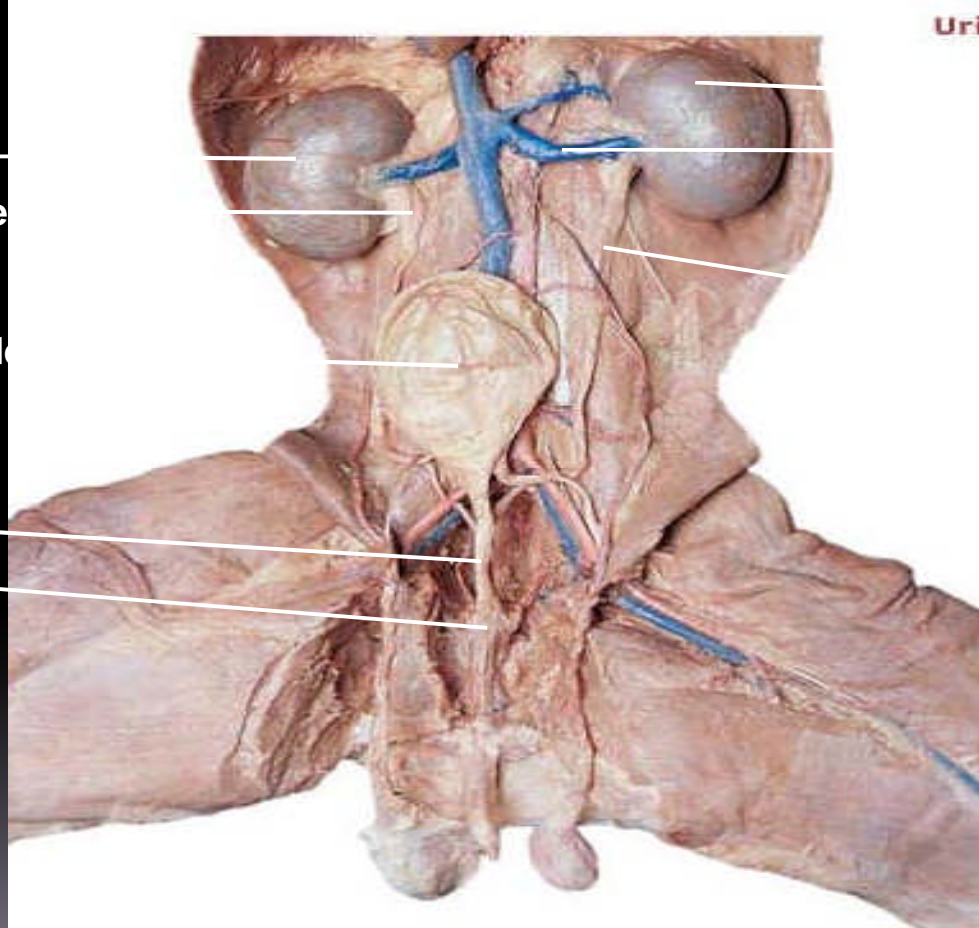
Renal pelvis

Renal medulla

Kidney



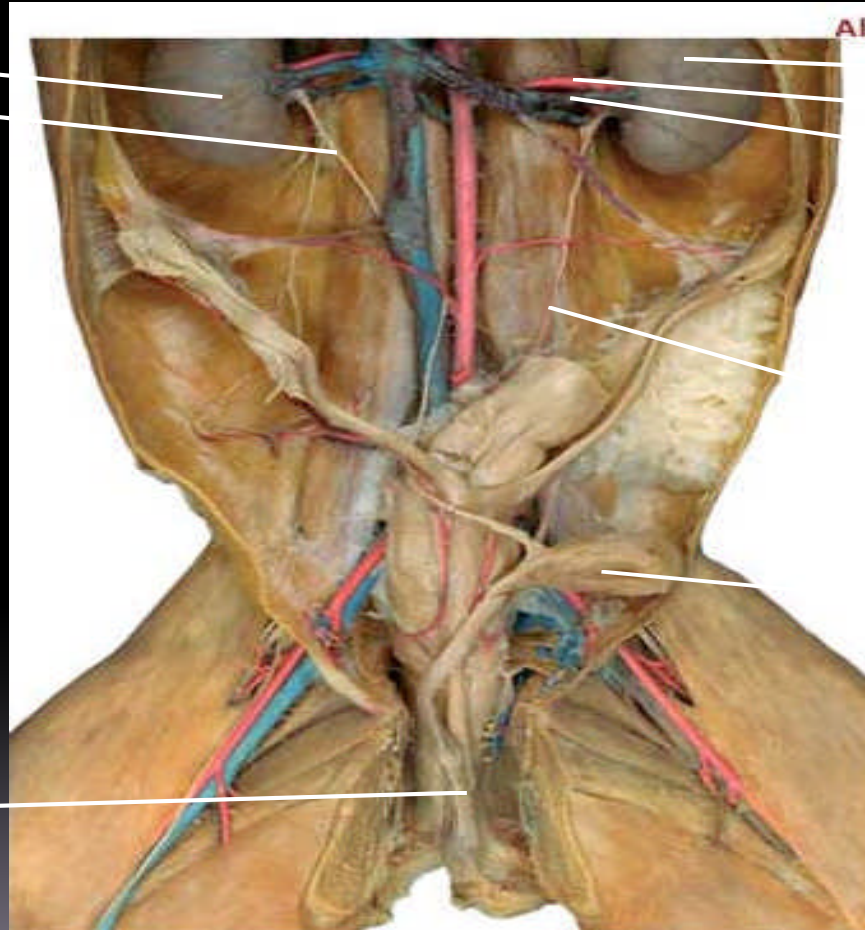
Right kidney
Right ureter
Urinary bladder
Urethra
Prostate



Uri

Left kidney
Renal veins (right and left)
Left ureter

Right kidney
Right ureter



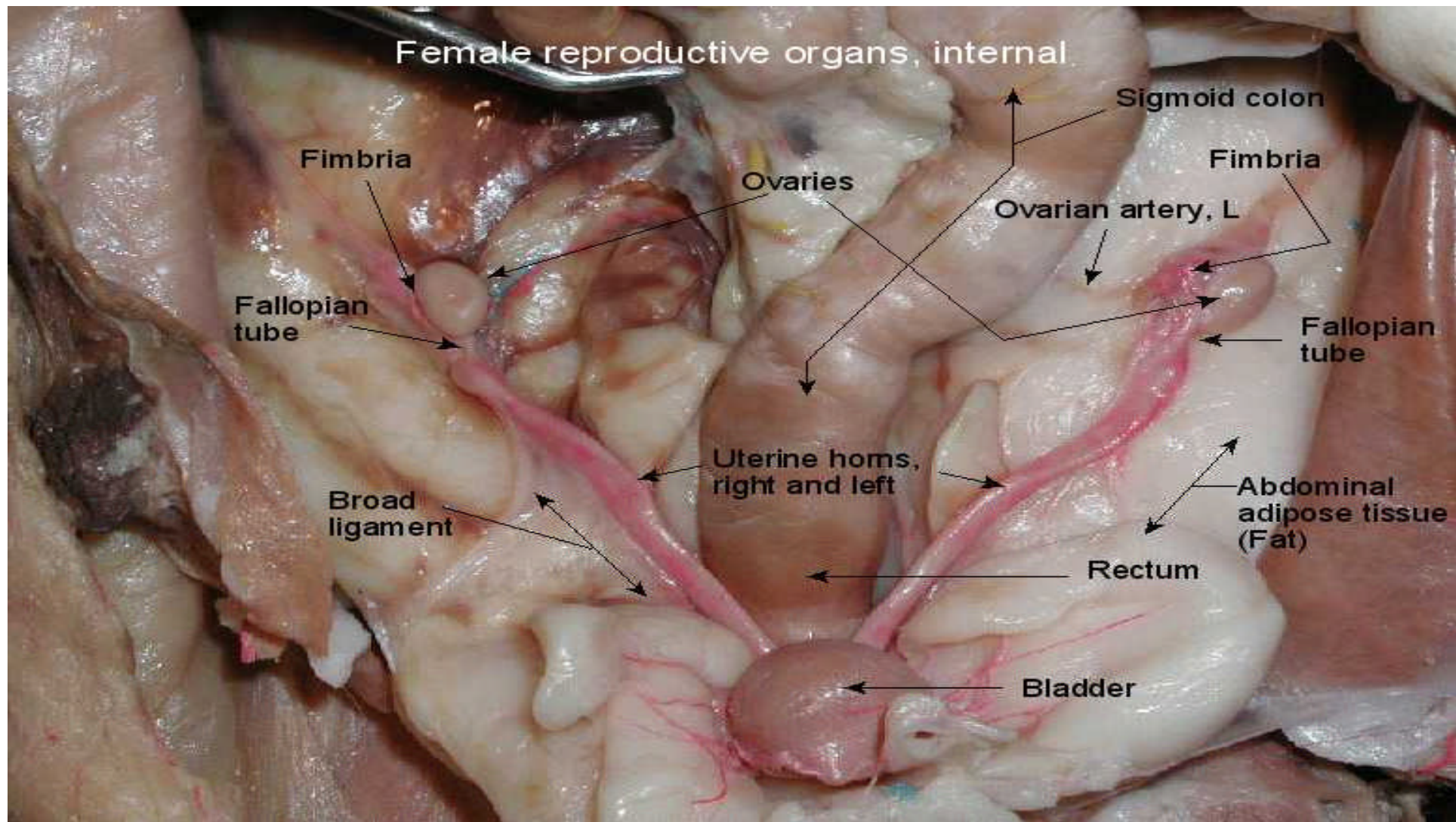
Left kidney
Renal artery
Renal vein

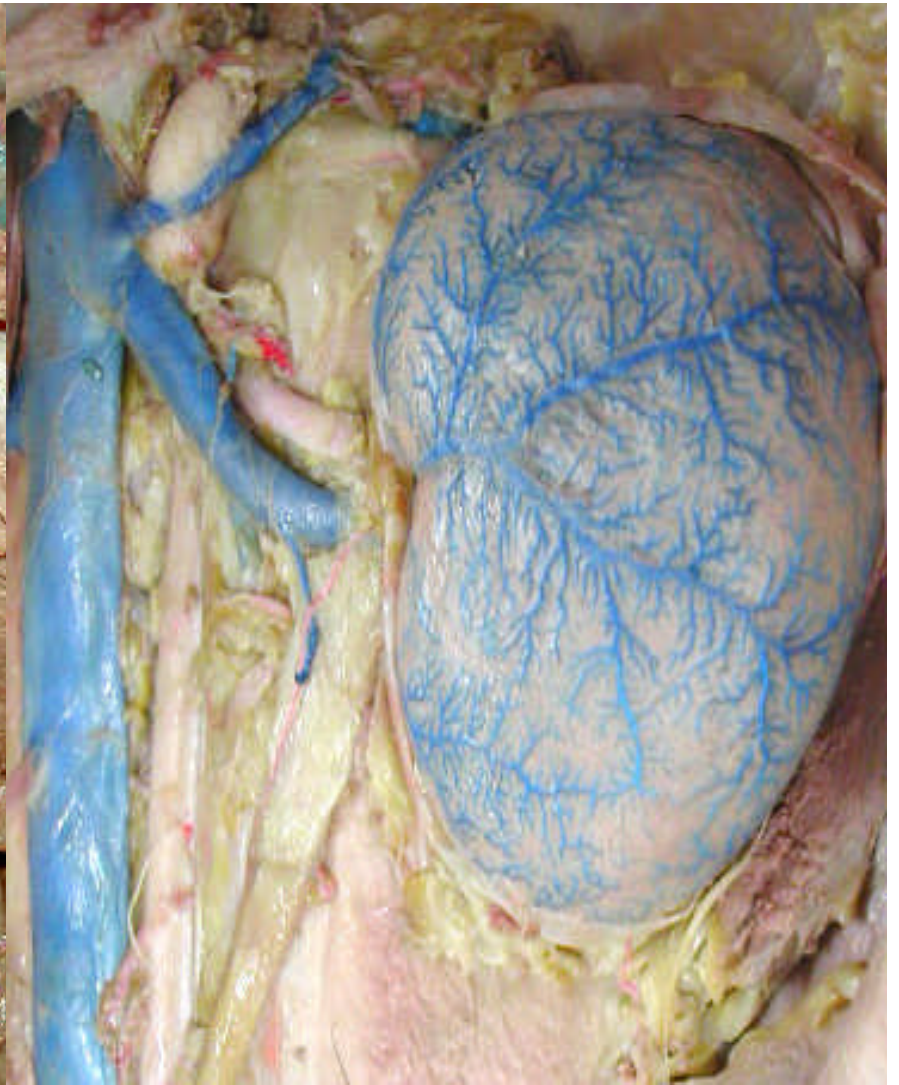
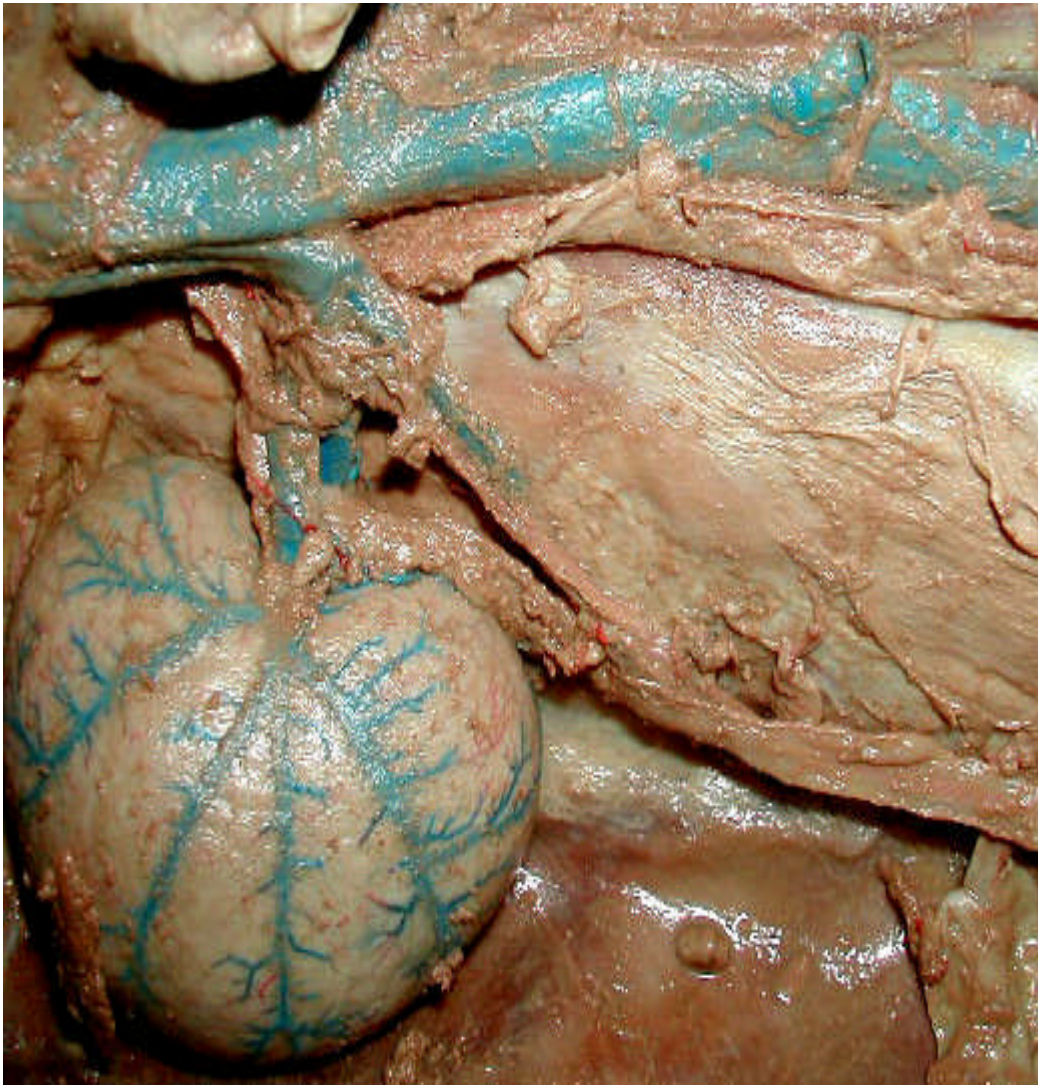
Left ureter

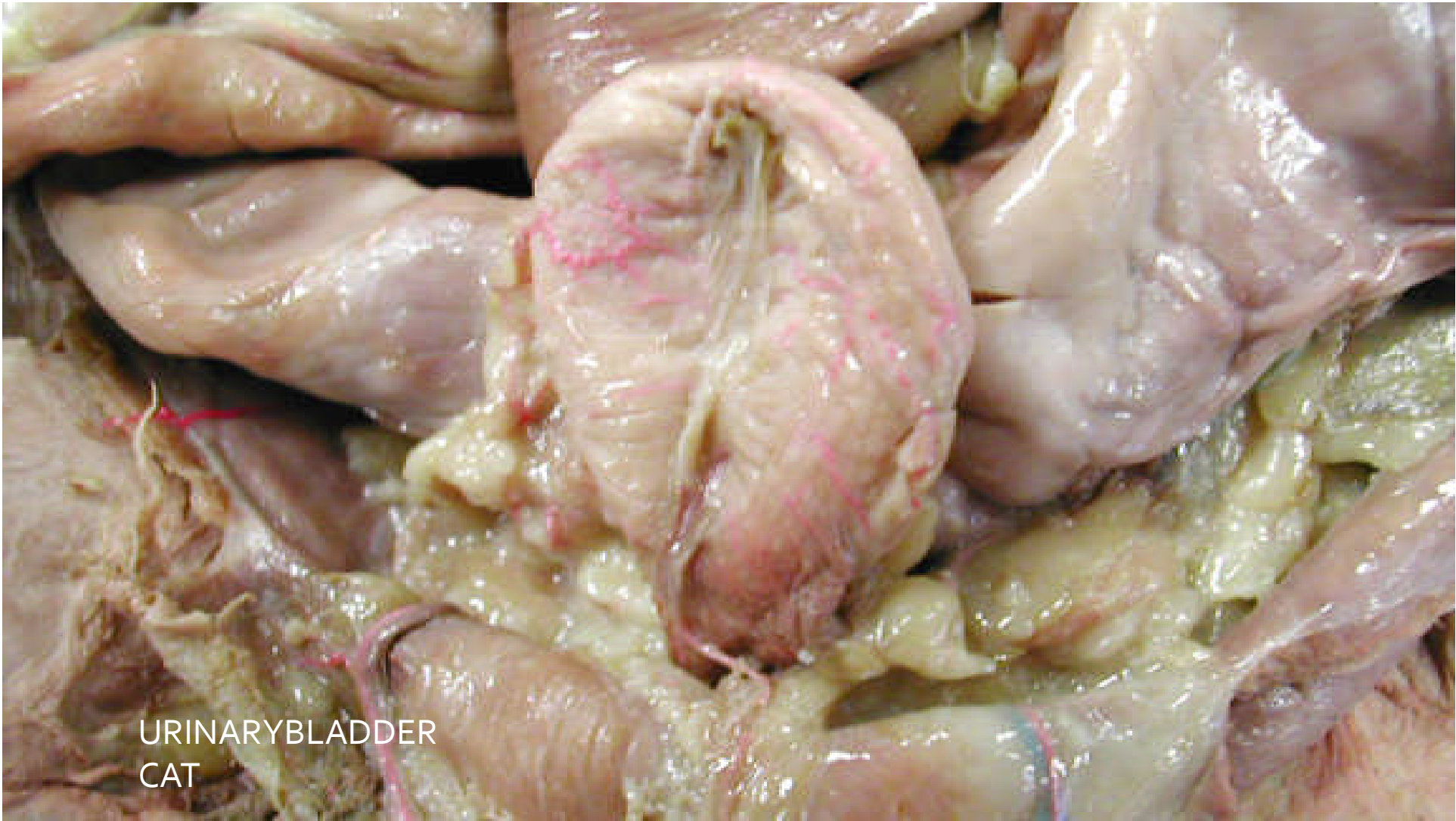Urinary bladder

Urethra

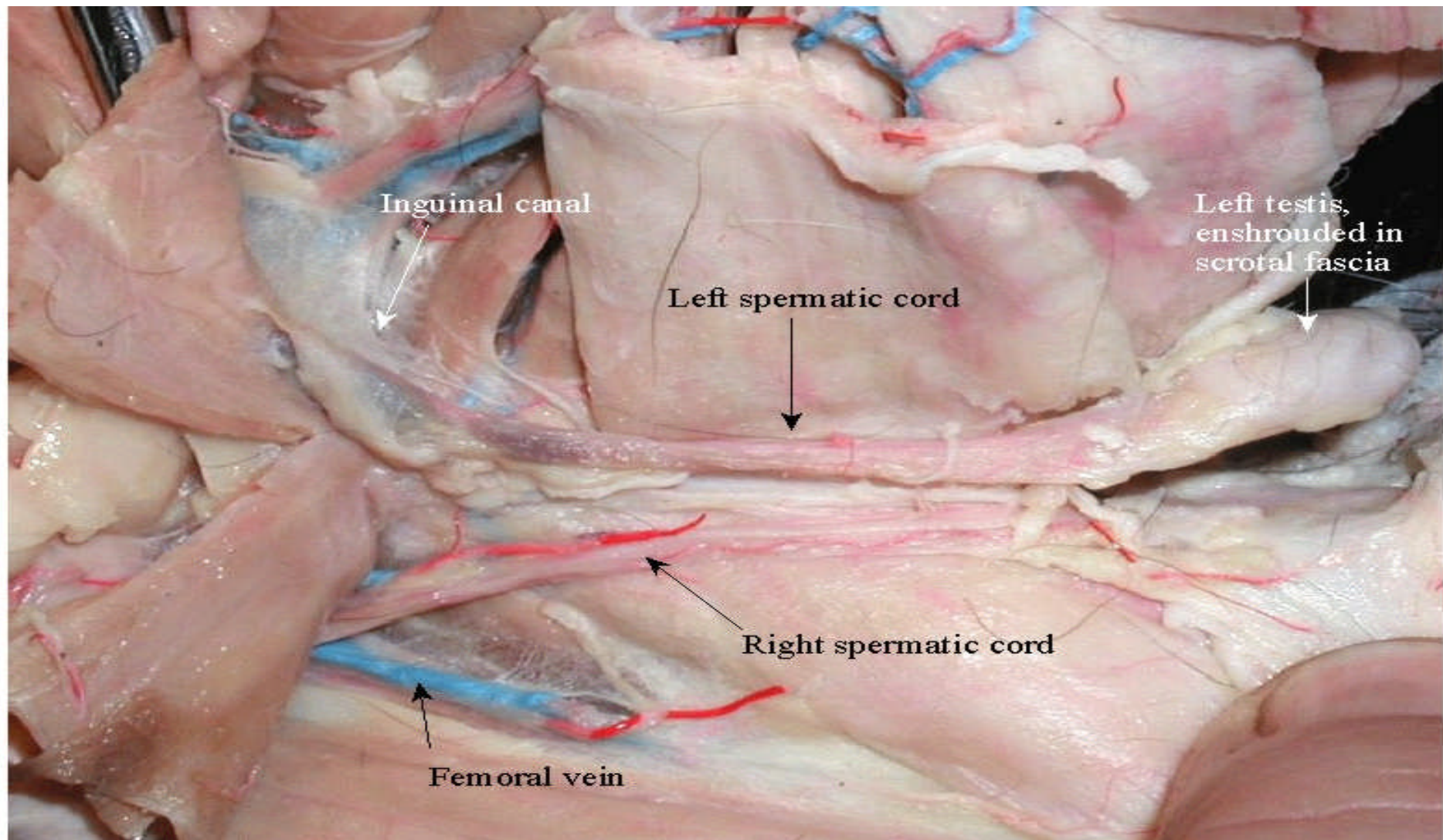
Female reproductive organs, internal

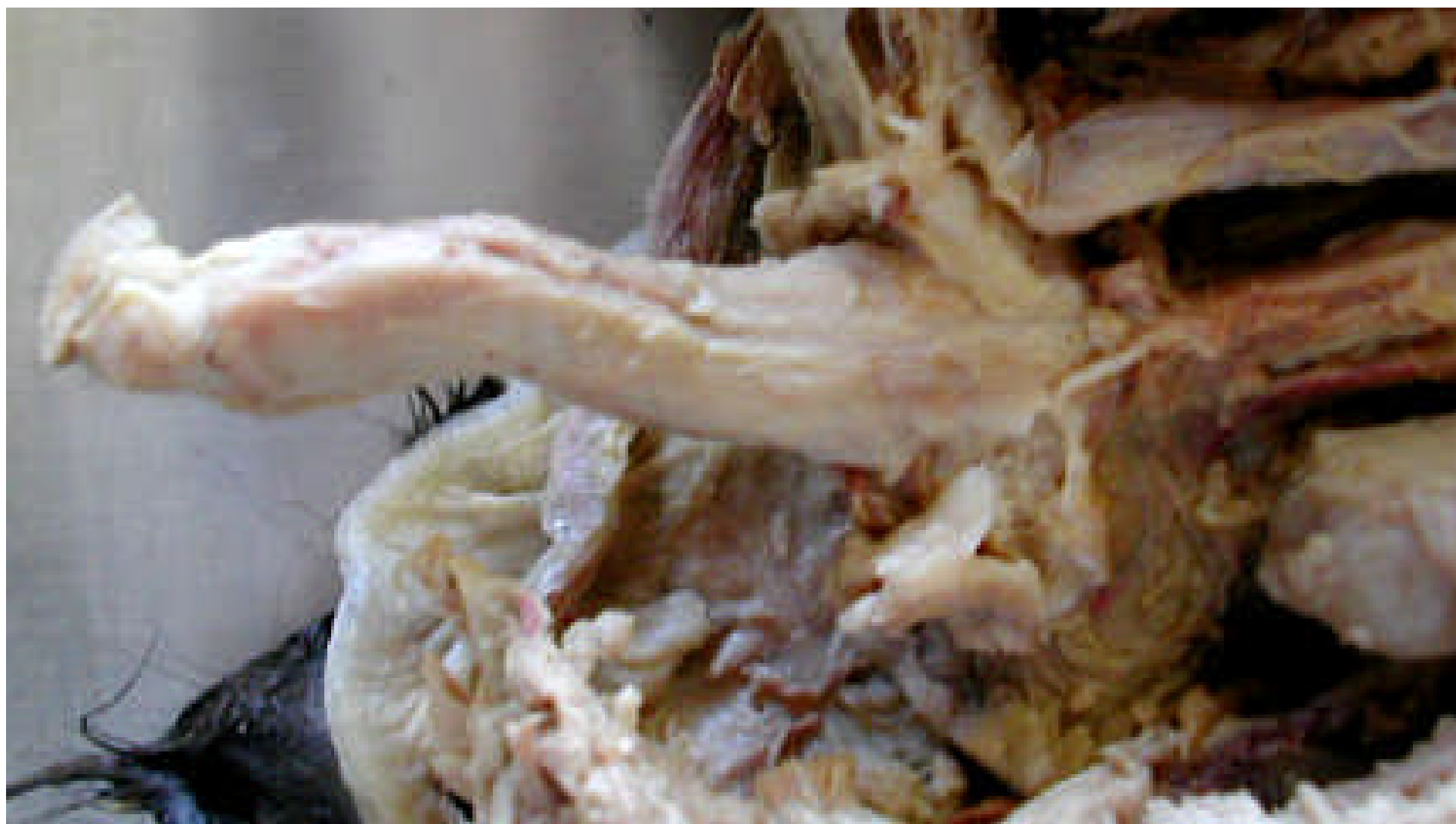





URINARYBLADDER
CAT





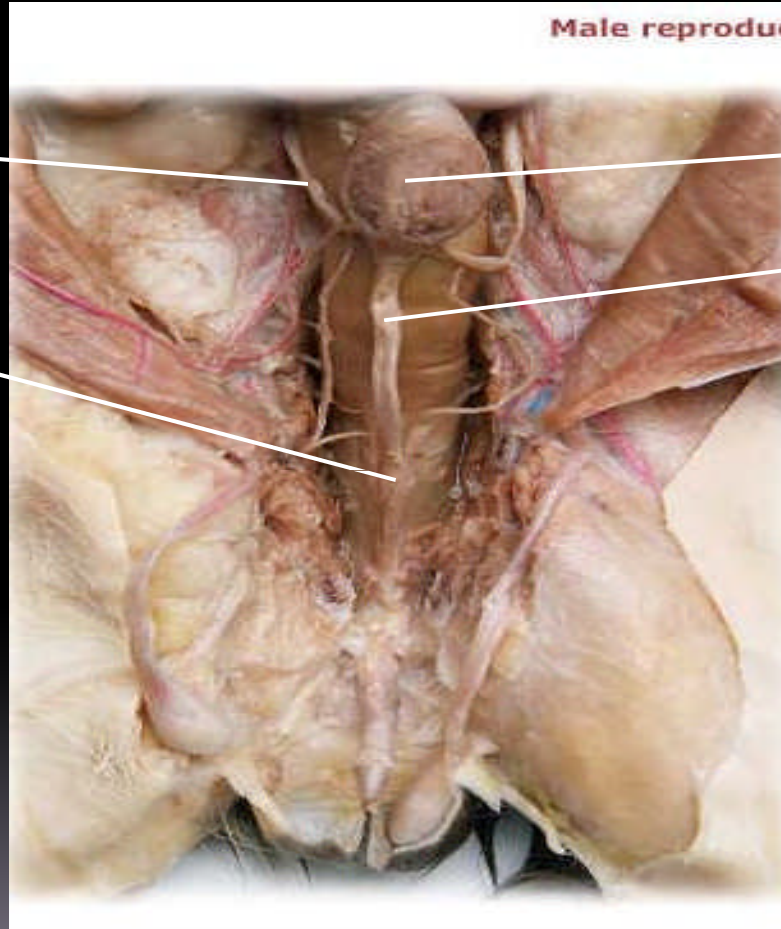
Male reproduc

Ureters

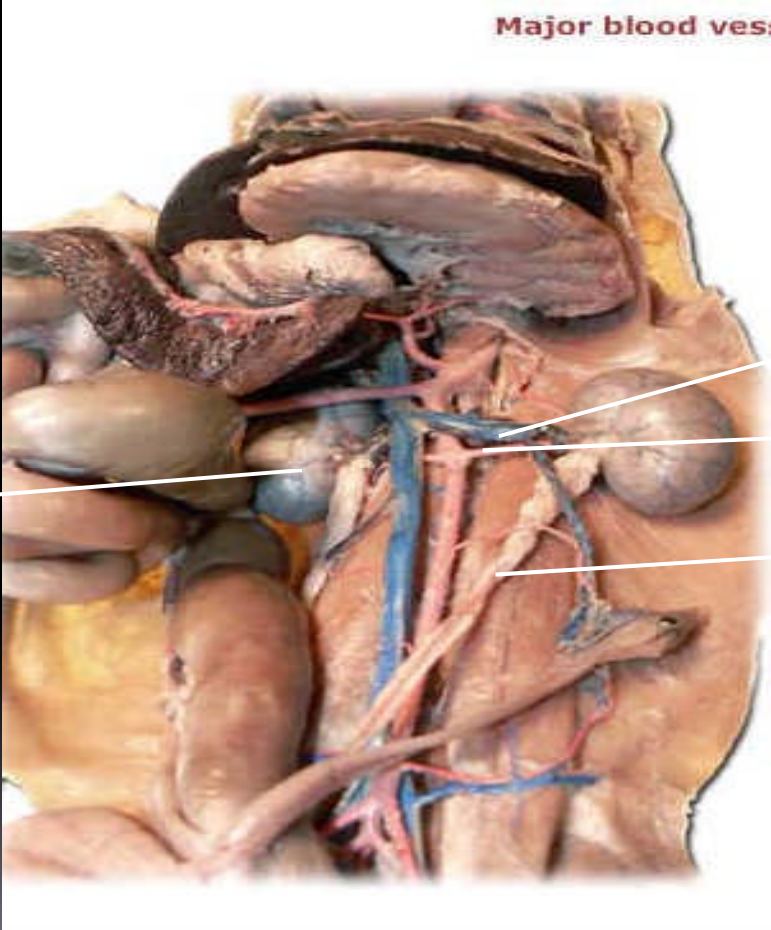
Urinary bladder

Prostate gland

Urethra



Major blood ves

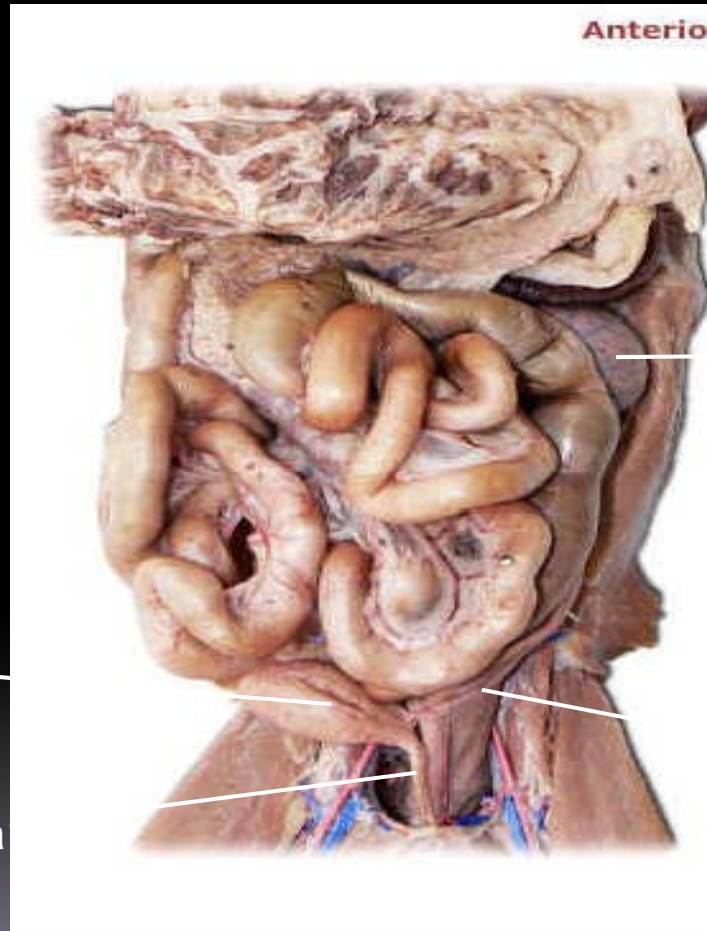


Kidney

Renal vein

Renal arteries

Ureter



Anterior

Kidney

Ureter

Urinary bladder

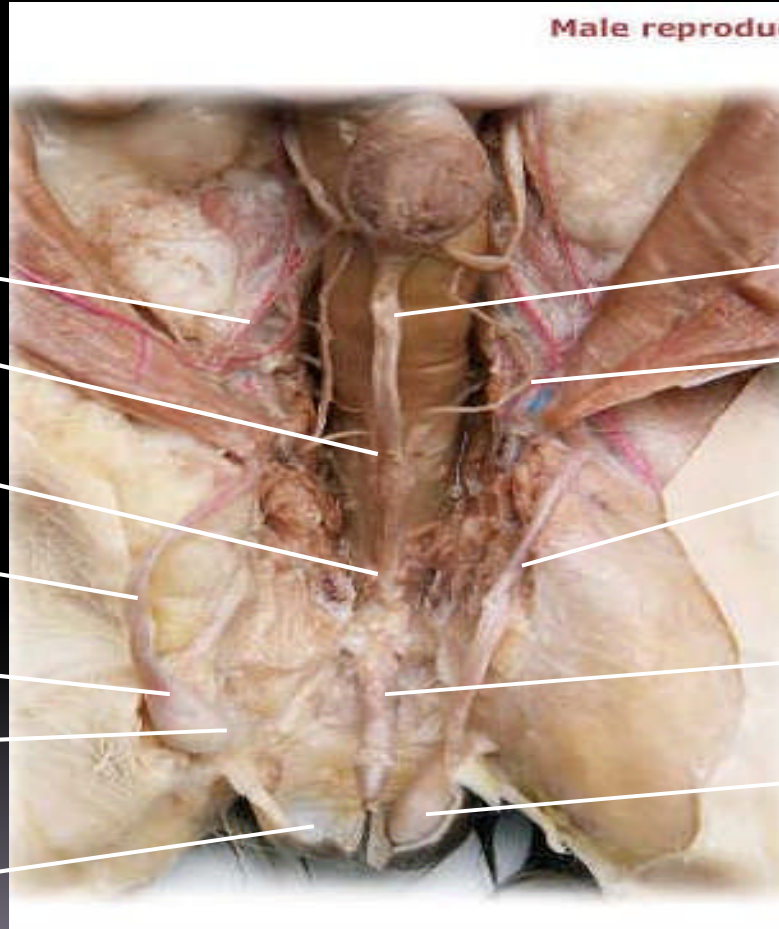
Urethra



Reproductive

CAT DISSECTION

Male reproduc



Right ductus
deferens

Prostate
gland

Bulbourethral
glands

Right spermatic
cord

Right testis

Epididymis

Scrotum

Urethra

Left ductus
deferens

Left spermatic
cord

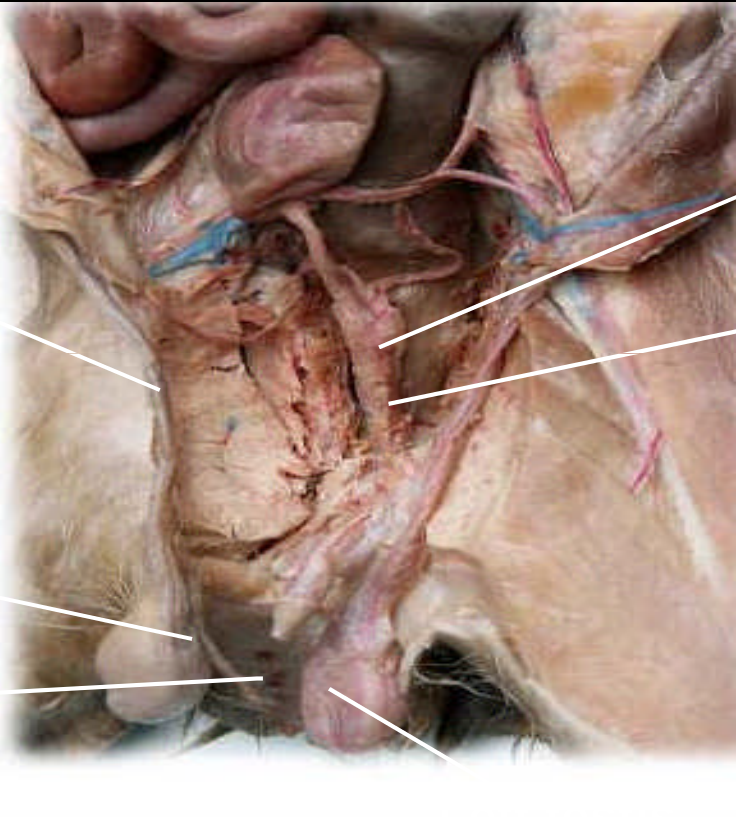
Penis

Left testis

Right ductus deferens

Epididymis

Scrotum

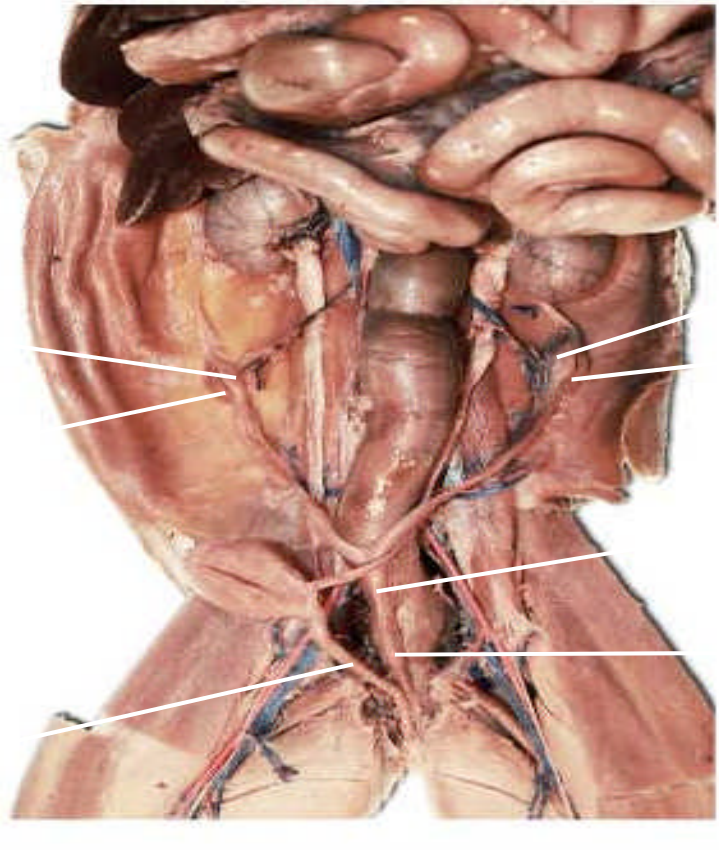


Prostate

Urethra

Left testis

Female reprod



Right ovary

Right uterine tube

Urethra

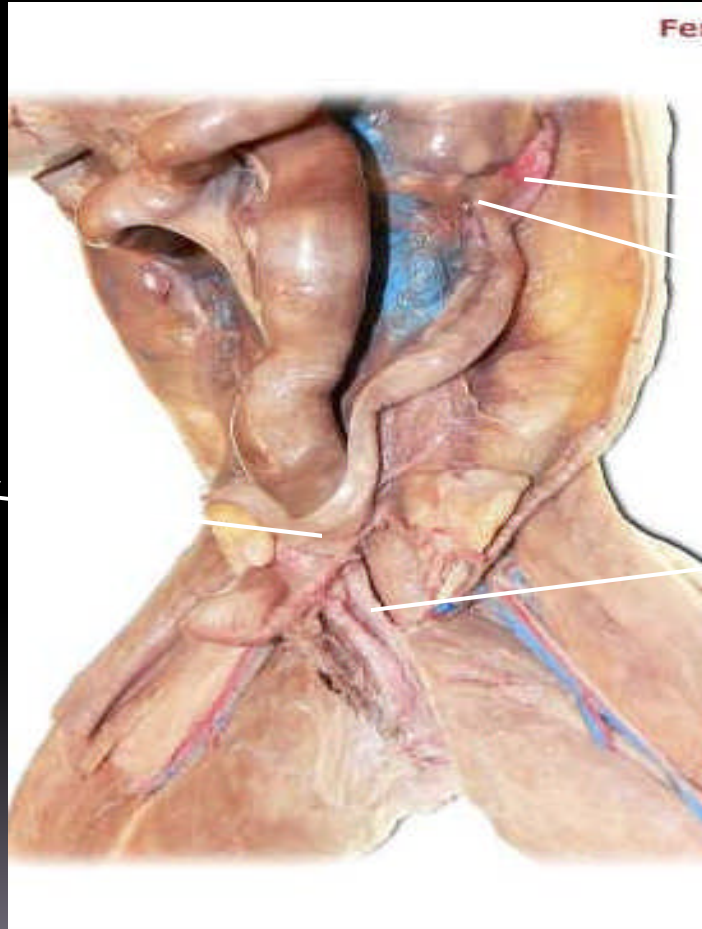
Left ovary

Left uterine tube

uterine body

Vagina

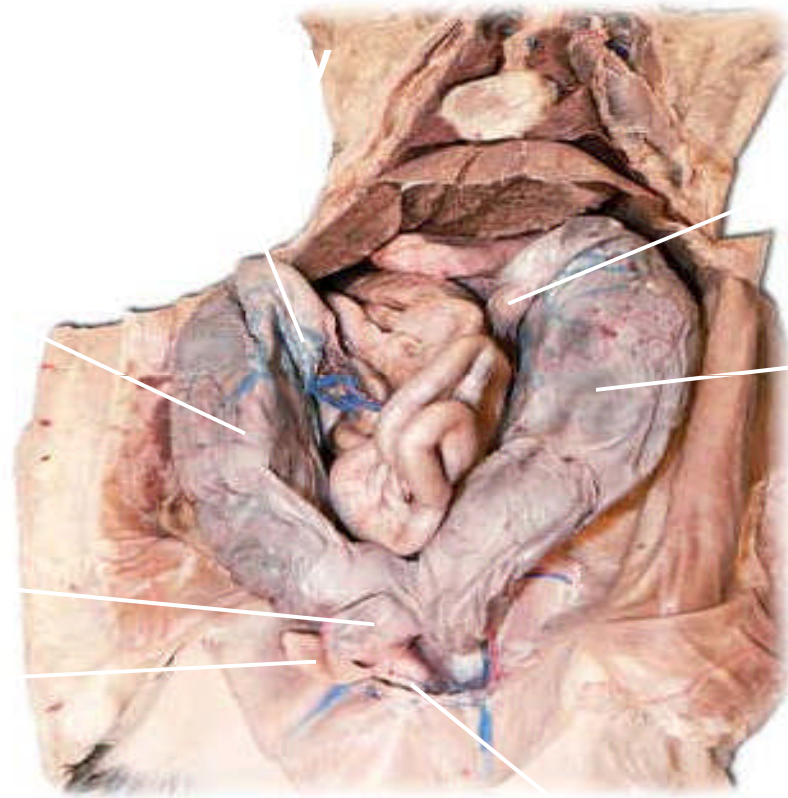
Uterine body



**Left uterine
tube**
Left ovary

Vagina

Pregnant female (uterine horns closed), anterior view

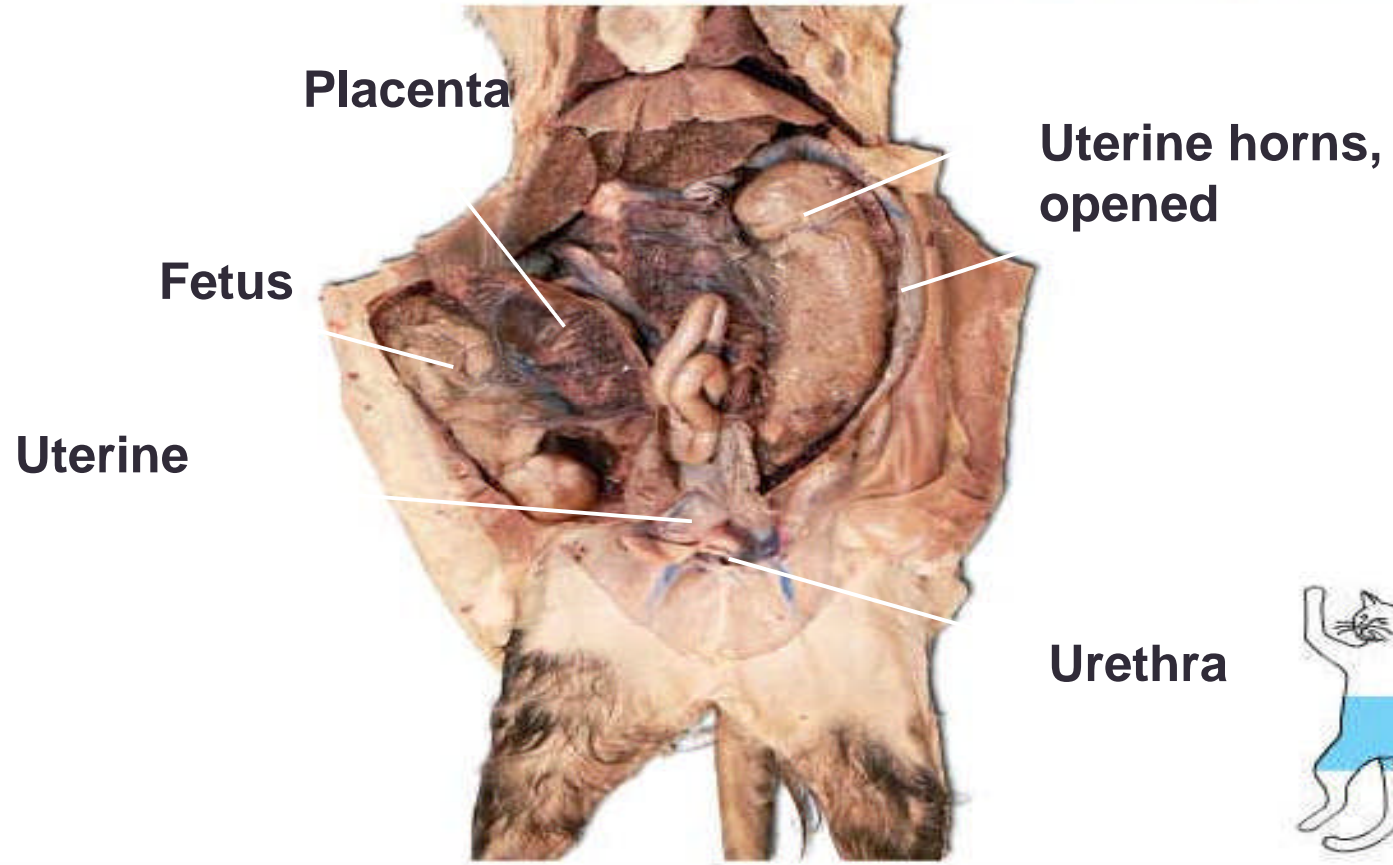


Urethra

R
W

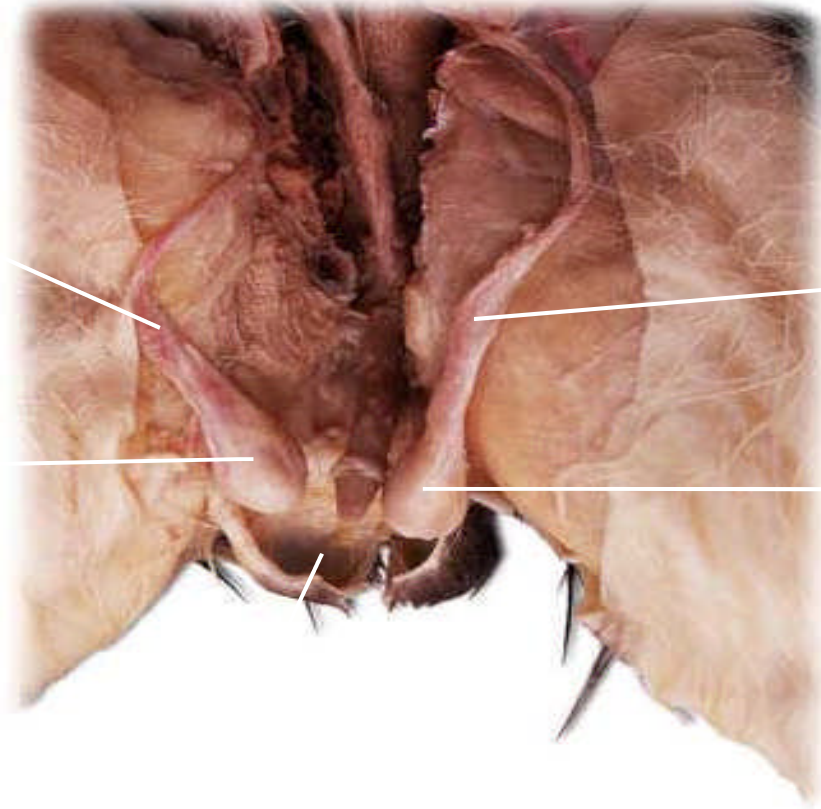n

Pregnant female (uterine horns opened), anterior view

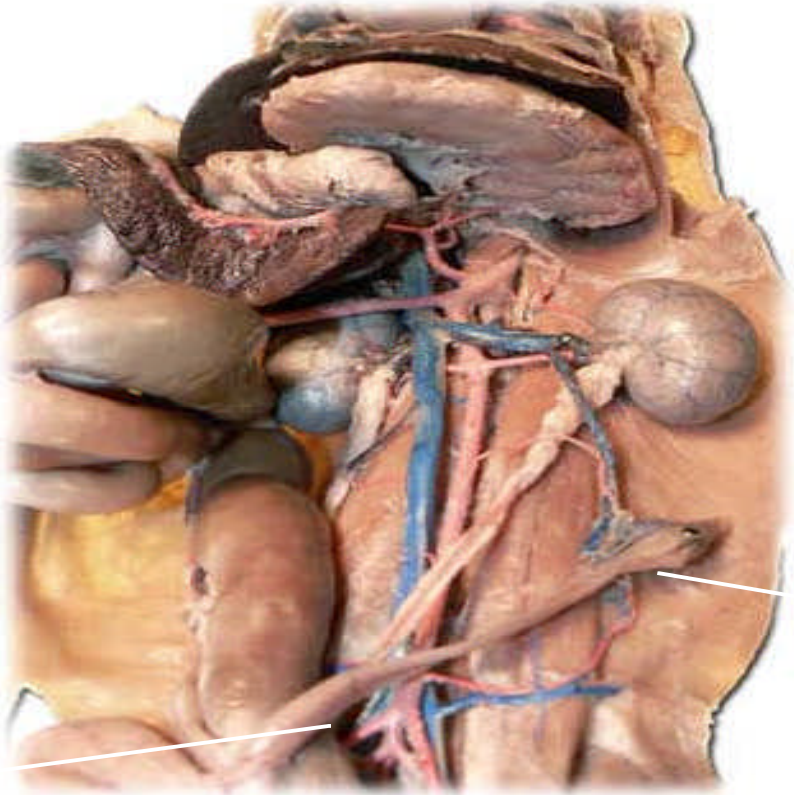


The testes

Right spermatic cord



Major blood vessels of the lower abdomen

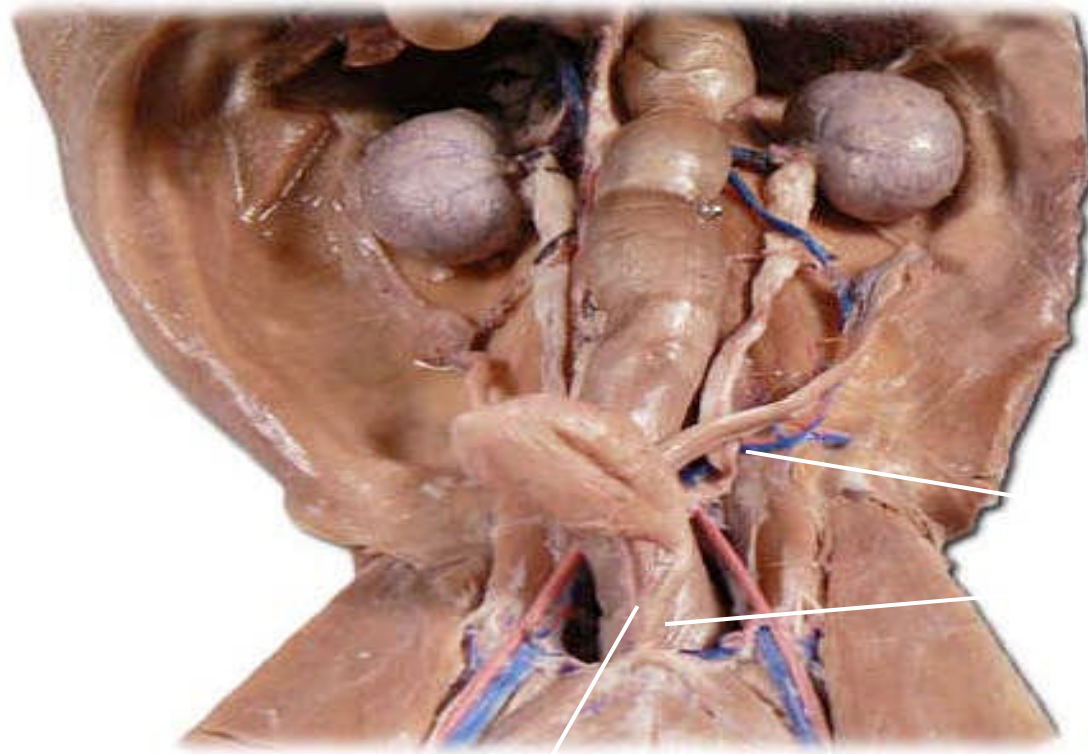


Uterine horn

Ovary



Female urinary system, anterior view



Body of uterus