

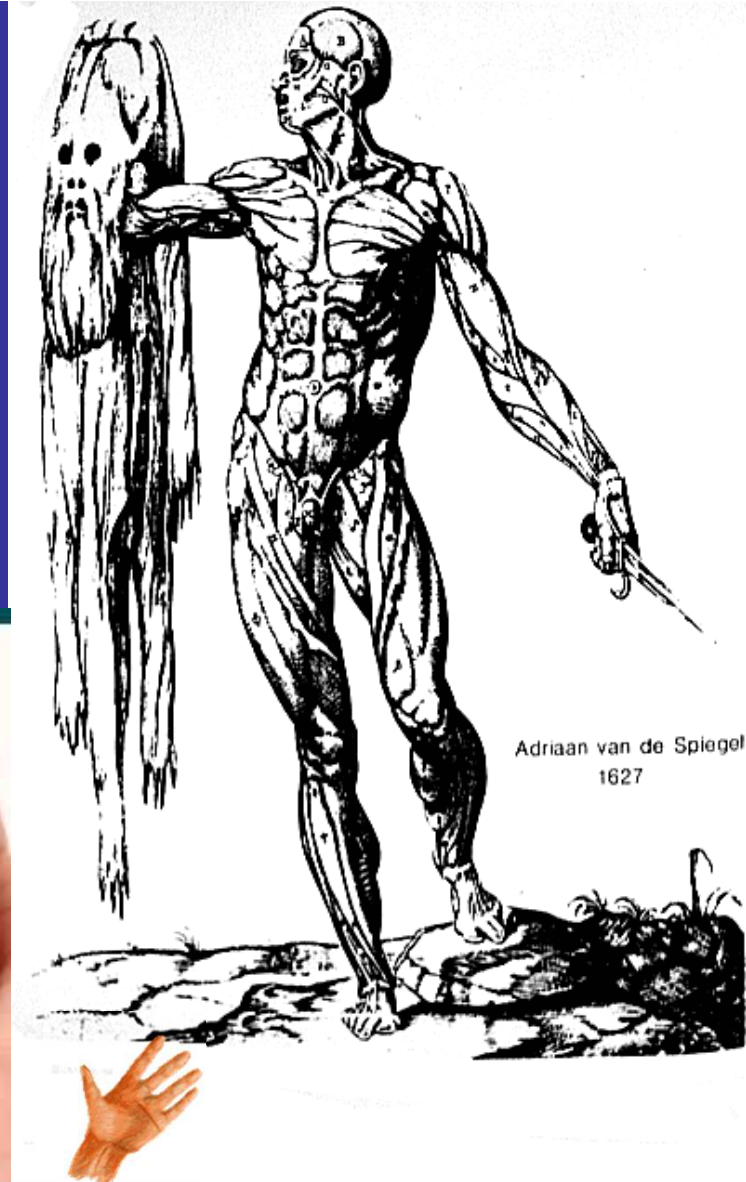

# Integumentary System

Danil Hammoudi.MD

# Integumentary System

- One of our 11 organ systems.
- Consists of the skin (i.e., the cutaneous membrane) plus all the appendages (or accessory structures) of the skin including:
  - **Sweat glands (sudoriferous glands)**
  - **Sebaceous glands (oil glands)**
  - **Hair**
  - **Nails**



# Embryology of the skin

- The two major tissue organizations of epithelial (ectoderm, epidermis)
- Mesenchyme (mesoderm connective tissue, dermis and hypodermis).
- In addition, we have also extensive populating by melanocytes (neural crest) and sensory nerve endings.
- **Ectoderm forms the surface epidermis and the associated glands.**
- **Mesoderm**, from the somites, forms the underlying **connective tissue of dermis and hypodermis.**
- **Neural crest cells** also migrate into the **forming epidermis and the skin** is also populated by specialized sensory endings.
- **Fetal skin also has the ability to heal wounds without a scar in contrast to adult skin, this may relate to differences in the fetal extracellular matrix structure.**

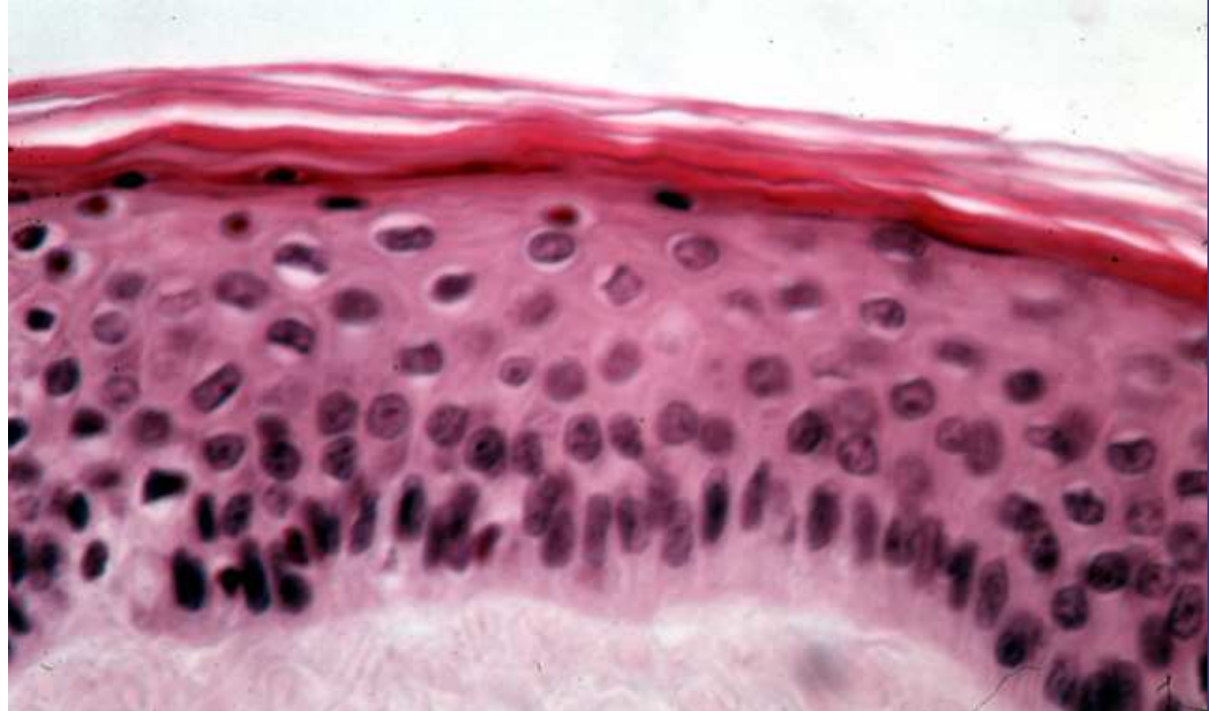# Fetal dermis

The following data is from an immunohistological study of fetal skin dermis layer.

- **Collagen type I** is the principal component of extracellular matrix (ECM) (also in adult skin).
- **Collagen type III** high ratio to collagen type I (than adult skin).
- **Glycosaminoglycans (GAGs)** level higher (than adult skin).
- **Hyaluronic acid and chondroitin sulfate** both higher.
- **Elastin** was not present (found in adult skin).

# General Functions of the Integumentary System

- Protection from mechanical injury
- Physical protection of pathogen entry
- Chemical prevention of pathogen entry
- Sensation
- Thermoregulation
- Metabolic functions
- Looking good
- Art



## INTEGUMENTARY SYSTEM

- Physical protection from environmental hazards
- Thermoregulation
- Synthesis and storage of lipid reserves
- Excretion
- Synthesis of vitamin D<sub>3</sub>
- Sensory information
- Coordination of immune response to pathogens and cancers in skin

### CUTANEOUS MEMBRANE

#### EPIDERMIS

- Protects dermis from trauma, chemicals
- Controls skin permeability, prevents water loss
- Prevents entry of pathogens
- Synthesizes vitamin D<sub>3</sub>
- Sensory receptors detect touch, pressure, pain, and temperature
- Coordinates immune response to pathogens and skin cancers

#### DERMIS

##### PAPILLARY LAYER

- Nourishes and supports epidermis

##### RETICULAR LAYER

- Restricts spread of pathogens penetrating epidermis
- Stores lipid reserves
- Attaches skin to deeper tissues
- Sensory receptors detect touch, pressure, pain, vibration, and temperature
- Vessels assist in thermoregulation

### ACCESSORY STRUCTURES

#### HAIR FOLLICLES

- Produce hairs that protect skull
- Produce hairs that provide delicate touch sensations on general body surface

#### EXOCRINE GLANDS

- Assist in thermoregulation
- Excrete wastes
- Lubricate epidermis


#### NAILS

- Protect and support tips of fingers and toes



Skin performs the following functions:

- **Protection:** an anatomical barrier from pathogens and damage between the internal and external environment in bodily defense; Langerhans cells in the skin are part of the adaptive immune system.
- **Sensation:** contains a variety of nerve endings that react to heat and cold, touch, pressure, vibration, and tissue injury; see somatosensory system and haptics.
- **Heat regulation:** the skin contains a blood supply far greater than its requirements which allows precise control of energy loss by radiation, convection and conduction. Dilated blood vessels increase perfusion and heatloss, while constricted vessels greatly reduce cutaneous blood flow and conserve heat.
- **Control of evaporation:** the skin provides a relatively dry and semi-impermeable barrier to fluid loss. Loss of this function contributes to the massive fluid loss in burns.
- **Aesthetics and communication:** others see our skin and can assess our mood, physical state and attractiveness.
- **Storage and synthesis:** acts as a storage center for lipids and water, as well as a means of synthesis of vitamin D by action of UV on certain parts of the skin.

- 
- **Excretion:** sweat contains urea, however its concentration is 1/130th that of urine, hence excretion by sweating is at most a secondary function to temperature regulation.
  - **Absorption:** the cells comprising the outermost 0.25–0.40 mm of the skin are "almost exclusively supplied by external oxygen", although the "contribution to total respiration is negligible".
  - In addition, **medicine can be administered through the skin**, by ointments or by means of adhesive patch, such as the nicotine\_patch or iontophoresis. The skin is an important site of transport in many other organisms.
  - **Water resistance:** The skin acts as a water resistant barrier so essential nutrients aren't washed out of the body.



# Basic Skin Structure

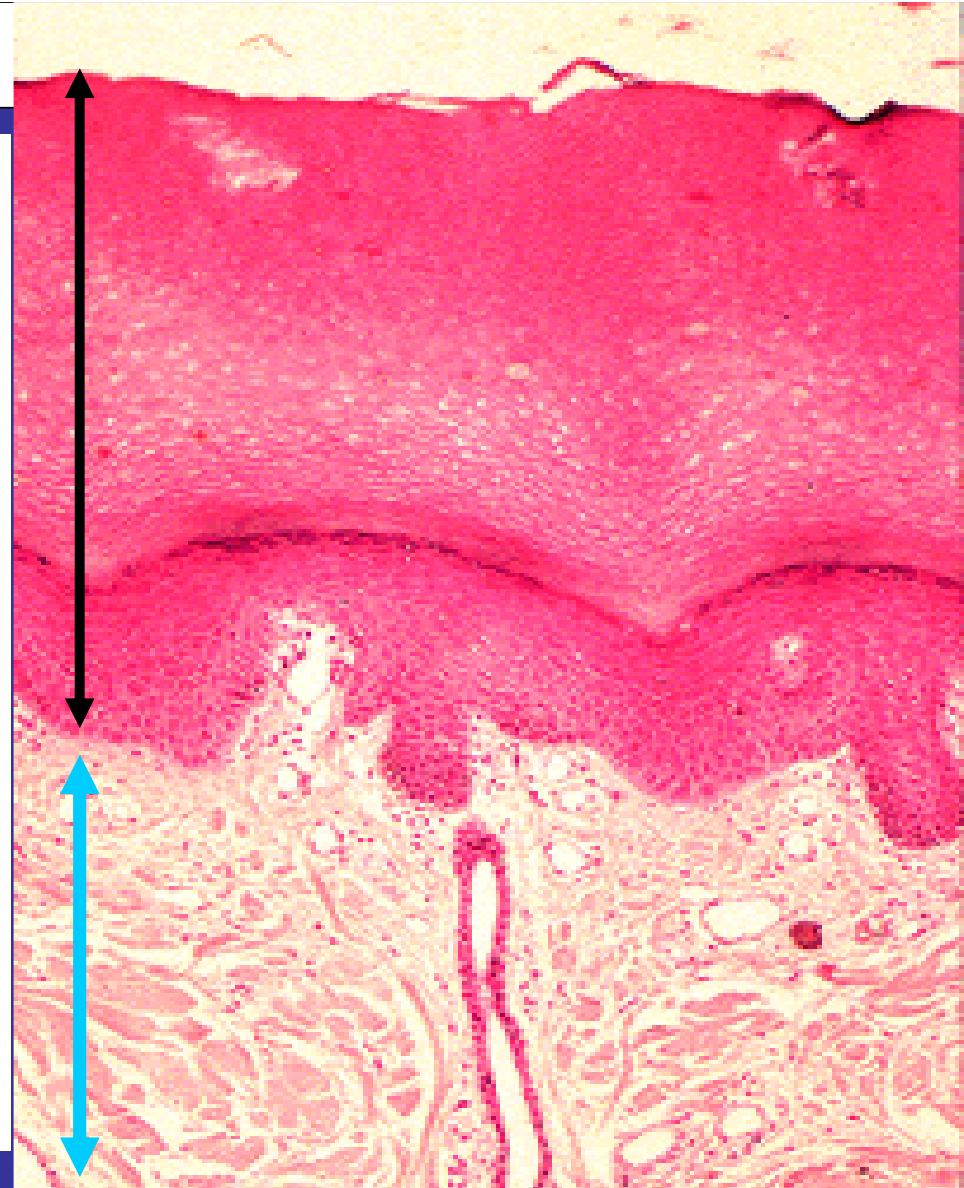
- The skin has 2 main layers:

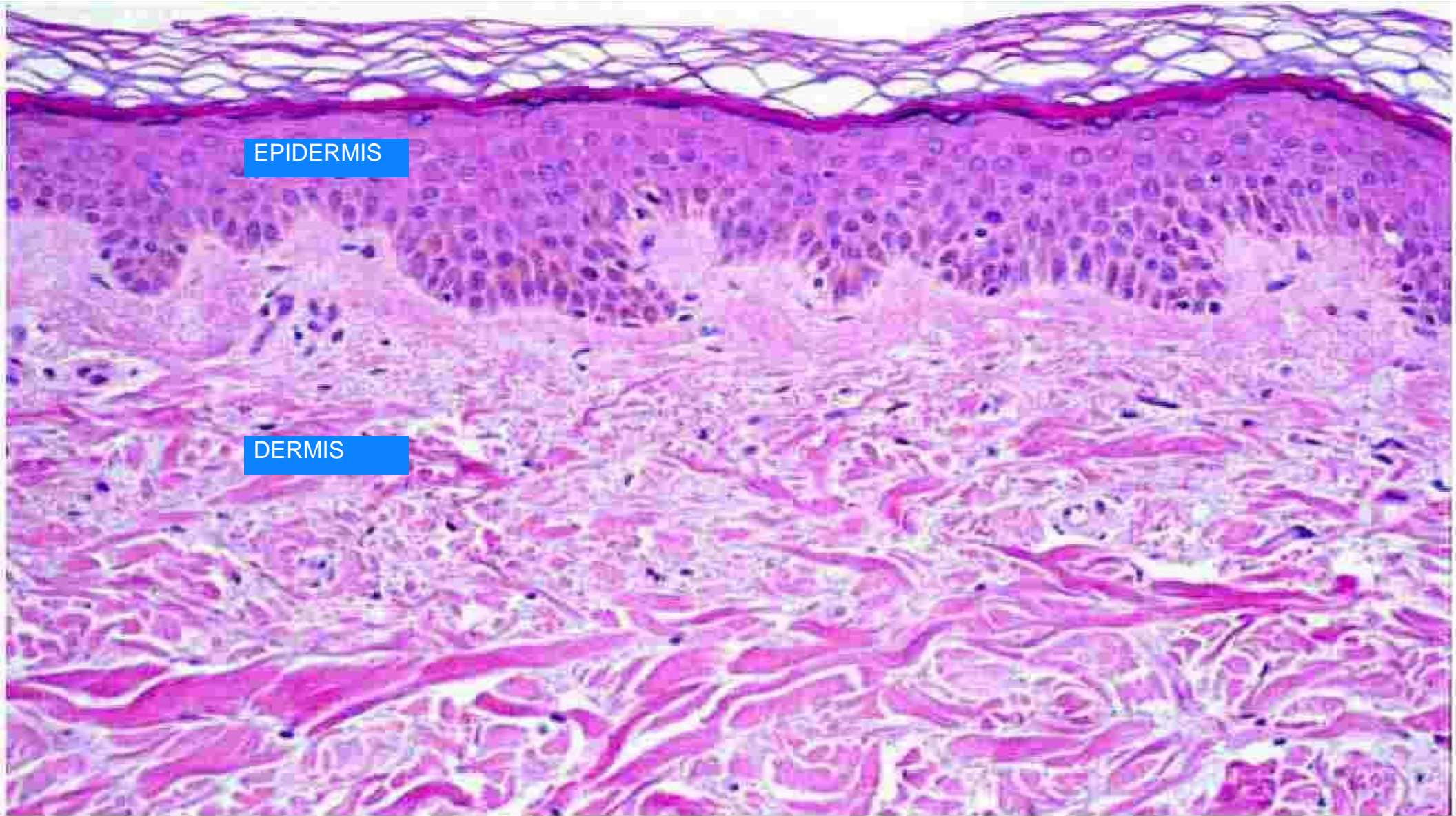
## 1. Epidermis

- The superficial, **avascular** (*epi* means “above” and *dermis* means “skin”)
- **stratified squamous epithelium of the skin.**
- consisting of 4-5 layers of epithelial cells resting upon a basement membrane.

## 2. Dermis

- The deep, vascular consisting of fibrous connective tissue.
- Contains multiple blood vessels, and the accessory appendages.
- **Accessory structures**
  - include hair, nails, and many multicellular exocrine glands.

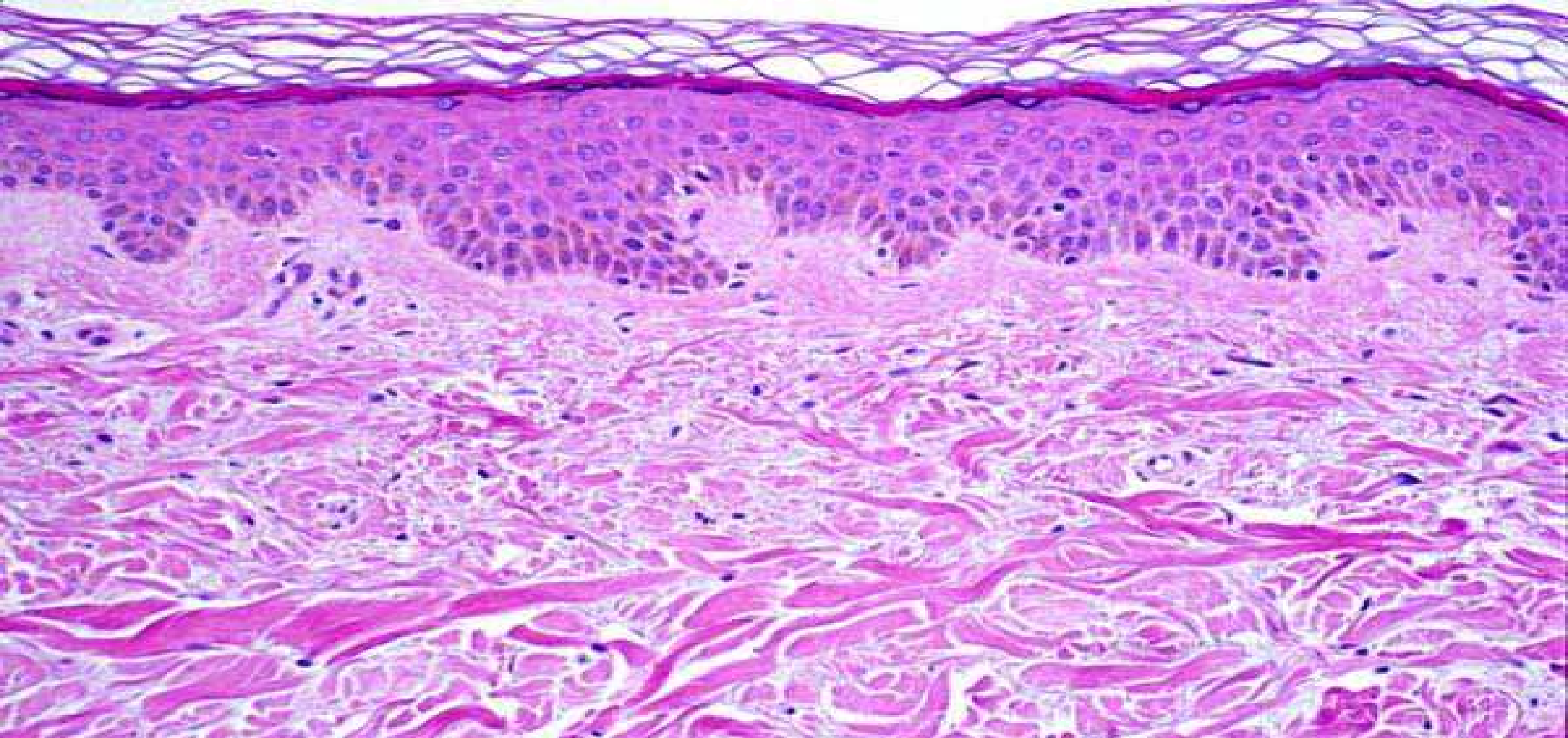





EPIDERMIS

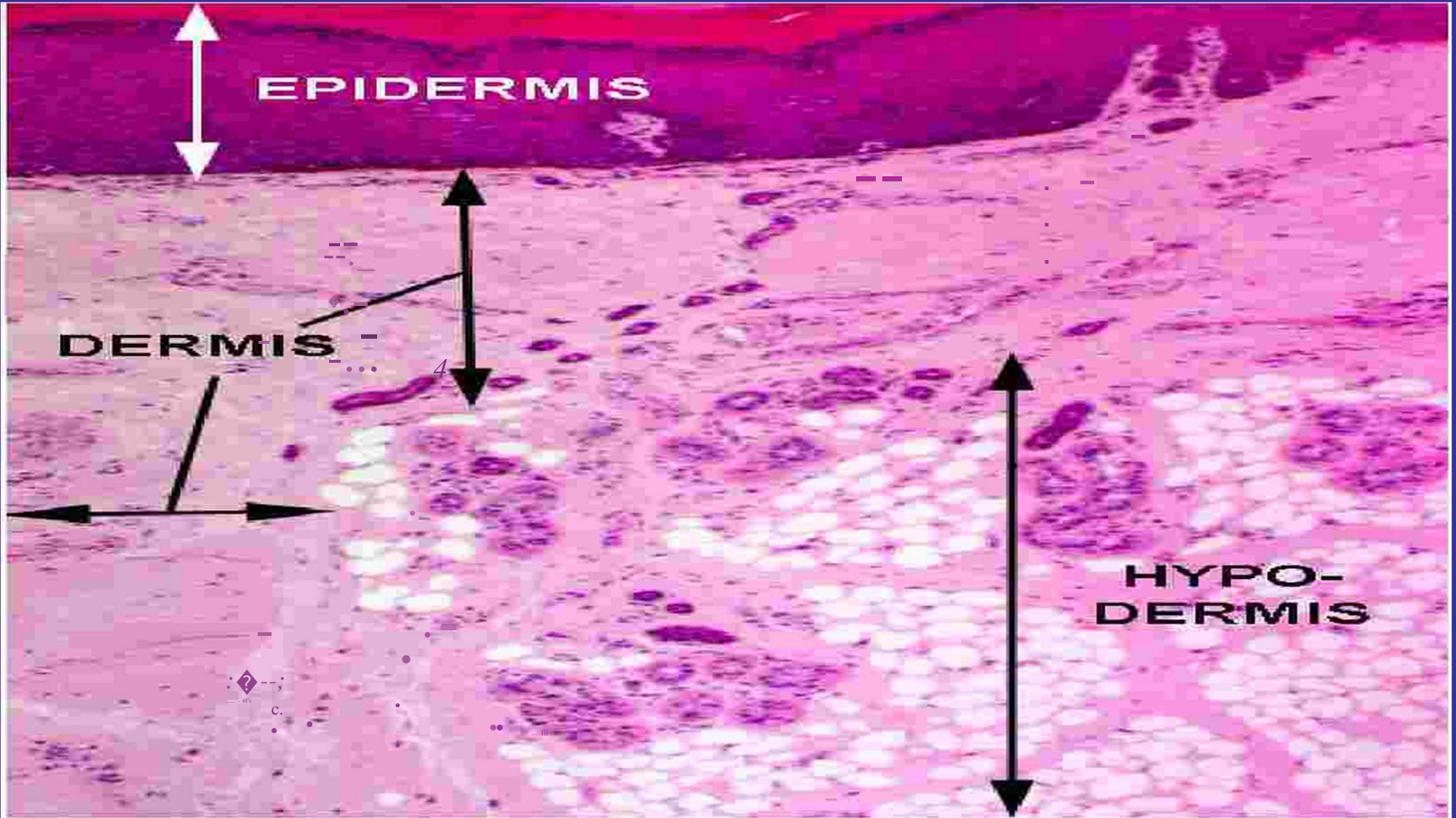
DERMIS

**Identify the epidermis and the dermis!  
Which is made of connective tissue? What  
type?**





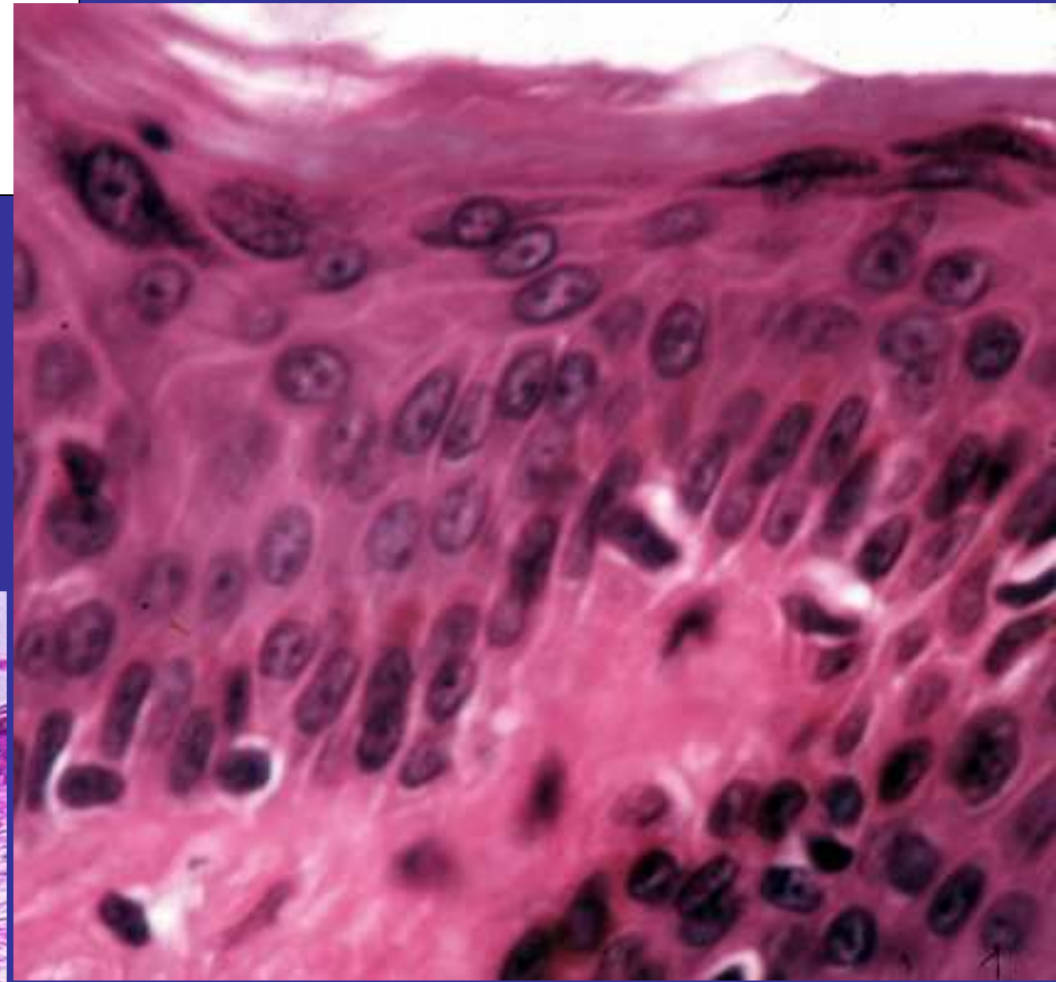
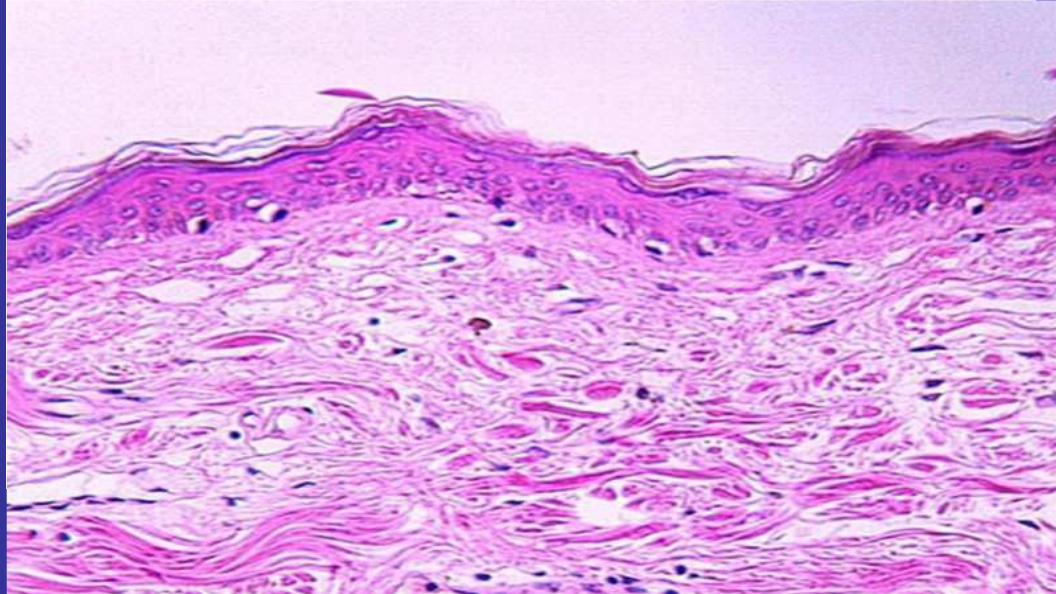
Histology



# Skin Types

## Thin skin

- Found everywhere else on the body.
  - Contains only 4 layers. (lacks a stratum lucidum).
  - The remaining 4 layers are thinner than those of thick skin.
- Why is thick skin found on the palms and soles? What is the advantage of that?



Note: this slide is at a higher mag. than the thick skin slide on the previous page

# Skin Types

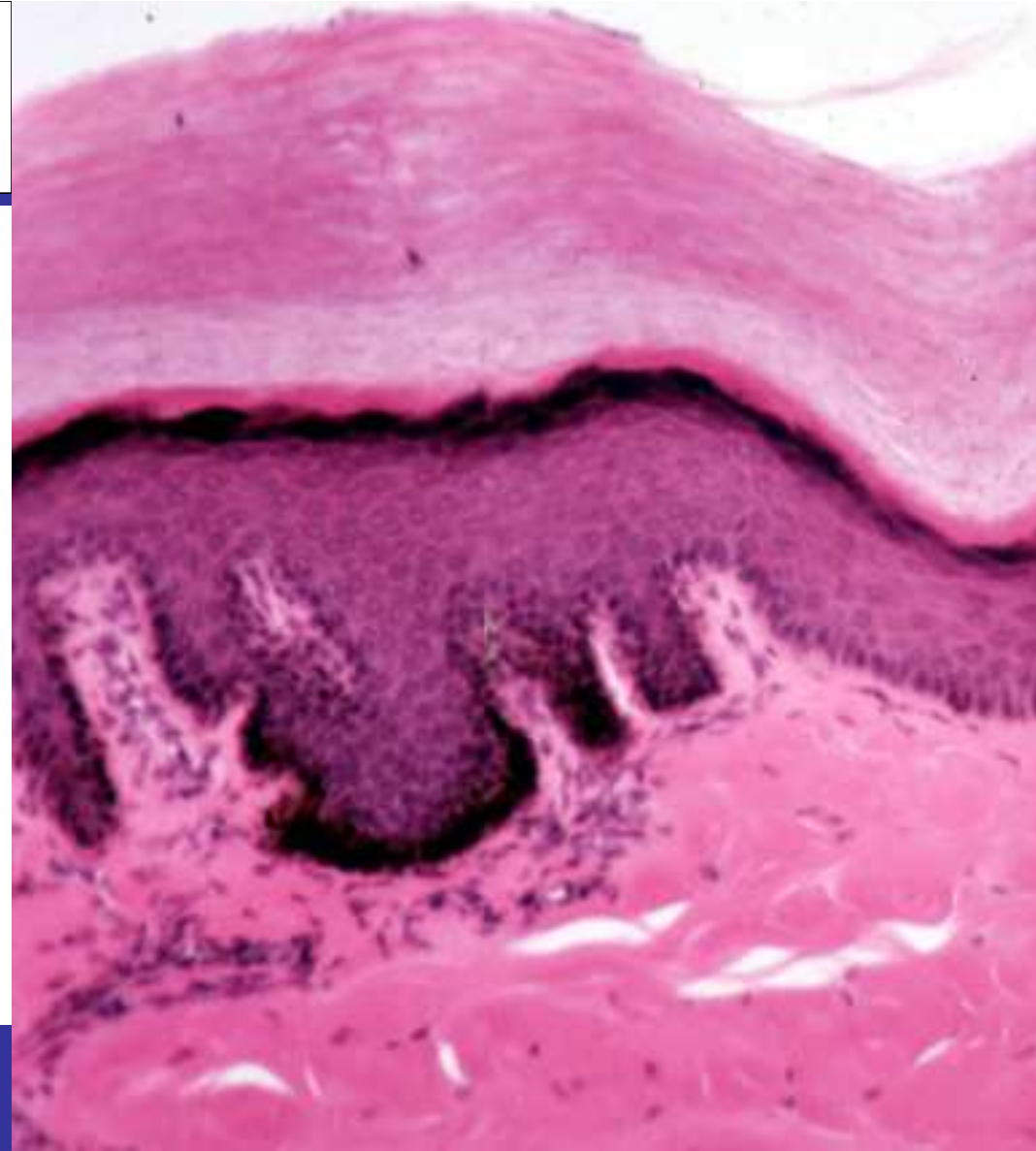
## Thick Skin

- Found on soles of feet and palms of hands and corresponding parts of fingers and toes.
- Contains 5 epidermal layers or *strata* (“sheets”):
  - **Stratum basale**
  - **Stratum spinosum**
  - **Stratum granulosum**
  - **Stratum lucidum**
  - **Stratum corneum**

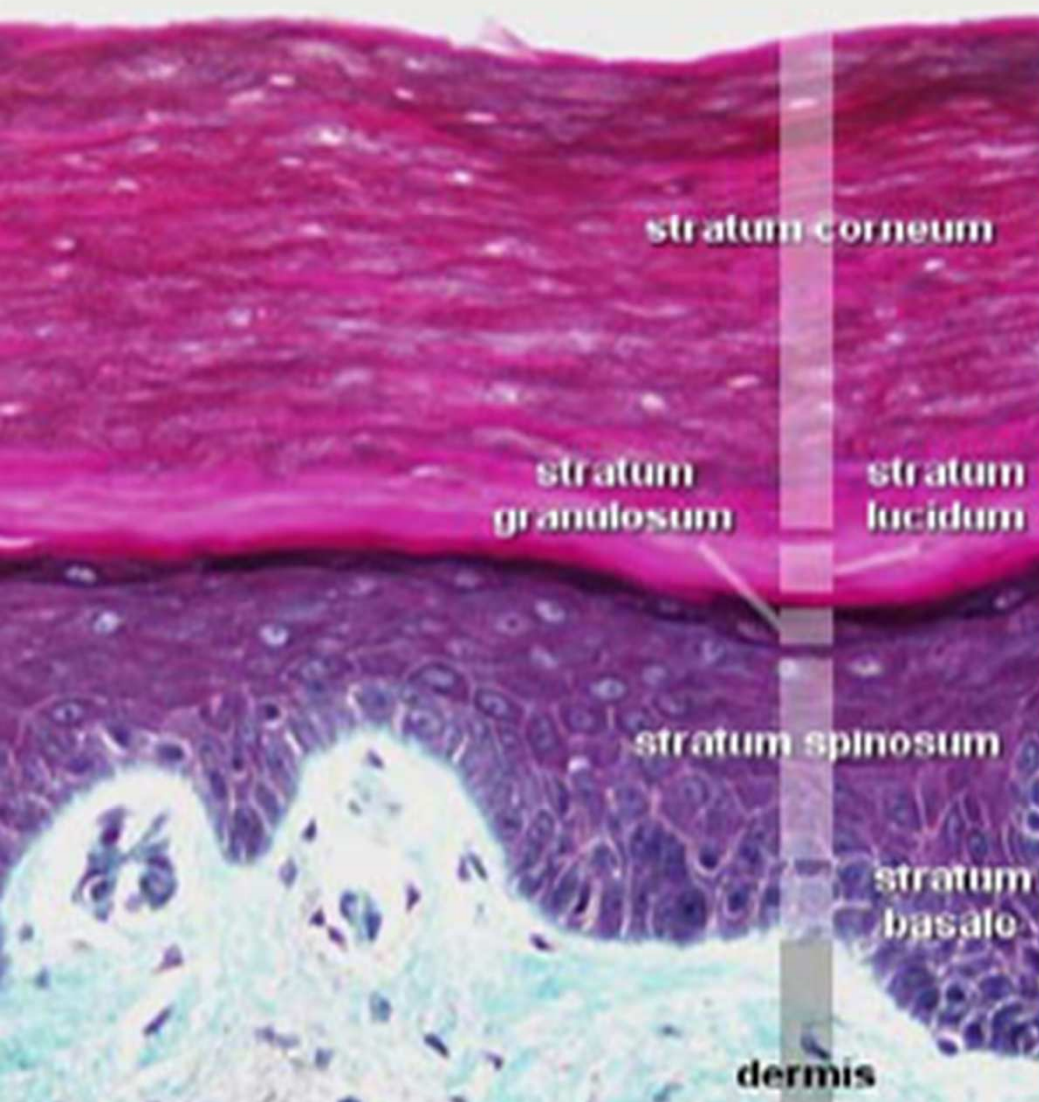
### Thick skin on

- the palms of the hands,
- the fingertips,
- soles of the feet may be covered by many layers of keratinized cells that have cornified.

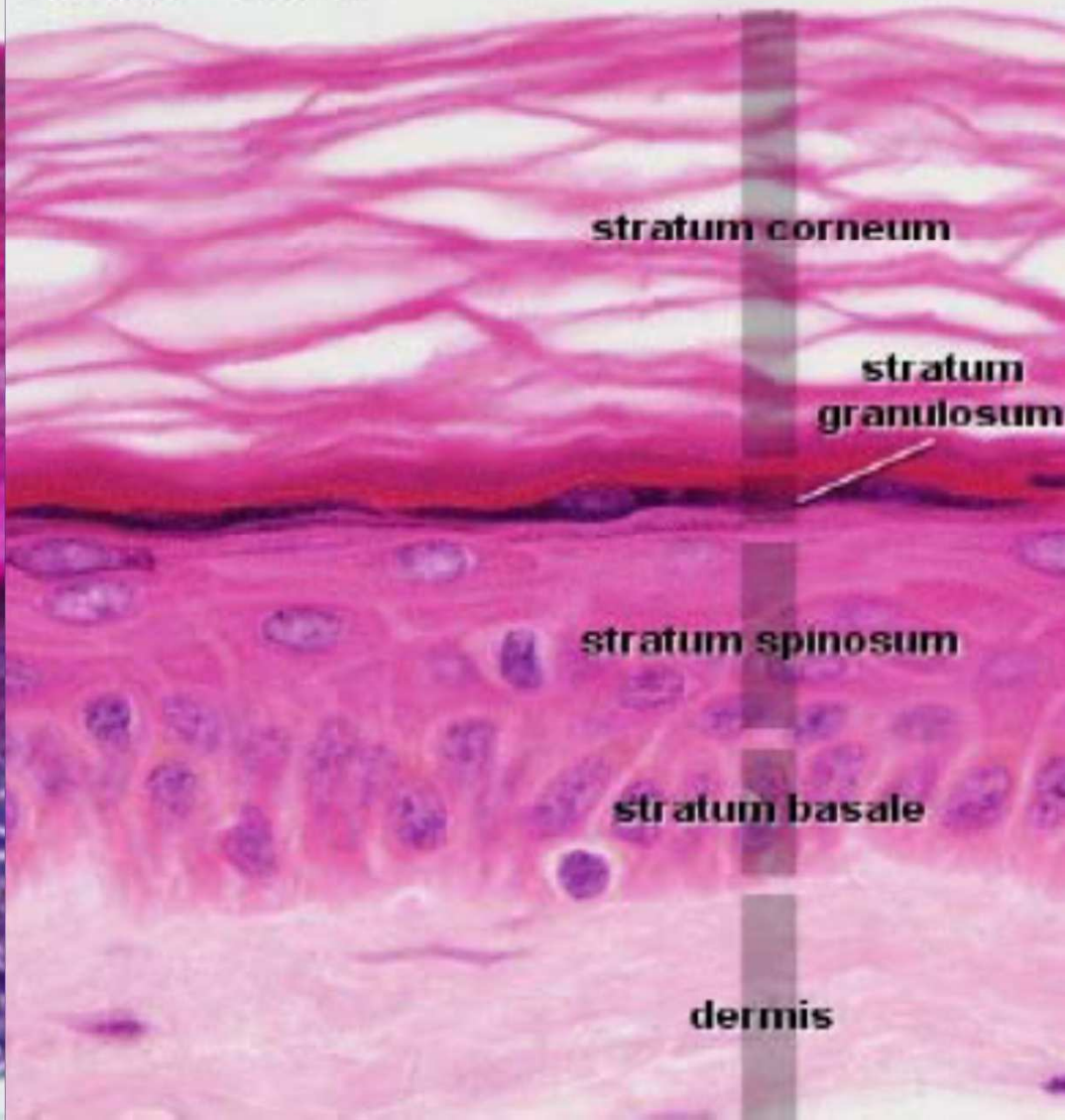
Thick skin **does not have hair, smooth muscles, No sebaceous glands.**



**Skin, thick trichrome**



**Skin, thin H&E**





## SUBLAYERS OF THE EPIDERMIS

- 1- **Can** (Stratum Corneum)
- 2- **Lucy** (Stratum **Lucidum**)
- 3- **Give** (Stratum Granulosum)
- 4- **Some** (Stratum Spinosum)
- 5- **Blood** (Stratum Basal) ( **Germinativum**)

Mnemonics that are good for remembering the layers of the skin (using "stratum basale" instead of "stratum germinativum"):

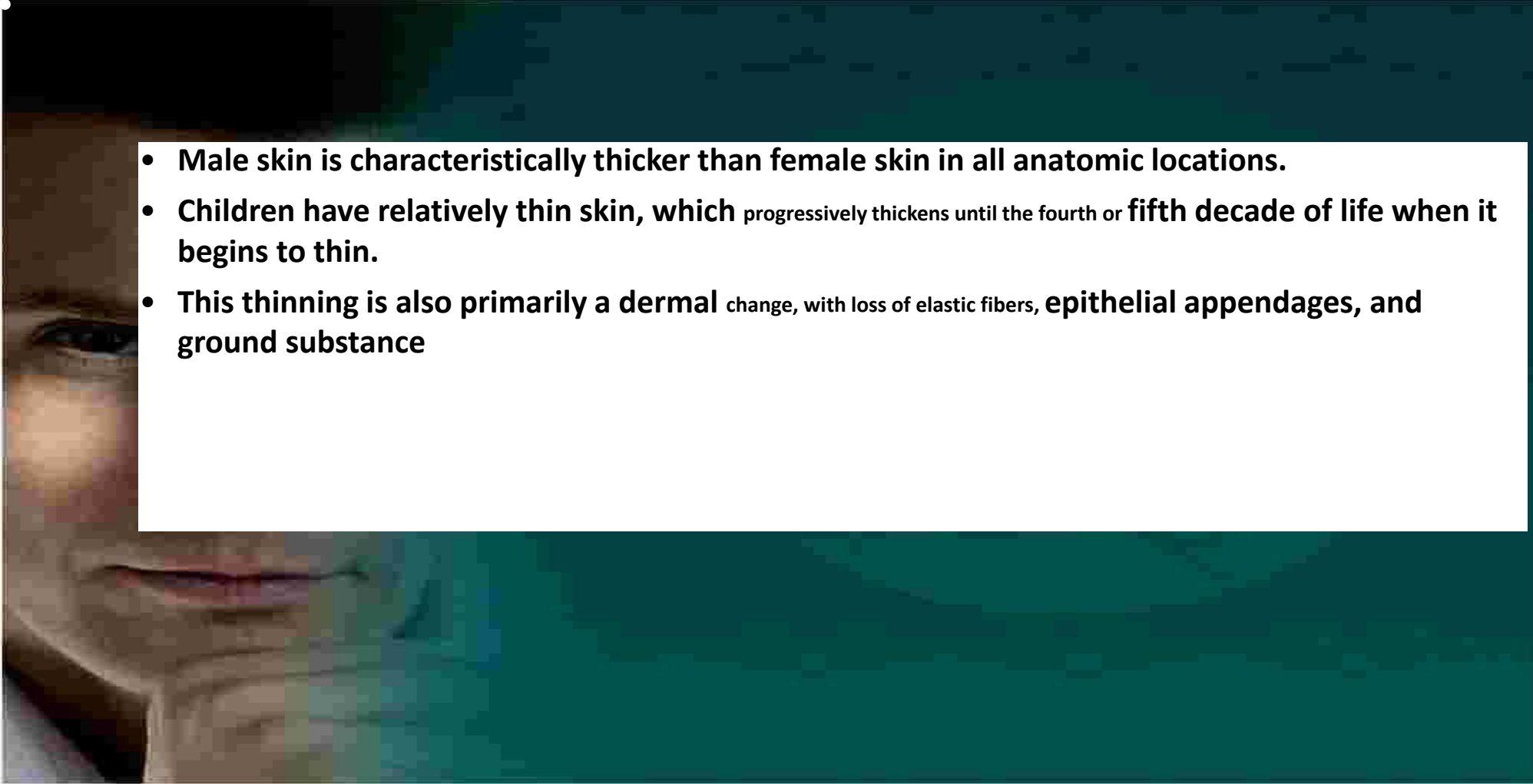
"**C**an **L**ong **G**et **S**ome **B**urgers" (from superficial to deep)

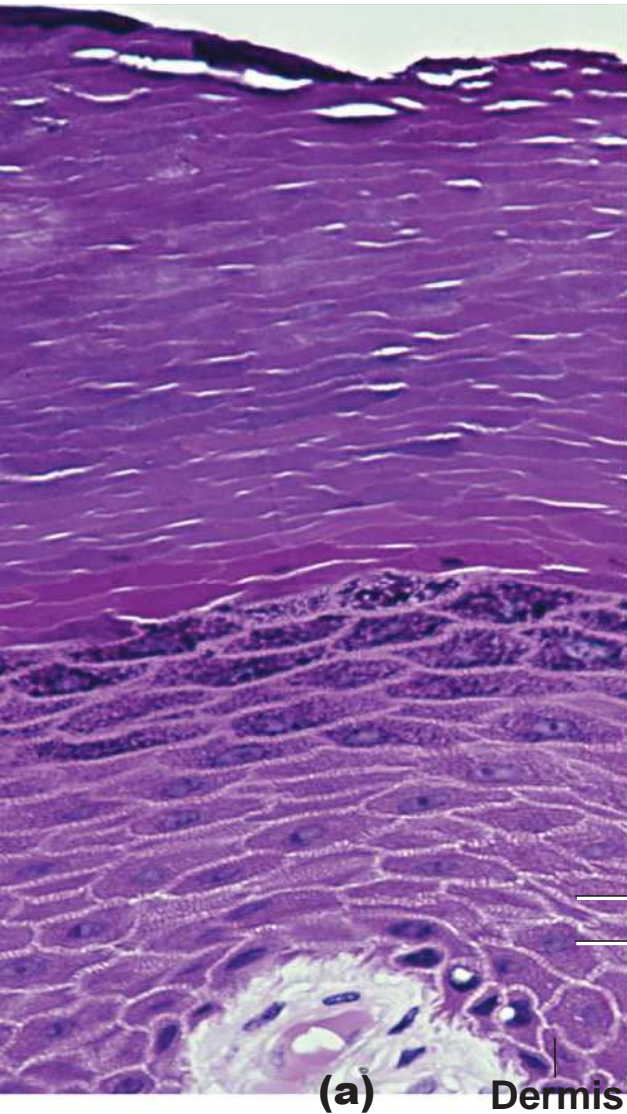
"**C**her **L**ikes **G**etting **S**kin **B**otoxed" (from superficial to deep)

"**B**efore **S**igning, **G**et **L**egal **C**ounsel" (from deep to superficial)

"**B**are **S**kin **G**rows **L**ike **C**orn" (from deep to superficial)

***The stratum lucidum is found is  
only in thick skin.***

- 
- **Male skin is characteristically thicker than female skin in all anatomic locations.**
  - **Children have relatively thin skin, which progressively thickens until the fourth or fifth decade of life when it begins to thin.**
  - **This thinning is also primarily a dermal change, with loss of elastic fibers, epithelial appendages, and ground substance**



**Stratum corneum**

Most superficial layer; 20–30 layers of dead cells represented only by flat membranous sacs filled with keratin. Glycolipids in extracellular space.

**Stratum granulosum**

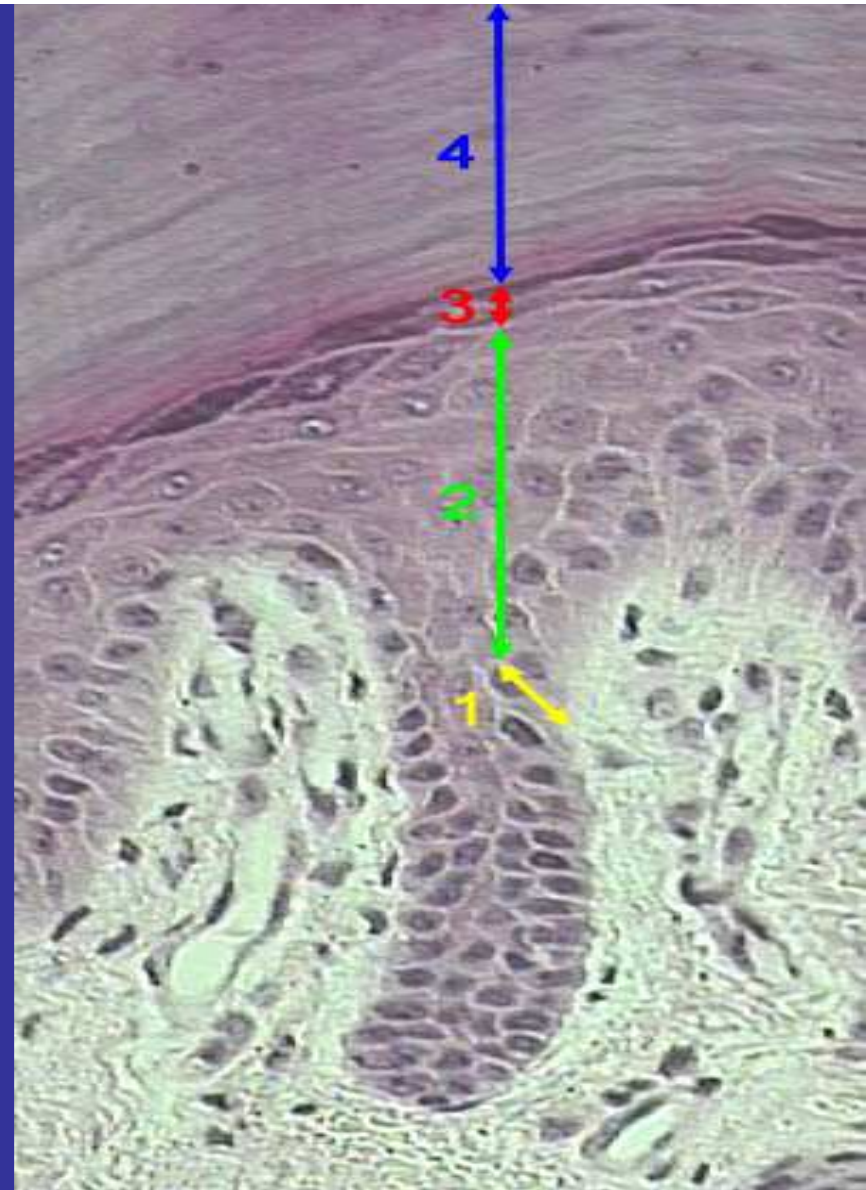
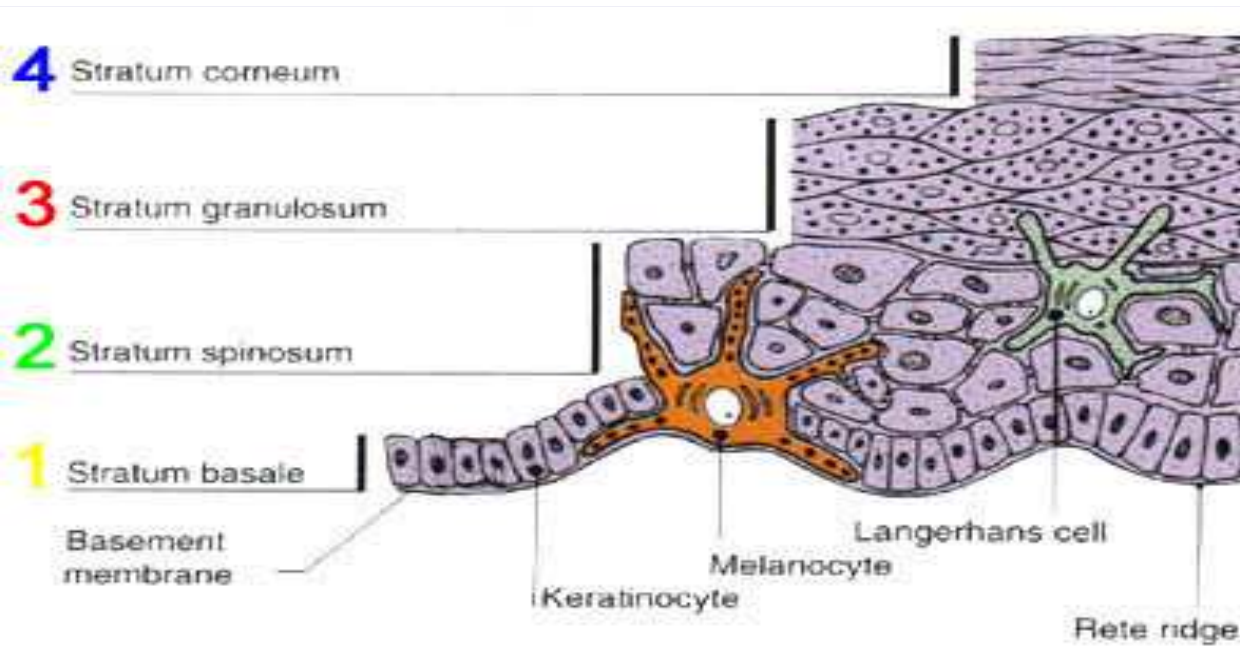
Three to five layers of flattened cells, organelles deteriorating; cytoplasm full of lamellated granules (release lipids) and keratohyaline granules.

**Stratum spinosum**

Several layers of keratinocytes unified by desmosomes. Cells contain thick bundles of intermediate filaments made of pre-keratin.

**Stratum basale**

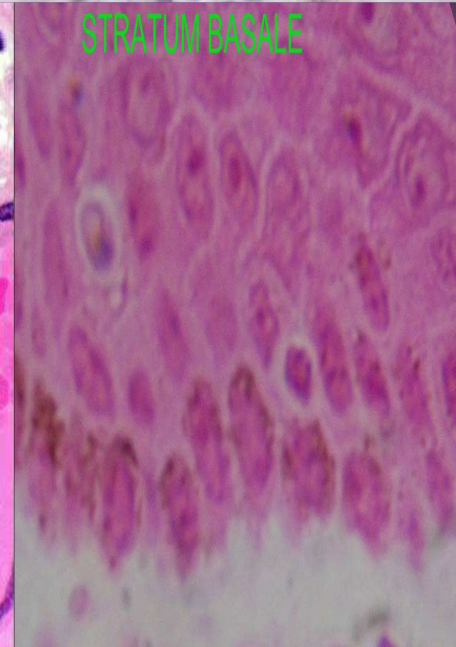
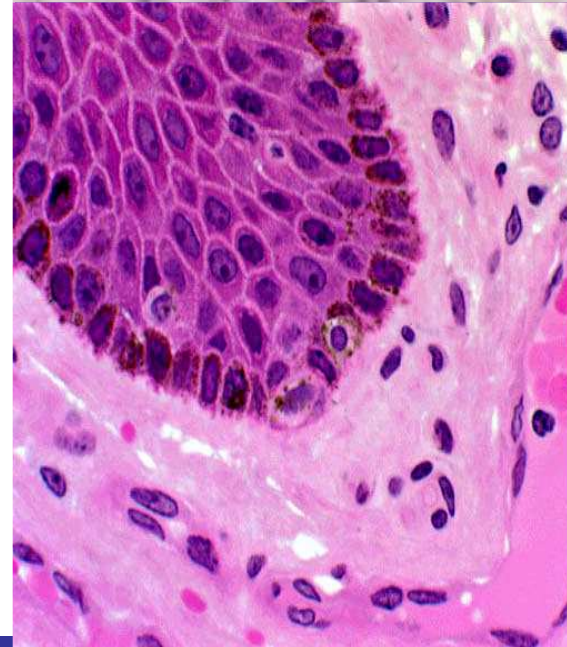
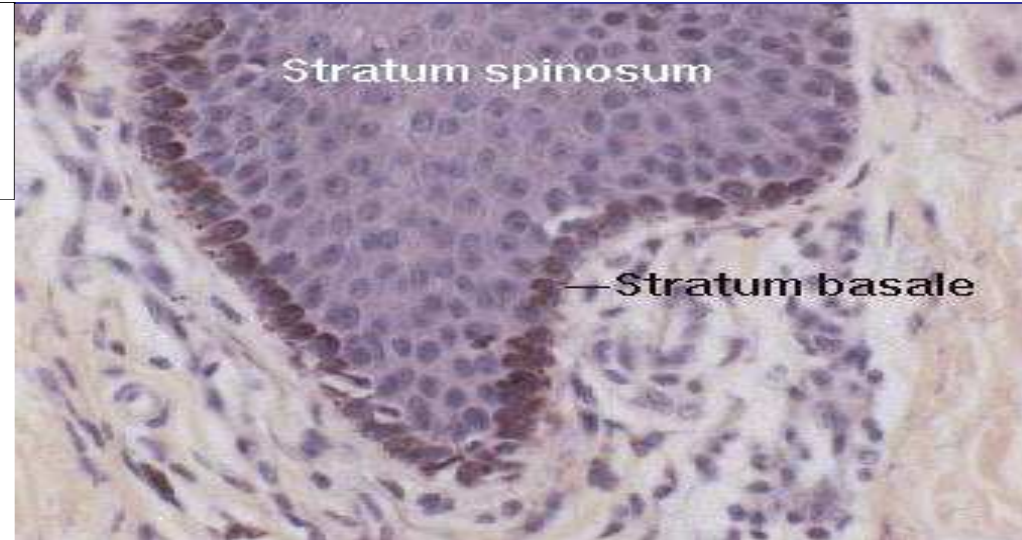
Deepest epidermal layer; one row of actively mitotic stem cells; some newly formed cells become part of the more superficial layers. See occasional melanocytes and epidermal dendritic cells.



Notice the 4 layers of thin skin in both the cartoon and the photomicrograph.

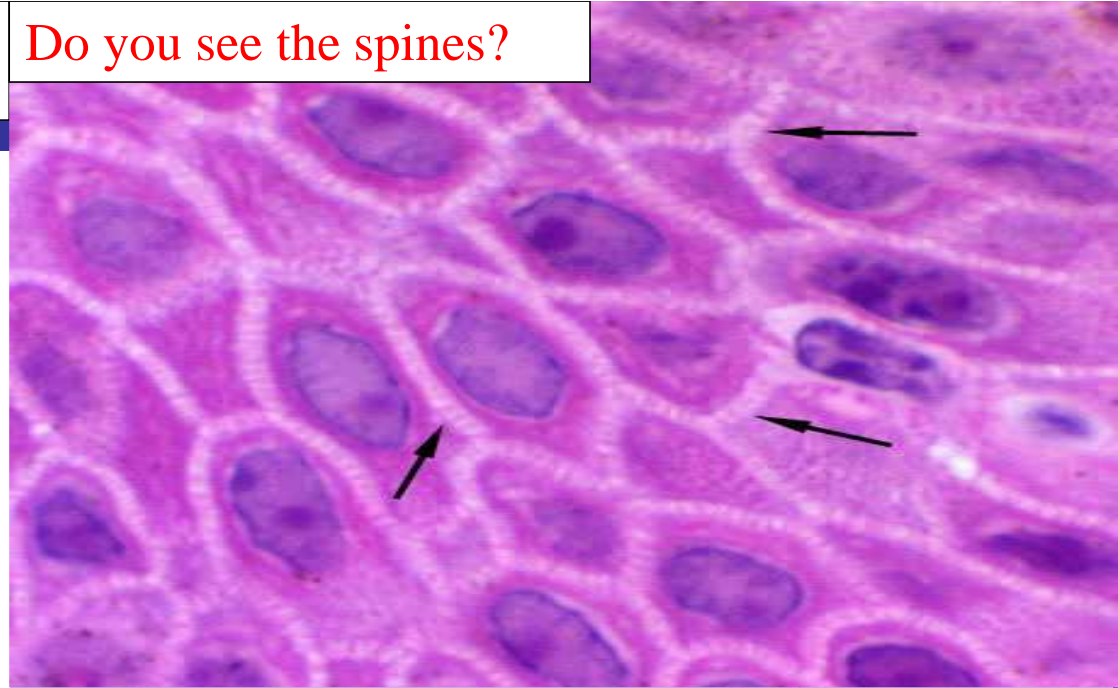
# Stratum Basale

- **Deepest epidermal layer.**
- **Firmly attached to the underlying dermis.**
- **Single row of cuboidal keratinocytes** with melanocytes Merkel cells interspersed.
- **Cells in this layer are highly mitotic – they're dividing often.**
- Due to this fact, this layer is a.k.a. the **stratum germinativum.**
- **Basal cells, which are stem cells,** divide in this region to replenish the more superficial layers.
  - Melanocytes are pigment-producing cells found in this layer that secrete the pigment melanin into other cells.
  - Merkel cells are sensory cells found in this layer in areas where there is no hair.
- origin of all cells of epidermis through mitosis
- origin of cells for sweat-oil glands and hair

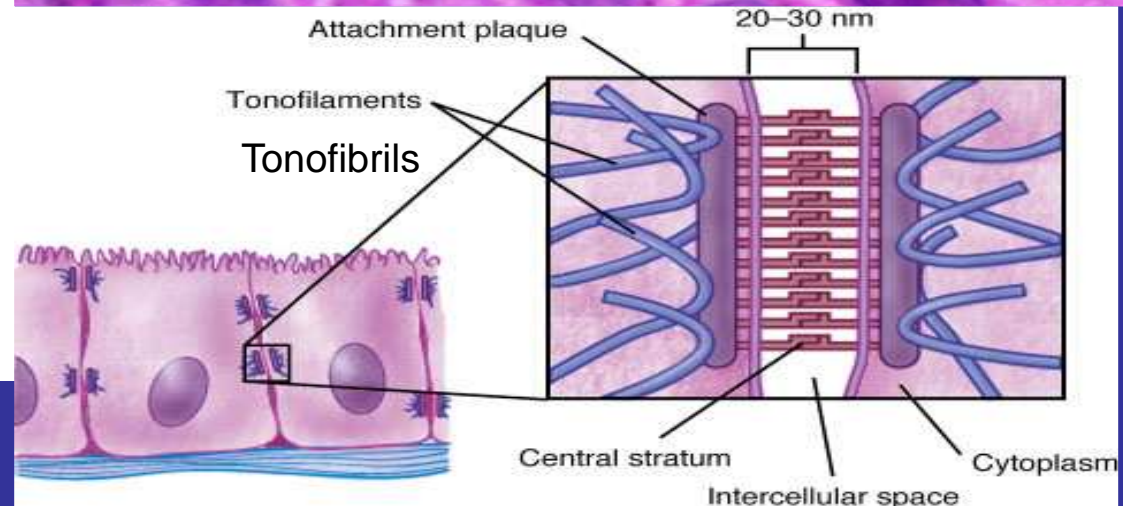


# Stratum Spinosum

Do you see the spines?

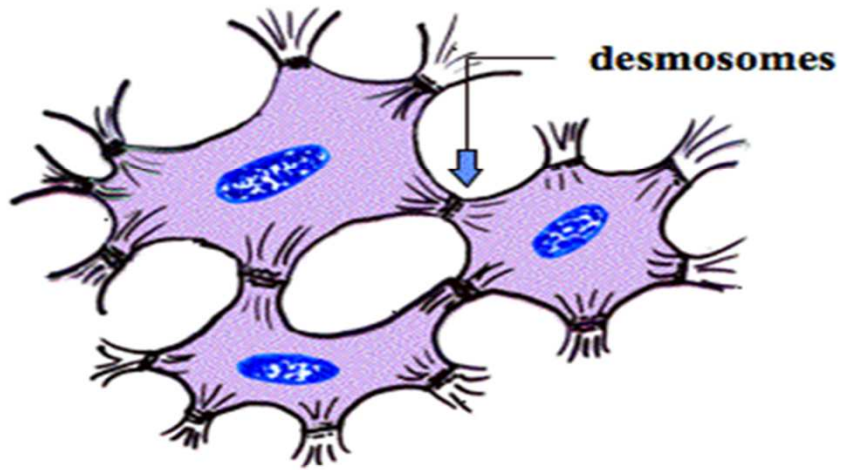


- 2<sup>nd</sup> deepest layer.
- Consists of 8-10 layers of cells.
- Cells of the lower layers can still be mitotic.
- As cells get pushed upward, they begin to flatten and begin to make the precursors of keratin.
- A.k.a. the "**prickly layer**," because in tissue sections, they shrink and pull back.
- This makes their exposed **desmosomes** connecting adjacent cells appear to resemble spikes or spines.
- **Keratinocytes in this layer take on a spiky appearance** due to the production of **interconnecting proteins called tonofibrils**.
- The **tonofibrils greatly increase stability in this layer**.
- **Langerhans cells account for about 5% of the cells in this layer.**
  - **These fixed macrophages are the first cells of the immune system to encounter any foreign object the tries to penetrate the skin.**
  - **They also play a role in monitoring of cancerous epidermal cells.**
- » 1. 8-10 rows of polyhedral shaped cells
- » 2. contain spine-like projections ("spinosum")

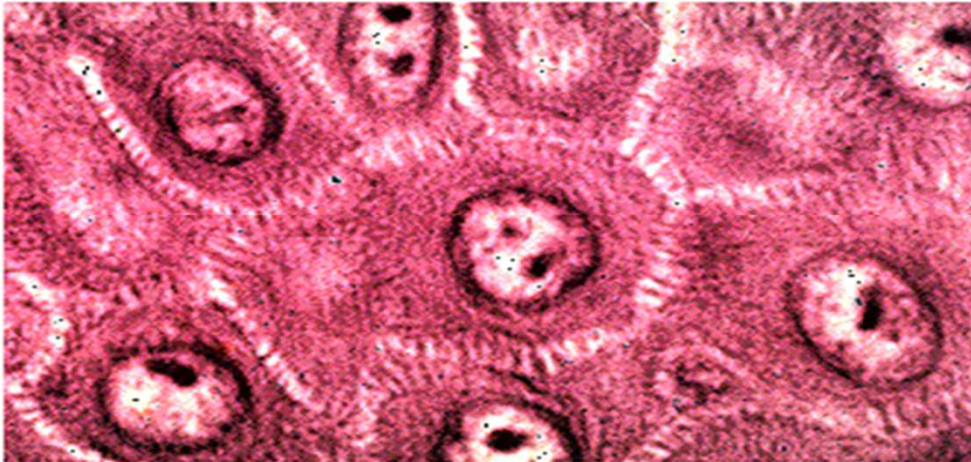


# STRATUM SPINOSUM

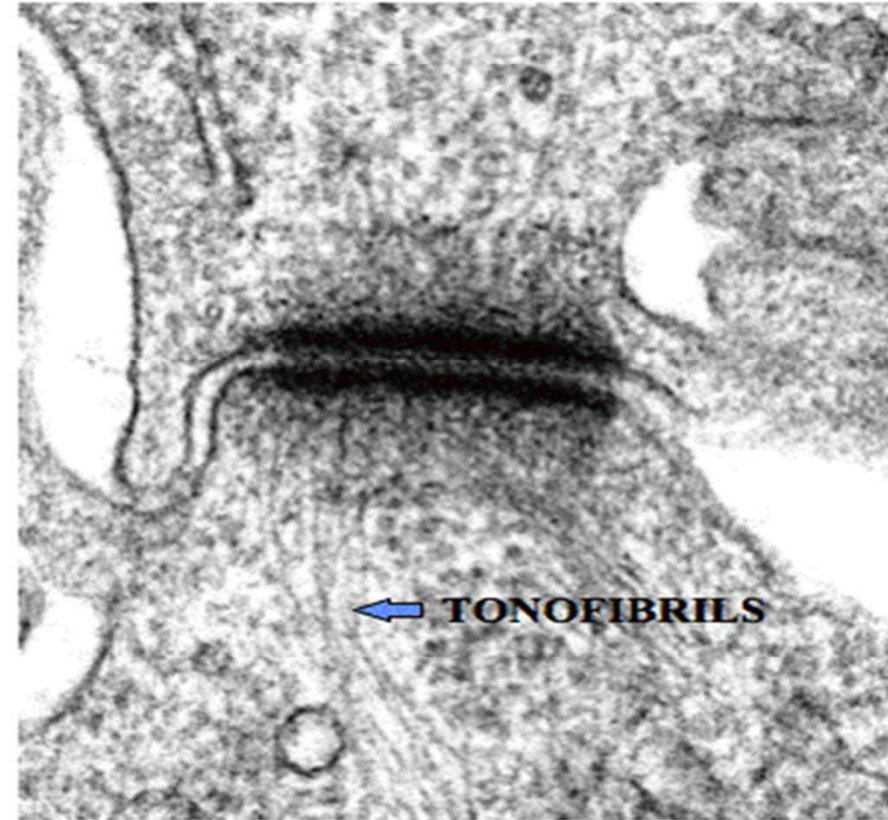
## PRICKLE CELLS



## PRICKLE CELLS IN STRATUM SPINOSUM

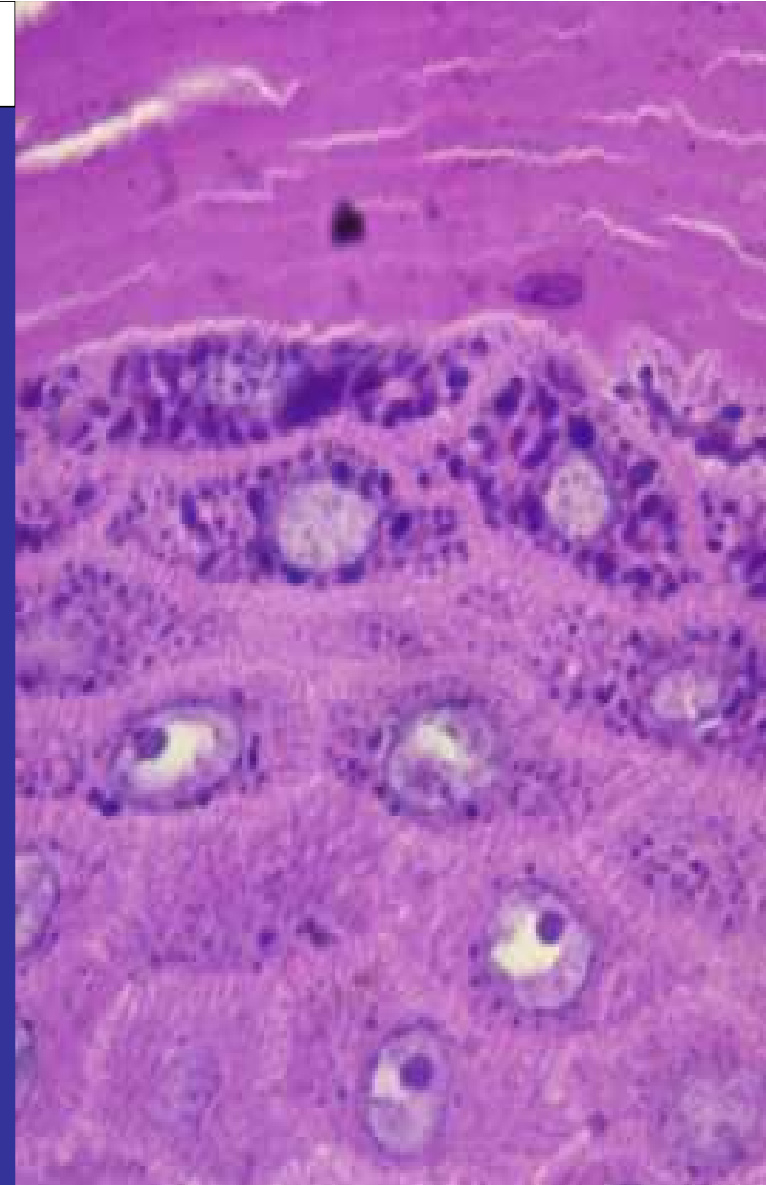


## TEM- DESMOSOME

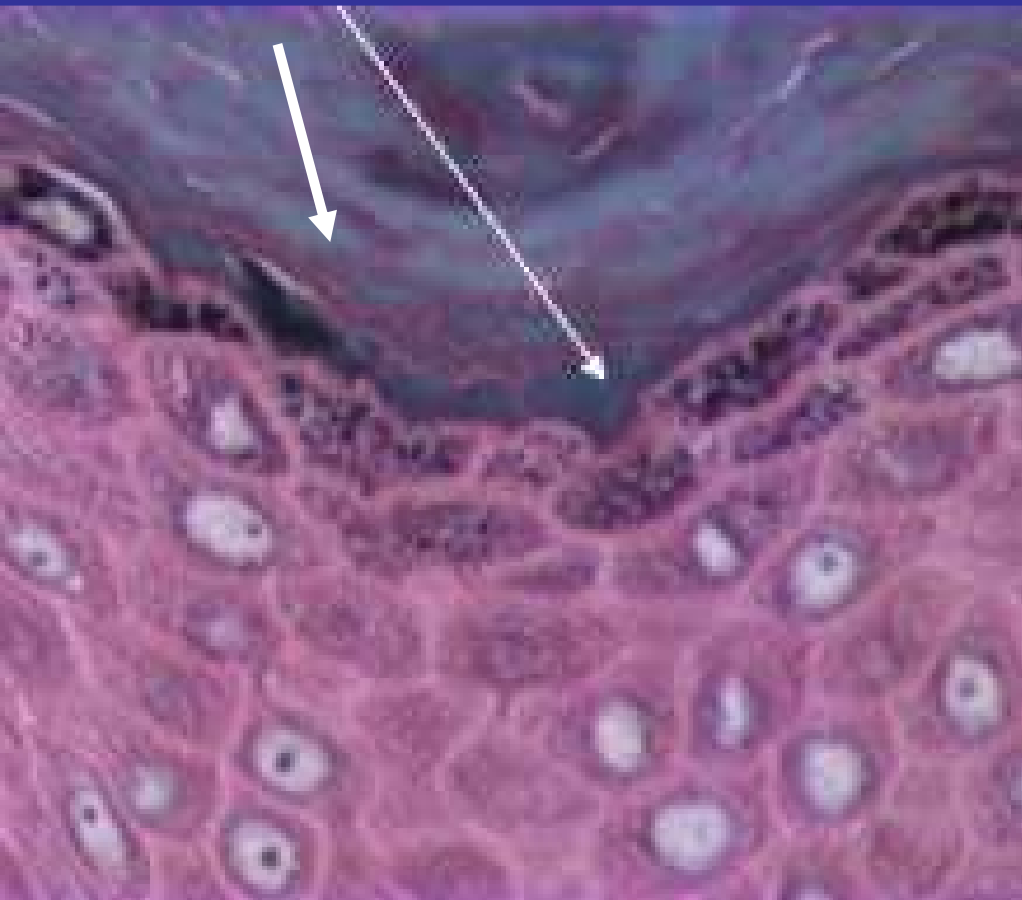


# Stratum Granulosum

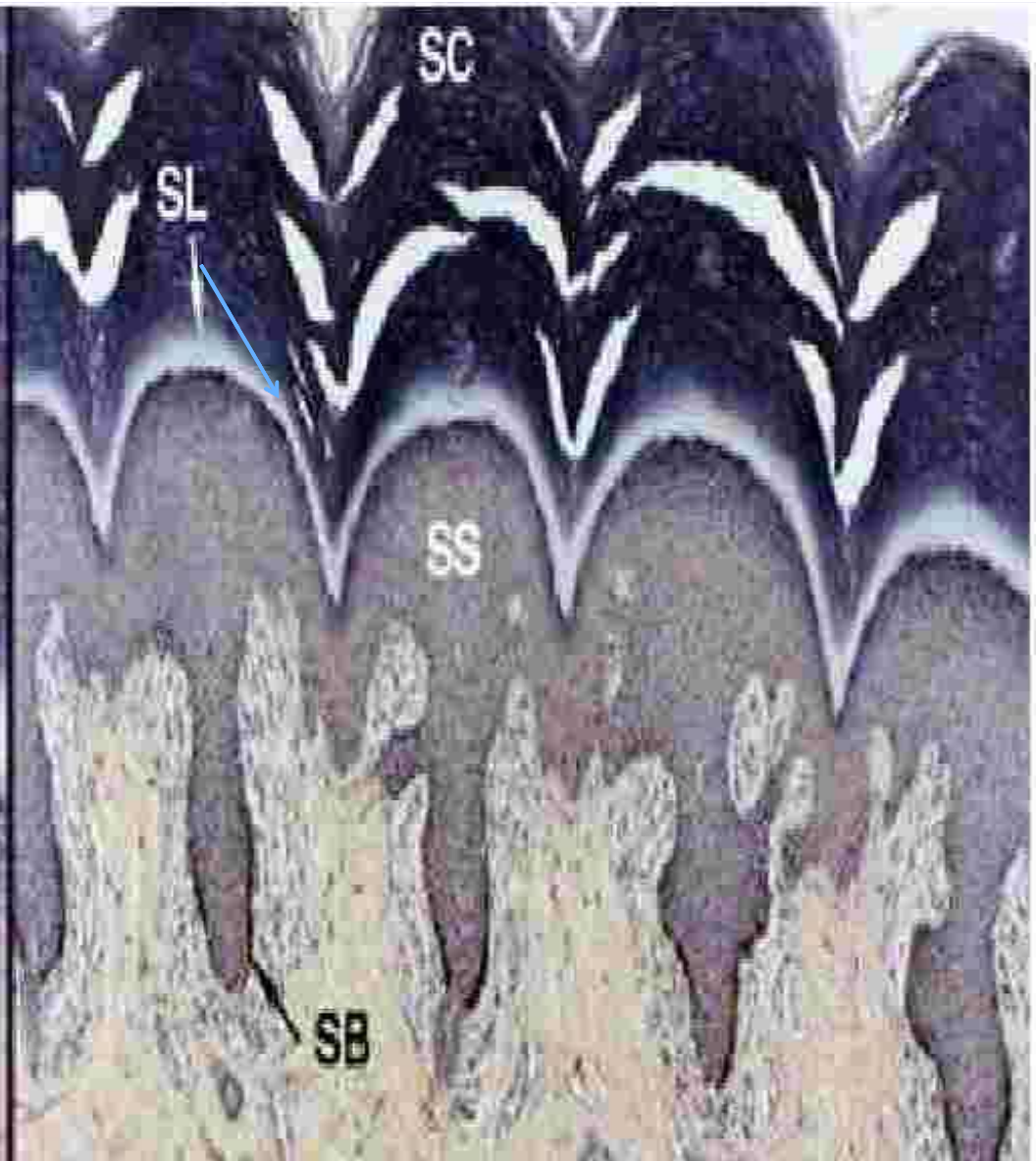
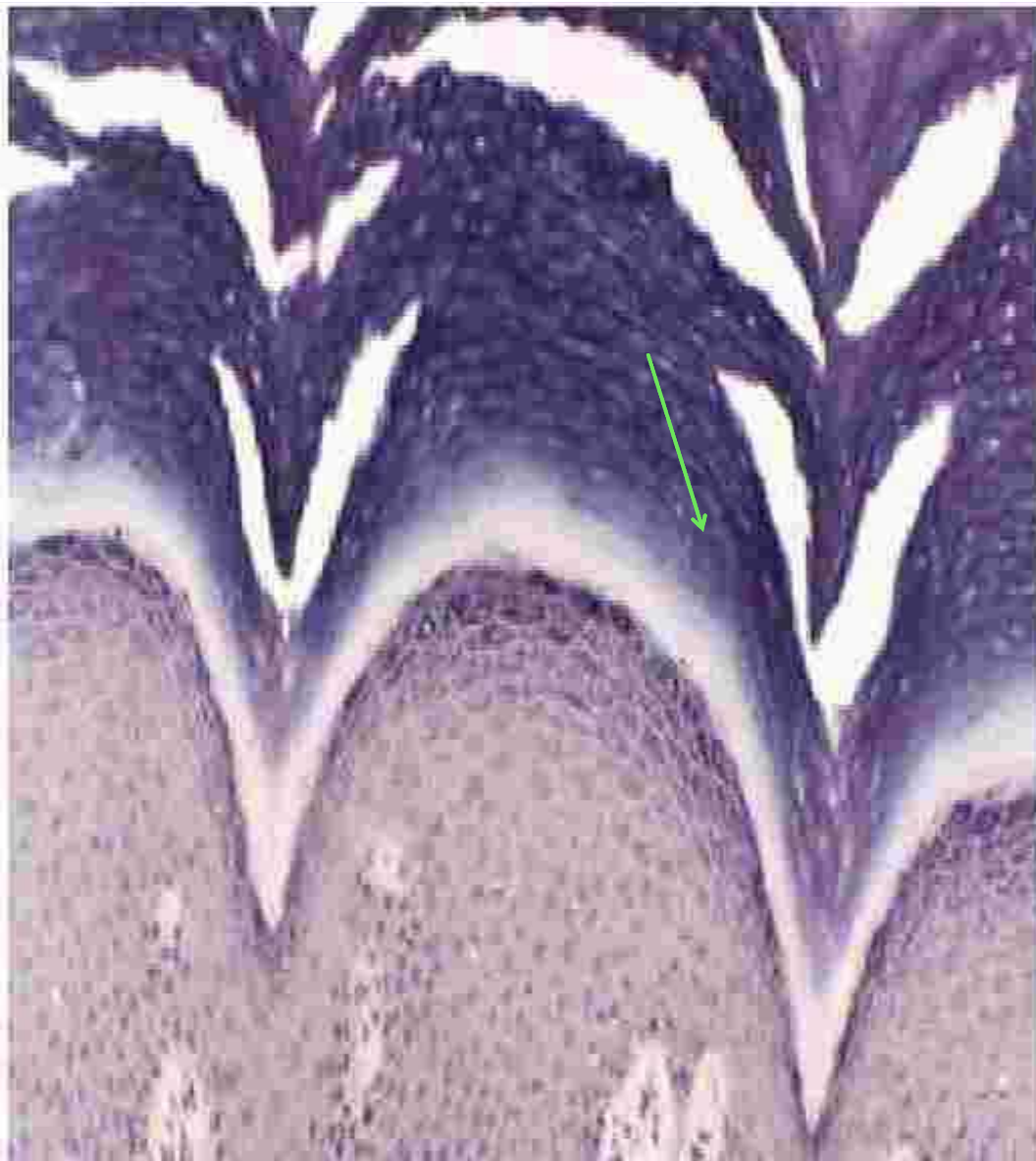- 3-5 cell layers thick.
- Cell morphology begins to change dramatically as cells continue to flatten and their nuclei and organelles disintegrate.
- Accumulate granules containing a precursor of keratin and granules containing a waterproofing agent.
  - If water can't diffuse upward, how would the cells above this layer receive nutrients? What would happen to them?
  - Keratohyalin and keratin are proteins manufactured by the keratinocytes in this layer.
  - Keratohyalin is packaged in granules that surround the keratin filaments.
  - Keratinocytes in this layer also become thinner,
  - however they become less permeable due to thickening cell membranes and the keratohyalin.
  - **1. cells from lower layers begin to die here**
  - **2. contain granules with keratohyalin**
  - **3. keratohyalin is precursor to eleidin and keratin**



# Stratum Lucidum



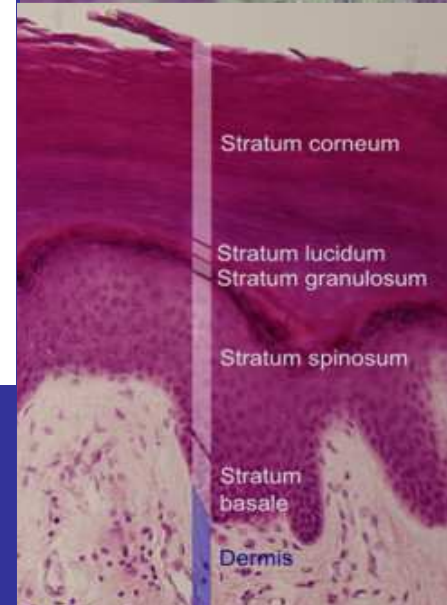
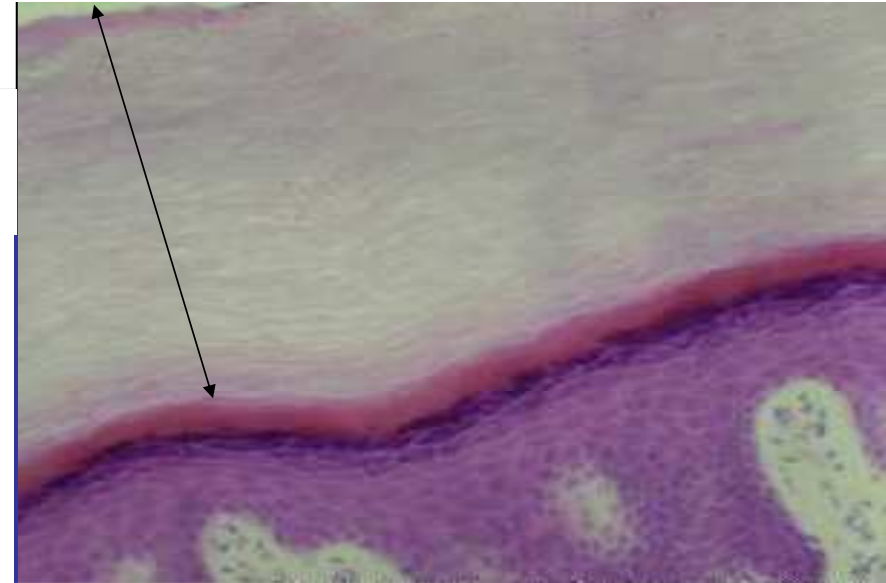
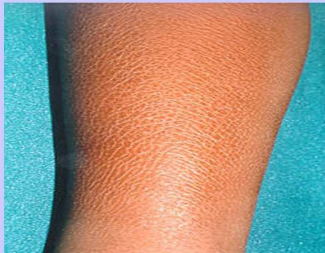- 3-5 layers of flat, dead keratinocytes.
- Appears clear in the light microscope because it lacks nuclei and organelles which typically stain well.
- is only found in the thick skin of the palms and soles.
- – The cells in this layer are very similar to those in the superficial layers of the granulosum, however they do not stain well.
- – 1. Present only in thick areas (palms, feet)
- – 2. Contain clear substance called eleidin
- – 3. Eleidin eventually changes into keratin at surface



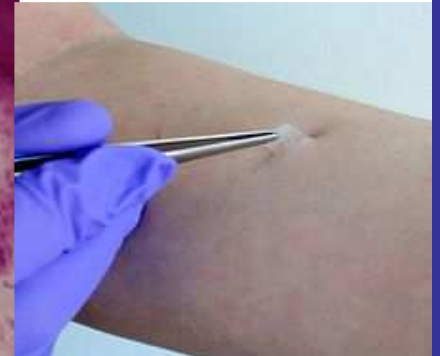# Stratum Corneum

- Outermost stratum.
- 20 – 30 layers of flat (squamous), highly keratinized, dead cells.
- Protects against mechanical abrasion – cells can absorb impacts and simply flake off if necessary.
- Prevents pathogen entry.
- Prevents desiccation (drying out).
- A.k.a. the **cornified layer**.
- The process by which cells in the stratum basale divide and then advance upward
- Keratinized is the term for an epithelium containing a
- large amount of keratin.
- The relatively dry covering that results is unsuitable of microorganism growth.
- Keratinization occurs everywhere on the surface of the skin except the anterior surface of the eyes.

Thickened Stratum Corneum

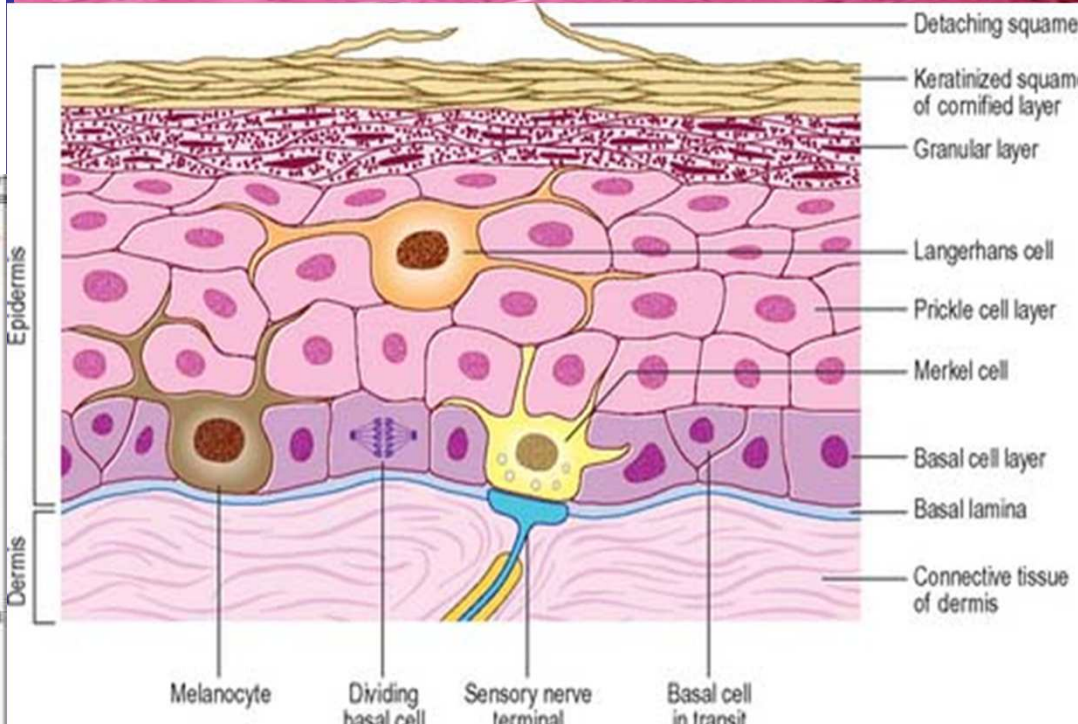
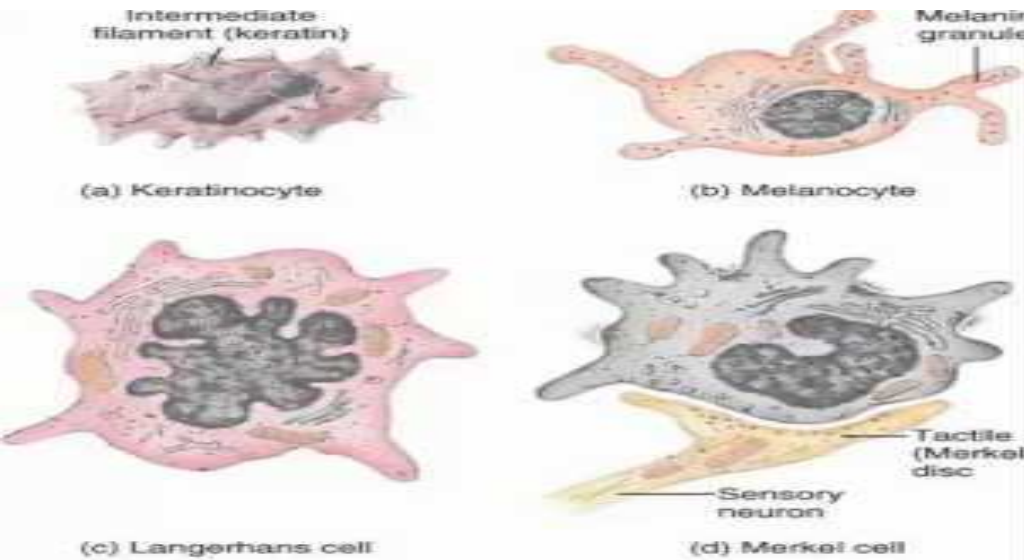
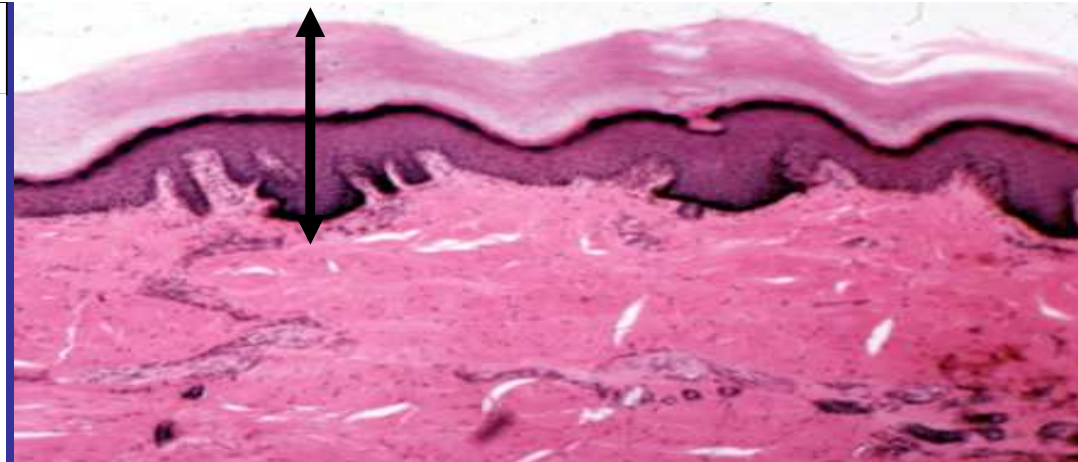


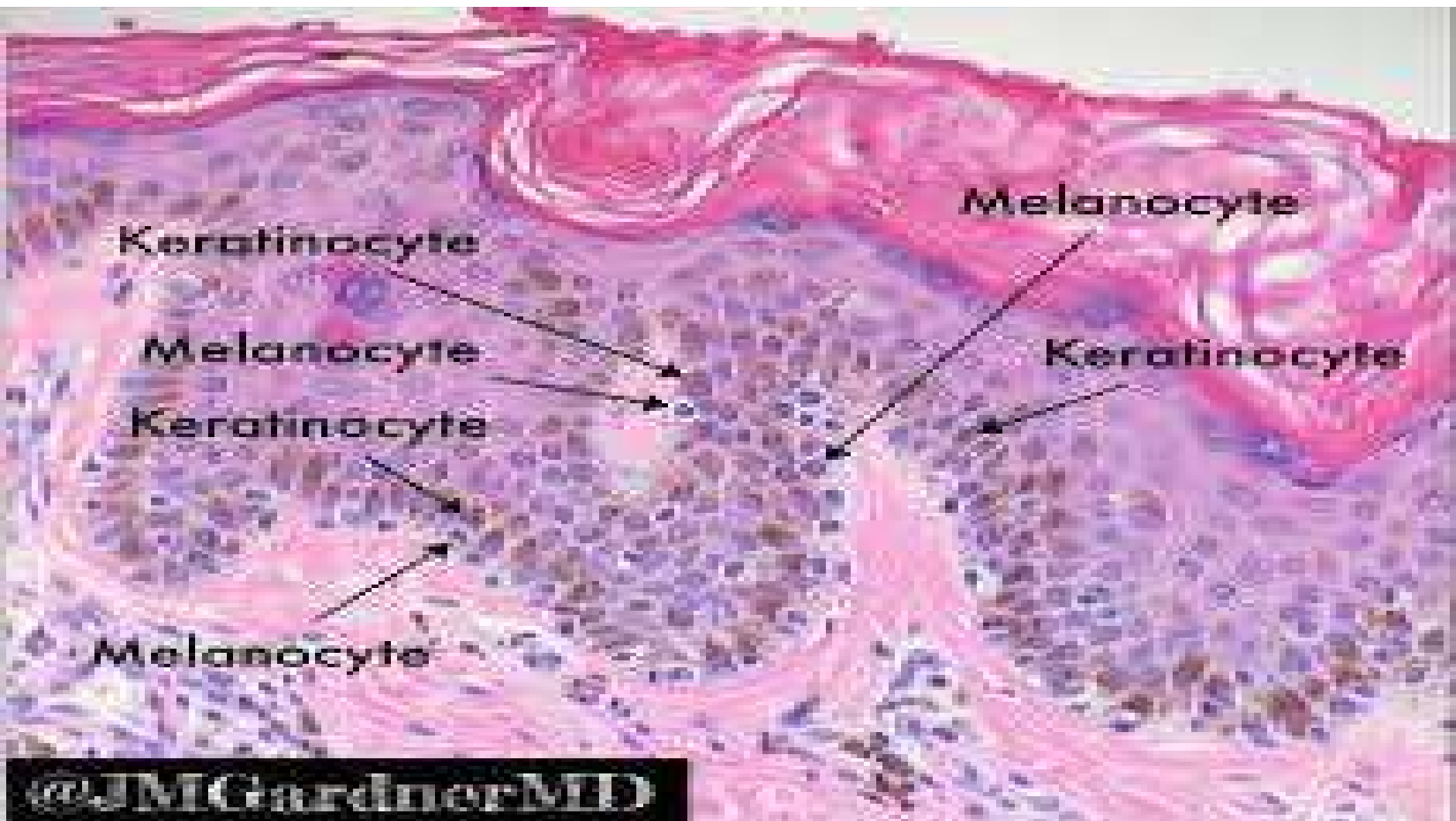
becoming more and more keratinized and less and less alive as they go is known as cornification.



# The Epidermis

- Keratinized stratified squamous epithelium.
- Avascular.
- Consists of 4 distinct cell types arranged in 4 or 5 distinct layers.
- Epidermal cell types:
  1. Keratinocytes (*structure*)
  2. Melanocytes (*pigment*)
  3. Merkel cells (*sensation*)
  4. Langerhans' cells (*phagocytes - immune defense*)





Keratinocyte

Melanocyte

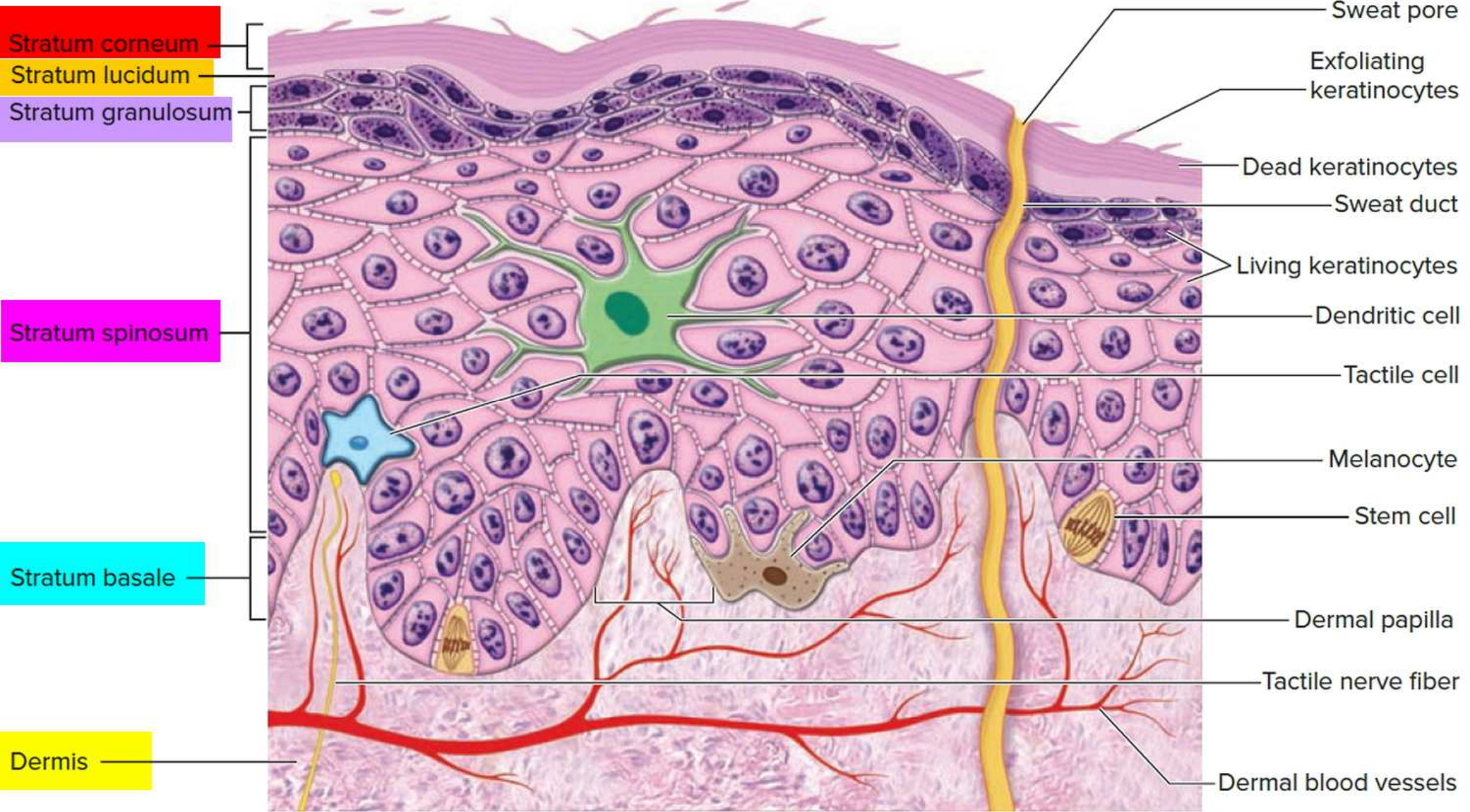
Melanocyte

Keratinocyte

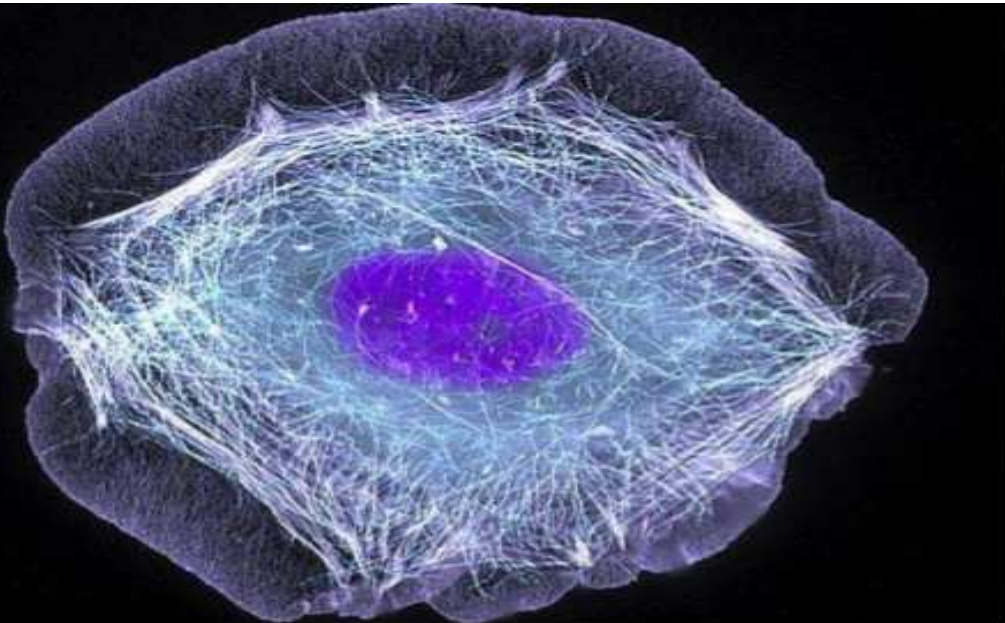
Keratinocyte

Melanocyte

@JMGardnerMD



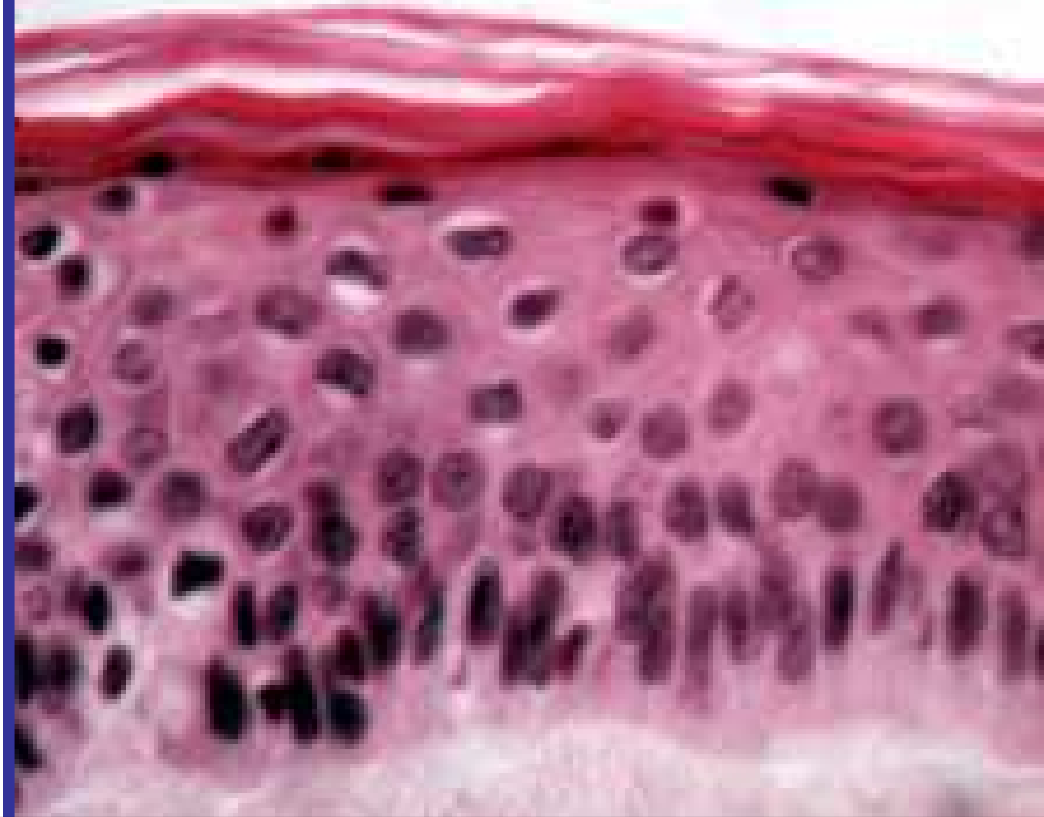
- **Most numerous epidermal cell** – found in all layers of the epidermis.
- **Chief function is the production of keratin** – a tough fibrous protein that gives strength and confers a lot of protective ability.
- **Tightly connected to one another by desmosomes.**
  - Provides continuity, strength, and protection.
  - Is the reason skin flakes off in sheets rather than as individual cells.



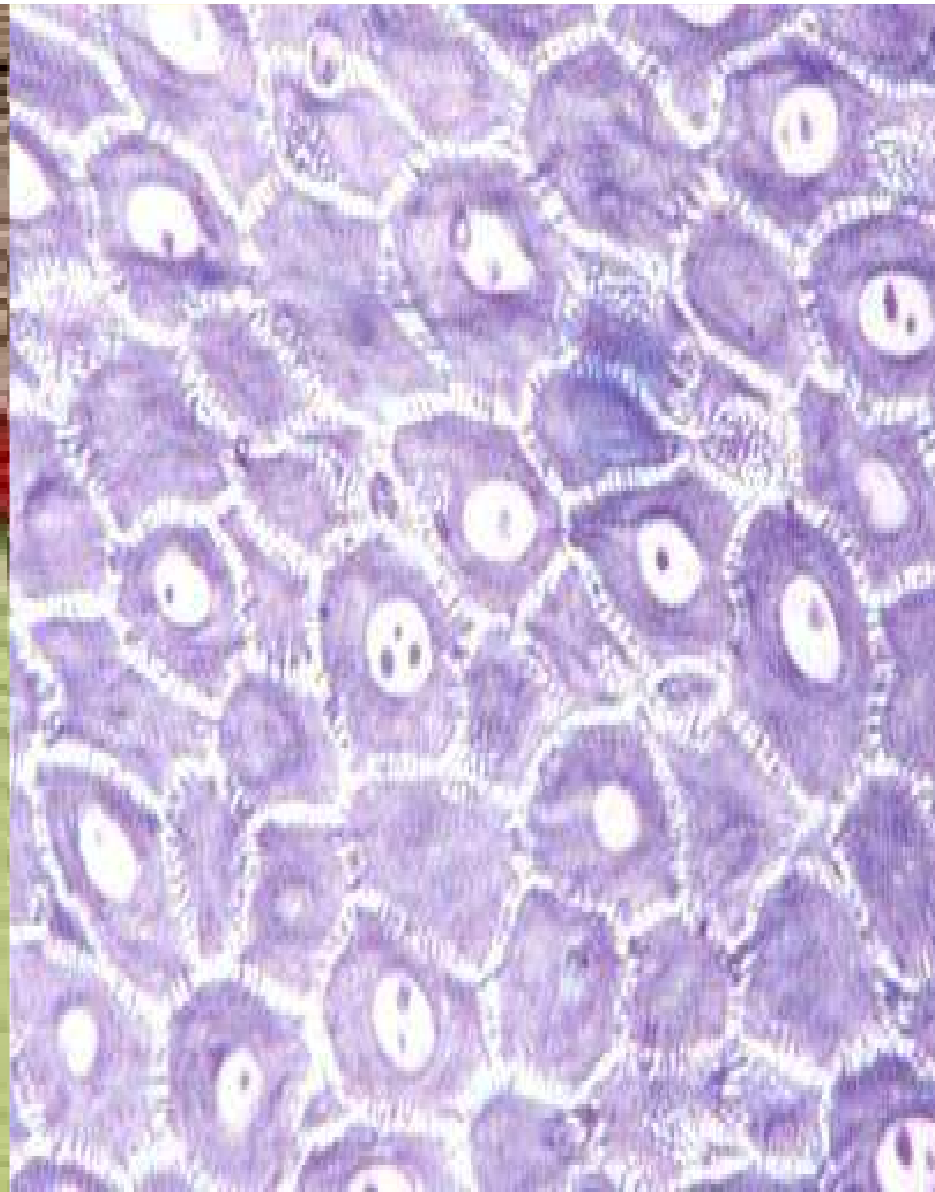
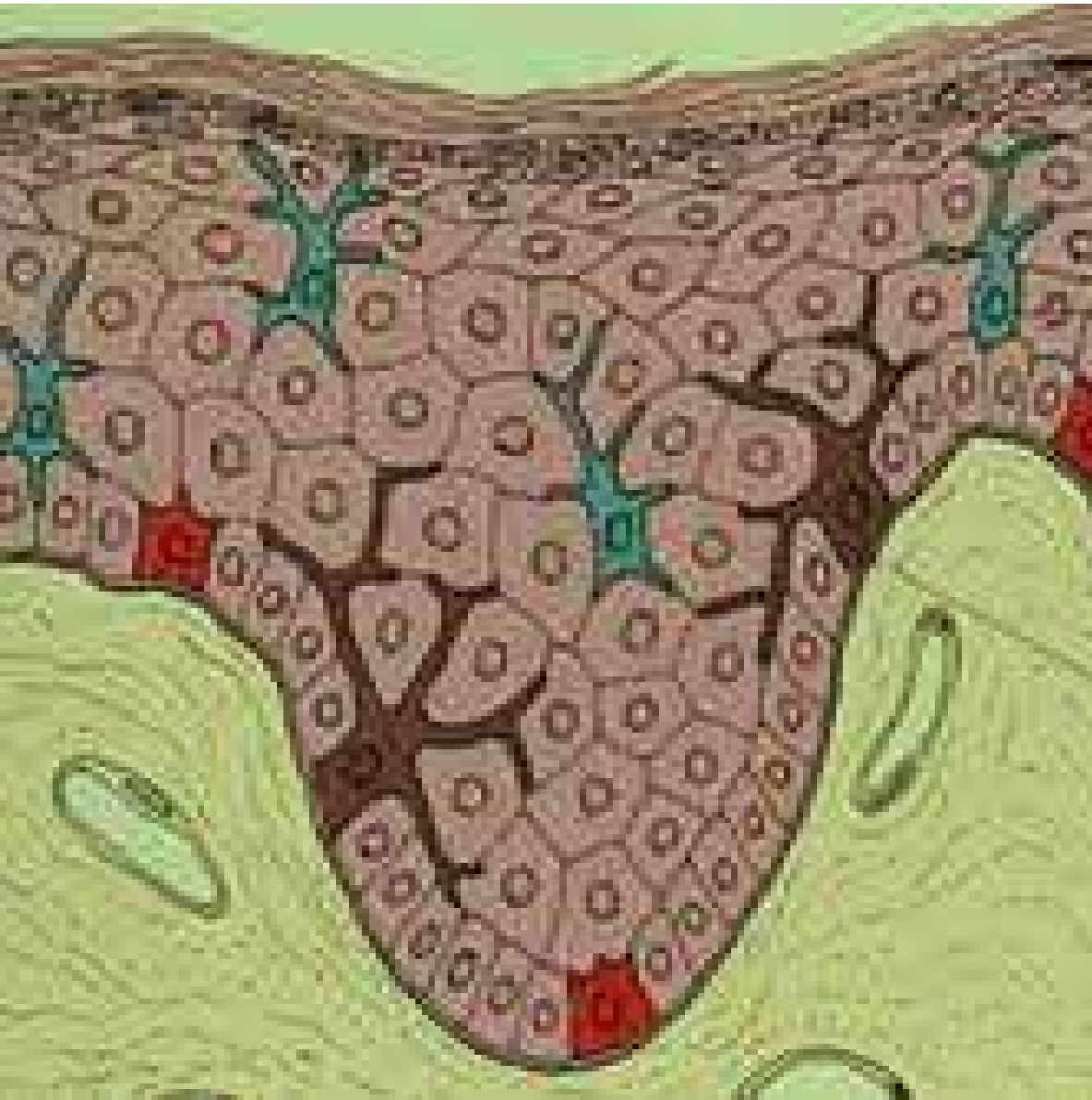
**Human keratinocytes**

# Keratinocytes

~~Keratinocytes are renewed every 28 days and die off in the form of scaly cells containing keratin.~~



Almost all of the epidermal cells in this slide are keratinocytes

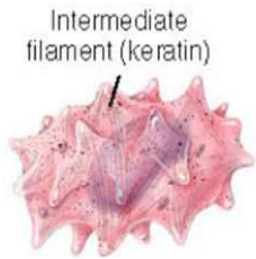


## Fitzpatrick skin type

| Skin type | Typical features                                 | Tanning ability                  |   |
|-----------|--|----------------------------------|---|
| I         | Pale white skin, blue/green eyes, blond/red hair | Always burns, does not tan       |    |
| II        | Fair skin, blue eyes                             | Burns easily, tans poorly        |    |
| III       | Darker white skin                                | Tans after initial burn          |    |
| IV        | Light brown skin                                 | Burns minimally, tans easily     |   |
| V         | Brown skin                                       | Rarely burns, tans darkly easily |  |
| VI        | Dark brown or black skin                         | Never burns, always tans darkly  |  |

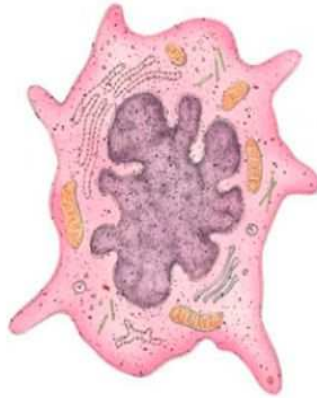
# Keratinocytes-Prickle cells

- New cells are continuously made in the deepest layer pushing the older cells up.
- As the keratinocytes move farther from the deepest layer, they make the keratin that eventually dominates their cell contents.



(a) Keratinocyte

Copyright © 2005 John Wiley & Sons, Inc. All rights reserved.



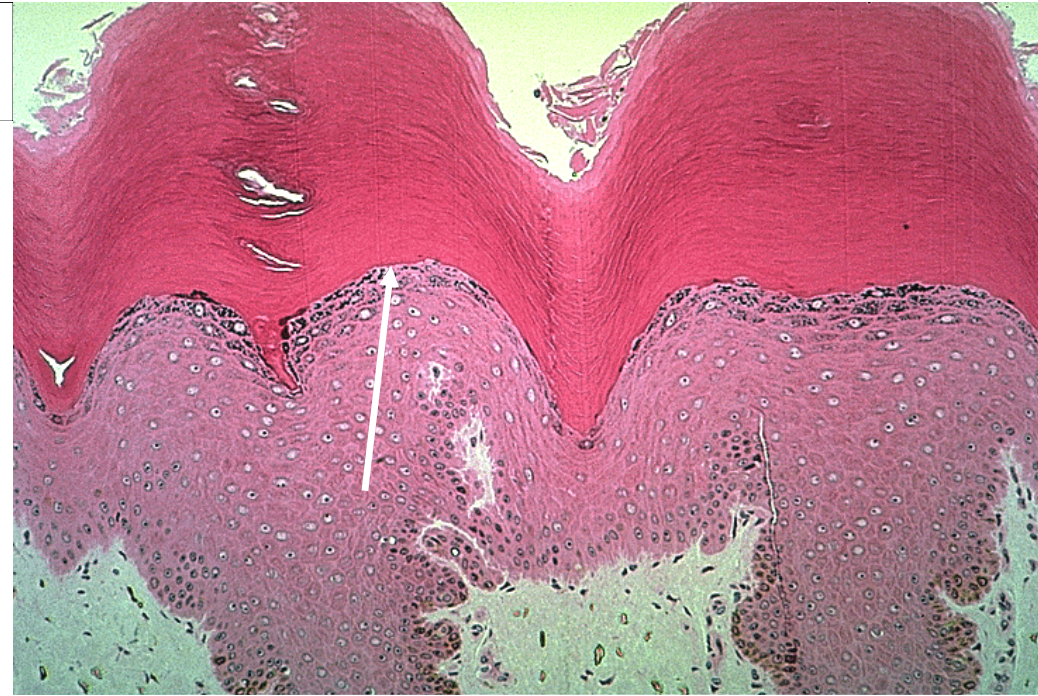(c) Langerhans cell

Copyright © 2005 John Wiley & Sons, Inc. All rights reserved.

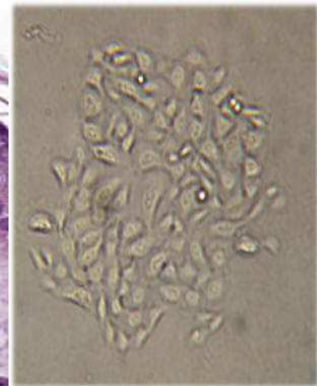
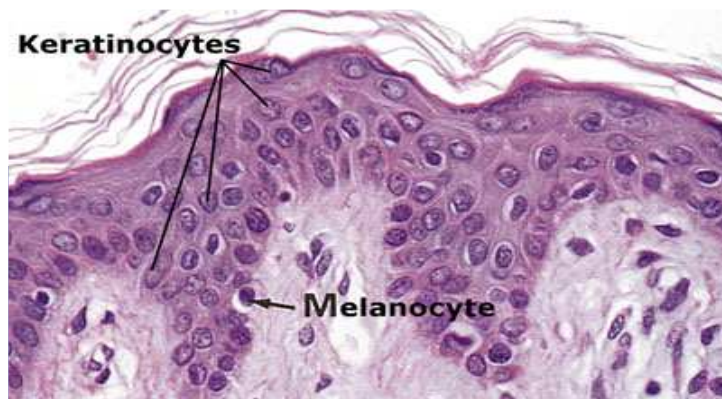
Most of the skin consists of Keratinocytes:

- Produce keratin
- Lamellar granules

- Found in Stratum Spinosum
- Arise from red bone marrow
  - Participate in immune response



When they have reached the upper layer, they are nothing more than scale-like bags of keratin.



- **The** primary function of keratinocytes is the formation of a barrier against:
  - **environmental damage such as pathogens (bacteria, fungi, parasites, viruses)**
  - **heat,**
  - **UV**
  - **radiation and water loss.**

Once pathogens start to invade the upper layers of the epidermis, keratinocytes can react with the production of proinflammatory mediators and in particular chemokines such as

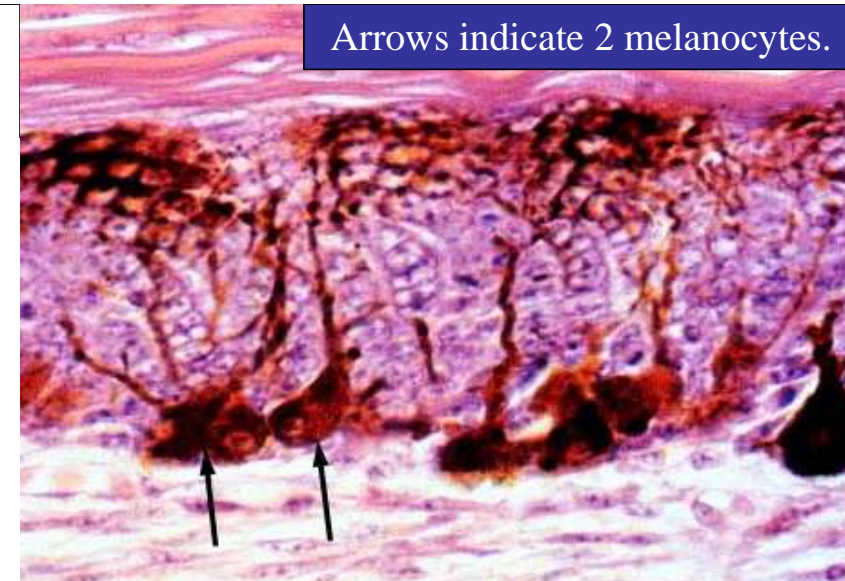
- **CXCL10,**
- **CCL2** which attract leukocytes to the site of pathogen invasion

# KERATIN TERMINOLOGY

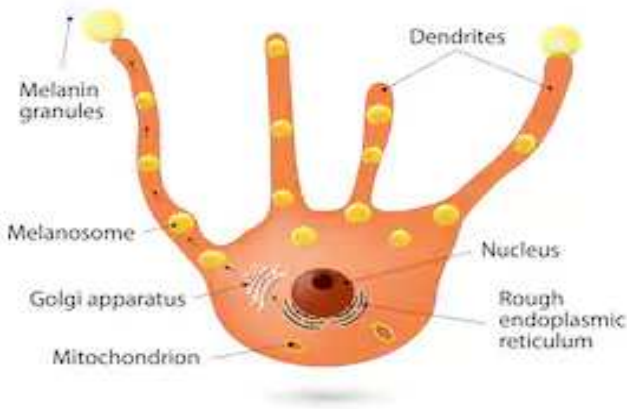
- **keratinization** - The process of converting (something, e.g., epidermis, hair, nails, horns, and hooves) into keratin.
- **keratohyaline** - The protein precursor to keratin which is the predominant form of the protein observed in keratinocytes in the stratum granulosum of the epidermis of the skin.
- **keratin** - A tough, insoluble protein, produced by keratinocytes, which is the predominant form of the protein in the stratum lucidum and stratum corneum of the skin; it helps protect the epidermis from abrasion and water loss; keratin is also the chief structural constituent of hair, nails, horns, and hooves.

# Melanocytes

- Spider-shaped epithelial cells that synthesize the protein pigment melanin.
- Found in the deepest layer of the epidermis
- **Melanin is made and then packaged into membrane-bound granules called melanosomes.**
- Granules are transferred to the keratinocytes in the 2 deepest layers of the epidermis.
- **Melanocytes are more numerous in the forehead, nipples, and genital regions.**

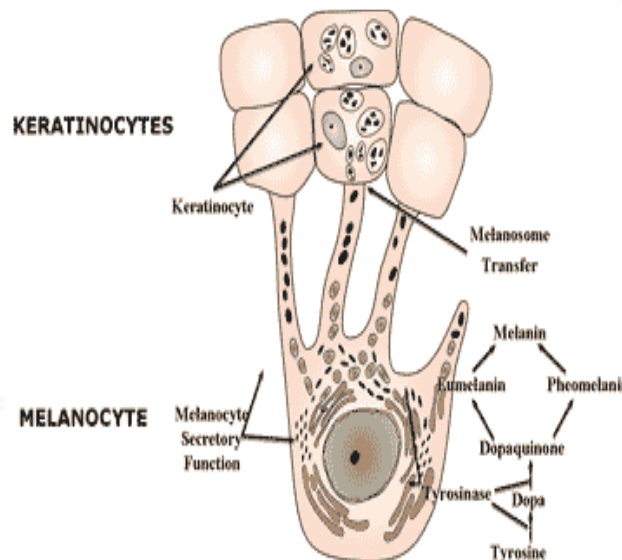


## MELANOCYTE

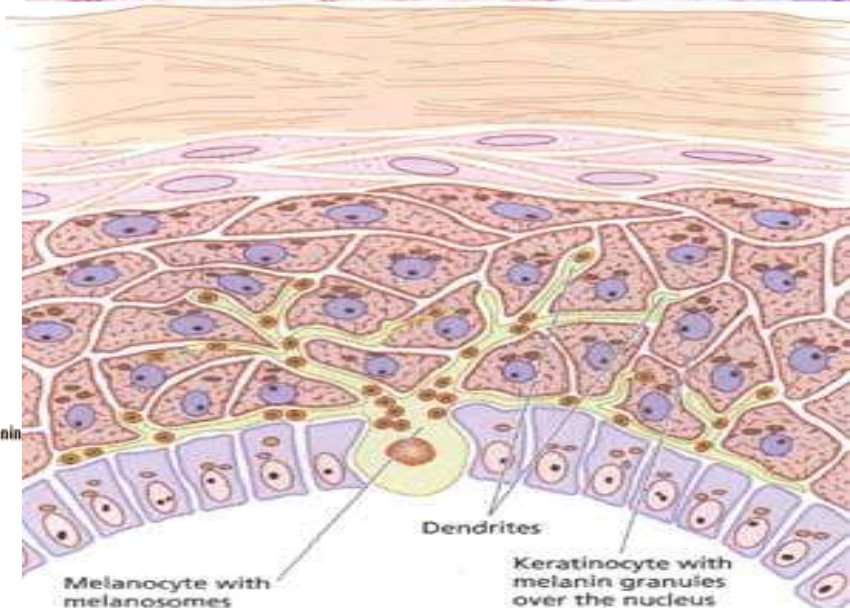


shutterstock.com · 281633990

## KERATINOCYTES

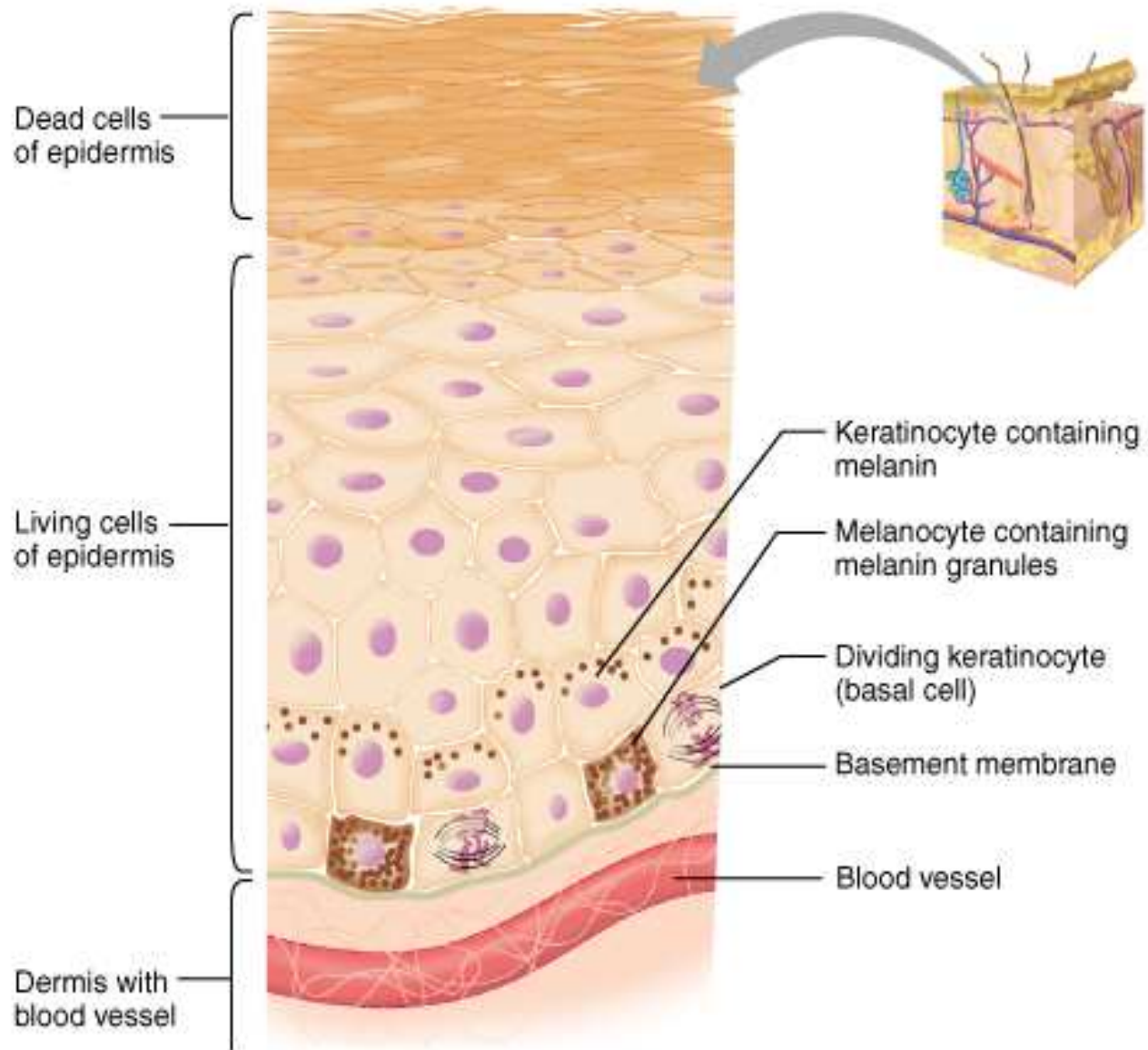
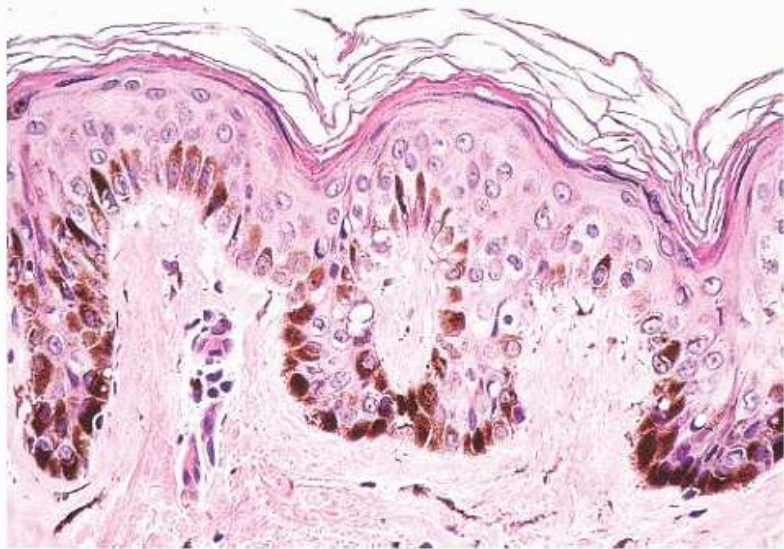


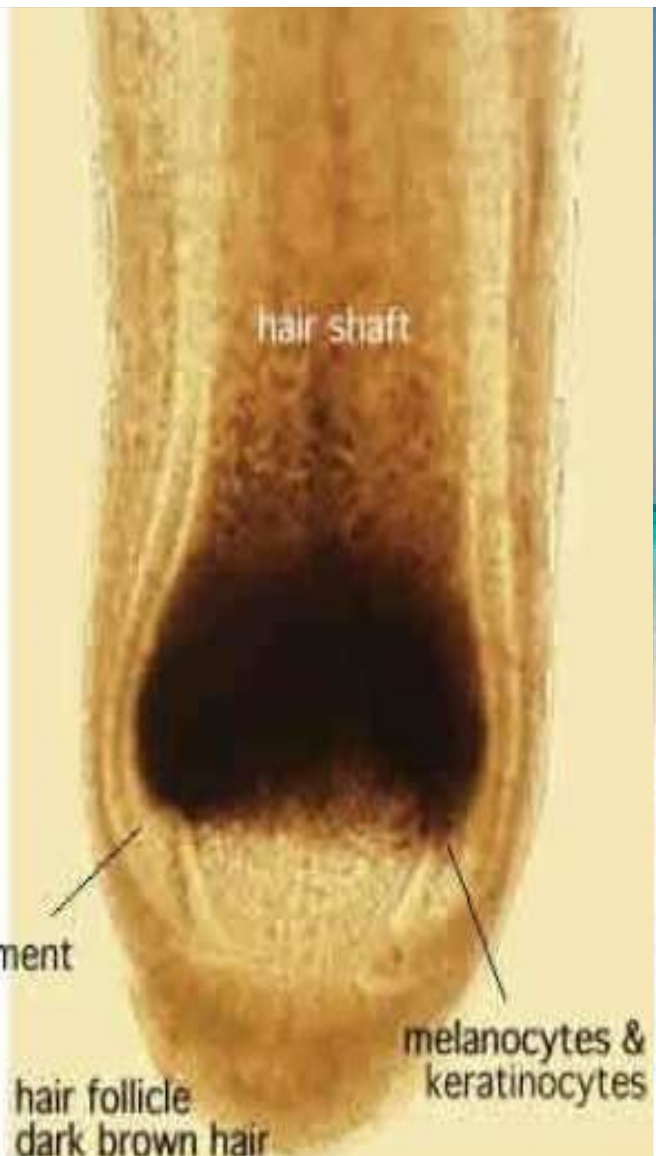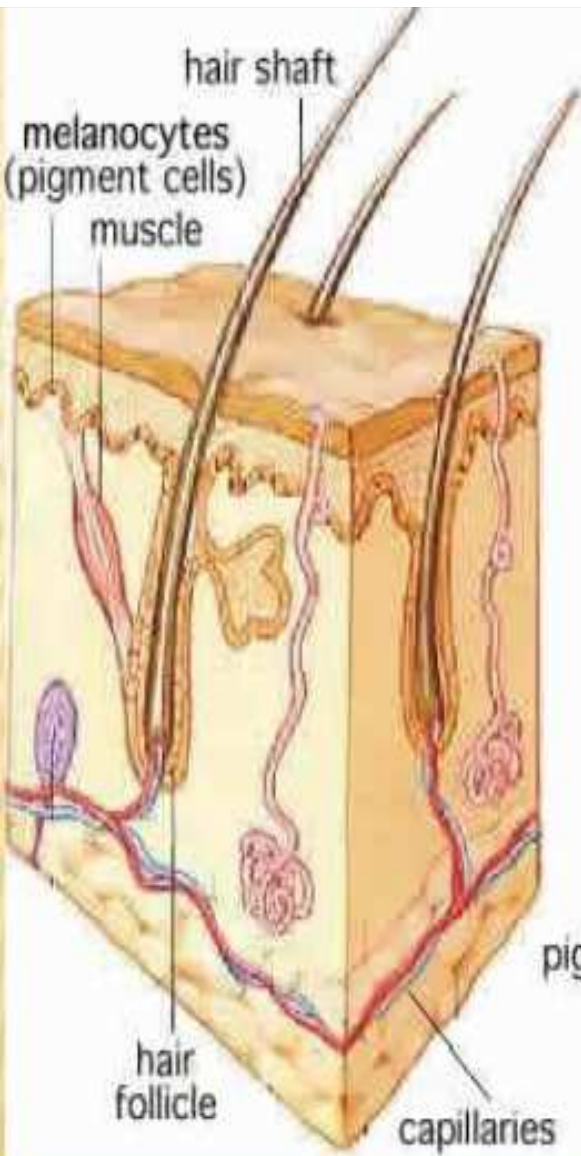
## MELANOCYTE



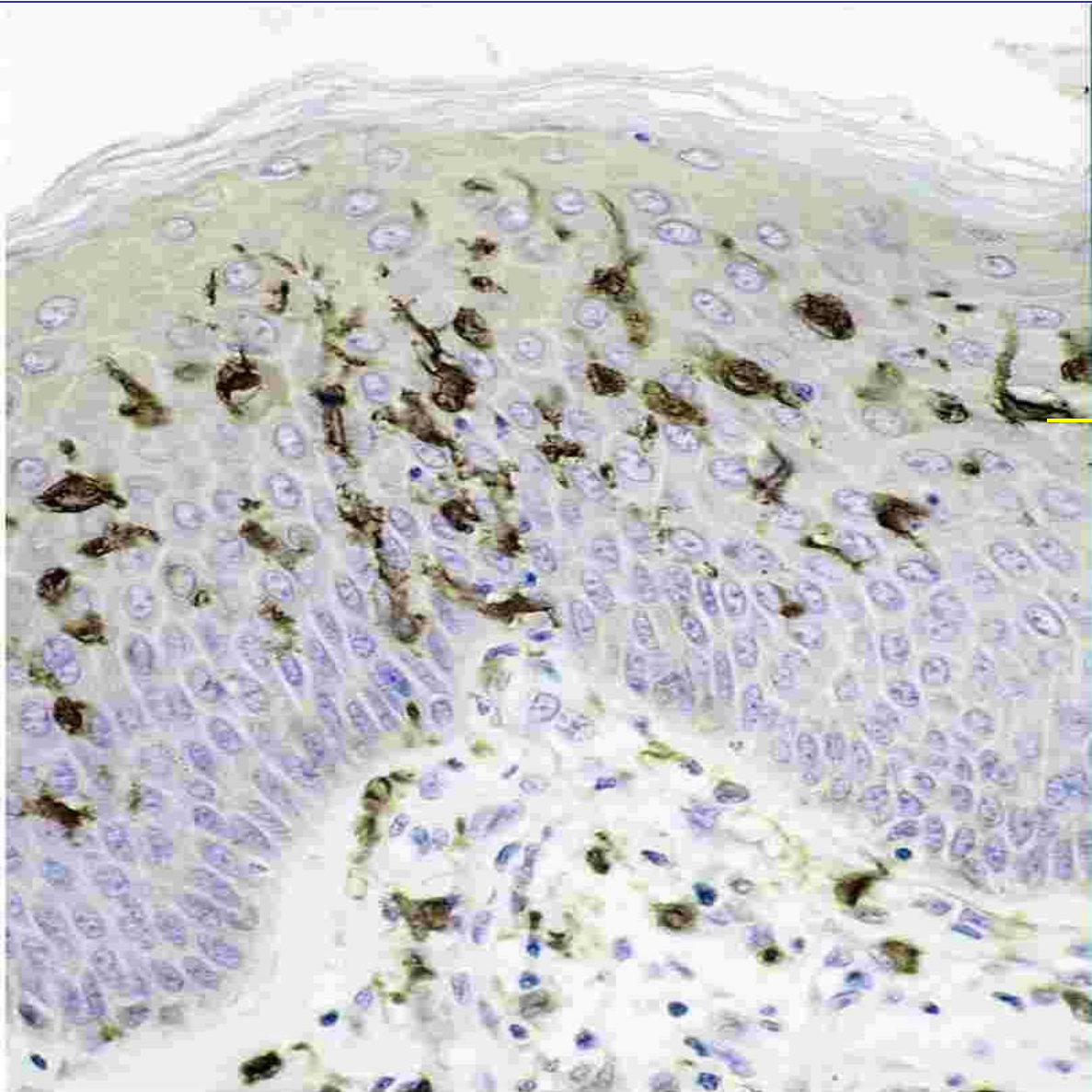
# Melanocytes

- Melanin granules accumulate on the **“sunny side”** of the nucleus of the keratinocytes.
- Melanin granules protect the DNA within the nucleus from being damaged by the ultraviolet radiation from the sun.





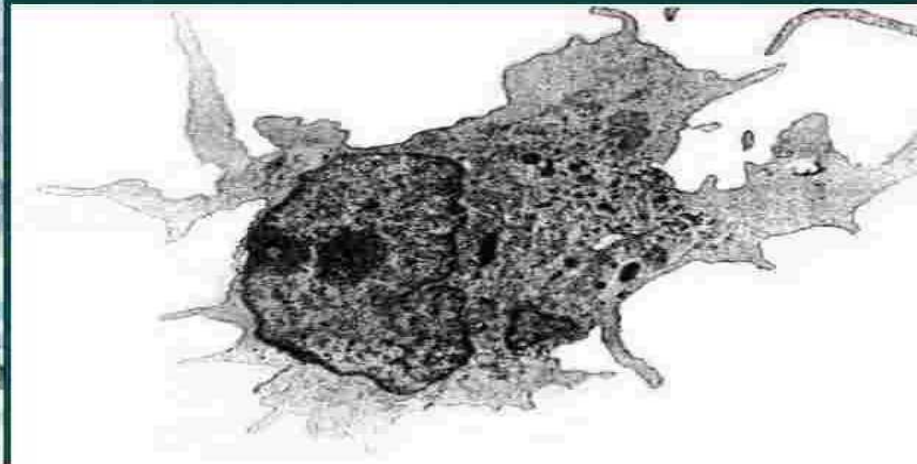
cells that do not contain melanin!

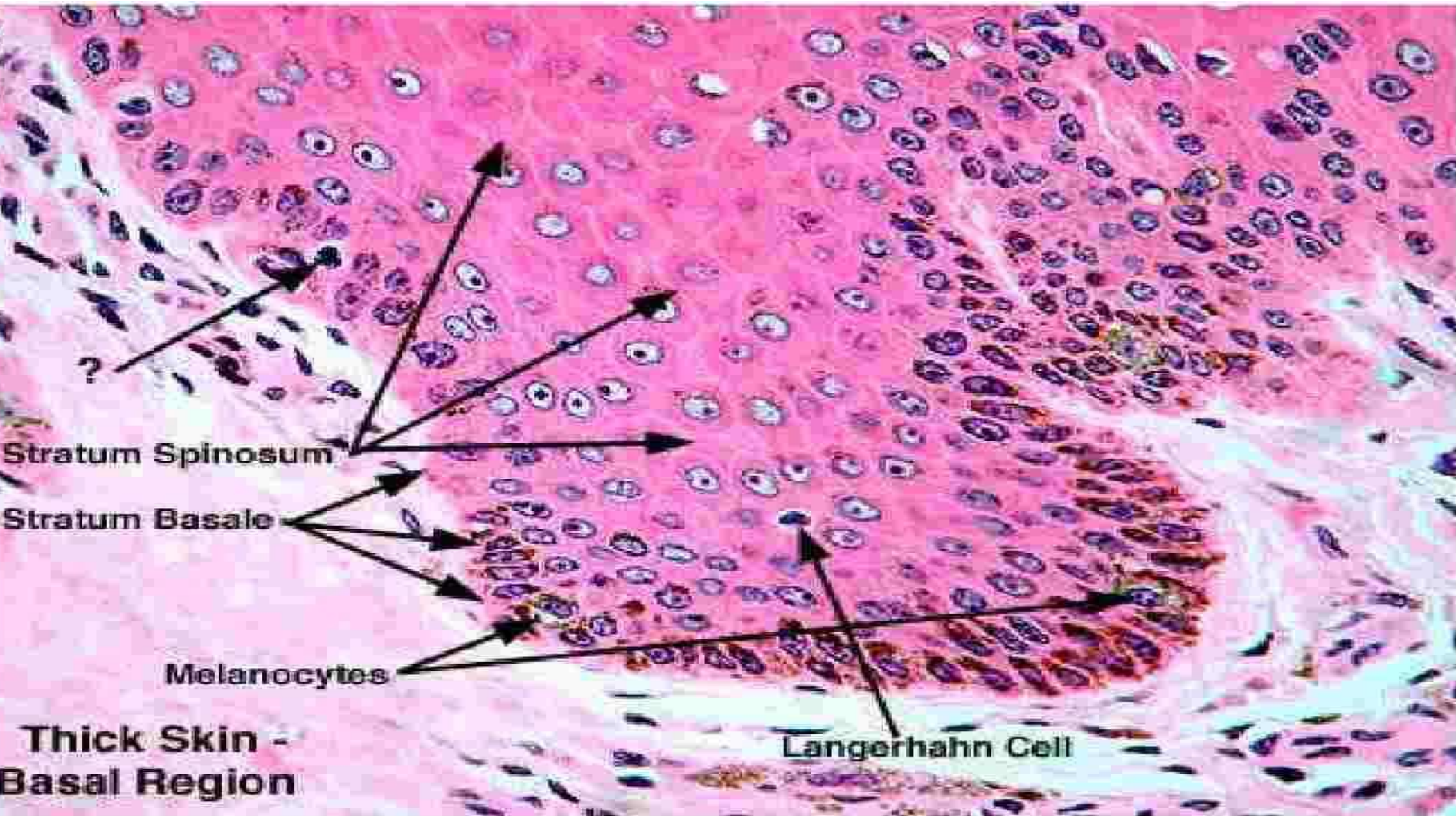


## LANGHERANS CELLS or Epidermal Dendritic Cells

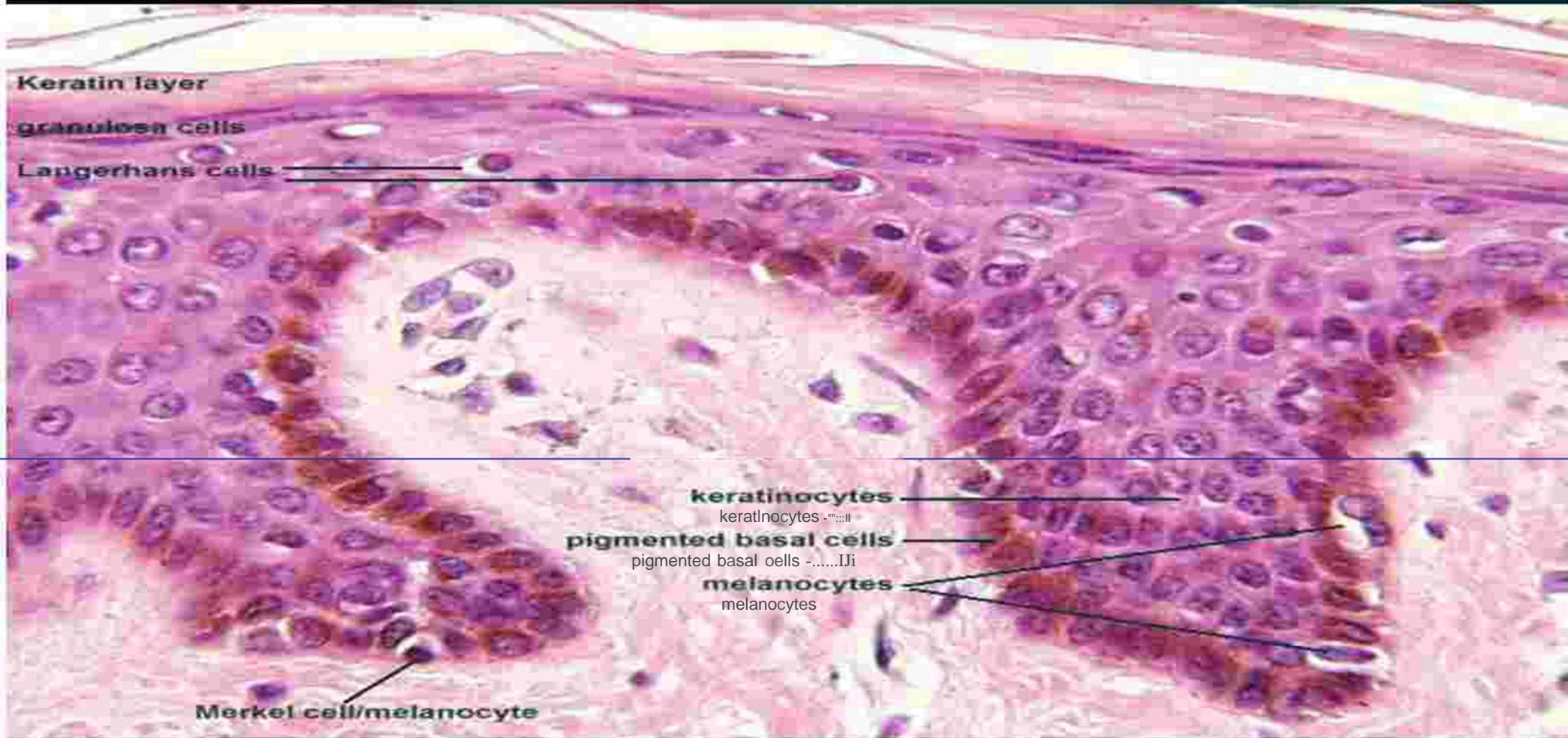
A star-shaped wandering **macrophage** derived from the

**bone marrow** which infiltrate the  
epidermal layers and serve the immune functions of  
phagocytosis and antigen-presentation.





# The cells of the epidermis

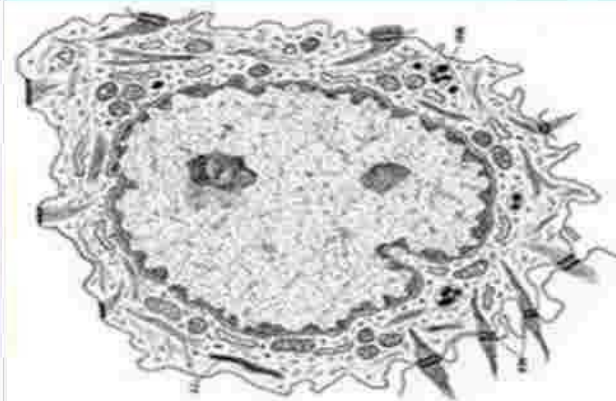


## Merkel cells .

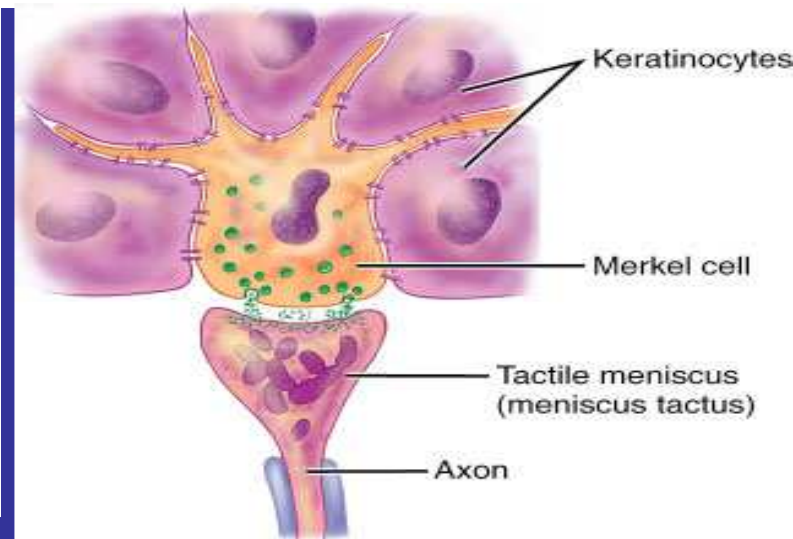
An exteroceptor located in the stratum germinativum of the epidermis;

a small receptor resembling a spiky hemisphere which communicates with the disk-like sensory terminal of a neuron;

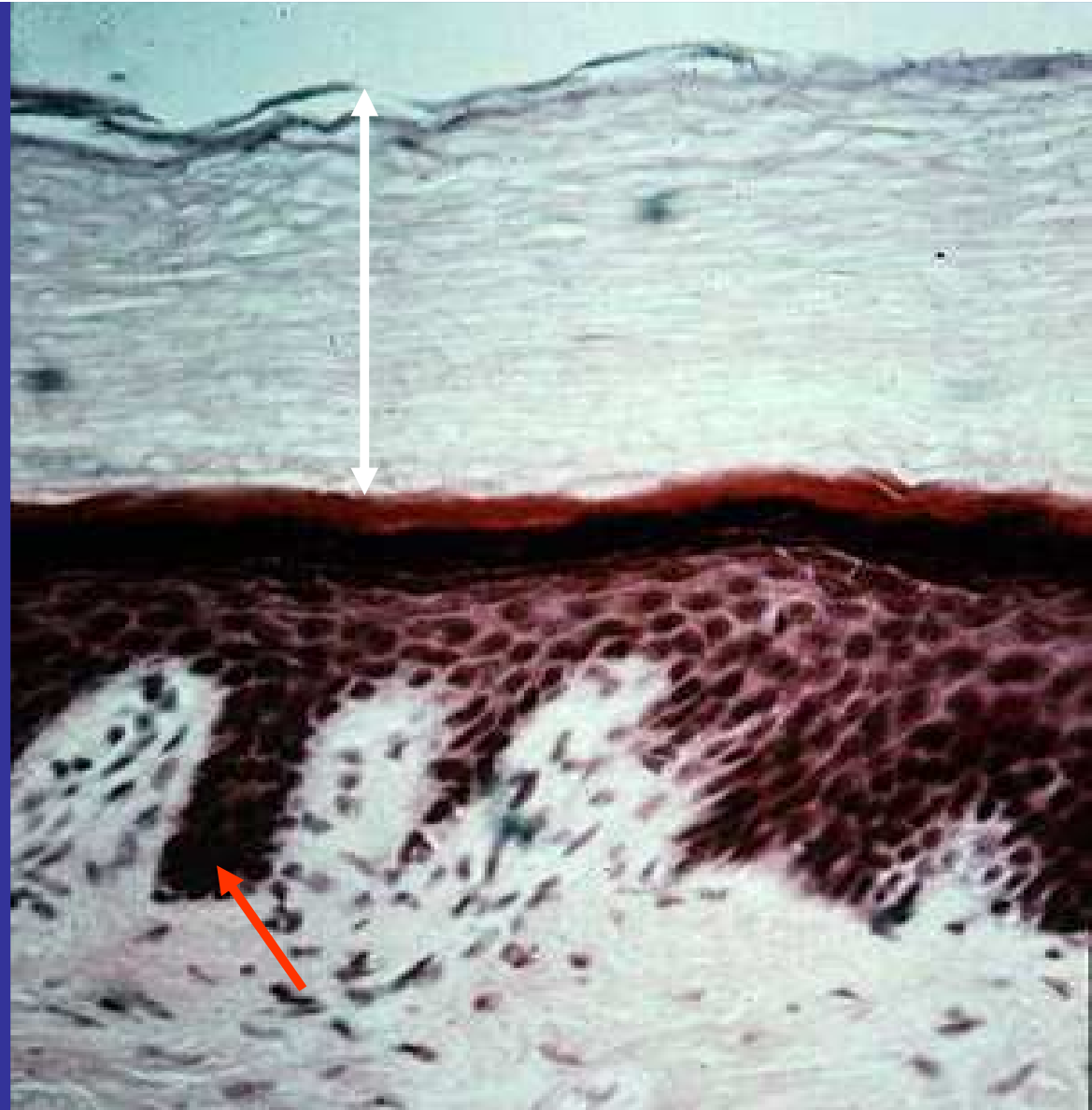
the combined structure is termed a Merkel or tactile disc; they are receptors for light or discriminative touch



Skin touch dome with Merkel cells and innervating neurites



Identify the 2 layers indicated by the arrows



# Skin Color

- **Due to 3 pigments:**
  1. **Melanin**
  2. **Carotene**
  3. **Hemoglobin**
- **Of these, only melanin is made in the skin.**

## Dermal blood supply

- 1- Decreased blood flow can cause one to become pale.  
» Cyanosis, a bluing coloration, is the result of long term decreased blood flow causing hypoxia in the area.
- 2- Increased blood flow will cause a pink “blush”.

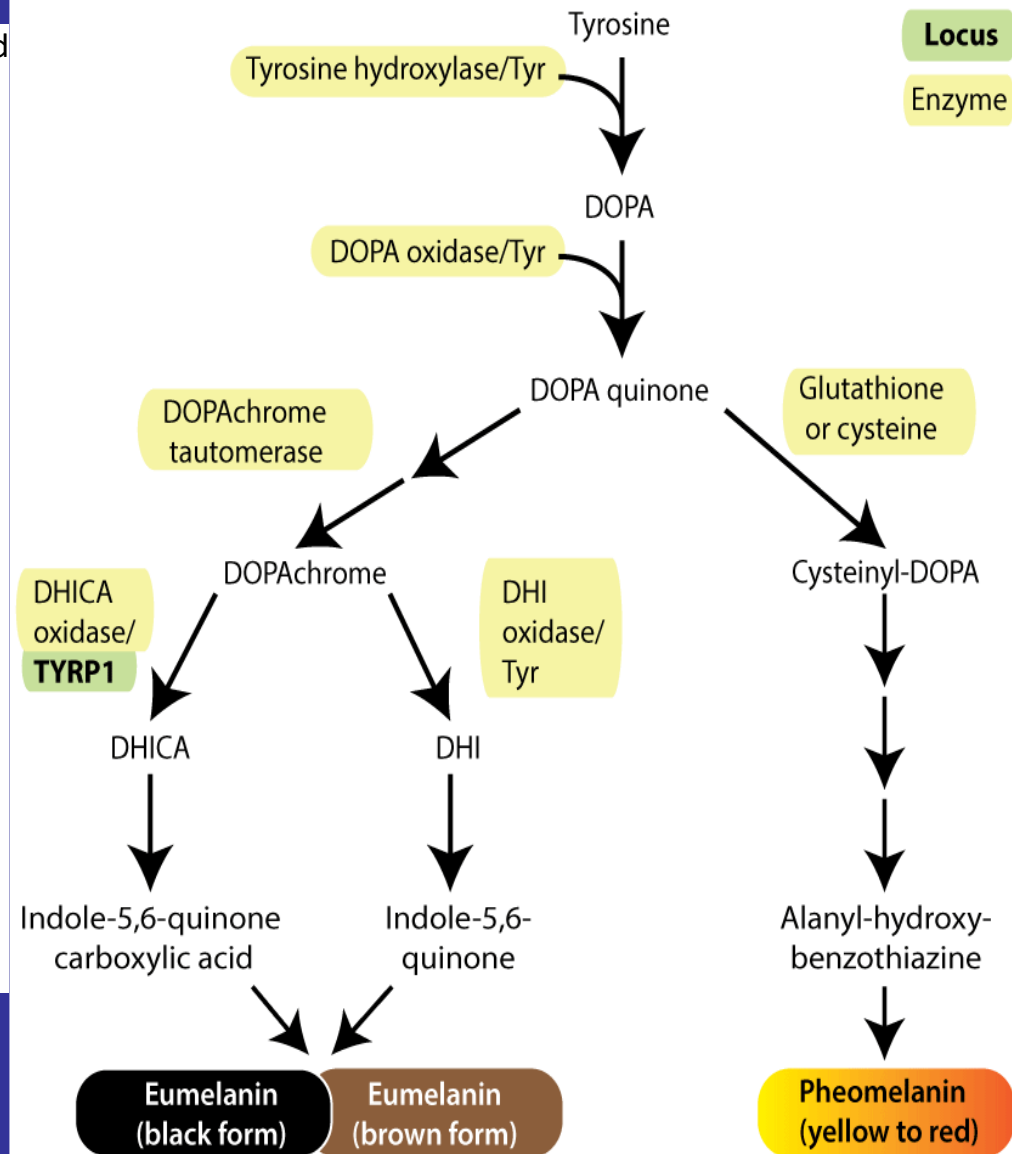
- Melanin:
  - Polymer of tyrosine amino acids. Its synthesis is catalyzed by an enzyme called **tyrosinase**. **Albinos lack this enzyme.**
  - Ranges in color from yellow to reddish brown to black.
  - All people have the same # of melanocytes, individual variations in skin color are due to how much and what type of melanin is made.
  - Freckles and moles are local accumulations of melanin.

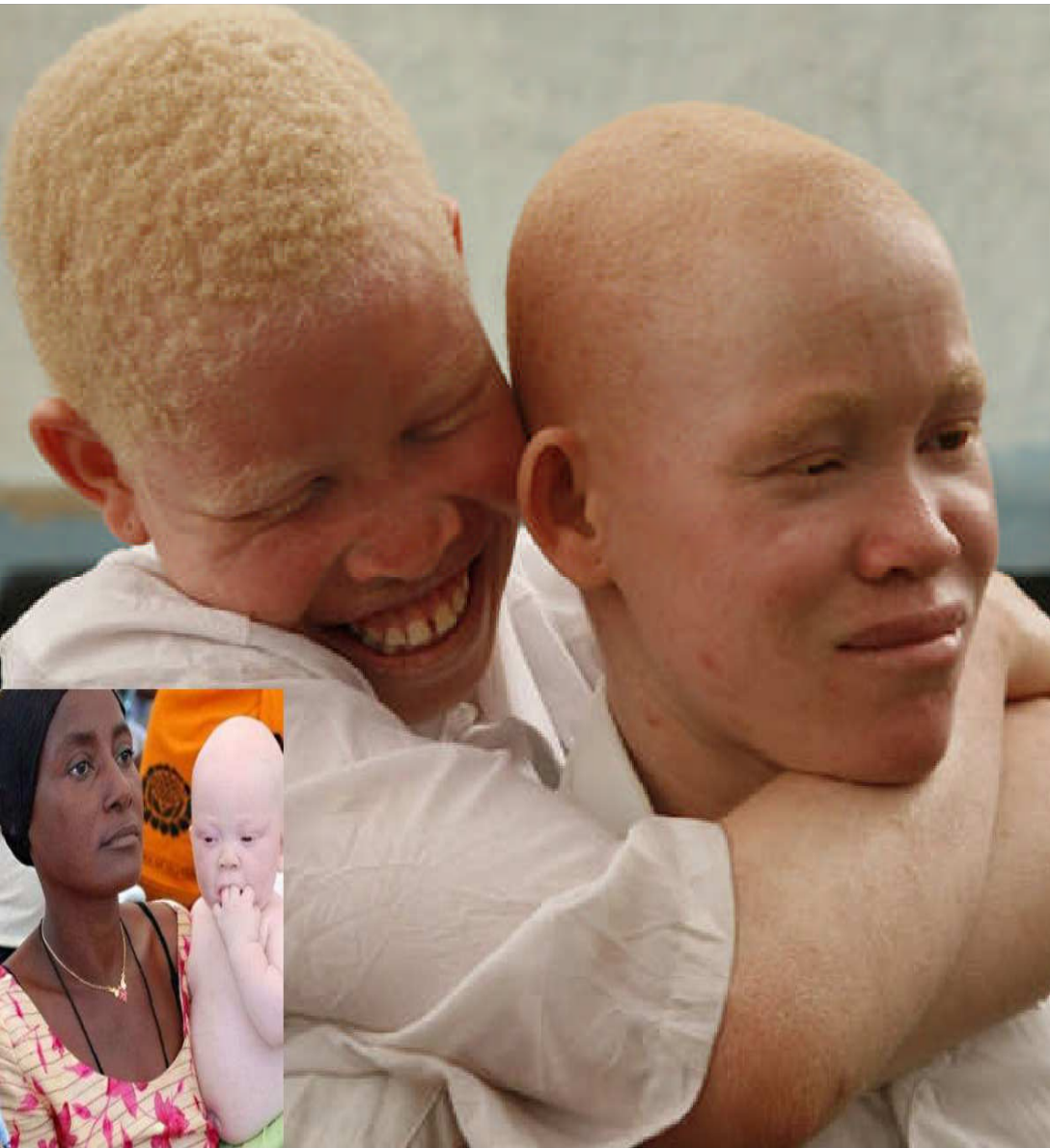

Skin pigmentation is genetically determined, though in lighter-skinned people pigmentary changes commonly result from :

- endocrine disturbances (such as excess ACTH)
- pregnancy (including changes in the color of the areola of the nipples)
- exposure to ultraviolet light ("suntan").

The **tanning process** following exposure to sunlight is a protective measure to reduce the damage of ultraviolet light to the underlying tissues. Following initial inflammatory changes, there is increased synthesis of tyrosinase and melanin. Ultraviolet light is a major cause of age-related skin changes, including skin thickening, hardening and increased wrinkling.





## **Skin Color**

### **A. Melanin - pigment made in melanocytes**

- 1. in basale and spinosum layers of epidermis
- 2. melanoblasts -> melanocytes in stratum basale
- 3. darkness due to melanin quantity (not cell #)
- 4. albinism - inability to produce melanin
- 5. vitiligo - patchy loss of melanocytes
- 6. freckles - patchy concentration of melanocytes
- 7. UV light causes: tyrosine --> melanin production

### **B. Carotene**

- 1. in stratum corneum and fatty areas of dermis
- 2. melanin + carotene = yellowish color

### **C. Other Colors**


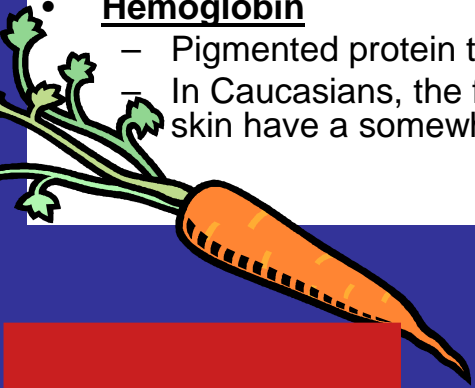
- 1. pink (Caucasian) - lack of pigment, capillaries
- 2. blue (cyanosis) - lack of oxygen in blood
- 3. yellow (jaundice) - liver disorder, protein release

- Carotene

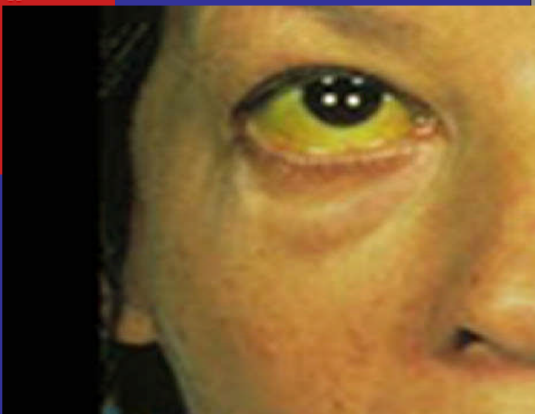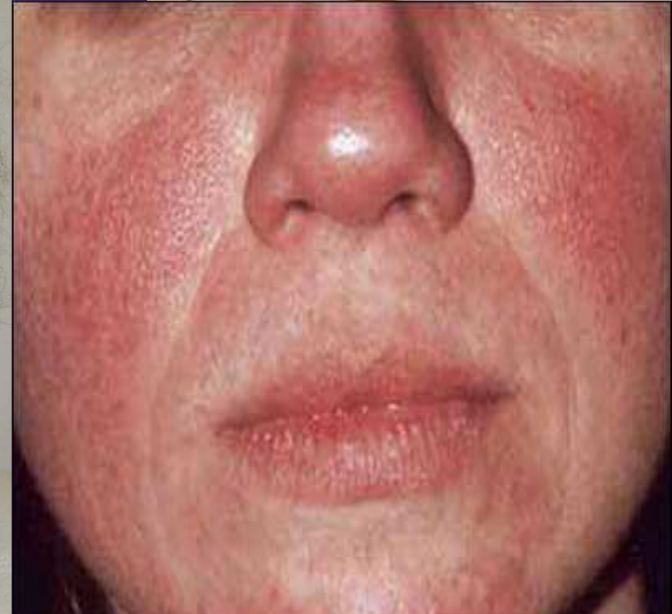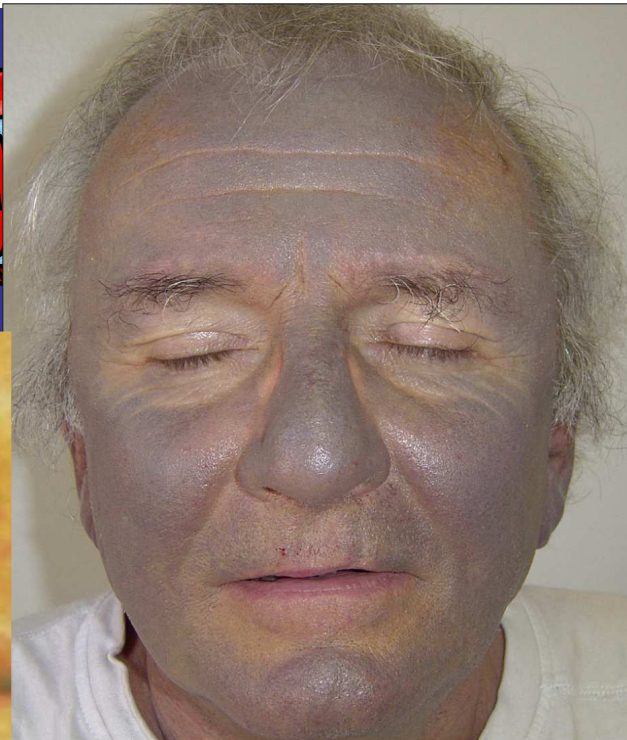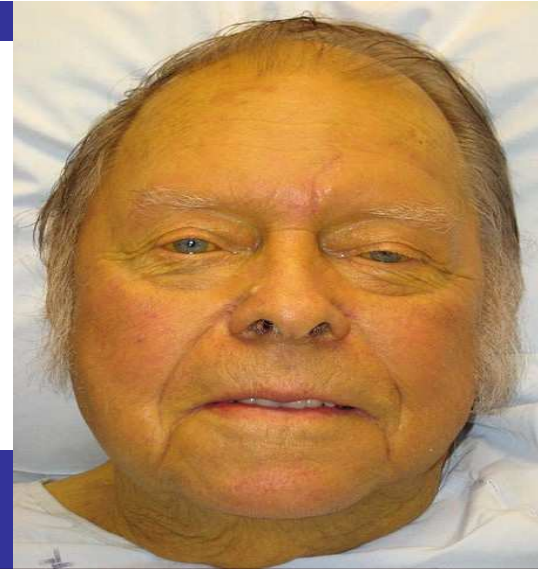- Yellow to orange pigment found in plant products such as carrots.
- When large amounts are eaten, it can be deposited in the stratum corneum of thick skin.

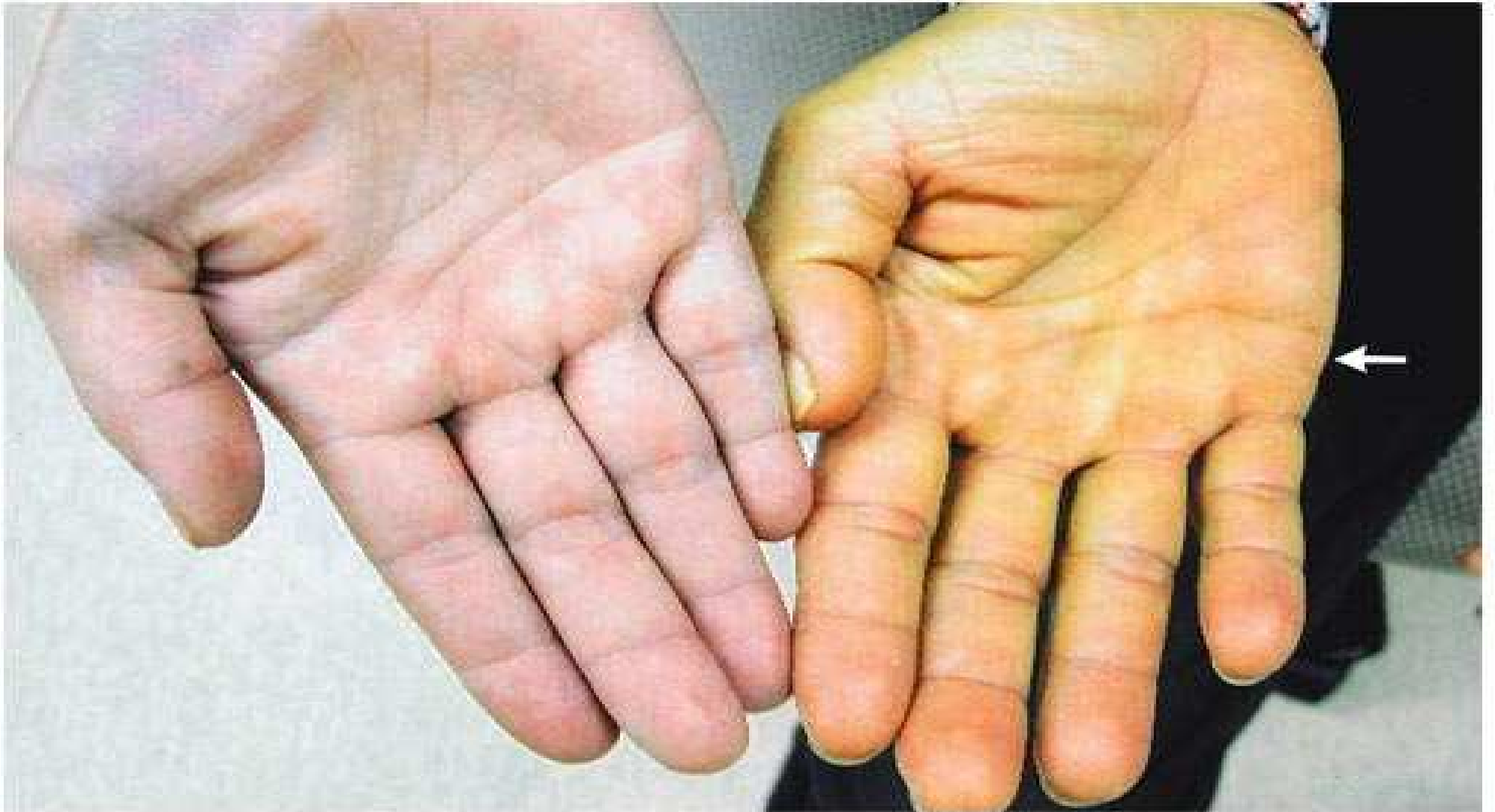
- Hemoglobin

- Pigmented protein that transports oxygen within the blood.
- In Caucasians, the fair skin allows **the crimson color of oxygenated blood** to make the skin have a somewhat pinkish hue.

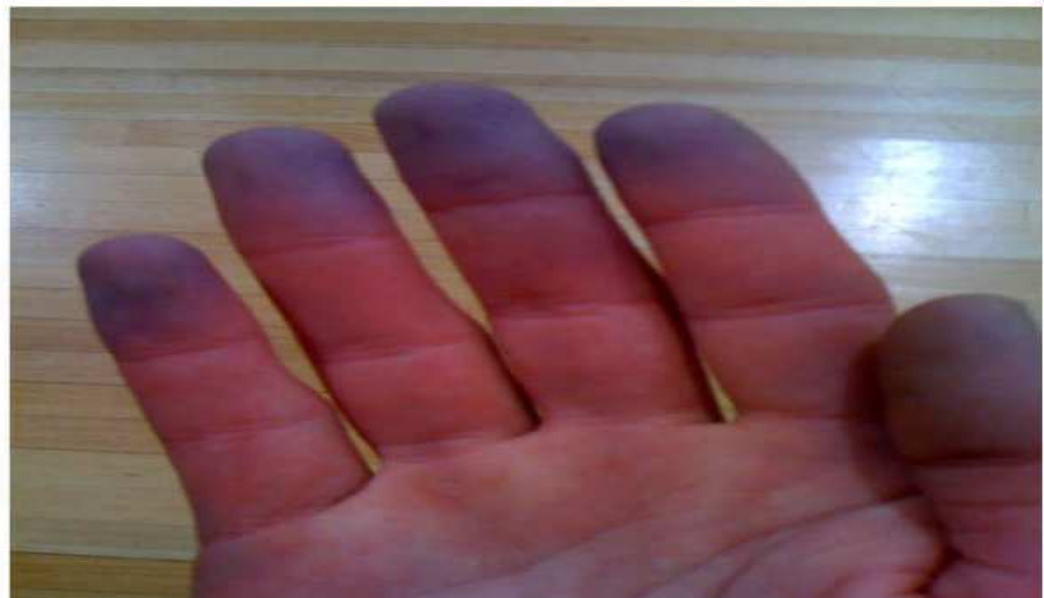
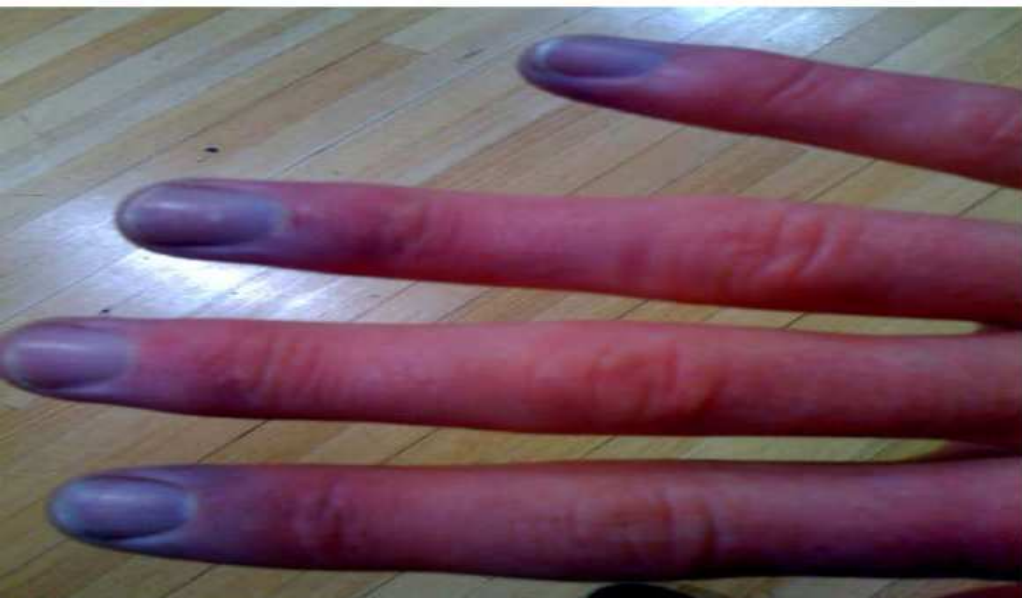
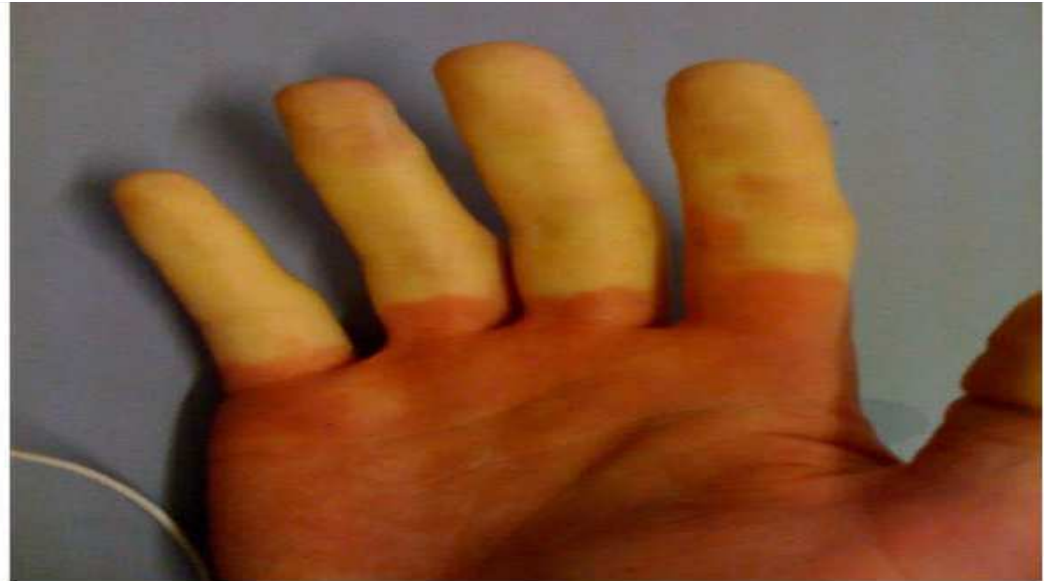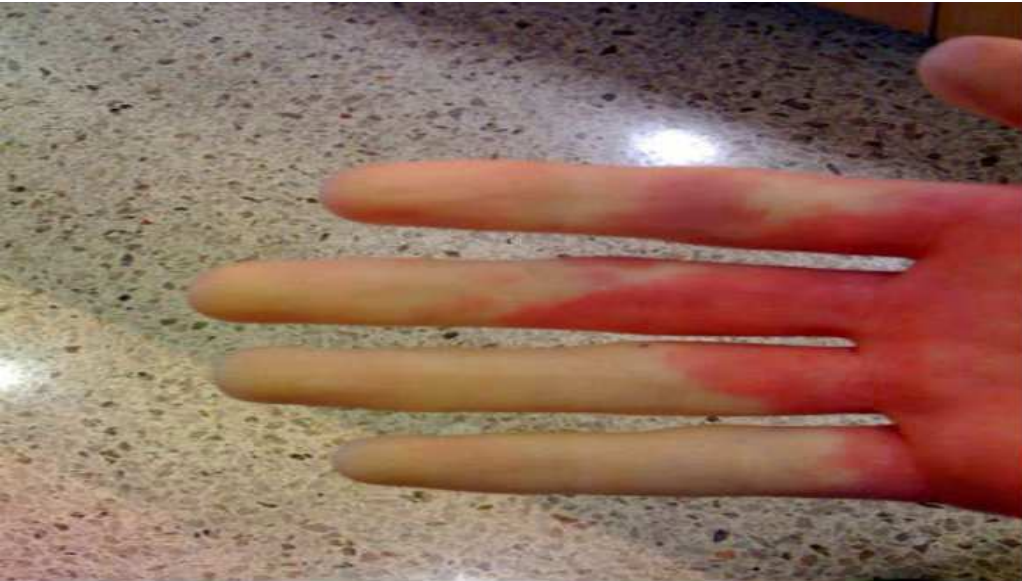Crimson Red



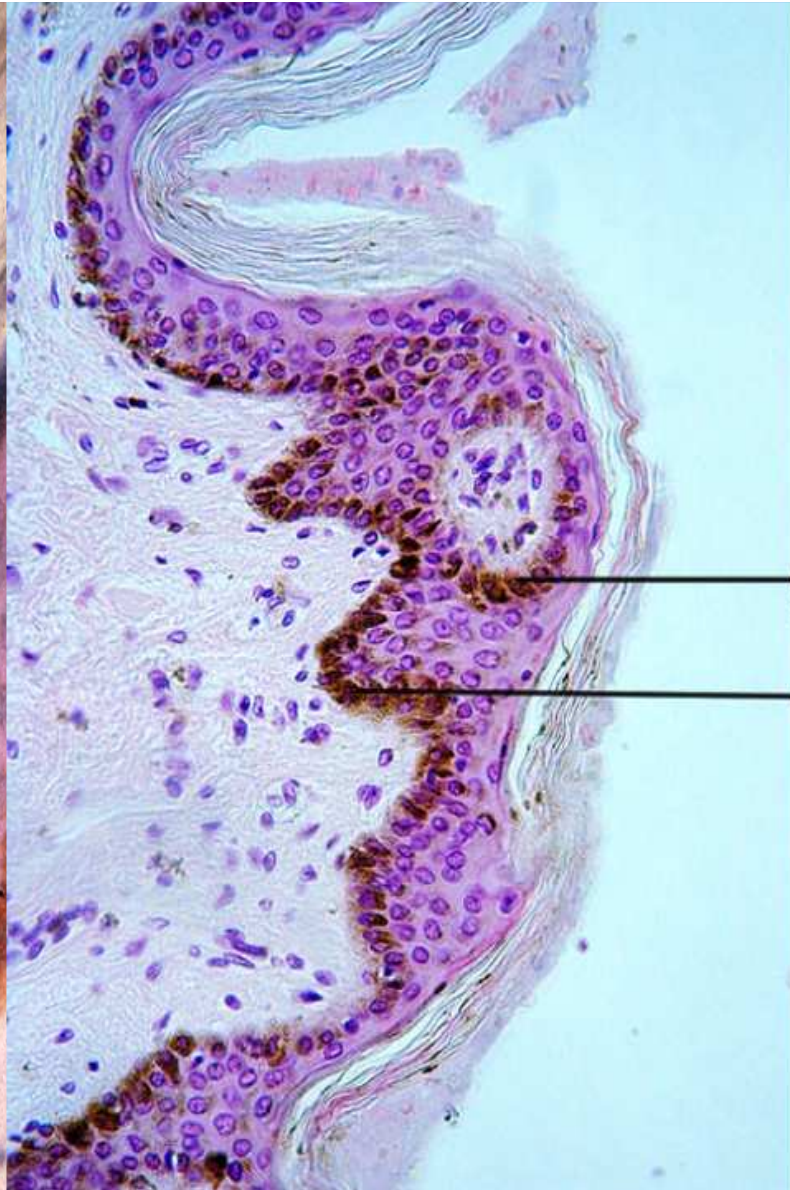
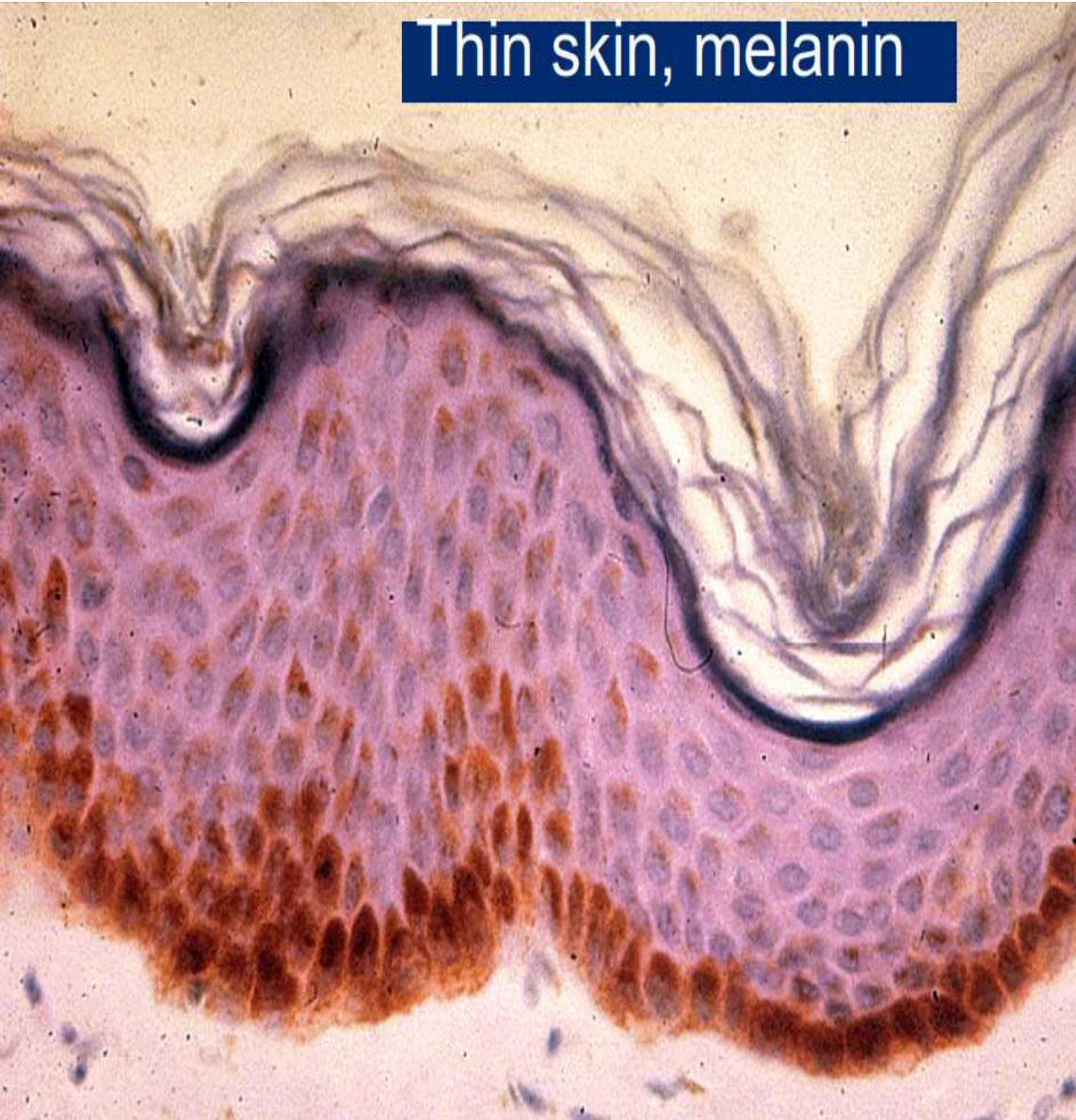
CAROTENE SKIN COLOR





Thin skin, melanin

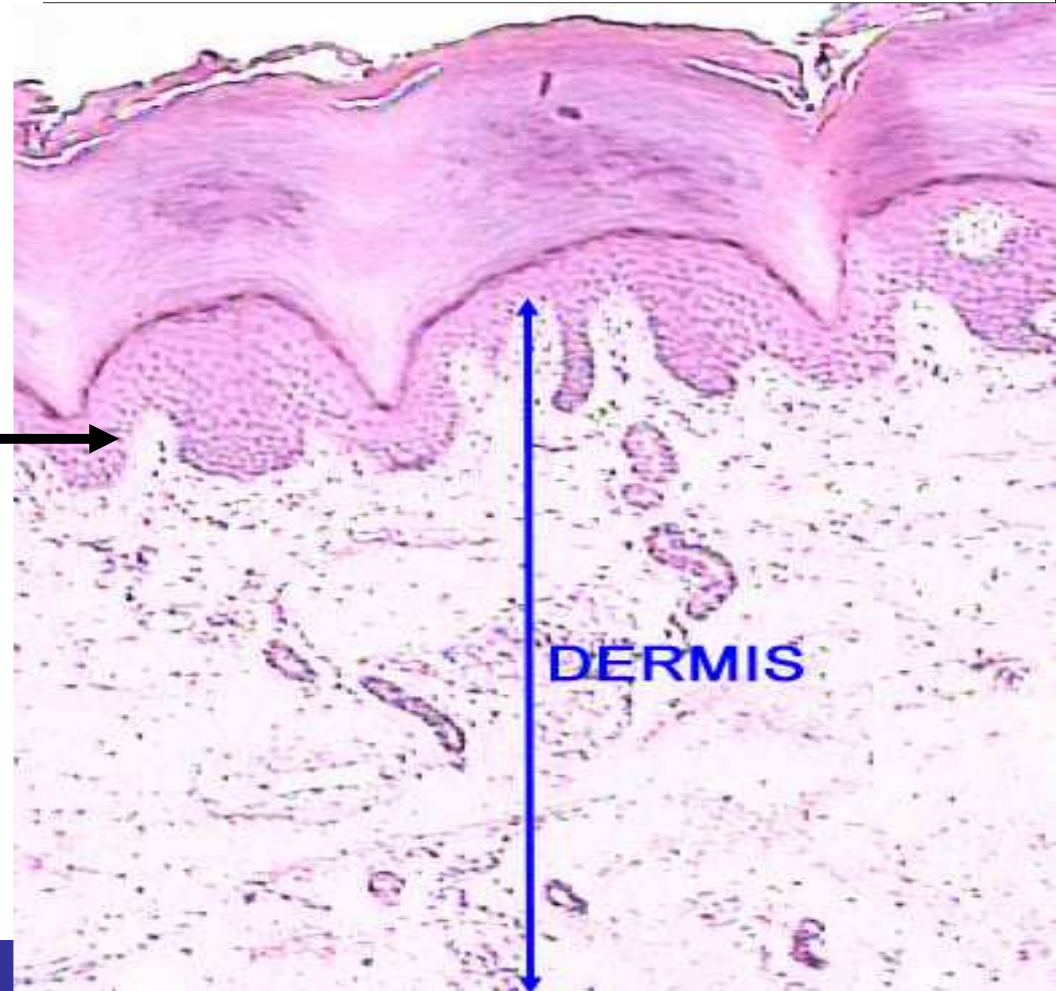


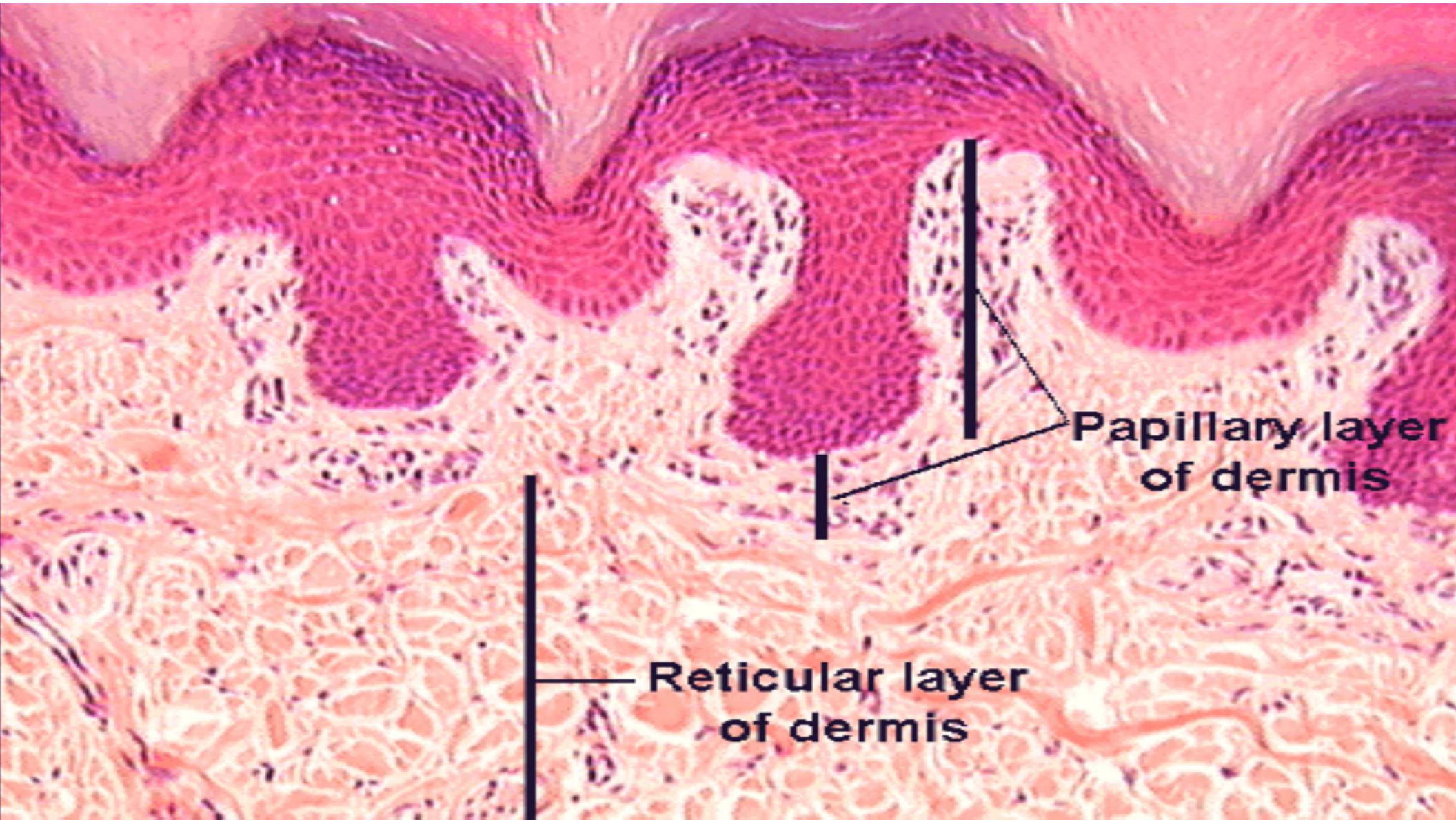
Note the pigment melanin

Melanocyte

- Strong, flexible fibrous connective tissue.
- Divided into papillary dermis and reticular dermis.
- **Papillary dermis** is the upper 1/5 of the dermis and **consists of loose (areolar) CT**.
  - Provides an arena for immune cells to fight invaders.
  - Projects upward (as dermal papillae) to interdigitate and form a strong connection with the epidermis.
  - Heavily invested with blood vessels – they constrict in cold weather and dilate in warm weather. Why?
  - Also contains multiple sensory receptors.

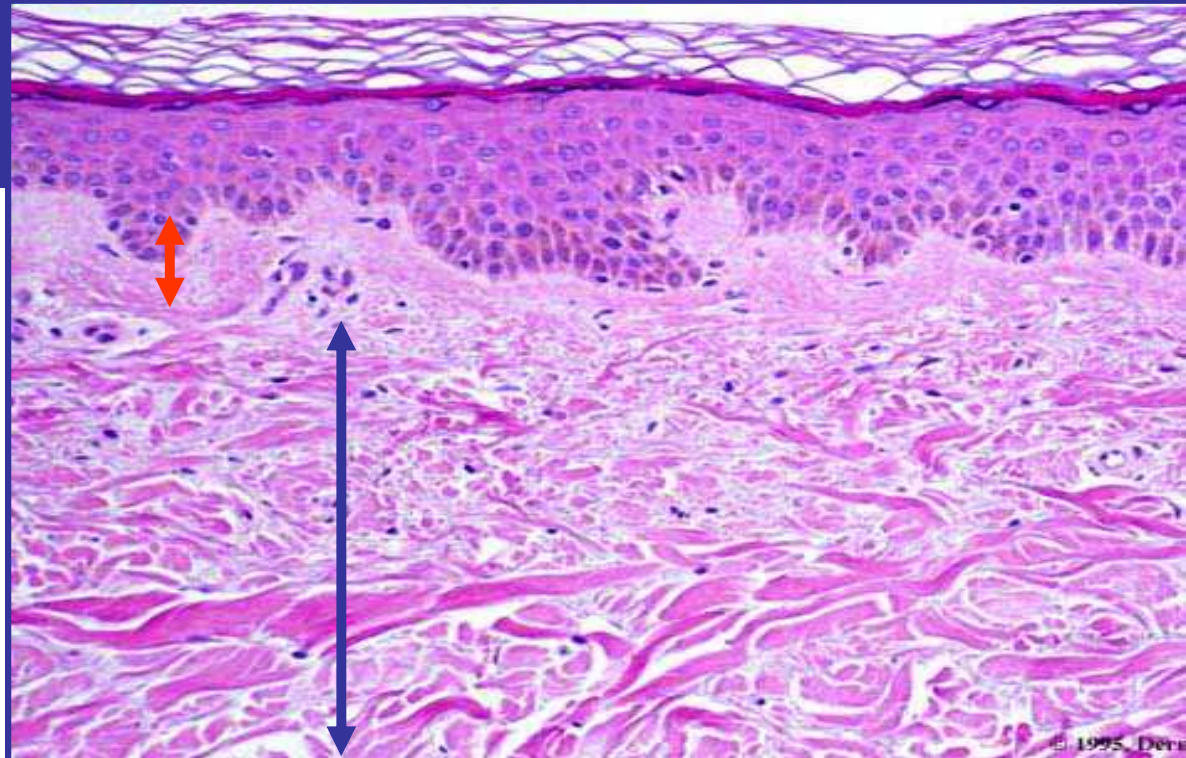
# Dermis





# Dermis

- **Reticular dermis** is lower 4/5 and consists of dense irregular connective tissue.
  - The prominent, horizontally running collagenous fibers give the skin strength and resiliency.
  - **Elastin gives the skin the ability to stretch and recoil.**
- The majority of the appendages of the skin are contained within the dermis.



Red arrow indicates the papillary dermis and blue arrow indicates the reticular dermis

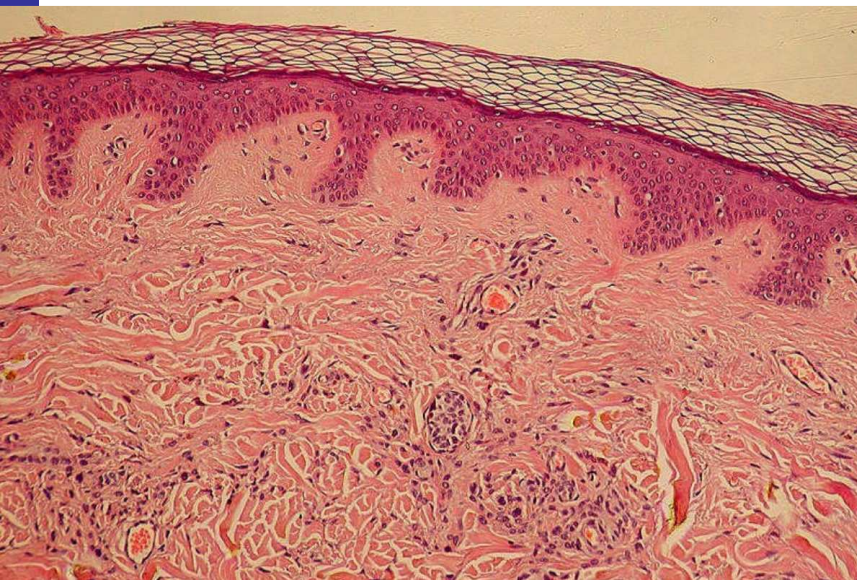
Both the papillary and the reticular layers have abundant **elastic fibers**, responsible for the elasticity and flexibility of the skin.

- With aging the collagen fibers thicken and crosslink and the elastic fibers lose much of their elasticity, causing increased wrinkling of the skin.

- The process of **age-related wrinkling is increased** in cigarette smokers and in people with excessive ultraviolet light exposure.

Sun exposure is a major factor in age-related damage to skin.

- The dermis of the face is the site of insertion of the **muscles of facial expression**.



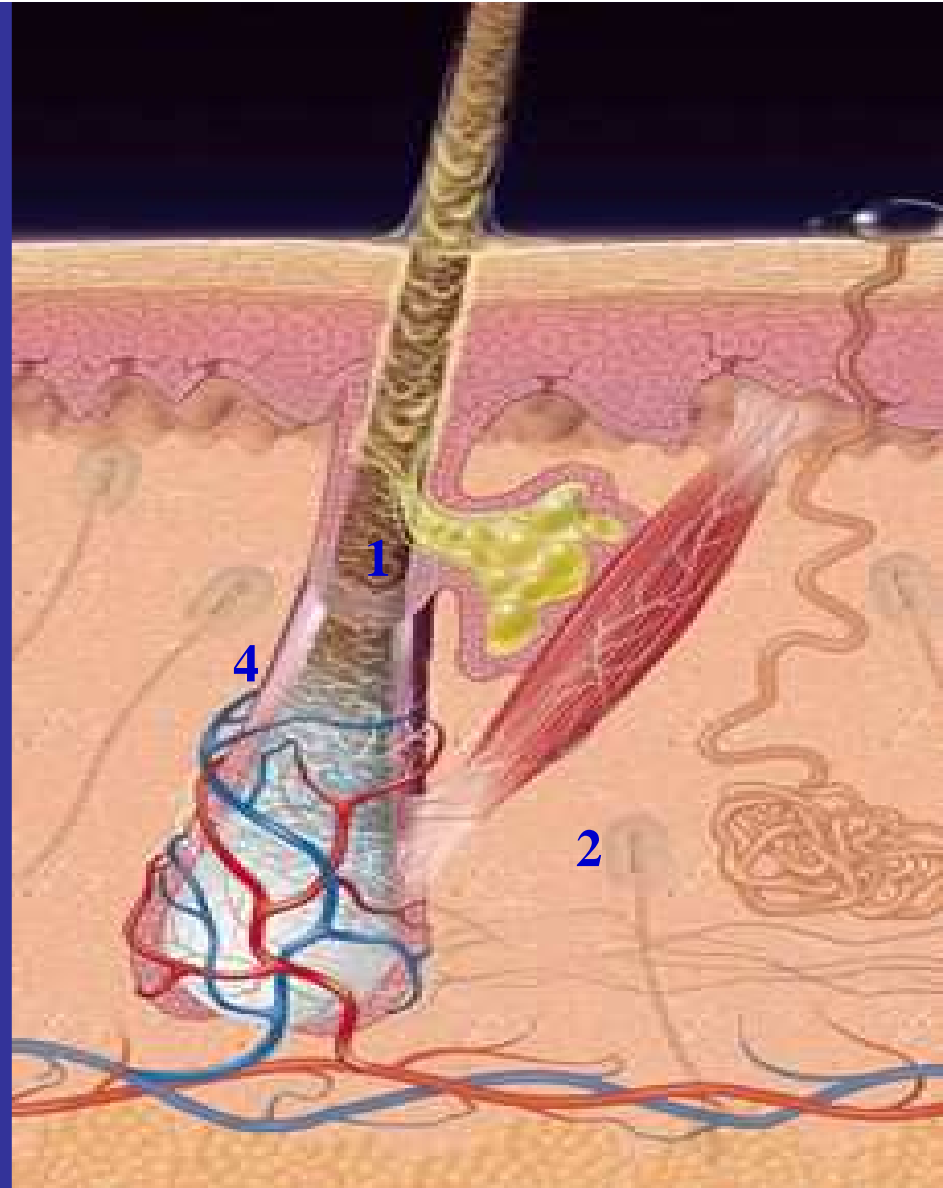


# Appendages of the Skin



# Appendages of the Skin

1. Sebaceous glands
2. Sudoriferous glands
3. Ceruminous glands
4. Hair
5. Nails



## EXOCRINE GLANDS

- Assist in thermoregulation
- Excrete wastes
- Lubricate epidermis

### SEBACEOUS GLANDS

- Secrete oily lipid (sebum) that coats hair shaft and epidermis
- Provide lubrication and antibacterial action

#### TYPICAL SEBACEOUS GLANDS

Secrete into hair follicles

#### SEBACEOUS FOLLICLES

Secrete onto skin surface

### SWEAT GLANDS

- Produce watery solution by merocrine secretion
- Flush epidermal surface
- Perform other special functions

#### APOCRINE SWEAT GLANDS

- Limited distribution (axillae, groin, nipples)
- Produce a viscous secretion of complex composition
- Possible function in communication
- Strongly influenced by hormones

##### CERUMINOUS GLANDS

Secrete waxy cerumen into external ear canal

##### MAMMARY GLANDS

Apocrine glands specialized for milk production

#### MEROCRINE SWEAT GLANDS

- Widespread
- Produce thin secretions, mostly water
- Merocrine secretion mechanism
- Controlled primarily by nervous system
- Important in thermoregulation and excretion
- Some antibacterial action

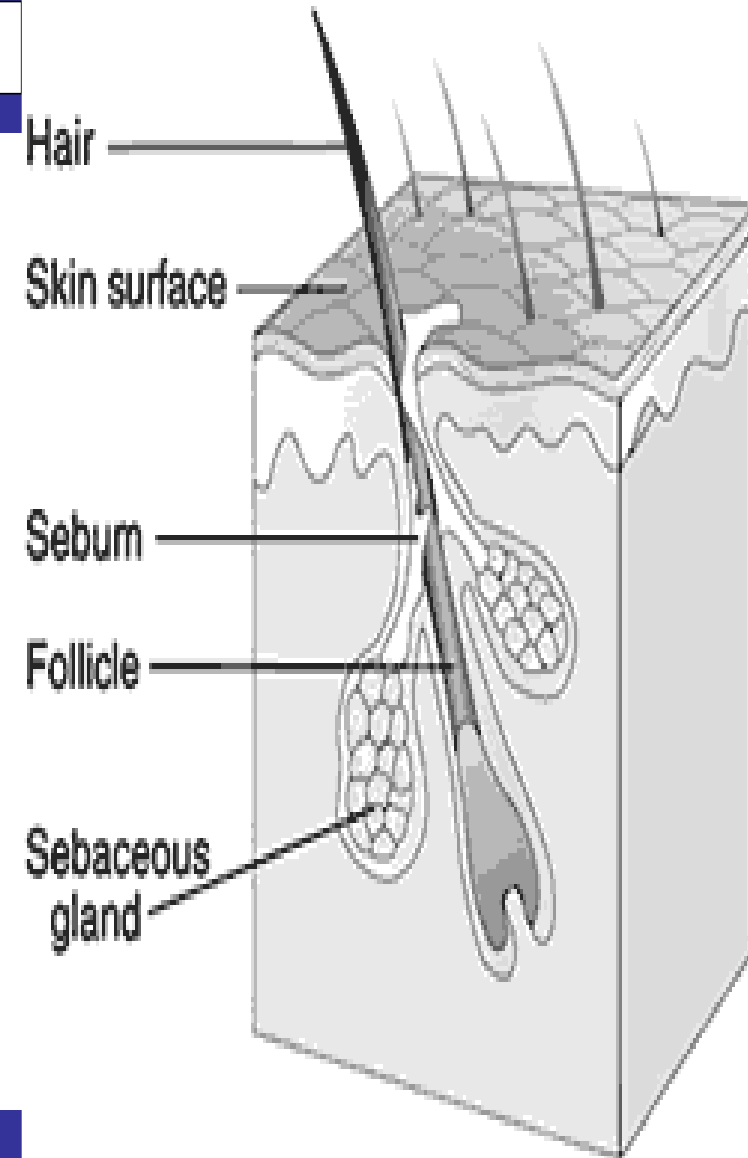
# Cutaneous glands include:

- **Cutaneous glands include:**
- **Sudoriferous glands** - or sweat glands
- **Sebaceous glands** - oil-producing glands
- **Ceruminous glands** - glands of the ear canal that produce cerumen (earwax)
- **Mammary glands** - milk-producing glands located in the breasts.



# Sebaceous Glands

- **Simple alveolar glands** found everywhere **except palms of the hands and soles of the feet.**
- **Secrete an oily, lipid-rich secretion called sebum.**
  - **Lanolin is actually sheep sebum**
- Sebum is typically secreted into a hair follicle or occasionally onto the body surface.
- Sebum softens and lubricates the skin.
- It also decreases the skin's permeability to water and is quite bactericidal.
  
- **In the eyelids, meibomian sebaceous glands**
  - secrete a special type of sebum into tears.
- There are several related medical conditions, including acne, sebaceous cysts, hyperplasia, sebaceous adenoma and sebaceous gland carcinoma



# Sebaceous Glands

- Sebaceous glands are also found in non-haired areas (**glabrous skin**)

- of eyelids,

- nose,

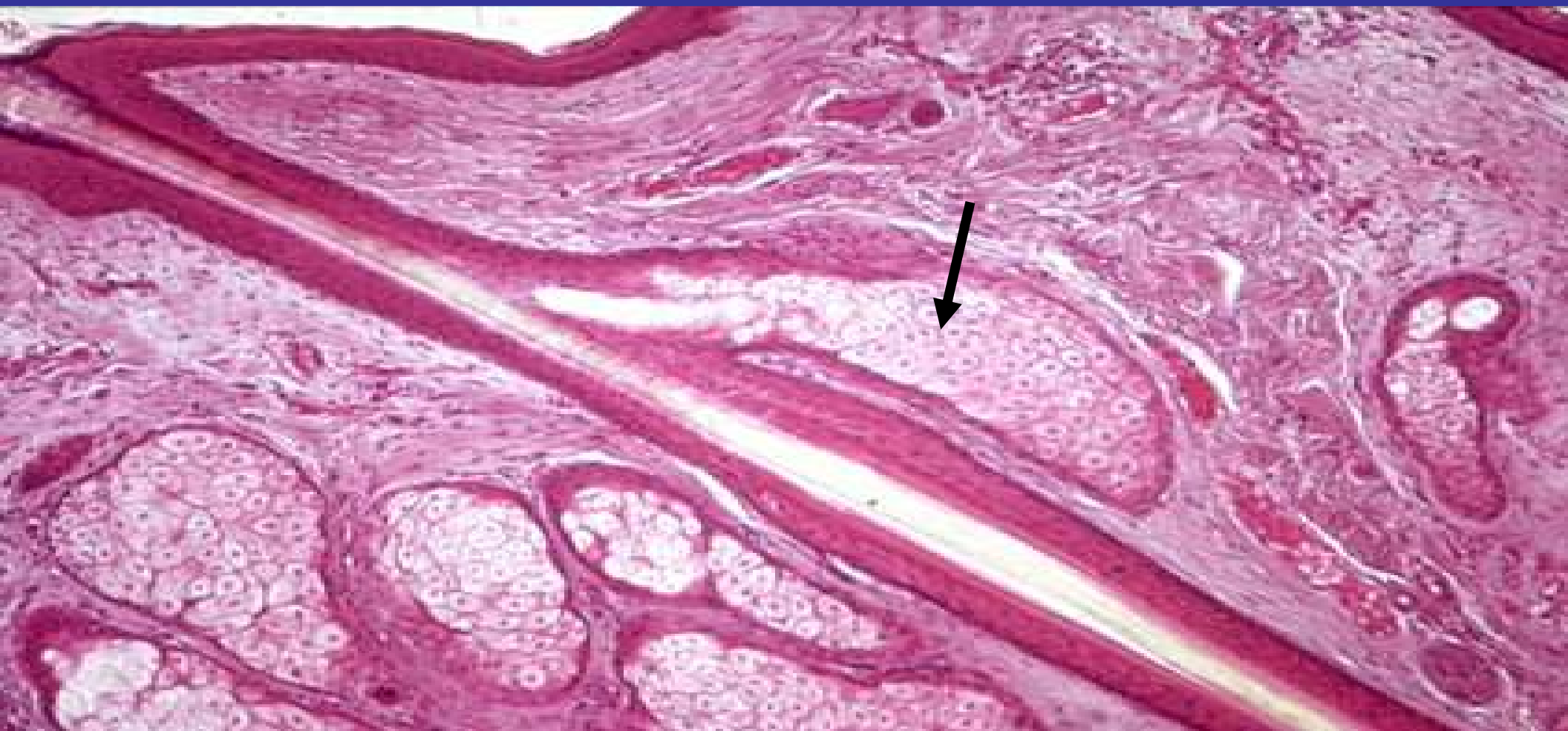
- penis,

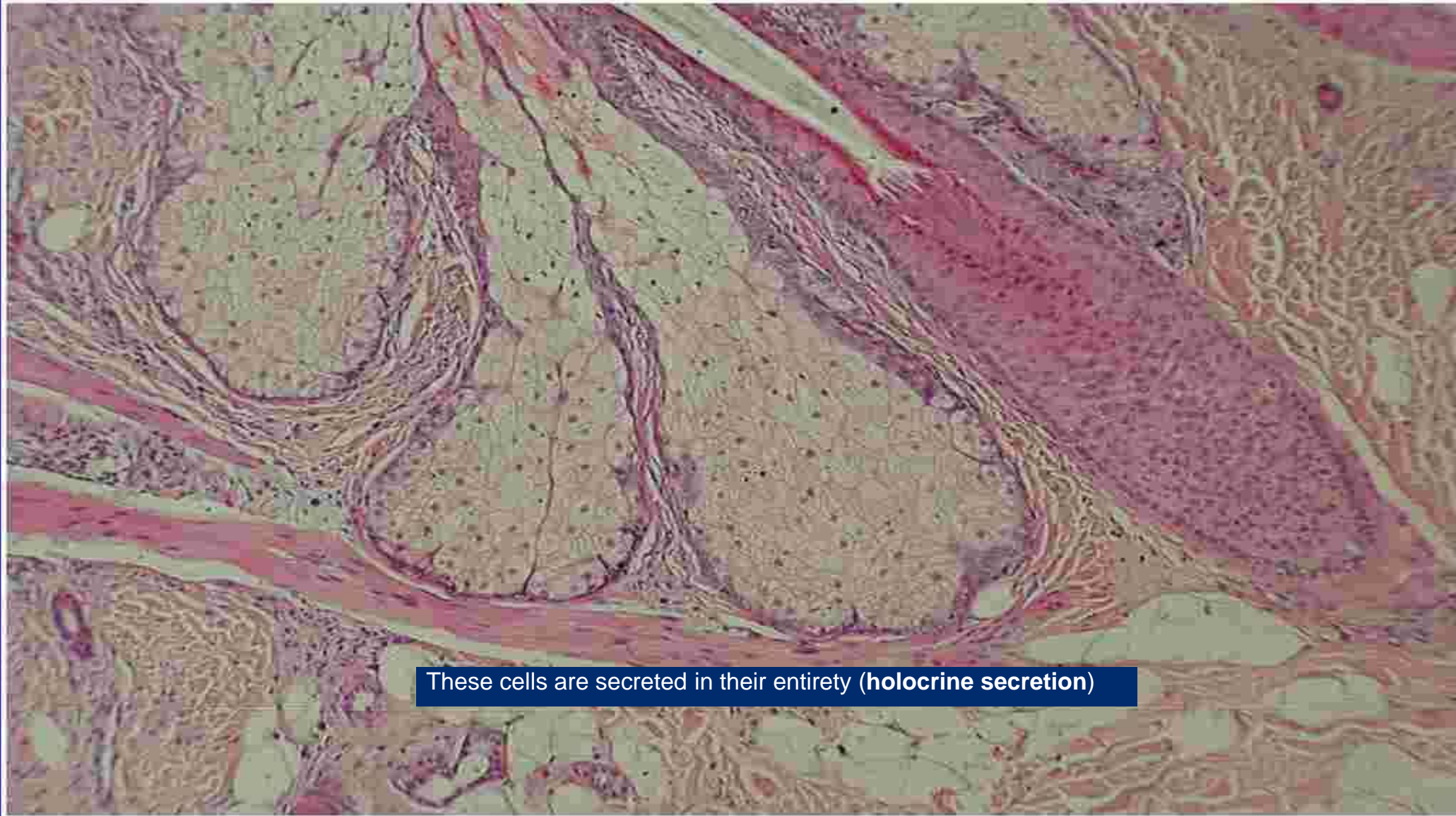- Labia minora

- nipples.

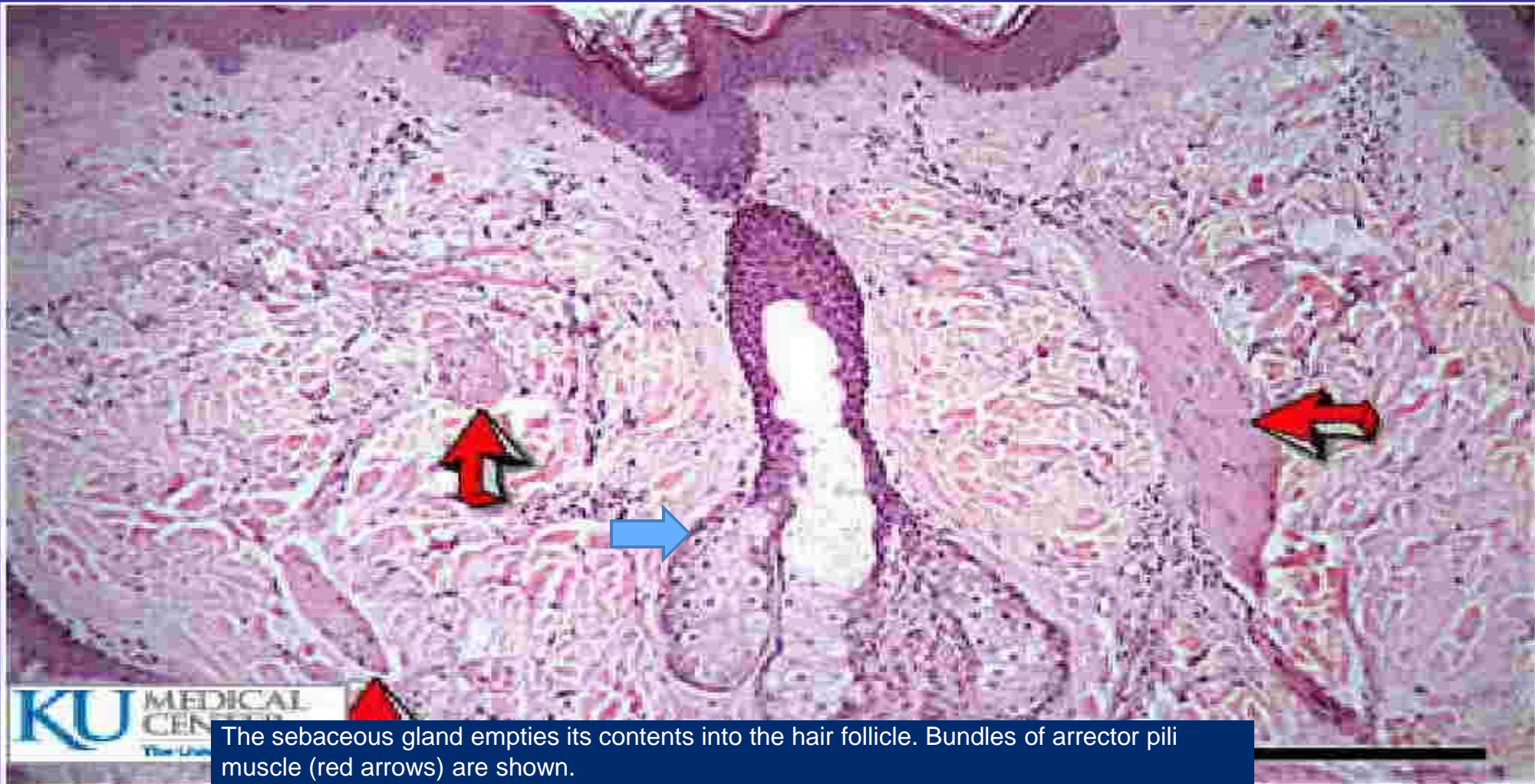
At the rim of the eyelids, meibomian glands are a specialized form of sebaceous gland. They secrete a form of sebum (called meibum) onto the eye, slowing the evaporation of tears.

**The sebaceous gland is indicated by the arrow.  
Note how its duct is unbranched and how it empties into a hair follicle.**

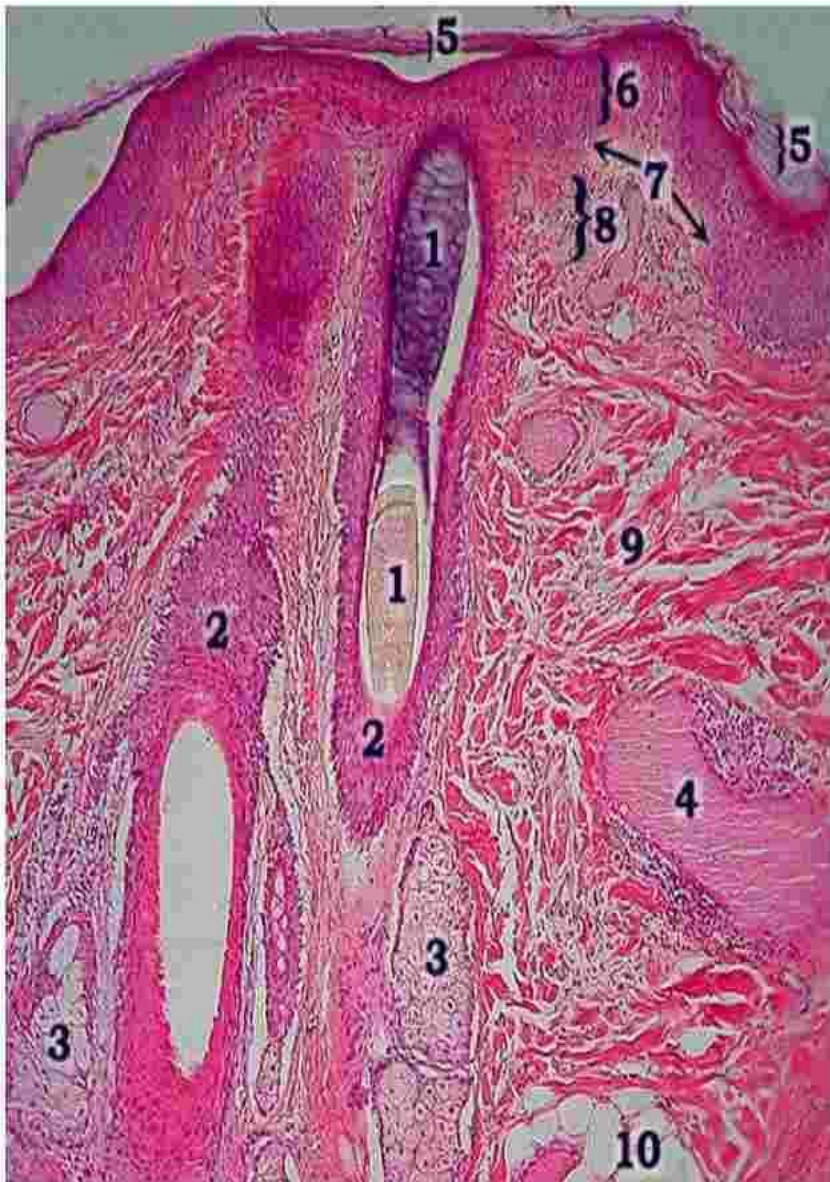




These cells are secreted in their entirety (**holocrine secretion**)

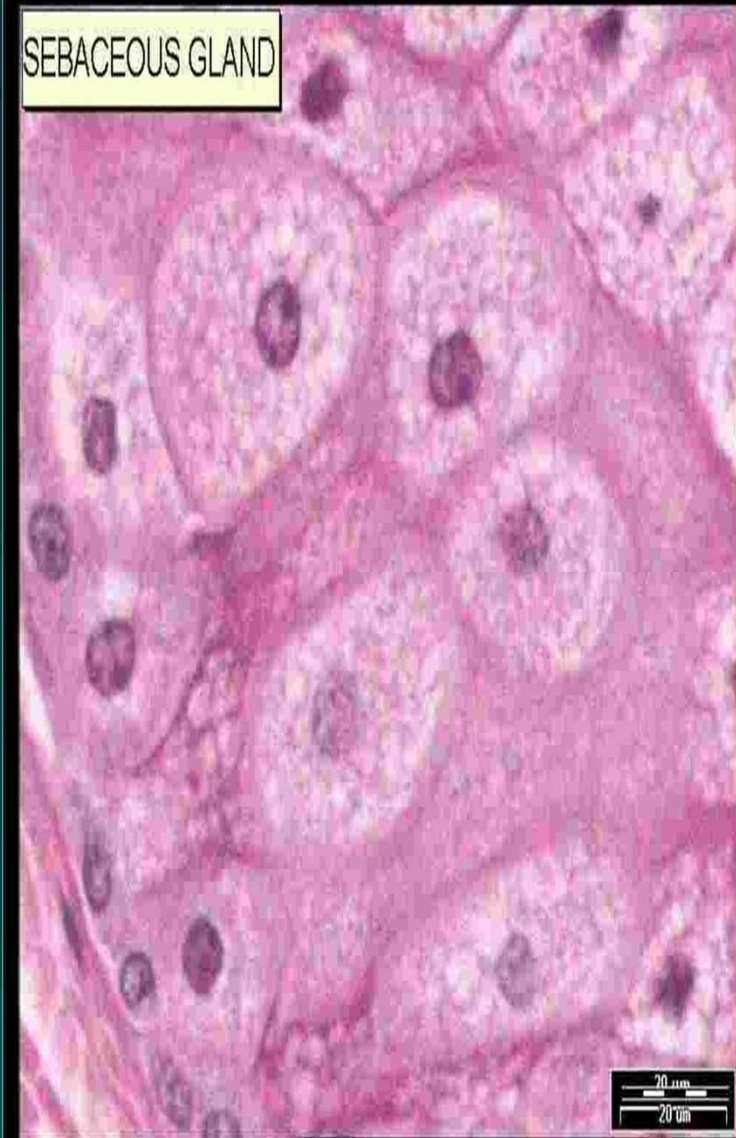


The sebaceous gland empties its contents into the hair follicle. Bundles of arrector pili muscle (red arrows) are shown.

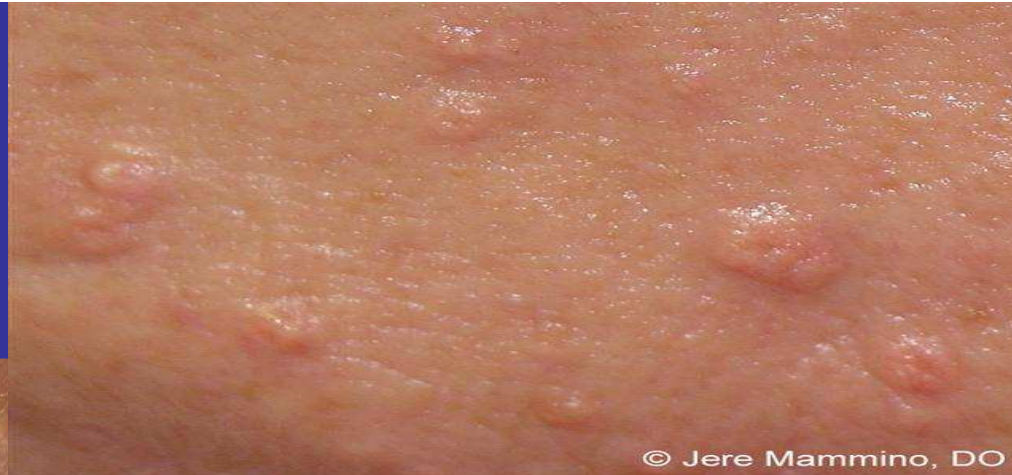
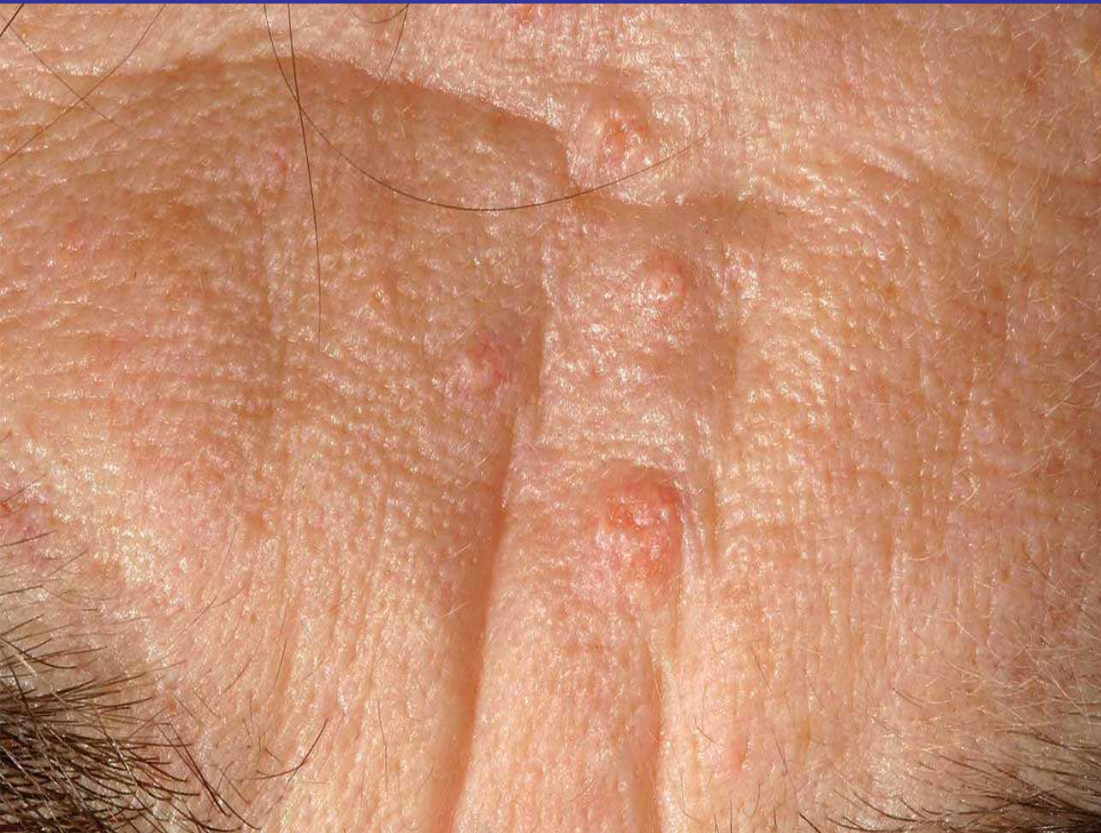
## Scalp with Hair (with sebaceous glands)

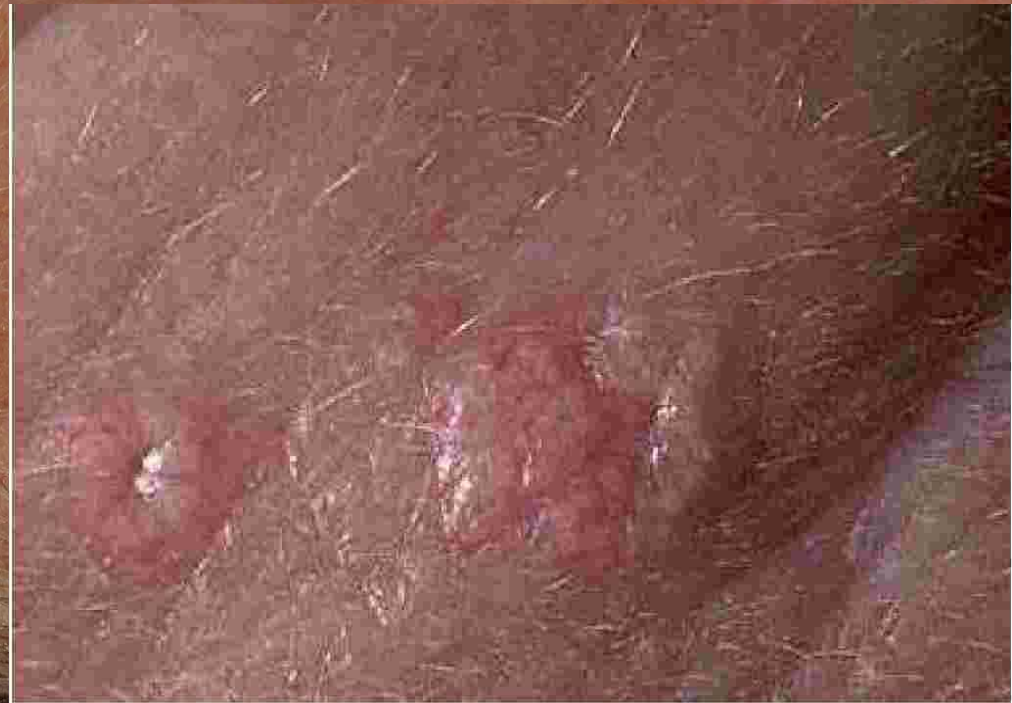
1. Hair root
2. Hair follicle
3. Sebaceous gland
4. Artery
5. Stratum corneum
6. Stratum spinosum
7. Stratum basale
8. Papillary layer
9. Reticular layer
10. Hypodermis



# Sebaceous hyperplasia



© Jere Mammino, DO



# Sudoriferous Glands

- Sweat glands.
- Distributed over the entire body **except the nipples and portions of the external genitalia.**
- Over 2.5 million per person.
- 2 types:
  1. **Merocrine sweat glands**
  2. **Apocrine sweat glands**

apocrine



Apocrine secretion designates a mechanism in which part of the apical cytoplasm of the cells is lost together with the secretory product. The continuity of the plasma membrane is restored by the fusion of the broken edges of the membrane, and the cell is able to accumulate the secretory product anew. This mechanism is used by apocrine sweat glands, the mammary glands and the prostate.

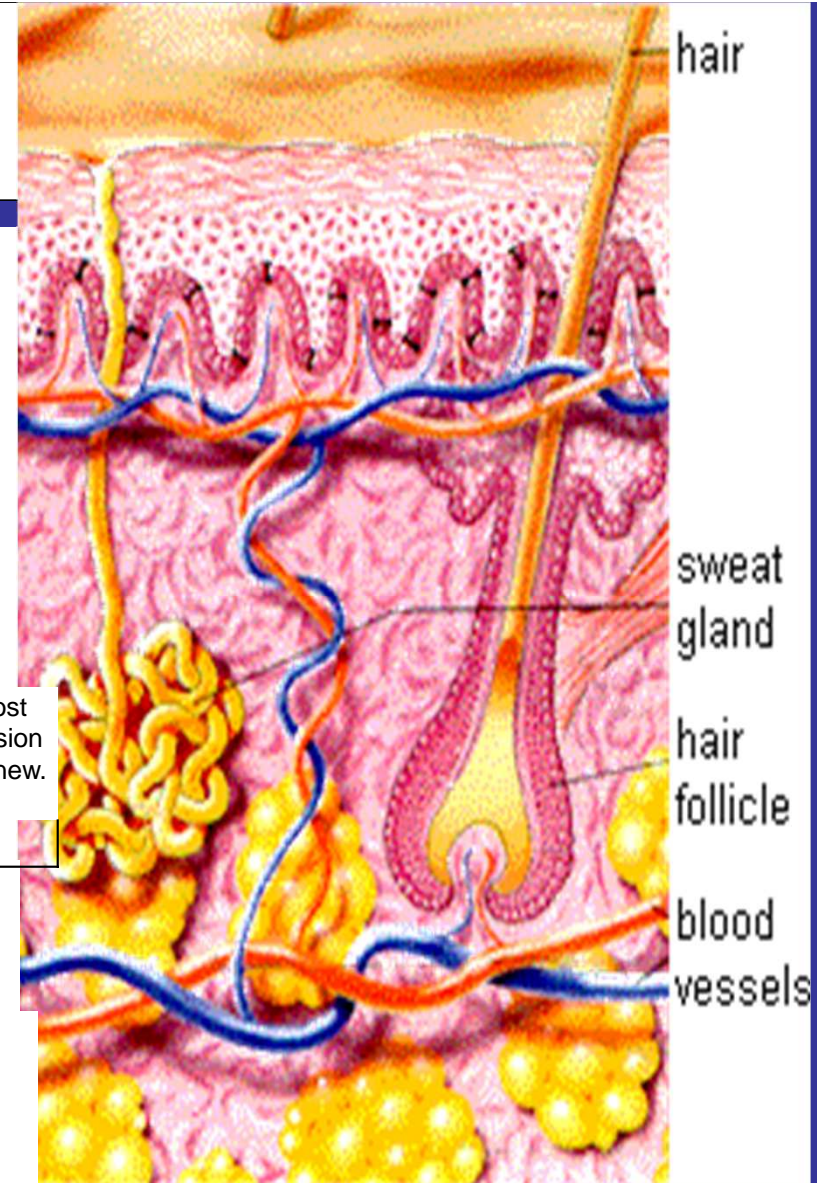


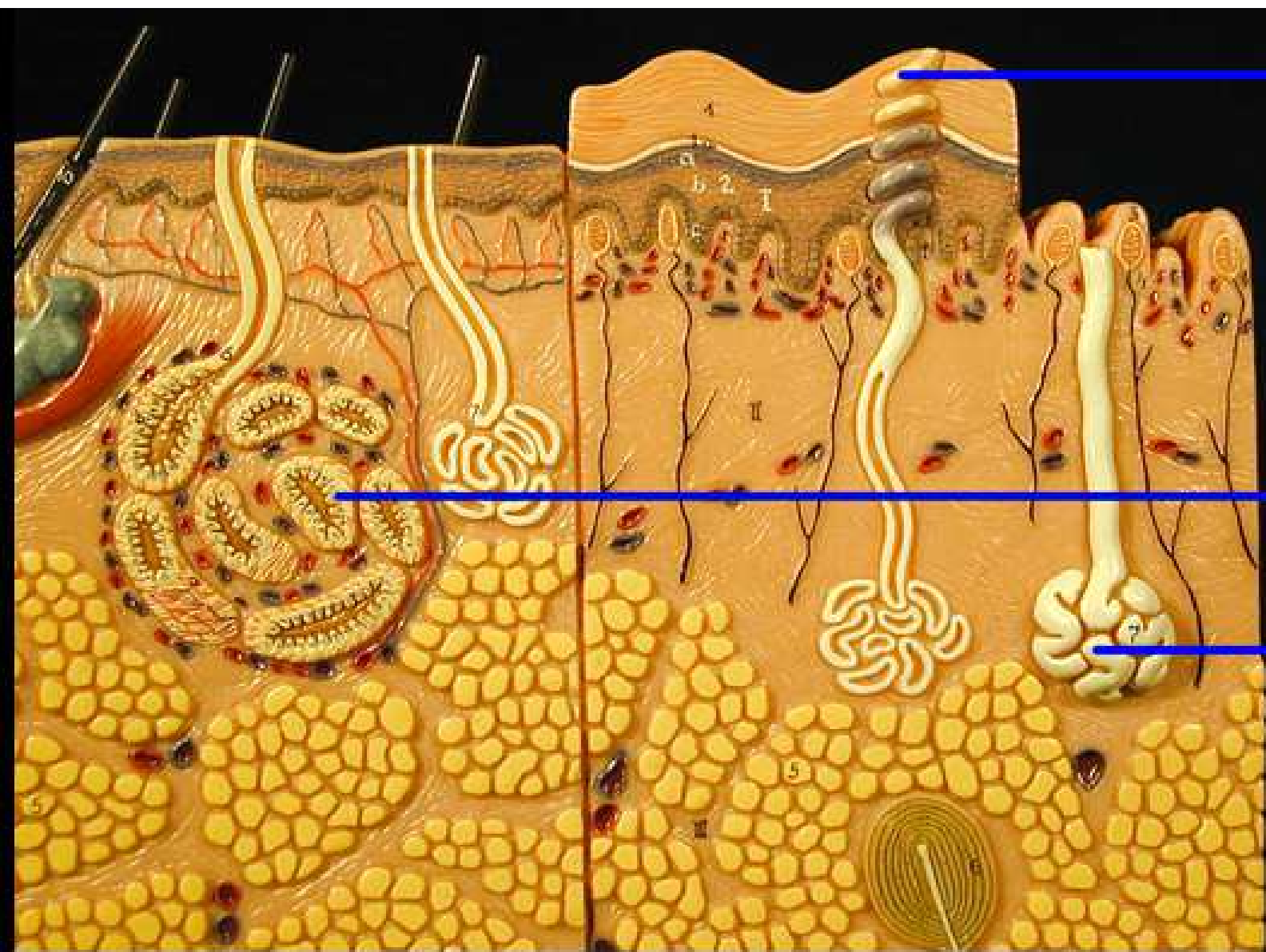
Holocrine secretion designates the breakdown and discharge of the entire secretory cell. It is only seen in the sebaceous glands of the skin.

merocrine



Merocrine secretion corresponds to the process of exocytosis. Vesicles open onto the surface of the cell, and the secretory product is discharged from the cell without any further loss of cell substance.

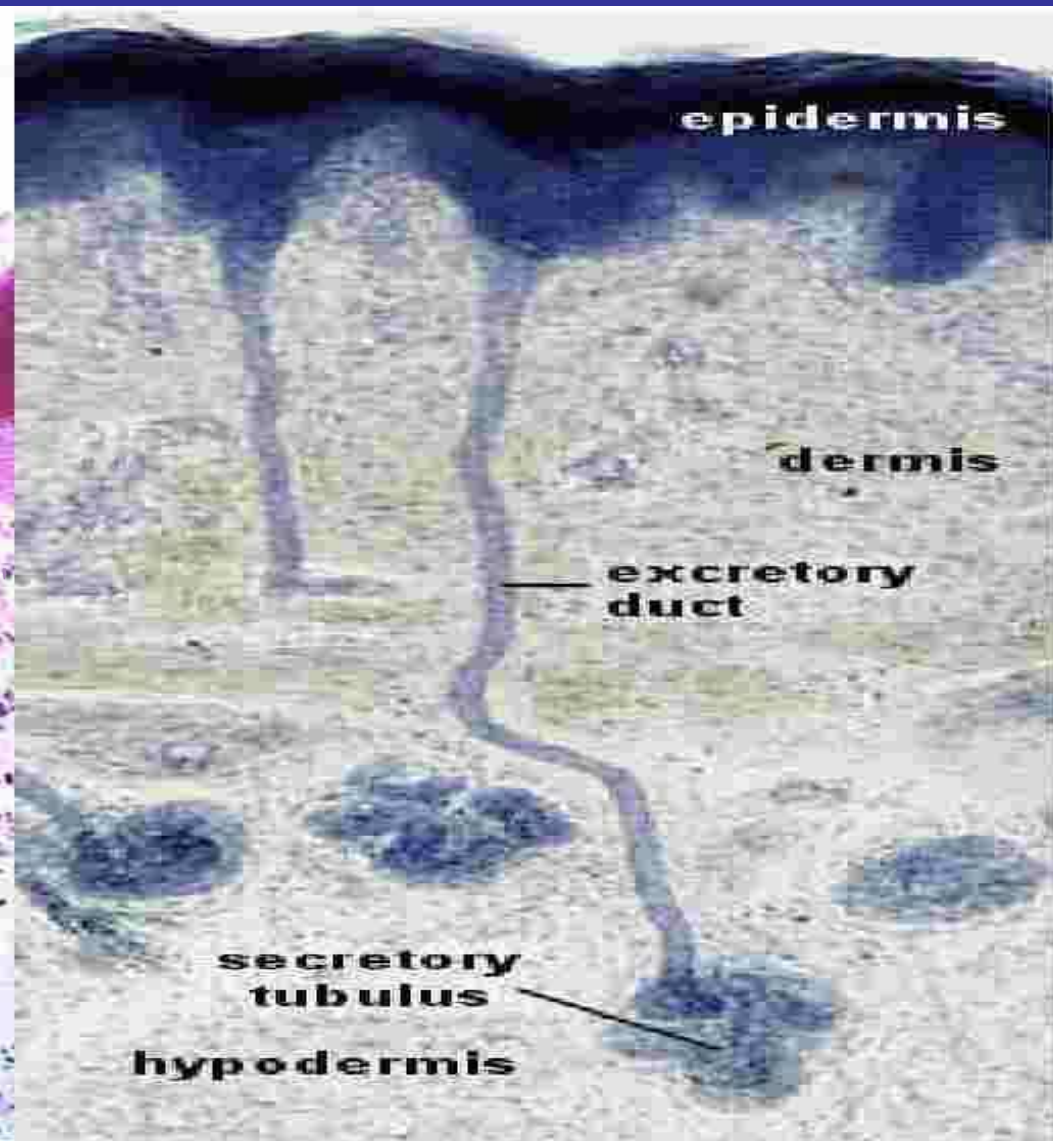
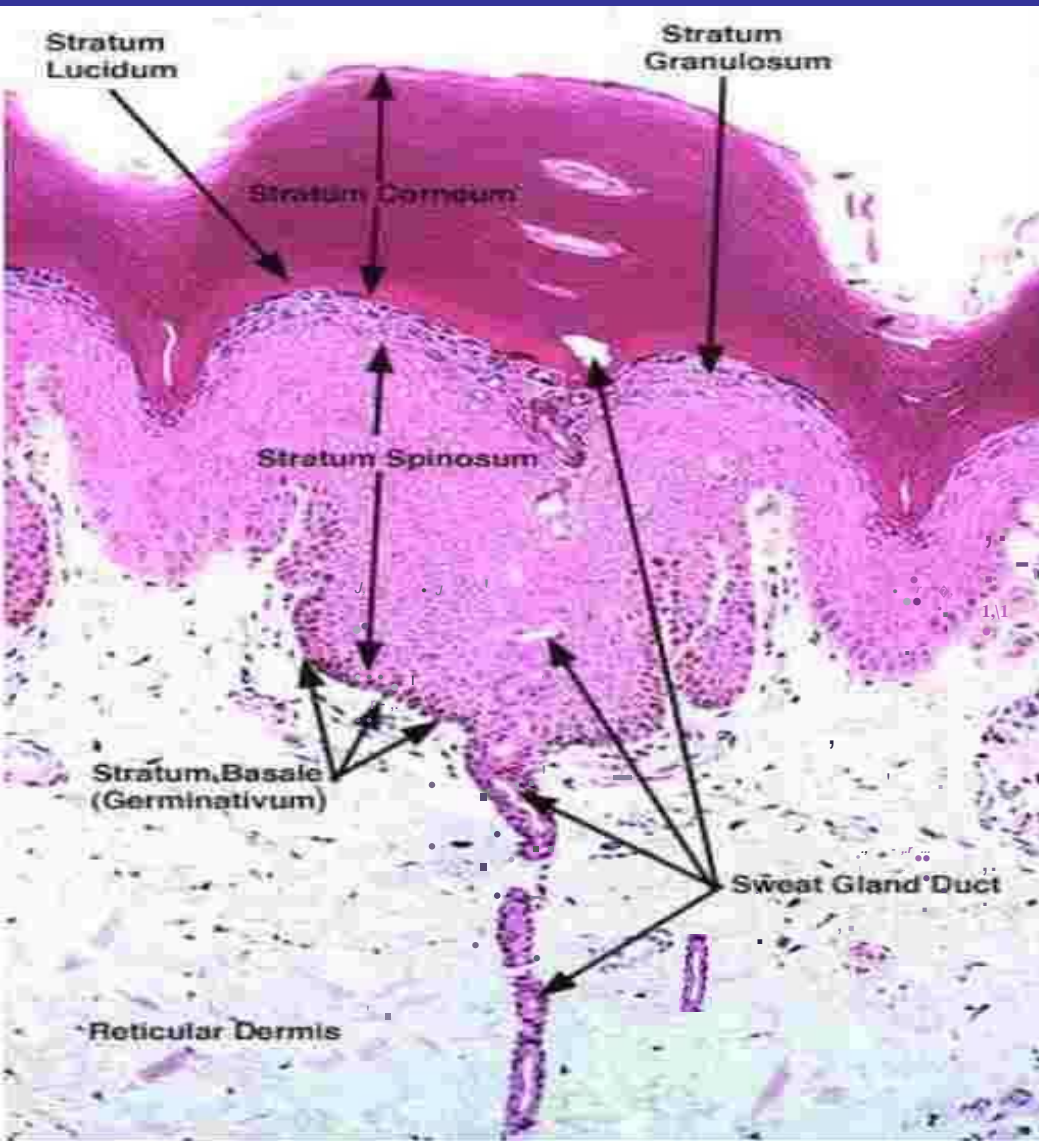


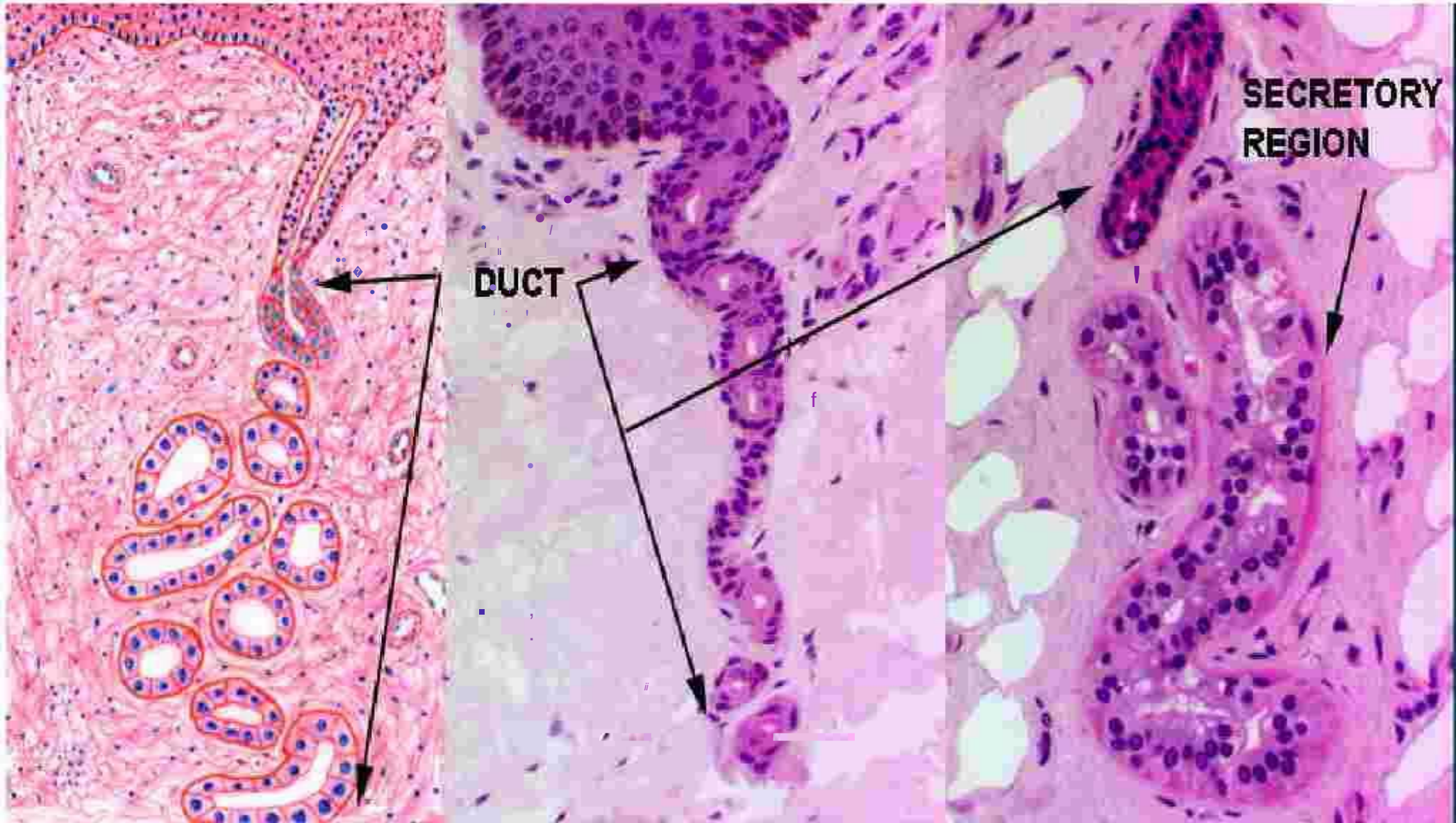


Duct of Eccrine  
Sudoriferous Gland

Apocrine Sudoriferous  
Gland

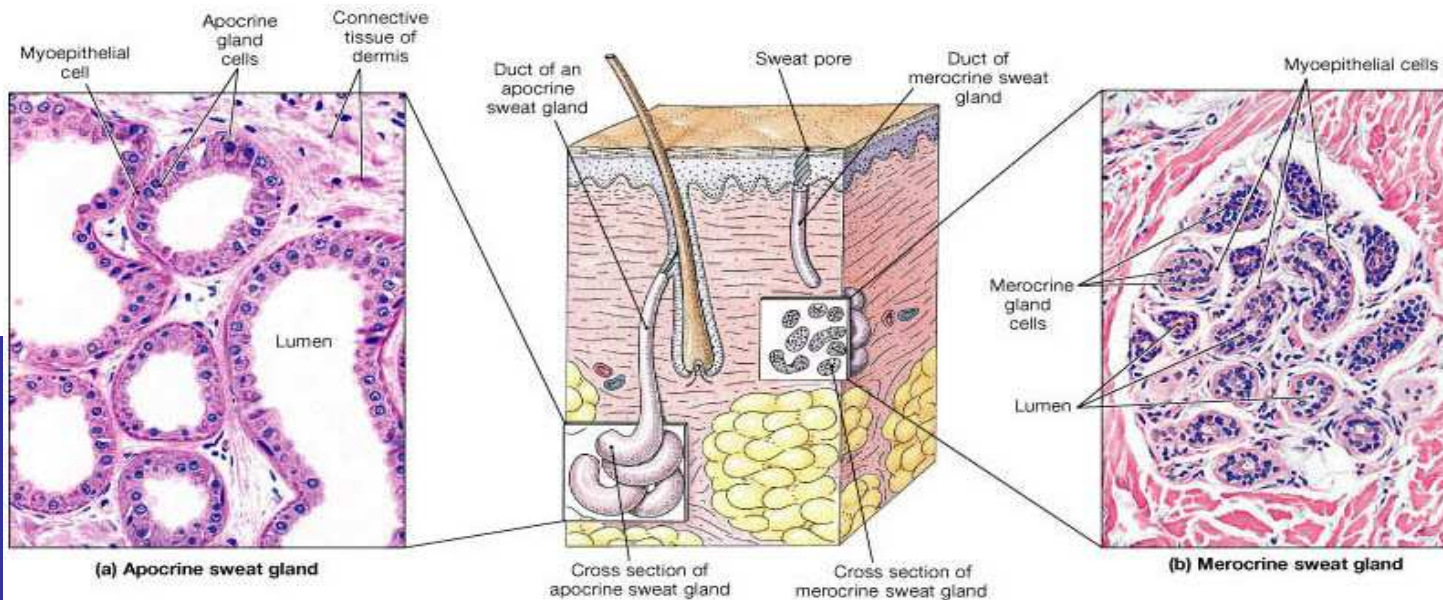

Eccrine Sudoriferous  
Gland





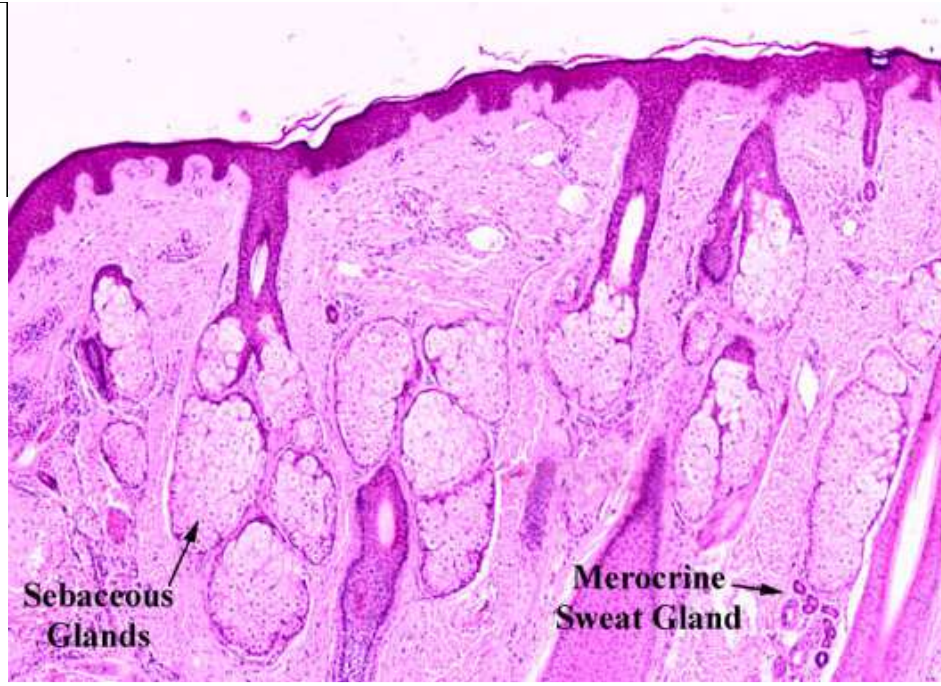
# Merocrine Sweat Glands [Eccrine glands]

- More numerous than apocrine sweat glands.
- **Especially prominent on the palms, soles, and forehead.**
- **Simple, coiled, tubular glands.**
- Duct empties into a funnel-shaped pore at the skin surface.
- Major function of merocrine sweating is to cool the body – **thermoregulation.**
- Fingerprints are formed by sweat glands.

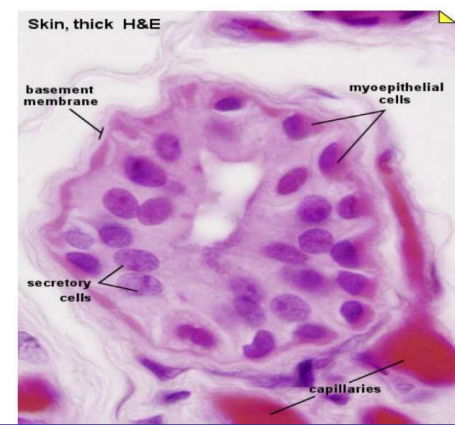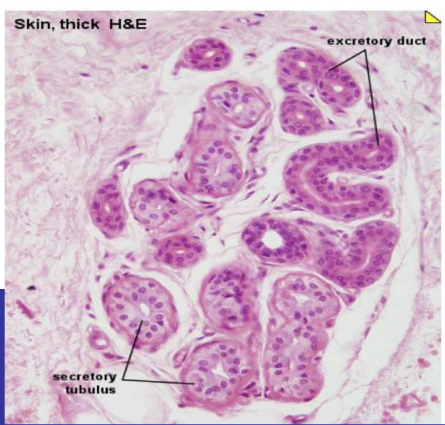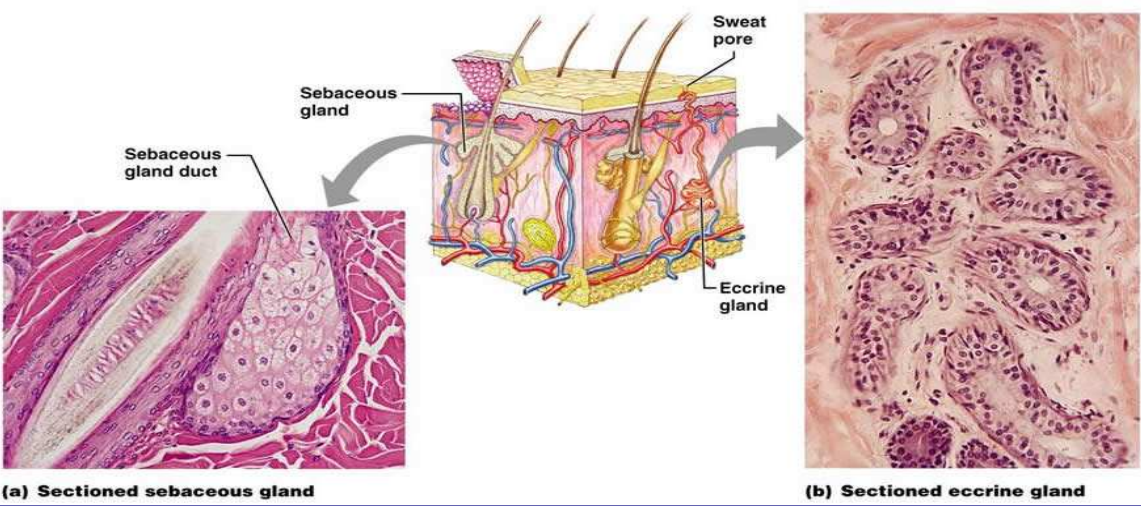


# Merocrine Sweat Glands

- Merocrine sweat is a dilute watery solution of some salts (including NaCl), vitamin C, antibodies, small amounts of nitrogenous wastes (urea, uric acid, and ammonia), and lactic acid.
- pH of sweat is 4-6 creating a film on the body known as the acid mantle.
- Such an acidic environment is bacteriostatic – prevents bacterial reproduction and growth.

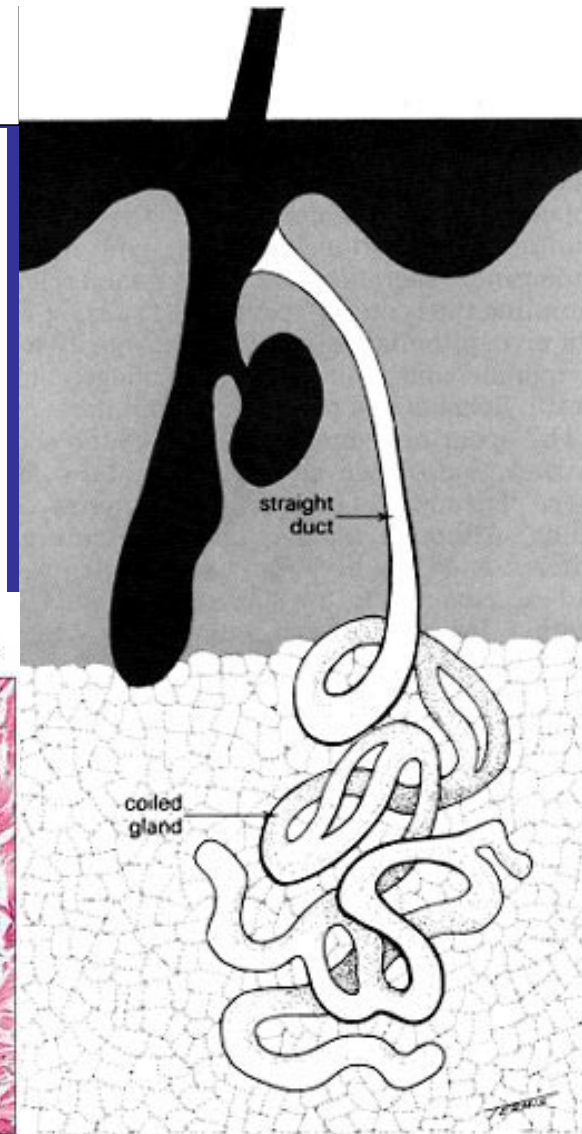
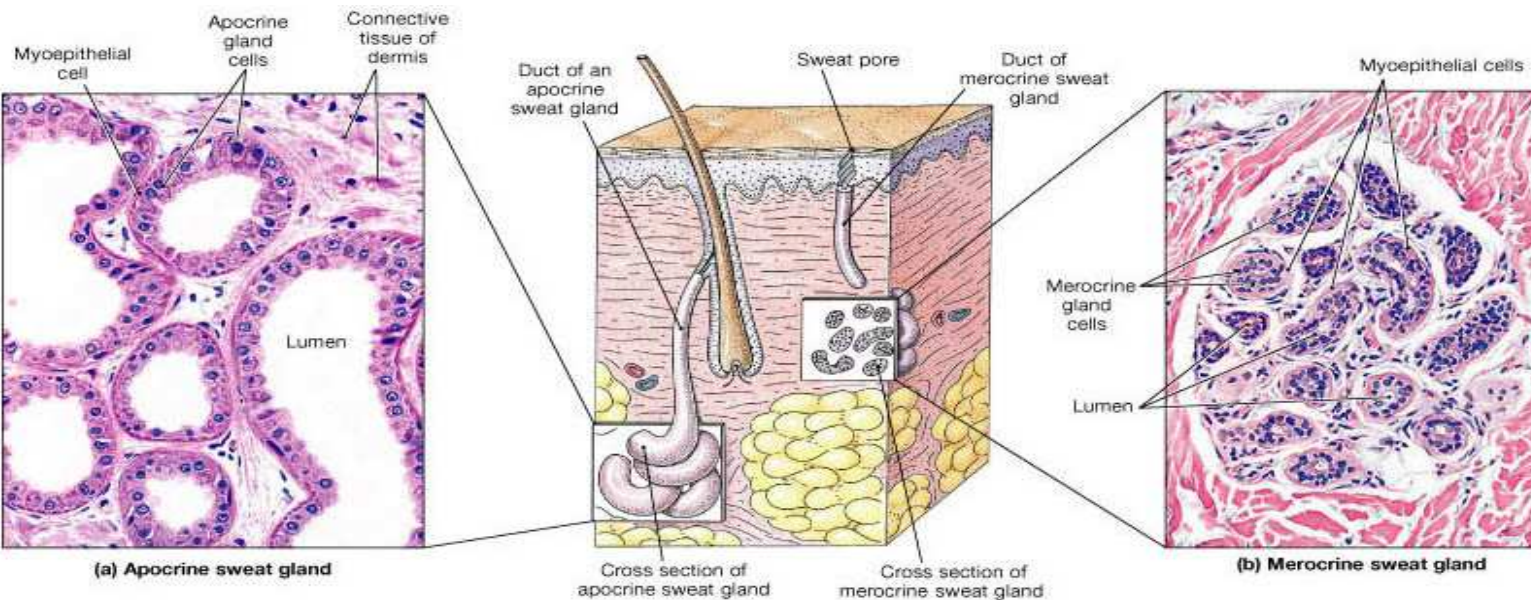


Skin Dermis with Merocrine Sweat Glands (stratified cuboidal)



# Apocrine Sweat Glands

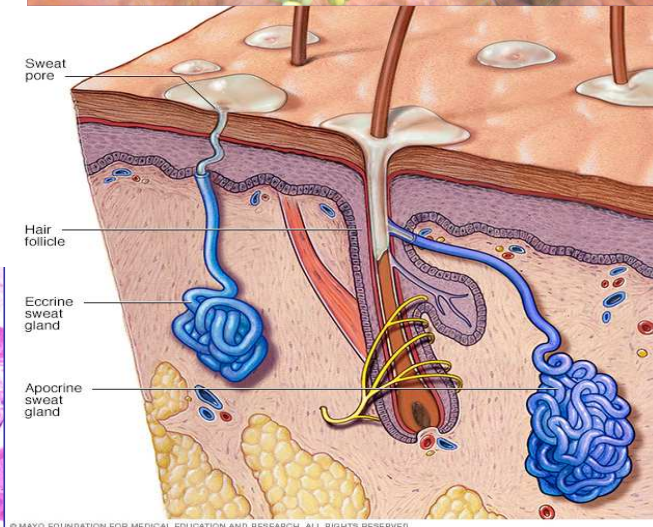
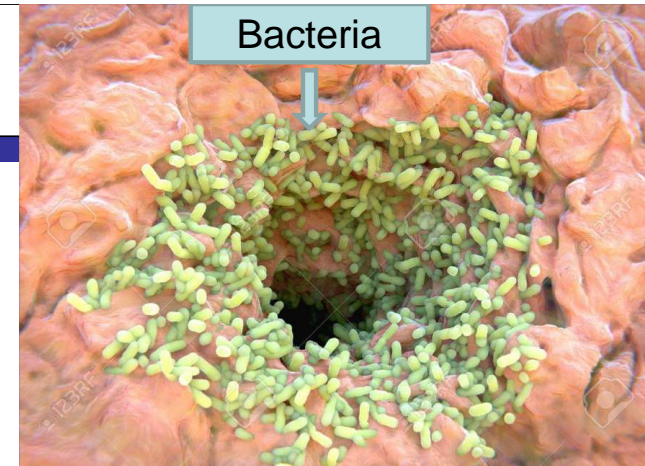
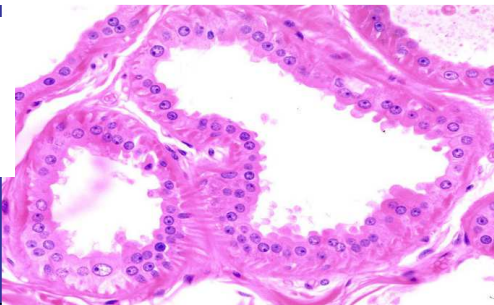- Found primarily in the axillary, pubic, and anal regions of the body.
  - Also found in the facial region in men only.
- Larger than merocrine sweat glands.
- Ducts empty into hair follicles.
- Apocrine sweat is thicker than merocrine sweat since it contains more lipids and proteins.
- When it's degraded by epidermal bacteria, foul odors can be produced.



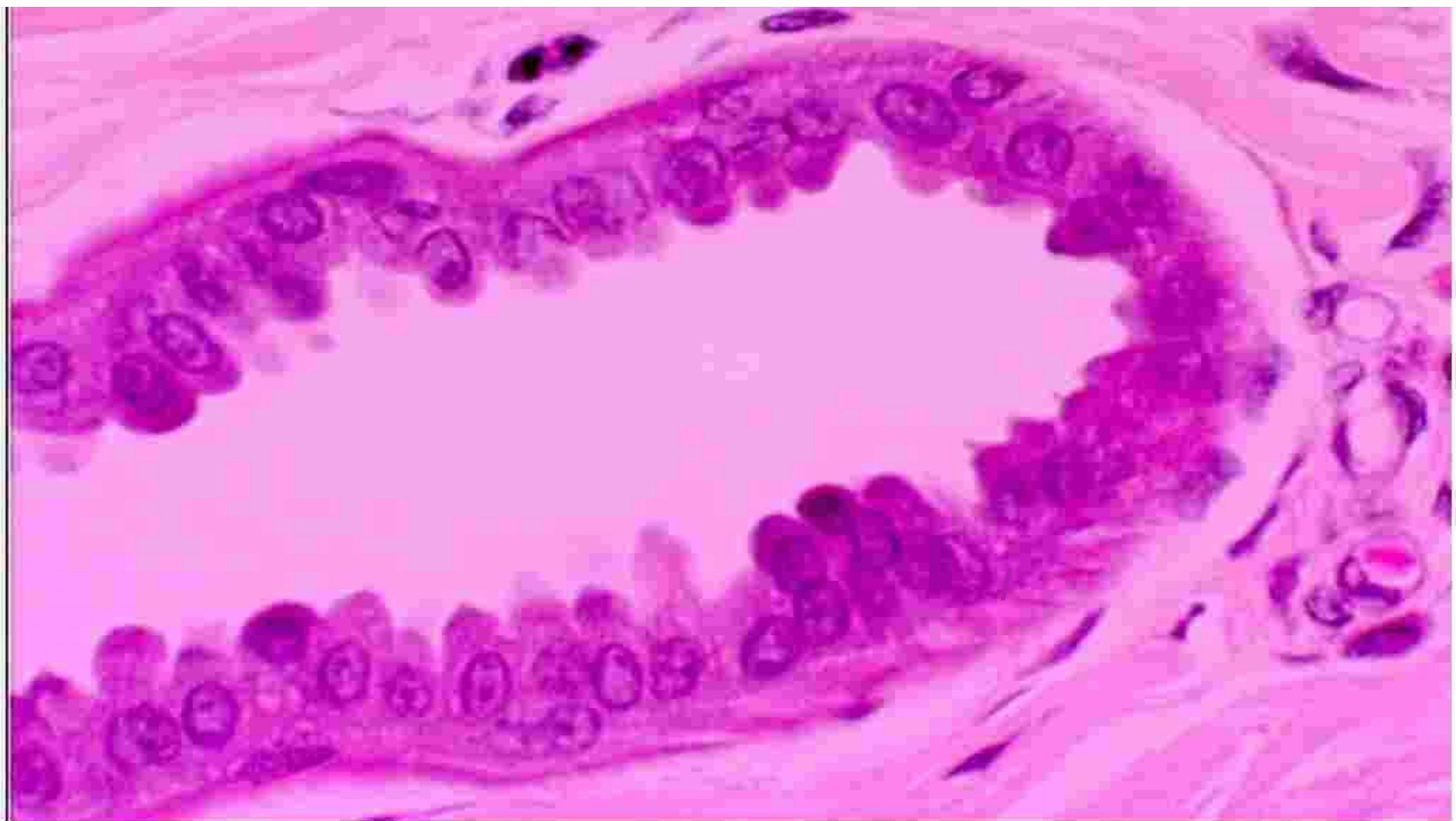# Apocrine Sweat Glands

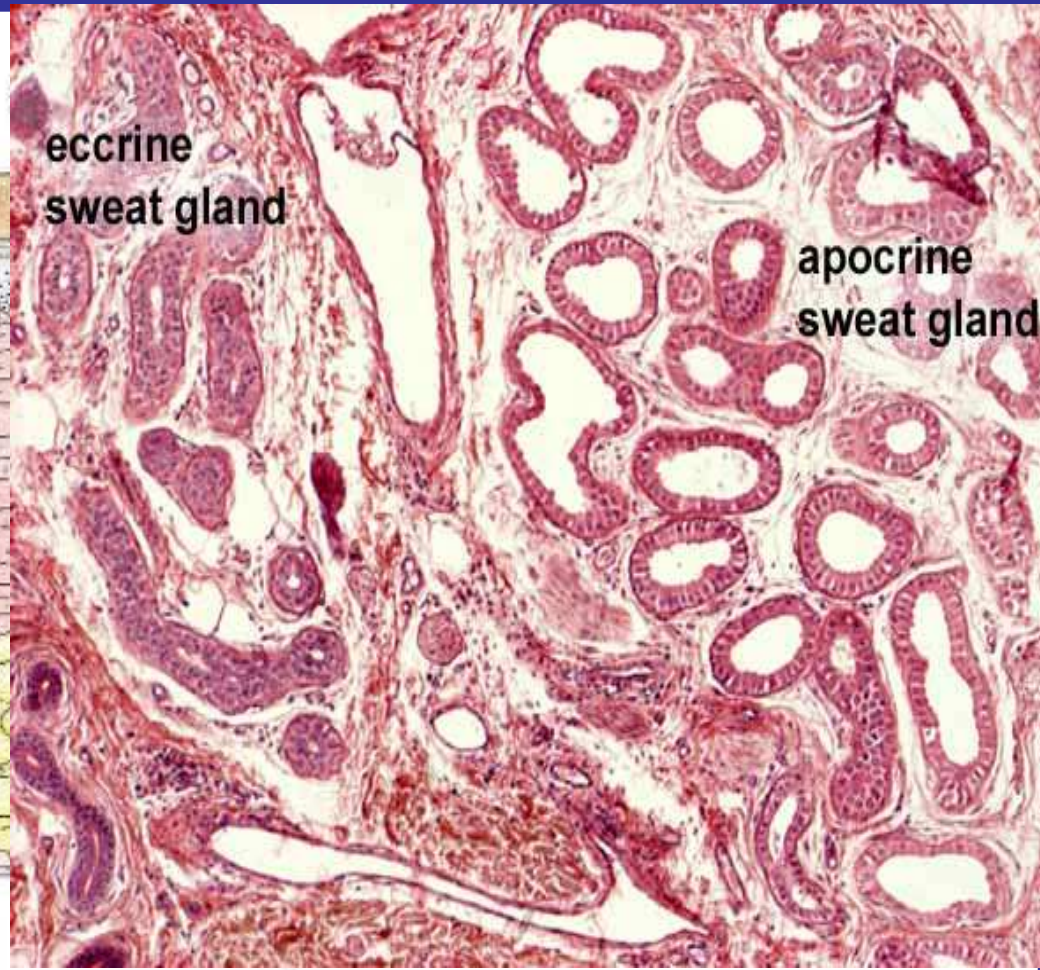
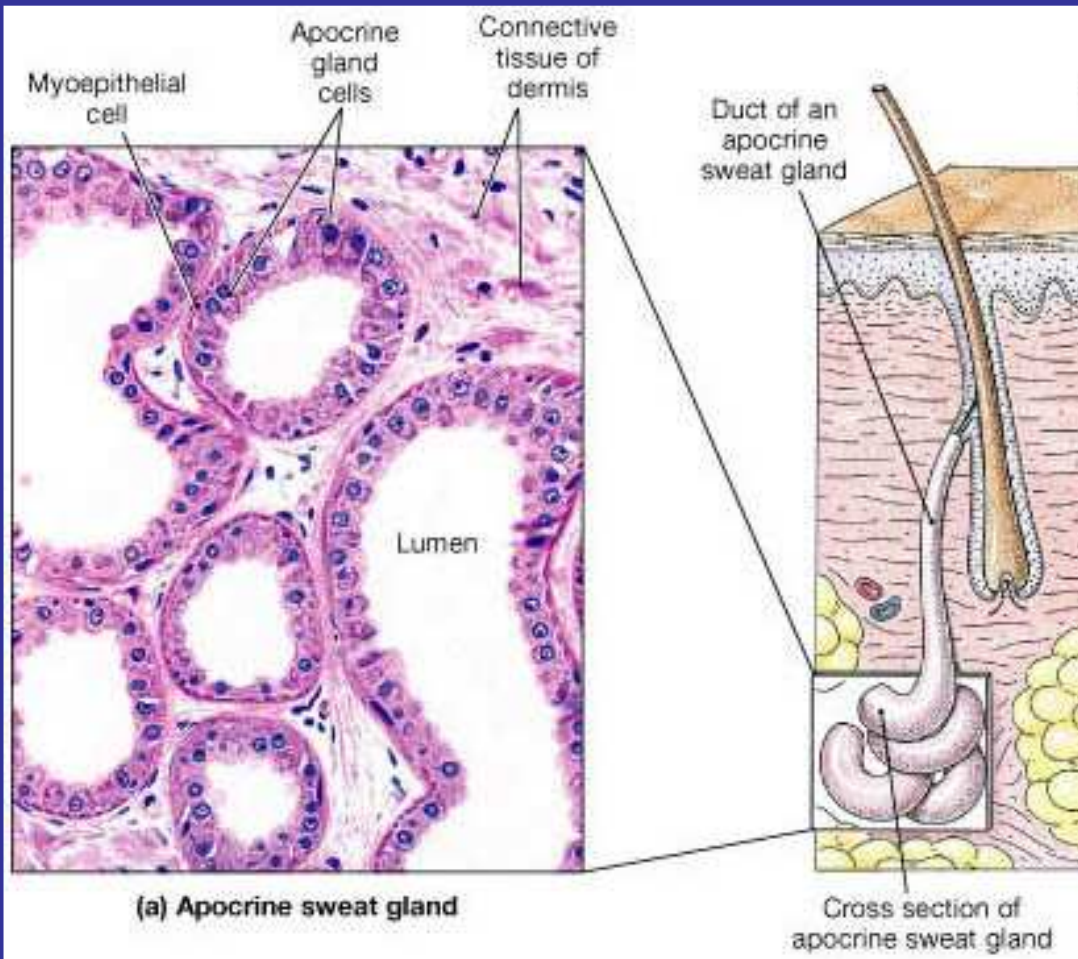
- Become active at puberty. Found primarily in the axillary, areola of the nipples pubic, and anal regions of the body.
- Also found in the facial region in men only.
- Larger than merocrine sweat glands.
- Ducts empty into hair follicles.
- Breast is part of it.
- Secrete sweat during times of pain, stress, and sexual activity.
- May have a possible pheromone-like function, the pubic and axillary one.
- Play no role in thermoregulation.
- stimulus for the secretion of apocrine sweat glands is adrenaline

Specialized types of apocrine sweat glands present on the eyelids are called Moll's glands [ *ciliary glands* ].



**Remember: Glands are derivatives of epithelial tissue. So even though many reside in the dermis, they are not made from connective tissue.**



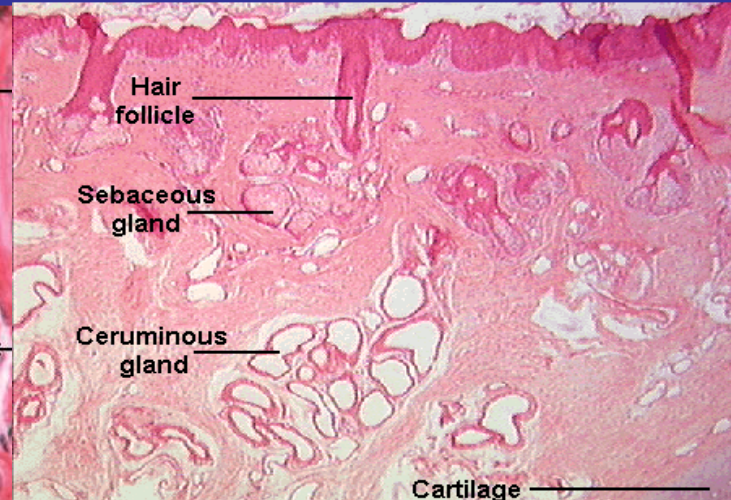
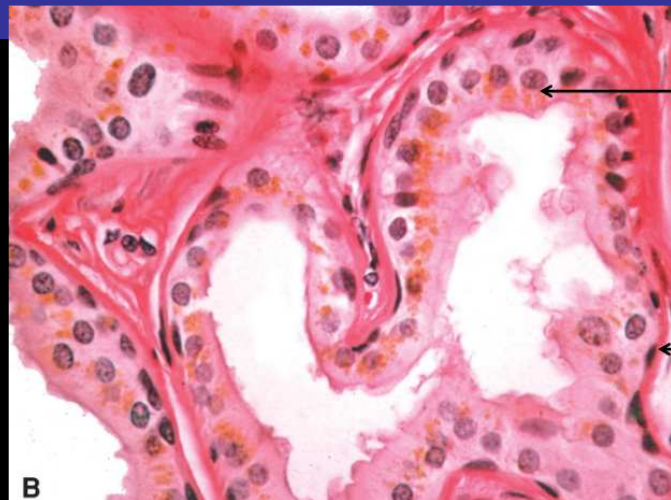
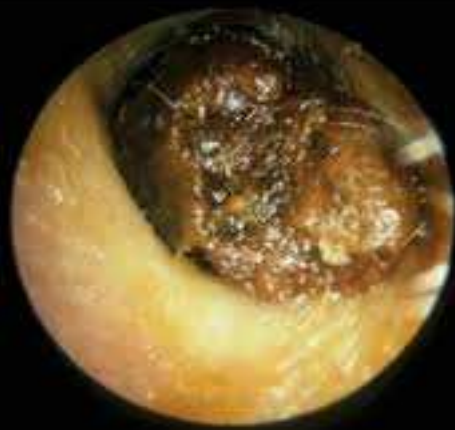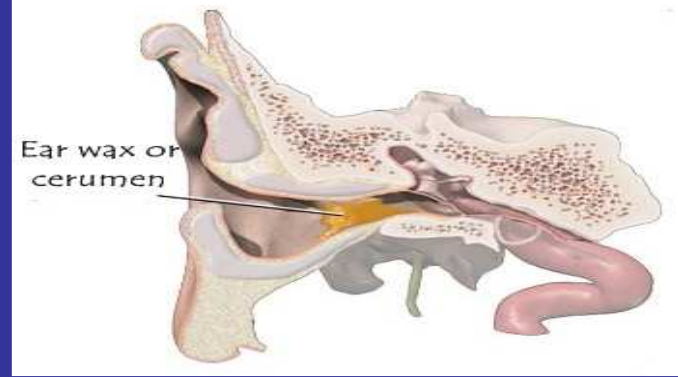
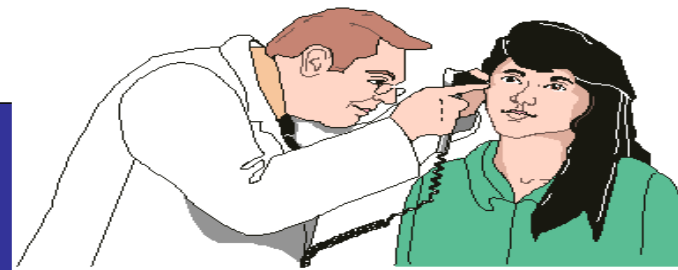


# Ceruminous Glands

- Modified apocrine glands found in the inner lining of the external ear canal.
- Secrete a sticky waxy substance **called cerumen** (earwax).
- It combines with sebum and dead epidermal cells to form a bitter compound that offers a **barrier to entry of the ear.**

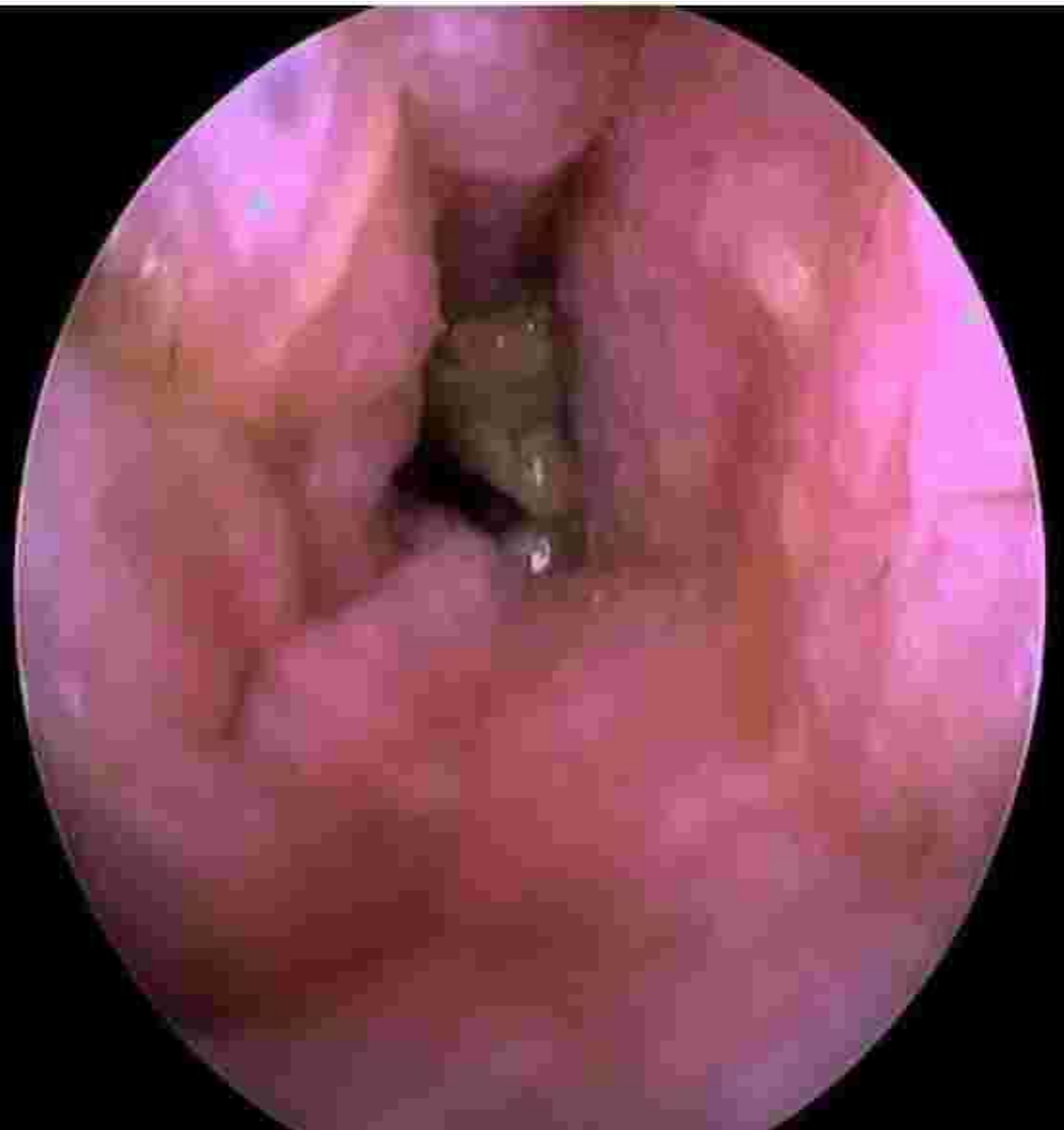
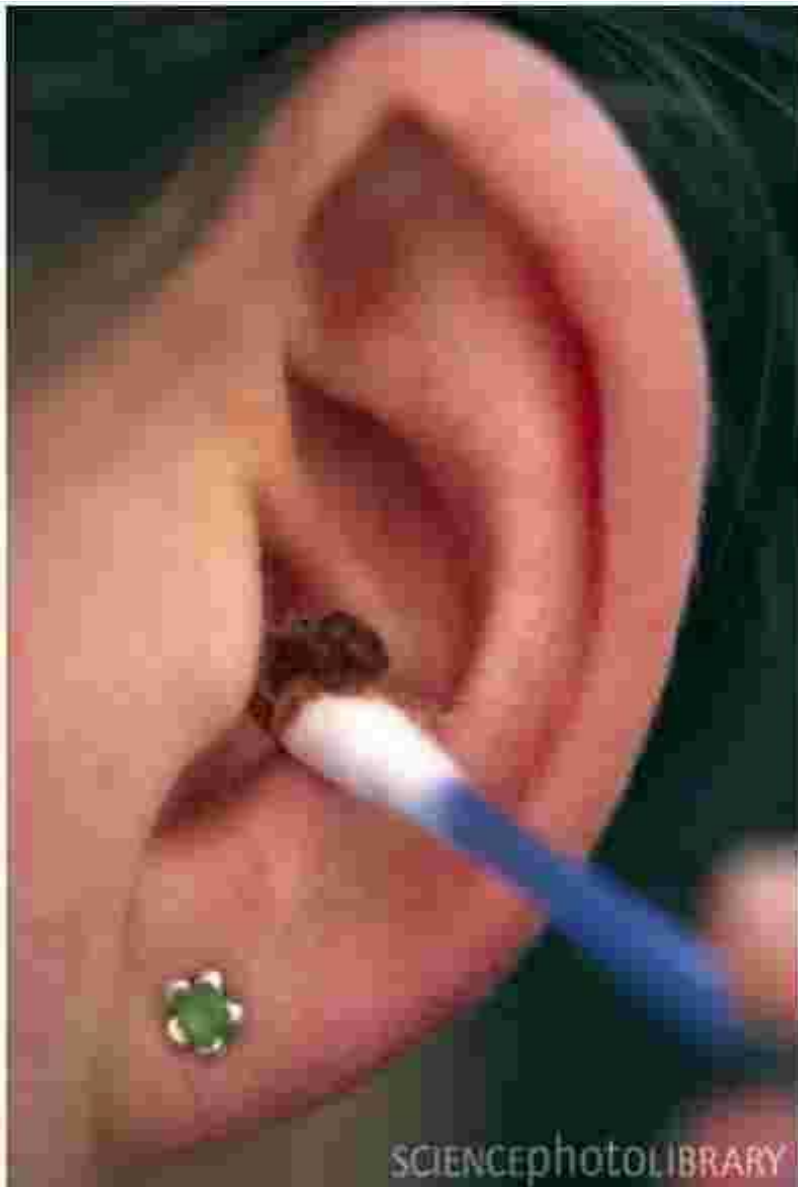
Cerumen :

- 1 keeps the eardrum pliable
2. lubricates and cleans the external auditory canal,
3. waterproofs the canal,
4. kill bacteria
5. serves as a barrier to trap foreign by coating the guard hairs of the ear, making them sticky



B

Cartilage



## Nerve endings in the skin

The skin has many sensory elements that respond to external impulses and signals.

• **Free nerve endings** are non-encapsulated nerve endings in the epidermis and which respond to pain.

• **Meissner corpuscles** are mechanoreceptors present

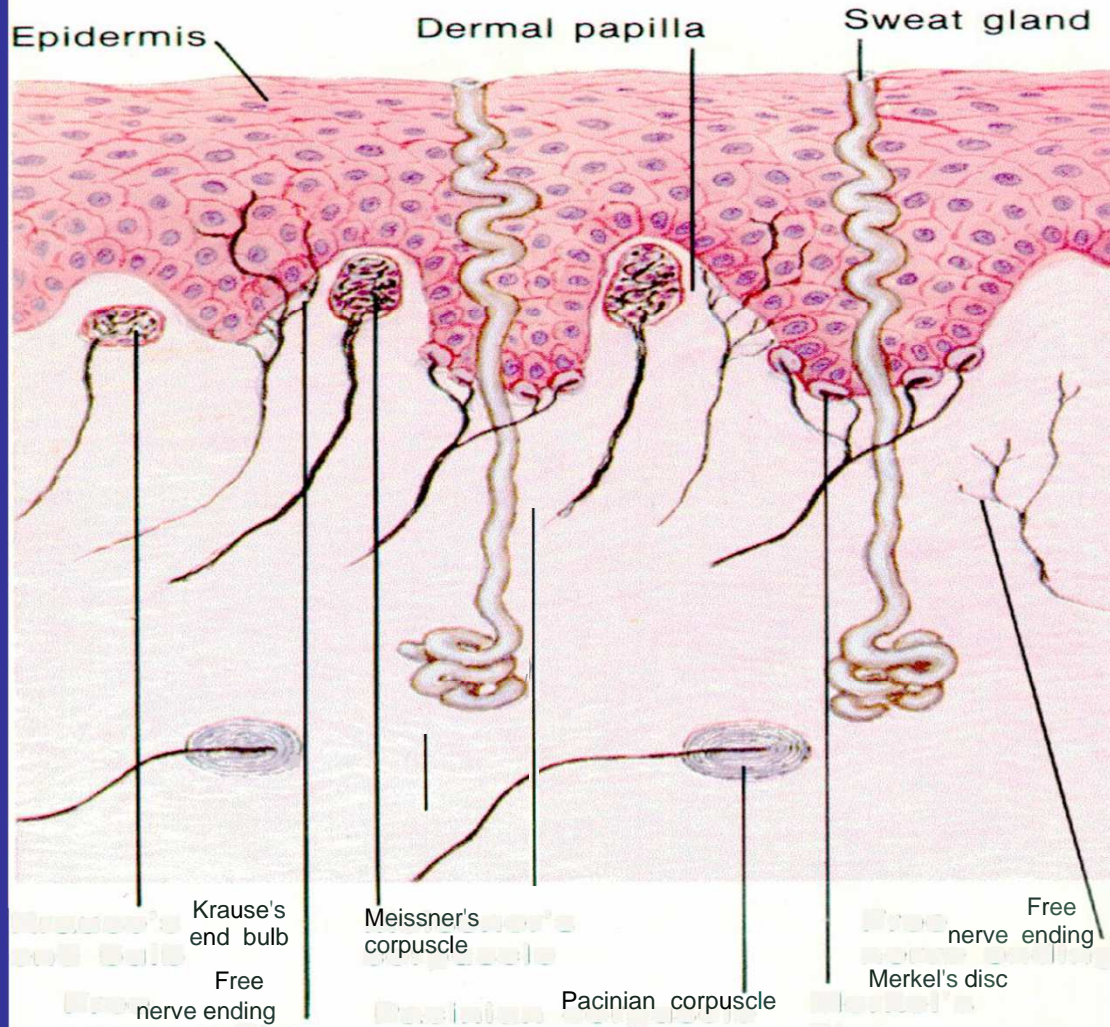
• **Merkel corpuscles** are mechanoreceptors surrounding hair follicles responsive to touch.

• **Pacinian corpuscles (Vater-Pacini)** are found in the dermis of thick skin of fingers and respond to pressure and vibratio.

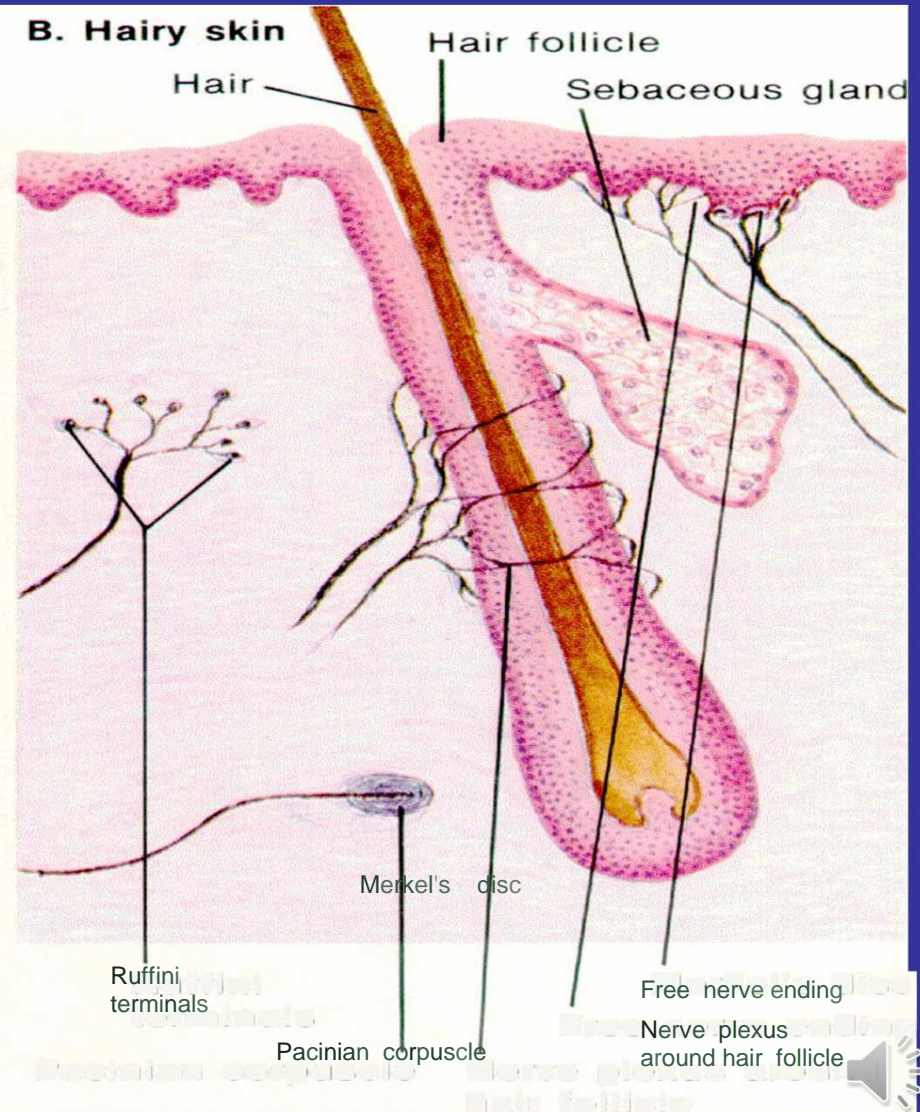
• **Krause end bulbs** are found in the dermis and respond to cold.



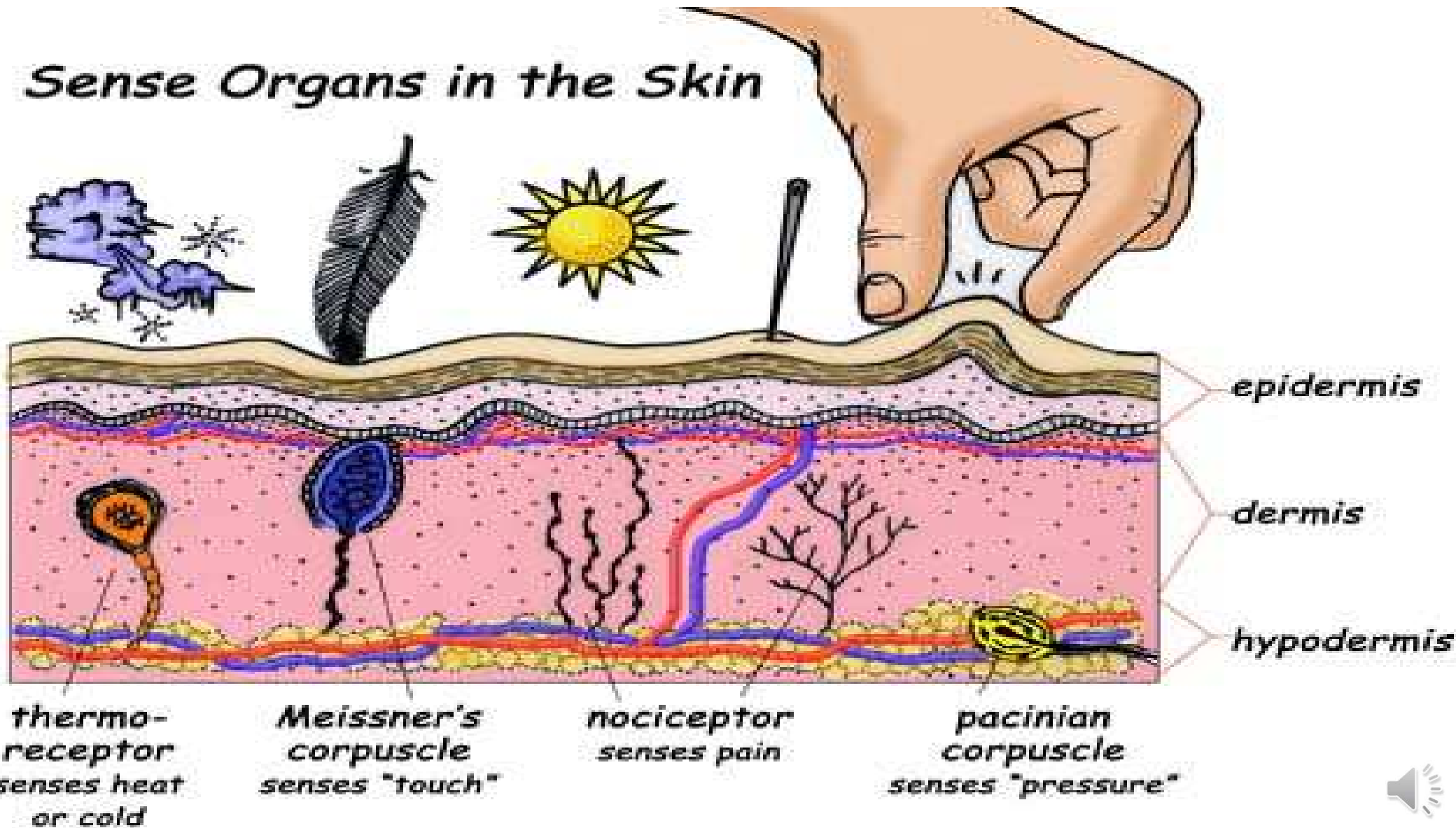
**A. Glabrous skin**

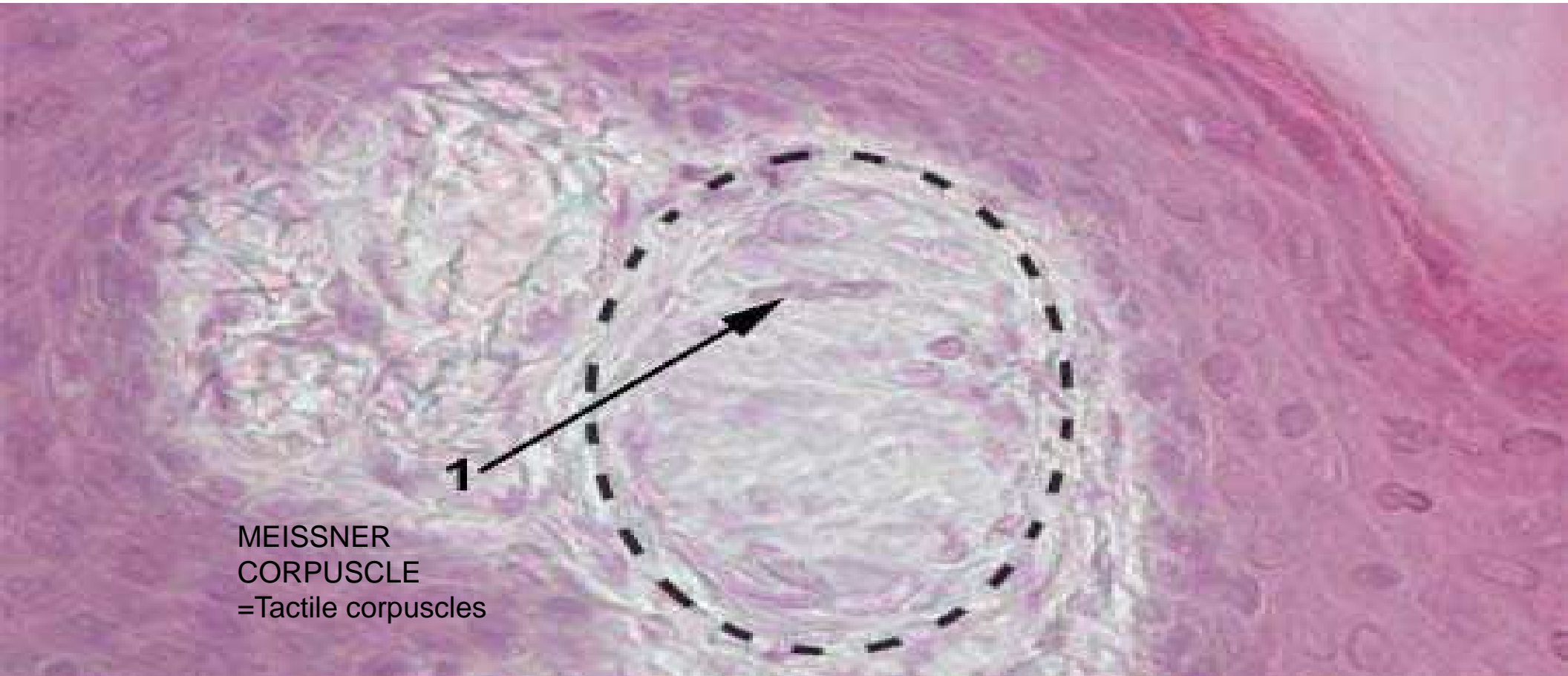


**B. Hairy skin**



# Sense Organs in the Skin

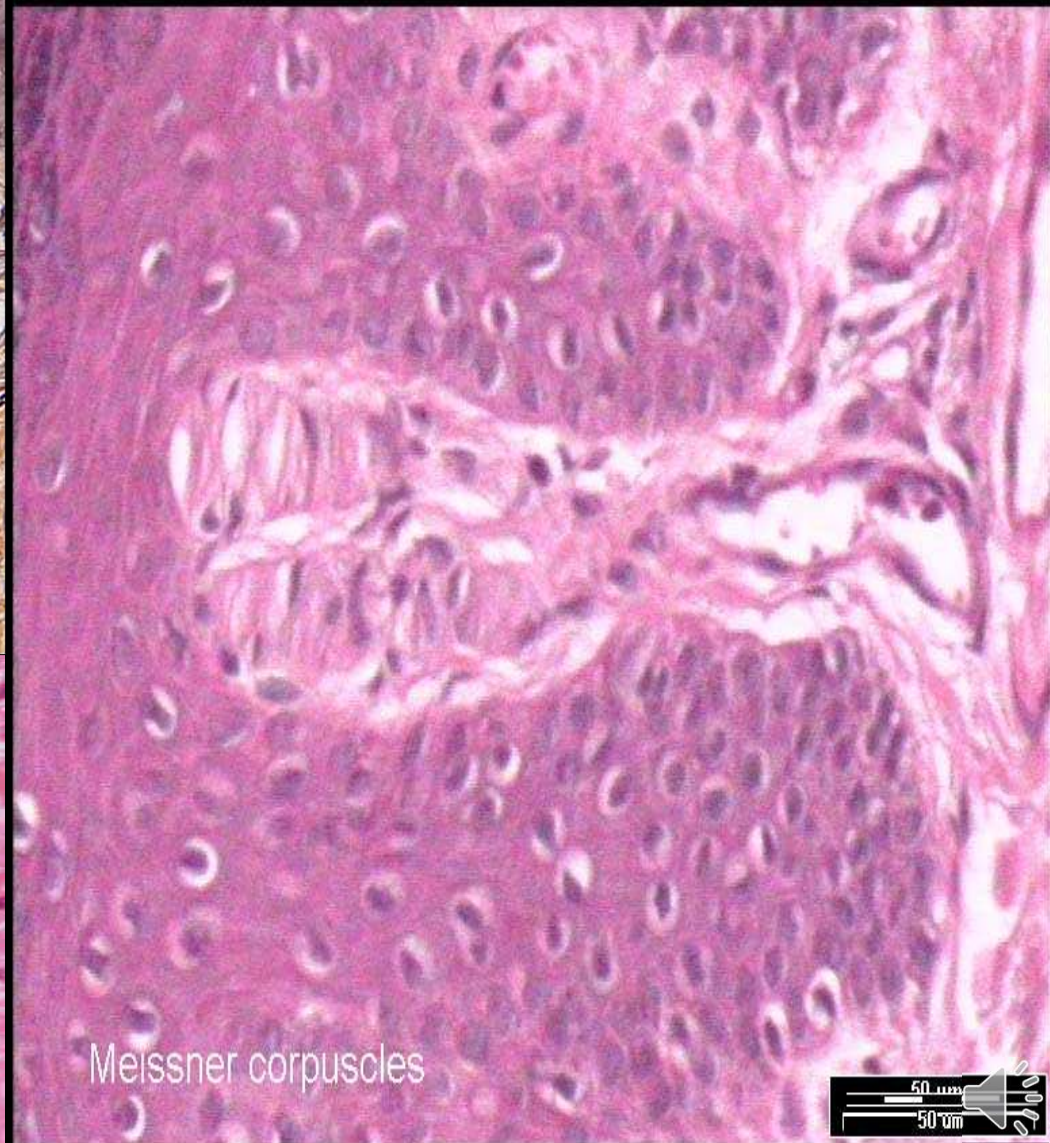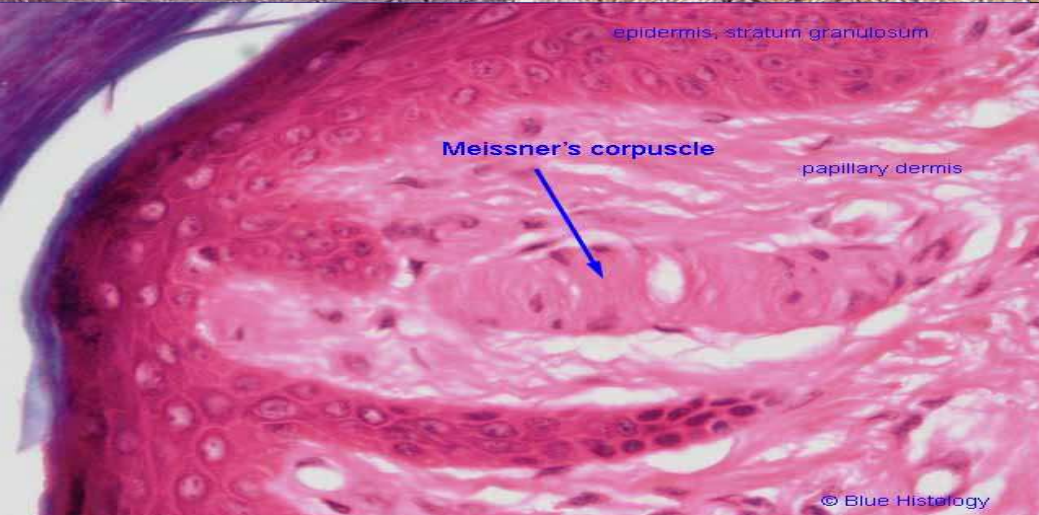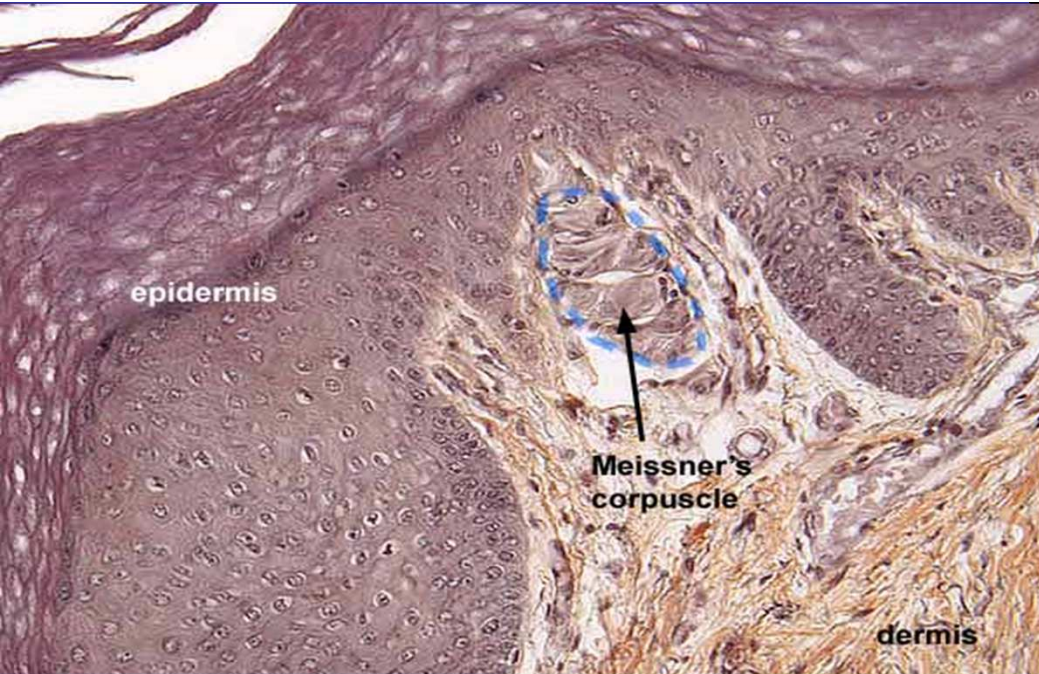


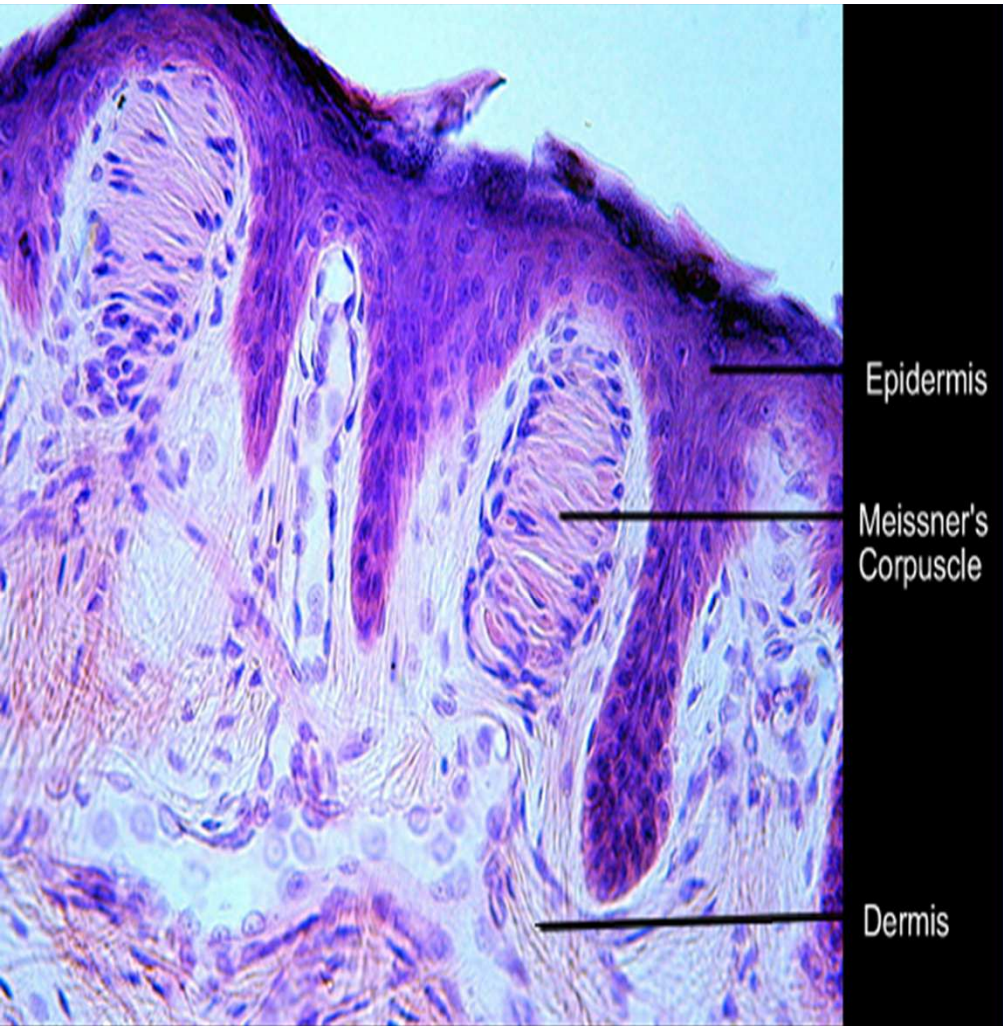


1  
MEISSNER  
CORPUSCLE  
=Tactile corpuscles

- a type of mechanoreceptor.
- sensitivity to light touch. In particular, they have their highest sensitivity (lowest threshold)
- They are rapidly adaptive receptors.
- They are most concentrated in thick hairless skin, especially at the finger pads.
- More specifically, they are primarily located in glabrous skin just beneath the epidermis within the dermal papillae

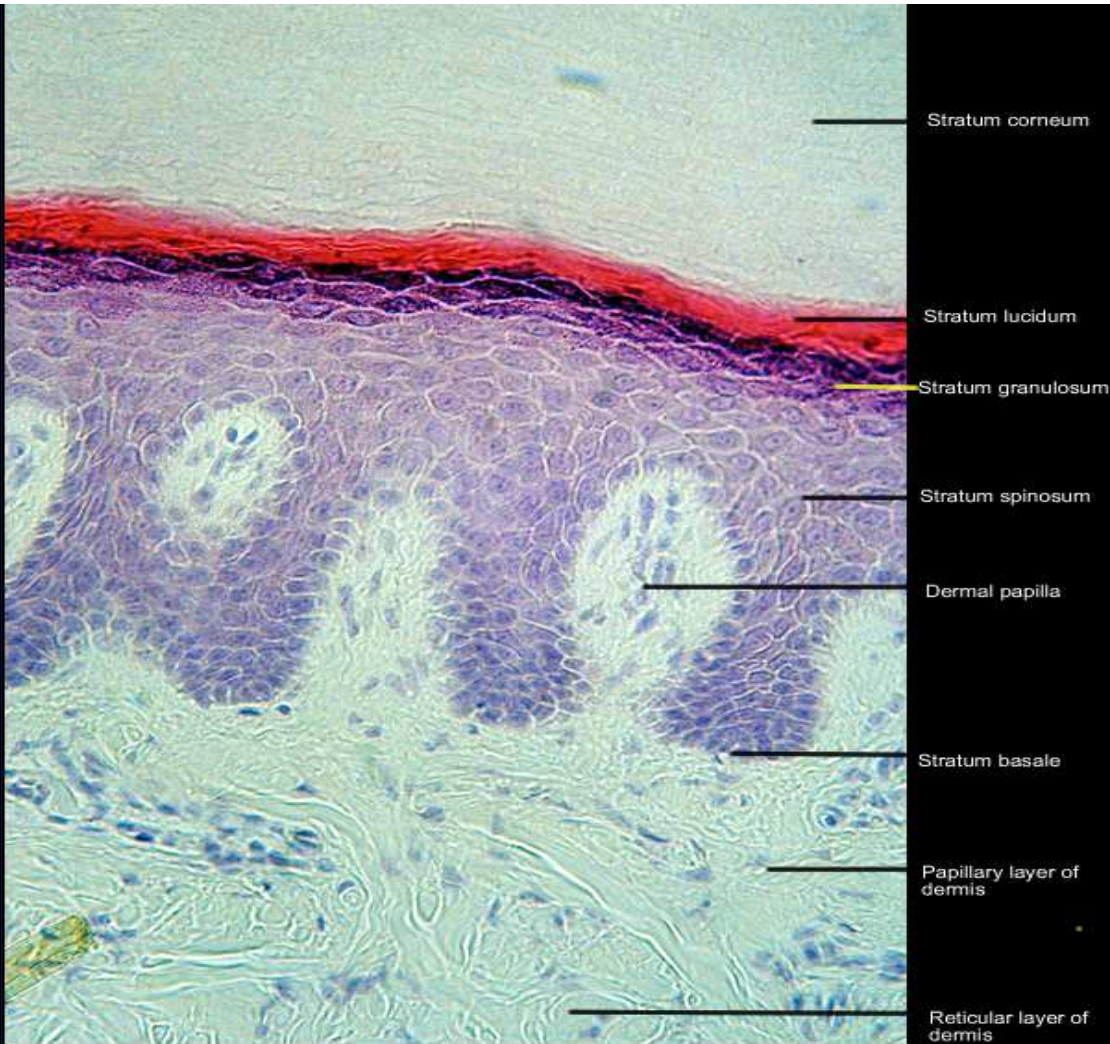






Meissner's Corpuscle (400x)

This is a touch receptor.



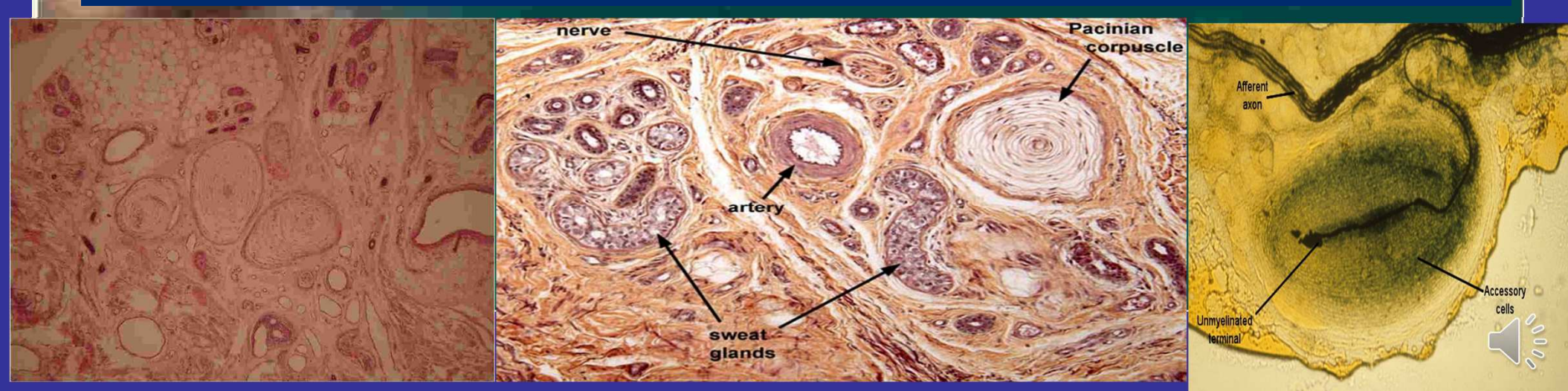
Cornified Skin (400x)

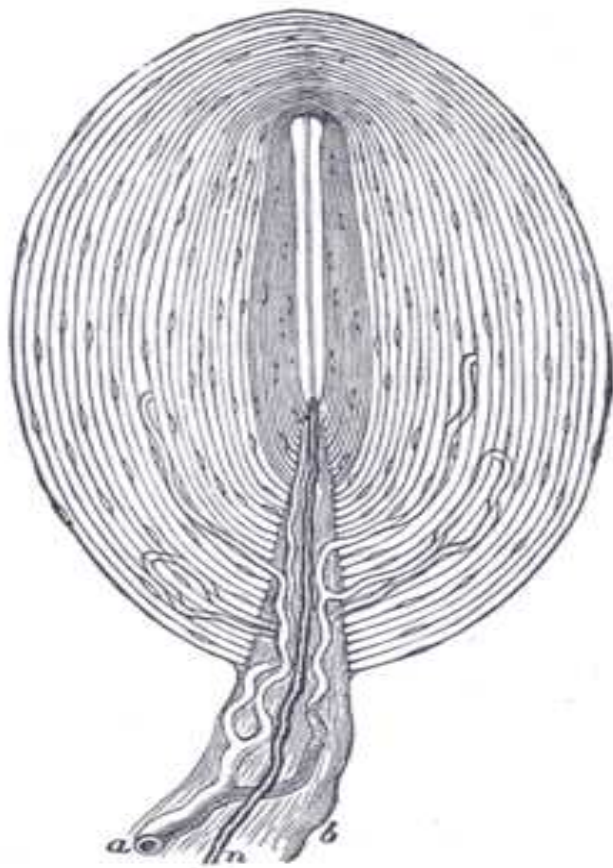


## Pacinian corpuscles = Lamellar corpuscles

- are one of the four major types of mechanoreceptor.
- They are nerve endings in the skin, responsible for sensitivity to vibration and pressure.
- Vibrational role may be used to detect surface, e.g., rough vs. smooth.

Pacinian corpuscles detect gross pressure changes and vibrations and are rapidly adapting (phasic) receptors

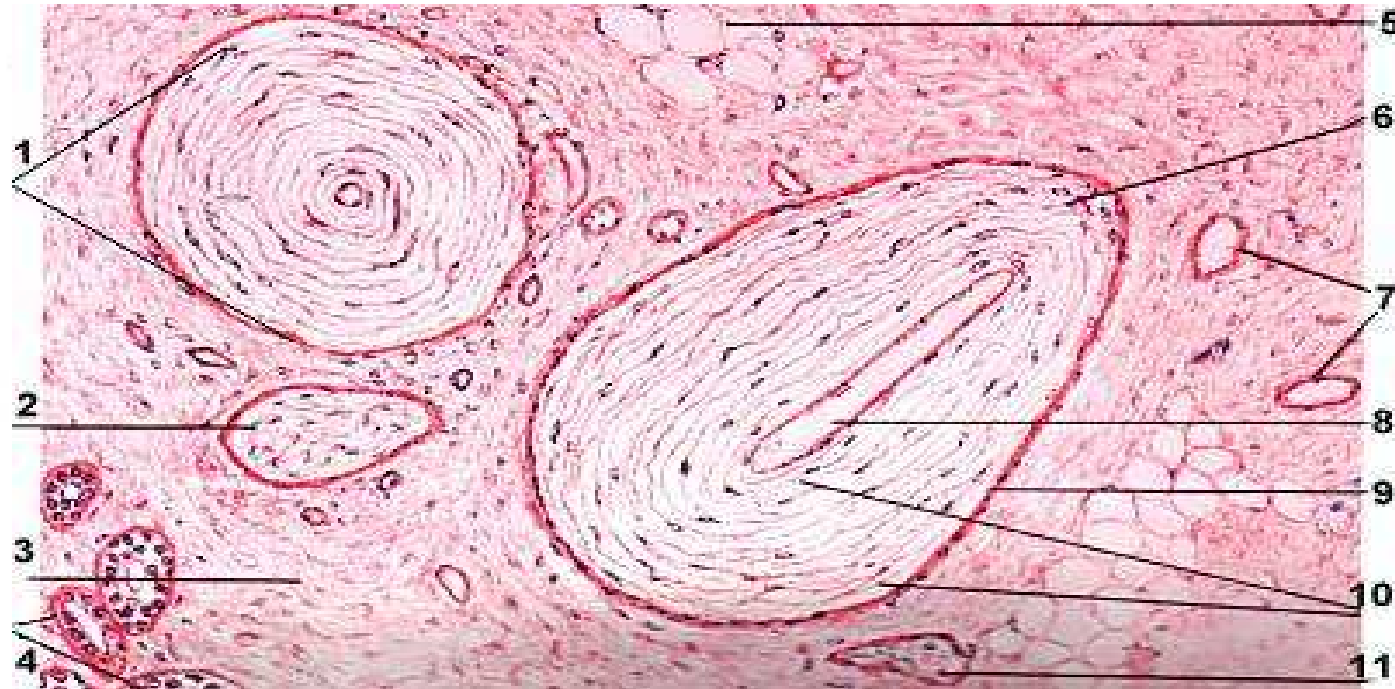




## Pacian corpuscles (dermis of thick skin) PASH.

350x

Eroschenko (1993) *di Fiore's Atlas of Histology 7th Ed.* Plate 49, Fig. 2, p. 133



Pacian corpuscles (dermis of thick skin) PASH.350x

1=pacian corpuscle 2=nerve

3=connective tissue of the dermis

4=duct and secretory portion of sweat gland

5=fat cells

6=pacian corpuscle: fibroblasts

7=venules

8=inner bulb of the corpuscle

9=sheath of the corpuscle 10=inner and outer Lamellae of the corpuscle

11=nerve

Eroschenko (1993) *di Fiore's Atlas of Histology 7th Ed.* Plate 49, Fig. 2, p. 133

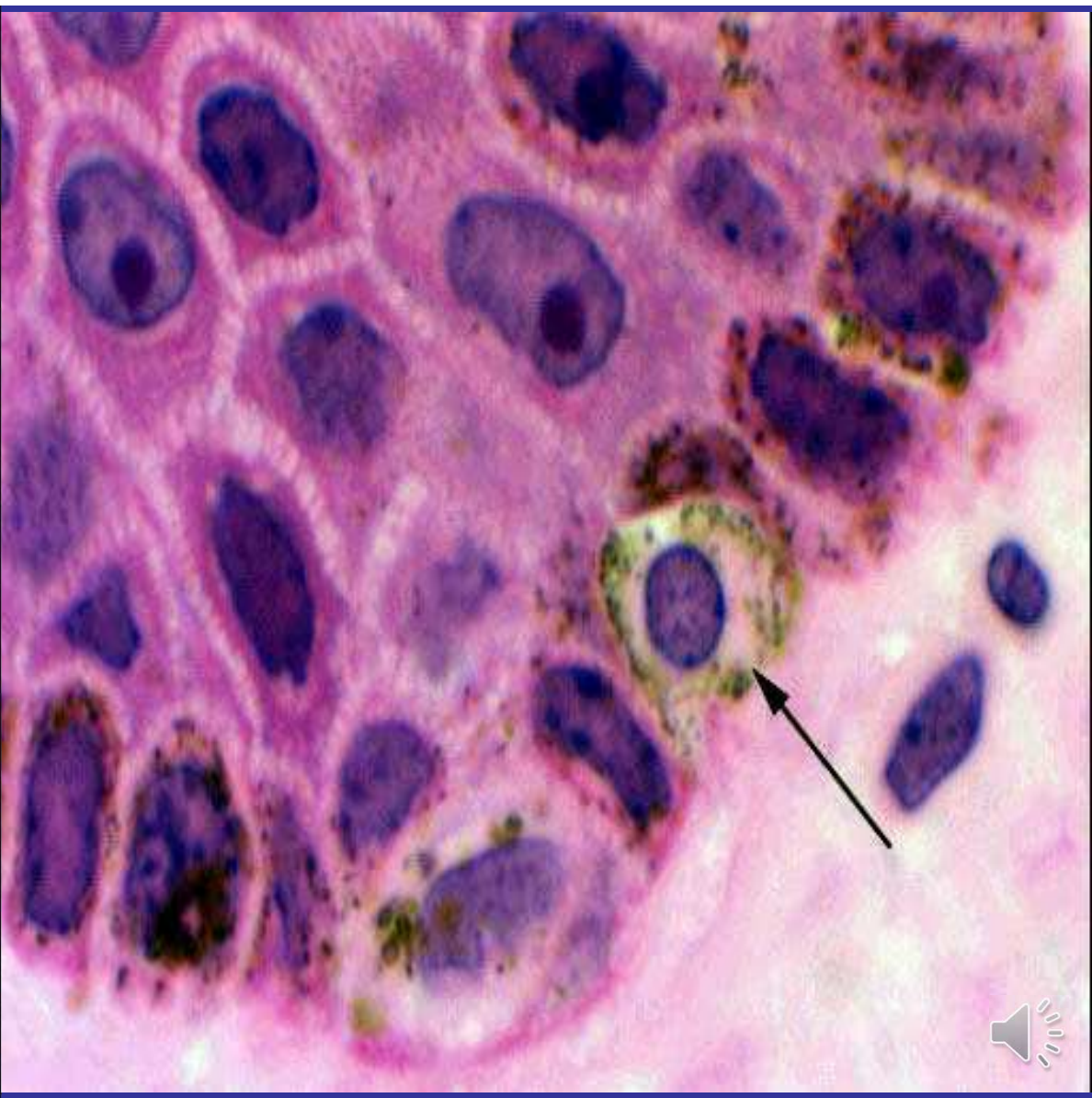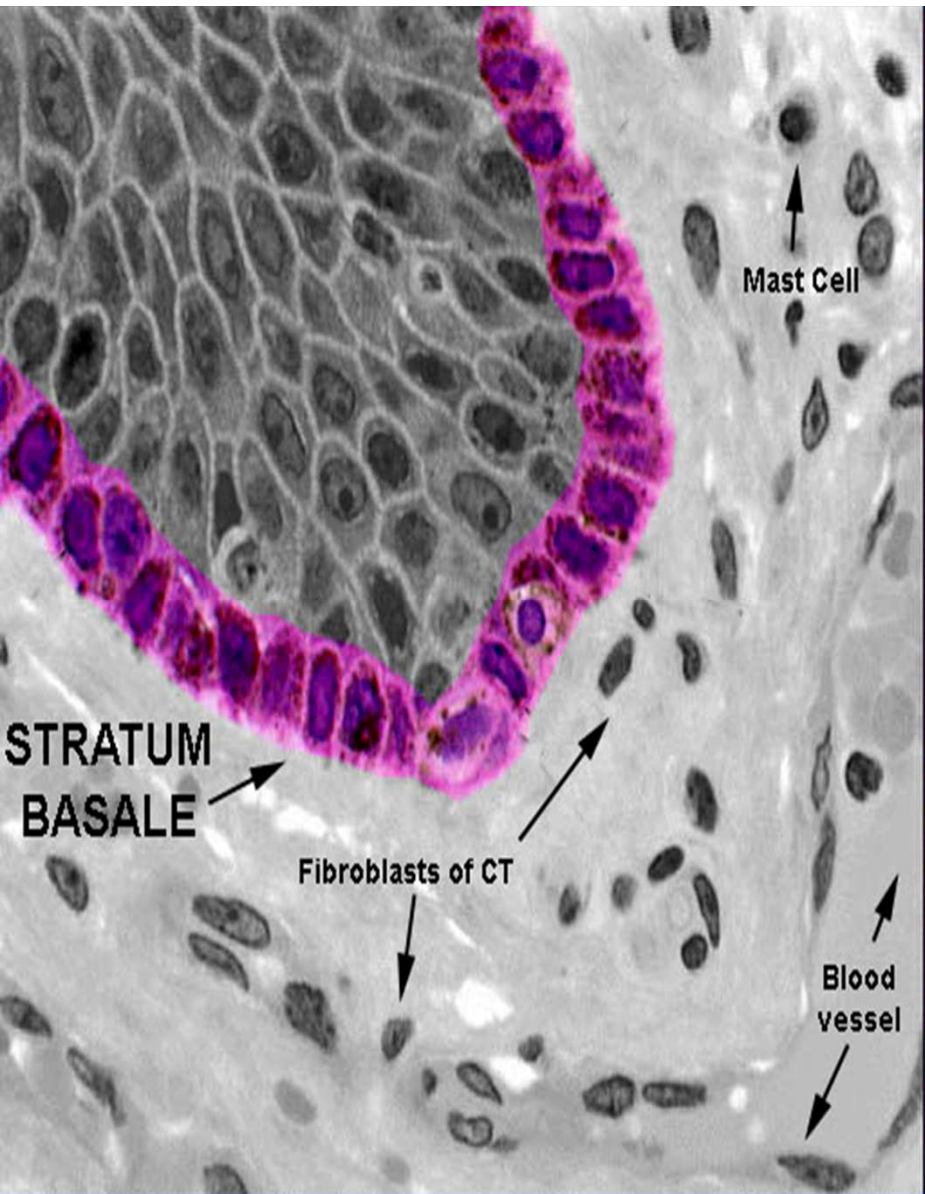


# Merkel nerve

- **endings** are mechanoreceptors found in the skin and mucosa that provide touch information to the brain.
- The information they provide are those regarding pressure and texture.
- Each ending consists of a Merkel cell in close apposition with an enlarged nerve terminal.
- This is sometimes referred to as a **Merkel cell neurite complex**, or a **Merkel disk receptor**.
- A single afferent nerve fibre branches to innervate up to 90 such endings.
- They are classified as slowly adapting type I mechanoreceptors.

- In humans, Merkel cells (along with Meissner's corpuscles) occur in the superficial skin layers, and are found clustered beneath the ridges of the fingertips that make up fingerprints.
- In hairy skin, Merkel nerve endings are clustered into specialized epithelial structures called "touch domes" or "hair disks".
- (Some other types of mechanoreceptors, such as Pacinian corpuscles and Ruffini endings, are found primarily in subcutaneous tissue.)
- Merkel receptors are also located in the mammary glands.
- Wherever they are found, the epithelium is arranged to optimize the transfer of pressure to the ending.





# Hair and Hair Follicles

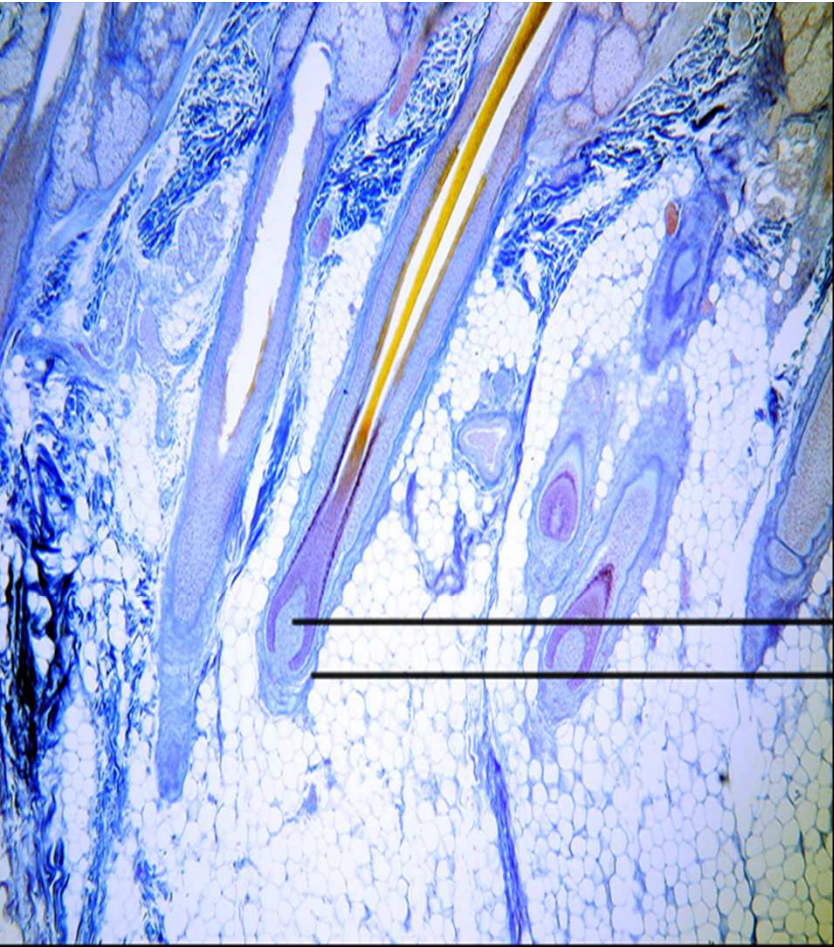


- Hair is a flexible strand made of highly keratinized dead cells.
- The keratin in both hair and nails is hard keratin, a stiffer, more compact version of the soft keratin that dominates the epidermis. It is tougher and its cells do not individually flake off.
- The hair is made by the living hair follicle.

The millions of hairs distributed on the surface of the human body have important functions that include

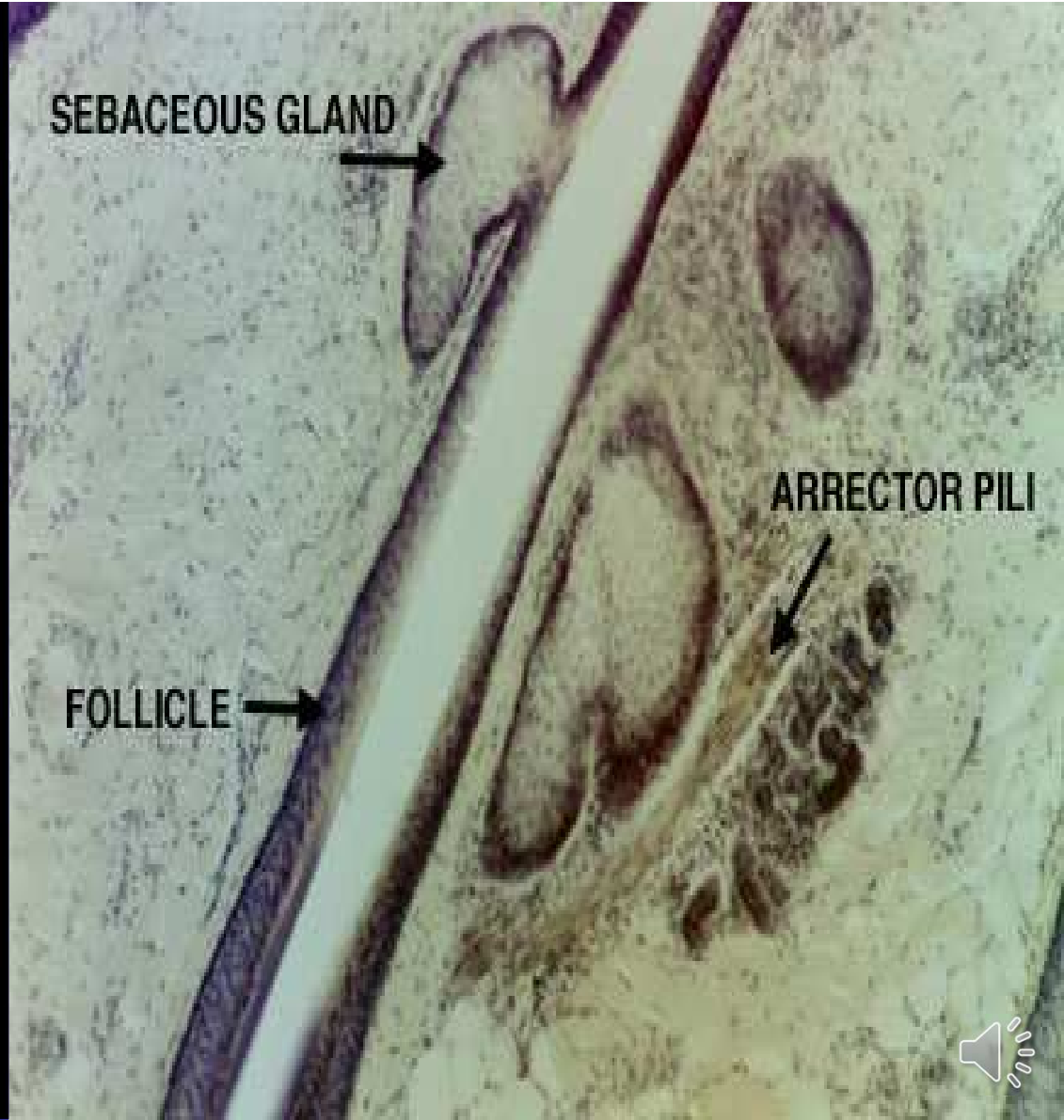
- **Protection.** The hair on the head protects the scalp from sunburn and injury. Hair within the nostrils entraps particles before they travel deeper into the respiratory system, whereas hairs within the external ear canal protect the ear from insects and foreign particles. Eyelashes protect the eyes.
- **Facial expression.** The hairs of the eyebrows function primarily to enhance facial expression.
- **Heat retention.** Hair on the head prevents the loss of conducted heat from the scalp to the surrounding air. Individuals who have lost their scalp hair release much more heat through the scalp than those who have a full head of hair.
- **Sensory reception.** Hair has associated tactile receptors (hair root plexuses) that detect light touch.
- **Visual identification.** Hair characteristics are important in determining age and sex, and in identifying individuals. (Hair analysis also assists in determining animal species.)
- **Chemical signal dispersal.** Hairs help disperse *pheromones*, which are chemical signals involved in attracting members of the opposite sex and in sex recognition. Pheromones are secreted by specific sweat glands onto hairs in the axillary and pubic regions, as described shortly.





Hair papilla  
Hair bulb

Scalp (100x)

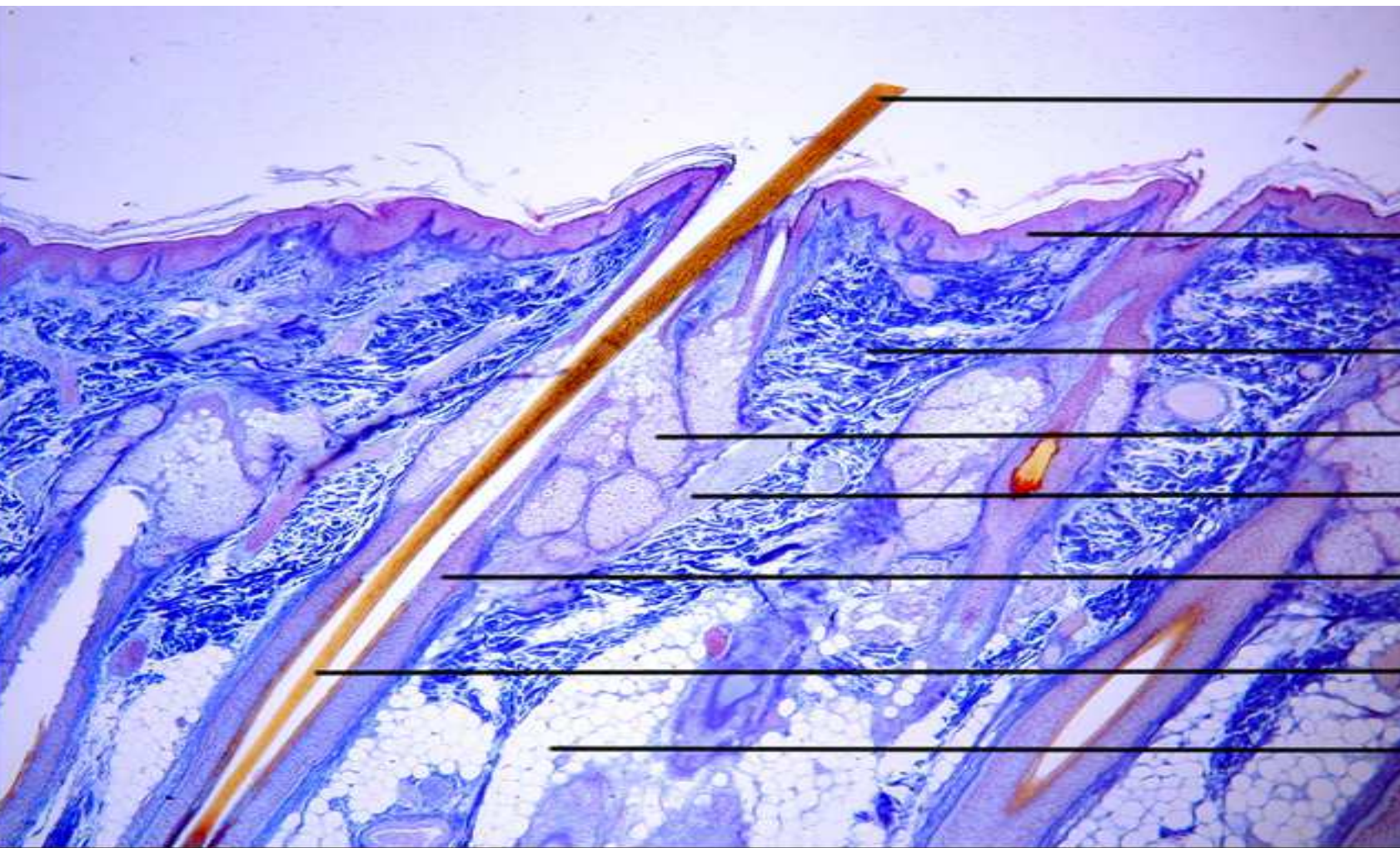


SEBACEOUS GLAND

ARRECTOR PILI

FOLLICLE





Hair shaft

Epidermis

Dermis

Sebaceous gland

Arrector pili muscle

Hair follicle





Hair root

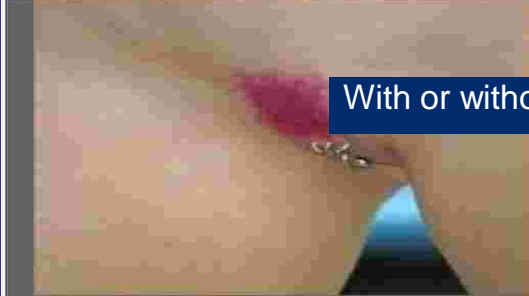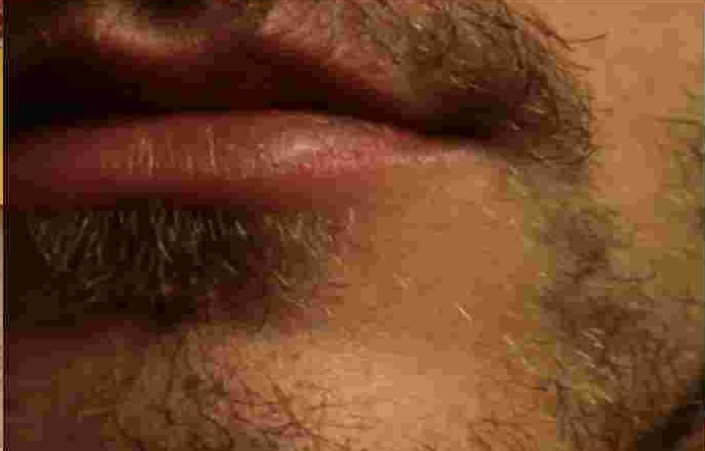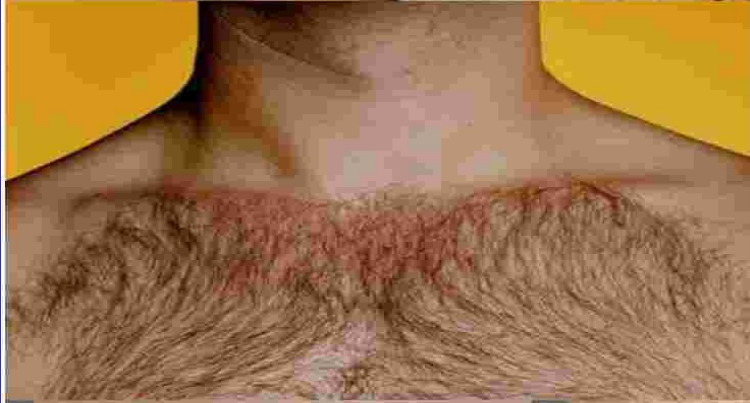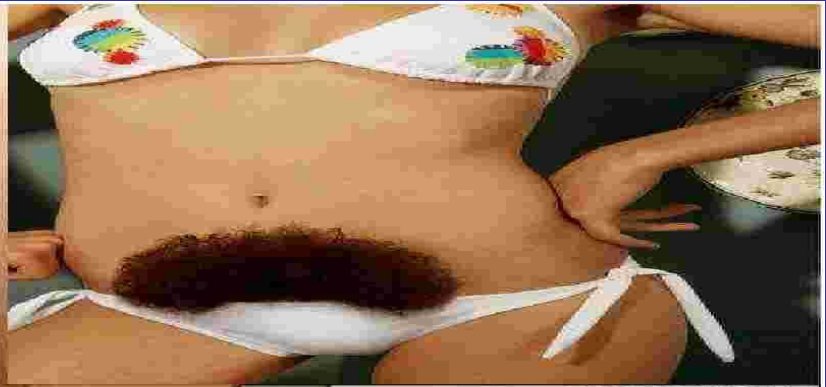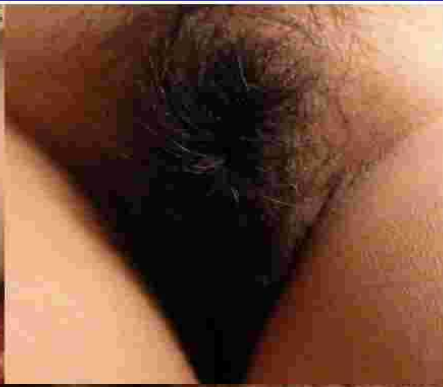
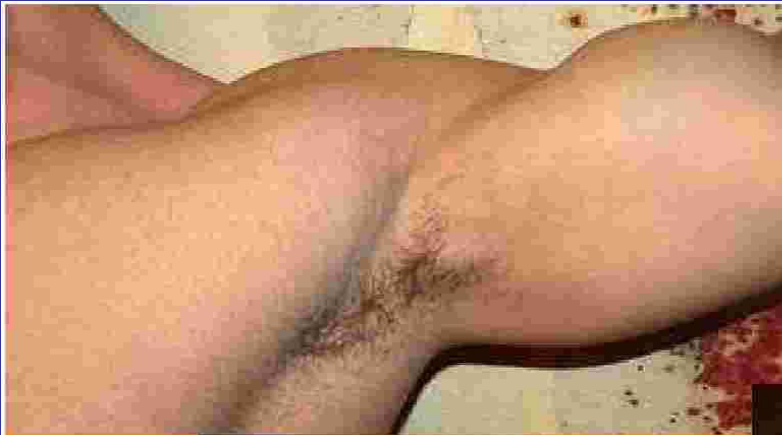Subcutaneous layer

Scalp (40x)

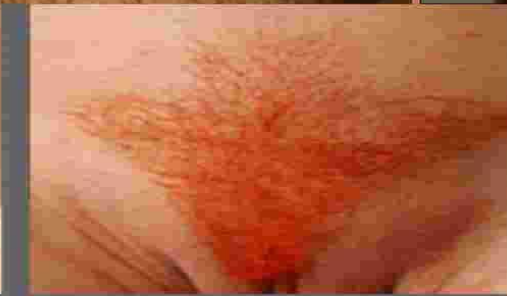

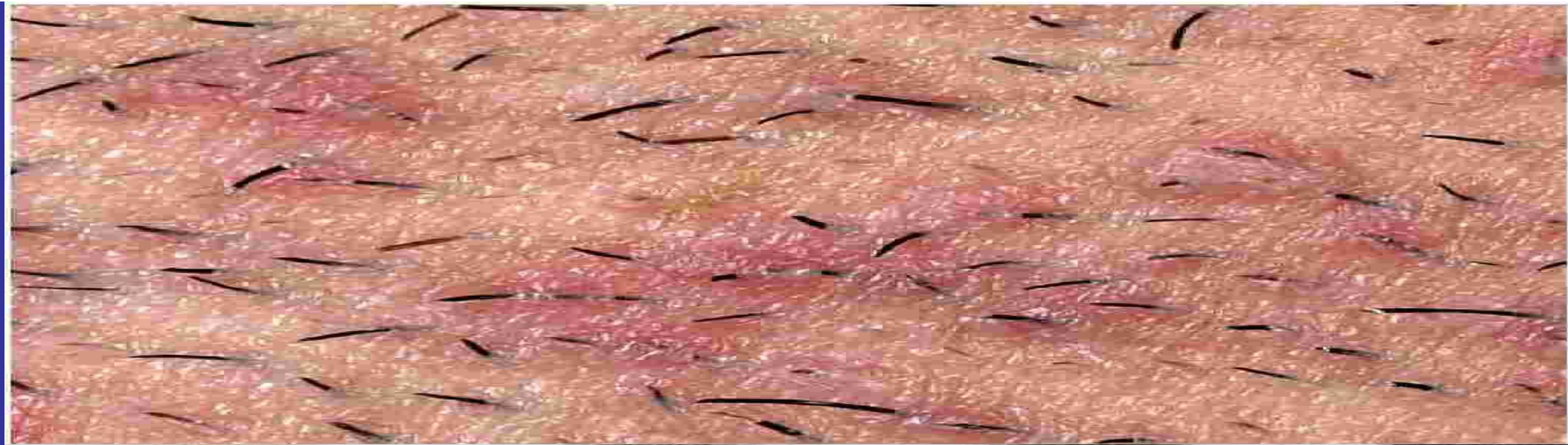
Hair  
ladies do you  
really know  
now the color  
of your hair?





With or without style





All natural hair colors are the result of two types of hair pigment.

Both of these pigments **are melanin types**, produced inside the hair follicle and packed into granules found in the fibers

**-Eumelanin** is the dominant pigment in

- brown hair,
- black hair,

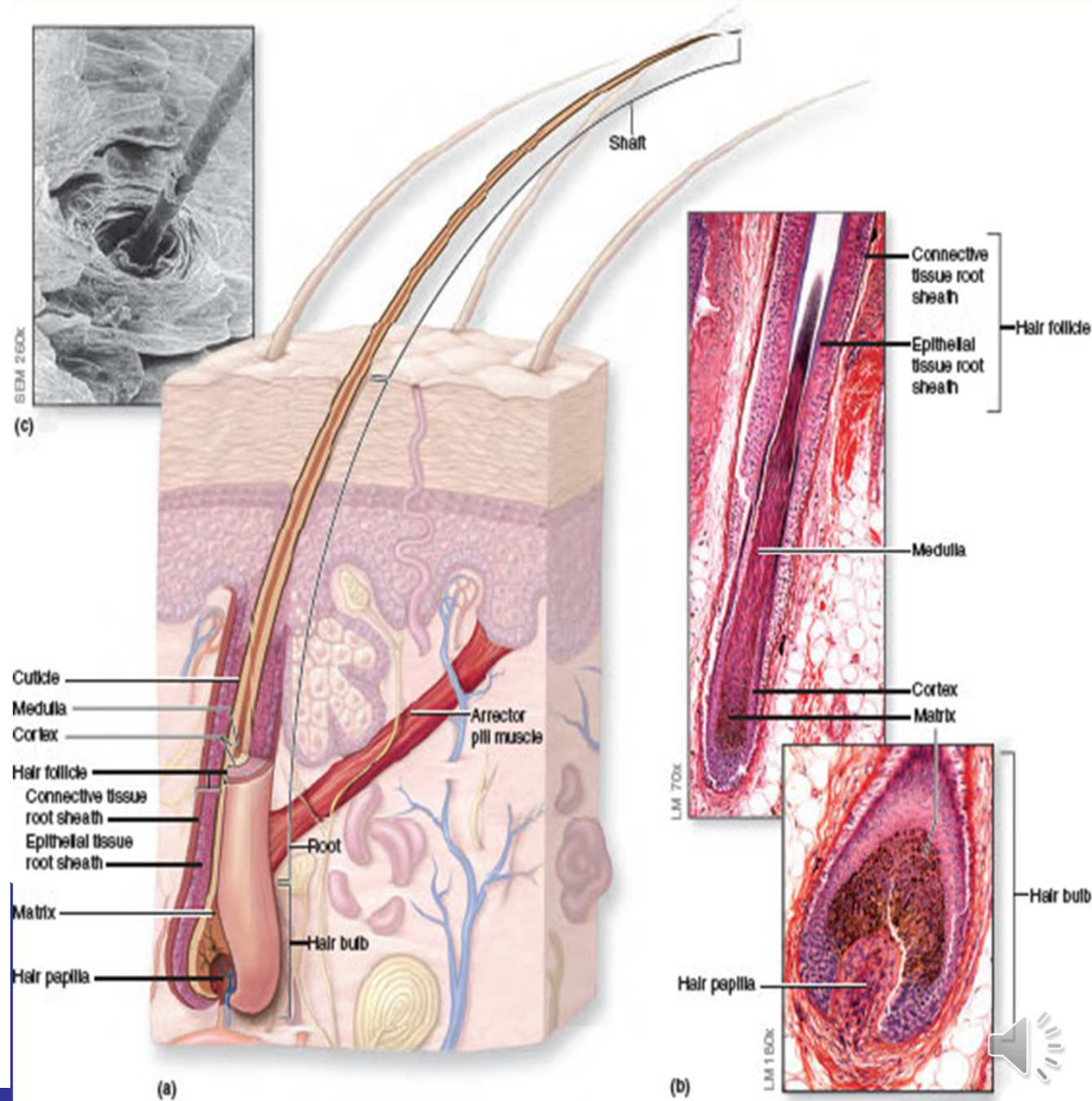
**-Pheomelanin** is dominant in red hair.

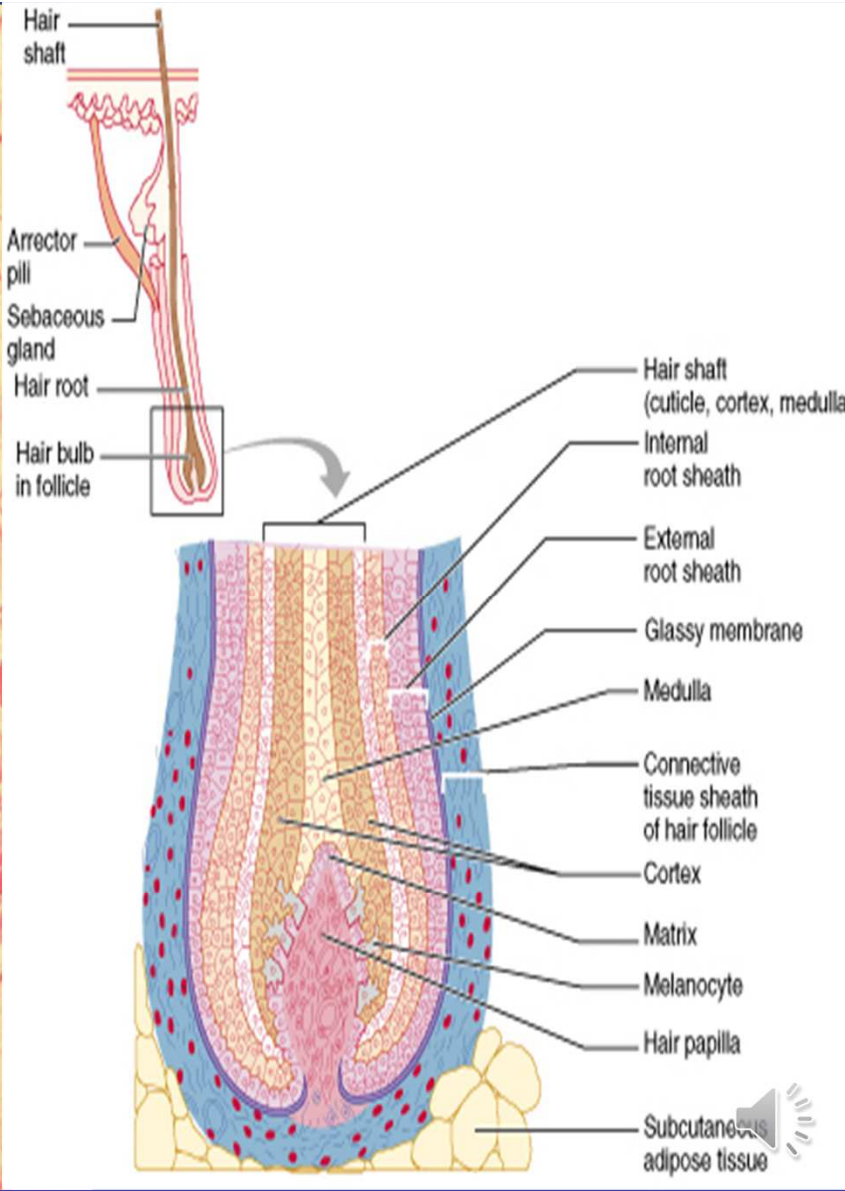
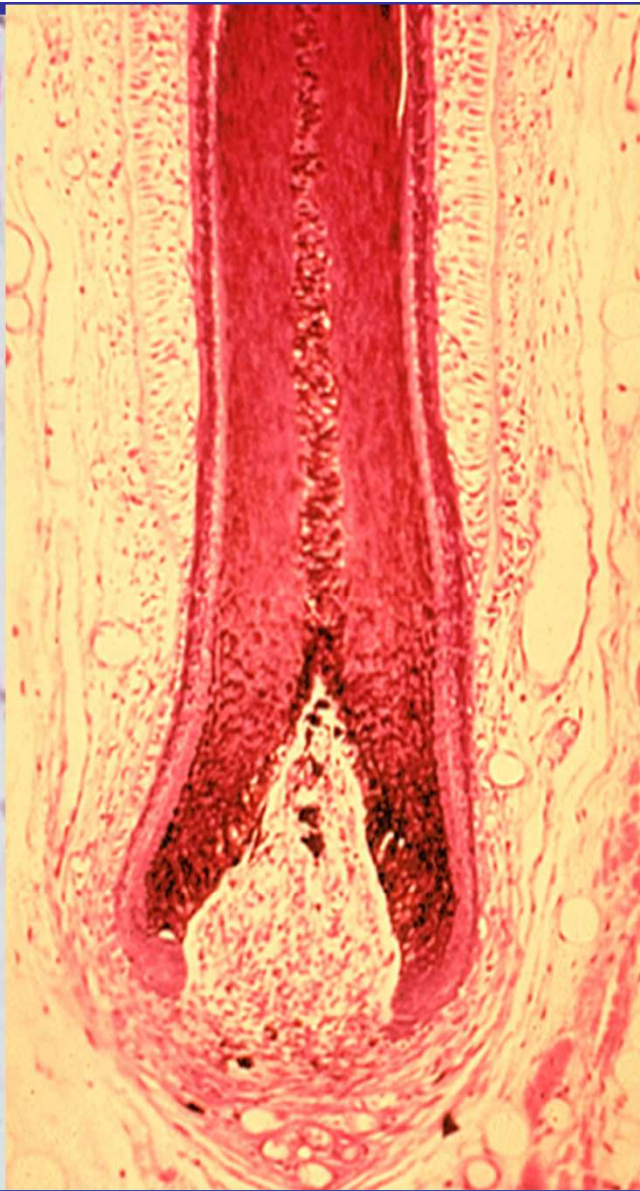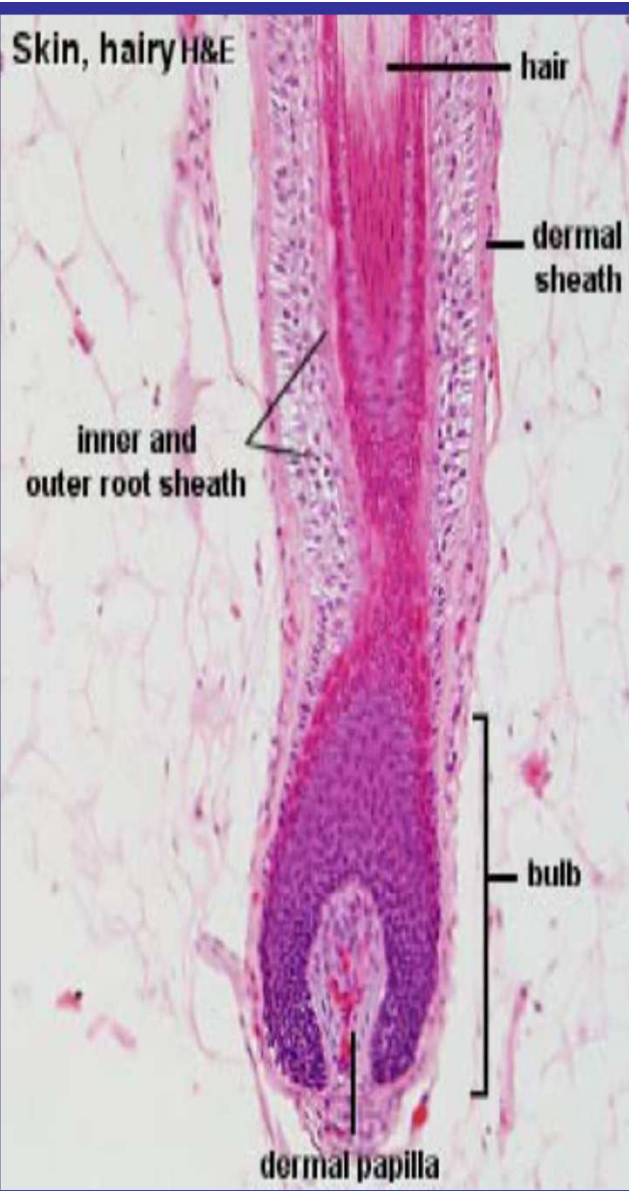
- Blond hair is the result of having little pigmentation in the hair strand.
- Gray hair occurs when melanin production decreases or stops



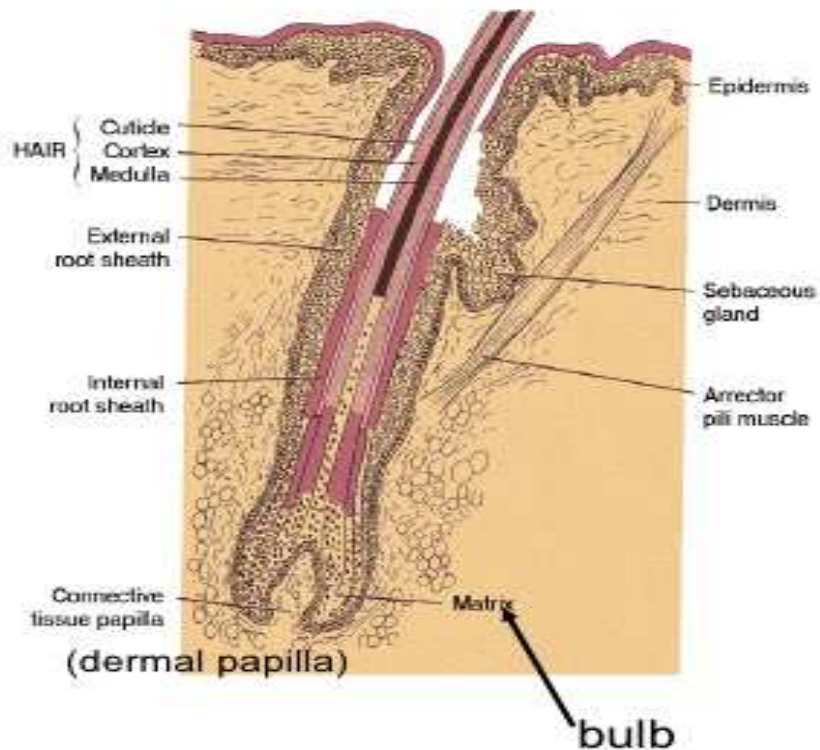
## Hair and Hair Follicles

- Hair consists of a shaft which protrudes from the skin and the root which is within the skin.
- At the base, the root gets wider forming the hair bulb.
- The hair consists of 3 concentric regions:
  - **Medulla** → the innermost region consisting of large cells and air spaces.
  - **Cortex** → surrounds the medulla and consists of flattened keratinized cells
  - **Cuticle** → outer layer of flat keratinized cells that overlap like shingles with their free edges pointing upward.
- The hair follicle surrounds much of the hair root.
- It contains an outer connective tissue sheath and an inner epithelial root sheath.
- At the base of the hair follicle is a single layer of mitotic cells derived from the stratum basale.
- This is the hair matrix.
- All the cells of the hair are derived from the hair matrix.
- Just beneath the hair matrix is an obvious dermal papilla called the hair papilla.
- It contains the blood vessels that nourish the matrix and the cells of the hair follicle.






# Structures of skin: hair follicle



- **Invagination of epidermis**
- **Hair contains keratin and melanin**
- **Dermal papilla**
  - **Connective tissue invagination into bulb, has capillary network**
- **Matrix**
  - **Germinative layer adjacent to dermal papilla**
  - **Also contains melanocytes**
- **Sebaceous gland**
  - **Secretion empties into hair follicle**
- **Arrector pili muscle**
  - **Smooth muscle, inserts on hair follicle and base of epidermis**





Hair shaft

Epidermis

Dermis

Sebaceous gland

Arrector pili muscle

Hair follicle

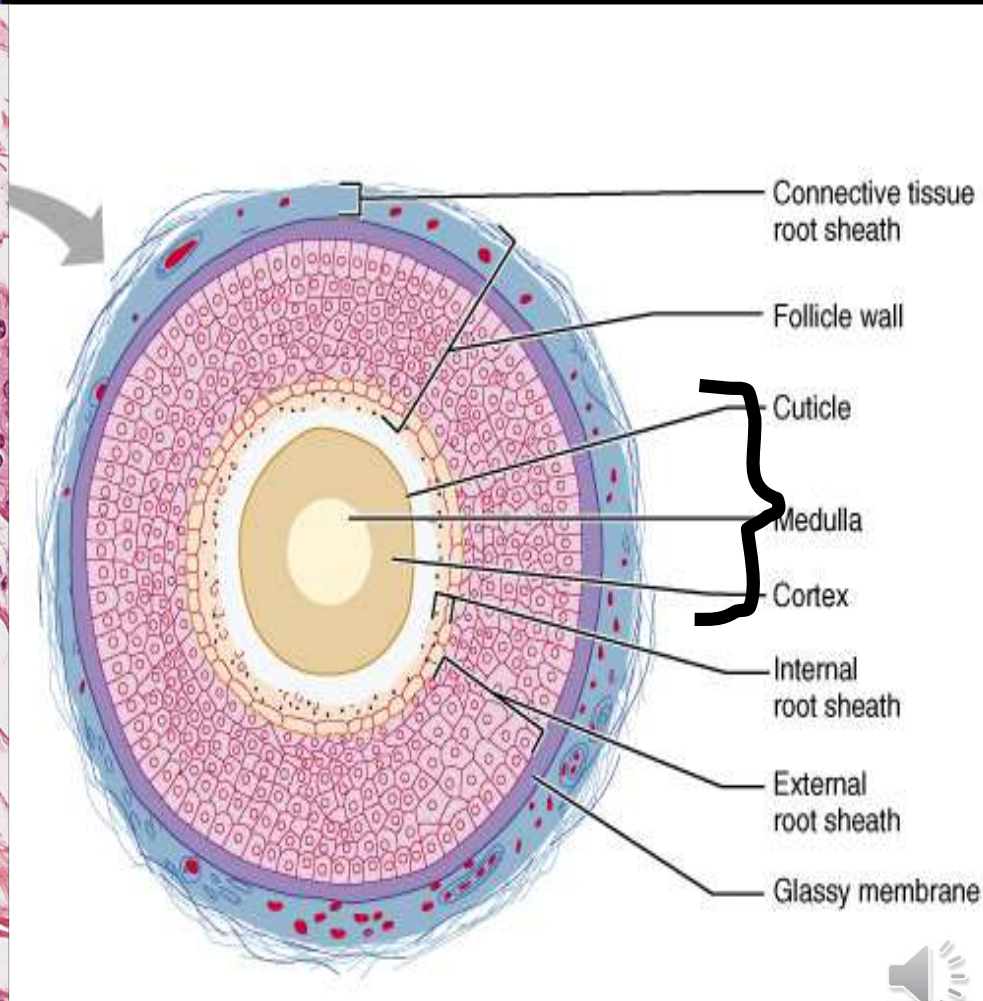
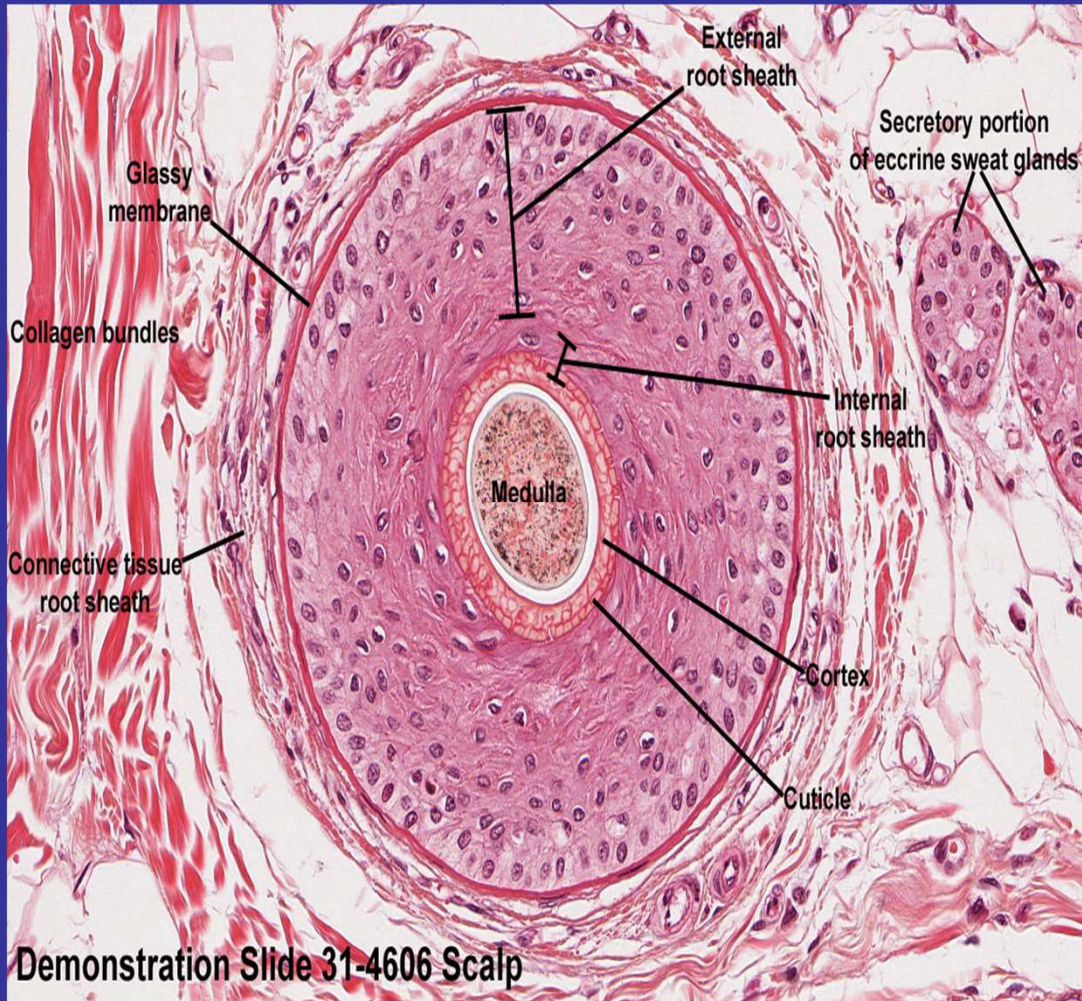
Hair root

Subcutaneous layer

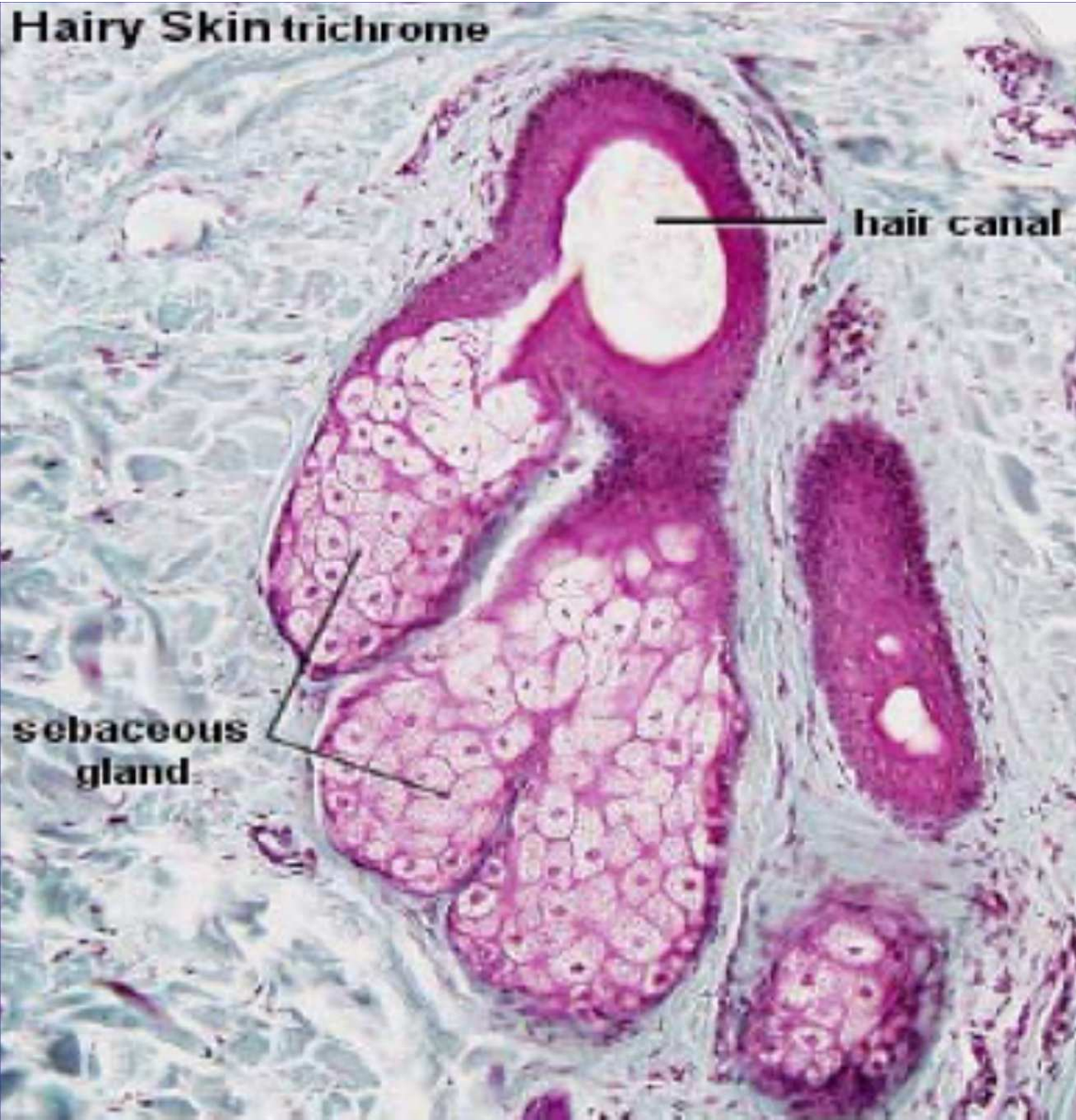
Scalp (40x)



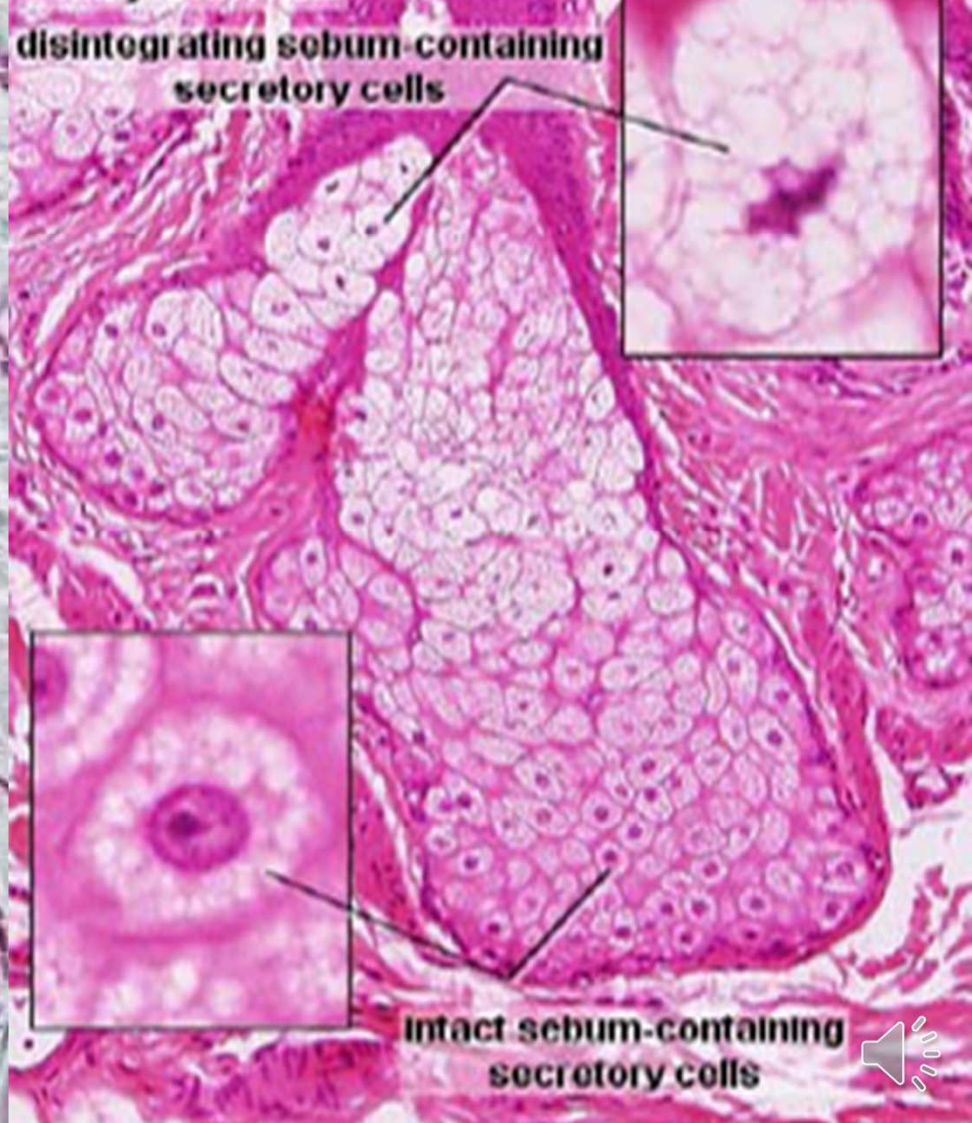
Notice the 3 layers of the hair itself.

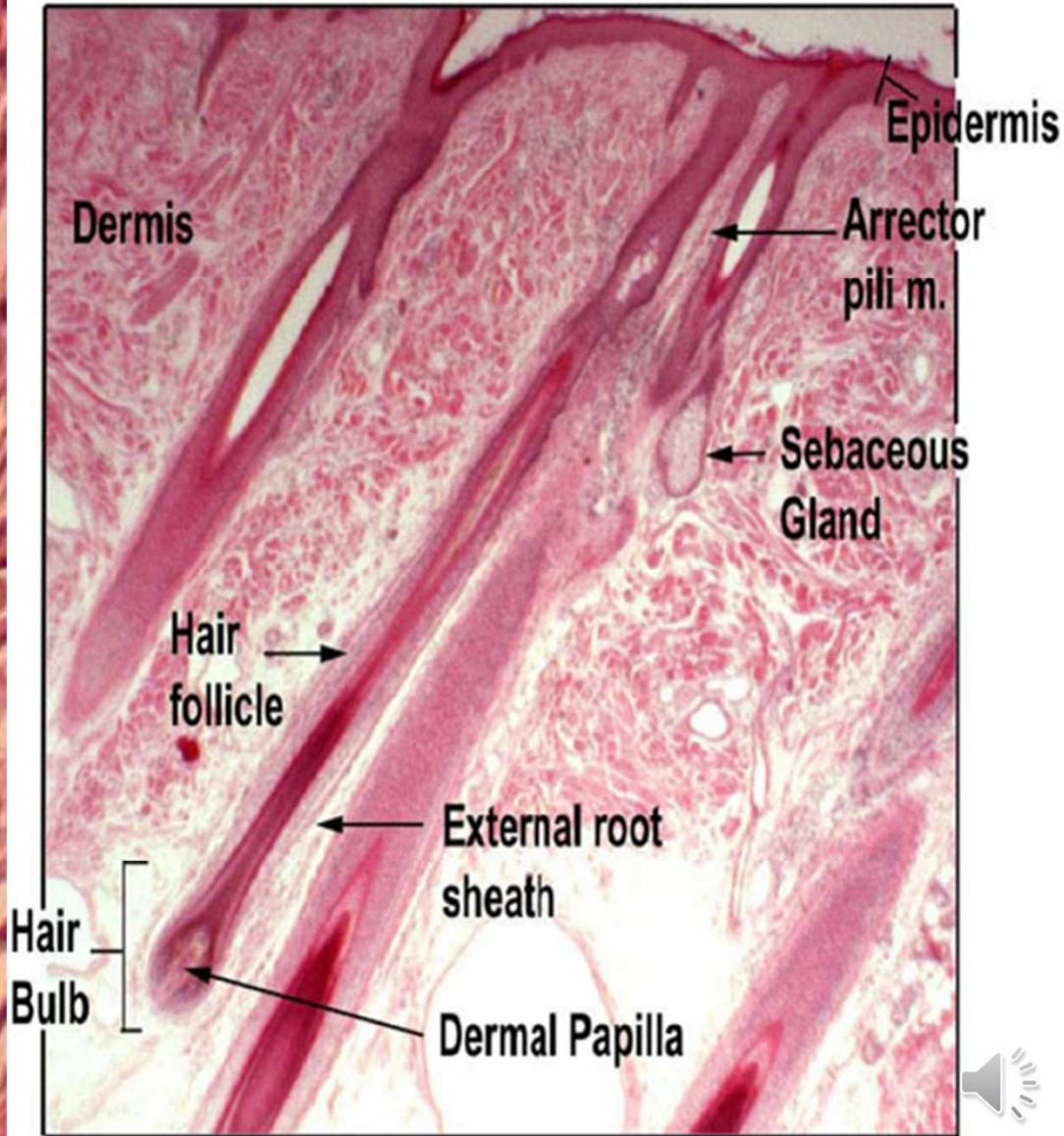
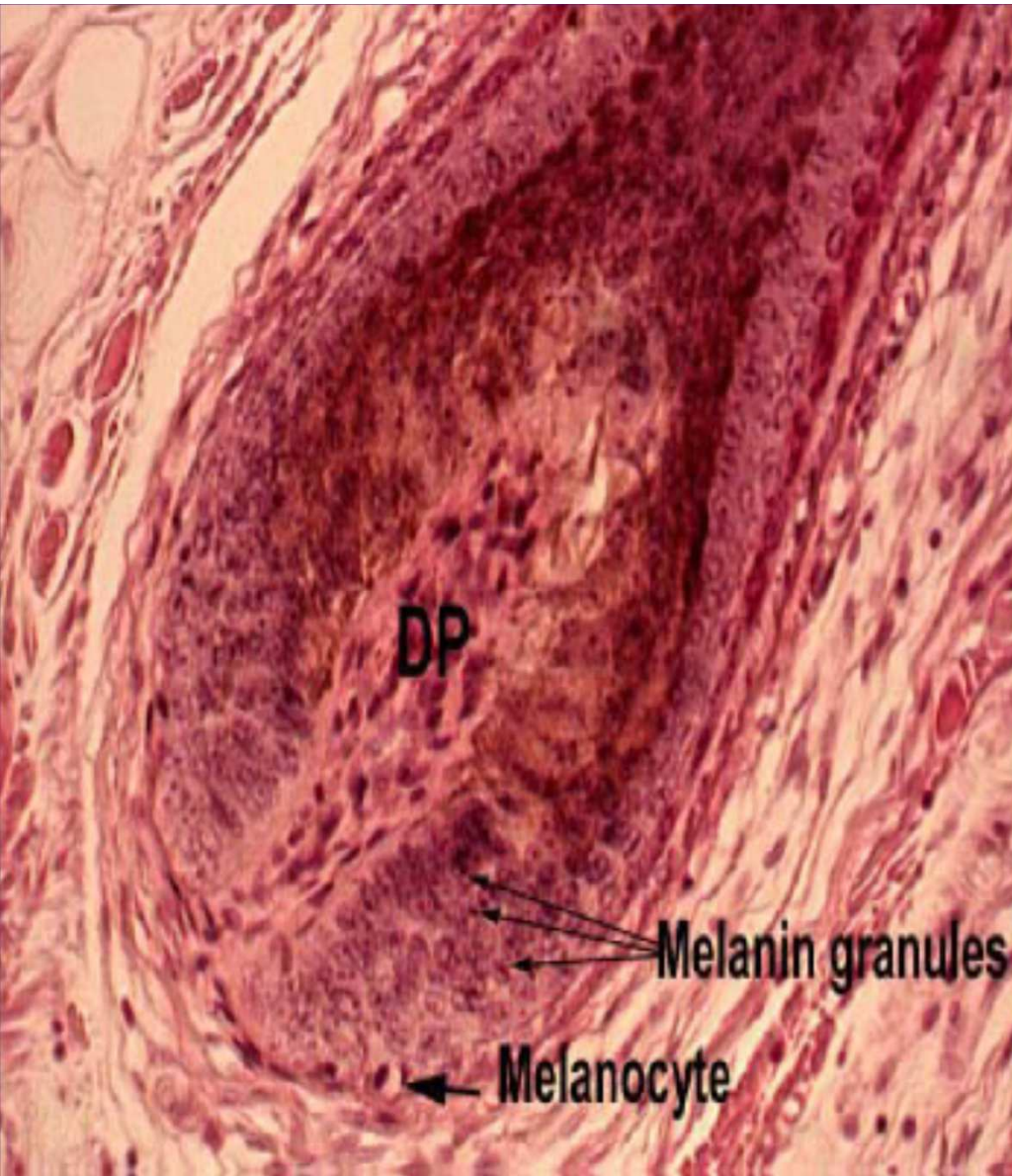

**Hairy Skin trichrome**



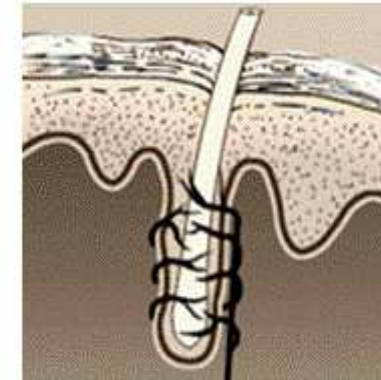
**Hairy Skin H&E**



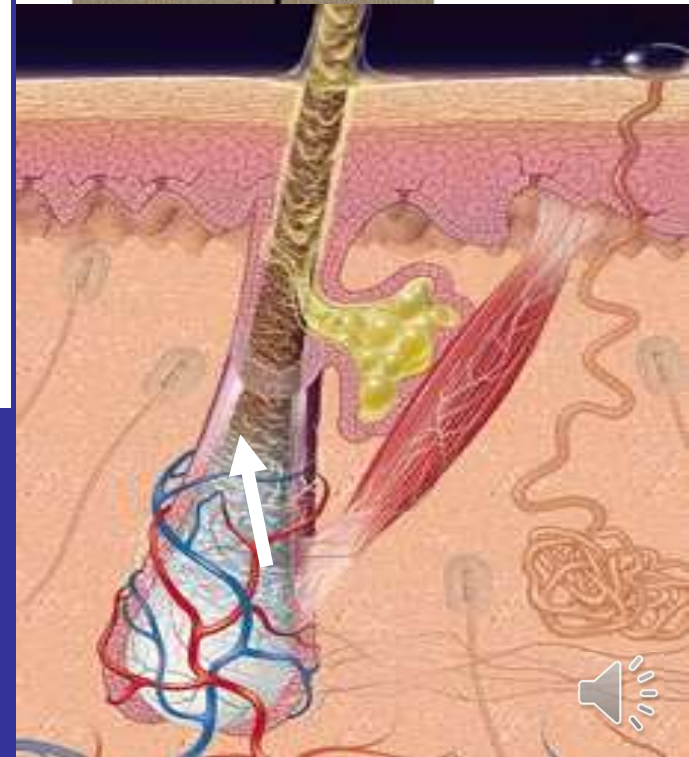


# Hair and Hair Follicles

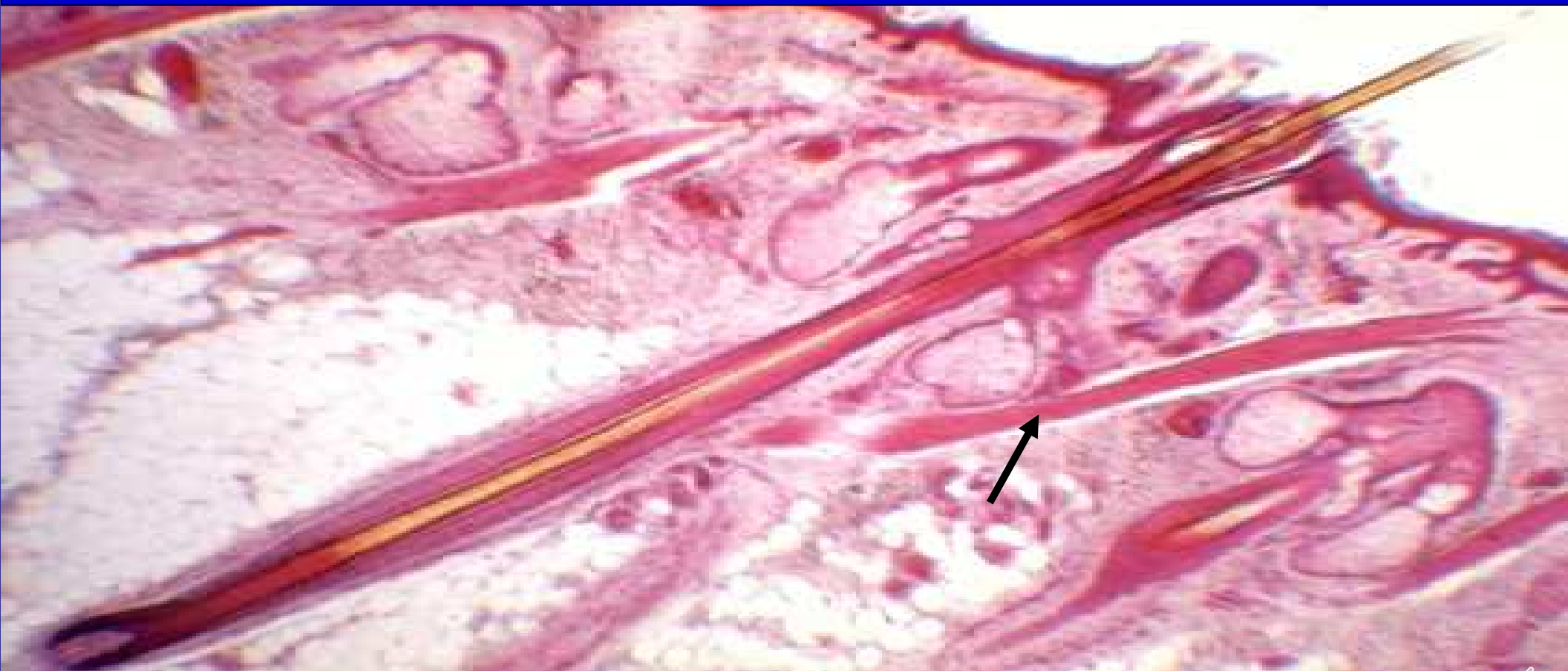- Wrapped **around the bulb of the follicle is a network of sensory nerve endings known as the hair root plexus.**
- Allow the hairs to serve a sensory function.
- **Attached to each hair is a bundle of smooth muscle known as an arrector pili muscle.**
- In times of fright or cold, these muscles contract and cause the hair to stand on end – and produces goose bumps.
  - Increases airflow in mammals with significant hair (i.e., not humans) and increases the apparent size of an animal with significant hair. Vestigial in humans.



**Hair  
Receptors**



The arrow indicates an arrector pili muscle. In this picture, you should also try to identify the shaft, root, follicle, hair papilla, and sebaceous gland.



Notice the hair shaft, hair follicle, papilla, and the multiple sebaceous glands.





**Hair grows everywhere on the external body except for :**

- **Mucous membranes**
- **Glabrous skin**, such as that found on the palms of the hands, soles of the feet, and on the lips.

**Hair follows a specific growth cycle with three distinct and concurrent phases:**

- **anagen,**
- **catagen,**

- Each has specific characteristics that determine the length of the hair.
- All three occur simultaneously; one strand of hair may be in the anagen phase, while another is in the telogen phase.

The body has different types of hair, including vellus hair and androgenic hair, each with its own type of cellular construction.

The different construction gives the hair unique characteristics, serving specific purposes, mainly warmth and protection.



# Hair Growth and Replacement

There are three stages of the hair growth cycle: **anagen, catagen, and telogen:**

**1. The anagen phase** is the **active phase of growth where living cells of the hair bulb are rapidly growing, dividing, and transforming into hair.**

- It is the longest part of the growth cycle and lasts from about **18 months to as much as 7 years**, depending on the **genetics of the person**.
- During the anagen phase, each hair strand grows about one-third of a millimeter per day, which equals 0.5 to 1.0 cm per month.
- **On a normal scalp, 80–95% of follicles are in anagen phase.**

**2. The catagen phase** is a **brief regression period where cell division ceases** and the follicle undergoes involution.

- This very short phase lasts for about 3 to 4 weeks.

**3. The telogen phase** is the **resting phase** and is usually **the phase where the hair is shed** (these hairs are the ones we find in our comb or brush).

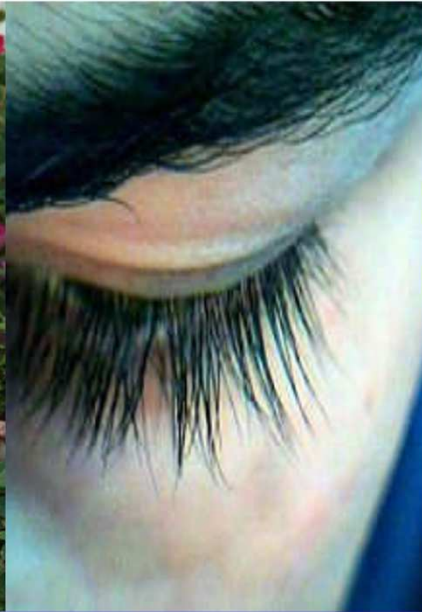- **After 3 to 4 months in the telogen phase, the cells of the hair bulb start regrowing, and the follicle reenters the anagen phase.**





## **Eyebrows and eyelashes**

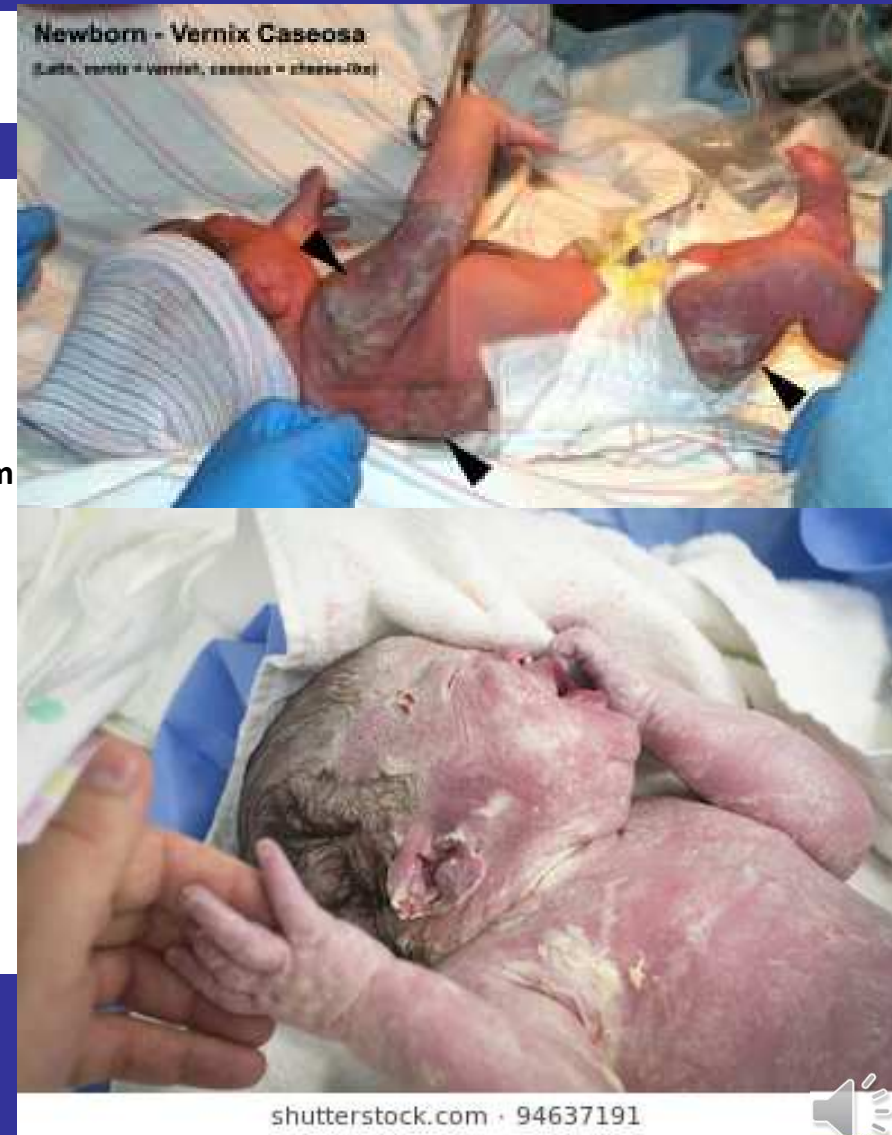- Eyelashes and eyebrows help to protect the eyes from dust, dirt, and sweat
- The eyebrows provide some protection to the eyes from dirt, sweat, and rain.
- More importantly, they play a key role in non-verbal communication.
- dirt.



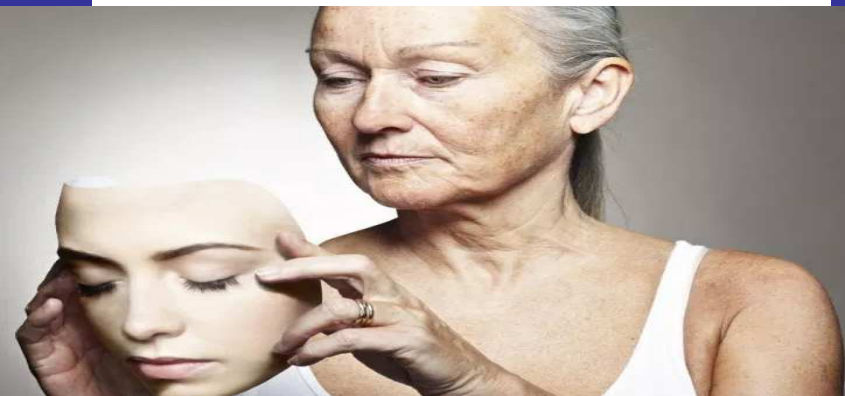# Vernix Caseosa

Has several different potential functions and a variable composition.

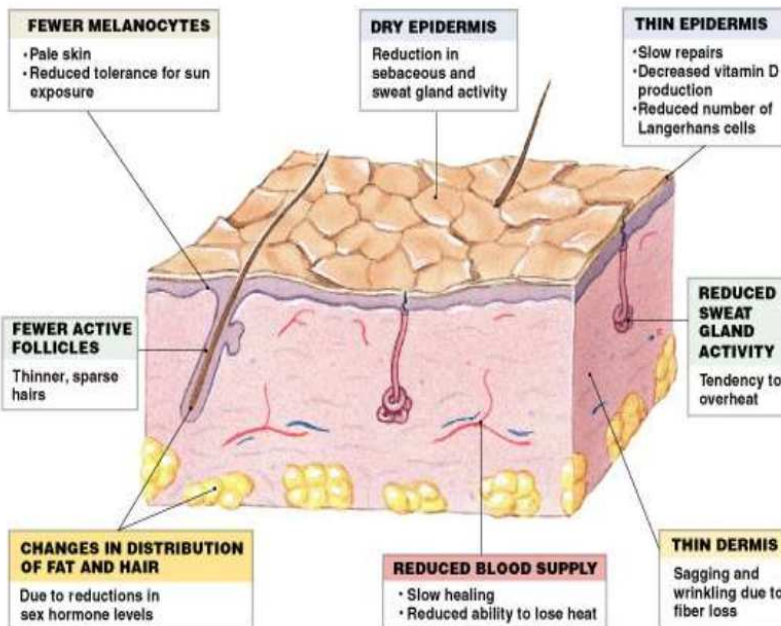
- a highly variable coating of the fetal skin
- high water content (80%) largely compartmentalized within fetal corneocytes (cells forming the stratum corneum)
- develops cranio-caudally production coincides in utero with terminal differentiation of the epidermis and formation of the stratum corneum
- primarily composed of sebum, cells that have sloughed off the fetus's skin and shed lanugo hair
- can be absent in preterm infants
- dehydration and rehydration processes occur two to four times faster at 37 degrees celcius than at room temperature
- towards term fragments of vernix can mix into the amniotic fluid resulting in (normal) turbidity
- fetal swallowing of amniotic fluid mixed with fragments of vernix can also occur



## Aging and the Integumentary System

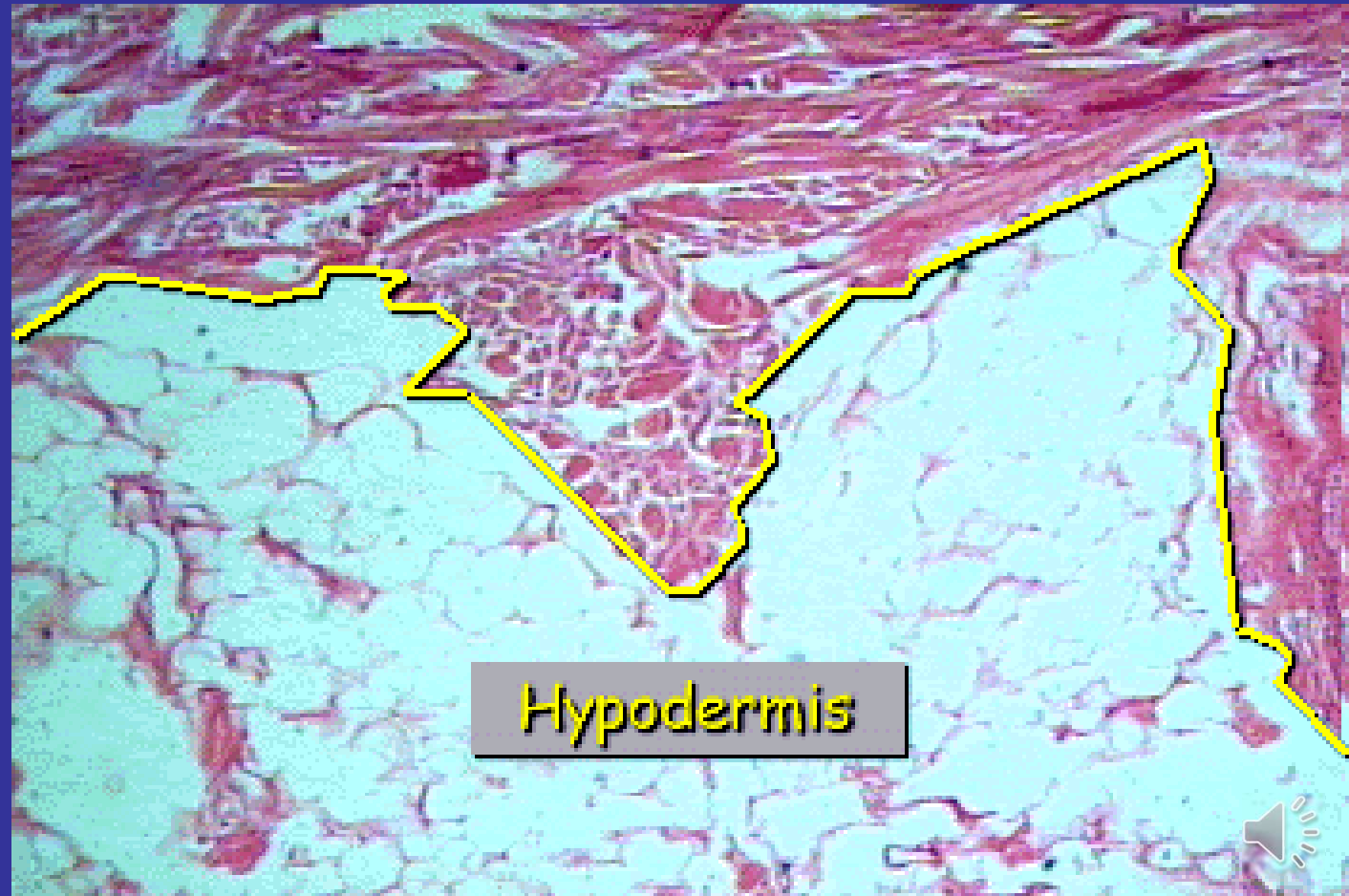


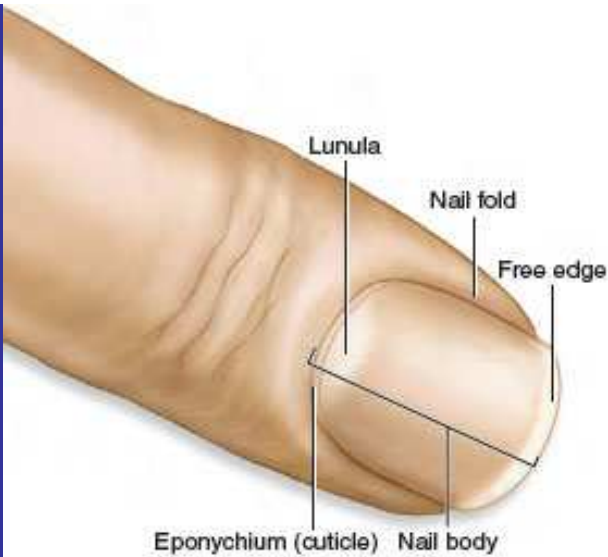
- The epidermis thins as germinative cell activity declines.
- The number of Langerhans cells decreases, affecting the immune system.
- Vitamin D production declines, leading to calcium deficiency.
- Melanocyte activity declines.
- Glandular activity declines, reducing the ability to cool oneself.
- Blood supply to the dermis decreases, further reducing cooling ability.
- Hair follicles stop functioning, or produce thinner hairs.
- The dermis thins and loses elastic fibers, resulting in wrinkles.
- Secondary sex characteristics of the integument fade.
- Skin repair slows.



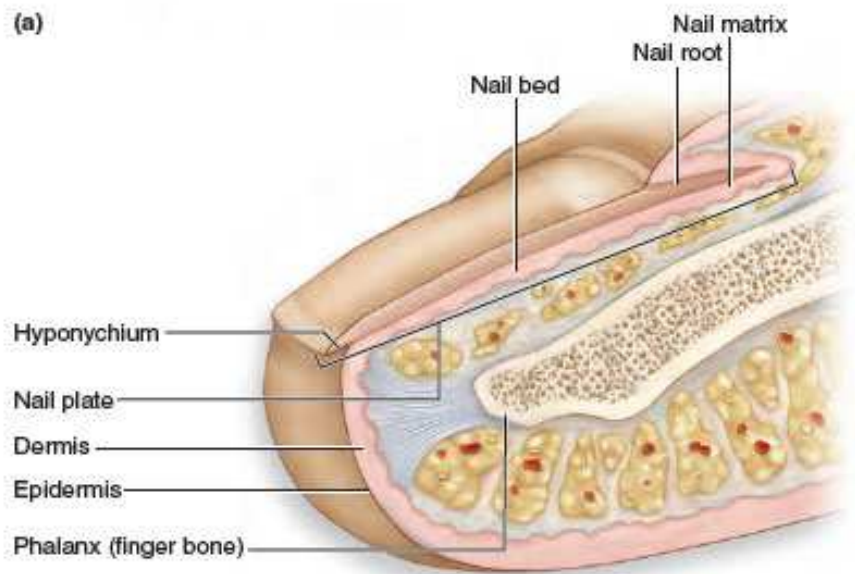
# Subcutaneous Tissue

- A.k.a. the hypodermis or the superficial fascia.
- Deep to the dermis.
- Consists of primarily adipose tissue plus some areolar connective tissue.
- Stores energy, provides insulation and padding.
- Anchors the skin to underlying structures, especially muscles.
- Different distribution between the sexes.





(a)



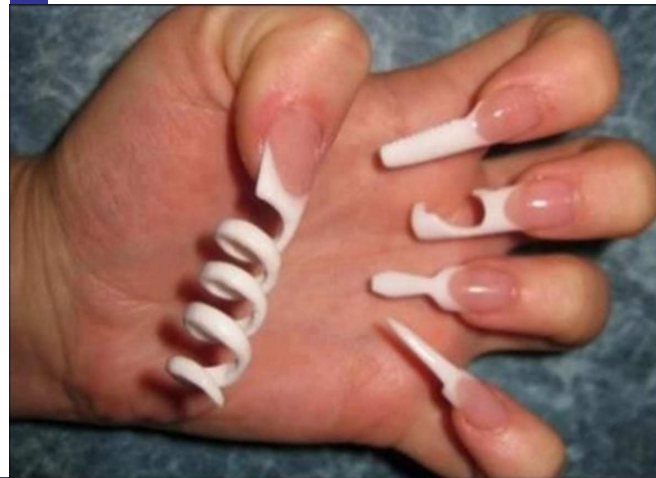(b)

Nails are a hard derivative of the stratum corneum that protect sensitive fingertips.

(a) Surface view of a fingernail.

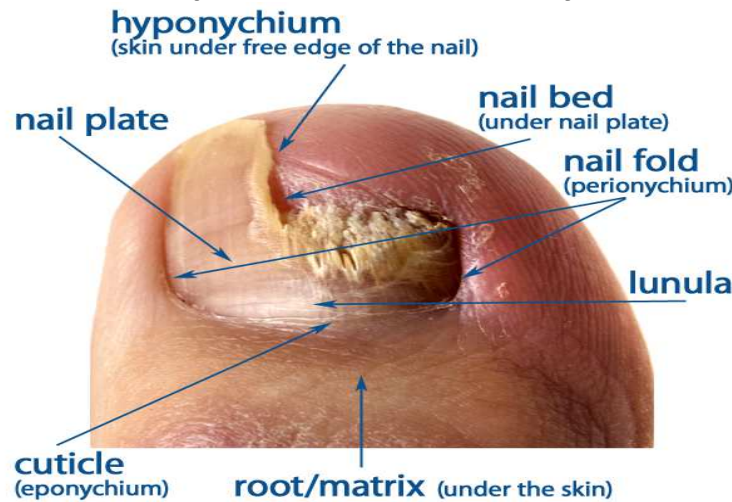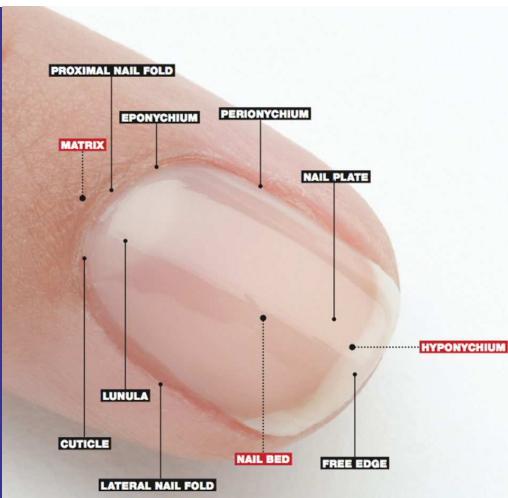
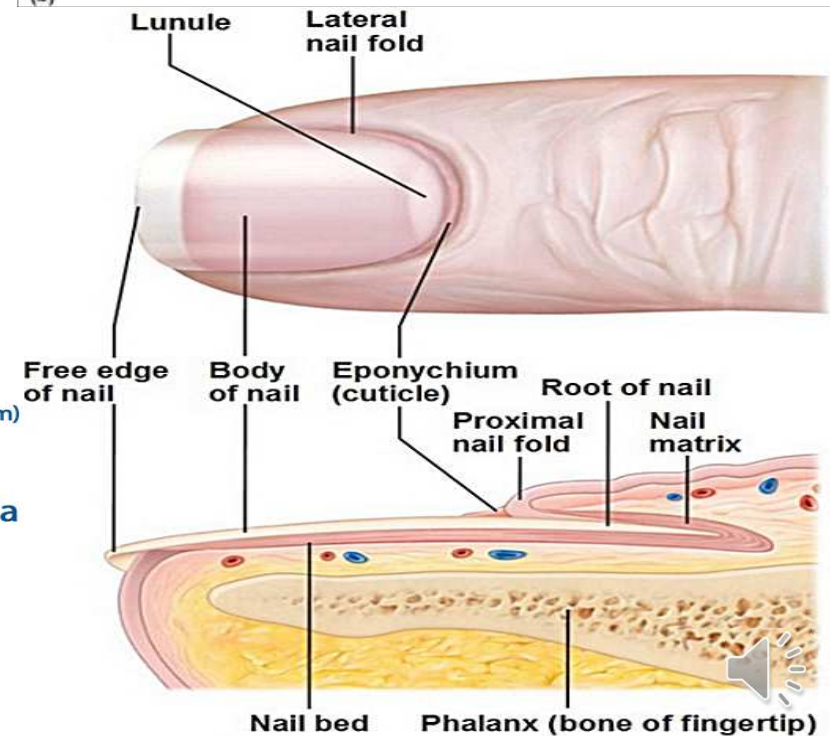
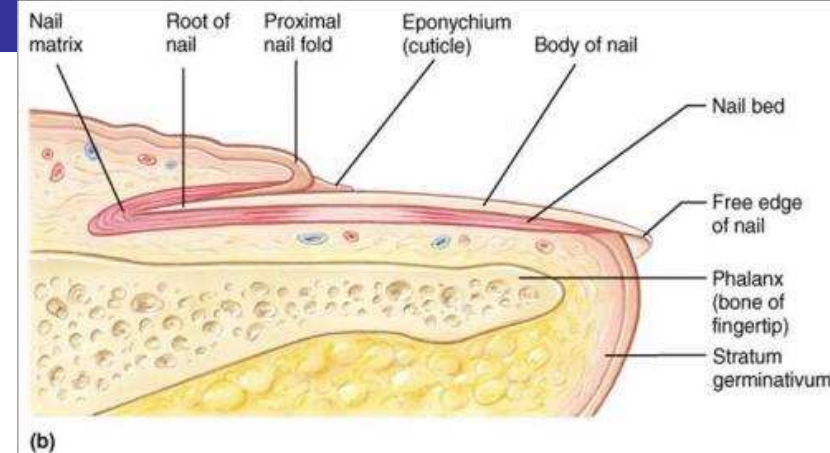
(b) Sagittal section showing the internal details of a fingernail.

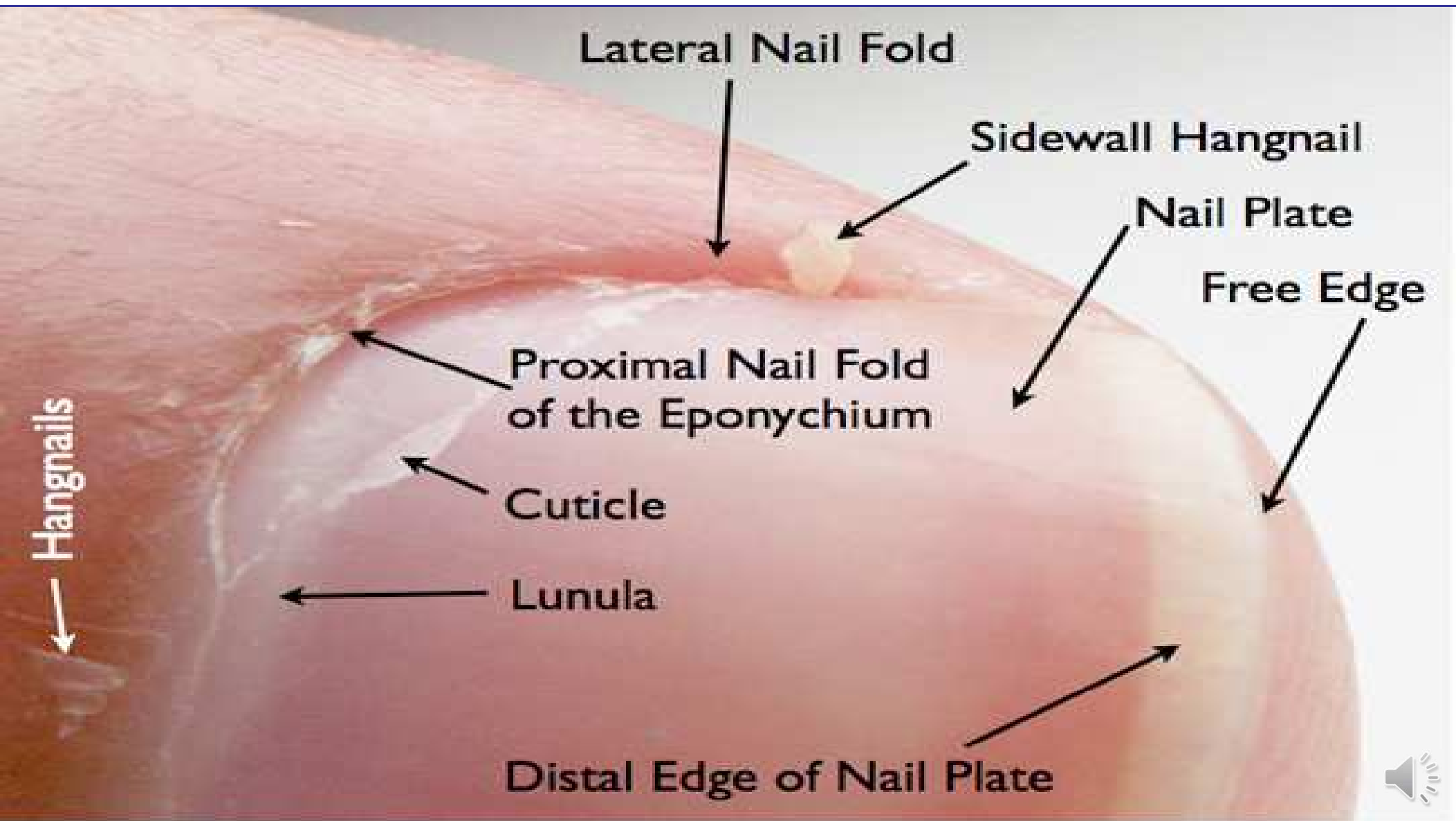
- Modification of the epidermis
- Composed of keratin.
- Composed of a free edge, body, and a root.
- Nail bed—epidermis under the nail.
- Nail matrix—growth occurs here.
- Lunula
- cuticle



**Nails are special keratinized structures of the epidermis that cover the dorsal surfaces of the distal digits.**

- Nail body is the actual nail.
- Nail bed is the epithelium under the nail body.
- Nail root is a fold in the epidermis near the bone of the digit.
- The nail body grows from this region outward.
- Nail grooves are the lateral borders of the nail body.
- Nail folds are the upward folds in the epidermis lateral to the nail grooves.
- Eponychium is the cuticle, an extension of the proximal nail fold that covers the nail root.
- Lunula is the pale area near the eponychium.
- Hyponychium is the fold of epidermis deep to the distal nail body.







Oval



Stiletto



Almond



Lipstick



Round



Pointed



Cut out



Square  
round corners



Edge



Squoval



Ballerina  
or coffin



Square



Trapeze



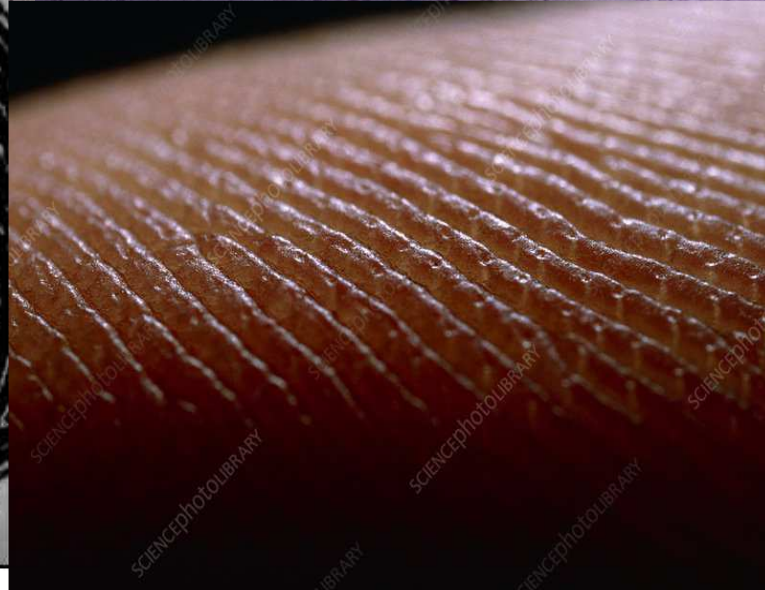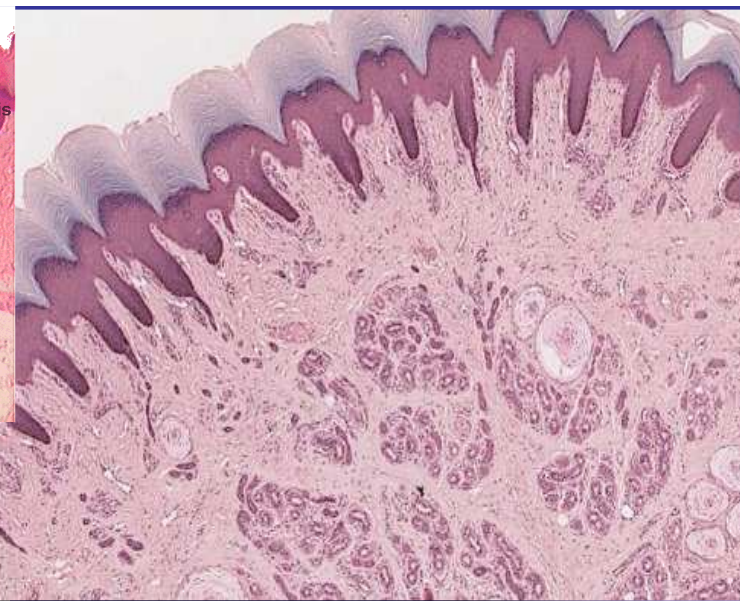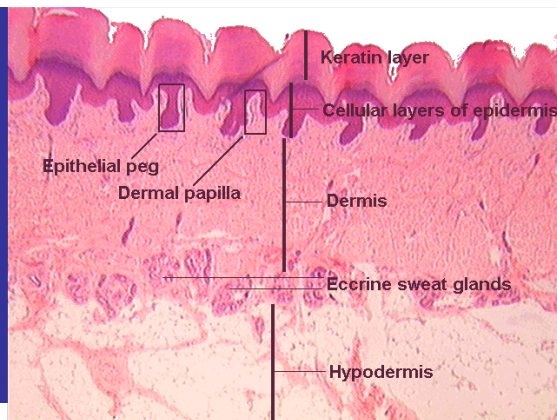
Stiletto  
square



## Fingerprints

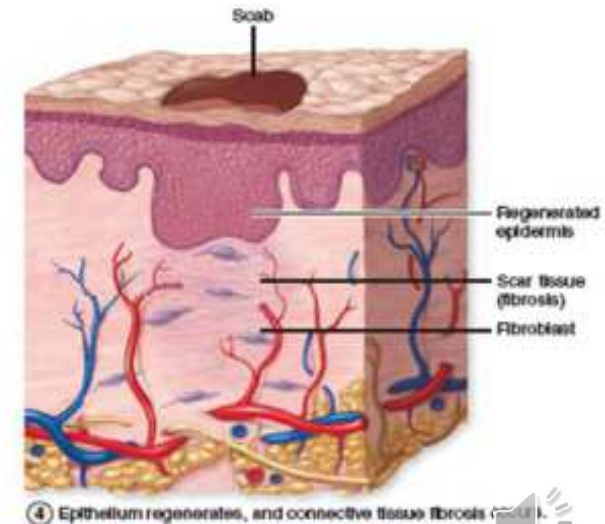
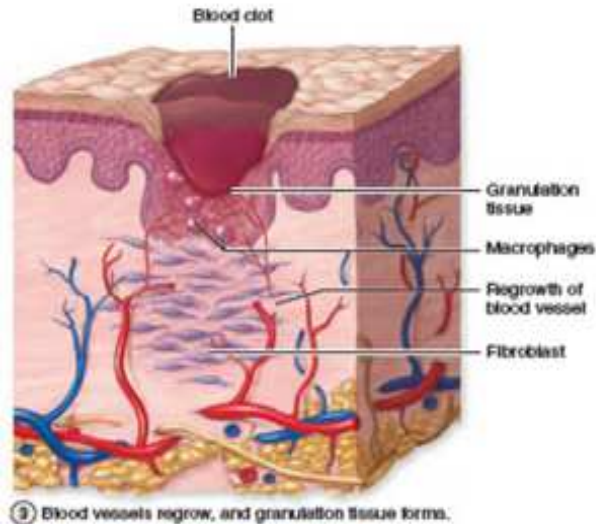
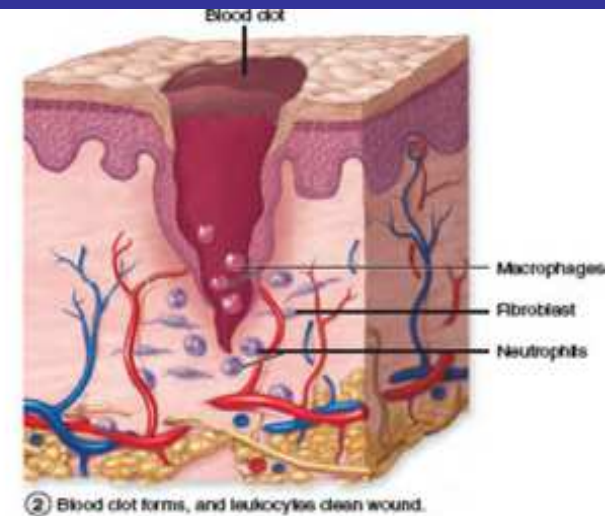
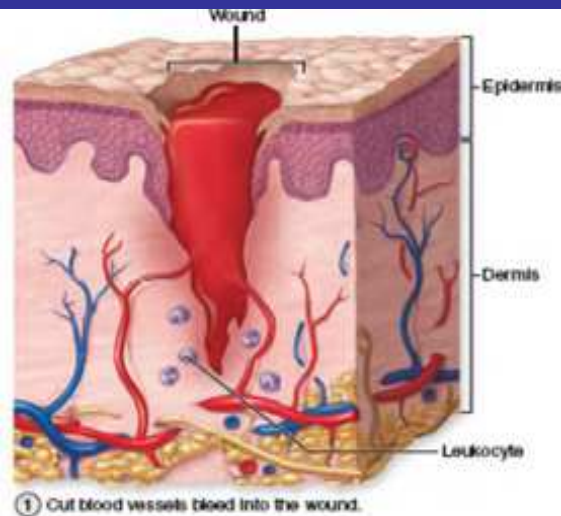
Are epidermal ridges and sweat pores

Extreme Dry Skin Leads to Fingerprint ID Failures



## The Healing Process : How Skin Repairs Itself

- **A. Superficial Wound Healing - Epidermal Repair**
- 1. epidermal cells of stratum basale migrate over area
- 2. contact inhibition - cells stop when they meet
- 3. dead cells sluff off (scab) as new cells replace
- **B. Deep Wound Healing - Dermal Repair**
- 1. inflammatory phase - blood clot, fibroblasts
- 
- **2. migratory phase - scab forms, epidermal migration**
- a. fibroblasts make scar tissue (collagen fibers)
- b. damaged vessels grow into place
- c. granulation tissue - new scar tissue in place
- d. fibroplasia - period of scar formation
- i. hypertrophic scar - normal
- ii. keloid scar - abnormal
- 
- **3. proliferative phase - new growth**
- a. epithelium grows beneath scab
- b. fibroblasts make random collagen deposit (scar)
- c. blood vessels continue to grow
- 
- **4. maturation phase - final healing process**
- a. epidermis is restored
- b. fibroblasts disappear, collagen more organized
- c. blood vessels repaired to normal



| SKIN LAYER  | SKIN FEATURES  |
|---|--|
| <b>STRATUM CORNEUM</b>  | A layer of dead corneocytes. No nuclei or organelles are present, just dried membranes and keratin fibers. Is thicker in thick skin than in thin skin.   |
| <b>STRATUM LUCIDUM</b>  | A thin, transparent layer of lightly stained, flattened keratinocytes. Keratinocytes in this layer have lost their organelles. Keratohyalin has been transformed into translucent eleidin. <b>Remember, stratum lucidum is not present in thin skin.</b>     |
| <b>STRATUM GRANULOSUM</b>   | A thin layer containing keratinocytes that are filled with darkly staining keratohyalin granules. Keratinocytes are semi-dry and flat, with elongated nuclei.  |
| <b>STRATUM SPINOSUM</b>   | Thickest of the epidermal layers. A few rows of irregular, polygonal-shaped keratinocytes that change from almost cuboidal to flat, as they move away from the stratum basale. The nuclei are round, and cells have visible rings of pink-stained cytoplasm. |
| <b>STRATUM BASALE</b>   | The first layer of cells on the basal membrane. A single layer of cuboidal cells, interspersed with melanocytes that contain brown-colored granules of melanin.  |
| <b>PAPILLARY LAYER</b>  | <b>RETICULAR LAYER</b>   |
| loose connective tissue with relatively little collagen fiber that is uniformly distributed | dense irregular connective tissue with many disordered bundles of collagen   |
| purple, elongated nuclei of the fibroblasts are scattered in extracellular matrix           | very few fibroblasts scattered between collagen bundles  |
| other cells include mast cells and macrophages  | other cells include macrophages, leukocytes, and limited adipocytes  |
| smaller blood and lymphatic vessels, and nerves   | very vascular, with larger blood vessels and nerves  |
| contain dermal papillae that form fingerprints  | contain glands and hair follicles (if in thin skin)  |