


Bone histo model



Osteon

Lacuna (cavities which house osteocytes)

Circumferential lamellae

Periosteum

Sharpey's fibers

Perforating canal

Central canal

Osteon Model


Central canal

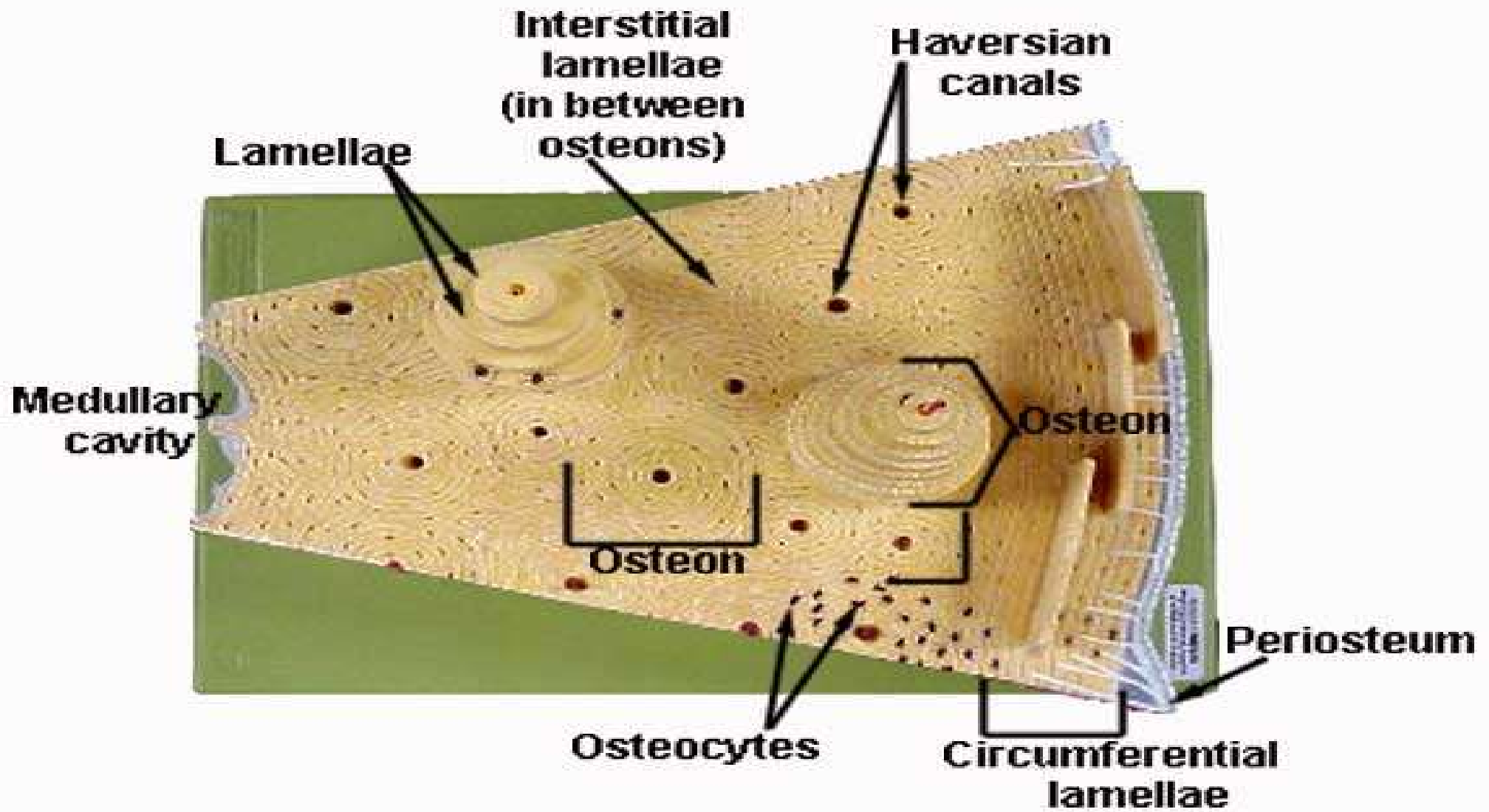
Concentric lamellae

Canaliculi

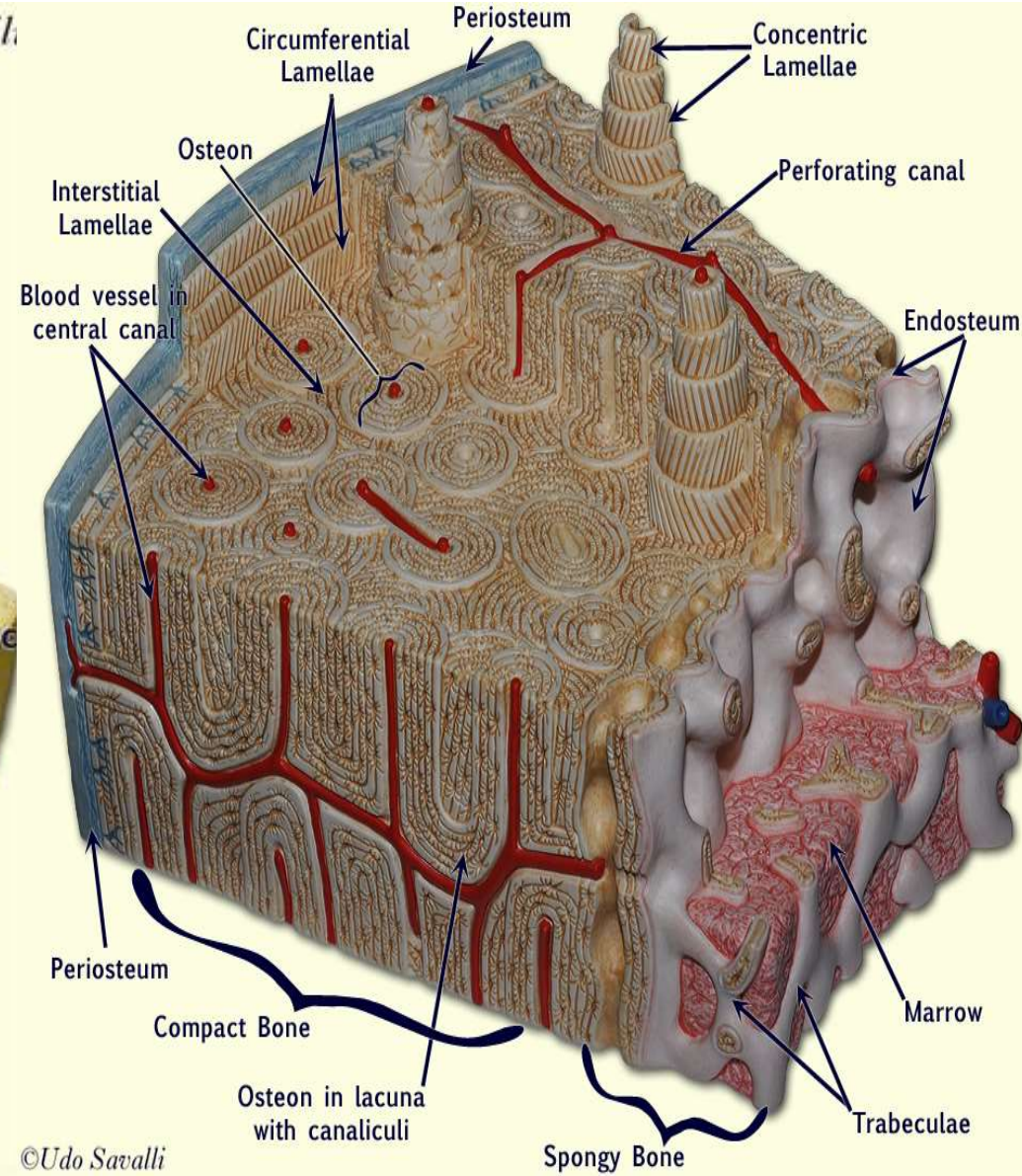
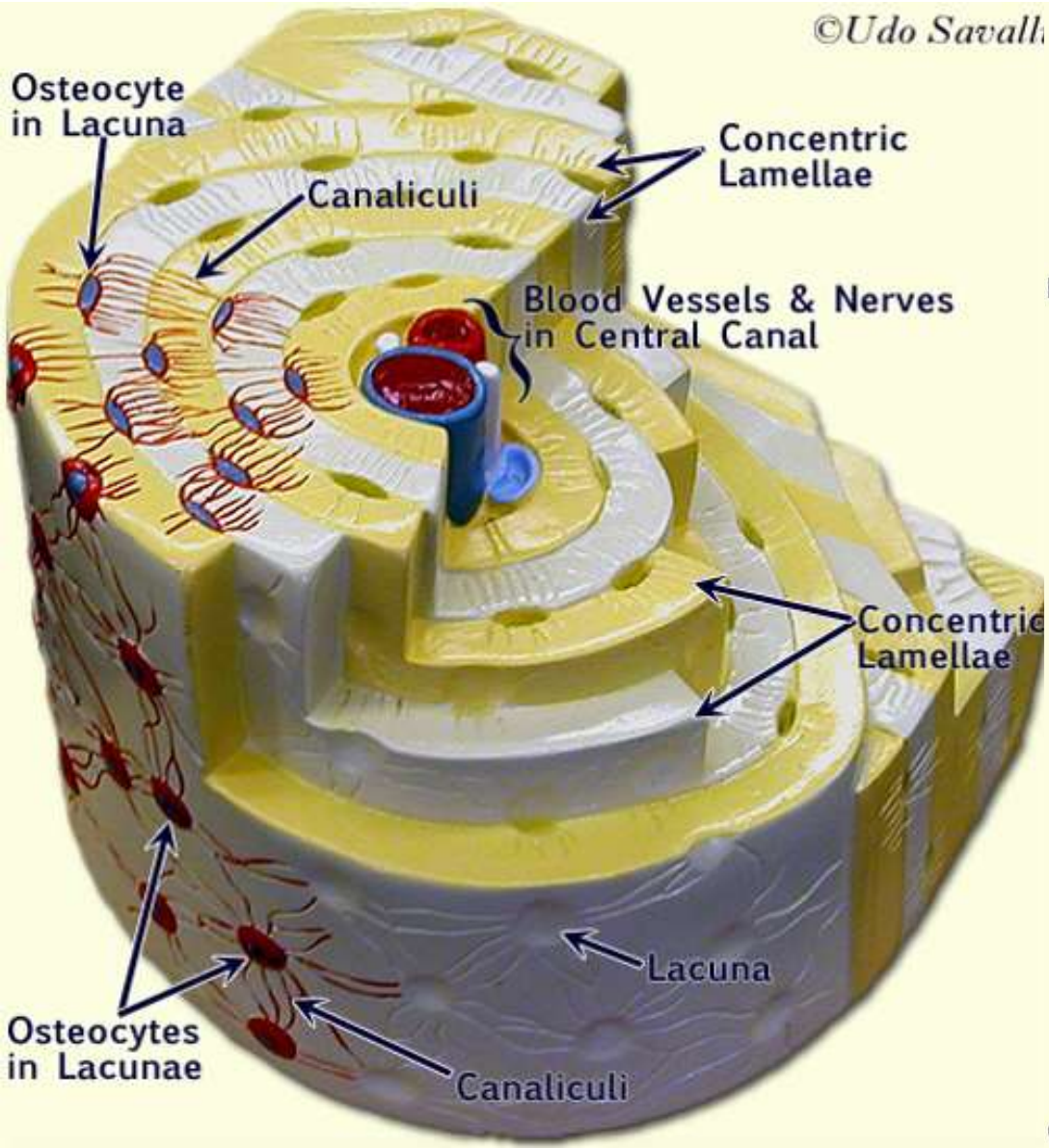
Interstitial lamellae

Osteocytes





©Udo Savalli



©Udo Savalli