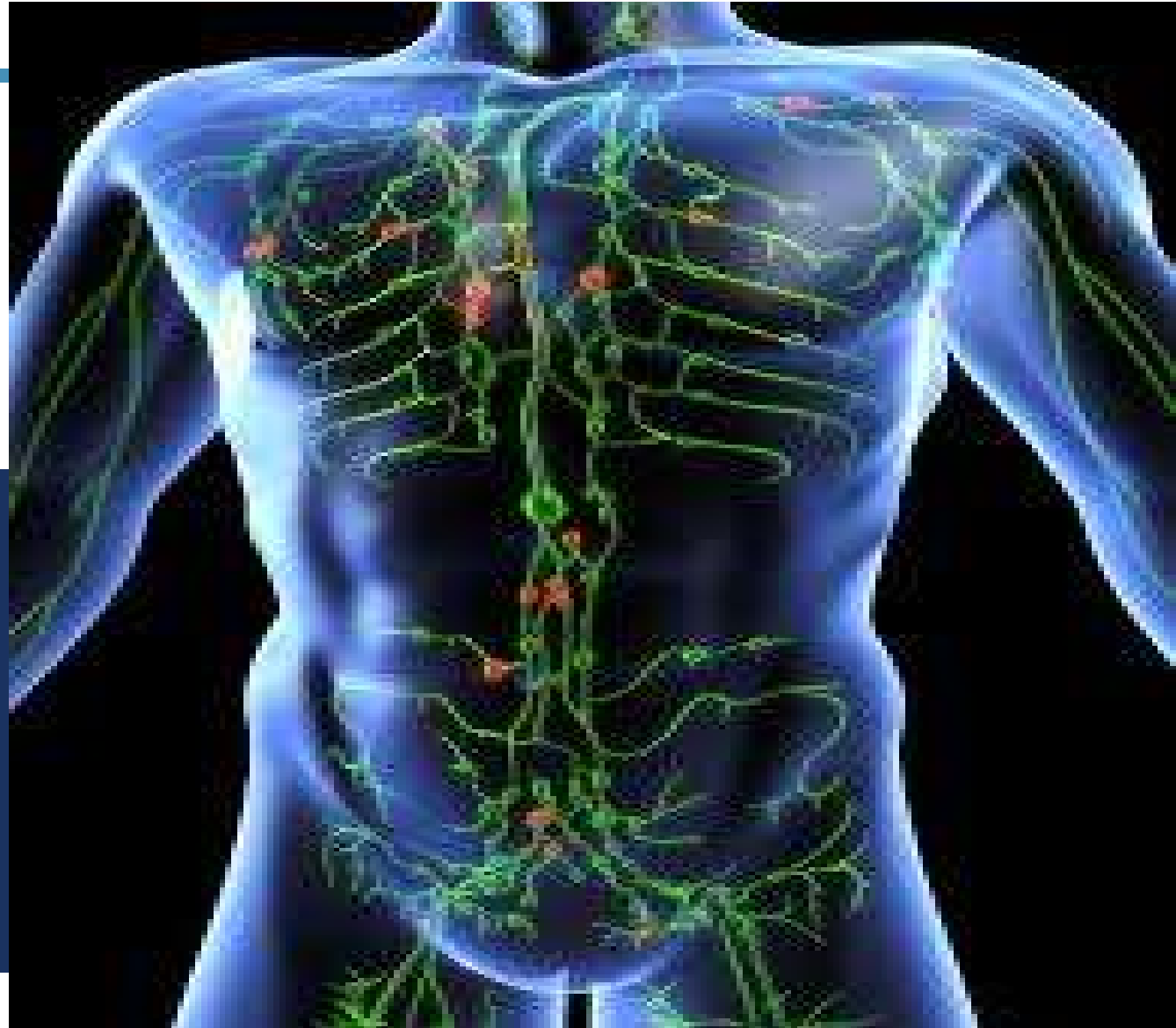

LYMPHOID TISSUE

D.HAMMOUDI.MD



LYMPHOID SYSTEM LECTURE OUTLINE

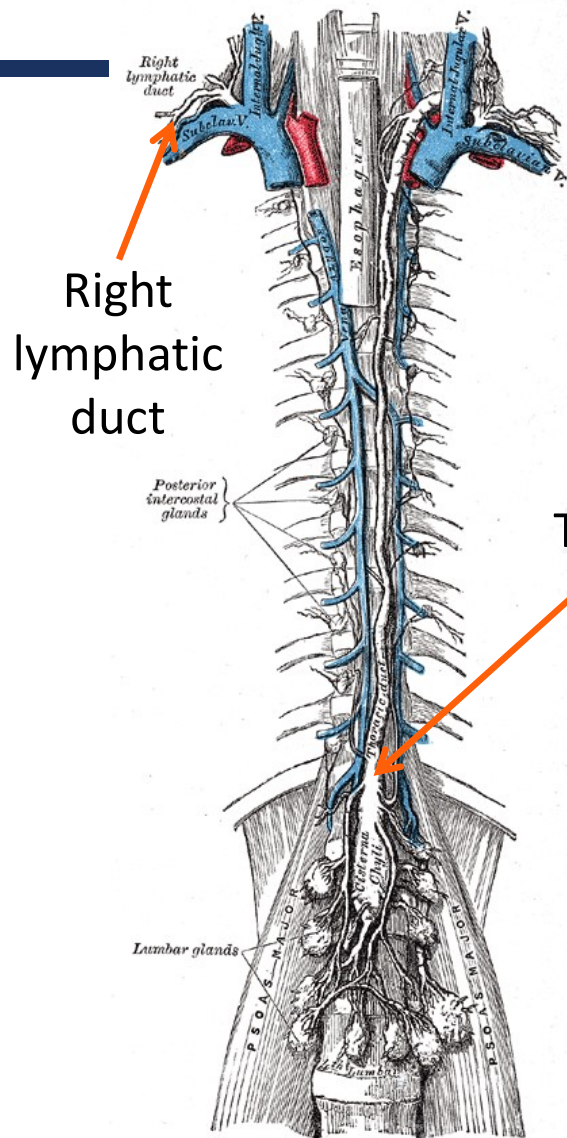
- Introduction
- Primary lymphoid organs
 - Bone marrow
 - Thymus
- Secondary lymphoid organs
 - Lymph nodes
 - Spleen
 - MALT

FUNCTION OF THE LYMPHOID SYSTEM

- The main purpose of the lymphoid system is to detect and inactivate foreign substances, such as:
 - Invading microorganisms
 - Cells of transplanted organs
 - Foreign materials (like pollen)
 - Cancer cells
- Lymph also brings nutrients from blood vessels to cells and picks up waste products.

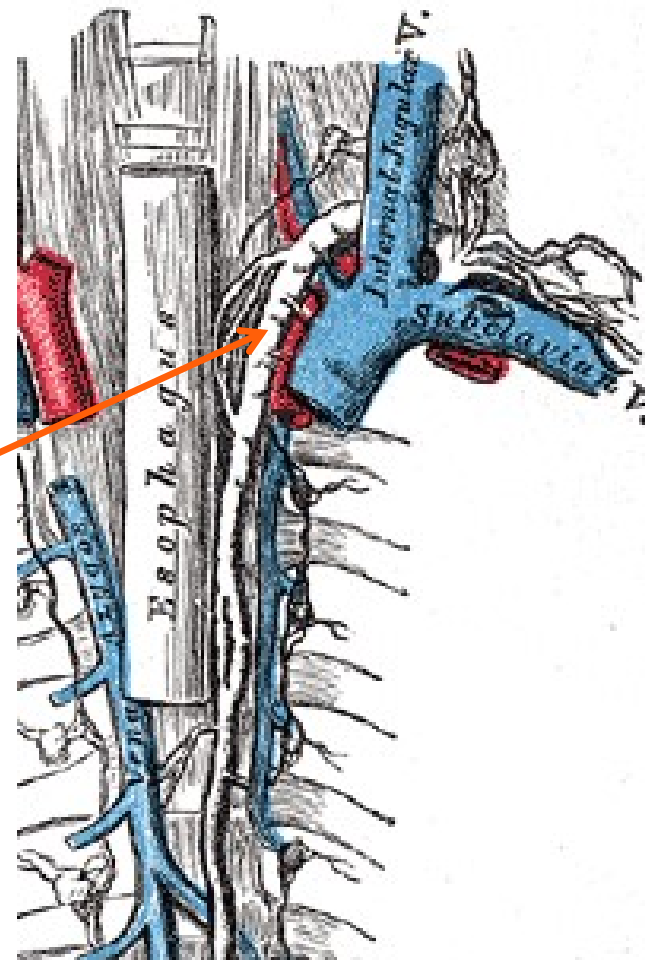
LYMPH (LYMPHATIC FLUID)

- Formed when interstitial fluid seeps into lymphatic vessels. Also contains lymphocytes, proteins, and sometimes bacteria or metastatic tumor cells.
- Composition varies in different body regions. Usually lymph is clear, but lymph draining the gut (called “chyle”) is milky and contains a lot of triglycerides.
- Lymphatic vessels eventually merge together and empty into the blood circulation via the thoracic duct and right lymphatic duct.



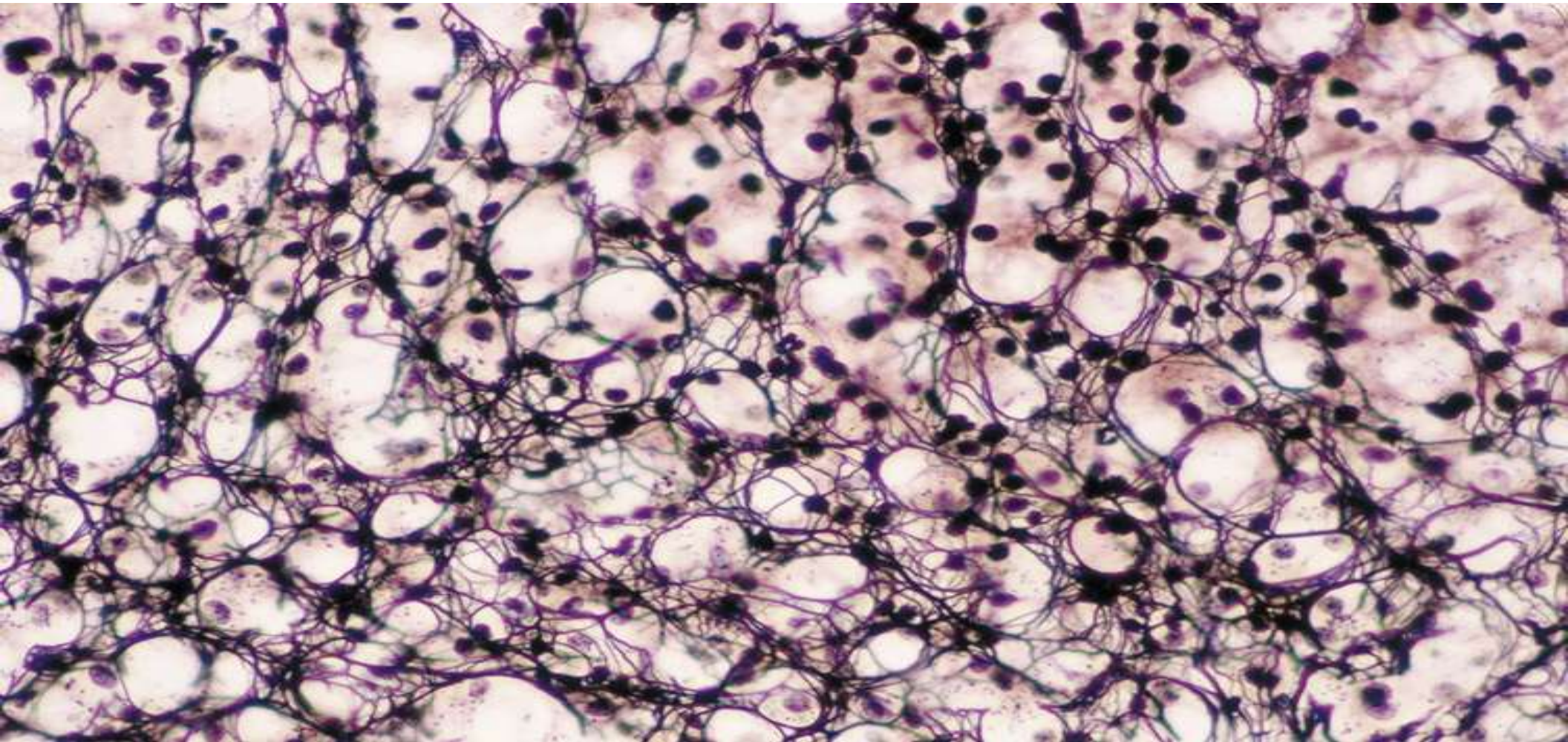
Right lymphatic duct

Thoracic duct



STROMA OF LYMPHOID ORGANS

- The stroma of all lymphoid organs except the thymus is composed of reticulin fibers.
- The stroma of the thymus is composed of cell processes of epithelial reticular cells.



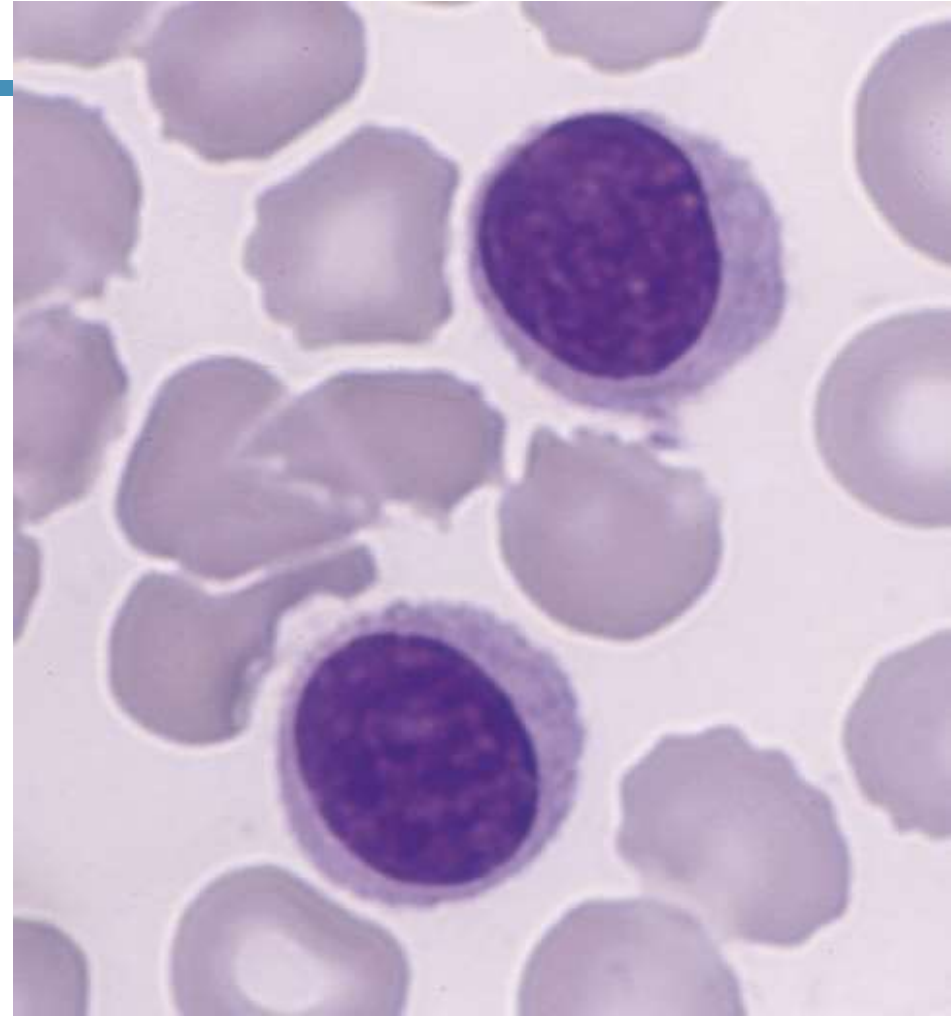
RETICULAR FIBERS (TYPE III COLLAGEN) FORMING A NETWORK. THESE FIBERS ARE ARGYROPHILIC (STAINABLE WITH SILVER STAINS).

CELLS OF THE LYMPHOID SYSTEM

- Lymphocytes
 - B lymphocytes
 - T lymphocytes
 - Natural killer (NK) cells
- All lymphocytes have surface receptors that recognize infected cells.

ALL LYMPHOCYTES LOOK THE SAME!*

- You can't reliably tell the type of lymphocyte by looking under a microscope.
- You have to use a technique called flow cytometry to look for markers (molecules) on the surface of the cells.
- B cells, T cells and NK cells have different markers on their cell surfaces.



* Pretty much. Sometimes T cells and NK cells are bigger and have little granules in the cytoplasm.

MORE CELLS OF THE LYMPHOID SYSTEM

- Antigen-presenting cells:
 - Macrophages
 - Dendritic cells
- Other blood cells:
 - Mast cells
 - Neutrophils
 - Monocytes
 - Eosinophils

RIDICULOUSLY OVERSIMPLIFIED IMMUNOLOGY

There are two main ways lymphocytes fight intruders (like bugs): humoral and cellular immunity.

Humoral immunity

B cells turn into plasma cells, which make antibodies. Antibodies coat and eliminate bugs.

Cellular immunity

T cells turn into cytotoxic T cells (which kill cells infected with bugs) and helper T cells (which help other cells do their jobs).

LYMPHOID SYSTEM LECTURE OUTLINE

- Introduction
- Primary lymphoid organs
 - Bone marrow
 - Thymus

PRIMARY (CENTRAL) LYMPHOID ORGANS

Lymphocytes arise, differentiate and become immunocompetent in primary lymphoid organs. There are two primary lymphoid organs:

- **Bone marrow**

All lymphocytes arise in the bone marrow.

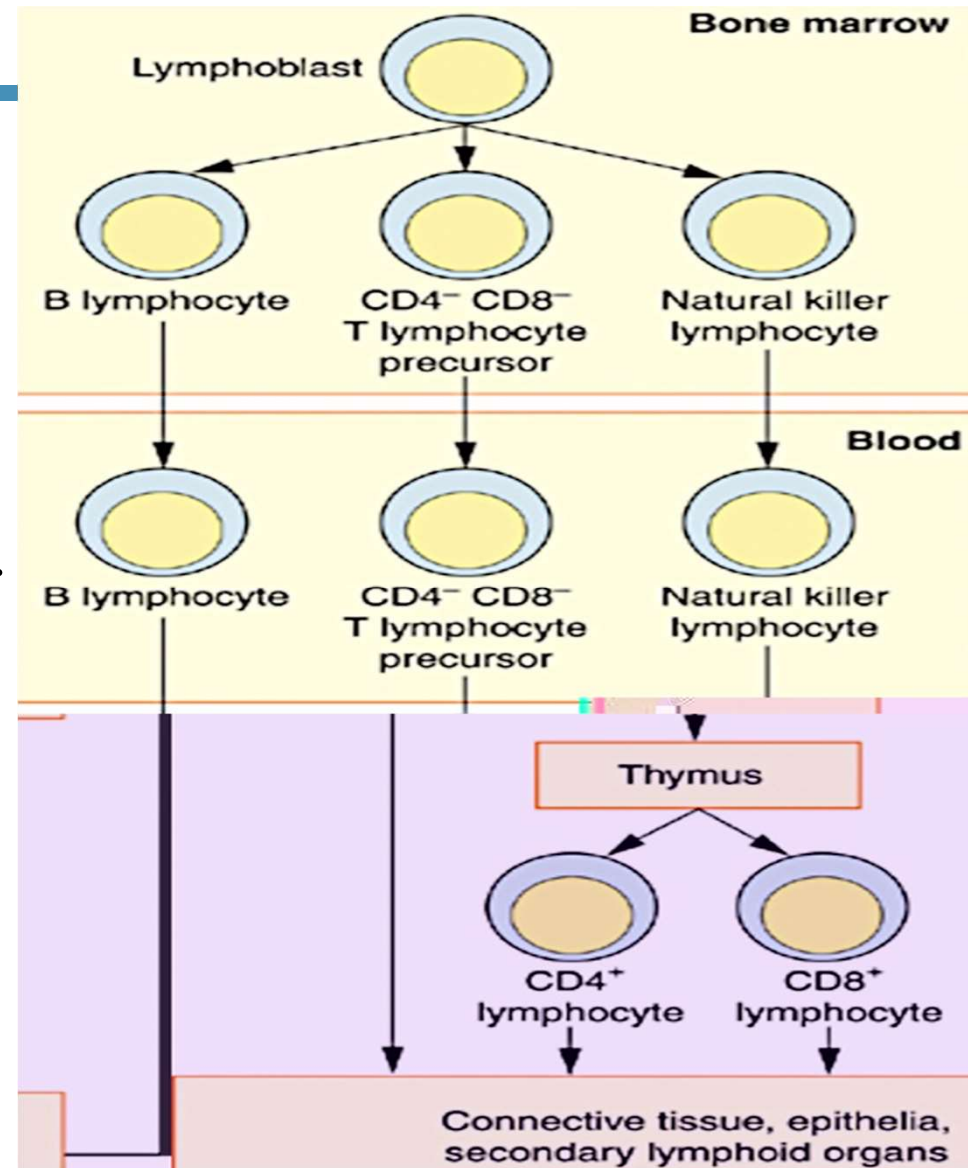
B cells and NK cells mature in the bone marrow.

- **Thymus**

T cells mature here.

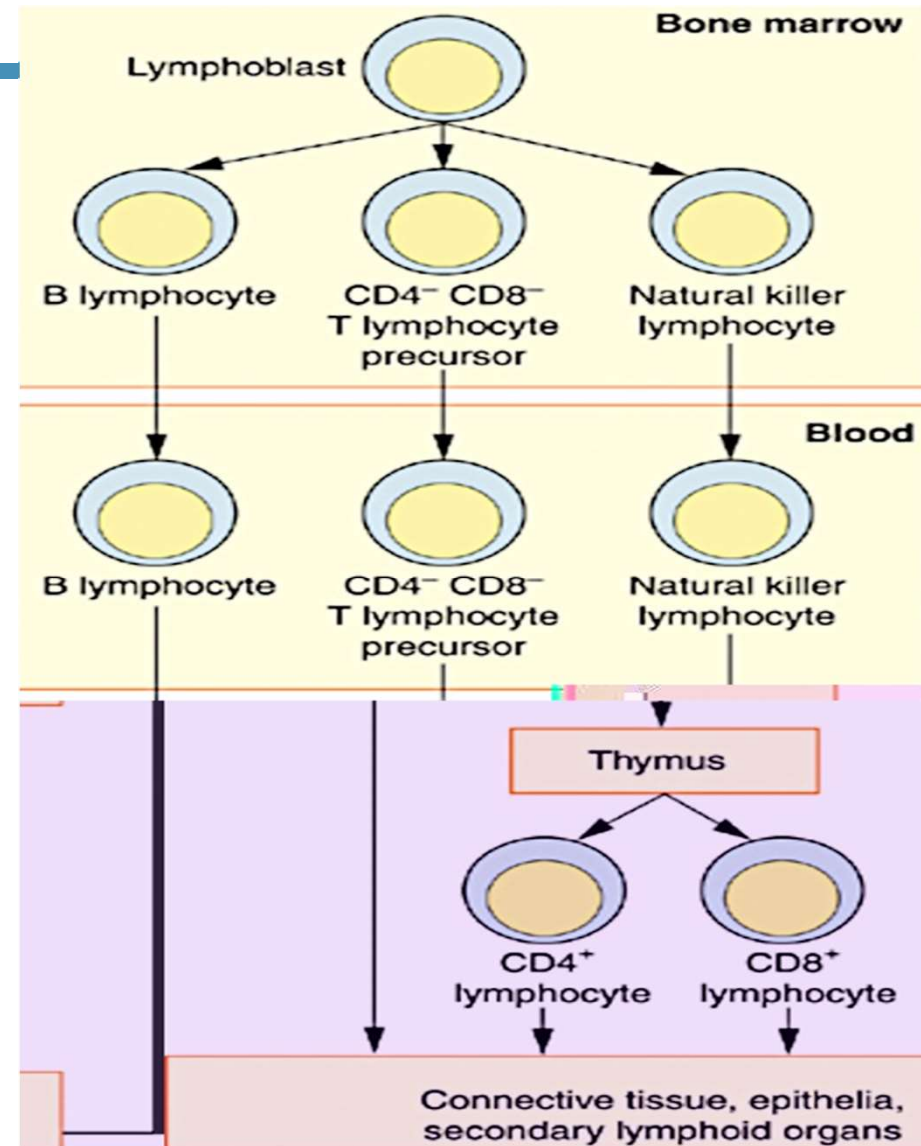
What do B cells do in primary and secondary lymphoid organs?

- B lymphocytes and natural killer cells are formed and mature in bone marrow.
- They then leave bone marrow, populate secondary lymphoid organs, and recirculate through blood, epithelia, and connective tissue.



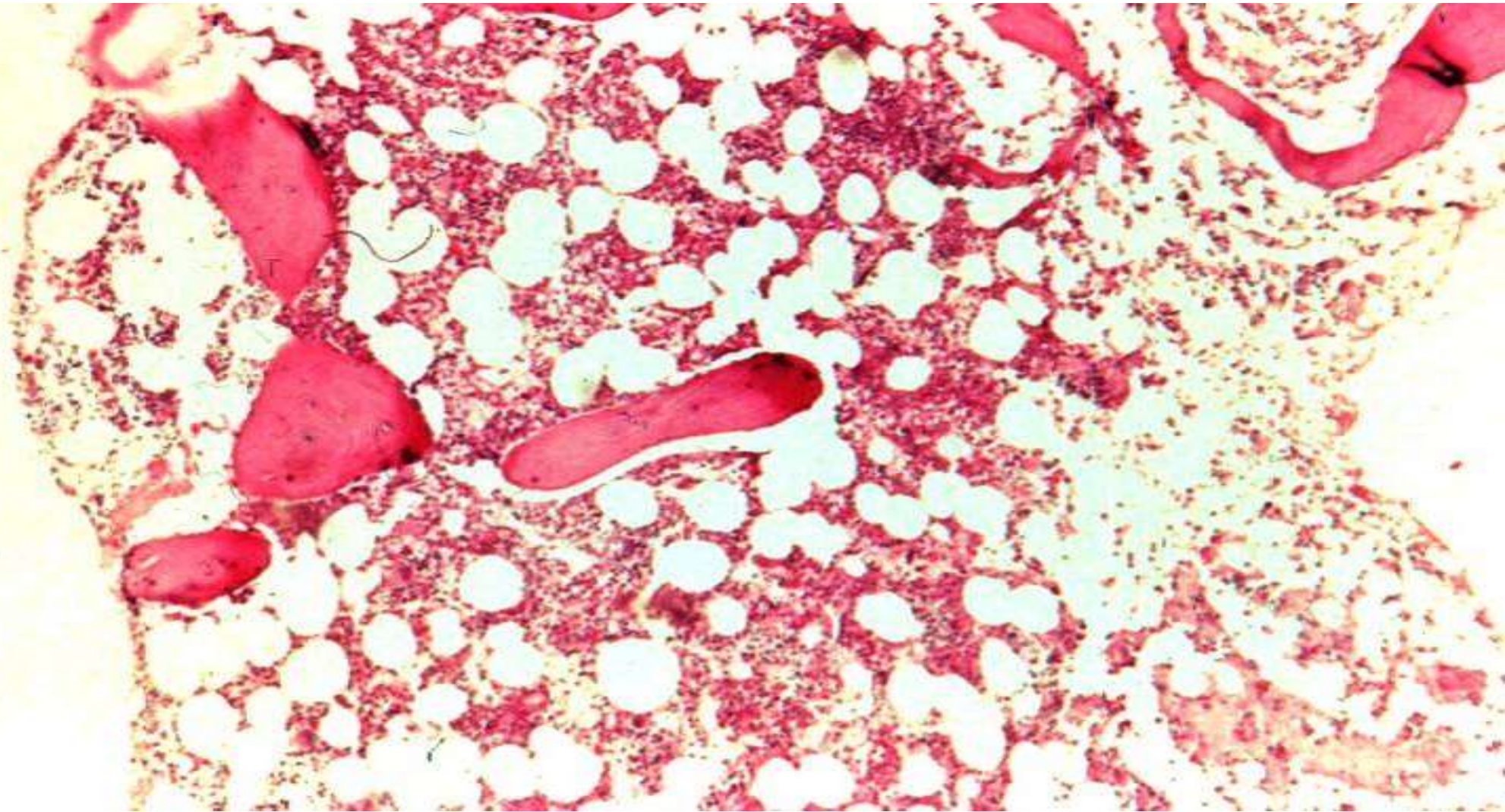
What do T cells do in primary and secondary lymphoid organs?

- Immature T-cell precursors originate in the bone marrow.
- They then leave bone marrow and travel through blood to the thymus.
- They finish maturing in the thymus and leave as CD4⁺ and CD8⁺ cells (this will make more sense next year!)

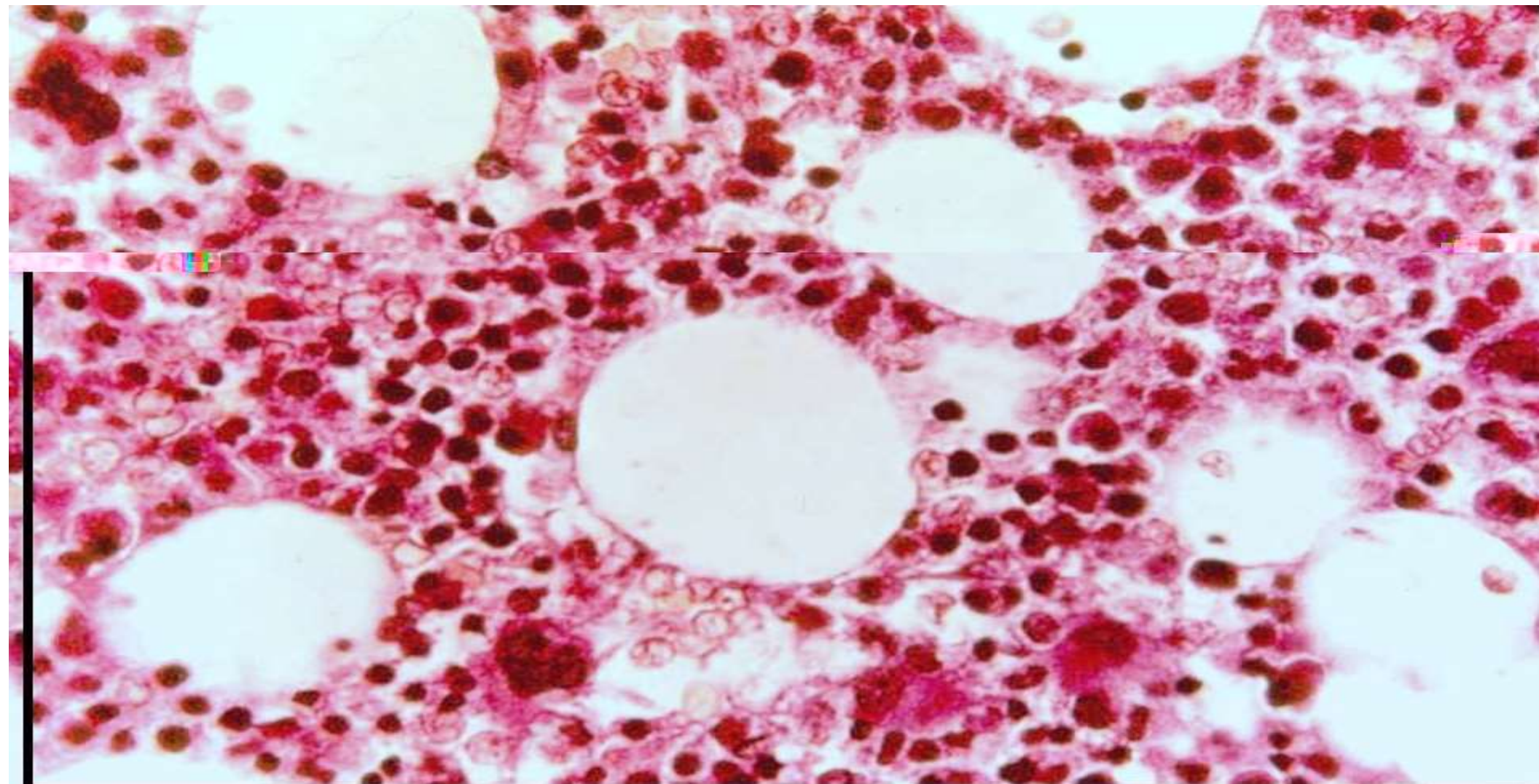


LYMPHOID SYSTEM LECTURE OUTLINE

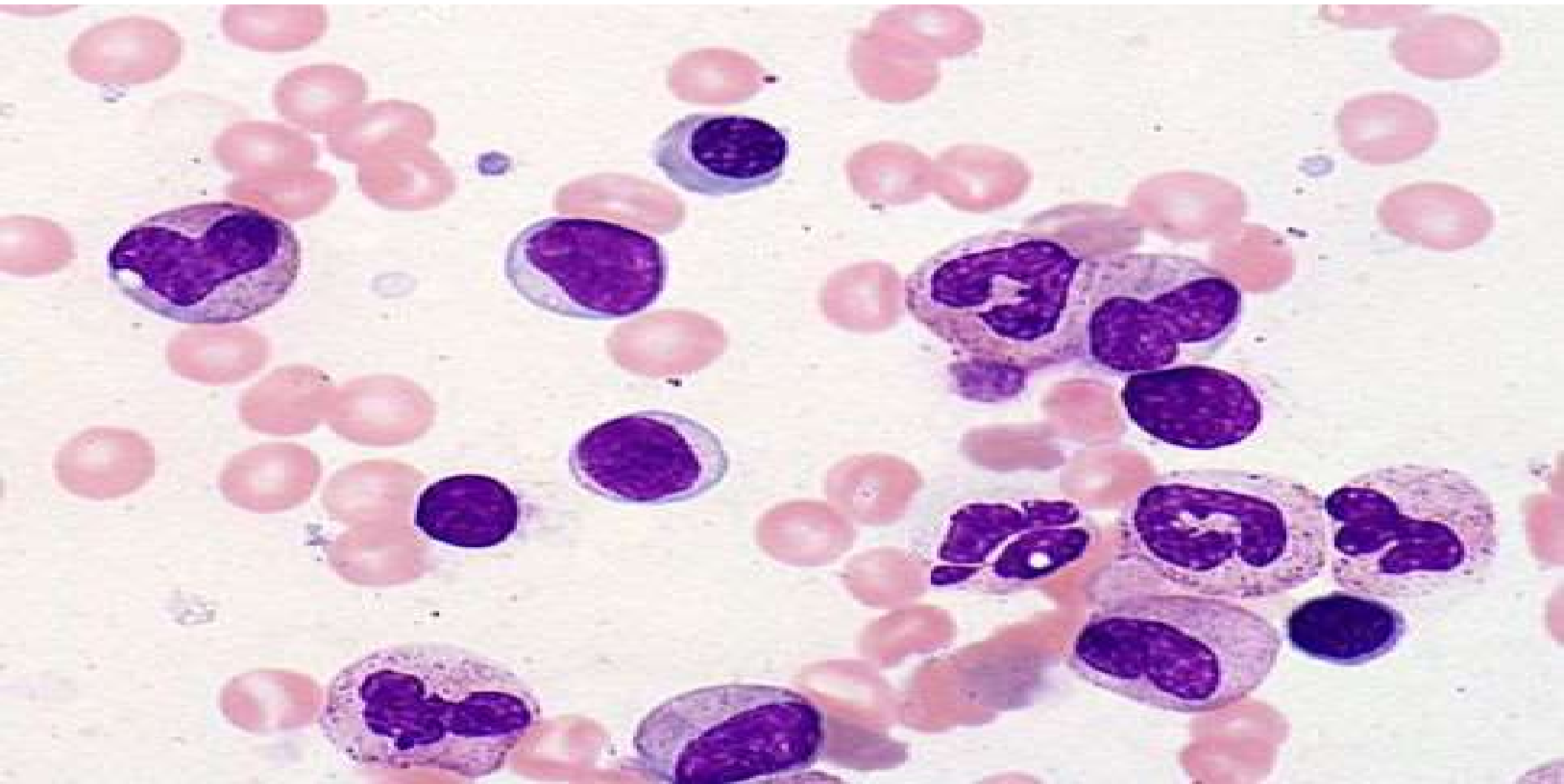
- Introduction
- Primary lymphoid organs
 - Bone marrow



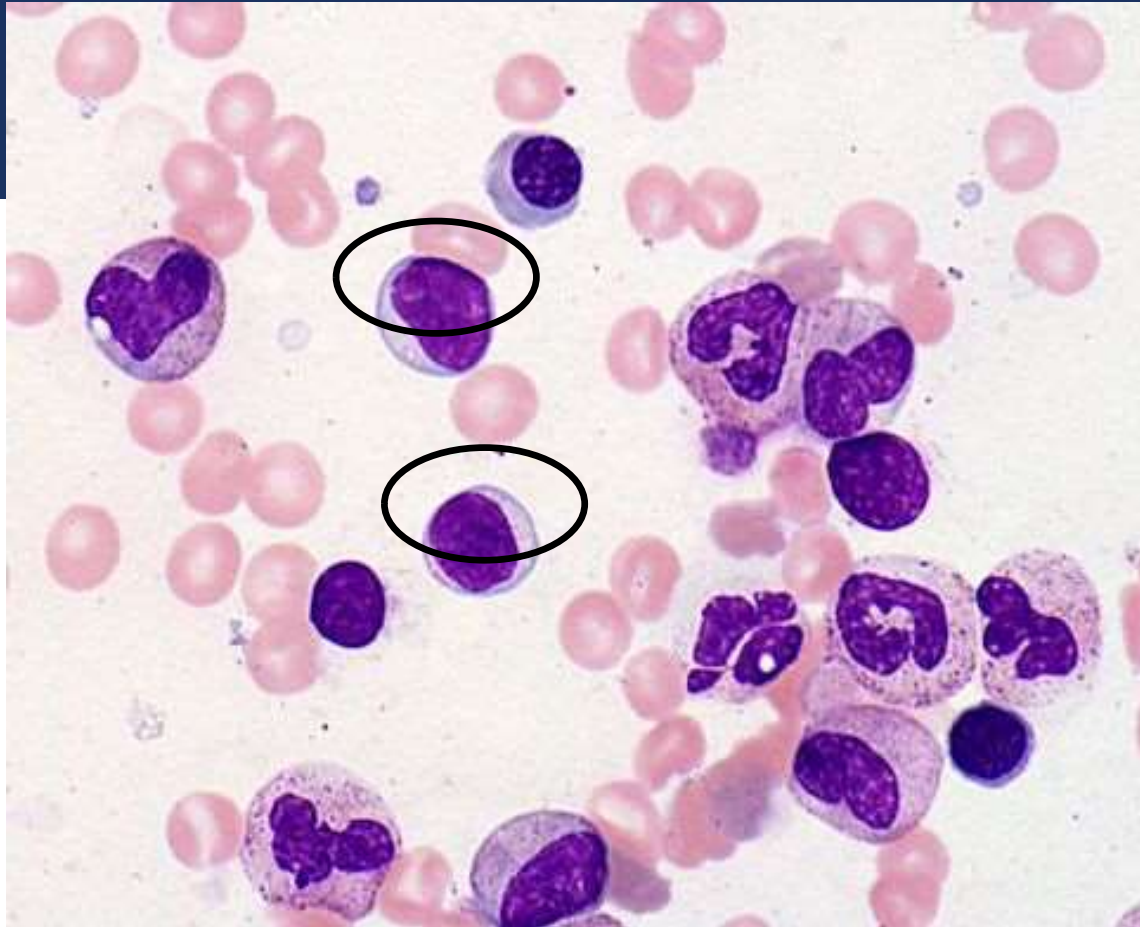Normal bone marrow biopsy



Normal bone marrow biopsy



Normal bone marrow biopsy



Lymphocytes

LYMPHOID SYSTEM LECTURE OUTLINE

- Introduction
- Primary lymphoid organs
 - Bone marrow
 - Thymus

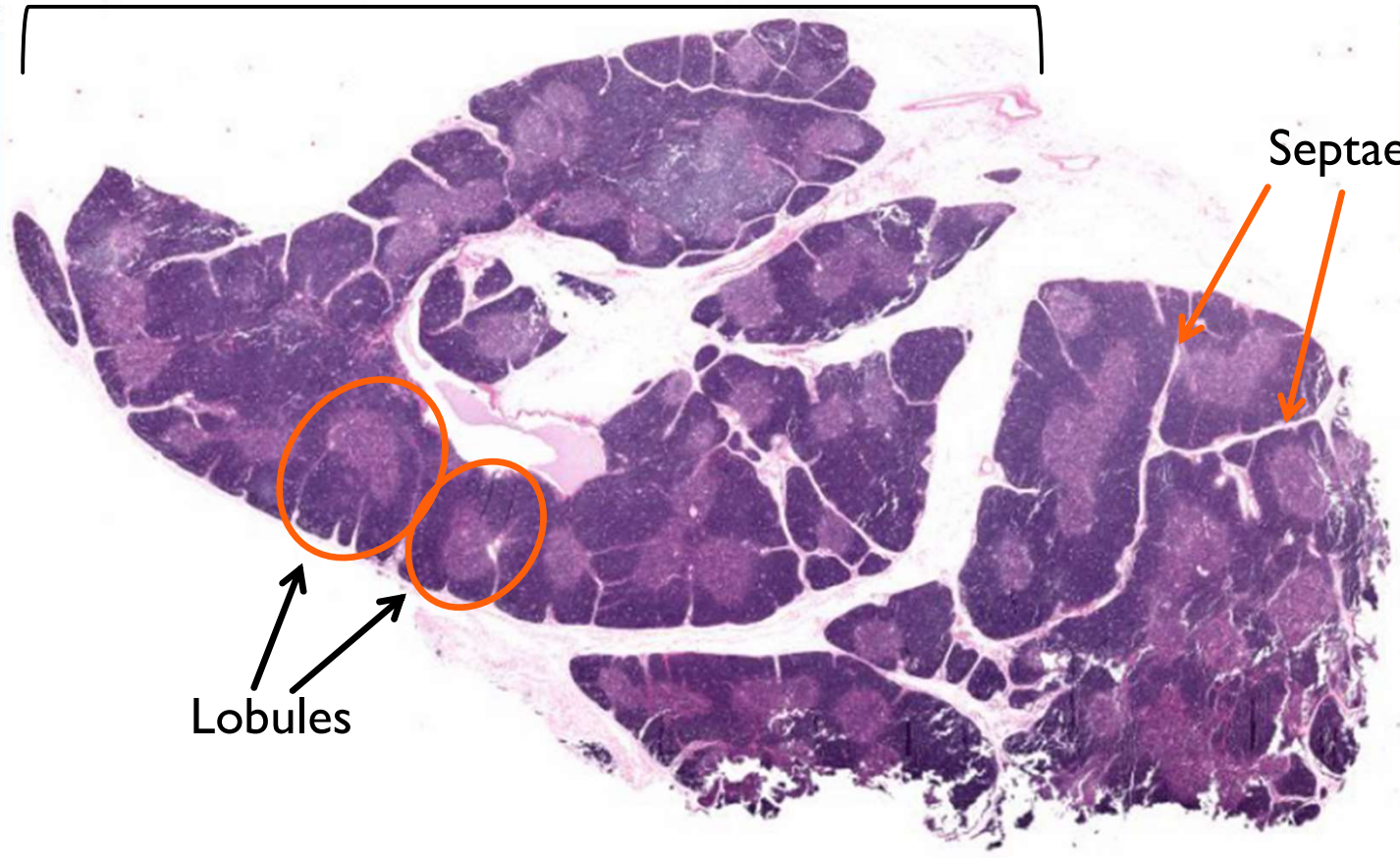
THYMUS

- Located in mediastinum
- Thymus consists of lobes, capsule, and septa. Septa incompletely divide the lobes into numerous lobules.
- Lobules have 2 regions:
 - Cortex is peripheral and darker staining.
 - Medulla is central and lighter staining.

Lobe

Septae

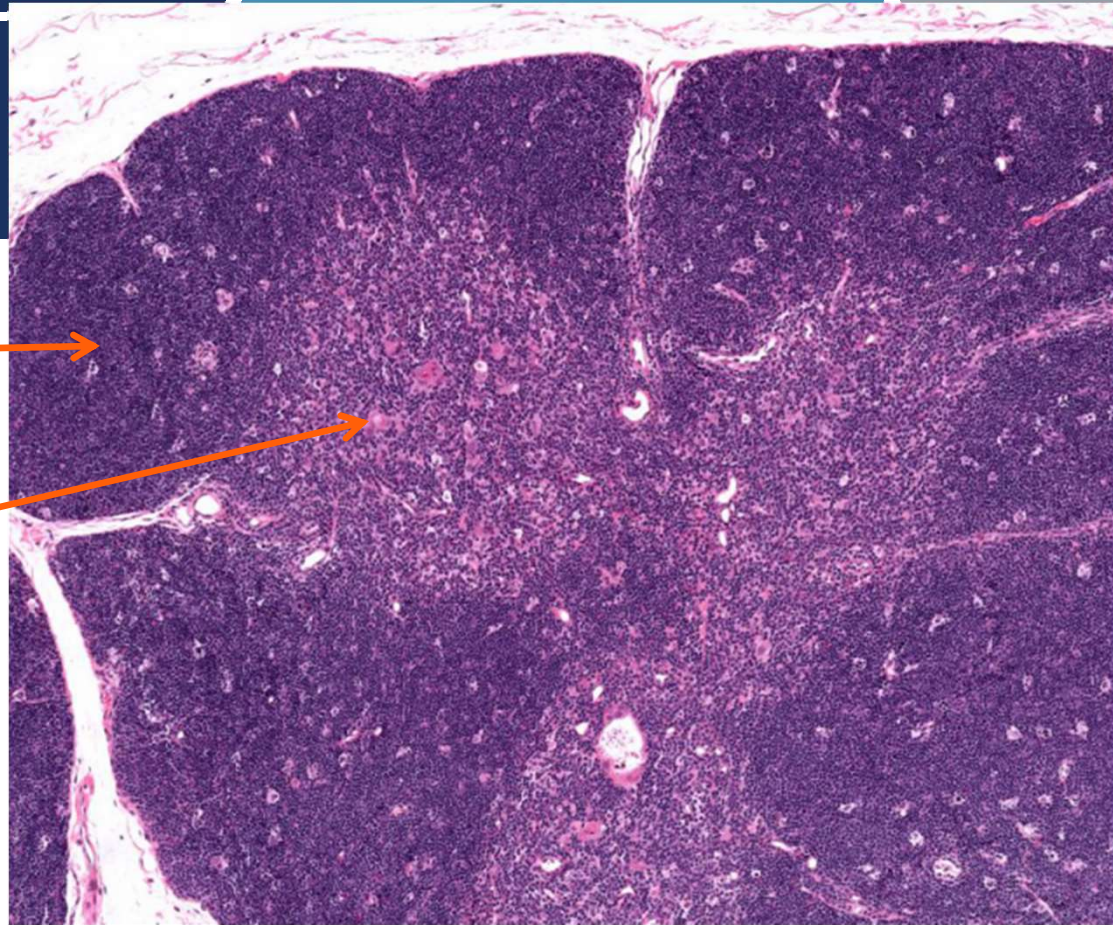
Lobules



THYMUS, LOW POWER

Cortex →

Medulla →



THYMUS, MEDIUM POWER

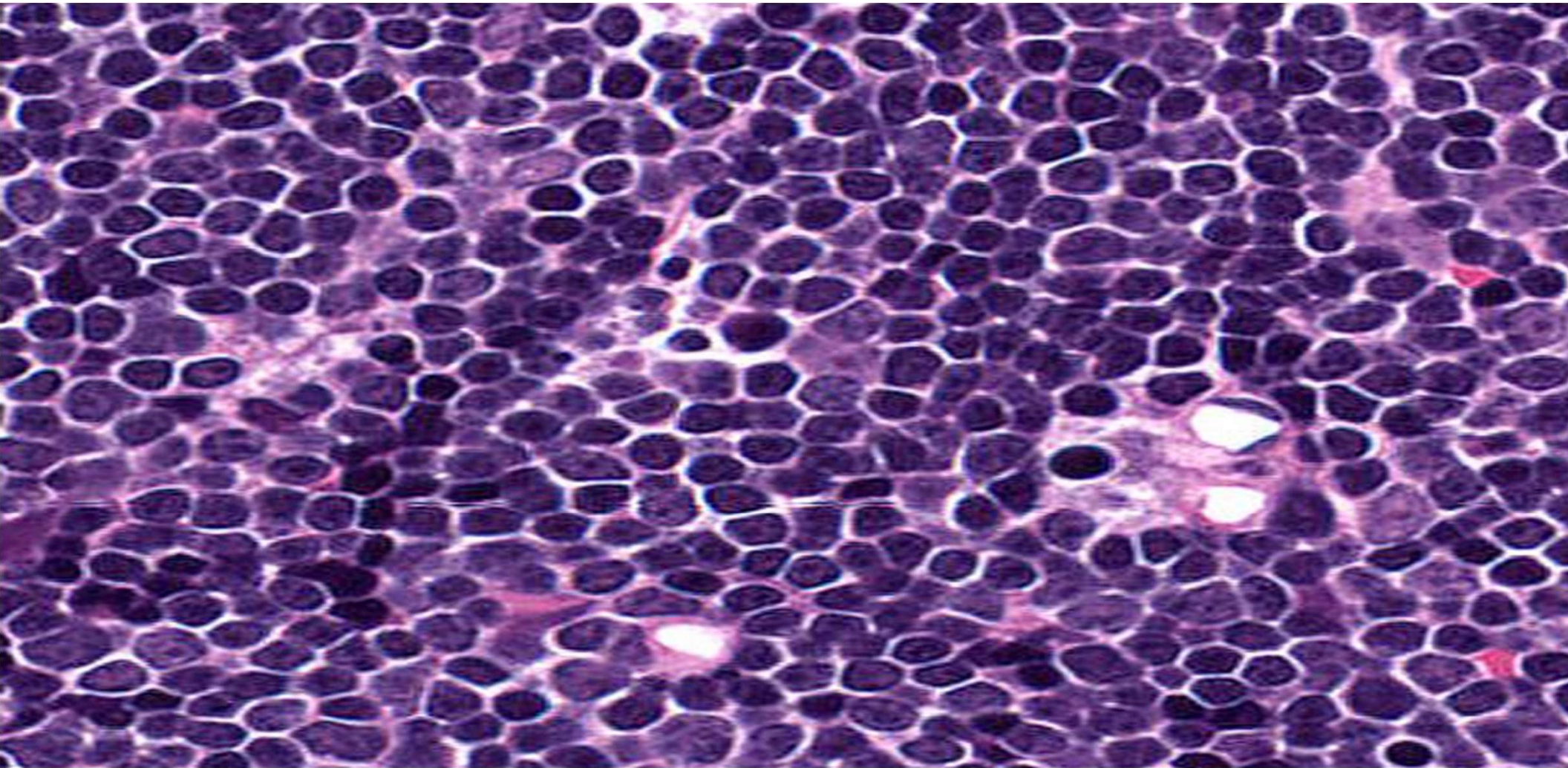
CELLS OF THE THYMUS

T cells (thymocytes)

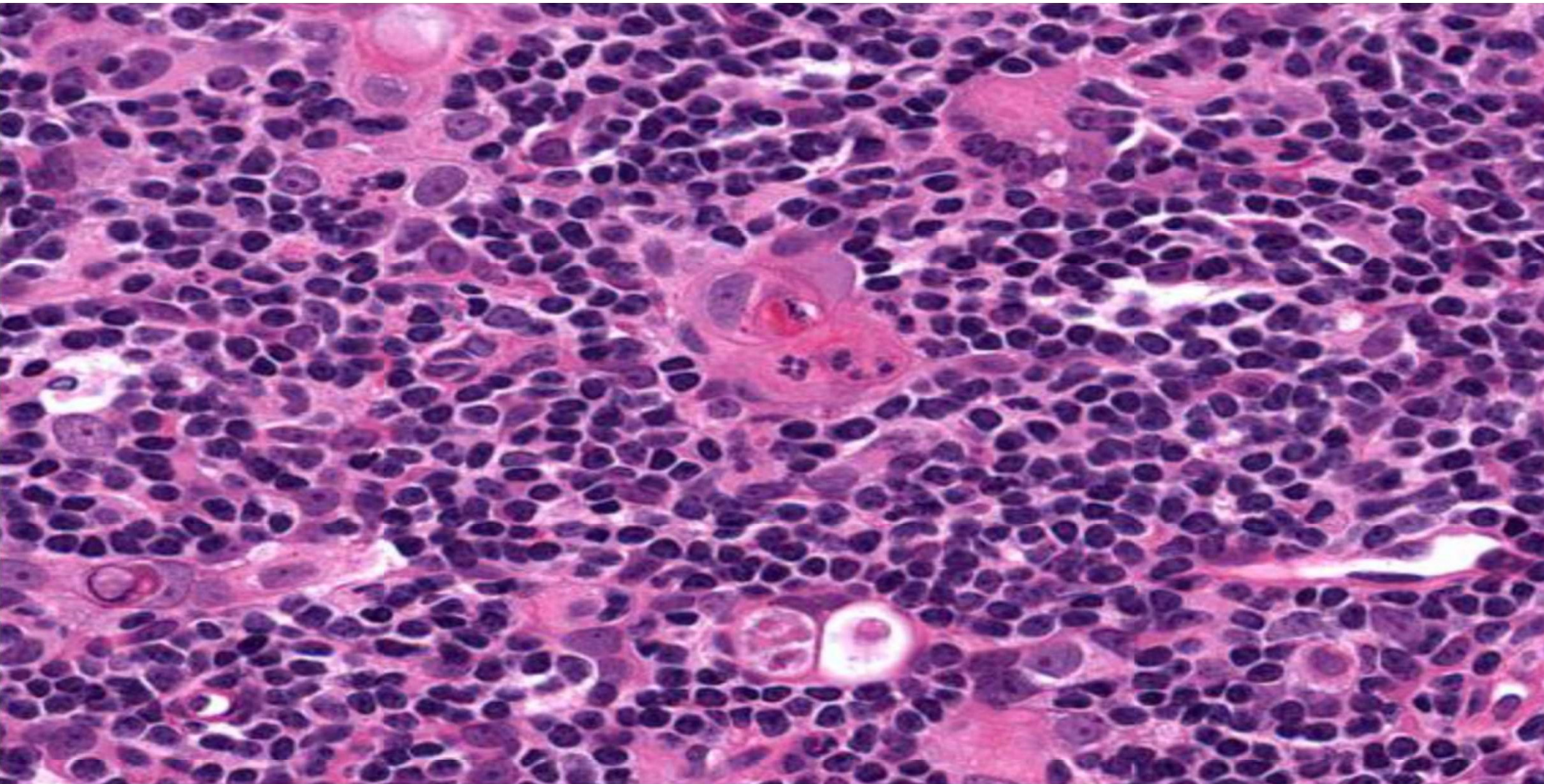
- T cells in the cortex are in various stages of differentiation.
- T cells in the medulla are mature.

Thymic epithelial reticular cells

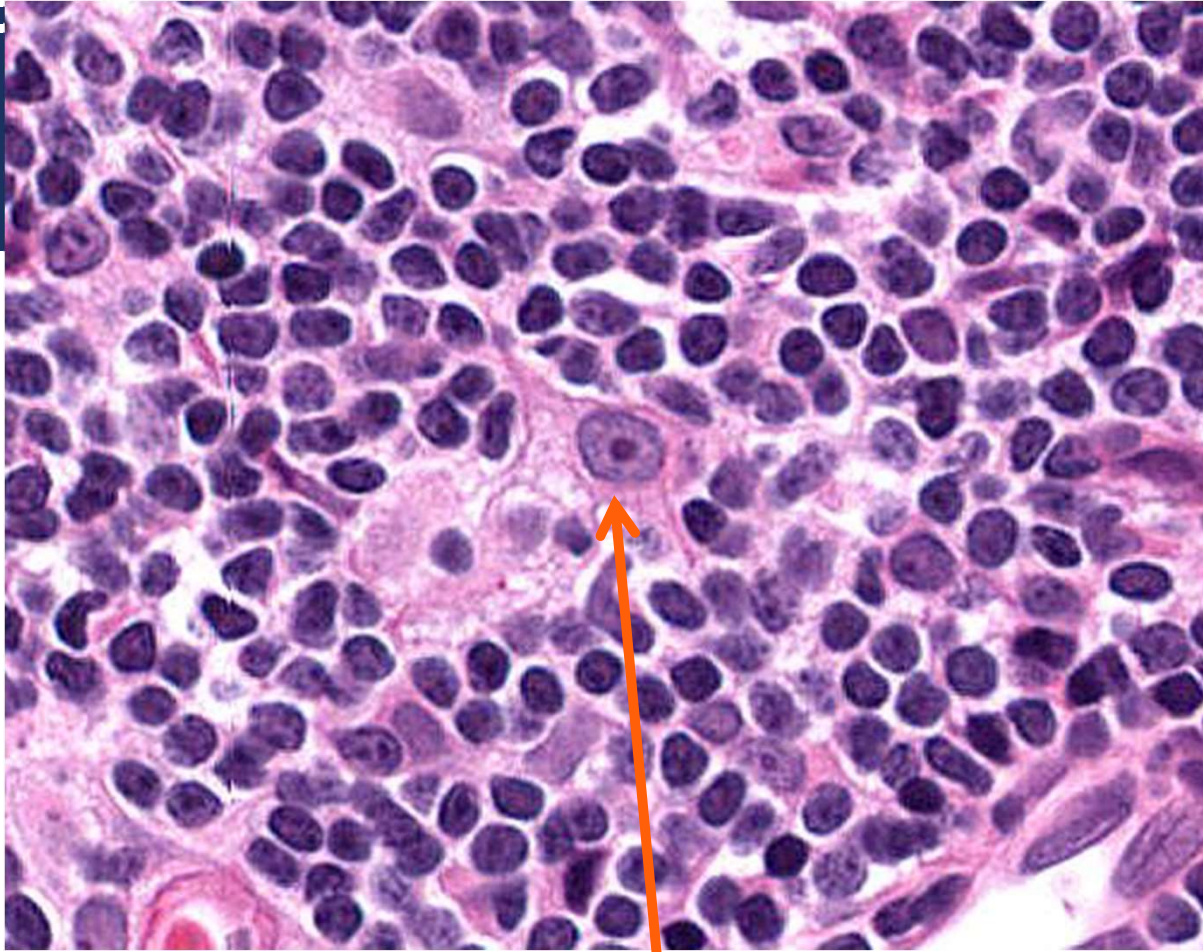
- Present in both the cortex and medulla.
- Abundant cytoplasm, large lightly-staining nuclei and long cytoplasmic processes attached to processes of adjacent cells by desmosomes.



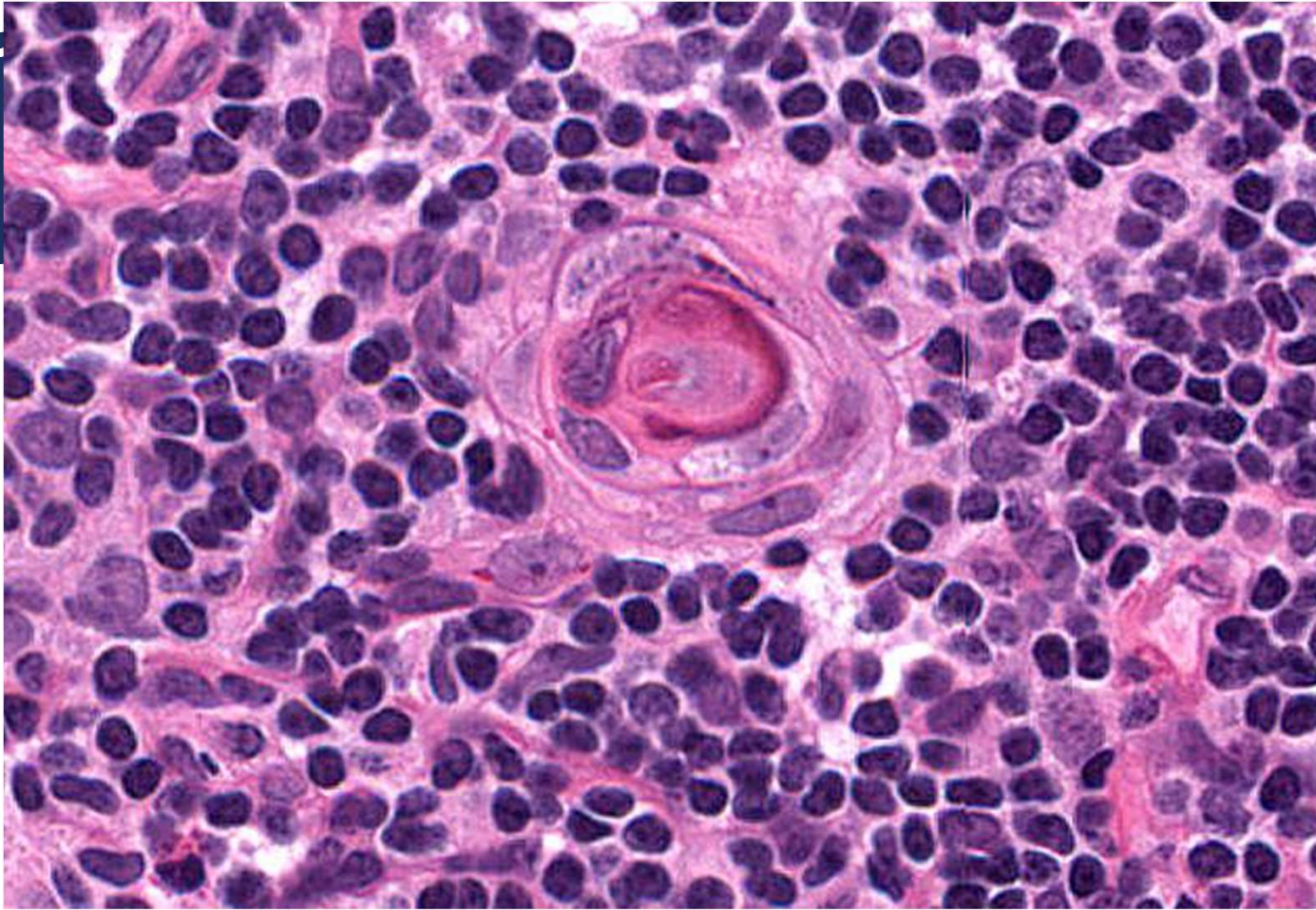
THYMUS, HIGH POWER:T CELLS IN THE CORTEX



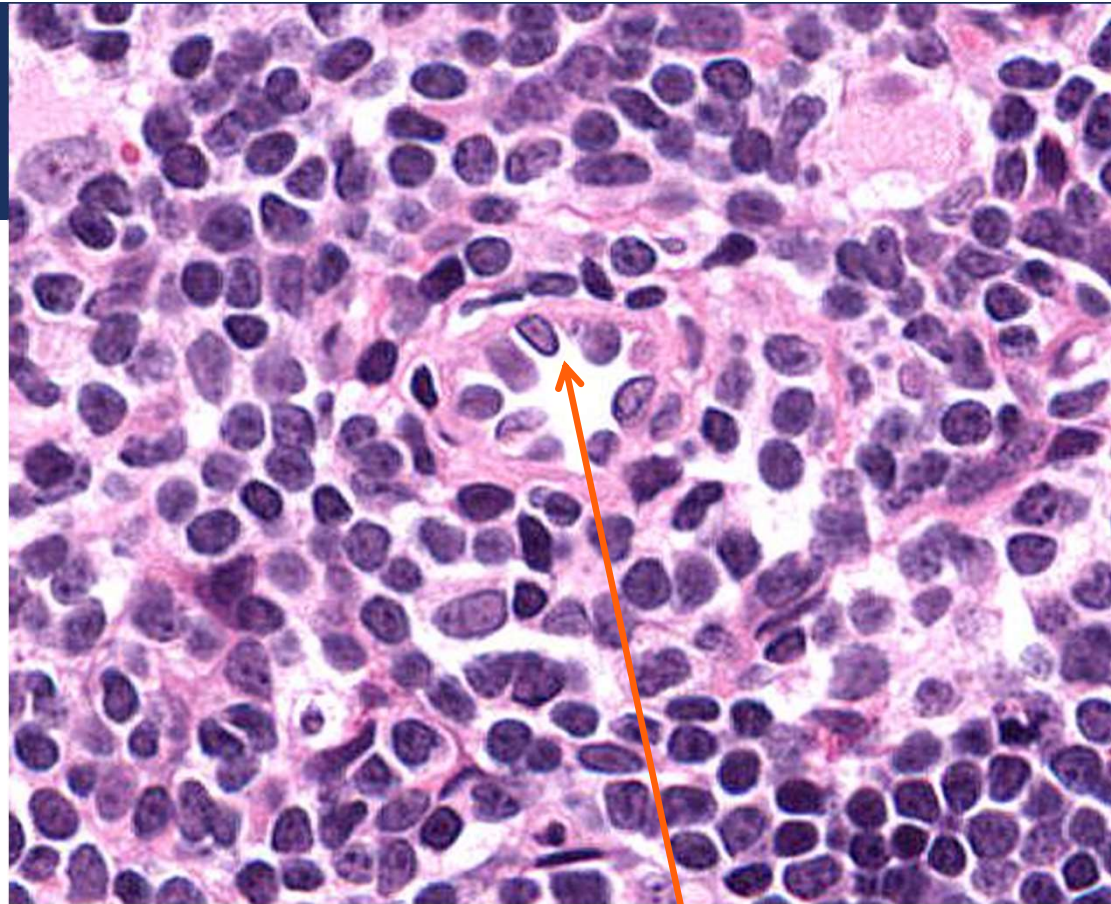
THYMUS, HIGH POWER:T CELLS IN THE MEDULLA



THYMUS, HIGH POWER: EPITHELIAL RETICULAR CELL



HASSEL CORPUSCLE (CLOSELY-PACKED, CONCENTRIC RETICULAR CELLS)



THYMUS, HIGH POWER: POST-CAPILLARY VENULE

T CELLS IN THE CORTEX

- T cell precursors from the bone marrow enter the thymus in the subcapsular region.
- In the outer cortex, T cells undergo active proliferation.
- In the deeper cortex, T cells undergo “selection.” If they can’t bind well enough to cell receptors, or if they bind too well to “self” cells, they die.
- So: many T cells are produced, but most (97%) die.

T CELLS IN THE MEDULLA

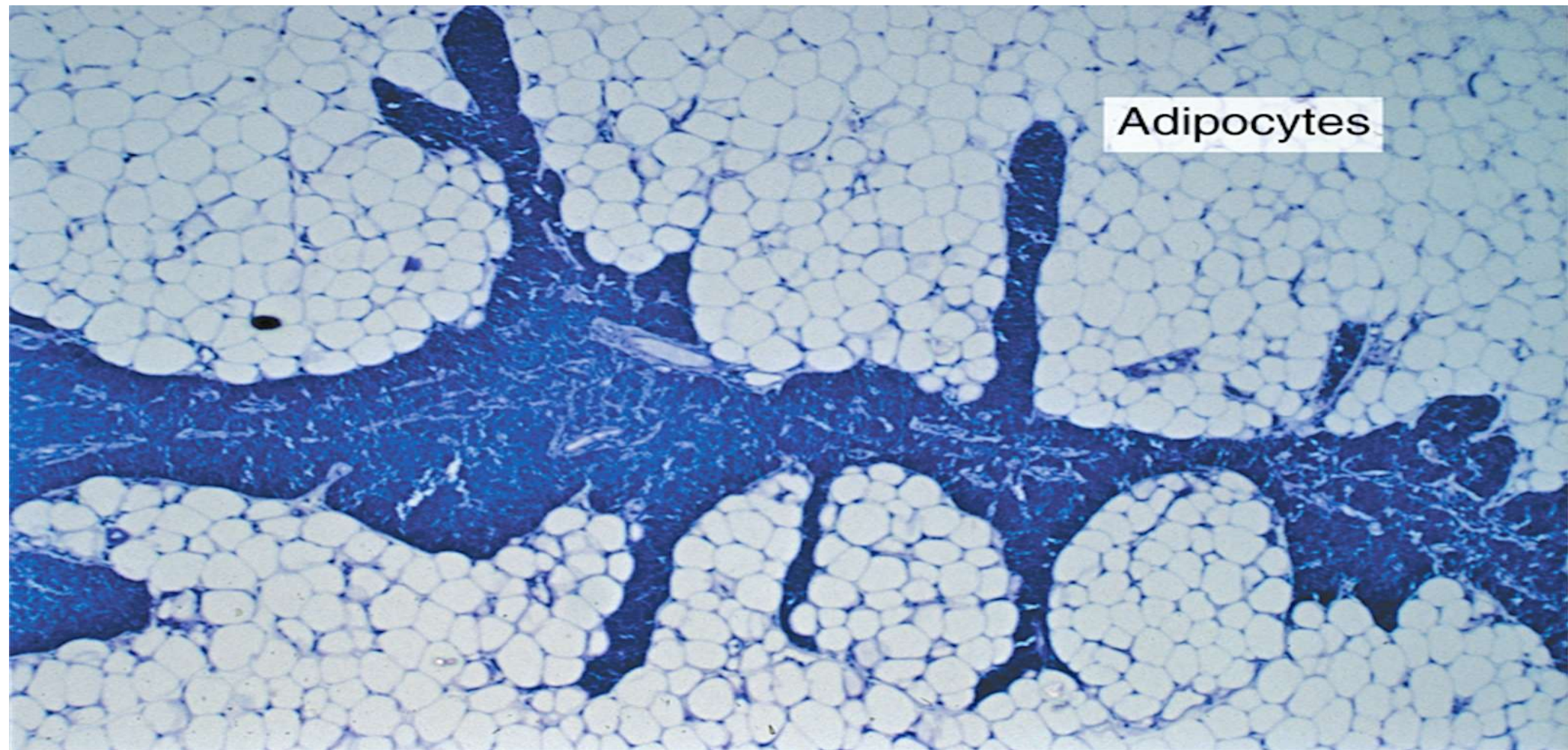
- The remaining T cells survive and migrate to the medulla.
- Cells in the medulla include mature T cells and epithelial reticular cells.
- Hassall's corpuscles are made of degenerating epithelial reticular cells and keratin filaments. Found only in medulla. Function unknown.

T CELLS IN THE BLOOD

- Mature T cells leave the thymus and enter the blood.
- Arterioles and capillaries in cortex are surrounded by epithelial reticular cells with tight junctions, forming a blood-thymus barrier which excludes most circulating antigens.
- Thymus has no afferent lymphatics, and does not filter lymph like a lymph node does.

DEVELOPMENT AND INVOLUTION OF THE THYMUS

- The thymus is well-developed before birth.
- The thymus is heaviest at puberty. After puberty, it involutes but never completely disappears.
- In old age, the thymus is composed mainly of connective tissue and fat, but it is still capable of producing lymphocytes.



THE THYMUS IN ELDERLY PEOPLE CONSISTS MOSTLY OF
FAT AND CONNECTIVE TISSUE

LYMPHOID SYSTEM LECTURE OUTLINE

- Introduction
- Primary lymphoid organs
 - Bone marrow
 - Thymus
- Secondary lymphoid organs
 - Lymph nodes
 - Spleen
 - MALT

SECONDARY (PERIPHERAL) LYMPHOID ORGANS

Secondary lymphoid organs trap antigens and initiate immune responses. Lymphoid cells can undergo further maturation here too. There are three secondary lymphoid organs:

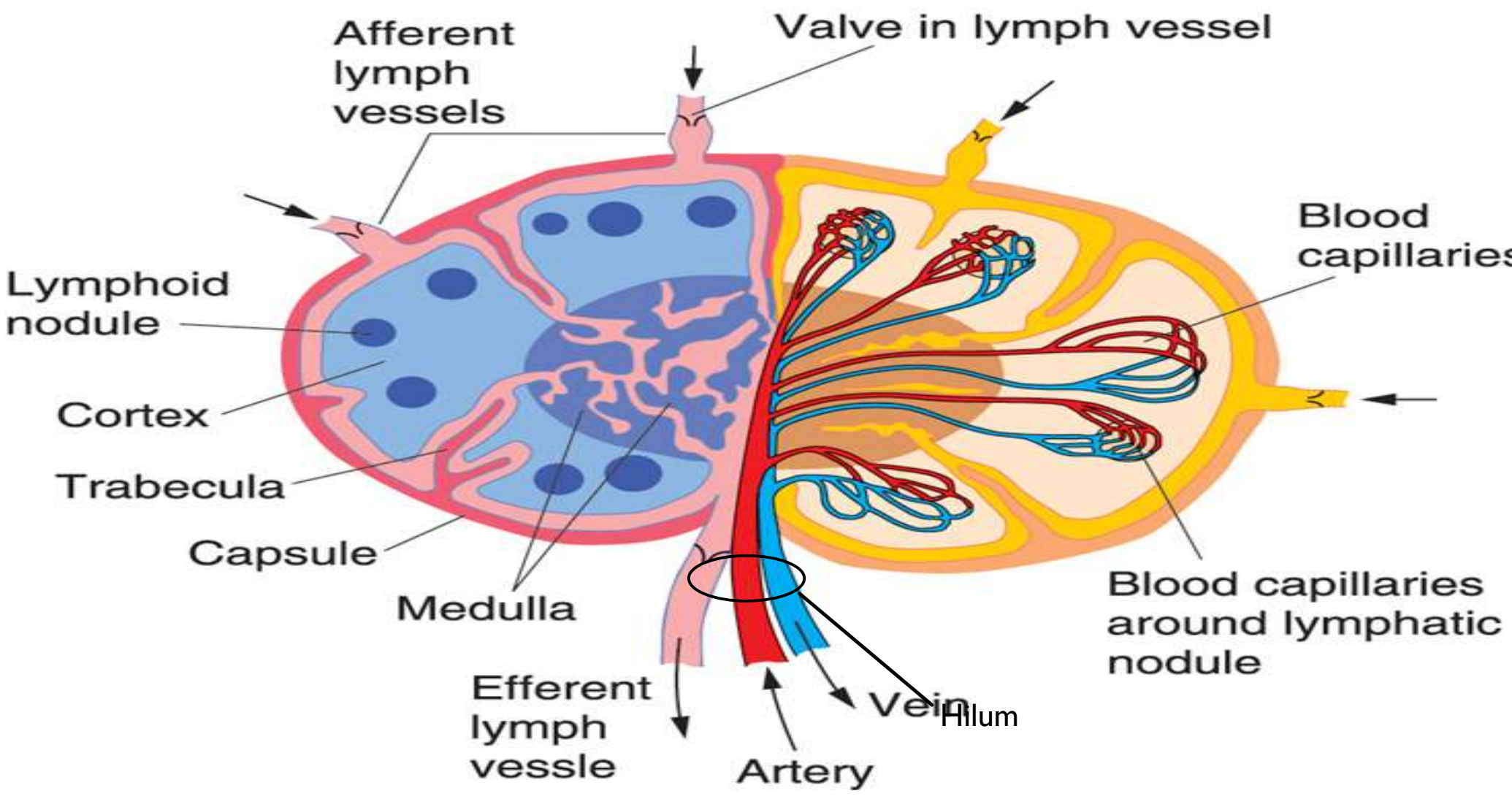
- Lymph nodes
- Spleen
- Mucosa-associated lymphoid tissue (MALT)

SECONDARY (PERIPHERAL) LYMPHOID ORGANS

- Secondary lymphoid organs consist of lymphoid follicles and diffuse lymphoid tissue in different architectural arrangements.
- Main function: trap antigens and present them to circulating lymphocytes.
- Specific functions:
 - Lymph nodes: filter lymph
 - Spleen: filters blood
 - MALT: filters antigens that attempt to cross mucosal surfaces

LYMPHOID SYSTEM LECTURE OUTLINE

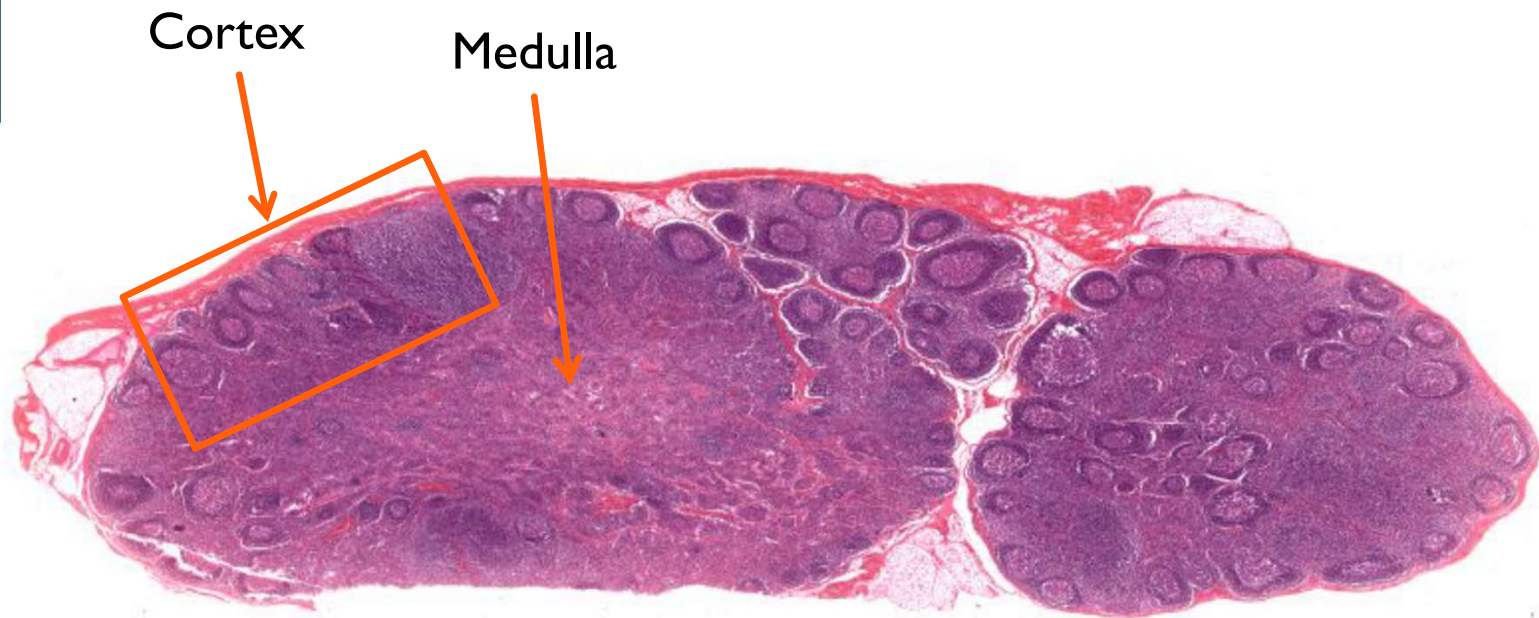
- Introduction
- Primary lymphoid organs
 - Bone marrow
 - Thymus
- Secondary lymphoid organs
 - Lymph nodes



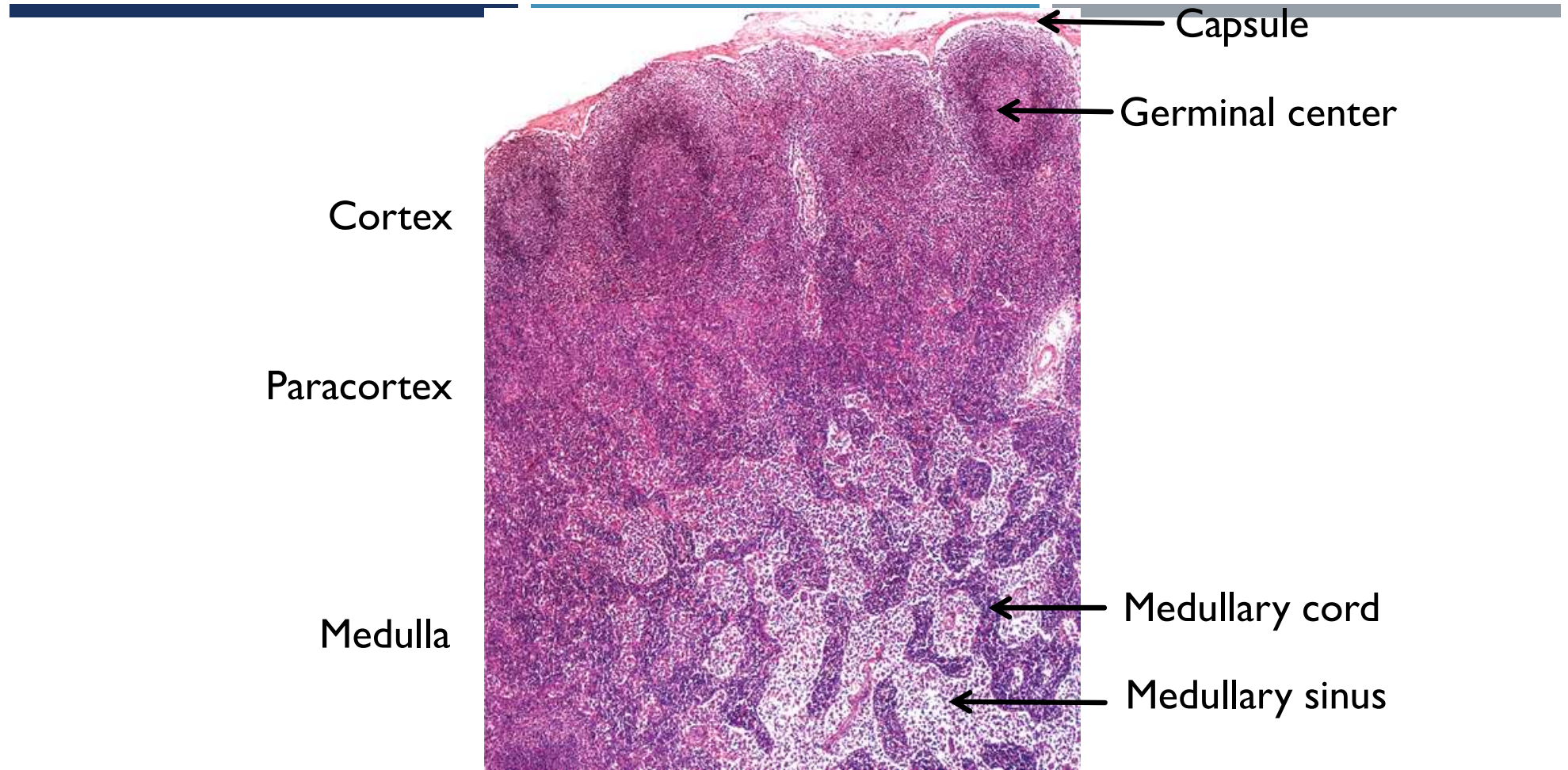
Lymph node

LYMPH NODE ARCHITECTURE

- **Outer cortex** contains round structures called lymphoid follicles (composed of B cells)
- **Paracortex** (inner cortex) contains T cells and high endothelial venules
- **Medulla** composed of cords (containing B cells and macrophages) and sinuses (containing reticular fibers, lymph, circulating cells and antigens)



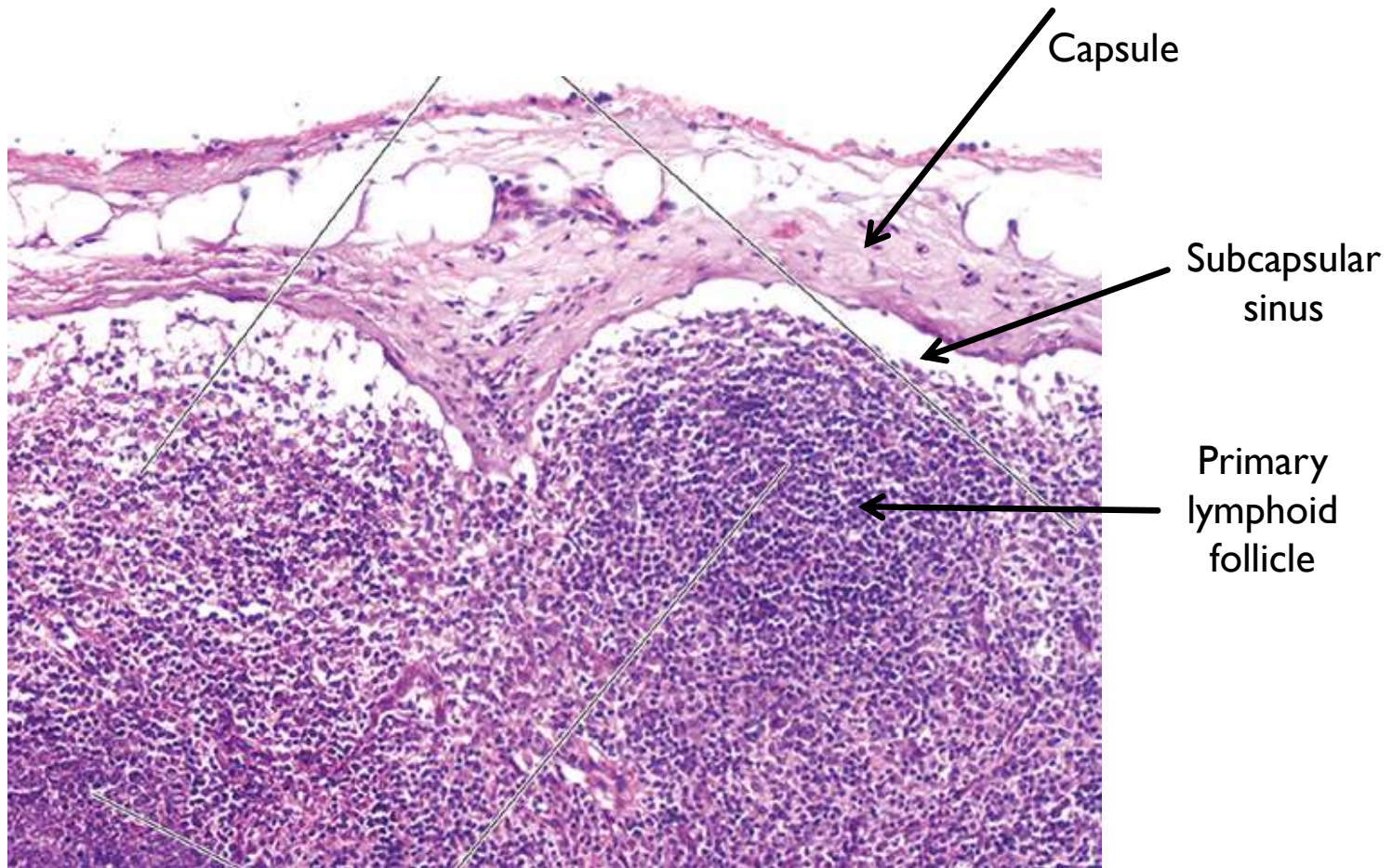
LYMPH NODE: LOW POWER



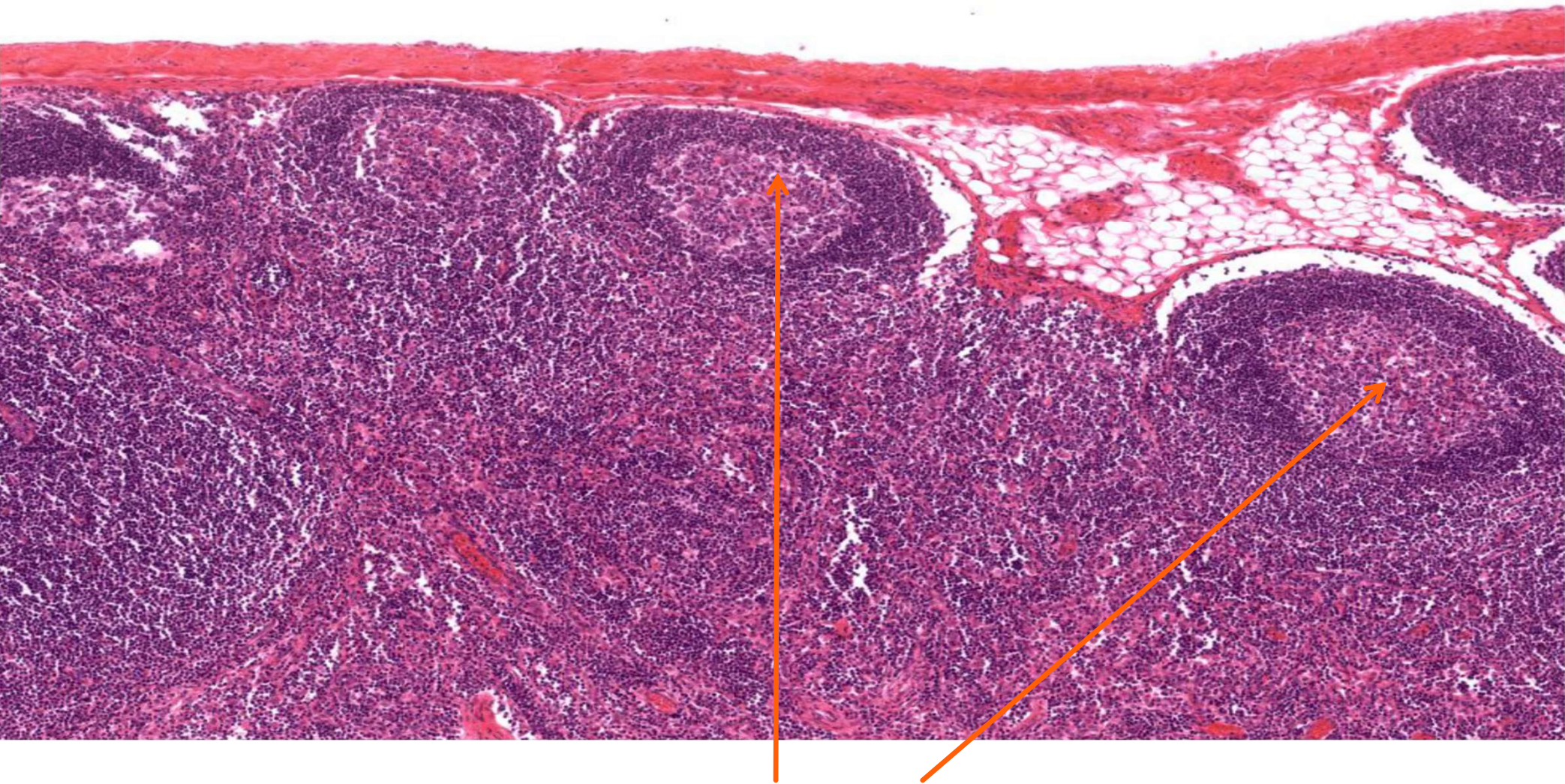
LYMPH NODE

LYMPH NODE FOLLICLES

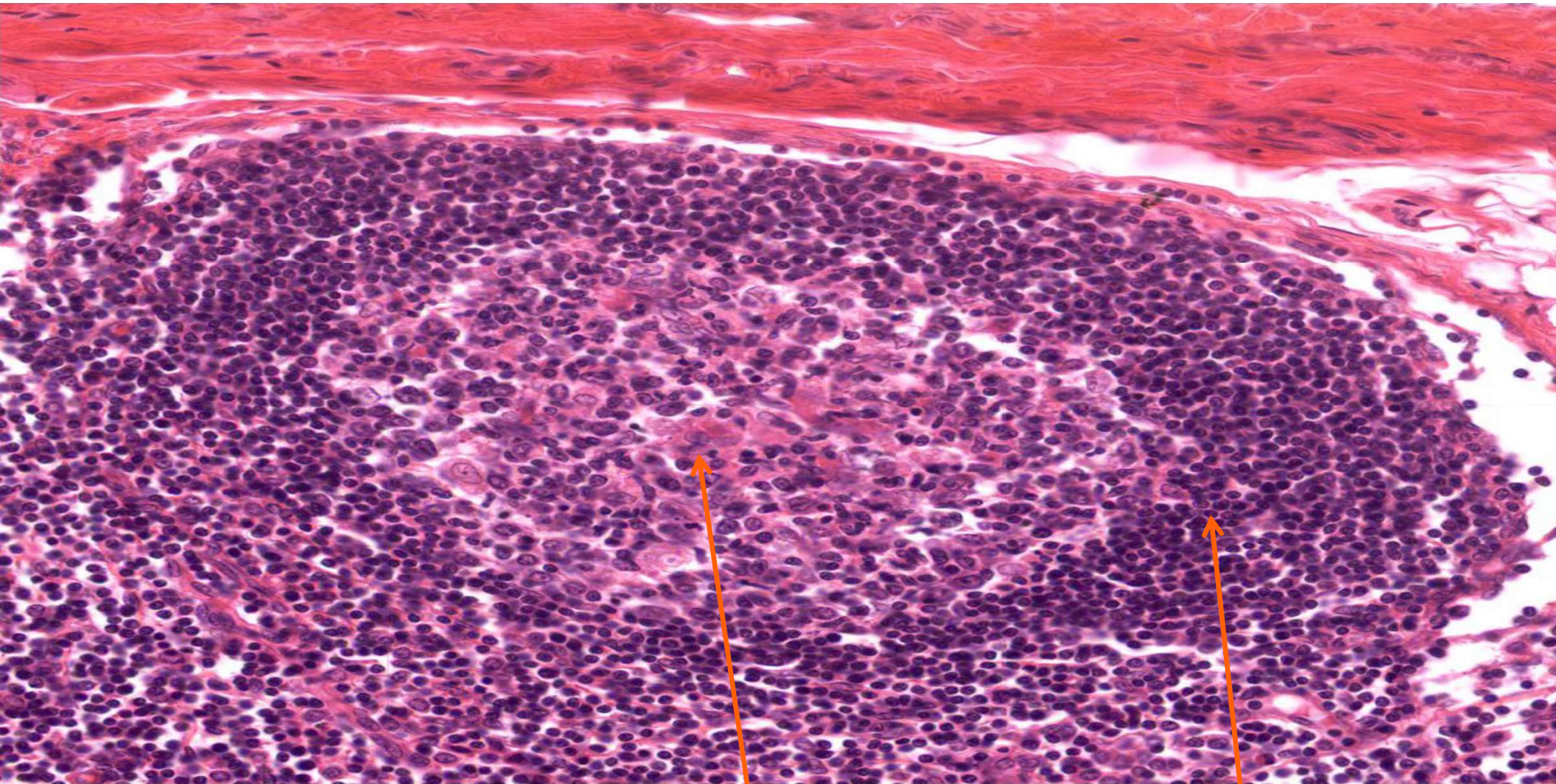
- **Primary (unstimulated) follicles** are composed of small, dark, mature lymphocytes.
- **Secondary (stimulated) follicles** are composed of:
 - Germinal center: a lighter-staining central area containing larger lymphocytes
 - Mantle zone: around germinal center; contains small, dark lymphocytes



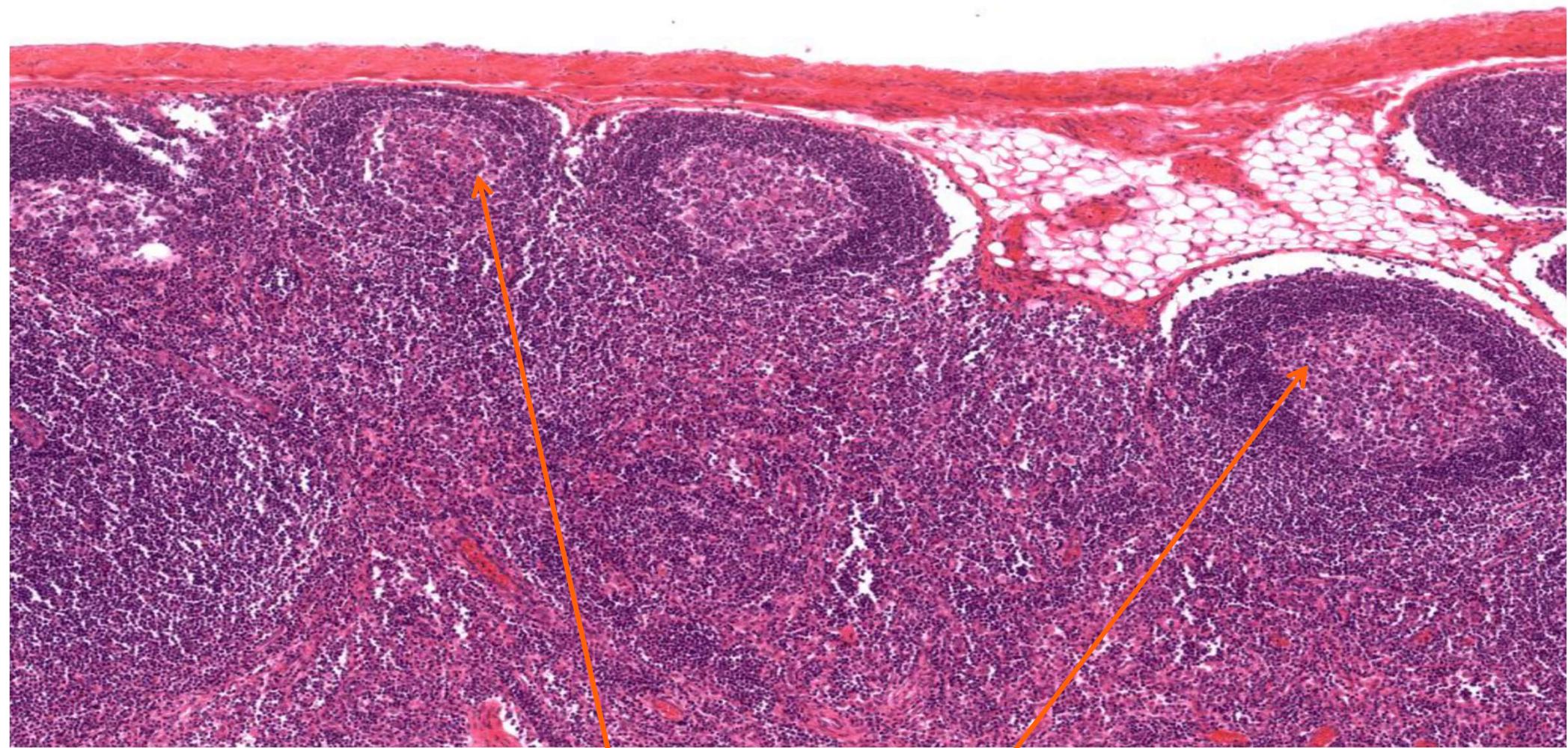
LYMPH NODE: PRIMARY FOLLICLES



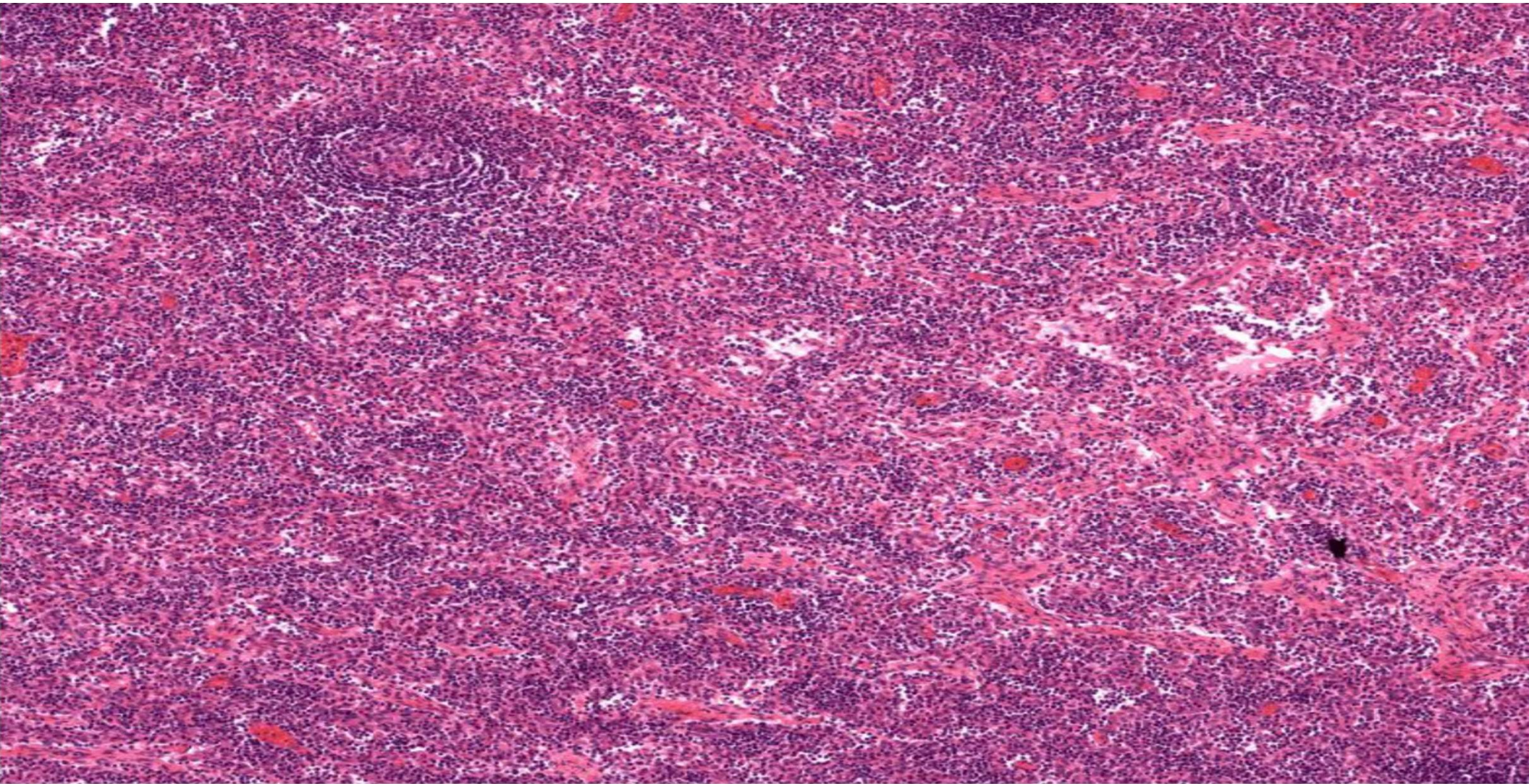
LYMPH NODE: SECONDARY FOLLICLES



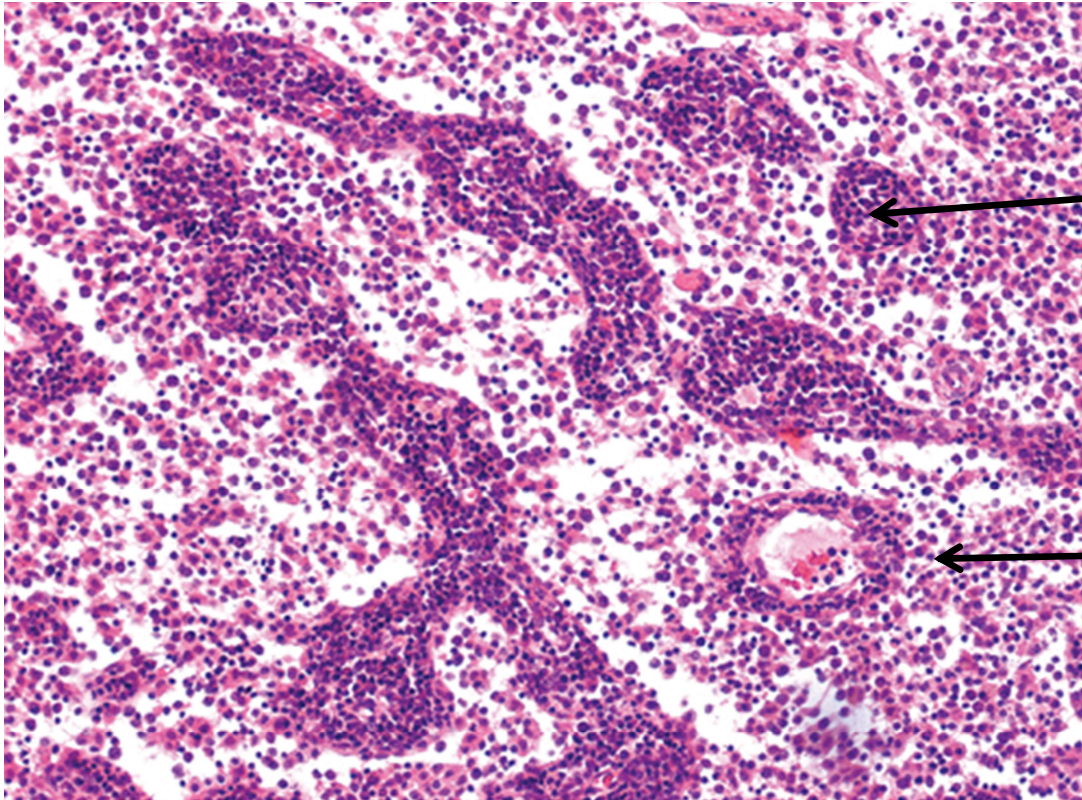
SECONDARY FOLLICLE WITH GERMINAL CENTER AND MANTLE ZONE



B CELLS ARE IN FOLLICLES; T CELLS ARE IN INTERFOLLICULAR AREAS



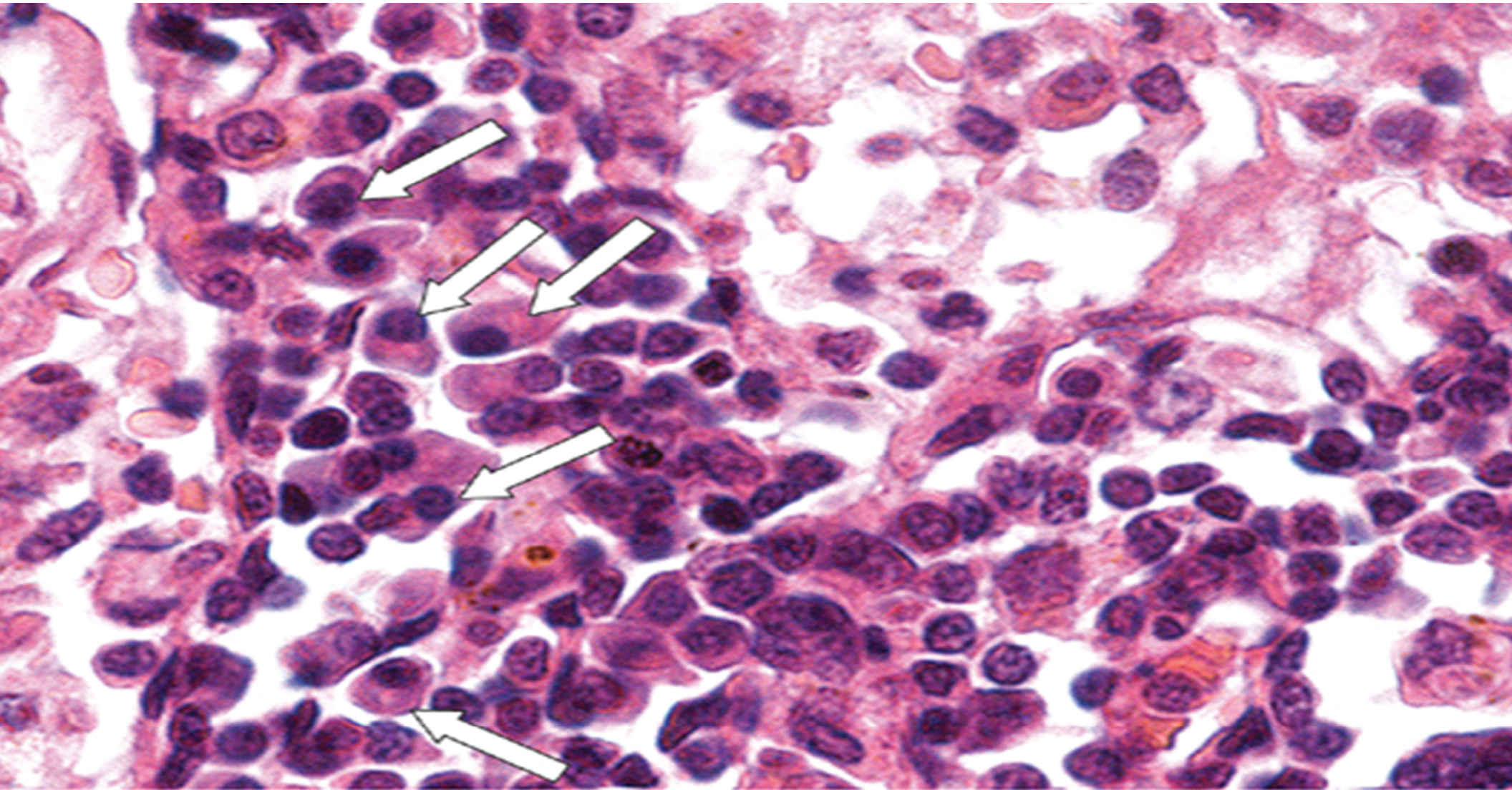
LYMPH NODE: MEDULLA



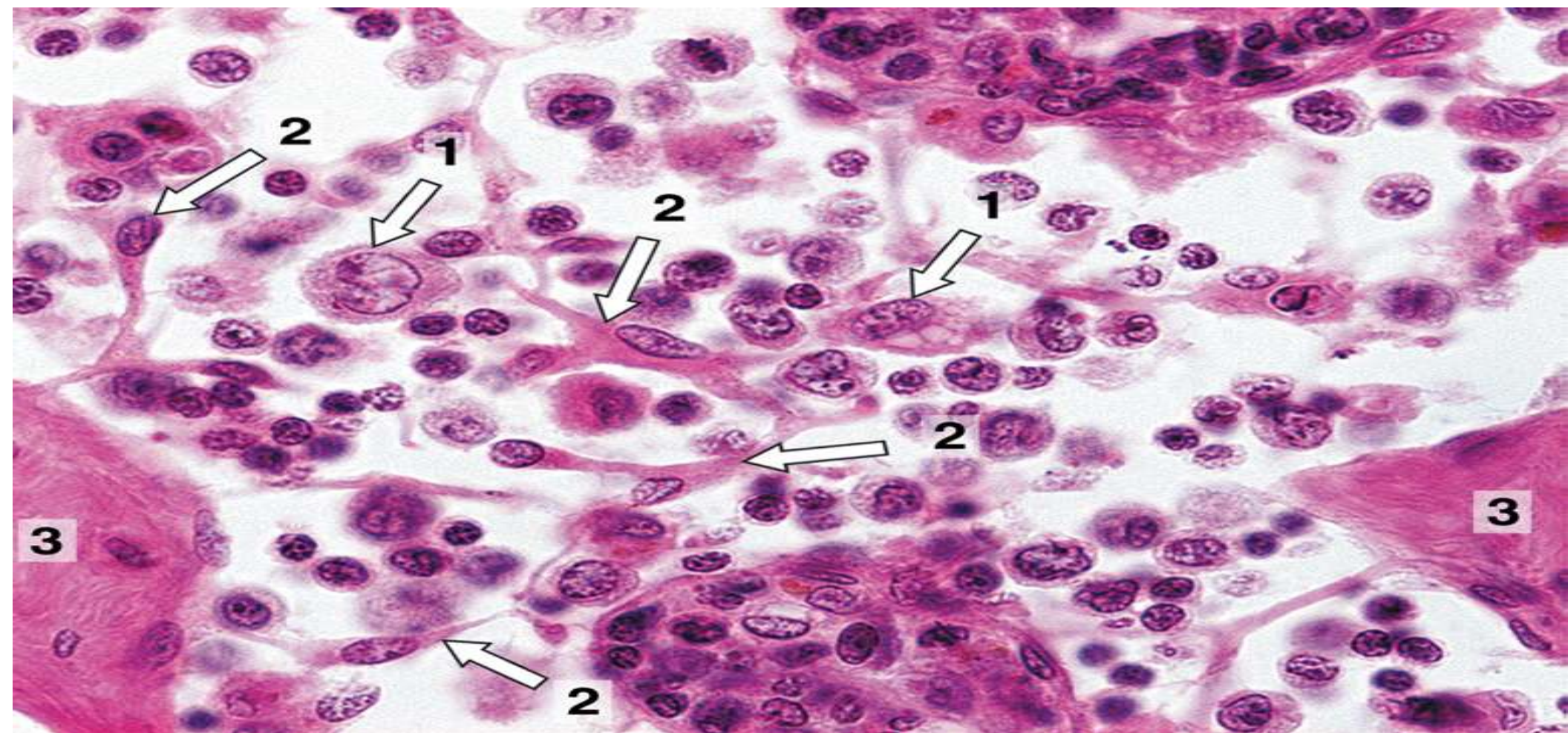
Medullary
cords contain B
cells, plasma
cells and
macrophages

Medullary
sinuses contain
reticular fibers,
lymph,
circulating cells
and antigens

LYMPH NODE: MEDULLA



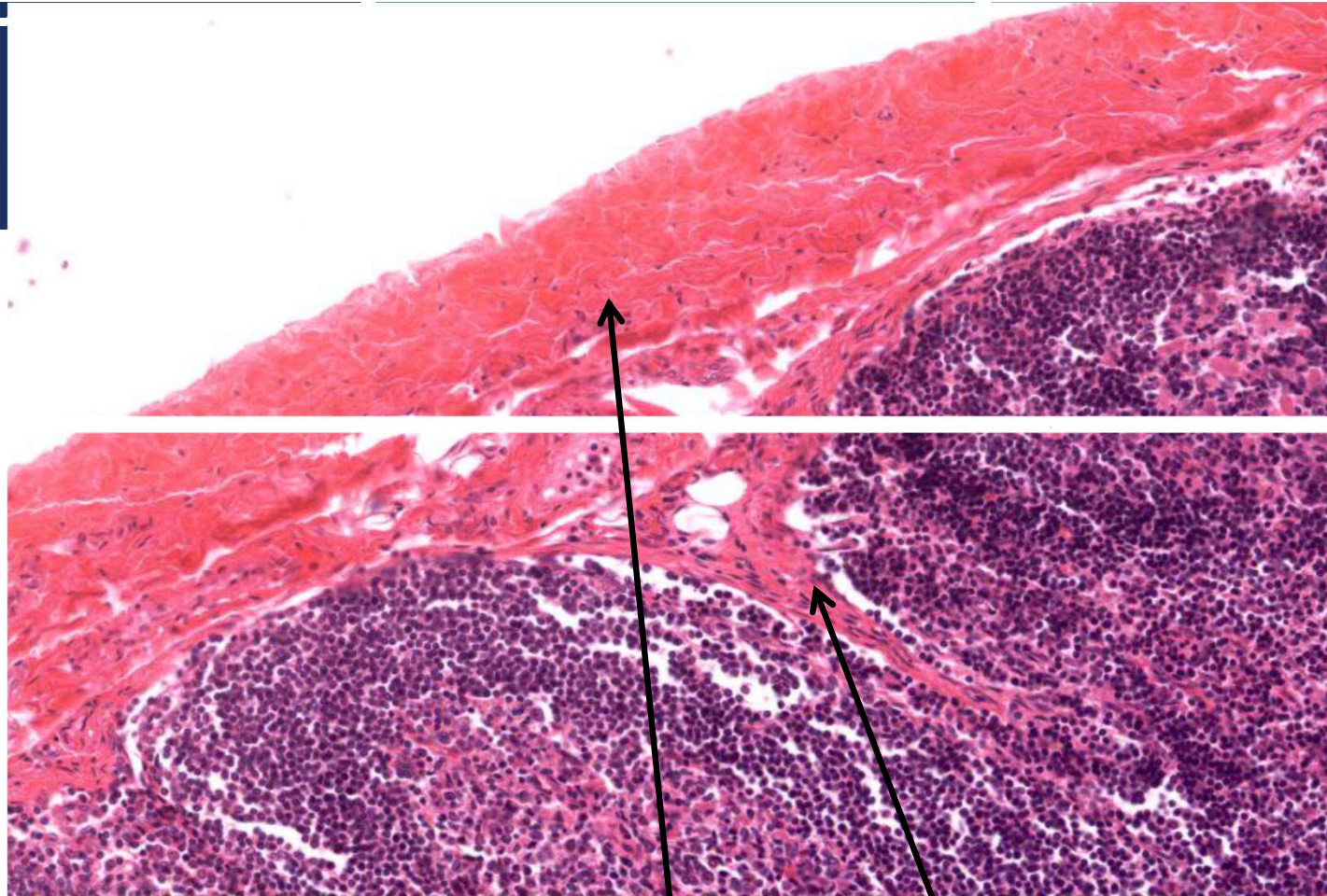
MEDULLARY CORD WITH TONS OF PLASMA CELLS (ARROWS)



MEDULLARY SINUS WITH MACROPHAGES (1),
RETICULAR CELLS (2) AND TRABECULAE (3)

LYMPH NODE STROMA

- The capsule and trabeculae consist of dense irregular connective tissue.
- The fine stroma consists of reticular connective tissue (fibroblasts and reticular fibers).



LYMPH NODE CAPSULE AND TRABECULUM

AFFERENT AND EFFERENT LYMPHATIC VESSELS

Afferent lymphatic vessels

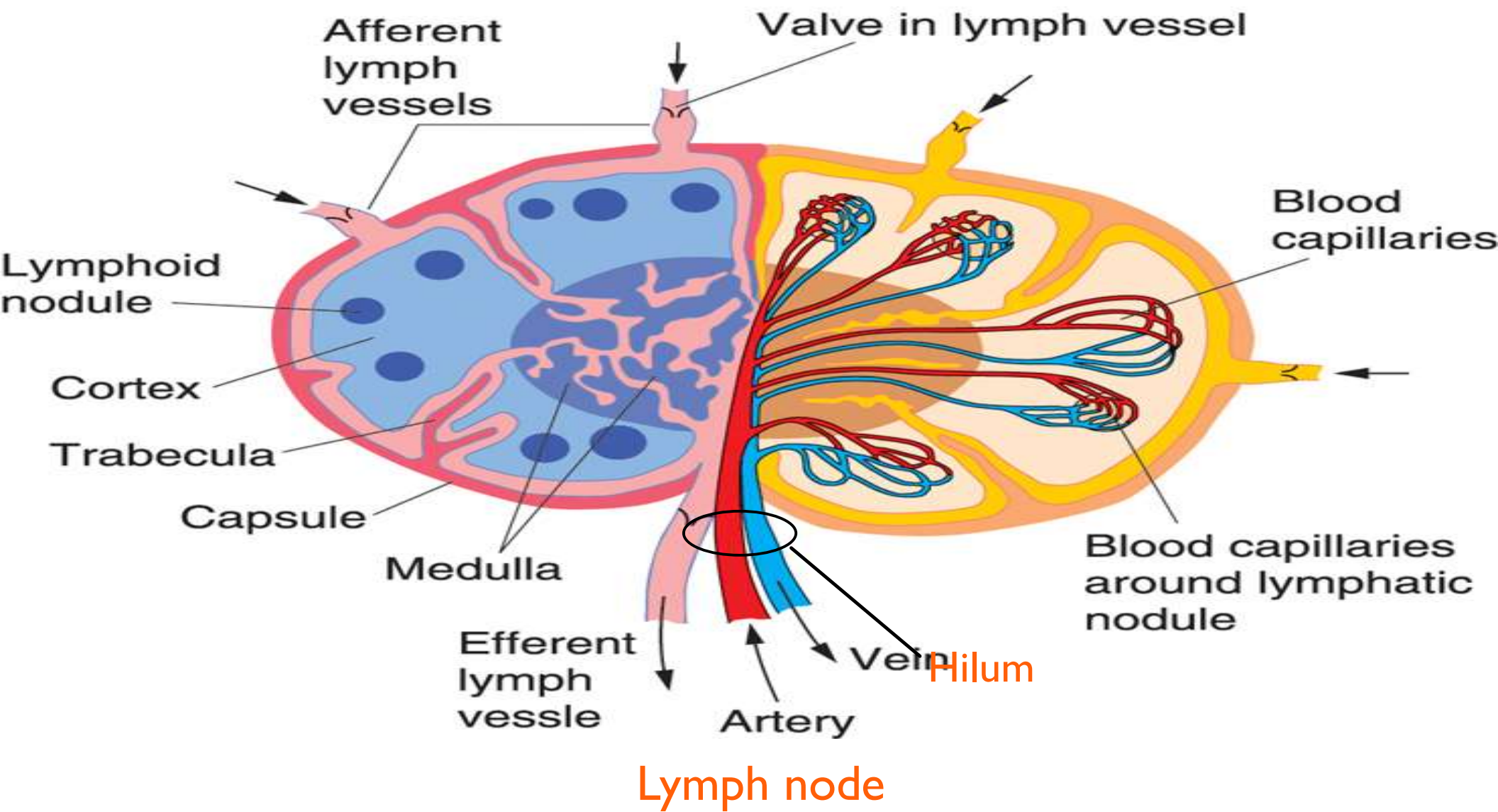
- Penetrate the capsule of the lymph node on the convex side.
- Carry lymph (with antigen and cells) from sites of infection back to the lymph nodes.

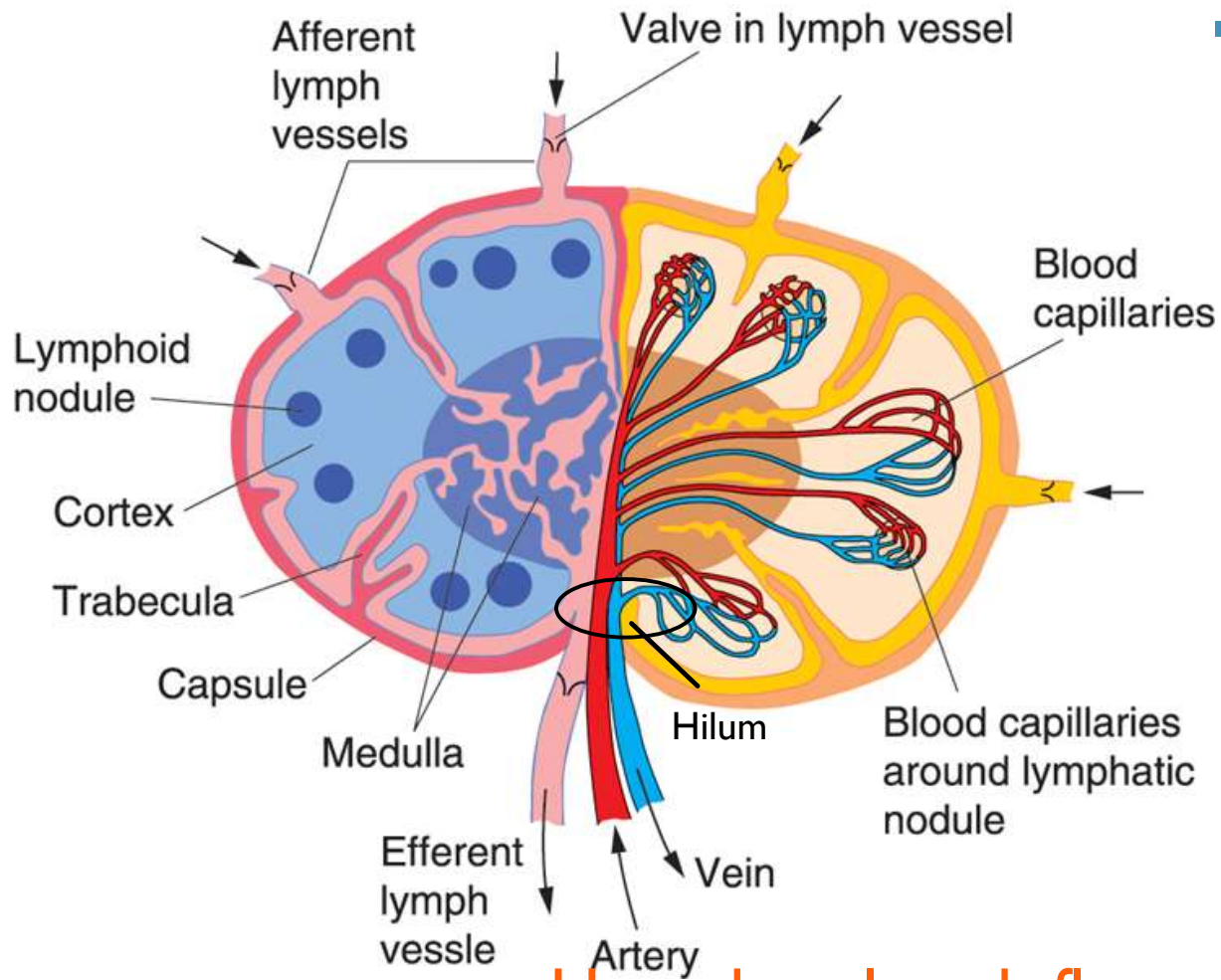
Efferent lymphatic vessels

- Leave through the the hilum.
- Carry lymph (with lymphocytes) from the lymph node and return them it to the blood.

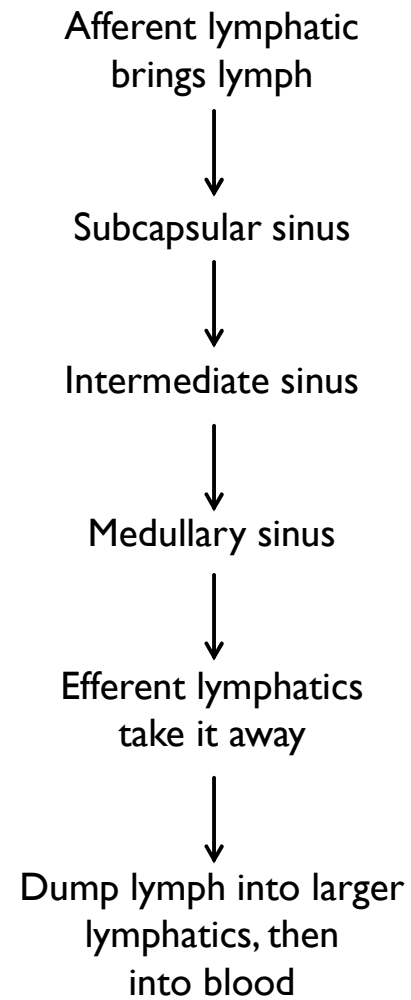
THE HILUM

- The hilum is a depression in the concave surface of the lymph node.
- Arteries and nerves enter at the hilum.
- Veins and efferent lymphatics leave at the hilum.



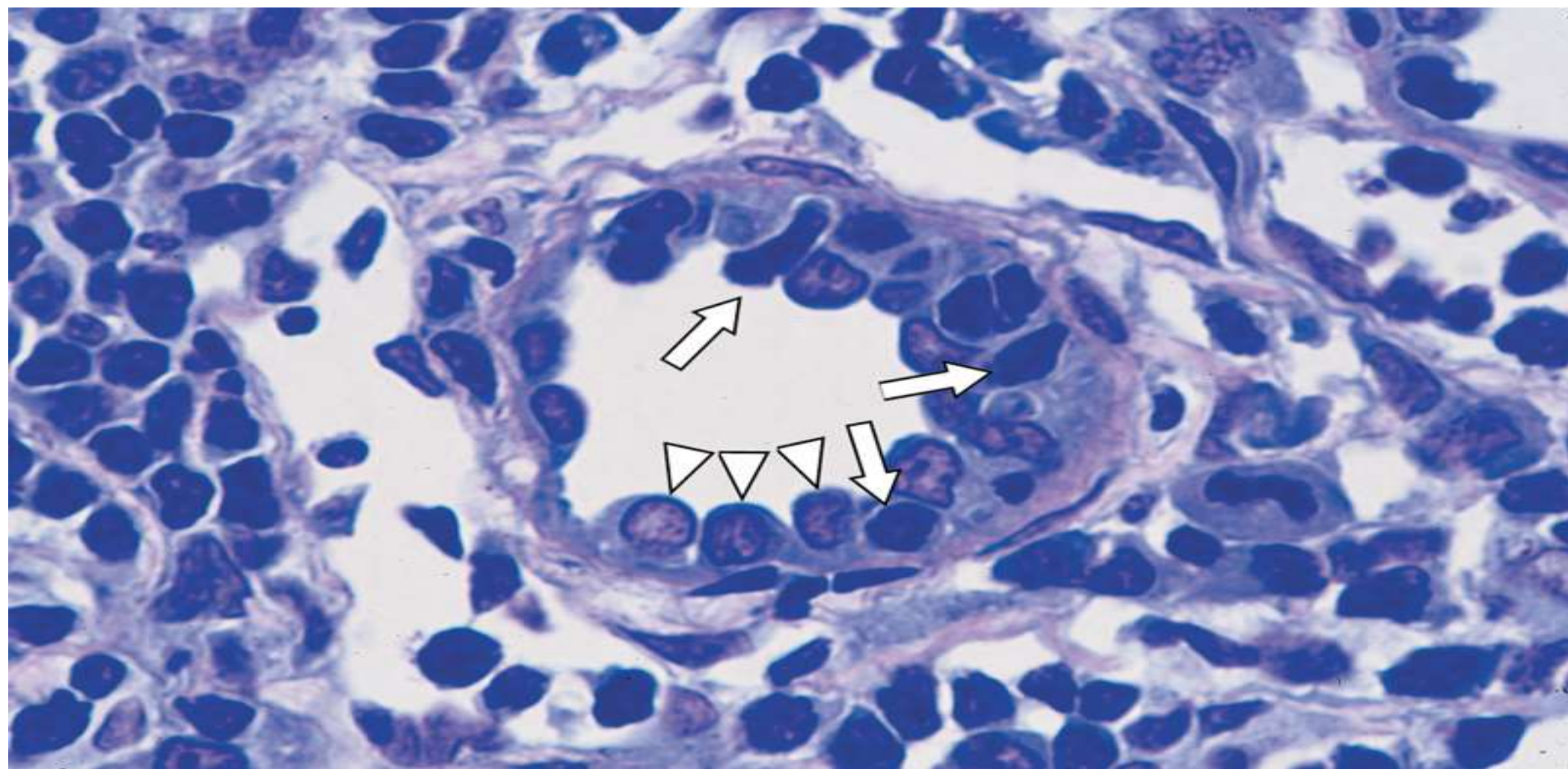


How does lymph flow through the node?



HIGH ENDOTHELIAL VENULES

- High-endothelial venules (venules with tall endothelial cells) in paracortex allow lymphocytes in blood vessels to adhere to endothelial cells and migrate across the vessel wall to the lymphoid tissue.
- Lymphocytes move from blood circulation to lymphatic circulation via high-endothelial venules.



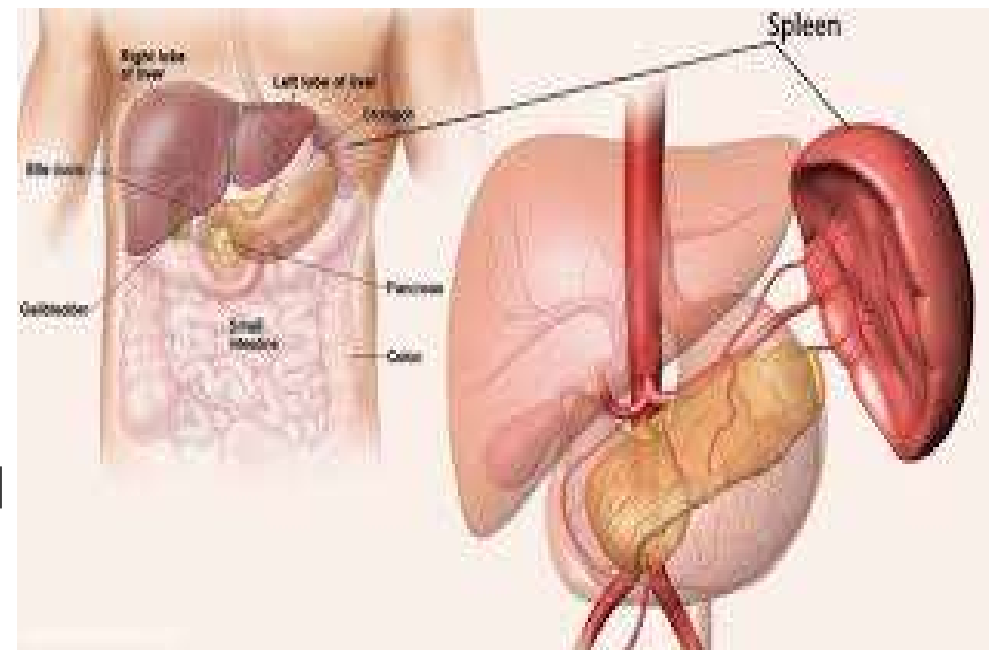
HIGH-ENDOTHELIAL VENULE IN LYMPH NODE

FLOW OF LYMPHOCYTES FROM BLOOD TO LYMPH IN LYMPH NODE

- Lymphocytes enter the lymph node in arterial vessels in the hilum, travel through arterioles and capillaries to high-endothelial venules in paracortex.
- Lymphocytes squeeze between endothelial cells of high-endothelial venules and enter lymphatic circulation in the cortex of the lymph node.
- Lymphocytes leave the node via efferent lymphatic vessels in the hilum.

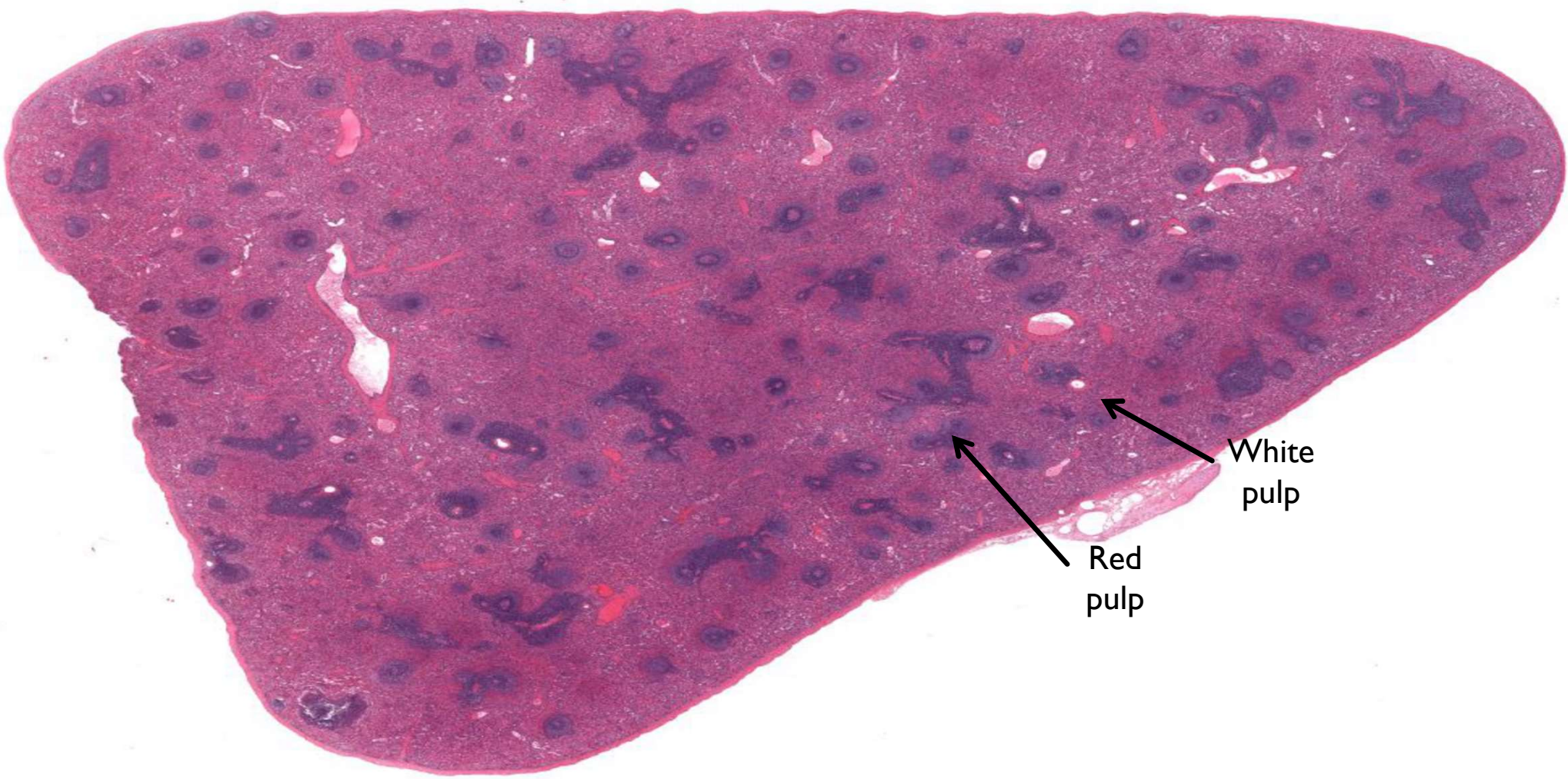
FUNCTIONS OF THE SPLEEN

- Immunologic filtration of blood (trapping of antigens)
- Activation and proliferation of lymphocytes
- Removal of old red cells, platelets and debris (by macrophages)



STRUCTURE OF THE SPLEEN

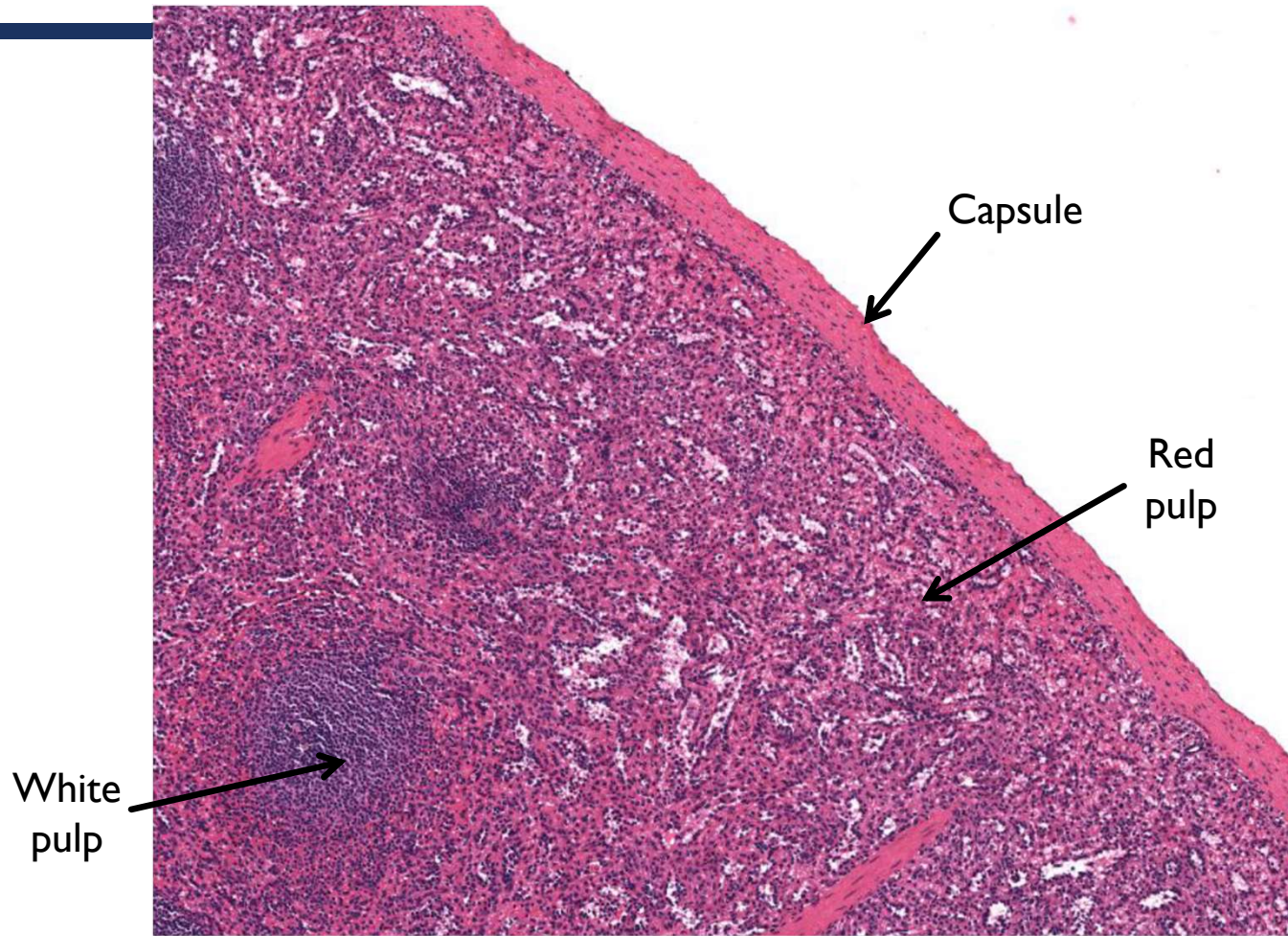
- The parenchyma of spleen is called splenic pulp and consists of white pulp and red pulp.
- No cortex or medulla are present.
- Stroma consists of capsule, trabeculae, and reticular connective tissue.
- Hilum contains nerves, arteries and veins.



White
pulp

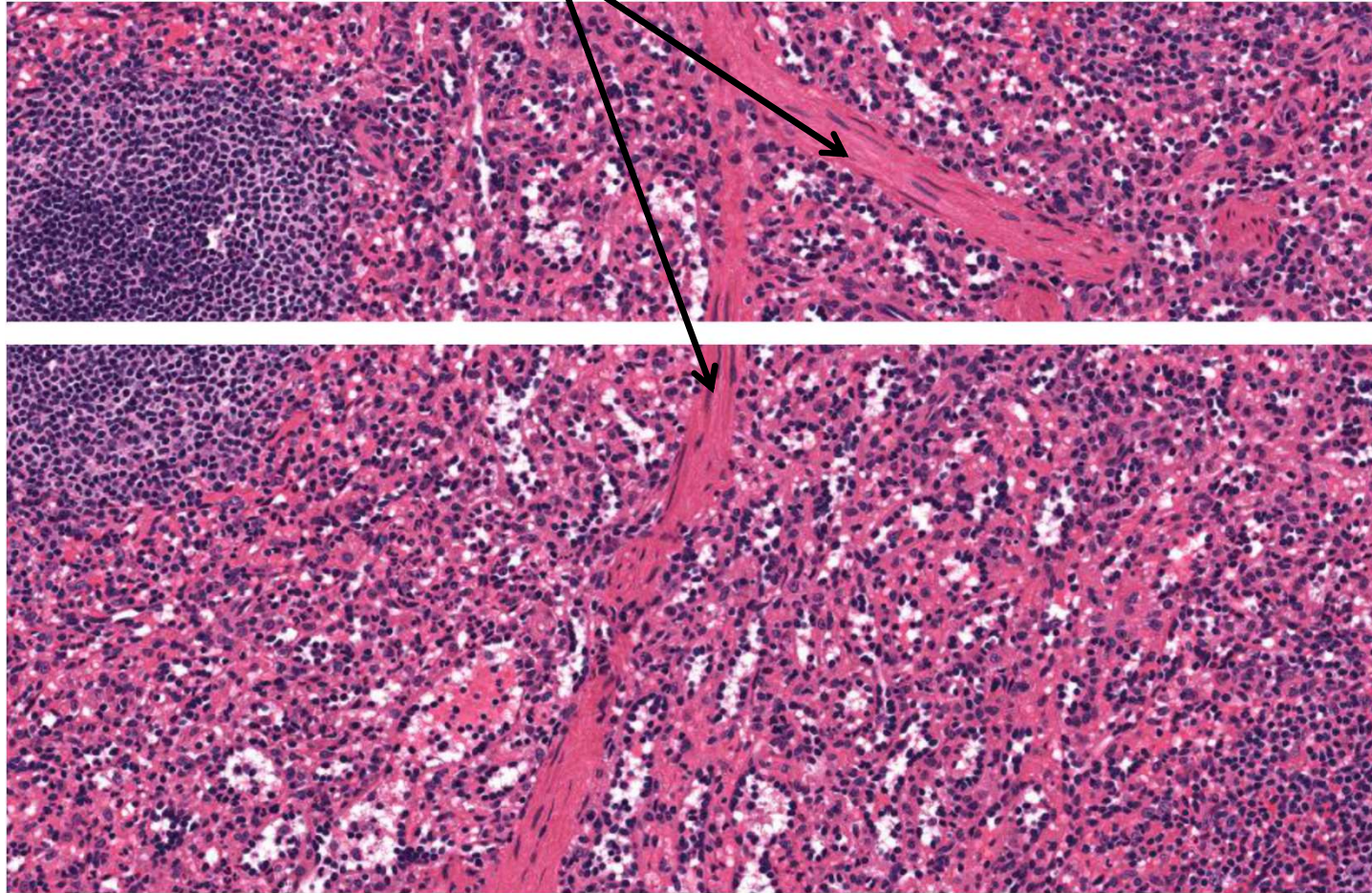
Red
pulp

SPLEEN: SUPER LOW POWER VIEW



SPLEEN: CAPSULE

Trabeculae



SPLEEN: TRABECULAE

WHITE PULP OF THE SPLEEN

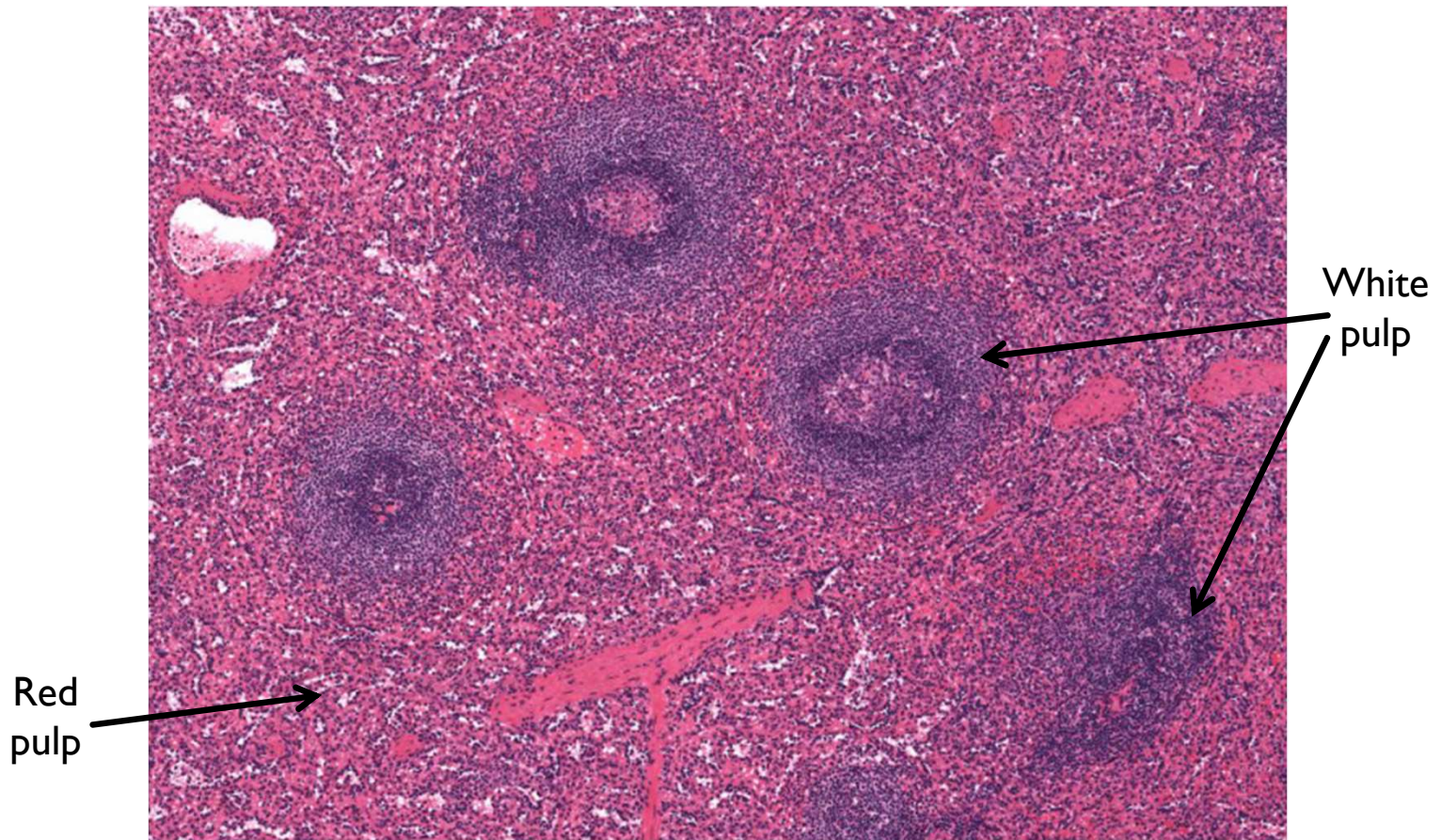
White pulp consists of:

Periarteriolar lymphatic sheaths (PALS)

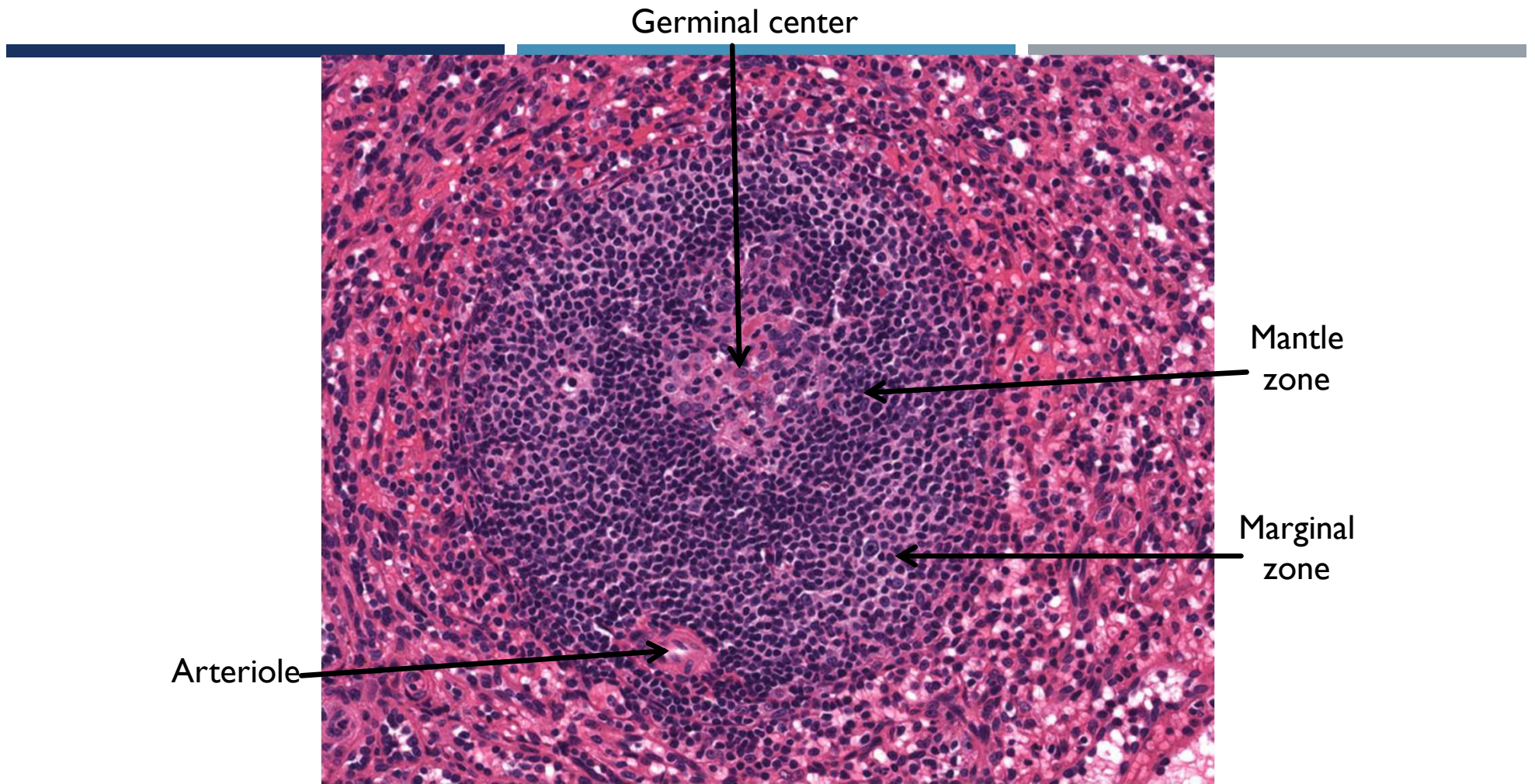
- Circular collections of T cells around arterioles

Splenic follicles (nodules)

- Just like secondary follicles in lymph nodes, except with one more layer: the marginal zone
- Composed of B cells
- Usually have arteriole at periphery



SPLEEN: WHITE AND RED PULP

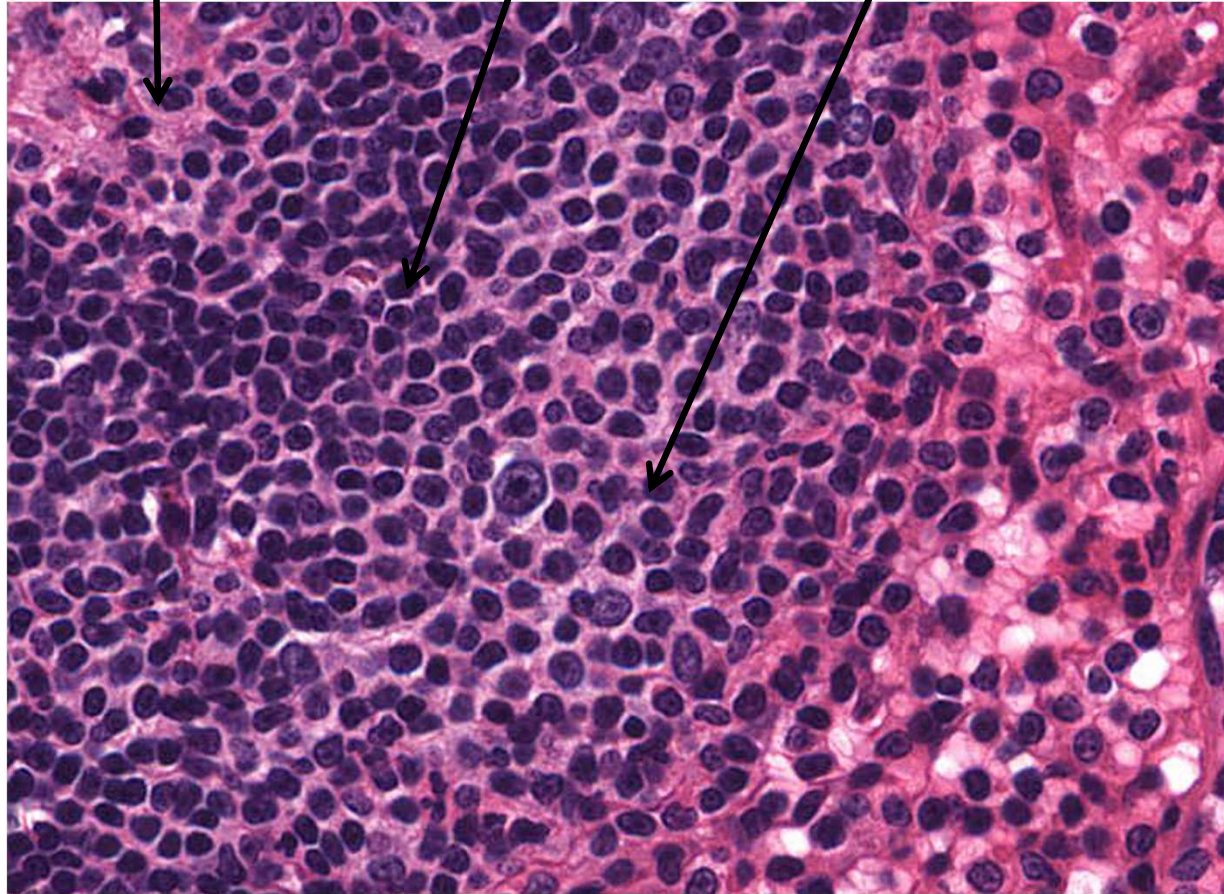


SPLEEN: CUTE FOLLICLE

Germinal center

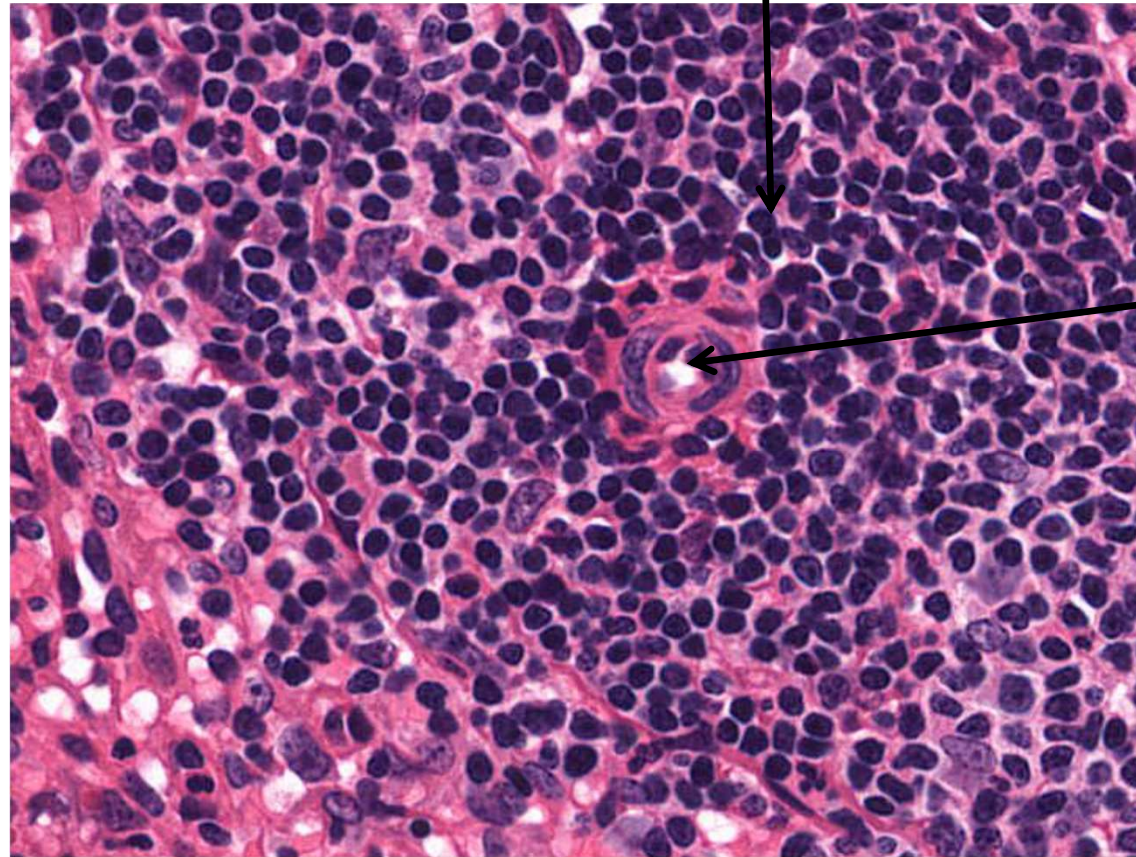
Mantle zone

Marginal zone



SPLEEN: HIGHER POWER OF FOLLICLE

Periarteriolar lymphatic sheath



Arteriole

**SPLEEN: PERIARTERIOLEAR LYMPHATIC SHEATH
(PALS)**

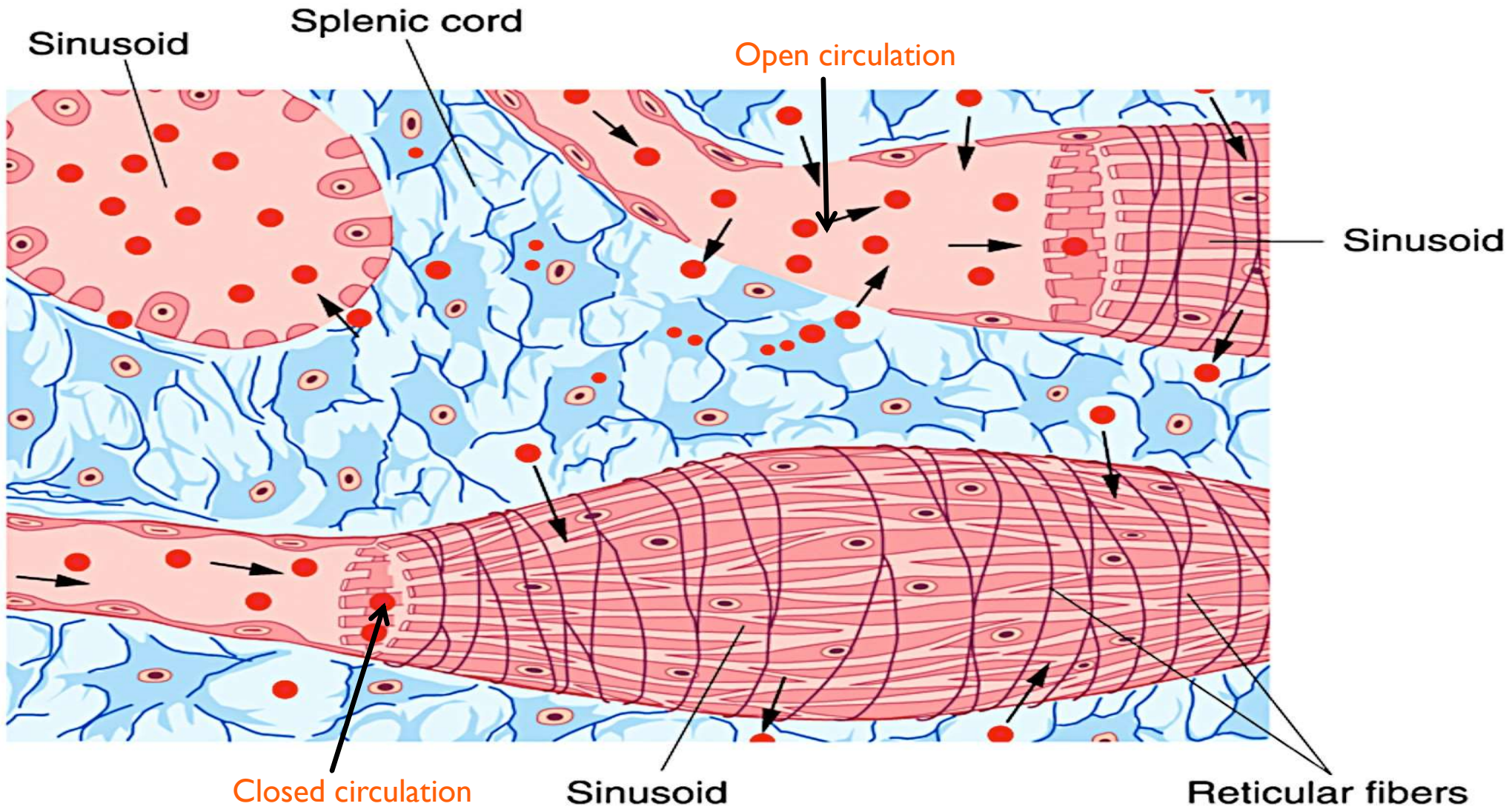
RED PULP OF THE SPLEEN

Splenic sinuses (sinusoids)

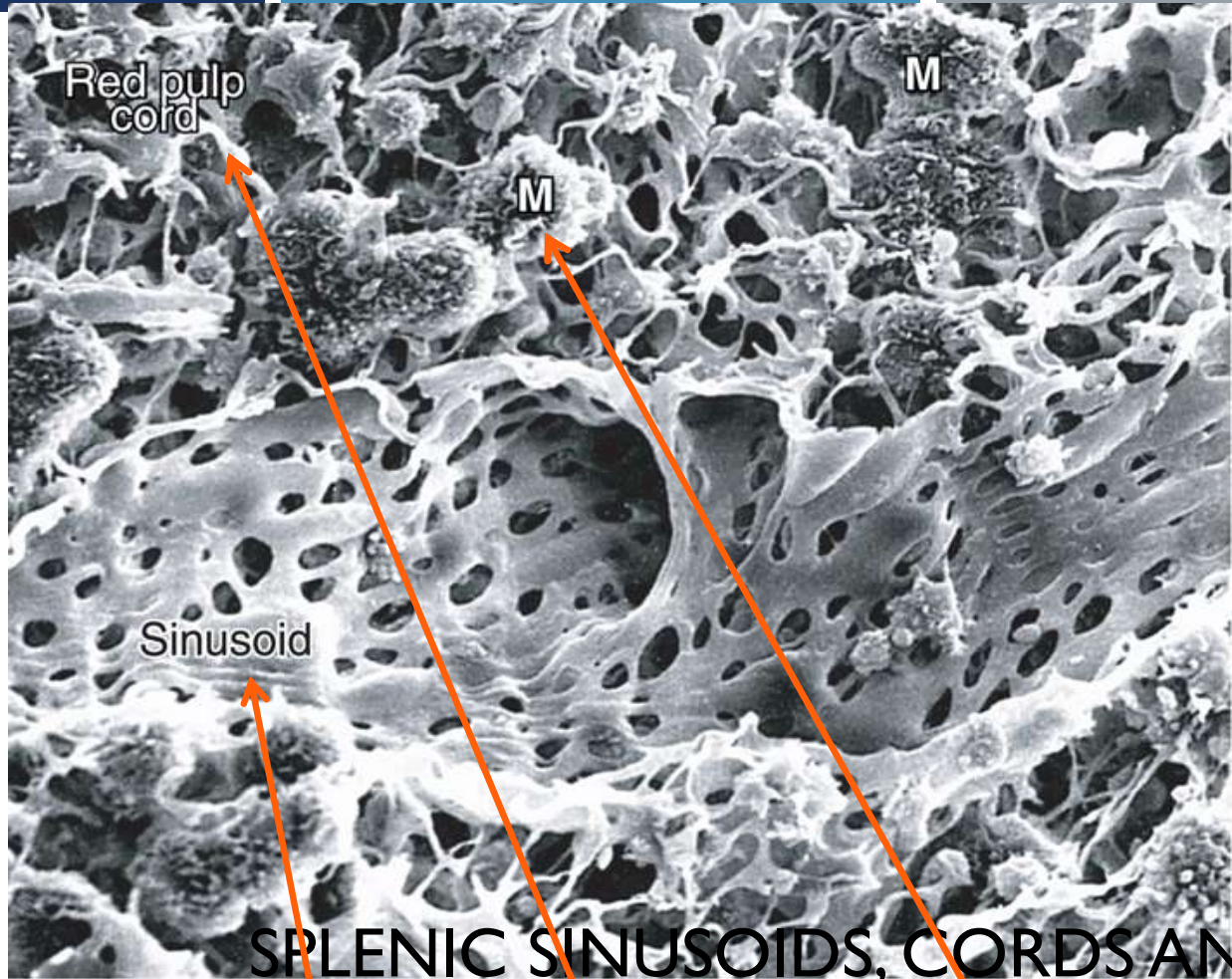
- Leaky vessels lined by specialized endothelial cells (“stave cells”) and surrounded by rings of reticular fibers like hoops on a barrel
- Healthy red cells easily squeeze through!
- Old or damaged red cells get stuck

Splenic cords (cords of Billroth)

- Located between sinuses
- Contain red cells, granulocytes, lymphocytes, macrophages, platelets, and plasma cells



OPEN AND CLOSED CIRCULATION



Red pulp
cord

M

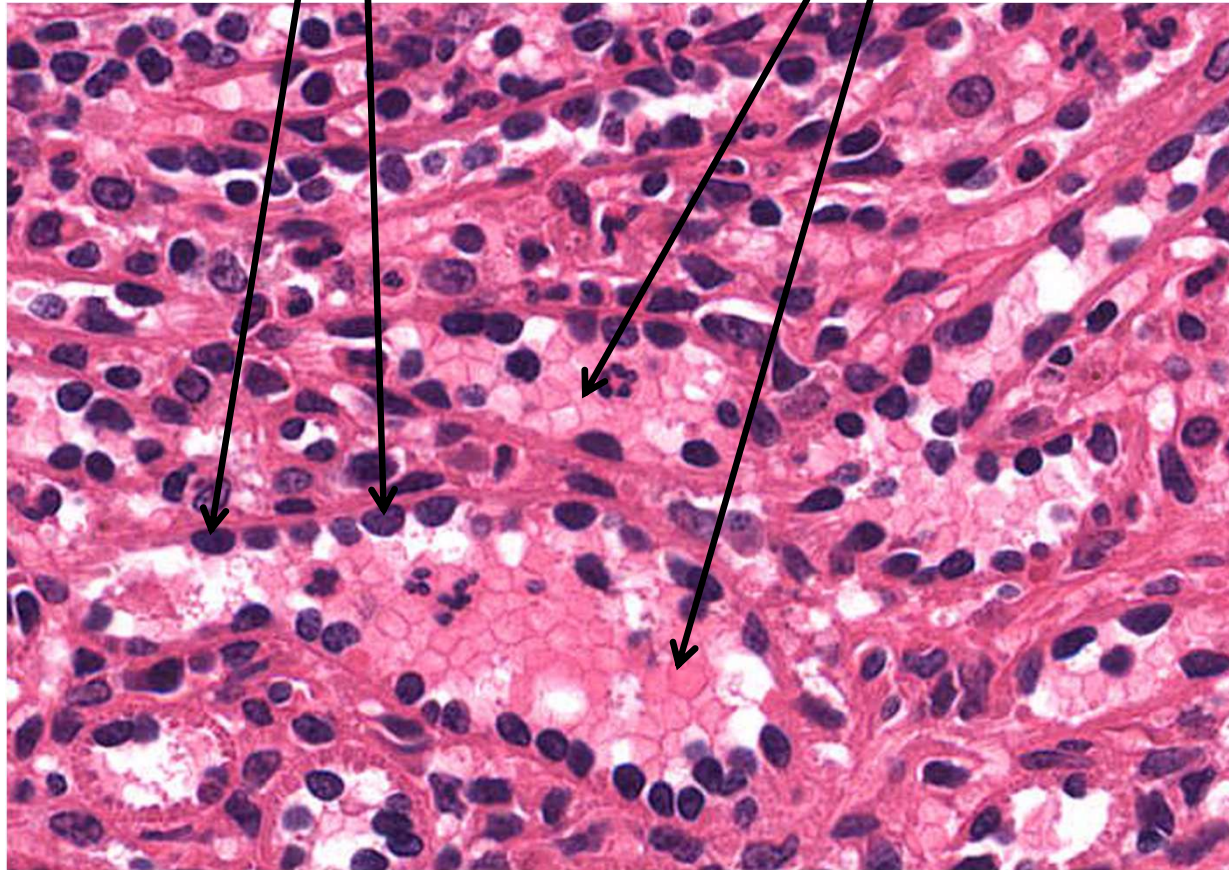
M

Sinusoid

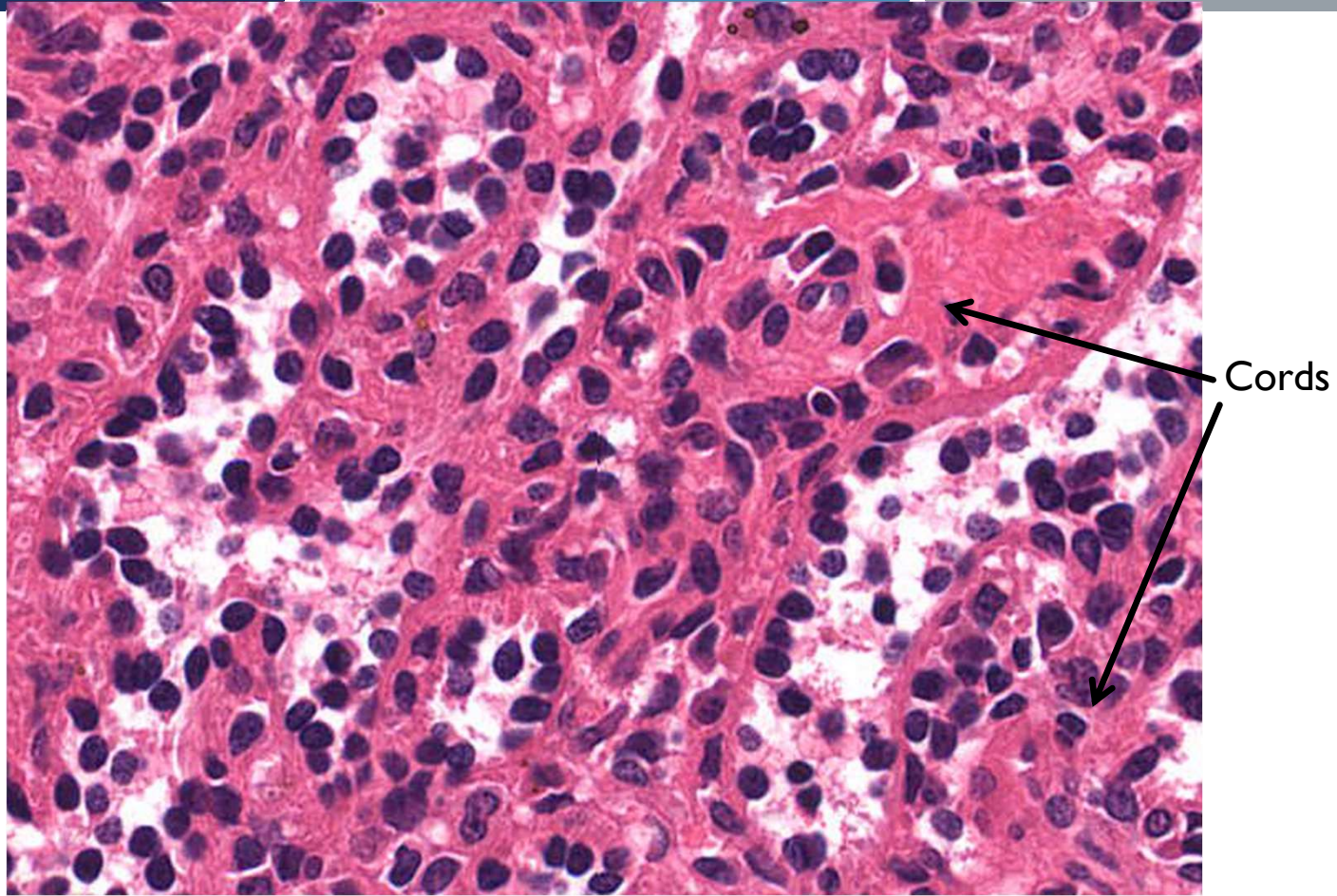
**SPLenic SINUSOIDS, CORDS AND
MACROPHAGES**

Endothelial cells

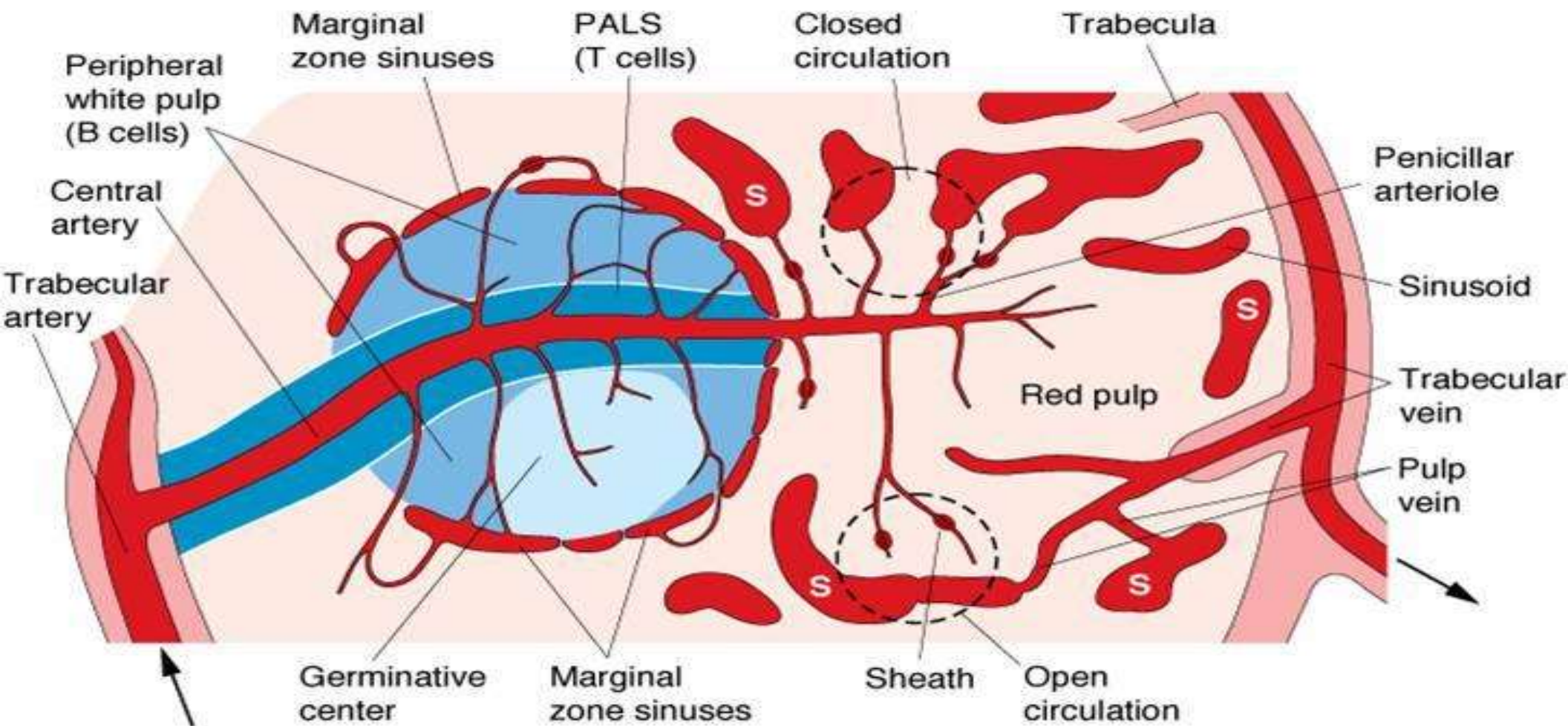
Sinusoids



SPLEEN: SPLENIC SINUSOIDS

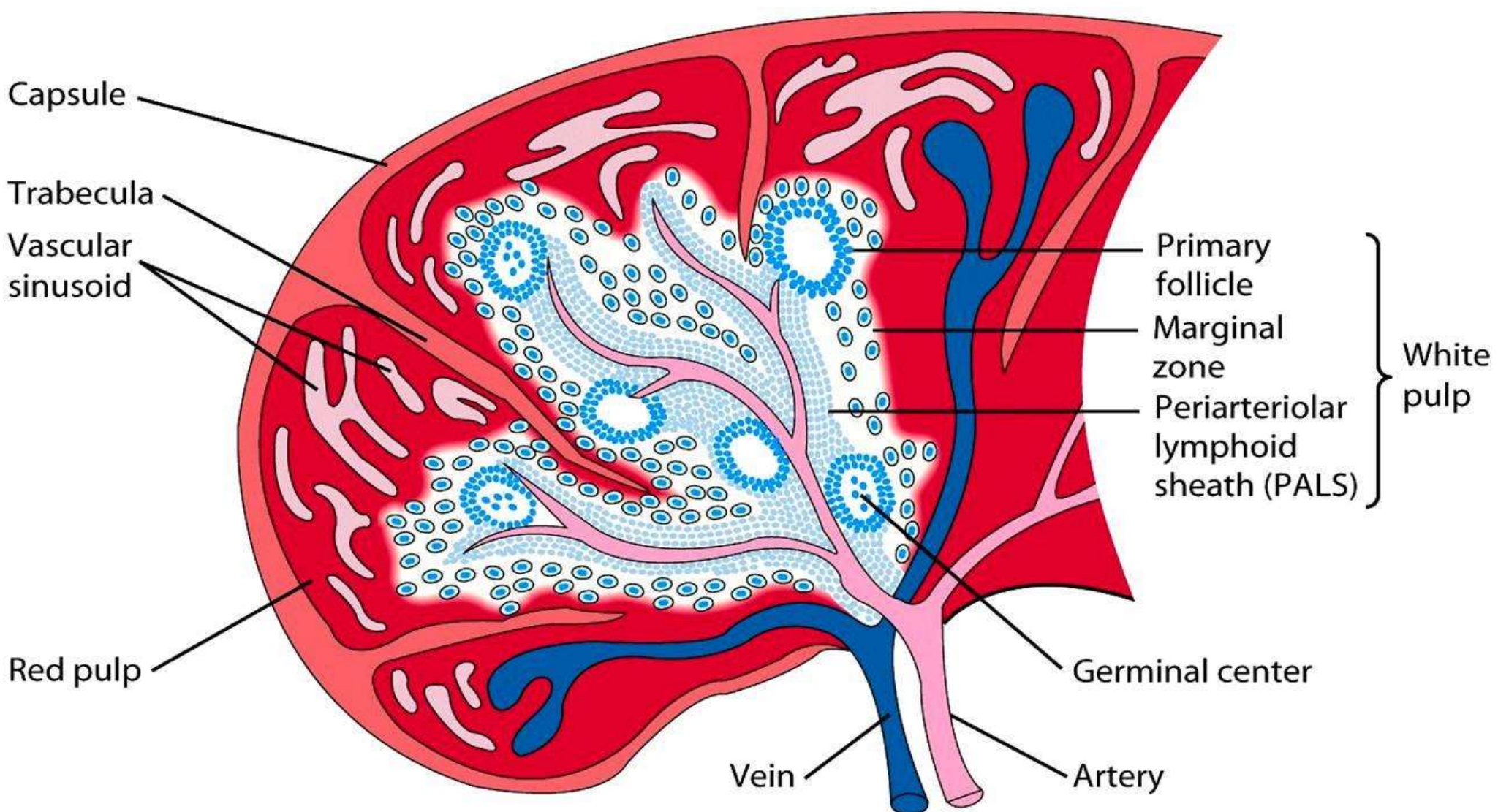


SPLEEN: CORDS OF BILLROTH



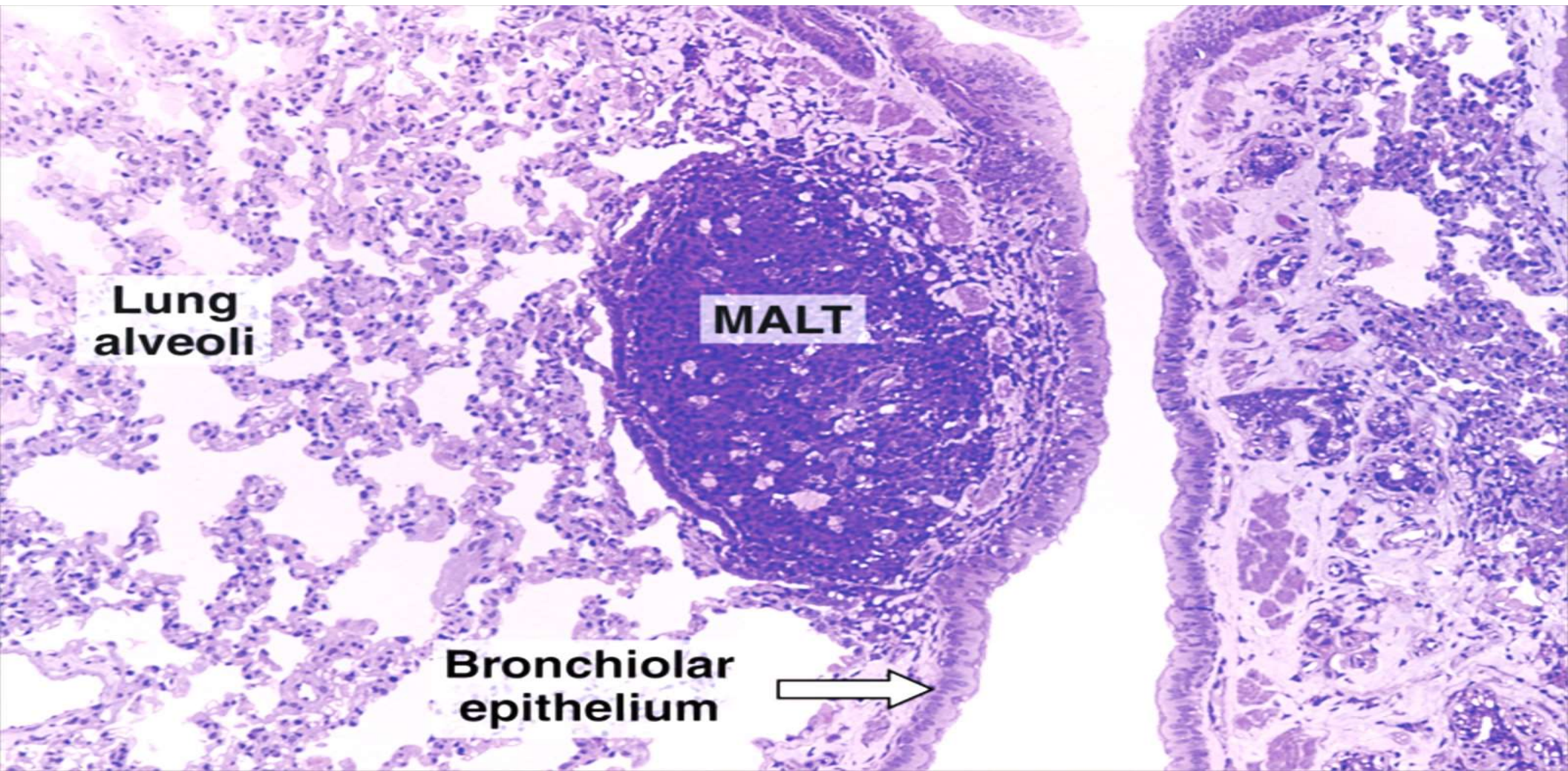
Source: Mescher AL: *Junqueira's Basic Histology: Text and Atlas, 12th Edition*: <http://www.accessmedicine.com>
 Copyright © The McGraw-Hill Companies, Inc. All rights reserved.

BLOOD FLOW IN THE SPLEEN

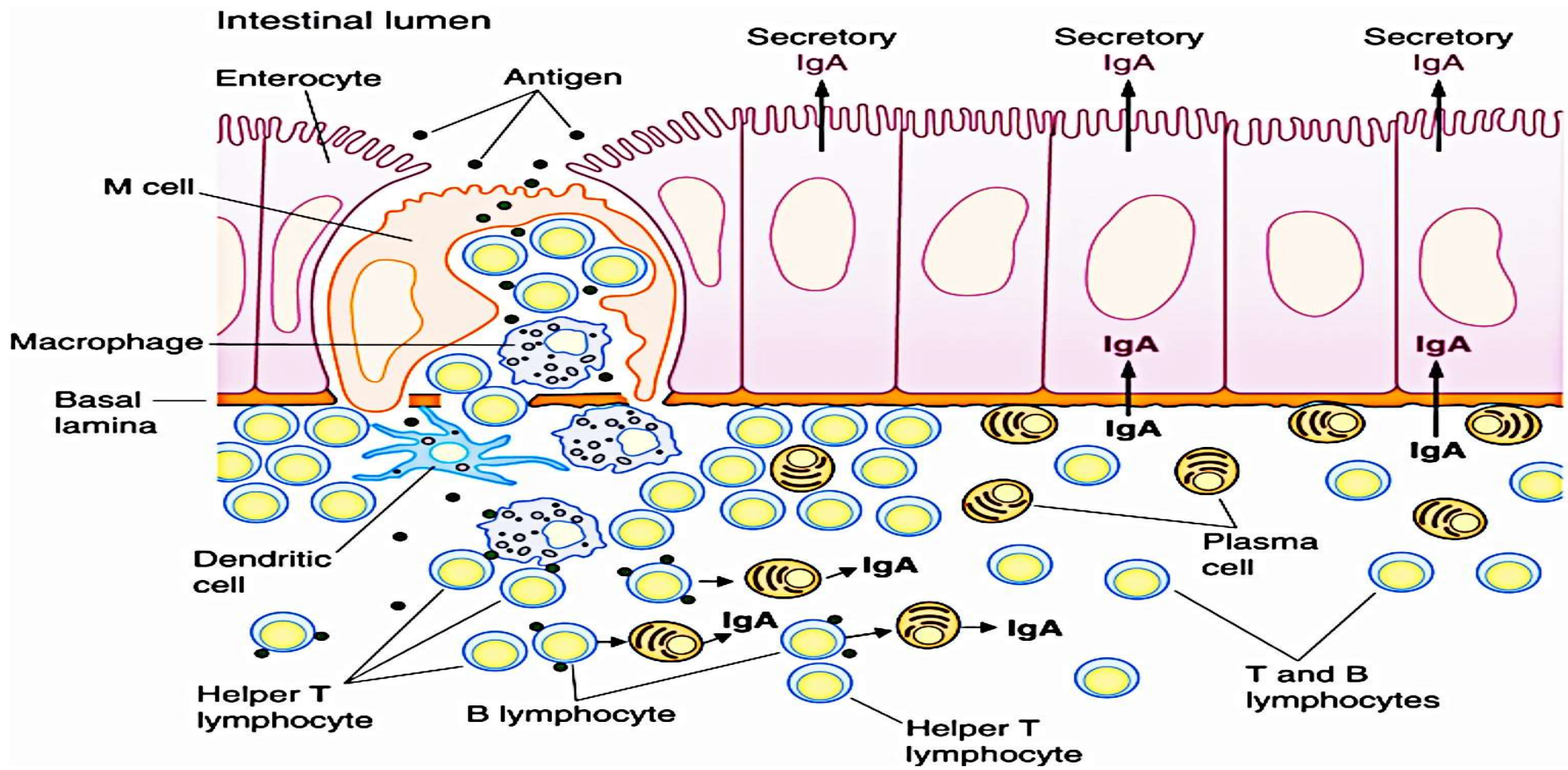


MUCOSA-ASSOCIATED LYMPHOID TISSUE (MALT)

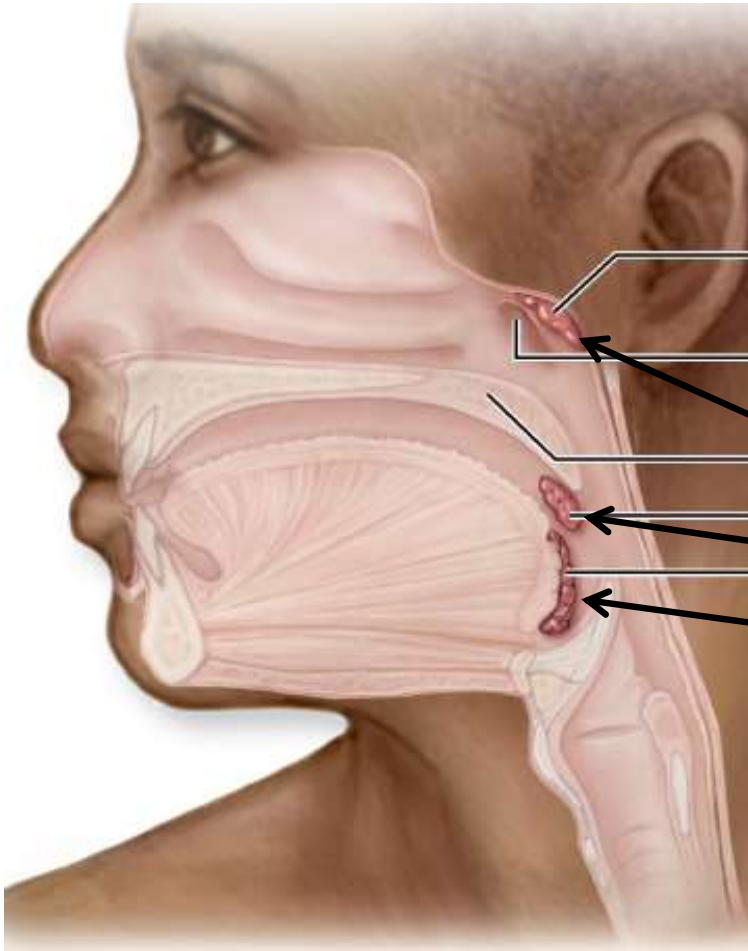
- Lymphoid tissue in mucosa and submucosa of digestive, respiratory, reproductive and urinary systems.
- Examples: tonsils, Peyer's patches (ileum), lymphoid tissue in oral mucosa.



MALT IN LUNG



PEYER'S PATCH IN ILEUM



- Tonsils are aggregates of lymphoid follicles beneath the epithelium of the posterior oral cavity and nasopharynx.
- Three tonsils:
 - Pharyngeal
 - Palatine
 - Lingual

TONSILS

THREE TYPES OF TONSILS

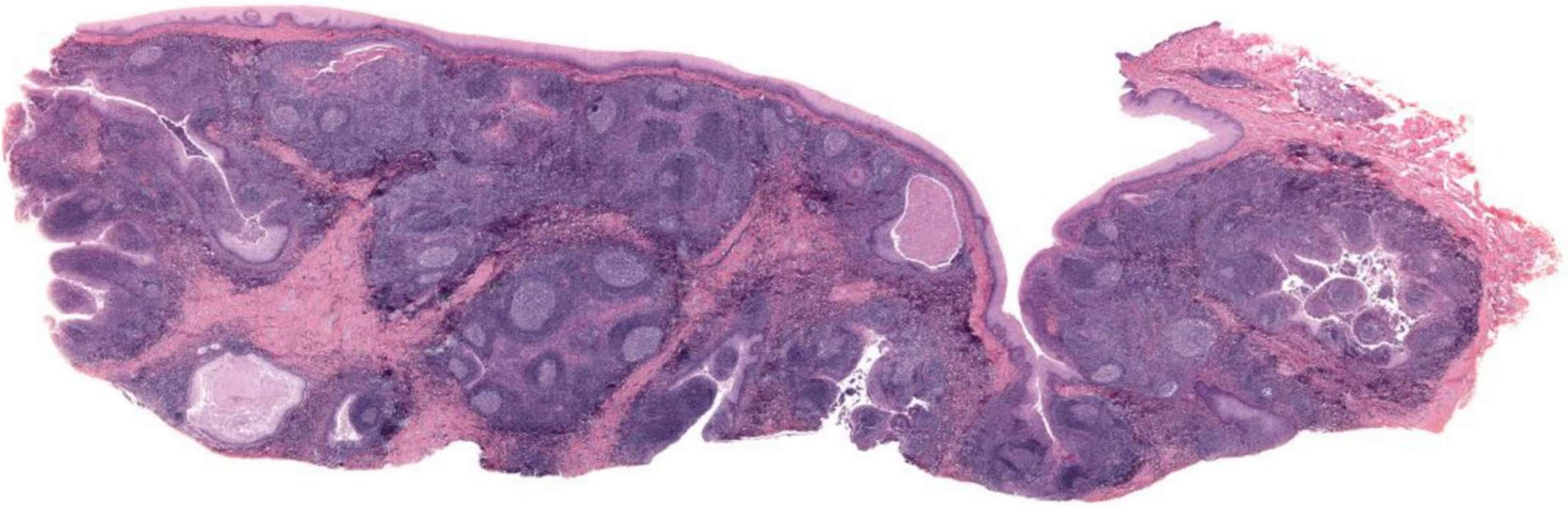
- Pharyngeal
- Palatine
- Lingual

THREE TYPES OF TONSILS

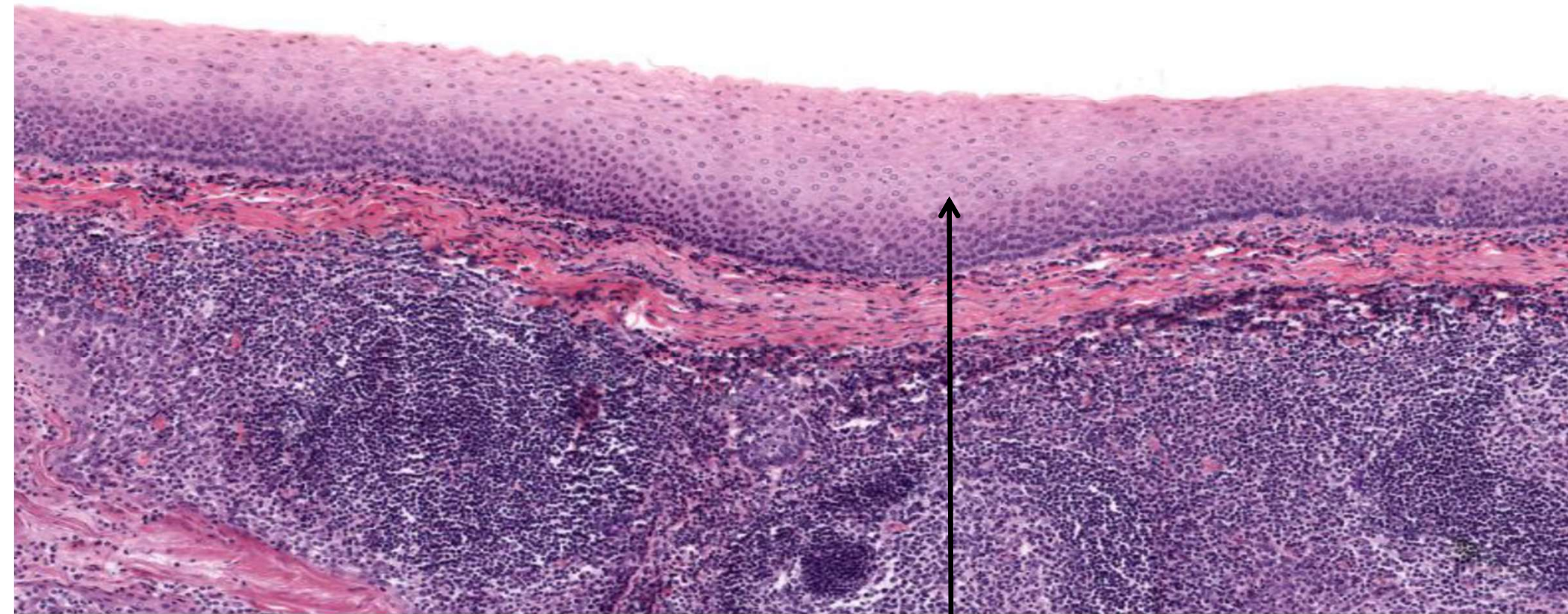
- **Pharyngeal**
 - One tonsil in midline of nasopharynx
 - Surface epithelium: pseudostratified ciliated columnar (sometimes with areas of stratified squamous)
 - Surface has gentle folds but no crypts
 - Thin partial capsule along deep portion

THREE TYPES OF TONSILS

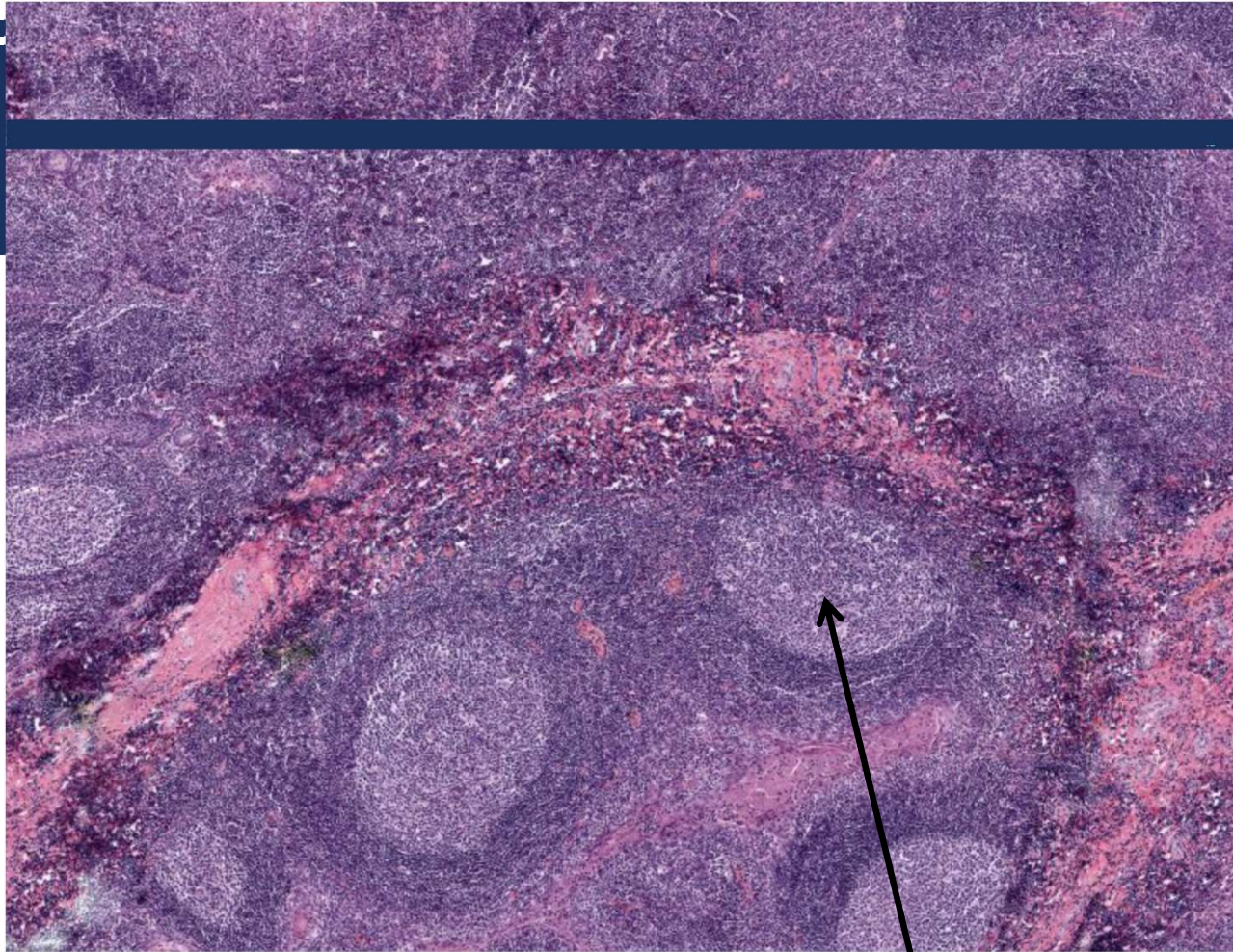
- Pharyngeal
- **Palatine**
 - Two tonsils in lateral oropharynx
 - Surface epithelium: stratified squamous
 - 10-20 deep invaginations (crypts)
 - Thick partial capsule along deep portion



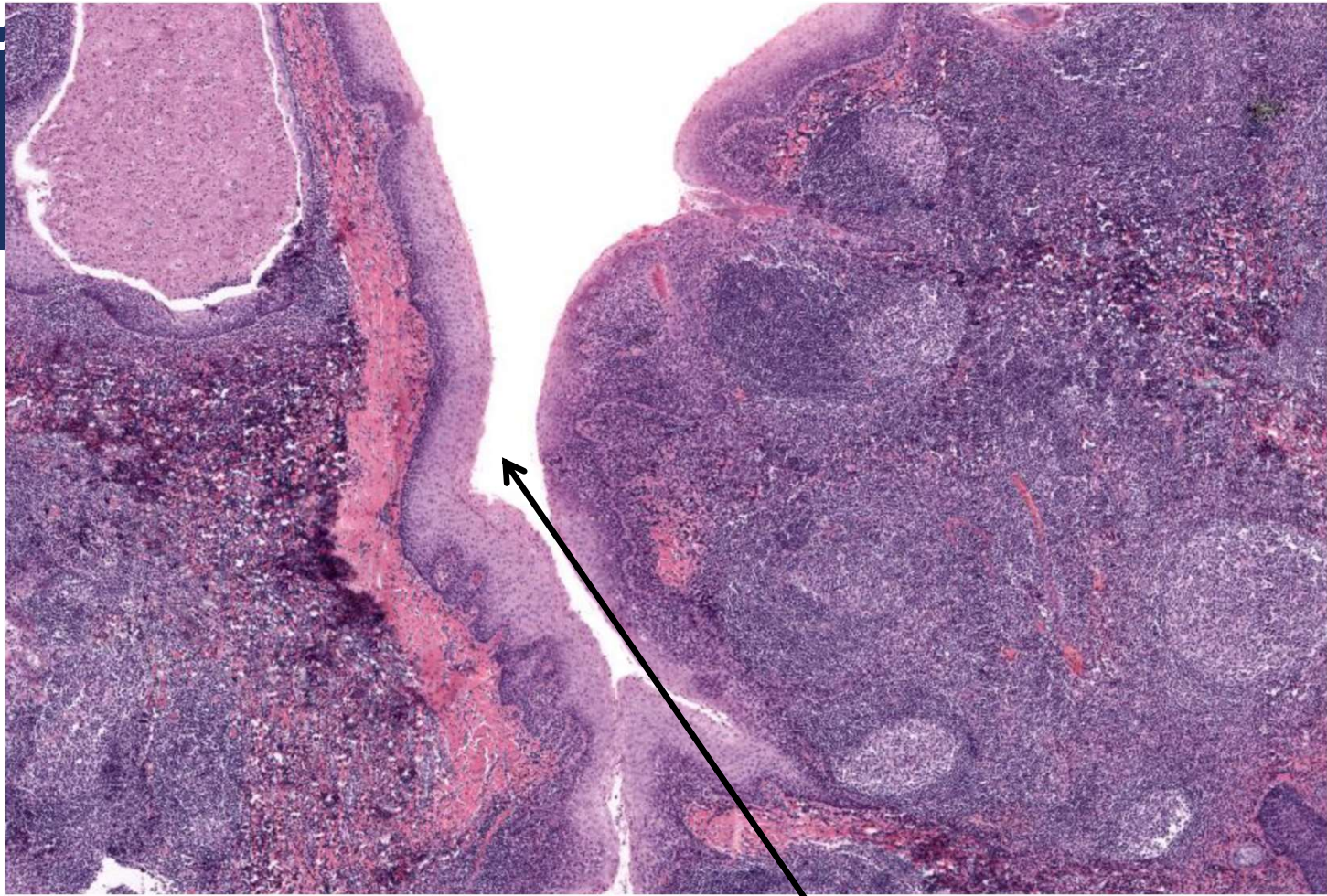
PALATINE TONSIL: SUPER LOW POWER VIEW



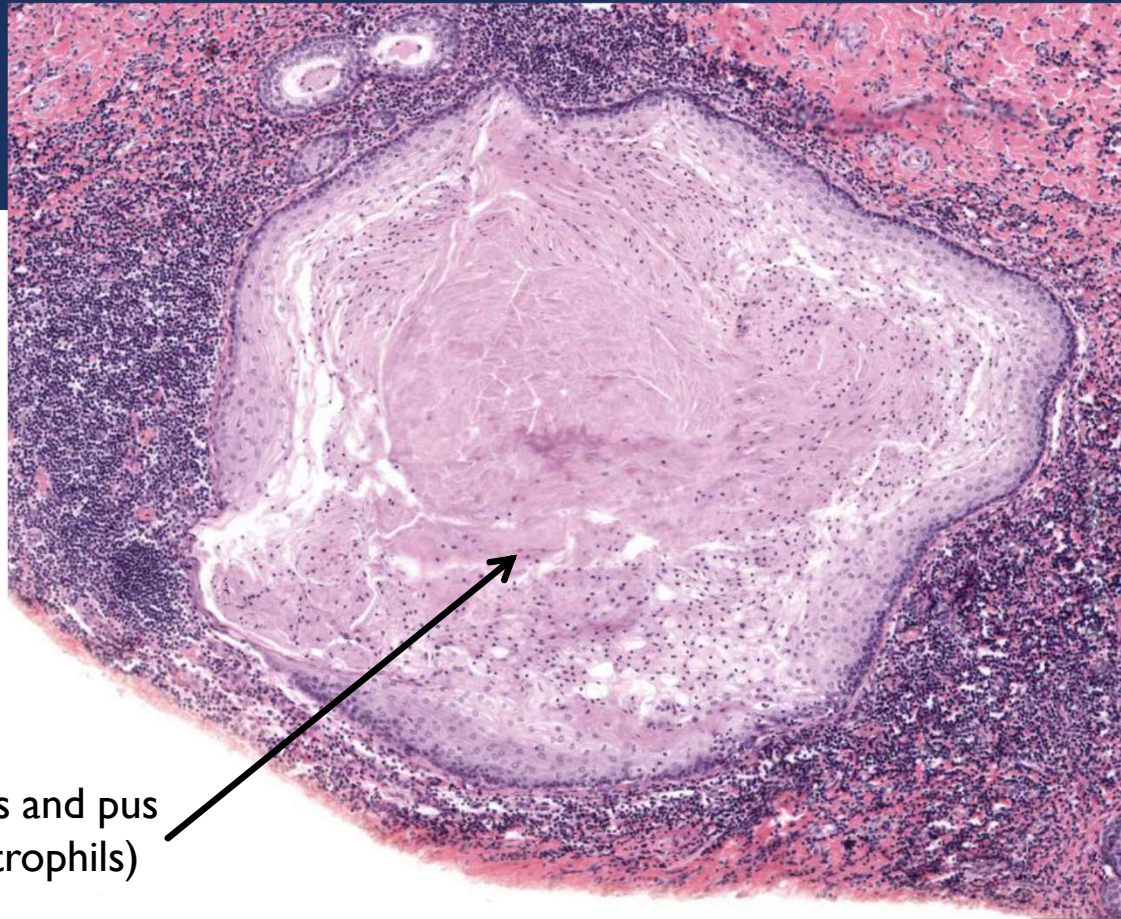
PALATINE TONSIL: STRATIFIED SQUAMOUS EPITHELIUM



PALATINE TONSIL: LYMPHOID FOLLICLES

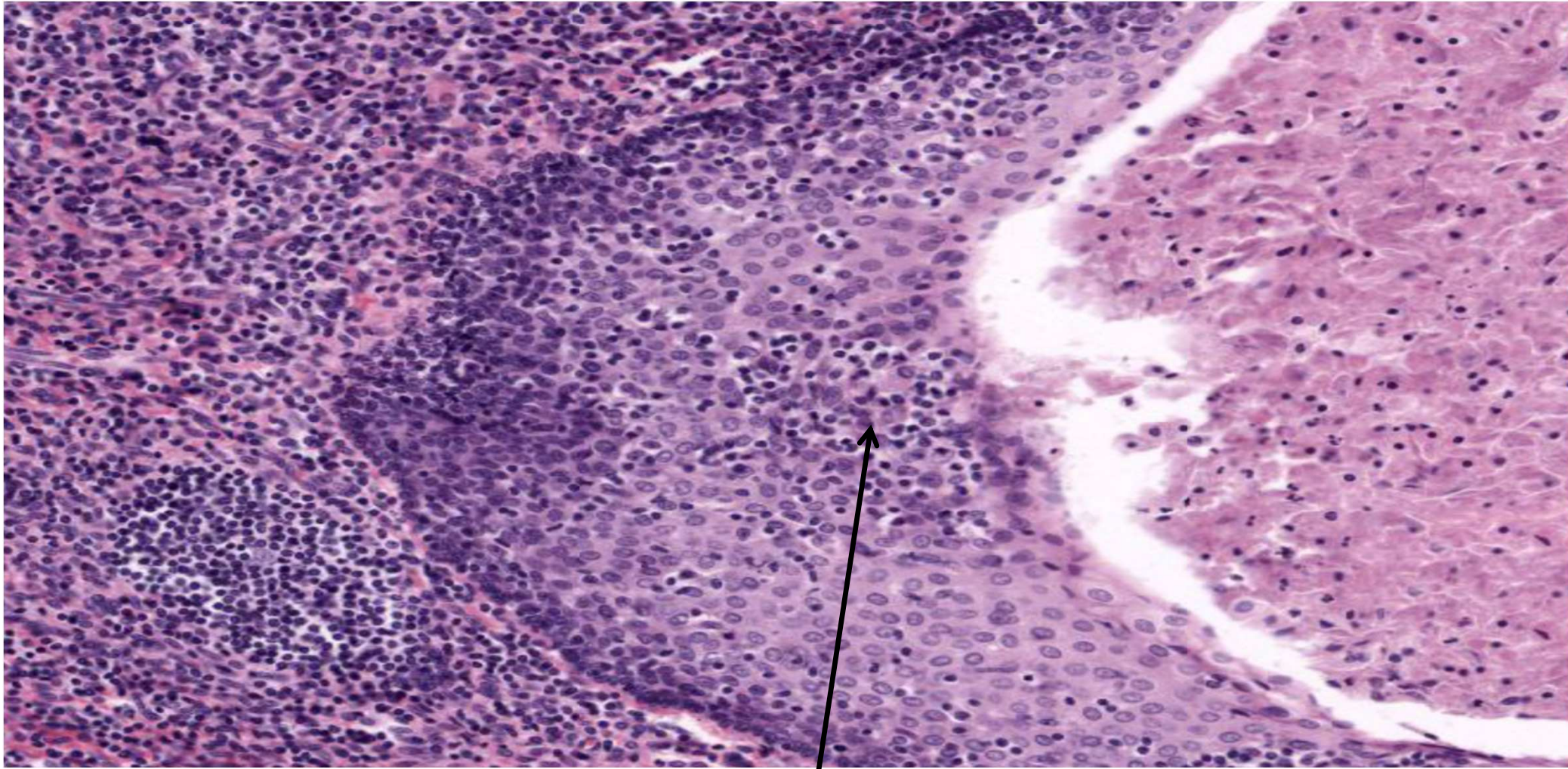


PALATINE TONSIL: CRYPT



Debris and pus
(neutrophils)

PALATINE TONSIL: SEQUESTERED CRYPT



PALATINE TONSIL: LYMPHOCYTES TRAVERSING EPITHELIUM

THREE TYPES OF TONSILS

- Pharyngeal
- Palatine
- **Lingual**
 - Numerous small tonsils at base of tongue
 - Surface epithelium: stratified squamous
 - Each tonsil has one short crypt
 - No capsule
 - Closely associated skeletal muscle and mucous salivary glands